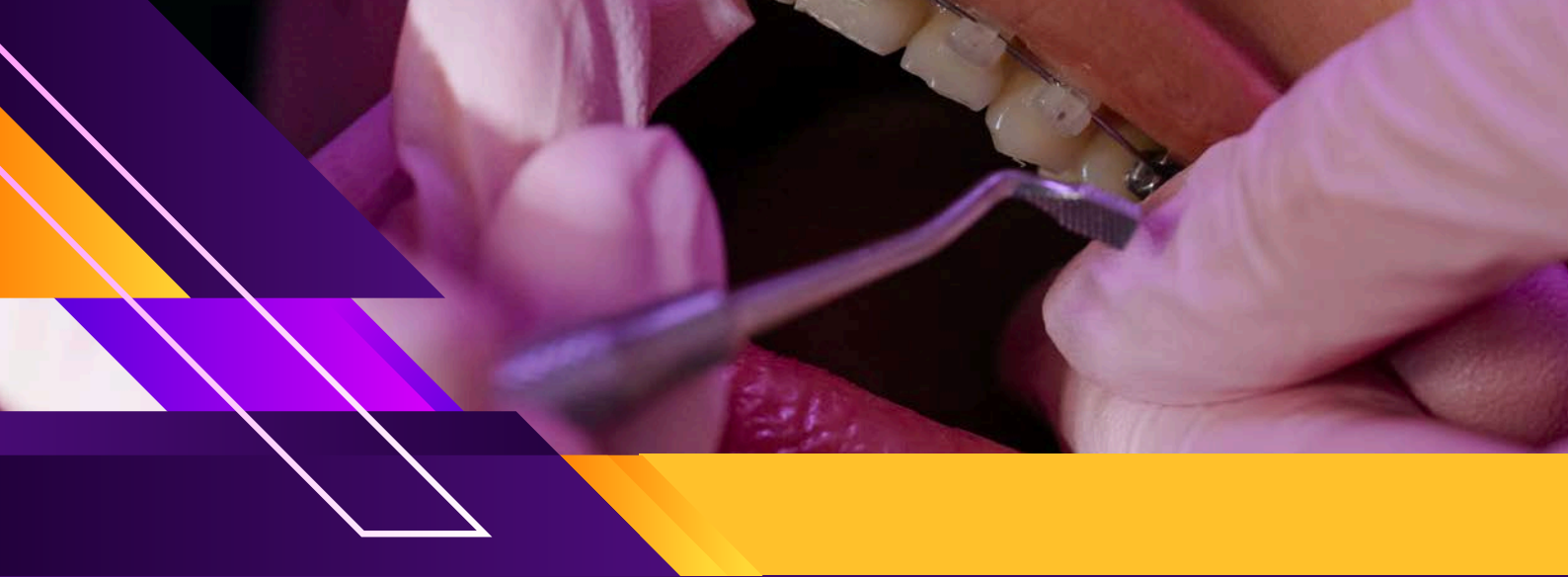



WINSPERT

WINSPERT

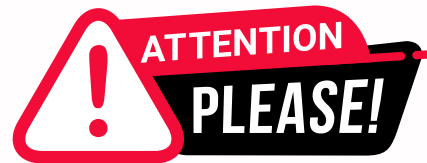# P.O.W.E.R

PREPARATION OF ADC WITH WINSPERT EXPERT REVIEW

# NOTES

By Dr. Jigyasa Sharma





Dear Students,

We'd like to remind you about the importance of respecting the integrity of the resources provided in our app.

Please be aware that **WINSPERT POWERNOTES ARE COPYRIGHTED CONTENT. Unauthorized use, including screenshots, copying, misuse, reuse, or resale of any content from this app, is strictly prohibited.**

**Our app monitors and records all screenshots and recordings. Violators will face strict legal action.**

We're committed to providing you with the best tools for your success, and we appreciate your cooperation in maintaining a fair and secure learning environment.

Thank you for your understanding and continued dedication.

Best regards,  
WINSPERT TEAM

# PROSTHO

## SBQ 1

PATIENT WHO HAS AN UPPER COMPLETE EDENTULOUS ARCH AND LOWER FEW TEETH, HE DOESN'T HAVE UPPER TEETH. AND HAS AN UPPER DENTURE. SAYS DENTURE ROCKING ALONG THE MIDLINE ON FUNCTION AND IS NOT RETENTIVE. 36 AND 46 MISSING AND 37 AND 47 HAVE TILTED IN ITS PLACE. DENTURE WAS DEFICIENT ON BORDER EXTENSIONS. (IN MY STATION IT ONLY SAID DEFICIENT DENTURE, "BORDER EXTENSION" PART WAS NOT THERE) PATIENT COMES AFTER 2-3 WEEKS AND IS NOT SATISFIED WITH DENTURE.

**I. Dentist took an impression of lower arch 10 weeks ago. What did it help him with?**

- A. Making custom tray
- B. To check the skeletal relationship maxilla and mandible
- C. To help with teeth setting and analyse the occlusion
- D. Check centric occlusion and centric relation (this option was not there in my station)

**II. The denture is rocking along the midline, what is the most likely reason?**

- A. Centric relation and centric occlusion not coinciding
- B. Interferences on lateral excursion/ not in laterally balanced occlusion Using
- C. Pressure indicating paste
- D. Pressure on Anterior incisors leading to tipping/ incorrect
- E. Improper curve of spee

**III. Why is denture not retentive? What will you check for that?**

- A. Denture insufficient on Peripheries
- B. Teeth are placed on the centre of the ridge
- C. Lack of soft tissue undercuts on upper ridge
- D. Deficient post dam area

**IV. You did all adjustments multiple visits for this patient and yet she is not happy with the denture. She has paid half and says won't pay till she is happy. What will you do?**

- A. Refer to a prosthodontist and pay her full refund
- B. Reline the denture for free
- C. Make brand new upper denture for free
- D. Refer to your known colleague who is an expert at dentures
- E. Do rebasing for free.

**V. What do you desire when setting teeth?**

- A. Bilaterally balanced occlusion
- B. Group function
- C. Canine Guidance
- D. Vertically balanced 2 dimensional occlusion

### DISCLAIMER

THIS IS COPYRIGHTED CONTENT. Unauthorized use, including screenshots, copying, misuse, reuse, or resale of any content from this app, is strictly prohibited. Our app monitors and records all screenshots and recordings. Violators will face strict legal action.

### DISCLAIMER

THIS IS COPYRIGHTED CONTENT. Unauthorized use, including screenshots, copying, misuse, reuse, or resale of any content from this app, is strictly prohibited. Our app monitors and records all screenshots and recordings. Violators will face strict legal action.

THIS IS COPYRIGHTED CONTENT. Unauthorized use, including screenshots, copying, misuse, reuse, or resale of any content from this app, is strictly prohibited. Our app monitors and records all screenshots and recordings. Violators will face strict legal action.

### DISCLAIMER

# PROSTHO

## P.O.W.E.R NOTES SBQ 1

Upper complete denture and few lower teeth signifies combination syndrome. In combination syndrome some teeth may be supra erupted and there may be excessive bone resorption in the opposed arch. So, it's difficult to bring teeth in occlusion and fabricate dentures.

There is denture rocking /dislodgment. Dislodgement happens either because of **lack of retention** or because of the **occlusal interference**.

If the denture is only **rocking in function means, there's no lack of retention**. Because lack of retention leads to rock the denture even not in function/at the rest mode.

If the **denture rocks in both function and rest, then it's due to lack of retention**.

There may be,

- an error with the impression
- tissue surface of the denture might be having the problem
- deficient post dam area
- flabby ridge
- denture insufficient on the periphery

So, **rocking in the function** is associated with occlusal interference and not associated with the periphery of the denture or the denture base.

- I. Lower impression is still needed to establish the occlusion. Lower arch impression is still needed when you are creating a denture for the upper arch to set the teeth and analyse occlusion. When lower teeth are present, lower teeth will act as a guide rather than the standard of the teeth setting.

It will also help to create a custom tray when you take the primary impression. It will also help to reconfirm the jaw relation and establish it on the articulator and check for the various relationships. But the most important factor that the mandibular impression will play in teeth setting.

The Skeletal relation of the maxilla and mandible is established either with the help of the jaw relation in the mouth. (centric relation, VD, horizontal relationship.)

### DISCLAIMER

THIS IS COPYRIGHTED CONTENT. Unauthorized use, including screenshots, copying, misuse, reuse, or resale of any content from this app, is strictly prohibited. Our app monitors and records all screenshots and recordings. Violators will face strict legal action.



# PROSTHO

- II. In edentulous patients we must create bilaterally balanced occlusion. Which means when working side teeth are in contact, even in non-working side of teeth also should come in contact. So that the non-working side doesn't tip. When anterior meet then the posteriors should also meet. So, it doesn't tip posteriorly. When posterior meet then the anterior should also meet. So, the anterior doesn't tip.

The denture doesn't rock anterior- posteriorly. If so the reason behind it is due to the centric occlusion is not coinciding with the centric relation. Because centric relation and centric occlusion is in the antero-posterior plane. So (A) is ruled out.

Pressure indicating paste is easily ruled out as it's not an indicator. It might be needed to check where the problem is.

Pressure on the anterior teeth will lead to tip the posteriors. So, option (D) is ruled out.

Improper curve of spee - when the patient tries to protrude the mandible if the denture rocks posteriorly that's is because there's not enough curve of spee given. So the posteriors don't come in contact in protrusion.

Denture rocking can be of 2 types

1. Antero-posterior rocking
2. Lateral rocking (rocking along the midline)

Antero-posterior rocking happens:

- When centric occlusion and centric relation are not in contact
- Pressure on the anterior incisors leading to tipping
- Improper curve of spee

Lateral rocking (rocking along the midline):

- Interference on the lateral excursion

- III. There's an interference on the lateral excursion, but still you need to check the denture base. You should not only rely on soft tissues for retention. So (C) is ruled out.

Teeth placed on the centre of the ridges may lead to uneven forces on the ridges and uneven resorption. It's more important in distribution of forces and preservation of alveolar ridge. So, option (B) is ruled out.

Primary source of retention comes from denture extension and denture periphery. So, the answer should be (A) or (D). but (A) is superior to (D) because post dam is one of the peripheries.

## DISCLAIMER

THIS IS COPYRIGHTED CONTENT. Unauthorized use, including screenshots, copying, misuse, reuse, or resale of any content from this app, is strictly prohibited. Our app monitors and records all screenshots and recordings. Violators will face strict legal action.

## DISCLAIMER

THIS IS COPYRIGHTED CONTENT. Unauthorized use, including screenshots, copying, misuse, reuse, or resale of any content from this app, is strictly prohibited. Our app monitors and records all screenshots and recordings. Violators will face strict legal action.

THIS IS COPYRIGHTED CONTENT. Unauthorized use, including screenshots, copying, misuse, reuse, or resale of any content from this app, is strictly prohibited. Our app monitors and records all screenshots and recordings. Violators will face strict legal action.

## DISCLAIMER

# PROSTHO

IV. Even referral is a part of your treatment. You should not waste patient's time and your time. Should not lead the patient to frustration. So, refer to the prosthodontist and refund the money. As patient has wasted time and multiple visits for an incomplete work. Combination syndrome is out of scope for a general dentist.

Rebasing and rebasing the denture will not change the occlusion.

V. (B) and (C) are for the dentate patients. Bilaterally balance occlusion for the edentulous patients.

THIS IS COPYRIGHTED CONTENT. Unauthorized use, including screenshots, copying, misuse, reuse, or resale of any content from this app, is strictly prohibited. Our app monitors and records all screenshots and recordings. Violators will face strict legal action.

THIS IS COPYRIGHTED CONTENT. Unauthorized use, including screenshots, copying, misuse, reuse, or resale of any content from this app, is strictly prohibited. Our app monitors and records all screenshots and recordings. Violators will face strict legal action.

THIS IS COPYRIGHTED CONTENT. Unauthorized use, including screenshots, copying, misuse, reuse, or resale of any content from this app, is strictly prohibited. Our app monitors and records all screenshots and recordings. Violators will face strict legal action.

## DISCLAIMER

THIS IS COPYRIGHTED CONTENT. Unauthorized use, including screenshots, copying, misuse, reuse, or resale of any content from this app, is strictly prohibited. Our app monitors and records all screenshots and recordings. Violators will face strict legal action.

DISCLAIMER  
THIS IS COPYRIGHTED CONTENT. Unauthorized use, including screenshots, copying, misuse, reuse, or resale of any content from this app, is strictly prohibited. Our app monitors and records all screenshots and recordings. Violators will face strict legal action.

# PROSTHO

## SBQ 2

MALE PATIENT COMES TO GET HIS TREATMENT DONE AS PART OF WORK COMPENSATION COVER BECAUSE HE SLIPPED WHILE DOING DUTY ON WORK. HE HAS SEEN ANOTHER DENTIST TO MAKE AN INSURANCE CLAIM. CLINICAL PHOTO SHOWS PHOTO OF UPPER AND LOWER ANTERIORS, 12 NORMAL, REST OF DENTITION SEEM TO HAVE ATTRITION AND CHIPPED. HE WANTS YOU TO HAVE A LOOK. PATIENT SAYS MY TEETH CHIPPED OFF AND MY LOWER DENTURE GOT BROKEN AS A RESULT OF FALLING. YOU EXAMINE.

MEDICAL HISTORY WAS GIVEN (NOT SURE EITHER STRESS OR SOME HISTORY OF BRUXISM WAS THERE TOO) ALSO WANTS TO KNOW ABOUT BLEACHING HIS TEETH. (MENTIONED KEYWORDS CHIPPED AND BROKEN DOWN) YOU EXAMINE HIM AND REALIZE THAT MOST OF HIS DENTAL CONDITION IS NOT A RESULT OF INJURY. HIS LOWER FLEXIBLE ACRYLIC DENTURE IS BROKEN, THE OTHER DENTIST MADE A CLAIM FOR THE PATIENT SO HE ALSO GETS MONEY TO REPAIR HIS OTHER TEETH. (PICTURE OF THE DENTURES PROVIDED)

### I. What would be the ideal treatment for him?

- A. Repair the flexible denture
- B. New cobalt chrome RPD
- C. Make him a new acrylic denture Implant supported removable denture Implant
- D. Supported bridge

### II. Even though his dental condition is not a result of injury, another dentist is willing to cover it all under his work cover so that the company can pay and the patient can get a larger compensation for his dental treatment. He shows you a slip in which this is written. How do you handle that claim for the insurance in the situation?

- A. Do the same what the other dentist did to avoid reputation damage
- B. Report the dentist to Ada
- C. Report the dentist to Ahpra
- D. Contact the other dentist and inquire about the whole thing
- E. Report to work cover Australia
- F. Refuse to cover the work in insurance bill which was not due to the fall.

### III. The same patient was also interested in bleaching. But according to your findings and diagnosis, his dentition needs a lot of work to be done and he is not a suitable candidate for the above mentioned treatment because of current dental health. What advice will you give to the patient?

- A. Discuss with the patient that other treatment needs to be done before we proceed with bleaching.
- B. Refer to prosthodontist
- C. Go ahead with the treatment
- D. Refuse to do treatment

#### DISCLAIMER

THIS IS COPYRIGHTED CONTENT. Unauthorized use, including screenshots, copying, misuse, reuse, or resale of any content from this app, is strictly prohibited. Our app monitors and records all screenshots and recordings. Violators will face strict legal action.

#### DISCLAIMER

THIS IS COPYRIGHTED CONTENT. Unauthorized use, including screenshots, copying, misuse, reuse, or resale of any content from this app, is strictly prohibited. Our app monitors and records all screenshots and recordings. Violators will face strict legal action.

#### DISCLAIMER

THIS IS COPYRIGHTED CONTENT. Unauthorized use, including screenshots, copying, misuse, reuse, or resale of any content from this app, is strictly prohibited. Our app monitors and records all screenshots and recordings. Violators will face strict legal action.

# PROSTHO

## IV. What should be the management of his worn down dentition?

- A. Refer to prosthodontist
- B. Add composites build up on anterior and oral rehabilitation
- C. Give him ceramic crowns
- D. Give him ceramic veneer

## V. Patient complains of sensitivity. What test would you conduct for your treatment?

- A. Probing
- B. IOPA
- C. Pulp sensitivity
- D. Percussion

### P.O.W.E.R NOTES SBQ 2

I. For bruxers cobalt chrome denture is ideal compared to acrylic or flexible dentures to withstand the occlusal forces. Repairing a flexible denture is quite difficult and due to heavy bruxing forces it will be difficult for it to withstand forces. Denture implant supported bridge will be expensive.

II. We don't know whether the provided document is legit or not. And, you don't need to contact the other dentist to know about this. You don't have to follow the same procedure what another dentist is doing. Follow the ethics. So, answer is (F).

III. According to your findings and diagnosis the patient needs to get many dental treatments. Therefore, he's not a suitable candidate for the bleaching treatment because of the current dental health. Dentinal tubules should be sealed, and other required restorations should be completed as bleaching can lead to necrosis of the exposed teeth. So best option is (A).

IV. Worn down dentition may require reorganised/confirmatory approach. And he wears an RPD. Now there's an opportunity to build up the vertical dimensions and build a new RPD and do full mouth rehabilitation. So, it's a complex situation to handle. It's good to refer complex cases (full mouth rehabilitation, implant placement, combination syndrome, crown lengthening) to the specialist.

V. In case of sensitivity, it's always advised to use pulp sensibility test to identify the tooth and to check for the pulp vitality. Pulp sensibility test is an important test to perform before doing an RCT or before giving crowns.

### DISCLAIMER

THIS IS COPYRIGHTED CONTENT. Unauthorized use, including screenshots, copying, misuse, reuse, or resale of any content from this app, is strictly prohibited. Our app monitors and records all screenshots and recordings. Violators will face strict legal action.



# PROSTHO

## SBQ 3

ANOTHER QUESTION WAS THE PATIENT THAT I THINK HAD COMBINATION SYNDROME AND WE ARE GOING TO CONSTRUCT A LOWER CHROME COBALT CLASS I PARTIAL DENTURE AND WAS ASKED IF: (POSTERIOIRS MISSING ON BOTH SIDES, PICTURE OF THE RIDGE GIVEN)

### I. What classification is this?

- A. Kennedy Class I mucosa and tooth supported
- B. Kennedy class I mucosa supported
- C. Kennedy class ii mucosa and tooth supported
- D. Kennedy class ii mucosa supported

### II. What type occlusion will u prefer in combination syndrome patient?

- A. Bilaterally balanced occlusion
- B. Group function
- C. Canine guided
- D. Mutually protected occlusion

### III. Overdenture case: what will be the advantage of overdenture over conventional complete dentures? What will you advise regarding the patient's perspective for aesthetic and functional purpose?

- A. Preservation of alveolar ridge
- B. Patient compliance
- C. Patience psychological rescue of not losing teeth
- D. Maintain vdo

THIS IS COPYRIGHTED CONTENT. Unauthorized use, including screenshots, copying, misuse, reuse, or resale of any content from this app, is strictly prohibited. Our app monitors and records all screenshots and recordings. Violators will face strict legal action.

#### DISCLAIMER

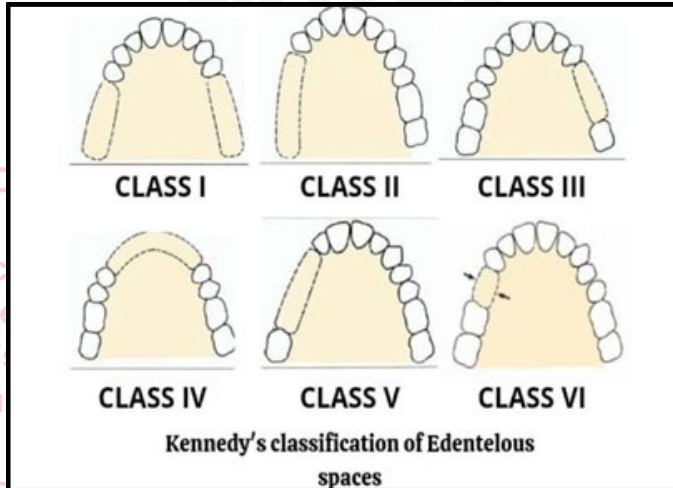
THIS IS COPYRIGHTED CONTENT. Unauthorized use, including screenshots, copying, misuse, reuse, or resale of any content from this app, is strictly prohibited. Our app monitors and records all screenshots and recordings. Violators will face strict legal action.

DISCLAIMER  
THIS IS COPYRIGHTED CONTENT. Unauthorized use, including screenshots, copying, misuse, reuse, or resale of any content from this app, is strictly prohibited. Our app monitors and records all screenshots and recordings. Violators will face strict legal action.

# PROSTHO

## P.O.W.E.R NOTES SBQ 3

- I. No RPD is completely mucosa supported because we use clasps for the abutments for the support. So, its tooth mucosa supported. CD are the completely mucosa supported. It's a class I Kennedy's situation as it's bilaterally distal extension.



- II. In combination syndrome maxilla is completely edentulous, in completely edentulous cases always bilateral balance occlusion is given. Bilaterally balanced occlusion is a method of retention in function in edentulous cases. C, D, E options are used in replacing 1 or 2 teeth in case of FPD.
- III. Overdentures have several advantages over conventional complete dentures, primarily due to the retention of some natural teeth or the use of dental implants.

Here are some key advantages:

- Improved Retention and Stability
- Preservation of Bone
- Enhanced Chewing Efficiency
- Improved Comfort
- Better Aesthetics
- Proprioception
- Psychological Benefits

Among all preservation of alveolar ridge is the most important biological benefit.

### DISCLAIMER

THIS IS COPYRIGHTED CONTENT. Unauthorized use, including screenshots, copying, misuse, reuse, or resale of any content from this app, is strictly prohibited. Our app monitors and records all screenshots and recordings. Violators will face strict legal action.

DISCLAIMER  
THIS IS COPYRIGHTED CONTENT. Unauthorized use, including screenshots, copying, misuse, reuse, or resale of any content from this app, is strictly prohibited. Our app monitors and records all screenshots and recordings. Violators will face strict legal action.

THIS IS COPYRIGHTED CONTENT. Unauthorized use, including screenshots, copying, misuse, reuse, or resale of any content from this app, is strictly prohibited. Our app monitors and records all screenshots and recordings. Violators will face strict legal action.

DISCLAIMER

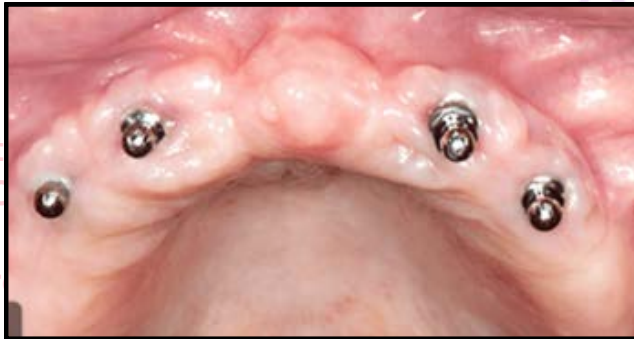# PROSTHO

## SBQ 4

**OVERDENTURE CASE. A 65 YEAR OLD FEMALE WHO IS NEW TO YOUR PRACTICE CAME BECAUSE SHE IS HAVING SOME DISCOMFORT WITH HER TOOTH RETAINED UPPER DENTURE. SHE IS OTHERWISE FIT AND WELL YOU HAVE CHECKED THE SOFT TISSUES AND DENTURES, UPPER DENTURE LOOKS GOOD WHILE IN REST.**

### I. Upper denture gets loose while in function, what is the likely cause?

- A. There is flabby tissue on the tuberosity
- B. Problem in the occlusion check and re do it
- C. Compromised retained tooth



### II. Case where you were going to extract tooth 41. After IAN block injection, long buccal nerve block was also given using correct technique and LA quantity, the patient complains he can still feel pain around the area. How will you complement anesthesia?

- A. Do another IAN injection on the LHS
- B. Do a mental nerve block
- C. Inject LA locally to 41 buccal and lingual

### III. Before you attempt extraction, what area is most important to check for numbness?

- A. Half lips and tip of the tongue
- B. Lower lip and tongue
- C. Gingiva around the 41
- D. Tongue and floor of the mouth
- E. Does not cross the midline

## DISCLAIMER

THIS IS COPYRIGHTED CONTENT. Unauthorized use, including screenshots, copying, misuse, reuse, or resale of any content from this app, is strictly prohibited. Our app monitors and records all screenshots and recordings. Violators will face strict legal action.

DISCLAIMER  
THIS IS COPYRIGHTED CONTENT. Unauthorized use, including screenshots, copying, misuse, reuse, or resale of any content from this app, is strictly prohibited. Our app monitors and records all screenshots and recordings. Violators will face strict legal action.

THIS IS COPYRIGHTED CONTENT. Unauthorized use, including screenshots, copying, misuse, reuse, or resale of any content from this app, is strictly prohibited. Our app monitors and records all screenshots and recordings. Violators will face strict legal action.

DISCLAIMER

# PROSTHO

## P.O.W.E.R NOTES SBQ 3

- I. Loose denture- either because of **lack of retention** or because of the **occlusal interference**.

If the denture is only **loose in function** means, there's **no lack of retention**. Because lack of retention leads to loose denture even not in function/at the rest mode.

If the denture is loose in both function and rest, then it's due to **lack of retention**. There may be,

- an error with the impression
- tissue surface of the denture might be having the problem
- deficient post dam area
- flabby ridge
- denture insufficient on the periphery

So, **loose denture in the function** is associated with **occlusal interference** and not associated with the periphery of the denture or the denture base.

- II. After giving all the anaesthesia (IAN, long buccal) if still the patient has pain, you should not repeat the same, instead you should give infiltration or intra-ligamentary anaesthesia (supplemental anaesthesia). Most effective supplemental anaesthesia is intra-ligamentary. Infiltration is drawn by a superficial vascularity. Into the PDL is far quicker. PDL intraligamentary is the best answer. That option is not given. So, among the given option (C) is the best.
- III. Lips and tongue will be anaesthetised 1st and gingiva get anaesthetised at last. So, you must wait until the gingiva get anaesthetised. You can't simply proceed extraction even though the lip and tongue are numb.

THIS IS COPYRIGHTED CONTENT. Unauthorized use, including screenshots, copying, misuse, reuse, or resale of any content from this app, is strictly prohibited. Our app monitors and records all screenshots and recordings. Violators will face strict legal action.

### DISCLAIMER

THIS IS COPYRIGHTED CONTENT. Unauthorized use, including screenshots, copying, misuse, reuse, or resale of any content from this app, is strictly prohibited. Our app monitors and records all screenshots and recordings. Violators will face strict legal action.

DISCLAIMER  
THIS IS COPYRIGHTED CONTENT. Unauthorized use, including screenshots, copying, misuse, reuse, or resale of any content from this app, is strictly prohibited. Our app monitors and records all screenshots and recordings. Violators will face strict legal action.



# PROSTHO

## SBQ 5

### ON PORCELAIN #MMF

ON EXAMINATION YOU FIND THE OBVIOUS SIGNS OF BRUXISM. WHAT IS YOUR MANAGEMENT, IF YOU WANT TO RETREAT THE RESTORATION AND DO NOT WANT THIS PROBLEM TO PROGRESS. CANINE WAS INCLUDED IN THE FPD GIVEN IN THE EXAM.

- A. Construct occlusal splint
- B. Give more favorable group function occlusion
- C. Give veneers
- D. Alter the bite to "canine protected" occlusion.

## P.O.W.E.R NOTES SBQ 5

- I. Canine guided/ canine protected occlusion will give more load on canines. So to prevent the load on the canine you will not give canine guided occlusion. Instead you give group function occlusion.

THIS IS COPYRIGHTED CONTENT. Unauthorized use, including screenshots, copying, misuse, reuse, or resale of any content from this app, is strictly prohibited. Our app monitors and records all screenshots and recordings. Violators will face strict legal action.

### DISCLAIMER

THIS IS COPYRIGHTED CONTENT. Unauthorized use, including screenshots, copying, misuse, reuse, or resale of any content from this app, is strictly prohibited. Our app monitors and records all screenshots and recordings. Violators will face strict legal action.

THIS IS COPYRIGHTED CONTENT. Unauthorized use, including screenshots, copying, misuse, reuse, or resale of any content from this app, is strictly prohibited. Our app monitors and records all screenshots and recordings. Violators will face strict legal action.

THIS IS COPYRIGHTED CONTENT. Unauthorized use, including screenshots, copying, misuse, reuse, or resale of any content from this app, is strictly prohibited. Our app monitors and records all screenshots and recordings. Violators will face strict legal action.

DISCLAIMER  
THIS IS COPYRIGHTED CONTENT. Unauthorized use, including screenshots, copying, misuse, reuse, or resale of any content from this app, is strictly prohibited. Our app monitors and records all screenshots and recordings. Violators will face strict legal action.

# PROSTHO

## SBQ 6

**WHAT IS MOST IMPORTANT RADIOLOGICAL CHARACTERISTIC OF CBCT/OPG (ONLY IN FEW CENTERS) IMAGING FOR IMPLANT?**

- A. Accuracy in linear measurement
- B. Superimposition of anatomic structures
- C. Breadth of the image
- D. High resolution

## P.O.W.E.R NOTES SBQ 6

- I. Breadth of the image and high resolution get covered under accuracy in linear measurement. Accuracy in linear measurements is one of the critical advantages of Cone Beam Computed Tomography (CBCT), particularly in dental and maxillofacial applications

### CLINICAL APPLICATIONS:

- In dental implantology, accurate linear measurements are crucial for assessing the height, width, and density of the alveolar bone.
- In orthodontics, precise measurements are required for evaluating tooth positions, root alignment, and planning corrective procedures.
- In maxillofacial surgery, accurate measurements are essential for pre-surgical planning and postoperative assessment.

THIS IS COPYRIGHTED CONTENT. Unauthorized use, including screenshots, copying, misuse, reuse, or resale of any content from this app, is strictly prohibited. Our app monitors and records all screenshots and recordings. Violators will face strict legal action.

### DISCLAIMER

THIS IS COPYRIGHTED CONTENT. Unauthorized use, including screenshots, copying, misuse, reuse, or resale of any content from this app, is strictly prohibited. Our app monitors and records all screenshots and recordings. Violators will face strict legal action.

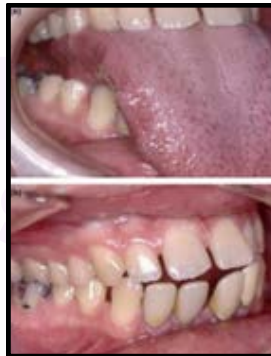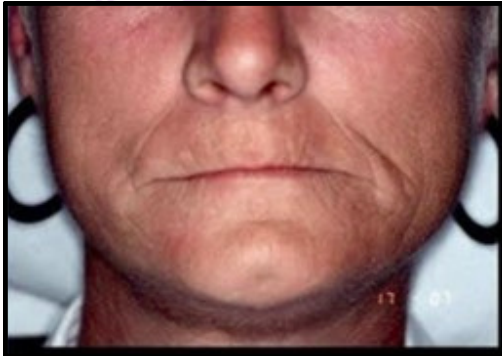THIS IS COPYRIGHTED CONTENT. Unauthorized use, including screenshots, copying, misuse, reuse, or resale of any content from this app, is strictly prohibited. Our app monitors and records all screenshots and recordings. Violators will face strict legal action.

DISCLAIMER  
THIS IS COPYRIGHTED CONTENT. Unauthorized use, including screenshots, copying, misuse, reuse, or resale of any content from this app, is strictly prohibited. Our app monitors and records all screenshots and recordings. Violators will face strict legal action.

THIS IS COPYRIGHTED CONTENT. Unauthorized use, including screenshots, copying, misuse, reuse, or resale of any content from this app, is strictly prohibited. Our app monitors and records all screenshots and recordings. Violators will face strict legal action.

# PROSTHO

## SBQ 7



**DID NOT GET THIS PICTURE IN MY EXAM, PICTURE WAS DIFFERENT. QUESTION ALSO GAVE A SECTION (PT RIGHT POST) VIEW OF THE OPG. PHOTO WAS SIMILAR.**

**ON THE OPG NO RESORPTION OR ANY COMPLICATIONS COULD BE SEEN.**

**I. You see a major complicating factor with constructing dentures in this patient. What do you think can cause aesthetic problems by looking at the photo? No major problems seen on clinical pic.**

- A. Tight Lower Lip
- B. Reverse smile line
- C. Prominent Mentalis
- D. Decreased VDO

**II. What group of muscles will have an effect on making an impression?**

- A. Orbicularis muscle
- B. Mentalis muscle
- C. Geniohyoid

**III. You are going to make a denture. What additional information is needed?**

- A. Photo and opg provide adequate information
- B. Ask the lab tech to do a occlusal analysis of the master cast
- C. An articulated study cast on semi -adjustable articulator for occlusal analysis
- D. Clinical assessment

**IV. How can you prolong setting time for Alginate imp without affecting its physical properties?**

- A. Add more powder than water
- B. Add more water than powder
- C. Decrease the water temperature
- D. Decrease spatulation speed

**V. Patient got burns after taking impressions which one material give burning.**

- A. Polyvinyl Siloxane compound material
- B. Alginate
- C. Zinc oxide eugenol

### DISCLAIMER

THIS IS COPYRIGHTED CONTENT. Unauthorized use, including screenshots, copying, misuse, reuse, or resale of any content from this app, is strictly prohibited. Our app monitors and records all screenshots and recordings. Violators will face strict legal action.

### DISCLAIMER

THIS IS COPYRIGHTED CONTENT. Unauthorized use, including screenshots, copying, misuse, reuse, or resale of any content from this app, is strictly prohibited. Our app monitors and records all screenshots and recordings. Violators will face strict legal action.

THIS IS COPYRIGHTED CONTENT. Unauthorized use, including screenshots, copying, misuse, reuse, or resale of any content from this app, is strictly prohibited. Our app monitors and records all screenshots and recordings. Violators will face strict legal action.

### DISCLAIMER

# PROSTHO

## P.O.W.E.R NOTES SBQ 7

- I. Lower lip seems to be tight and reverse smile line is seen. Though reduced VDO gives aesthetic problems, it is not challenging as it can be corrected. Prominent mentalis is challenging. It can give inverted/ protruded lip appearance. Even though you do changes in the denture you can't correct this. Prominent mentalis can lead to excessive protrusion of the lower lip.
- II. Mentalis muscle helps in tightening the labial vestibule a the labial vestibule is surrounded by the mentalis muscle.  
In case of hyperactive mentalis muscle situation, the lower lip seems to be very tight and the labial vestibular depth is uneven due to the excessive muscle force. If you try to get the impression in the hyperactive muscle situation, you won't be able to record the full extent of the vestibular depth. We need to relax the patient and make sure that the lower lip is loose while we are making the impression and border moulding as it goes deep into the labial vestibule. That's where the full retention comes from.
- III. Photos and OPG will not provide adequate information. Still you are at the information gathering stage so master casts and articulated study casts are not made yet. So, after photographs and OPG, clinical assessment is more important.
- IV. Anytime you control the water: powder ratio, it affects the physical property. So, option (A) and (B) are ruled out. Decreasing spatulation speed will lead to an incomplete mix/ non homogenous mixture and can lead to bubble formation and various discrepancy. Using cold water will be helpful in increasing the setting time.
- V. Option (A) and (B) are safe materials but eugenol causes mild irritation in certain patients.

THIS IS COPYRIGHTED CONTENT. Unauthorized use, including screenshots, copying, misuse, reuse, or resale of any content from this app, is strictly prohibited. Our app monitors and records all screenshots and recordings. Violators will face strict legal action.

### DISCLAIMER

THIS IS COPYRIGHTED CONTENT. Unauthorized use, including screenshots, copying, misuse, reuse, or resale of any content from this app, is strictly prohibited. Our app monitors and records all screenshots and recordings. Violators will face strict legal action.

THIS IS COPYRIGHTED CONTENT. Unauthorized use, including screenshots, copying, misuse, reuse, or resale of any content from this app, is strictly prohibited. Our app monitors and records all screenshots and recordings. Violators will face strict legal action.

THIS IS COPYRIGHTED CONTENT. Unauthorized use, including screenshots, copying, misuse, reuse, or resale of any content from this app, is strictly prohibited. Our app monitors and records all screenshots and recordings. Violators will face strict legal action.

DISCLAIMER  
THIS IS COPYRIGHTED CONTENT. Unauthorized use, including screenshots, copying, misuse, reuse, or resale of any content from this app, is strictly prohibited. Our app monitors and records all screenshots and recordings. Violators will face strict legal action.

DISCLAIMER

THIS IS COPYRIGHTED CONTENT. Unauthorized use, including screenshots, copying, misuse, reuse, or resale of any content from this app, is strictly prohibited. Our app monitors and records all screenshots and recordings. Violators will face strict legal action.



# PROSTHO

## SBQ 8

### REGARDING RPD WHERE THEY SAID RPI IS A CHOICE OF CLASP

#### I. Question was: how is given the indirect retention in this RPI system?

- A. Distal occlusal rest on nearest abutment
- B. Mesial occlusal rest
- C. Lingual plate minor connector
- D. Reciprocal arm
- E. Mesial proximal plate

#### II. In that same question it was asked that premolar 44 is used for clasp; it is periodontally weak gingival recession with class 2 mobility but still can be used . So what would be the preferred clasp which is less traumatic and more aesthetic?

- A. Cast clasp suprabulge with  $\frac{1}{3}$  retentive area below the survey line
- B. Cast clasp infrabulge
- C. Wrought clasp with suprabulge
- D. Wrought clasp with infrabulge

recordings. Violators will face strict legal action.

THIS IS COPYRIGHTED CONTENT. Unauthorized use, including screenshots, copying, misuse, reuse, or resale of any content from this app, is strictly prohibited. Our app monitors and records all screenshots and recordings. Violators will face strict legal action.

THIS IS COPYRIGHTED CONTENT. Unauthorized use, including screenshots, copying, misuse, reuse, or resale of any content from this app, is strictly prohibited. Our app monitors and records all screenshots and recordings. Violators will face strict legal action.

#### DISCLAIMER

THIS IS COPYRIGHTED CONTENT. Unauthorized use, including screenshots, copying, misuse, reuse, or resale of any content from this app, is strictly prohibited. Our app monitors and records all screenshots and recordings. Violators will face strict legal action.

DISCLAIMER  
THIS IS COPYRIGHTED CONTENT. Unauthorized use, including screenshots, copying, misuse, reuse, or resale of any content from this app, is strictly prohibited. Our app monitors and records all screenshots and recordings. Violators will face strict legal action.

# PROSTHO

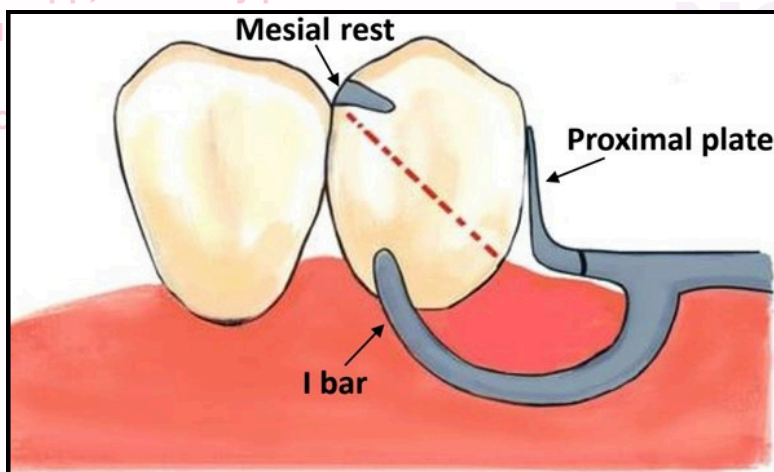
## P.O.W.E.R NOTES SBQ 8

### I. RPI system-Rest/ Proximal plate/ I-Bar

It consists of a mesial rest (R), proximal plate (P), and I-bar retentive arm (I). The proximal plate and mesial rest act as a reciprocating element to prevent lingual tooth migration as the I-bar moves over the tooth. It doesn't have a reciprocal arm.

Indirect retention comes from the **rest component**, either from the auxiliary rest or the mesial rest. That is part of the clasp assembly. Auxiliary rest is placed perpendicular to the most distal fulcrum line on the anterior teeth or on the rest of the part of the clasp.

**Proximal plate** is a component along with the I-bar and it act as the direct retention. It's also for the adaptation. Proximal plate act as a guiding area which guides the RPD into place. And it braces the tooth on the proximal area, that would be either for the guiding or for the direct retention.



### I. In a periodontally compromised tooth which clasp would be preferred?

According to the evidence-based research, the placement of RPDs using **cast clasp** had a significantly greater stabilizing effect on the abutment teeth than use of **wrought wire clasps**. This finding indicates that directly applying a cast clasp to a retainer can stabilize mobile abutment teeth and increase their rigidity. So, option (C) and (D) are ruled out. And (D) answer is incorrect. Wrought clasp doesn't come as infra-bulge.

In **I-bar** limited amount of tooth get touched with the clasp assembly. Lesser the amount of clasp touches lesser the force acting on the tooth. In **circumferential clasp**, the whole retentive/reciprocal arm is touching the tooth surface. So, more force is applied on the tooth. Therefore, less traumatic and more aesthetic clasp among the given is cast clasp infra-bulge.

#### DISCLAIMER

THIS IS COPYRIGHTED CONTENT. Unauthorized use, including screenshots, copying, misuse, reuse, or resale of any content from this app, is strictly prohibited. Our app monitors and records all screenshots and recordings. Violators will face strict legal action.

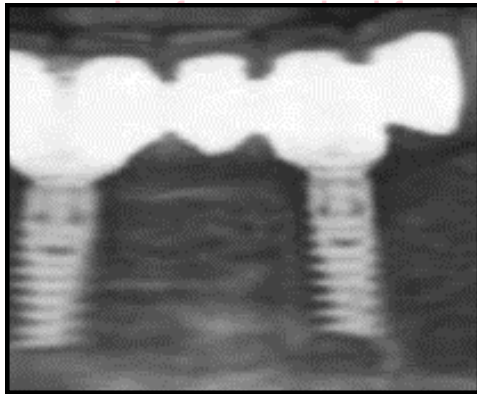
THIS IS COPYRIGHTED CONTENT. Unauthorized use, including screenshots, copying, misuse, reuse, or resale of any content from this app, is strictly prohibited. Our app monitors and records all screenshots and recordings. Violators will face strict legal action.

DISCLAIMER  
THIS IS COPYRIGHTED CONTENT. Unauthorized use, including screenshots, copying, misuse, reuse, or resale of any content from this app, is strictly prohibited. Our app monitors and records all screenshots and recordings. Violators will face strict legal action.

# PROSTHO

## SBQ 9

PATIENT COMPLAINS OF LOOSE PROSTHESIS IN THE LOWER ANTERIOR REGION. ON EXAMINATION YOU SEE A SWELLING IN THE 32 REGION. PATIENT BRUSHES TWICE DAILY WITH A FLUORIDE TOOTHPASTE AND FLOSSES HIS INTERDENTAL REGION ONCE DAILY BUT IS NOT ABLE TO CLEAN 32 REGION. (IMAGE OF A 5 UNIT IMPLANT SUPPORTED FPD GIVEN WITH A CANTILEVER ON 33 AND IMPLANTS AT POSITION 42 AND 32). FPD ON 41,42, 31, 32, 33 (CANTILEVER). RADIOLUCENCY AROUND THE TOP PORTION OF IMPLANTS. CANTILEVER PART, 32, CLEARLY HAD AN OPEN CONTACT AND BONE LOSS AROUND 33 CANTILEVER AND 34 (SOUND TOOTH) AND 42 AREA WAS MASKED BY THE SWOLLEN GUMS. X-RAY: SHOWED PERI IMPLANTITIS AROUND BOTH IMPLANTS UPTO AT LEAST 1/3RD OF IMPLANTS. LOOSE ABUTMENT SCREWS WERE VISIBLE IN BOTH IMPLANTS WITH LOTS OF GAPS ON SIDES AND TOP PARTS.



### I. How should the patient maintain the hygiene under the prosthesis?

- A. Superfloss
- B. Unwaxed floss
- C. Circumferential floss method
- D. Water floss
- E. There's no current conclusive evidence about this matter

### II. The question asked about what hinders the access to maintaining oral hygiene around implant at 32?

- A. Open contact
- B. Food impaction
- C. Periodontitis
- D. Cantilever pontic 33
- E. Swollen gum

#### DISCLAIMER

THIS IS COPYRIGHTED CONTENT. Unauthorized use, including screenshots, copying, misuse, reuse, or resale of any content from this app, is strictly prohibited. Our app monitors and records all screenshots and recordings. Violators will face strict legal action.

#### DISCLAIMER

THIS IS COPYRIGHTED CONTENT. Unauthorized use, including screenshots, copying, misuse, reuse, or resale of any content from this app, is strictly prohibited. Our app monitors and records all screenshots and recordings. Violators will face strict legal action.

THIS IS COPYRIGHTED CONTENT. Unauthorized use, including screenshots, copying, misuse, reuse, or resale of any content from this app, is strictly prohibited. Our app monitors and records all screenshots and recordings. Violators will face strict legal action.

#### DISCLAIMER

# PROSTHO

## III. What is the reason for the mobile bridge

- A. Peri-implant mucositis
- B. Peri-implantitis
- C. Loose abutment screw
- D. Loss of bone
- E. Occlusal overload in the front teeth
- F. No osseointegration
- G. Food Impaction

## IV. What method of mechanical debridement of the implant will be most effective?

- A. Plastic curette for manual debridement
- B. Metal curette
- C. Ultrasonic tip of metal.
- D. Ultrasonic tip of ceramic
- E. Metal brush scraper

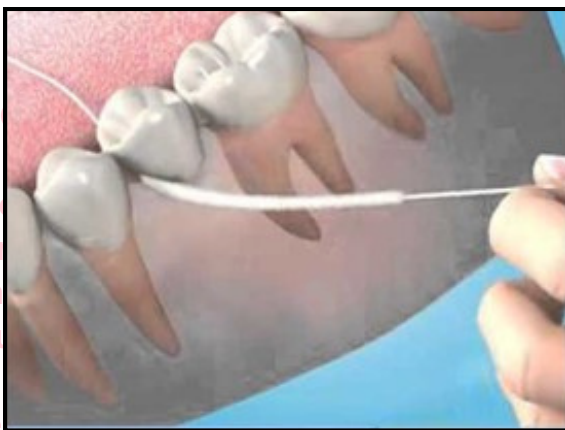## V. When performing SRP, what is the scientifically proven combination with Metronidazole effective in controlling bacterial growth?

- A. Amoxicillin
- B. Doxycycline
- C. Clindamycin

(Lat ceph was quite similar but with missing teeth no occlusion)

### P.O.W.E.R NOTES SBQ 9

- I. It's an implant retained FPD. Can see the swelling in the area of 32. 33 is a cantilever. There's radiolucency and bone loss around implants. In implant retained FPDs, under the prosthesis a stiffer floss is recommended to maintain the OH. It's known as super floss. It's mostly indicated in FPDs.



#### DISCLAIMER

THIS IS COPYRIGHTED CONTENT. Unauthorized use, including screenshots, copying, misuse, reuse, or resale of any content from this app, is strictly prohibited. Our app monitors and records all screenshots and recordings. Violators will face strict legal action.

THIS IS COPYRIGHTED CONTENT. Unauthorized use, including screenshots, copying, misuse, reuse, or resale of any content from this app, is strictly prohibited. Our app monitors and records all screenshots and recordings. Violators will face strict legal action.

DISCLAIMER  
THIS IS COPYRIGHTED CONTENT. Unauthorized use, including screenshots, copying, misuse, reuse, or resale of any content from this app, is strictly prohibited. Our app monitors and records all screenshots and recordings. Violators will face strict legal action.

DISCLAIMER

THIS IS COPYRIGHTED CONTENT. Unauthorized use, including screenshots, copying, misuse, reuse, or resale of any content from this app, is strictly prohibited. Our app monitors and records all screenshots and recordings. Violators will face strict legal action.



# PROSTHO

## P.O.W.E.R NOTES SBQ 9

- II. Open contacts don't hinder as it gives access for maintaining OH.  
Food impaction will lead to bone loss problems in 32 which is present right now.  
There's no access problem with it.  
Patient can maintain OH in pontics.  
Swelling is present on 32 which is due to improper cleaning in the area and will hinder the access to oral hygiene maintenance so answer is Option (E).
- III. Peri-implantitis is the diagnosis. The cause/ aetiology is the loose screws as all the detrimental forces are acting on it. Option (A) and (B) are ruled out.  
Occlusal load is fine as there's no bruxism or no edge to edge occlusion. It's the abutment that can't take up the load. Option (E) is ruled out.  
Loss of bone is not the reason of mobility. Loss of bone is the outcome. The bridge would have started getting loose even before the bone loss because of the loose screw. Patient is maintaining good oral hygiene so that it doesn't lead to bone loss. Option (D) ruled out.  
Osseointegration loss can happen due to 3 reasons; surgical problem during the placement of implants, poor OH maintenance, abutment problem with the screw loosening. Option (F) is ruled out.  
If loose screw is not given in the x-ray or in the history then what would be the reason for the mobile bridge? No osseointegration or no proper OH.
- IV. As a metal only titanium is recommended for mechanical debridement. This answer is not given. The second-best material is the plastic curettes.
- V. According to TG amoxicillin is given along with metronidazole.

THIS IS COPYRIGHTED CONTENT. Unauthorized use, including screenshots, copying, misuse, reuse, or resale of any content from this app, is strictly prohibited. Our app monitors and records all screenshots and recordings. Violators will face strict legal action.

### DISCLAIMER

THIS IS COPYRIGHTED CONTENT. Unauthorized use, including screenshots, copying, misuse, reuse, or resale of any content from this app, is strictly prohibited. Our app monitors and records all screenshots and recordings. Violators will face strict legal action.

DISCLAIMER  
THIS IS COPYRIGHTED CONTENT. Unauthorized use, including screenshots, copying, misuse, reuse, or resale of any content from this app, is strictly prohibited. Our app monitors and records all screenshots and recordings. Violators will face strict legal action.

DISCLAIMER

THIS IS COPYRIGHTED CONTENT. Unauthorized use, including screenshots, copying, misuse, reuse, or resale of any content from this app, is strictly prohibited. Our app monitors and records all screenshots and recordings. Violators will face strict legal action.

# PROSTHO

## SBQ 10

### COMBINATION SYNDROME CASE:

- I. Pt had a very old denture, lower canine to canine present, there was a question about what is the best material and technique to take the **SECONDARY impression of the upper denture with a flabby ridge.**
  - A. Pvs with custom made tray
  - B. Pvs with compound modified custom tray
  - C. 3d intraoral scan
  - D. Alginate with compound modified custom tray
  - E. ZoE in the denture
- II. Which muscle is to be taken care of while construction of the denture in the lower left lingual side?
  - A. Mylohyoid
  - B. Superior constrictor
  - C. Medial pterygoid
  - D. Lateral pterygoid
- III. You constructed a lower cobalt chrome. Patient came with a complaint of loose denture on the left side after 2 weeks. What is the best way to correct this?
  - A. Reline the distal saddle
  - B. Construct new rpd
  - C. Check occlusion and correct it
  - D. Adjust the clasp and denture base
- IV. Pt complains of loose upper denture, loose only during function. Lower canine to canine present with minimal calculus what is the cause of ill fitting denture ? ridge was firm and sound
  - A. Due to canine interference on chewing
  - B. Resorbed anterior ridge

THIS IS COPYRIGHTED CONTENT. Unauthorized use, including screenshots, copying, misuse, reuse, or resale of any content from this app, is strictly prohibited. Our app monitors and records all screenshots and recordings. Violators will face strict legal action.

#### DISCLAIMER

THIS IS COPYRIGHTED CONTENT. Unauthorized use, including screenshots, copying, misuse, reuse, or resale of any content from this app, is strictly prohibited. Our app monitors and records all screenshots and recordings. Violators will face strict legal action.

DISCLAIMER  
THIS IS COPYRIGHTED CONTENT. Unauthorized use, including screenshots, copying, misuse, reuse, or resale of any content from this app, is strictly prohibited. Our app monitors and records all screenshots and recordings. Violators will face strict legal action.

THIS IS COPYRIGHTED CONTENT. Unauthorized use, including screenshots, copying, misuse, reuse, or resale of any content from this app, is strictly prohibited. Our app monitors and records all screenshots and recordings. Violators will face strict legal action.

DISCLAIMER  
THIS IS COPYRIGHTED CONTENT. Unauthorized use, including screenshots, copying, misuse, reuse, or resale of any content from this app, is strictly prohibited. Our app monitors and records all screenshots and recordings. Violators will face strict legal action.

# PROSTHO

## P.O.W.E.R NOTES SBQ 10

- I. For loose flabby ridges PVS with compound modified custom made tray (because you do border moulding) and window technique is the best. Retention is better with PVS compared to 3D intra oral scan.
- II.
  - Lower lingual side of the mouth- mylohyoid muscle creates the floor of the mouth.
  - Superior constrictor muscle is the most posterior in the pharynx.
  - Medial and lateral pterygoid muscles are the condylar muscles.
- III.
  - After 2 weeks' time the denture is loose. So, u must check for the retentive components.
  - Resorption will not happen drastically in 2 weeks to make the denture loose. So relining is not indicated. Option (A) is ruled out.
  - Occlusion would have been the problem from day 1 or day 2. It is not loose on function. So, occlusion is not the problem. It's a loose denture on a side always. When looseness present always we must check for the retention. If looseness present only during the function, then the answer would be (C). option (C) is ruled out.
- IV. Denture is loose only during the function. So, there must be an occlusion interference. You can't give canine guided occlusion in combination syndrome. It will lead to canine interference on chewing. You can't give group function occlusion in combination syndrome. It should be bilaterally balance occlusion.

THIS IS COPYRIGHTED CONTENT. Unauthorized use, including screenshots, copying, misuse, reuse, or resale of any content from this app, is strictly prohibited. Our app monitors and records all screenshots and recordings. Violators will face strict legal action.

### DISCLAIMER

THIS IS COPYRIGHTED CONTENT. Unauthorized use, including screenshots, copying, misuse, reuse, or resale of any content from this app, is strictly prohibited. Our app monitors and records all screenshots and recordings. Violators will face strict legal action.

DISCLAIMER  
THIS IS COPYRIGHTED CONTENT. Unauthorized use, including screenshots, copying, misuse, reuse, or resale of any content from this app, is strictly prohibited. Our app monitors and records all screenshots and recordings. Violators will face strict legal action.

DISCLAIMER

THIS IS COPYRIGHTED CONTENT. Unauthorized use, including screenshots, copying, misuse, reuse, or resale of any content from this app, is strictly prohibited. Our app monitors and records all screenshots and recordings. Violators will face strict legal action.

# PROSTHO

## SBQ 11

THERE WAS A PICTURE GIVEN IN WHICH IT SHOWED REDUCED INTER OCCLUSAL SPACE IN THE POSTERIORES AS THE LOWER RIGHT SIDE POSTERIOR TEETH WERE MISSING. BUT THE UPPER RIGHT SIDE POSTERIOR TEETH WERE NOT SHOWING ANY EXTRUSION

- I. With the first picture what can you see? (first picture was especially mentioned showing asymmetry of lips)
  - A. Reverse smile line
  - B. Resorption of ridge
  - C. Reduced vdo
  - D. Hyperactive mentalis
  - E. Tight lower lip
- II. A second photograph provided: The whole upper right posterior segment was extruded including the bone and gingiva. Lower right edentulous ridge with reduced interocclusal distance. what is the reason for losing inter occlusal distance?
  - A. Attrition of anterior teeth
  - B. Dento alveolar extrusion of whole maxillary segment with attachment loss
  - C. Postero-inferior collapse of maxilla (some had maxilla effected)
  - D. Hypertrophy of mandible (kind of visible in radiograph) (some has mandible affected)
- III. They also asked what was the best method to measure the re-established VDO?
  - A. By reducing freeway space by 1 mm
  - B. Recording VDO in by various methods
  - C. By asking the patient to pronounce M and measure from the third molar distance.
  - D. Or by increasing the VDR more than freeway space.

THIS IS COPYRIGHTED CONTENT. Unauthorized use, including screenshots, copying, misuse, reuse, or resale of any content from this app, is strictly prohibited. Our app monitors and records all screenshots and recordings. Violators will face strict legal action.

### DISCLAIMER

THIS IS COPYRIGHTED CONTENT. Unauthorized use, including screenshots, copying, misuse, reuse, or resale of any content from this app, is strictly prohibited. Our app monitors and records all screenshots and recordings. Violators will face strict legal action.

DISCLAIMER  
THIS IS COPYRIGHTED CONTENT. Unauthorized use, including screenshots, copying, misuse, reuse, or resale of any content from this app, is strictly prohibited. Our app monitors and records all screenshots and recordings. Violators will face strict legal action.



# PROSTHO

## P.O.W.E.R NOTES SBQ 11

- I. According to the picture it's a protruded lip it's due to the hyperactive mentalis as mentioned above.
- II. Lower right-side posterior teeth were missing. So, it's Kennedy's class II. Upper right-side posterior teeth had reduced inter occlusal space. But there's no extrusion of the upper right-side posteriors. OPG was given and not showing any bone loss or extrusion of teeth. So, option (B) is ruled out.  
It's not the hypertrophy of mandible rather than atrophy due to excessive maxillary forces. So, option (D) is ruled out.
- III. We don't measure VDO by using only 1 method. VDO keeps changing. You will use various methods to measure VDO to get an average value.

Reference: **ADA article -clinical considerations for increasing occlusal vertical dimension-page no 3.** "it has been suggested that in order to improve the accuracy of the recording procedure (VDO) more than 1 method should be used."

# PROSTHO

## SBQ 12

**WHAT IS MOST IMPORTANT RADIOLOGICAL CHARACTERISTIC OF CBCT/OPG (ONLY IN FEW CENTERS) IMAGING FOR IMPLANT:**

- A. Accuracy in linear measurement
- B. Superimposition of anatomic structures
- C. Breadth of the image
- D. High resolution

## P.O.W.E.R NOTES SBQ 12

Repeated question SBQ 6

THIS IS COPYRIGHTED CONTENT. Unauthorized use, including screenshots, copying, misuse, reuse, or resale of any content from this app, is strictly prohibited. Our app monitors and records all screenshots and recordings. Violators will face strict legal action.

THIS IS COPYRIGHTED CONTENT. Unauthorized use, including screenshots, copying, misuse, reuse, or resale of any content from this app, is strictly prohibited. Our app monitors and records all screenshots and recordings. Violators will face strict legal action.

THIS IS COPYRIGHTED CONTENT. Unauthorized use, including screenshots, copying, misuse, reuse, or resale of any content from this app, is strictly prohibited. Our app monitors and records all screenshots and recordings. Violators will face strict legal action.

THIS IS COPYRIGHTED CONTENT. Unauthorized use, including screenshots, copying, misuse, reuse, or resale of any content from this app, is strictly prohibited. Our app monitors and records all screenshots and recordings. Violators will face strict legal action.

## DISCLAIMER

THIS IS COPYRIGHTED CONTENT. Unauthorized use, including screenshots, copying, misuse, reuse, or resale of any content from this app, is strictly prohibited. Our app monitors and records all screenshots and recordings. Violators will face strict legal action.

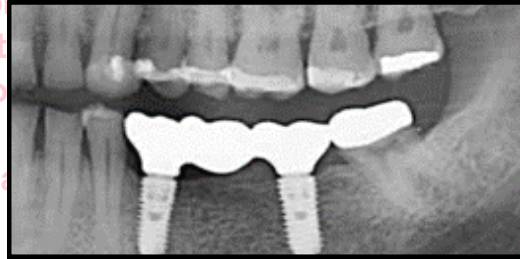
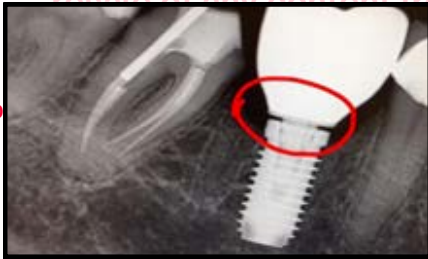**DISCLAIMER**  
THIS IS COPYRIGHTED CONTENT. Unauthorized use, including screenshots, copying, misuse, reuse, or resale of any content from this app, is strictly prohibited. Our app monitors and records all screenshots and recordings. Violators will face strict legal action.

# PROSTHO

## SBQ 13

### ON IMPLANT (NEW QUESTION)

(PLASTIC CURETTAGE, SWELLING HINDRANCE, SUPERFLOSS SAME QUESTION AS YOURS. ONLY ONE QUESTION WAS DIFFERENT) CANTILEVER BRIDGE FROM 42 TO 33, ABUTMENTS ARE 32,42. NOTHING IS GIVEN IN HISTORY ABOUT PAIN,BLEEDING, OR BONE LOSS. PATIENT WAS COMPLAINING ABOUT THE MOBILITY OF THE BRIDGE FOR 3 WEEKS, HE HAD DIFFICULTY CLEANING THE AREA. IMPLANTS WERE PLACED 3 YEARS AGO. BRIDGE WAS PLACED 9 MONTHS LATER.IN OPG IMPLANTS LOOK HEALTHY (IN SOME CENTERS THERE WAS CLEAR RADIOLUCENCY SURROUNDING THE CORONAL THIRD OF BOTH THE IMPLANTS), NO CALCULUS WAS VISIBLE.PATIENT HAS MEDICAL HISTORY OF DM. (IN SOME CENTERS YOU COULD SEE THE GAP BETWEEN THE BRIDGE AND IMPLANT AND NO RADIOLUCENCY AROUND IMPLANTS.



#### I. What is the reason for the mobility of the bridge?

- A. Lack of Osseointegration
- B. Loose abutment screws
- C. Peri implantitis
- D. Peri implant mucositis

#### II. You plan to refer the patient to a specialist. Which instruments will be used to curette implant

- A. Plastic curette
- B. Ultrasonic ceramic tip
- C. Metal scrubber
- D. Ultrasonic metallic tip

#### III. How does the adjunctive treatment help in the management?

- A. Influence the micro flora,
- B. Alter host response to the bacteria
- C. Regenerate periodontal ligament

#### DISCLAIMER

THIS IS COPYRIGHTED CONTENT. Unauthorized use, including screenshots, copying, misuse, reuse, or resale of any content from this app, is strictly prohibited. Our app monitors and records all screenshots and recordings. Violators will face strict legal action.

DISCLAIMER  
THIS IS COPYRIGHTED CONTENT. Unauthorized use, including screenshots, copying, misuse, reuse, or resale of any content from this app, is strictly prohibited. Our app monitors and records all screenshots and recordings. Violators will face strict legal action.

THIS IS COPYRIGHTED CONTENT. Unauthorized use, including screenshots, copying, misuse, reuse, or resale of any content from this app, is strictly prohibited. Our app monitors and records all screenshots and recordings. Violators will face strict legal action.

DISCLAIMER

# PROSTHO

## P.O.W.E.R NOTES SBQ 13

- I. There's a gap between the abutment and the implant and no radiolucency around the bone. The answer would be loose abutment screws which are leading to the mobility of the bridge.  
If there's no loose abutment screw and in the presence of distinct radiolucency, then the answer would be lack of osseointegration.
- II. As a metal only titanium is recommended for mechanical debridement. This answer is not given. The second-best material is the plastic curettes.
- III. Adjunctive treatment is helpful in regeneration of PDL in dentate patients and not in implant patients. Adjunct treatment is helpful in implant patients by influencing the bacteria.  
Amoxicillin and metronidazole don't have regeneration capacity in both natural teeth and implants. Tetracycline has a regeneration capacity in natural tooth to create new PDL fibers.

all screenshots and recordings. Violators will face strict legal action.

THIS IS COPYRIGHTED CONTENT. Unauthorized use, including screenshots, copying, misuse, reuse, or resale of any content from this app, is strictly prohibited. Our app monitors and records all screenshots and recordings. Violators will face strict legal action.

THIS IS COPYRIGHTED CONTENT. Unauthorized use, including screenshots, copying, misuse, reuse, or resale of any content from this app, is strictly prohibited. Our app monitors and records all screenshots and recordings. Violators will face strict legal action.

### DISCLAIMER

THIS IS COPYRIGHTED CONTENT. Unauthorized use, including screenshots, copying, misuse, reuse, or resale of any content from this app, is strictly prohibited. Our app monitors and records all screenshots and recordings. Violators will face strict legal action.

DISCLAIMER  
THIS IS COPYRIGHTED CONTENT. Unauthorized use, including screenshots, copying, misuse, reuse, or resale of any content from this app, is strictly prohibited. Our app monitors and records all screenshots and recordings. Violators will face strict legal action.



# PROSTHO

## SBQ 14

### (NEW) - COMBINATION SYNDROME

LADY WEARING UPPER DENTURE FOR 17 YEARS AND LOWER 34-44 TEETH PRESENT. EXCESSIVE WORN OUT DENTURE TEETH INFORMATION GIVEN IN QUESTION.

- CLICKING IN JAW WHILE EATING FOOD
- REDUCED VDO AND SORENESS AROUND CORNER OF MOUTH
- DENTURE UNSTABLE UPON CHEWING
- RESORBED ANTERIOR MAXILLA WITH FLABBY RIDGE

(NO CLINICAL PICTURE WAS GIVEN)

I. What is the reason for soreness around the corner of mouth?

- A. Reduced VDO
- B. Reduced freeway space
- C. Vitamin deficiency

II. Muscle attached to the disc of the TMJ is pulled in front of the articular eminence it slides over. Which muscle is involved in clicking the tmj?

- A. Masseter
- B. Buccinator
- C. Medial pterygoid
- D. Temporalis
- E. Lateral pterygoid

III. Reason for denture instability upon chewing

- A. Excessive worn out teeth
- B. Reduced VDO
- C. Faulty post dam seal
- D. Anterior resorbed ridges
- E. Incorrect centric occlusion

IV. What can be done to stabilize the new denture?

- A. Make a functional lower rpd
- B. New denture with wear resistance teeth
- C. Make sure new denture have post dam seal

V. Best method for impression taking of an edentulous patient with maxillary anterior flabby ridge

- A. 3D impression technique
- B. Polyvinyl with compound modified custom made tray
- C. Alginate

### DISCLAIMER

THIS IS COPYRIGHTED CONTENT. Unauthorized use, including screenshots, copying, misuse, reuse, or resale of any content from this app, is strictly prohibited. Our app monitors and records all screenshots and recordings. Violators will face strict legal action.

DISCLAIMER  
THIS IS COPYRIGHTED CONTENT. Unauthorized use, including screenshots, copying, misuse, reuse, or resale of any content from this app, is strictly prohibited. Our app monitors and records all screenshots and recordings. Violators will face strict legal action.

THIS IS COPYRIGHTED CONTENT. Unauthorized use, including screenshots, copying, misuse, reuse, or resale of any content from this app, is strictly prohibited. Our app monitors and records all screenshots and recordings. Violators will face strict legal action.

DISCLAIMER

# PROSTHO

## P.O.W.E.R NOTES SBQ 14

- Clicking in the jaw while eating food is associated with excessive worn out denture teeth. As a result, there will be reduced VDO. Reduced VDO results in angular cheilitis and soreness around the corner of mouth. TMJ problems/pain in the mandibular joint can happen with reduced VDO.
  - Denture is unstable upon chewing is not because of occlusal interference. Because occlusal interference is not identified after 17 years of denture use.
  - Resorbed anterior maxilla with flabby ridge is a long-standing feature of combination syndrome, which leads to loose denture.
- Soreness around the corner of mouth is due to reduced VDO and increased freeway space but not due to vitamin deficiency.
  - In dentate patients presenting history of angular cheilitis is due to vitamin deficiency.
- Superior head of the lateral pterygoid muscle that is connected to the disc.
- Flabby ridges from the combination syndrome will be seen from years of denture use.  
Worn out teeth leads to reduced VDO and it doesn't cause instability of denture or rocking denture. Reduced VDO leads to angular cheilitis. When VDO is lost you must record both VDO and centric relation again. Options (A) and (B) are ruled out. Faulty post dam lead to unstable denture at both function and rest. According to the question this denture is unstable upon chewing, therefore faulty post dam can't be the reason. Option (C) is ruled out.  
Incorrect centric occlusion can give rise to instability of denture during function.
- This is an ADC release sample question answer given is making a functional lower RPD. Will provide stability to the upper denture in the combination syndrome, patient

THIS IS COPYRIGHTED CONTENT. Unauthorized use, including screenshots, copying, misuse, reuse, or resale of any content from this app, is strictly prohibited. Our app monitors and records all screenshots and recordings. Violators will face strict legal action.

### DISCLAIMER

THIS IS COPYRIGHTED CONTENT. Unauthorized use, including screenshots, copying, misuse, reuse, or resale of any content from this app, is strictly prohibited. Our app monitors and records all screenshots and recordings. Violators will face strict legal action.

DISCLAIMER

THIS IS COPYRIGHTED CONTENT. Unauthorized use, including screenshots, copying, misuse, reuse, or resale of any content from this app, is strictly prohibited. Our app monitors and records all screenshots and recordings. Violators will face strict legal action.

DISCLAIMER

THIS IS COPYRIGHTED CONTENT. Unauthorized use, including screenshots, copying, misuse, reuse, or resale of any content from this app, is strictly prohibited. Our app monitors and records all screenshots and recordings. Violators will face strict legal action.

# PROSTHO

## P.O.W.E.R NOTES SBQ 14

- V. Patient will still have flabby ridge even if you are giving a new denture, if you are not surgically removing it. So, you need to use the window technique with PVS flowable with compound modified border moulded custom tray. ZOE will be used for the rest of the palate, anteriorly flowable.

THIS IS COPYRIGHTED CONTENT. Unauthorized use, including screenshots, copying, misuse, reuse, or resale of any content from this app, is strictly prohibited. Our app monitors and records all screenshots and recordings. Violators will face strict legal action.

THIS IS COPYRIGHTED CONTENT. Unauthorized use, including screenshots, copying, misuse, reuse, or resale of any content from this app, is strictly prohibited. Our app monitors and records all screenshots and recordings. Violators will face strict legal action.

THIS IS COPYRIGHTED CONTENT. Unauthorized use, including screenshots, copying, misuse, reuse, or resale of any content from this app, is strictly prohibited. Our app monitors and records all screenshots and recordings. Violators will face strict legal action.

### DISCLAIMER

THIS IS COPYRIGHTED CONTENT. Unauthorized use, including screenshots, copying, misuse, reuse, or resale of any content from this app, is strictly prohibited. Our app monitors and records all screenshots and recordings. Violators will face strict legal action.

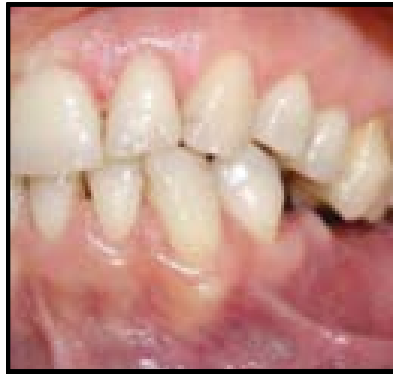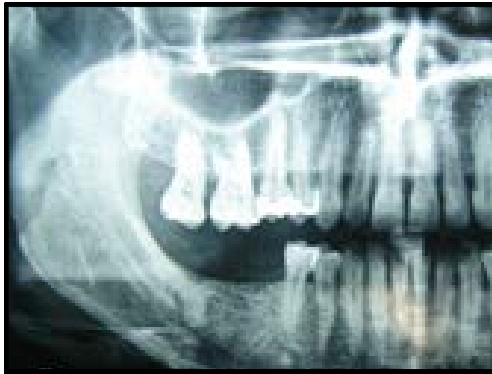
DISCLAIMER  
THIS IS COPYRIGHTED CONTENT. Unauthorized use, including screenshots, copying, misuse, reuse, or resale of any content from this app, is strictly prohibited. Our app monitors and records all screenshots and recordings. Violators will face strict legal action.

# PROSTHO

## SBQ 15

### DENTURE PATIENT

LADY PATIENT COMES TO YOU, YOU OBSERVE HYPERACTIVE MENTALIS MUSCLE, 2 CLINICAL PICTURES GIVEN - ONE FROM FRONT (EXTRA-ORAL), OTHER ONE INTRAORAL RIGHT SIDE CROPPED PIC - YOU COULD SEE EXTRUSION OF UPPER RIGHT DENTOALVEOLAR, NO LOWER TEETH PRESENT. CROPPED OPG OF RIGHT SIDE GIVEN.



(2ND PIC - COULD CLEARLY SEE DENTOALVEOLAR EXTRUSION WITHOUT ATTACHMENT LOSS)

I. After clinically checking teeth in maximum intercuspation (intra-oral pic was given) and radiographic assessment, what additional information or investigation will help to make a lower denture

- Clinical assessment and OPG provides all the required information.
- Ask the lab tech to do an occlusal analysis of the master cast
- An articulated study cast on semi-adjustable articulator for occlusal analysis

THIS IS COPYRIGHTED CONTENT. Unauthorized use, including screenshots, copying, misuse, reuse, or resale of any content from this app, is strictly prohibited. Our app monitors and records all screenshots and recordings. Violators will face strict legal action.

#### DISCLAIMER

THIS IS COPYRIGHTED CONTENT. Unauthorized use, including screenshots, copying, misuse, reuse, or resale of any content from this app, is strictly prohibited. Our app monitors and records all screenshots and recordings. Violators will face strict legal action.

DISCLAIMER  
THIS IS COPYRIGHTED CONTENT. Unauthorized use, including screenshots, copying, misuse, reuse, or resale of any content from this app, is strictly prohibited. Our app monitors and records all screenshots and recordings. Violators will face strict legal action.

THIS IS COPYRIGHTED CONTENT. Unauthorized use, including screenshots, copying, misuse, reuse, or resale of any content from this app, is strictly prohibited. Our app monitors and records all screenshots and recordings. Violators will face strict legal action.

THIS IS COPYRIGHTED CONTENT. Unauthorized use, including screenshots, copying, misuse, reuse, or resale of any content from this app, is strictly prohibited. Our app monitors and records all screenshots and recordings. Violators will face strict legal action.



# PROSTHO

## P.O.W.E.R NOTES SBQ 15

- I.
  - It's a complex case. Only by doing the clinical assessment and OPG will not provide all the required information.
  - Occlusal analysis should be done by the dentist and not by the lab technician.
  - The best way to do is the occlusal analysis on a articulated study casts.

THIS IS COPYRIGHTED CONTENT. Unauthorized use, including screenshots, copying, misuse, reuse, or resale of any content from this app, is strictly prohibited. Our app monitors and records all screenshots and recordings. Violators will face strict legal action.

THIS IS COPYRIGHTED CONTENT. Unauthorized use, including screenshots, copying, misuse, reuse, or resale of any content from this app, is strictly prohibited. Our app monitors and records all screenshots and recordings. Violators will face strict legal action.

THIS IS COPYRIGHTED CONTENT. Unauthorized use, including screenshots, copying, misuse, reuse, or resale of any content from this app, is strictly prohibited. Our app monitors and records all screenshots and recordings. Violators will face strict legal action.

### DISCLAIMER

THIS IS COPYRIGHTED CONTENT. Unauthorized use, including screenshots, copying, misuse, reuse, or resale of any content from this app, is strictly prohibited. Our app monitors and records all screenshots and recordings. Violators will face strict legal action.

DISCLAIMER  
THIS IS COPYRIGHTED CONTENT. Unauthorized use, including screenshots, copying, misuse, reuse, or resale of any content from this app, is strictly prohibited. Our app monitors and records all screenshots and recordings. Violators will face strict legal action.

DISCLAIMER

THIS IS COPYRIGHTED CONTENT. Unauthorized use, including screenshots, copying, misuse, reuse, or resale of any content from this app, is strictly prohibited. Our app monitors and records all screenshots and recordings. Violators will face strict legal action.

# PROSTHO

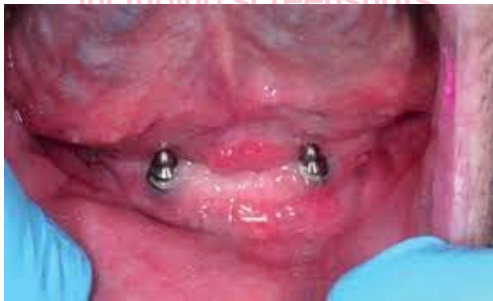## SBQ 16

### LOST DENTURE

A 70 YEAR OLD PATIENT NAMED VALERIE, STAYS IN THE OLD AGE HOME. PATIENT HAD GOT AN IMPLANT SUPPORTED UPPER LOWER DENTURES A FEW YEARS BACK. SHE ALSO HAD DISCOMFORT SINCE SHE HAS LOST THE DENTURES.

PATIENT WAS ON IV BISPHOSPHONATES (6 MONTHLY) TO TREAT OSTEOPOROSIS. ALSO HAD A HISTORY OF DEMENTIA, POORLY CONTROLLED DIABETES.

PHOTOGRAPH WAS GIVEN AND YOU COULD CLEARLY SEE INFLAMMATION AROUND THE IMPLANT. SHE IS ANXIOUS AND DOESN'T WANT TO LEAVE THE CARE HOME SO DAUGHTER REQUESTED TREATMENT IN CARE HOME ITSELF.



I. What could be the cause for the inflammation around the implant, implant was labially placed and making an indentation on labial mucosa of lower lip.

- A. Denture has not been worn from a long time
- B. Abutment place too labially
- C. Implant positioned too high
- D. Mentalis muscle

II. What can be the complication in her case when you plan to change the implant abutment to healing abutment?

- A. Osteoporosis
- B. Type 2 diabetes
- C. Smoking
- D. MRONJ

III. What is the barrier in treating this patient?

- A. Anxiety of patient
- B. Lack of clinical environment
- C. Old age

IV. What is the major risk/barrier of implant placement?

- A. Poor Diabetic control
- B. Osteoporosis
- C. Anxiety
- D. Inflammation around the abutment

### DISCLAIMER

THIS IS COPYRIGHTED CONTENT. Unauthorized use, including screenshots, copying, misuse, reuse, or resale of any content from this app, is strictly prohibited. Our app monitors and records all screenshots and recordings. Violators will face strict legal action.

# PROSTHO

## SBQ 16

V. Healing abutment was given. What would be your course of action now?

- A. Give a new upper lower complete denture
- B. New upper complete denture
- C. Refer to specialist for new implant placement

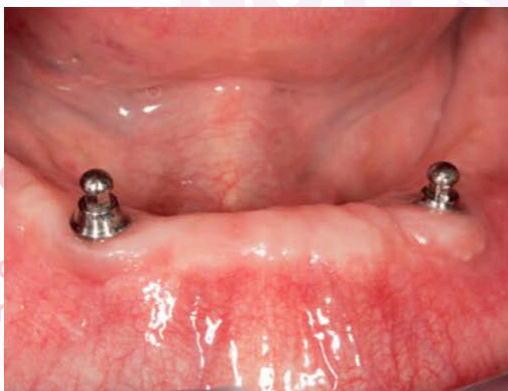
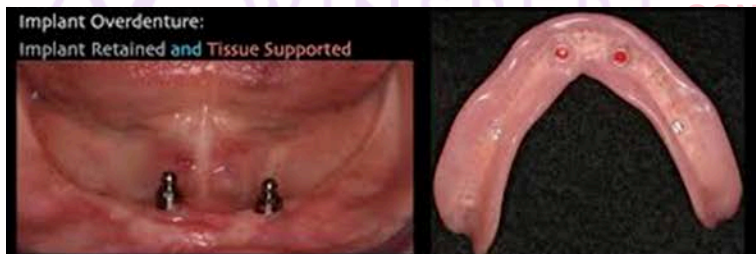## P.O.W.E.R NOTES SBQ 16

- I. Inflammation around the implants can be due peri-implant mucositis. peri-implant mucositis can be due to biological irritation by plaque or can be due to the irritation by the physical positioning of the implant or the abutment. In the question it is mentioned that the implant was labially placed and making an indentation on the labial mucosa of the lower lip.

### REFERENCE:

However, if the labial musculature is tensed or the amount of attached gingiva is limited, the *implants should not be placed too deep or too labially*, which might prevent gingival growth over the abutments. In those cases, *ball anchor abutments with elevated shoulders* can be used to improve implant anatomy.

### MUCOSAL CYLINDERS PREVENT SOFT TISSUE OVERGROWTH & IMPINGEMENT



### DISCLAIMER

THIS IS COPYRIGHTED CONTENT. Unauthorized use, including screenshots, copying, misuse, reuse, or resale of any content from this app, is strictly prohibited. Our app monitors and records all screenshots and recordings. Violators will face strict legal action.

DISCLAIMER  
THIS IS COPYRIGHTED CONTENT. Unauthorized use, including screenshots, copying, misuse, reuse, or resale of any content from this app, is strictly prohibited. Our app monitors and records all screenshots and recordings. Violators will face strict legal action.

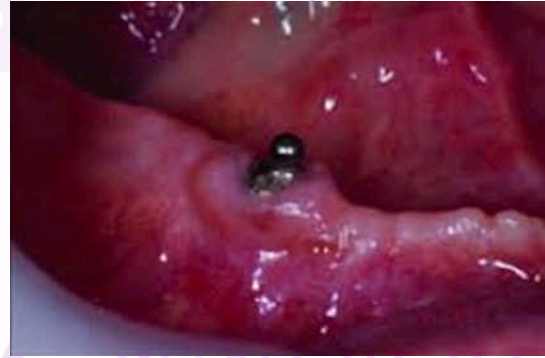
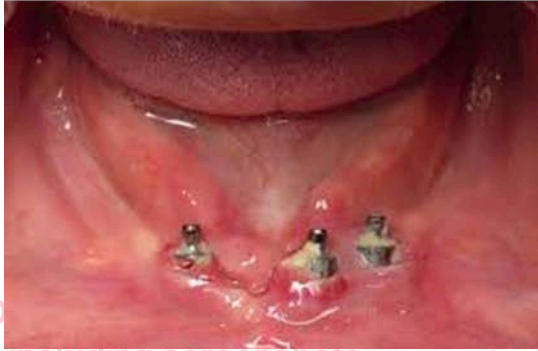THIS IS COPYRIGHTED CONTENT. Unauthorized use, including screenshots, copying, misuse, reuse, or resale of any content from this app, is strictly prohibited. Our app monitors and records all screenshots and recordings. Violators will face strict legal action.

DISCLAIMER

# PROSTHO

## P.O.W.E.R NOTES SBQ 16

### I. GINGIVAL INFLAMMATION AROUND THE IMPLANTS



- II. Osteoporosis itself doesn't not show increased risk for implants. But bisphosphonates are associated with increased risk for implant failure. Experts opinion is required in patients who are on bisphosphonates. Surgery should be avoided in poorly controlled diabetes although diabetes is not a contraindication to implant therapy.

Smoking can also be a risk factor. And it's not mentioned in the history.

- III. In the question it's mentioned "she's anxious and doesn't want to leave the care home, so, daughter requested treatment in the care home itself. Doing the treatment in the care home is a barrier. Therefore, the answer is (B).

- IV. In this patient there are 2 main risk factors / barriers for implant placement.

They are:

Poorly controlled diabetes

IV bisphosphonates

- V. in the history it is given that the patient has lost both upper and lower denture so best answer would be (A). As patient lives in the residential care referral would be difficult. The patient implants do not require replacement as the soft tissue swelling around the connectors has been addressed by you.

THIS IS COPYRIGHTED CONTENT. Unauthorized use, including screenshots, copying, misuse, reuse, or resale of any content from this app, is strictly prohibited. Our app monitors and records all screenshots and recordings. Violators will face strict legal action.

#### DISCLAIMER

THIS IS COPYRIGHTED CONTENT. Unauthorized use, including screenshots, copying, misuse, reuse, or resale of any content from this app, is strictly prohibited. Our app monitors and records all screenshots and recordings. Violators will face strict legal action.

DISCLAIMER  
THIS IS COPYRIGHTED CONTENT. Unauthorized use, including screenshots, copying, misuse, reuse, or resale of any content from this app, is strictly prohibited. Our app monitors and records all screenshots and recordings. Violators will face strict legal action.

THIS IS COPYRIGHTED CONTENT. Unauthorized use, including screenshots, copying, misuse, reuse, or resale of any content from this app, is strictly prohibited. Our app monitors and records all screenshots and recordings. Violators will face strict legal action.

DISCLAIMER

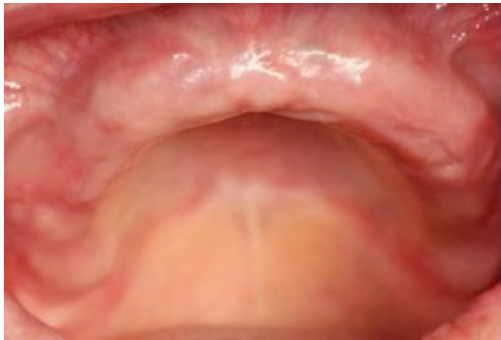

# PROSTHO

## SBQ 17

### DENTURE

PATIENT UNDERGOING THE TREATMENT FOR OSTEOPOROSIS TAKING 6 MONTHLY BISPHOSPHONATES, PREVIOUSLY HAD UPPER RPD. HAS RECENTLY GOT HIS TOOTH EXTRACTED AND IS WEARING A COMPLETE DENTURE ON HIS UPPER JAW. COMPLAINS OF SORENESS AND PAIN UNDER THE DENTURE. PICTURE WAS GIVEN SHOWING MAXILLA, HEALING PHASE AFTER EXTRACTIONS THAT WERE DONE



#### I. Question asked which tooth you think are extracted

- A. 25-27
- B. 23-25
- C. 17-13
- D. 13-21

#### II. What will you do now or how can you resolve this issue?

- A. Tissue conditioners Reline
- B. Assess the vdo
- C. Assess the areas of the denture causing pain and correct it

#### III. You did some corrections patient came back again and still has the same complaints?

- A. Remove the denture and refund her full fee
- B. Make new denture
- C. Refer to the specialist

#### IV. What should you inform the patient to look out for?

- A. Soreness under denture
- B. Discomfort while chewing

THIS IS COPYRIGHTED CONTENT. Unauthorized use, including screenshots, copying, misuse, reuse, or resale of any content from this app, is strictly prohibited. Our app monitors and records all screenshots and recordings. Violators will face strict legal action.

**DISCLAIMER**  
THIS IS COPYRIGHTED CONTENT. Unauthorized use, including screenshots, copying, misuse, reuse, or resale of any content from this app, is strictly prohibited. Our app monitors and records all screenshots and recordings. Violators will face strict legal action.

### DISCLAIMER

THIS IS COPYRIGHTED CONTENT. Unauthorized use, including screenshots, copying, misuse, reuse, or resale of any content from this app, is strictly prohibited. Our app monitors and records all screenshots and recordings. Violators will face strict legal action.

THIS IS COPYRIGHTED CONTENT. Unauthorized use, including screenshots, copying, misuse, reuse, or resale of any content from this app, is strictly prohibited. Our app monitors and records all screenshots and recordings. Violators will face strict legal action.

**DISCLAIMER**

# PROSTHO

## P.O.W.E.R NOTES SBQ 17

- I. Classic feature of a healing socket (long healing line with multiple extractions can be identified in the picture) it presents at the site of 23-25
- II. According to the given picture there's no inflammation in the extraction site. Denture wearing patient with loose dentures and who is on bisphosphonates are at a risk of developing MRONJ. (REFERENCE: TG pg. 166)

In case of denture problems, you need to check in the below order:

**F- FIT of the denture**  
**O-OCCLUSION**  
**S-SOFT TISSUES**  
**B-BORDERS OF THE DENTURE**

Fitness of the denture is assessed by checking the borders of the denture. In this case there's no complaint about the looseness of the denture, which means there is no issue with the fit of the denture.

Excessive VDO is the predominant cause for the pain under the denture. By assessing VDO, you are able to check the occlusion. Occlusion interferences can also lead to pain under the denture. VDO is assessed in centric occlusion. Then you are asking the patient to protrude and to do laterotrusive chewing movements to identify the occlusal interferences.

Pressure indicating paste is the last thing to do. It's usually done after the soft tissue and border analysis. Pressure paste helps you in identifying where the occlusal interference is. But you can't trim this point in the tissue bearing area. Because that is not due to the extra material and that's due to the occlusal interference. After marking the high points with the pressure indicating paste, you will be sending the dentures to the lab for occlusal adjustments.

Tissue conditioners and re-liners will not eliminate the cause. For eliminating the cause, we must do full fit analysis, full occlusal analysis, full soft tissue analysis and full border analysis.

- III. Now you must refer the patient to the specialist because, patient is at a high risk of developing MRONJ. You can't let this persist for a week as it can turn to MRONJ.
- IV. Discomfort can be due to lot of reasons. It can be due to the problem with the fit, wearing off of the denture, occlusion changes etc.  
 When the patient is at a higher risk of developing MRONJ, it is advised to look for the soreness under the denture.

### DISCLAIMER

THIS IS COPYRIGHTED CONTENT. Unauthorized use, including screenshots, copying, misuse, reuse, or resale of any content from this app, is strictly prohibited. Our app monitors and records all screenshots and recordings. Violators will face strict legal action.