



WINSPERT

PEDODONTICS

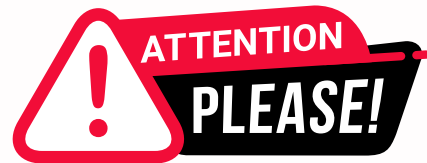H.O.T

HIGH-PRIORITY ORGANISED THEORY

NOTES

By Dr. Jigyasa Sharma





Dear Students,

We'd like to remind you about the importance of respecting the integrity of the resources provided in our app.

Please be aware that **WINSPERT HOT NOTES ARE COPYRIGHTED CONTENT. Unauthorized use, including screenshots, copying, misuse, reuse, or resale of any content from this app, is strictly prohibited.**

Our app monitors and records all screenshots and recordings. Violators will face strict legal action.

We're committed to providing you with the best tools for your success, and we appreciate your cooperation in maintaining a fair and secure learning environment.

Thank you for your understanding and continued dedication.

Best regards,
WINSPERT TEAM

PEDODONTICS

H.O.T TOPICS

- 1. Childhood Gingival diseases**
- 2. Age determination from OPG**
- 3. Preventive dentistry in Pediatric Dentistry - Pit & Fissure Sealants, Fluorides**
- 4. Childhood Caries Management**
- 5. Developmental Defects on Teeth**
- 6. Vital Pulp Therapy**

CHILDHOOD GINGIVAL DISEASES

(Sources: TG, review article in Gingival diseases in childhood, Periodontal diseases of Children and Adolescent.)

- Gingival diseases in children are numerous and may progress to jeopardize the periodontium of adult.
- Dental practitioners have an important role to play in the early recognition and diagnosis of gingival and periodontal diseases of gingival and periodontal diseases to optimize treatment outcomes.

There are several **anatomical differences** between the periodontal structures of child and adult.

Clinical appearances and their histological correlation in gingiva of a child:

- Gingiva is more reddish in color, due to thinner epithelium, a lesser degree of cornification and greater vascularity.
- There is lack of stippling due to shorter and flatter papillae from the lamina propria.
- Rounded and rolled gingival margins are seen in childhood, this is due to hyperemia and edema that accompanies eruption and pronounced cervical ridge of crown in deciduous dentition.
- Greater sulcular depth. The mean sulcular depth for primary dentition is 2.1mm +/- 0.2 mm.
- The attached gingiva increases in width with age.

Periodontium in Children

Gingiva	The connective tissue has comparatively less well-developed net of collagen fibres than in adults. The surface of the col was said to be covered by an odontogenically-derived epithelium that is atrophic, (four cell-layers thick) and has a diminished proliferative activity. The replacement of the odontogenically-derived epithelium by ingrowing oral epithelium was considered essential for a healthy periodontium.
Periodontal Ligament	It is wider, has fewer and less dense fibres per unit area and has increased hydration with a greater blood and lymph supply than in adults. During eruption the principal fibres are parallel to the long axis of the teeth. The bundle arrangement occurs after the teeth encounter their functional antagonists.
Cementum	It is often thinner and less dense than of adults. It shows a tendency to hyperplasia of cementoid apical to the epithelial attachment. Before the tooth reaches the occlusal plane, a cellular cementum is formed.
Alveolar Bone	The lamina dura is thinner; there are fewer trabecular and larger marrow spaces. There is a smaller amount of calcification greater blood and lymph supply and the alveolar crest appears flatter.

[Table/Fig-2]: Tooth supporting structures and its features in childhood

DISCLAIMER

THIS IS COPYRIGHTED CONTENT. Unauthorized use, including screenshots, copying, misuse, reuse, or resale of any content from this app, is strictly prohibited. Our app monitors and records all screenshots and recordings. Violators will face strict legal action.

DISCLAIMER
THIS IS COPYRIGHTED CONTENT. Unauthorized use, including screenshots, copying, misuse, reuse, or resale of any content from this app, is strictly prohibited. Our app monitors and records all screenshots and recordings. Violators will face strict legal action.

THIS IS COPYRIGHTED CONTENT. Unauthorized use, including screenshots, copying, misuse, reuse, or resale of any content from this app, is strictly prohibited. Our app monitors and records all screenshots and recordings. Violators will face strict legal action.

DISCLAIMER

CHILDHOOD GINGIVAL DISEASES

Physiological Gingival changes associated with tooth eruption:

- There are changes that occurs in the gingiva which associated with eruption of permanent teeth during the transition phase of dentition:
 - a) **Pre-eruption Bulge:**
 - Before the crown appears, the gingiva appears as a firm bulge, slightly blanch and conforms to contour of underlying crown.
 - b) **Formation of gingival margin:**
 - Marginal gingiva and sulcus develop as the crown penetrates oral mucosa.
 - In course of eruption gingival margin is edematous, rounded and slightly reddened.
 - c) **Normal prominence of gingival margin:**
 - During the period of mixed dentition, it is normal for marginal gingiva around permanent tooth to be prominent, particularly maxillary anterior region.
 - At this stage of tooth eruption gingiva is still attached to the crown, and it appears prominent when superimposed on bulk of underlying enamel.

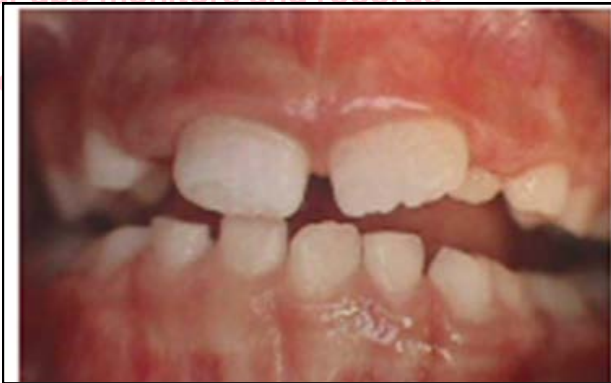

Image: Physiologic changes with teeth eruption

THIS IS COPYRIGHTED CONTENT. Unauthorized use, including screenshots, copying, misuse, reuse, or resale of any content from this app, is strictly prohibited. Our app monitors and records all screenshots and recordings. Violators will face strict legal action.

DISCLAIMER

THIS IS COPYRIGHTED CONTENT. Unauthorized use, including screenshots, copying, misuse, reuse, or resale of any content from this app, is strictly prohibited. Our app monitors and records all screenshots and recordings. Violators will face strict legal action.

DISCLAIMER
THIS IS COPYRIGHTED CONTENT. Unauthorized use, including screenshots, copying, misuse, reuse, or resale of any content from this app, is strictly prohibited. Our app monitors and records all screenshots and recordings. Violators will face strict legal action.

THIS IS COPYRIGHTED CONTENT. Unauthorized use, including screenshots, copying, misuse, reuse, or resale of any content from this app, is strictly prohibited. Our app monitors and records all screenshots and recordings. Violators will face strict legal action.

DISCLAIMER
THIS IS COPYRIGHTED CONTENT. Unauthorized use, including screenshots, copying, misuse, reuse, or resale of any content from this app, is strictly prohibited. Our app monitors and records all screenshots and recordings. Violators will face strict legal action.

CHILDHOOD GINGIVAL DISEASES

Classification of Gingival Diseases:

A) Gingival diseases associated with Plaque:

1) Without local contributing factors:

i) Plaque induced Gingivitis:

- The primary cause of gingivitis is plaque.
- Dental plaque appears to form more rapidly in children from 8-12 years than in adults.
- The plaque induced inflammatory lesions is usually confined to the marginal aspects of gingiva and with time, progresses to other tissues of the periodontium.

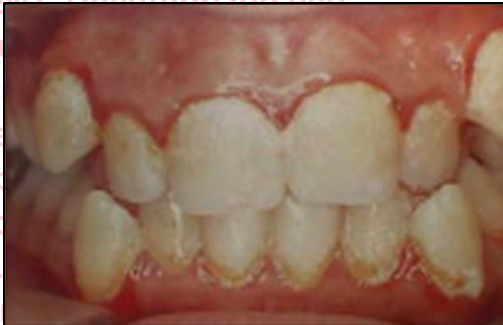

Fig: Plaque induced gingivitis

- A fiery red surface discoloration is often superimposed on underlying chronic changes.
- Gingival color change and swelling appear to be more common expressions of gingivitis in children than are bleeding and increased pocket depth.
- The highest grade of gingival inflammation is in the 14-16 years old.

2) With local contributing factors:

i) Eruption cyst and Hematoma

- It is common for erupting tooth to be associated with a form of dentigerous cyst called an eruption cyst.
- It is usually translucent, fluctuant and circumscribed swelling.

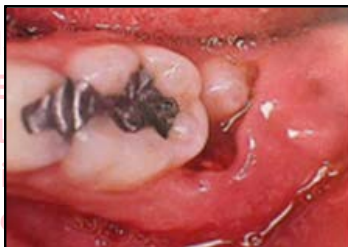

Fig: Eruption cyst

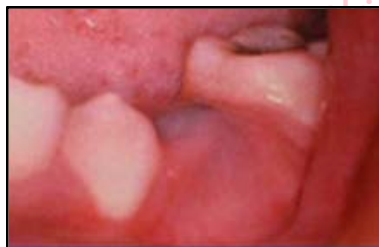

Fig: Eruption Hematoma

- When a cystic cavity contains blood, swelling appears as purple/ deep blue fluctuant, well circumscribed it is termed as eruption hematoma.

DISCLAIMER

THIS IS COPYRIGHTED CONTENT. Unauthorized use, including screenshots, copying, misuse, reuse, or resale of any content from this app, is strictly prohibited. Our app monitors and records all screenshots and recordings. Violators will face strict legal action.

DISCLAIMER
THIS IS COPYRIGHTED CONTENT. Unauthorized use, including screenshots, copying, misuse, reuse, or resale of any content from this app, is strictly prohibited. Our app monitors and records all screenshots and recordings. Violators will face strict legal action.

DISCLAIMER
THIS IS COPYRIGHTED CONTENT. Unauthorized use, including screenshots, copying, misuse, reuse, or resale of any content from this app, is strictly prohibited. Our app monitors and records all screenshots and recordings. Violators will face strict legal action.

CHILDHOOD GINGIVAL DISEASES

Classification of Gingival Diseases:

A) Gingival diseases associated with Plaque:

2) With local contributing factors:

ii) Eruption Gingivitis:

- Gingivitis associated with tooth eruption is frequent.
- It may be caused by greater risk of plaque accumulation in areas of shedding primary teeth and erupting permanent teeth, as oral hygiene may be difficult/ unpleasant to perform.

iii) Gingivitis associated with orthodontic Appliances:

- Access of interproximal toothbrushing is reduced significantly during fixed appliance therapy.
- The problem is more the tooth are banded rather than bonded.
- Supragingival plaque deposits are shifted to subgingival location by tipping movement.
- Bodily movement however are less likely to induce a relocation of supragingival plaque.
- **Gingival changes can occur within 1-2 months of appliance placement and are generally transient.**

iv) Other factors leading to gingivitis:

- Excessive overjet and overbite, nasal obstruction, mouth breathing habit, partially exfoliated tooth, loose deciduous teeth, malposed teeth, eroded margin of partially resorbed and carious teeth can cause gingivitis.

B) Gingival Diseases Modified by Systemic Factors:

1) Associated with Endocrine System:

i) Puberty Gingivitis:

- Enhanced level of gingival inflammation without increased levels of plaque accumulation occurs in children at puberty.
- There is a relationship between elevated levels of circulating sex hormones and prevalence of gingivitis in puberty.

plaque accumulation occur in children at puberty. The cytoplasm of gingival cells contains specific high affinity, low capacity receptors for both estrogens and testosterone. Estrogen receptors are found in the basal and spinous layers of the epithelium and in fibroblasts and endothelial cells of small vessels in the connective tissue. Thus, gingiva appears to be a target organ for some of the steroid hormones. The relationship between elevated levels of circulating sex hormones and prevalence of gingivitis in puberty is strengthened

DISCLAIMER

THIS IS COPYRIGHTED CONTENT. Unauthorized use, including screenshots, copying, misuse, reuse, or resale of any content from this app, is strictly prohibited. Our app monitors and records all screenshots and recordings. Violators will face strict legal action.

DISCLAIMER
THIS IS COPYRIGHTED CONTENT. Unauthorized use, including screenshots, copying, misuse, reuse, or resale of any content from this app, is strictly prohibited. Our app monitors and records all screenshots and recordings. Violators will face strict legal action.

DISCLAIMER
THIS IS COPYRIGHTED CONTENT. Unauthorized use, including screenshots, copying, misuse, reuse, or resale of any content from this app, is strictly prohibited. Our app monitors and records all screenshots and recordings. Violators will face strict legal action.

CHILDHOOD GINGIVAL DISEASES

Classification of Gingival Diseases:

B) Gingival Diseases Modified by Systemic Factors:

1) Associated with Endocrine System:

i) Puberty Gingivitis:

- During adolescence, Gingivitis peaks earlier in girls 11-13 years than in boys 13-14 years, which further strengthens the relationship between elevated sex hormones and gingivitis.
- It is characterized by pronounced inflammation, bluish red discoloration, edema and enlargement which results from local irritants that would ordinarily elicit mild gingival response.

2) Associated with Blood Dyscrasias:

i) Leukemia

- Leukemia is a malignant disease caused by proliferation of the WBC forming tissues, especially those in the bone marrow.
- It may be acute or chronic and may affect any of the WBC (granulocytes (myeloid), lymphocytes or monocytes).
- **Acute type of leukemia** is frequent in people under age of **20 years**.
- **Acute Lymphoblastic leukemia** occurs mainly in children under 10 years.

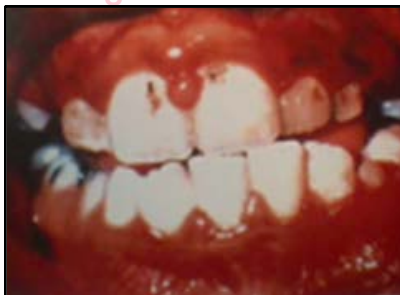

Fig: Leukemia Induced gingivitis

- Gingiva appears as swollen, glazed and spongy tissues which is red – deep purple in appearance with gingival bleeding.
- Diffuse enlargement of gingival mucosa may be seen.
- An oversized extension of marginal gingiva or a discrete tumor like interproximal mass may be seen.
- The consistency is moderately firm, but with a tendency toward friability and hemorrhage, that occurs either spontaneously or upon slight irritation.
- Associated symptoms and signs are lethargy, malaise, sore throat, skin infections that fail to heal, cervical lymphadenopathy, splenomegaly, hepatomegaly and petechiae.

DISCLAIMER

THIS IS COPYRIGHTED CONTENT. Unauthorized use, including screenshots, copying, misuse, reuse, or resale of any content from this app, is strictly prohibited. Our app monitors and records all screenshots and recordings. Violators will face strict legal action.

DISCLAIMER
THIS IS COPYRIGHTED CONTENT. Unauthorized use, including screenshots, copying, misuse, reuse, or resale of any content from this app, is strictly prohibited. Our app monitors and records all screenshots and recordings. Violators will face strict legal action.

THIS IS COPYRIGHTED CONTENT. Unauthorized use, including screenshots, copying, misuse, reuse, or resale of any content from this app, is strictly prohibited. Our app monitors and records all screenshots and recordings. Violators will face strict legal action.

DISCLAIMER

CHILDHOOD GINGIVAL DISEASES

Classification of Gingival Diseases:

B) Gingival Diseases Modified by Systemic Factors:

3) Associated with Nutritional Deficiency:

- Overgrowth of gingiva is a well-recognized unwanted effect of a number of drugs.
- The most frequently implicated are Phenytoin, Cyclosporin and nifedipine.
- **The anterior part of mouth more severely and frequently involved.**

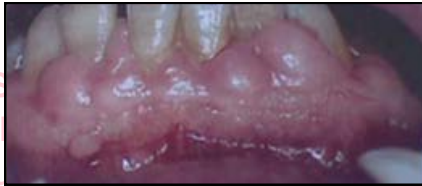

Fig: Drug induced gingival enlargement.

- The interdental papillae become nodular before enlarging more diffusely to encroach upon labial tissues.
- The enlarged gingiva is pink, firm, stippled in pts with good oral hygiene.

CHILDHOOD GINGIVAL DISEASES

Non- Plaque Induced Gingival Diseases:

A) Viral

a) Acute Herpetic Gingivostomatitis:

- It is caused by Herpes Simplex Virus (HSV) type 1
- Primary oral mucocutaneous Herpes occurs mostly in Infants and children younger than 6 years of age, but it is also seen in adolescents and adults.
- It occurs with systemic symptoms, Fever, malaise, lethargy, and cervical lymphadenopathy.
- They begin as blisters and ulcerate rapidly.

Clinical features	Diffuse erythematous, shiny involvement of the gingiva and the adjacent oral mucosa. Varying degrees of edema, gingival bleeding, Discrete spherical gray vesicles which rupture and form painful small ulcers with a red, elevated, halo like margin and a depressed yellowish or grayish white central portion are also seen. It occurs occasionally without overt vesiculation ¹⁸
-------------------	---

- Healing occurs within several days in infants and can take up to 2 weeks in older children.
- Herpetic gingivostomatitis is rare in adults, but can be severe and present with dehydration due to severe odynophagia.
- **Treatment:**

<p>Treat minor primary oral mucocutaneous herpes with supportive management (ie oral fluids, antipyretic drugs and analgesia). Apply a topical anaesthetic or analgesic, such as:</p> <p>benzylamine 1% gel (adult and child 6 years or older), topically to the lesions, 2- to 3-hourly as necessary.</p> <p>If this is not available, lidocaine viscous solution is an alternative topical anaesthetic for hospital settings (but be aware of the higher cost):</p> <p>lidocaine 2% viscous solution</p> <p>adult: use the lowest dose necessary up to 15 mL, rinsed in the mouth for 30 seconds then spat out, 3-hourly as necessary; maximum 8 doses in 24 hours</p> <p>child 3 years or older: use the lowest dose necessary up to 0.2 mL/kg (maximum 5 mL), rinsed in the mouth for 30 seconds then spat out, 3-hourly as necessary; maximum 4 doses in 24 hours*</p> <p>child younger than 3 years: use the lowest dose necessary up to 0.2 mL/kg (maximum 1.25 mL), applied to the affected areas with a cotton swab, 3-hourly as necessary; maximum 4 doses in 24 hours.*</p> <p>If the pharynx is affected in adults and children older than 12 years, lidocaine viscous solution can be gargled and swallowed.</p> <p>Management of primary oral mucocutaneous herpes differs for the following patients, so referral to a medical practitioner is required:</p> <ul style="list-style-type: none"> • patients with severe presentations • immunocompromised patients • patients with HIV.
--

Image: TG

DISCLAIMER

THIS IS COPYRIGHTED CONTENT. Unauthorized use, including screenshots, copying, misuse, reuse, or resale of any content from this app, is strictly prohibited. Our app monitors and records all screenshots and recordings. Violators will face strict legal action.

DISCLAIMER
THIS IS COPYRIGHTED CONTENT. Unauthorized use, including screenshots, copying, misuse, reuse, or resale of any content from this app, is strictly prohibited. Our app monitors and records all screenshots and recordings. Violators will face strict legal action.

THIS IS COPYRIGHTED CONTENT. Unauthorized use, including screenshots, copying, misuse, reuse, or resale of any content from this app, is strictly prohibited. Our app monitors and records all screenshots and recordings. Violators will face strict legal action.

DISCLAIMER

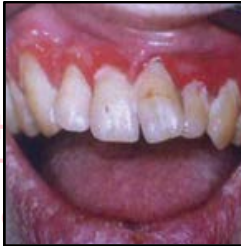CHILDHOOD GINGIVAL DISEASES

Non- Plaque Induced Gingival Diseases:

B) Viral

a) Linear Gingival Erythema:

- It is characterized by 2-3 mm of marginal band of intense erythema in free gingiva extending to attached gingiva as focal or diffuse erythema and extending beyond mucogingival line into alveolar mucosa.



- It may be localized to one or two teeth but it is more commonly a generalized gingival condition.

b) Candidiasis:

- It occurs from an overgrowth of candida albicans, usually after a course of antibiotics or as a result of congenital or acquired immunodeficiency.

C) Bacterial

a) Acute Necrotizing Ulcerative Gingivitis

- It affects the interdental papilla and gingiva and if not managed properly can spread to involve bone.
- Most commonly occurs in young adults and smokers.
- Rarely occurs in children.
- Children thought to have necrotizing gingivitis should be assessed for acute herpetic gingivostomatitis.

- Punched out appearance due to ulcerated and necrotic papillae and gingival margins.
- Ulcers are covered by a yellowish-white or grayish slough termed pseudomembrane.
- Removal of the slough results in bleeding and underlying tissue becomes exposed.
- A foetor ex ore is often associated, but can vary in intensity.

- Seldom associated with deep pocket formation as extensive gingival necrosis often coincides with loss of crestal alveolar bone.
- The involved papillae are separated into facial and lingual portion with an interposed necrotic depression.
- Swelling of lymph nodes and increased bleeding tendency are often present.
- Fever and malaise is not a consistent.
- The oral hygiene in these patients is usually poor [Table/Fig-11].

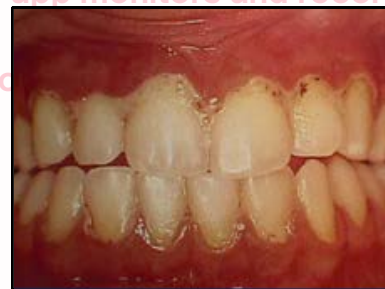

Fig: ANUG

DISCLAIMER

THIS IS COPYRIGHTED CONTENT. Unauthorized use, including screenshots, copying, misuse, reuse, or resale of any content from this app, is strictly prohibited. Our app monitors and records all screenshots and recordings. Violators will face strict legal action.

DISCLAIMER
THIS IS COPYRIGHTED CONTENT. Unauthorized use, including screenshots, copying, misuse, reuse, or resale of any content from this app, is strictly prohibited. Our app monitors and records all screenshots and recordings. Violators will face strict legal action.

DISCLAIMER
THIS IS COPYRIGHTED CONTENT. Unauthorized use, including screenshots, copying, misuse, reuse, or resale of any content from this app, is strictly prohibited. Our app monitors and records all screenshots and recordings. Violators will face strict legal action.

CHILDHOOD GINGIVAL DISEASES

Non- Plaque Induced Gingival Diseases:

C) Bacterial

a) Acute Necrotizing Ulcerative Gingivitis

• Management

Management of necrotising gingivitis

Thorough debridement of plaque and necrotic debris is necessary for successful management of necrotising gingivitis. However, it may not be possible to complete debridement at the initial presentation because necrotising gingivitis can be associated with significant pain.

Begin management of necrotising gingivitis with:

- gentle removal of as much plaque and necrotic debris as possible, using local anaesthetics if necessary
- local irrigation with chlorhexidine 0.2% mouthwash or hydrogen peroxide 3% solution. Chlorhexidine mouthwash or hydrogen peroxide solution (as below) may also be used if pain limits the patient's ability to mechanically clean their teeth
- antibiotic therapy (as below)
- analgesics (to select an appropriate analgesic regimen for acute dental pain, see p.137)
- advice to stop smoking.

Profoundly immunocompromised patients (for guidance on assessing a patient's degree of immune compromise, see p.181) or patients with severe cases of necrotising gingivitis require prompt referral for specialist management in addition to the management above.

For antibiotic therapy of necrotising gingivitis, use:

metronidazole 400 mg orally, 12-hourly for 3 to 5 days.

If pain and inflammation restrict oral hygiene practices, recommend short-term use of a mouthwash to reduce plaque formation; use:

- 1 hydrogen peroxide 3% solution 5 mL, mixed with 5 mL of warm water, rinsed in the mouth for 1 minute then spat out, 12-hourly until pain has reduced

OR

- 1 hydrogen peroxide 1.5% solution 10 mL, rinsed in the mouth for 1 minute then spat out, 12-hourly until pain has reduced

OR

- 2 chlorhexidine 0.2% mouthwash 10 mL rinsed in the mouth for 1 minute then spat out, 8- to 12-hourly until pain has reduced*

OR

- 2 chlorhexidine 0.12% mouthwash 15 mL rinsed in the mouth for 1 minute then spat out, 8- to 12-hourly until pain has reduced.*

Review the patient in 48 to 72 hours; perform a periodontal examination and provide the patient with advice on oral hygiene. Perform thorough debridement as soon as possible to prevent recurrence.

A poor response to treatment or recurrence of symptoms is usually due to inadequate debridement or a lack of improvement in oral hygiene, rather than an ineffective antibiotic regimen. If the infection has not responded to appropriate management (complete debridement, antibiotic therapy, improved oral hygiene) within 2 weeks, refer for specialist management.

Treatment failure is usually due to inadequate debridement or poor oral hygiene, rather than ineffective antibiotic therapy.

DISCLAIMER

THIS IS COPYRIGHTED CONTENT. Unauthorized use, including screenshots, copying, misuse, reuse, or resale of any content from this app, is strictly prohibited. Our app monitors and records all screenshots and recordings. Violators will face strict legal action.

DISCLAIMER

THIS IS COPYRIGHTED CONTENT. Unauthorized use, including screenshots, copying, misuse, reuse, or resale of any content from this app, is strictly prohibited. Our app monitors and records all screenshots and recordings. Violators will face strict legal action.

THIS IS COPYRIGHTED CONTENT. Unauthorized use, including screenshots, copying, misuse, reuse, or resale of any content from this app, is strictly prohibited. Our app monitors and records all screenshots and recordings. Violators will face strict legal action.

THIS IS COPYRIGHTED CONTENT. Unauthorized use, including screenshots, copying, misuse, reuse, or resale of any content from this app, is strictly prohibited. Our app monitors and records all screenshots and recordings. Violators will face strict legal action.

THIS IS COPYRIGHTED CONTENT. Unauthorized use, including screenshots, copying, misuse, reuse, or resale of any content from this app, is strictly prohibited. Our app monitors and records all screenshots and recordings. Violators will face strict legal action.

CHILDHOOD GINGIVAL DISEASES

Non- Plaque Induced Gingival Diseases:

D) Congenital Abnormalities:

a) Congenital Epulis:

- Congenital Epulis of newborn is rare gingival tumor that occurs along the alveolar ridge.
- It is usually associated with abnormalities of teeth or additional congenital malformations.
- Clinically, it appears as a smooth well defined erythematous masses arising from gum pads.

b) Congenital Gum Synechiae

- Characterized by congenital adhesions between different parts of oral cavity.
- Causes difficulty in breathing and respiration soon after birth.

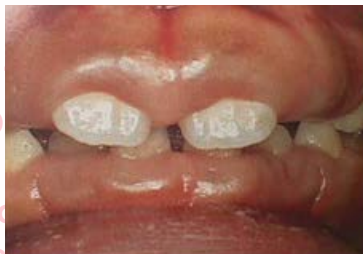E) Trauma:

- Gingival changes due to trauma includes:

External trauma to the tissue, bites, tooth brush abrasion, idiopathic trauma, habits like nail biting and abrasive foods	Traumatic lesions
Fixed anterior margin of the acrylic plate of a removable appliance	Transient Gingival Hyperplasia
Chronic irritation during orthodontic treatment	Localized, acute inflammatory reaction
Improper brushing technique	Mucogingival defects like recession ⁴

F) Gingival Diseases associated with Heredity

- Benign, non-inflammatory, familial fibrotic enlargements such as hereditary gingival fibromatosis, appears non- hemorrhagic, firm, progressing slowly upon eruption of permanent dentition.



- It can be inherited as a simple mendelian trait.

DISCLAIMER

THIS IS COPYRIGHTED CONTENT. Unauthorized use, including screenshots, copying, misuse, reuse, or resale of any content from this app, is strictly prohibited. Our app monitors and records all screenshots and recordings. Violators will face strict legal action.

DISCLAIMER
THIS IS COPYRIGHTED CONTENT. Unauthorized use, including screenshots, copying, misuse, reuse, or resale of any content from this app, is strictly prohibited. Our app monitors and records all screenshots and recordings. Violators will face strict legal action.

THIS IS COPYRIGHTED CONTENT. Unauthorized use, including screenshots, copying, misuse, reuse, or resale of any content from this app, is strictly prohibited. Our app monitors and records all screenshots and recordings. Violators will face strict legal action.

DISCLAIMER

CHILDHOOD GINGIVAL DISEASES

Non- Plaque Induced Gingival Diseases:

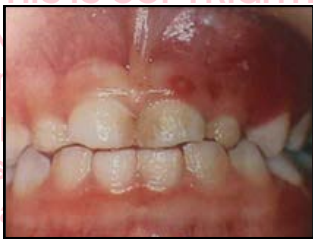G) Foreign Body Reaction:

- Not very common, but can happen during amalgam tattooing.

H) Gingival Manifestations of Systemic Diseases:

i) Gingival lesions associated with Chicken pox

- Varicella herpes virus, primarily affects individuals under the age of 15 years.
- Small ulcers may develop in the oral cavity often in palate, buccal mucosa and gingiva.



ii) Gingival Lesions associated with Mononucleosis:

- Mononucleosis is produced by Epstein Barr Virus.
- It is a primary disease of children and young adults.

primarily a disease of children and young adults [26]. The clinical symptoms are most prominent in young adults and common signs & symptoms include fatigue, malaise, headache, fever, sore throat, enlarged tonsils, and lymphadenopathy [27,28]. Alterations in the oral cavity include gingival bleeding, petechiae of the soft palate, ulceration of the gingiva and buccal mucosa (White, 1998). Palatal petechiae are usually present before systemic symptoms become evident [29].

iii) Soft tissue lesions associated with Herpangina

- The coxsackie group A viruses are associated with Herpangina.
- Commonly seen in young children.
- Clinically consists of numerous small vesicles which proceed to small ulcers contained on a gray base and inflamed periphery.
- The ulcers appear in the hard and soft palate, posterior pharyngeal wall, buccal mucosa or tongue.
- The ulcers are generally not painful and usually heal within a few days to a week.

DISCLAIMER

THIS IS COPYRIGHTED CONTENT. Unauthorized use, including screenshots, copying, misuse, reuse, or resale of any content from this app, is strictly prohibited. Our app monitors and records all screenshots and recordings. Violators will face strict legal action.

DISCLAIMER
THIS IS COPYRIGHTED CONTENT. Unauthorized use, including screenshots, copying, misuse, reuse, or resale of any content from this app, is strictly prohibited. Our app monitors and records all screenshots and recordings. Violators will face strict legal action.

CHILDHOOD GINGIVAL DISEASES

Non- Plaque Induced Gingival Diseases:

H) Gingival Manifestations of Systemic Diseases:

iv) Soft tissue lesions associated with hand foot and mouth lesions:

- The majority of hand foot and mouth lesion appear in children between 6 months and 5 years of age.
- Both Coxsackie group A and B may play a role in this disease.
- Clinically resembles herpangina but results in difficulty in eating due to sore mouth.
- Generally self-limiting and regress in 1-2 weeks.

v) Wegener's Granulomatosis:

- It is a systemic disease that initially presents with striking alterations that are confined to gingival diseases.
- Classically, the gingival tissues exhibit erythema and enlargement band that are typically described as Strawberry Gums.

vi) Kindlers Syndrome:

- Cutaneous neonatal bullae, poikiloderma, photosensitivity and acral atrophy are present in this condition.
- It may also present with oral lesions that are consistent with desquamative gingivitis.

PERIODONTITIS IN CHILDREN: (TG and AAPD article)

- Periodontitis in children is rare and if present is usually associated with systemic disease like leukemia, cyclic neutropenia, type 1 diabetes.
- If a child with periodontitis is encountered refer for specialist review.
- Although there is a much lower prevalence of destructive periodontal disease in children than in adults, children can develop severe forms of periodontitis.

predisposition for aggressive disease. Current modalities for managing periodontal diseases of children and adolescents may include antibiotic therapy in combination with non-surgical and/or surgical therapy. Since early diagnosis ensures the greatest chance for successful treatment,⁹² it is important that children receive a periodontal examination as part of their routine dental visits.

this app, is strictly prohibited. Our app monitors and records all screenshots and recordings. Violators will face strict legal action.

DISCLAIMER

THIS IS COPYRIGHTED CONTENT. Unauthorized use, including screenshots, copying, misuse, reuse, or resale of any content from this app, is strictly prohibited. Our app monitors and records all screenshots and recordings. Violators will face strict legal action.

DISCLAIMER
THIS IS COPYRIGHTED CONTENT. Unauthorized use, including screenshots, copying, misuse, reuse, or resale of any content from this app, is strictly prohibited. Our app monitors and records all screenshots and recordings. Violators will face strict legal action.

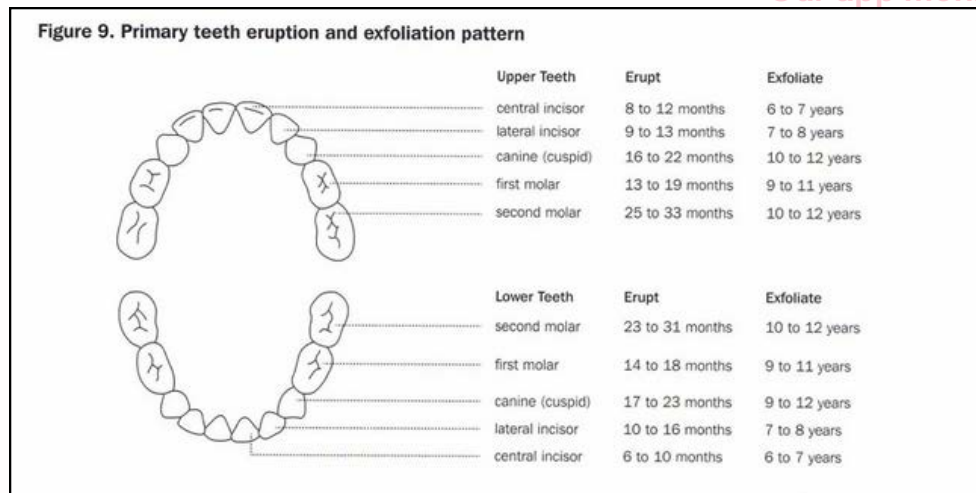
THIS IS COPYRIGHTED CONTENT. Unauthorized use, including screenshots, copying, misuse, reuse, or resale of any content from this app, is strictly prohibited. Our app monitors and records all screenshots and recordings. Violators will face strict legal action.

DISCLAIMER

AGE DETERMINATION FROM OPG

- Tooth eruption serves as a valuable indicator of dental age and serves as an index of the skeletal maturation.
- From 6 months to 2 and half years of age the primary teeth erupt in the mouth.

Primary teeth: Eruption and Exfoliation time



Primary Tooth Eruption Timeline		
Maxillary	Eruption(Months)	Order of eruption
Central incisor	8-12	2nd
Lateral incisor	9-13	3rd
Canine	16-22	7th
First molar	13-19	5th
Second molar	25-33	10th
Mandibular		
Central incisor	6-10	1st
Lateral incisor	10-16	4th
Canine	17-23	8th
First molar	14-18	6th
Second molar	23-31	9th

- From six years of age permanent 1st molar start to appear in the mouth.
- Permanent teeth eruption is a complex process that can be influenced by a number of general factors: Genetics, nutrition, preterm birth, socioeconomic status, body height and weight, craniofacial morphology, hormonal factors, and various systemic diseases.
- From 6 -12 years of age the primary teeth are being shed along with eruption of permanent teeth:

DISCLAIMER

THIS IS COPYRIGHTED CONTENT. Unauthorized use, including screenshots, copying, misuse, reuse, or resale of any content from this app, is strictly prohibited. Our app monitors and records all screenshots and recordings. Violators will face strict legal action.

DISCLAIMER
THIS IS COPYRIGHTED CONTENT. Unauthorized use, including screenshots, copying, misuse, reuse, or resale of any content from this app, is strictly prohibited. Our app monitors and records all screenshots and recordings. Violators will face strict legal action.

THIS IS COPYRIGHTED CONTENT. Unauthorized use, including screenshots, copying, misuse, reuse, or resale of any content from this app, is strictly prohibited. Our app monitors and records all screenshots and recordings. Violators will face strict legal action.

THIS IS COPYRIGHTED CONTENT. Unauthorized use, including screenshots, copying, misuse, reuse, or resale of any content from this app, is strictly prohibited. Our app monitors and records all screenshots and recordings. Violators will face strict legal action.

AGE DETERMINATION FROM OPG

Eruption Sequence for permanent teeth:

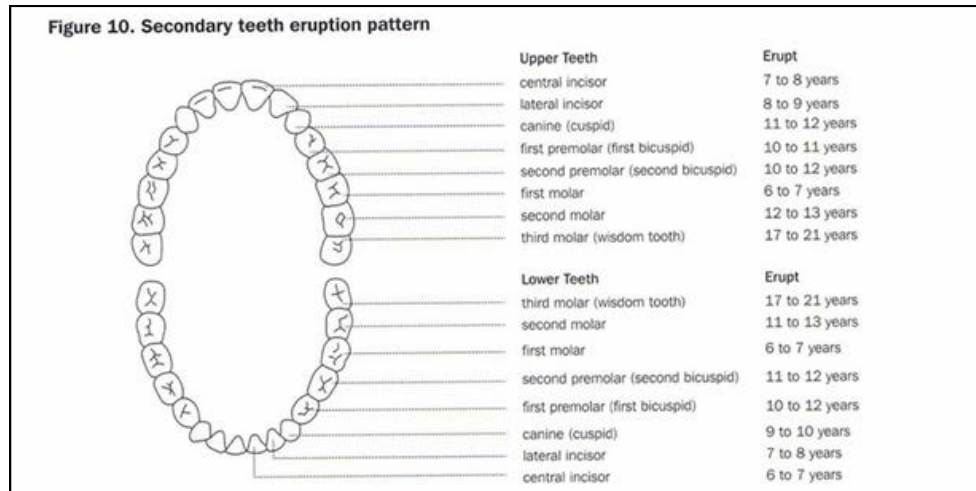


Image: Source - TG

Permanent Tooth Eruption Timeline				
	Maxillary Eruption(Years)	Order of Eruption	Mandibular Eruption(Years)	Order of Eruption
Central Incisor	7-8	2nd	6-7	1st
Lateral Incisor	8-9	3rd	7-8	2nd
Canine	11-12	6th	9-10	3rd
1st Premolar	10-11	5th	10-12	5th
2nd Premolar	10-12	5th	11-12	6th
1st Molar	6-7	1st	6-7	1st
2nd Molar	12-13	7th	11-13	7th
3rd Molar	17-21	8th	17-21	8th

Image: Source - Online

- However, it should be noted that dental development and eruption vary from person to person.

THIS IS COPYRIGHTED CONTENT. Unauthorized use, including screenshots, copying, misuse, reuse, or resale of any content from this app, is strictly prohibited. Our app monitors and records all screenshots and recordings. Violators will face strict legal action.

DISCLAIMER

THIS IS COPYRIGHTED CONTENT. Unauthorized use, including screenshots, copying, misuse, reuse, or resale of any content from this app, is strictly prohibited. Our app monitors and records all screenshots and recordings. Violators will face strict legal action.

DISCLAIMER
THIS IS COPYRIGHTED CONTENT. Unauthorized use, including screenshots, copying, misuse, reuse, or resale of any content from this app, is strictly prohibited. Our app monitors and records all screenshots and recordings. Violators will face strict legal action.

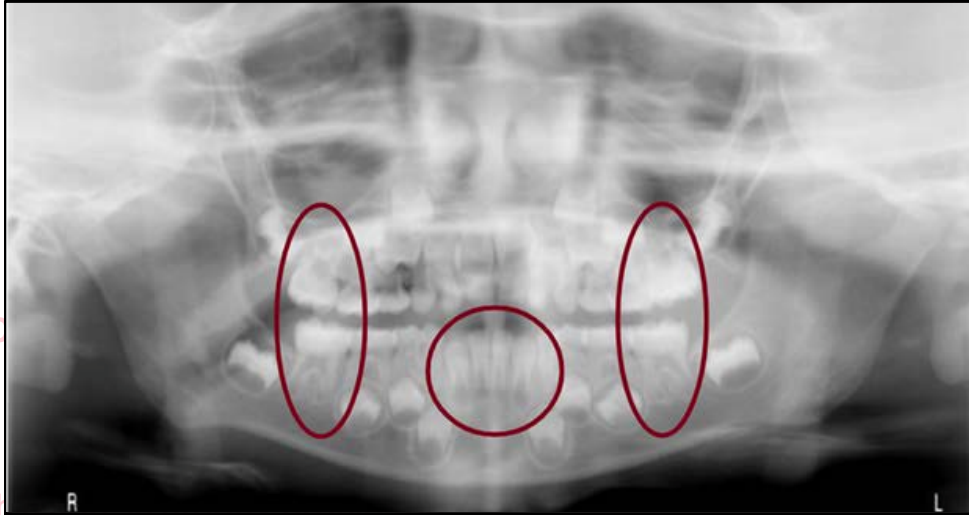
THIS IS COPYRIGHTED CONTENT. Unauthorized use, including screenshots, copying, misuse, reuse, or resale of any content from this app, is strictly prohibited. Our app monitors and records all screenshots and recordings. Violators will face strict legal action.

THIS IS COPYRIGHTED CONTENT. Unauthorized use, including screenshots, copying, misuse, reuse, or resale of any content from this app, is strictly prohibited. Our app monitors and records all screenshots and recordings. Violators will face strict legal action.

AGE DETERMINATION FROM OPG

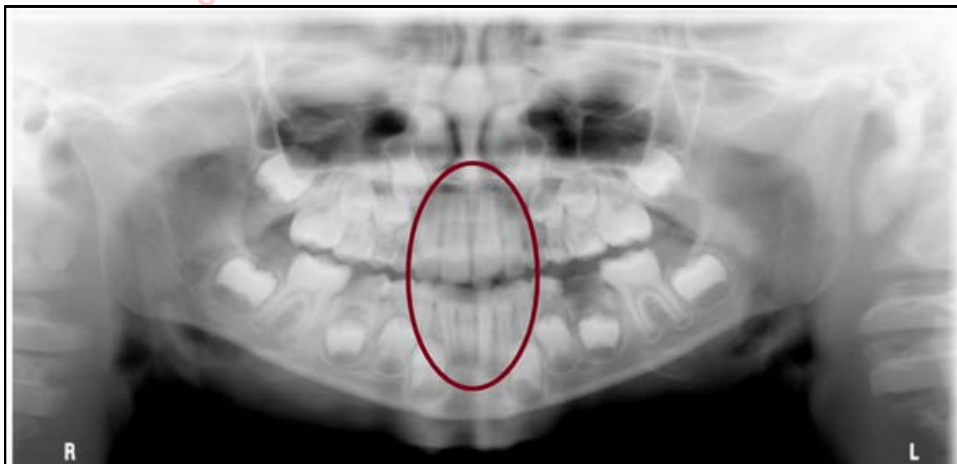
Age determination on OPG:

1) 6-7 years old



- Permanent 1st molar and mandibular incisors are visible in the mouth at this stage.

2) 8-9 years old



- All permanent incisors are erupted between the age of 8 and 9 years of age.

DISCLAIMER

THIS IS COPYRIGHTED CONTENT. Unauthorized use, including screenshots, copying, misuse, reuse, or resale of any content from this app, is strictly prohibited. Our app monitors and records all screenshots and recordings. Violators will face strict legal action.

DISCLAIMER
THIS IS COPYRIGHTED CONTENT. Unauthorized use, including screenshots, copying, misuse, reuse, or resale of any content from this app, is strictly prohibited. Our app monitors and records all screenshots and recordings. Violators will face strict legal action.

THIS IS COPYRIGHTED CONTENT. Unauthorized use, including screenshots, copying, misuse, reuse, or resale of any content from this app, is strictly prohibited. Our app monitors and records all screenshots and recordings. Violators will face strict legal action.

THIS IS COPYRIGHTED CONTENT. Unauthorized use, including screenshots, copying, misuse, reuse, or resale of any content from this app, is strictly prohibited. Our app monitors and records all screenshots and recordings. Violators will face strict legal action.

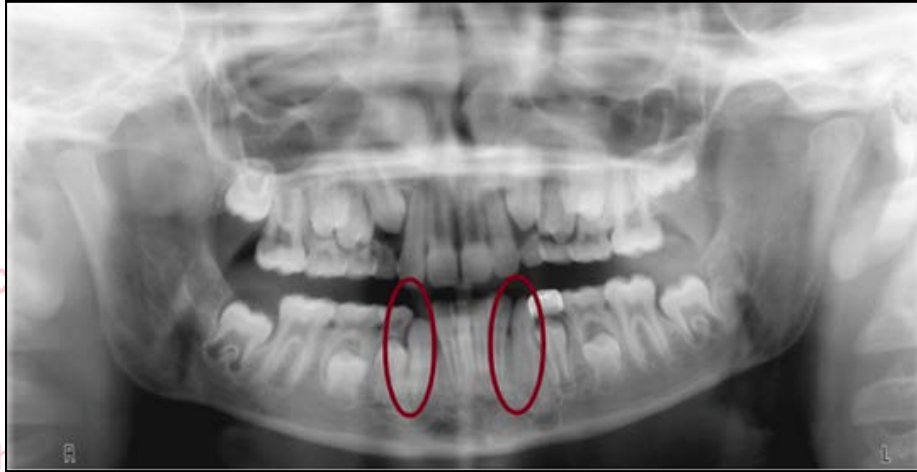THIS IS COPYRIGHTED CONTENT. Unauthorized use, including screenshots, copying, misuse, reuse, or resale of any content from this app, is strictly prohibited. Our app monitors and records all screenshots and recordings. Violators will face strict legal action.

AGE DETERMINATION FROM OPG

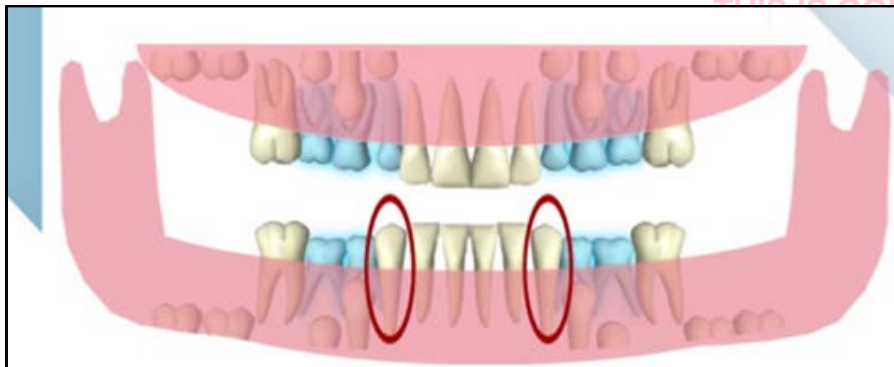
Age determination on OPG:

3) 10-12 years of age:

a) Early stage (age: 9-10 years)



- Permanent mandibular canines replace primary mandibular canines in early stage of 10-12 years of age.
- Permanent mandibular canines are first to erupt after the first molars and incisors.
- Age 9-10 years



THIS IS COPYRIGHTED CONTENT. Unauthorized use, including screenshots, copying, misuse, reuse, or resale of any content from this app, is strictly prohibited. Our app monitors and records all screenshots and recordings. Violators will face strict legal action.

DISCLAIMER

THIS IS COPYRIGHTED CONTENT. Unauthorized use, including screenshots, copying, misuse, reuse, or resale of any content from this app, is strictly prohibited. Our app monitors and records all screenshots and recordings. Violators will face strict legal action.

THIS IS COPYRIGHTED CONTENT. Unauthorized use, including screenshots, copying, misuse, reuse, or resale of any content from this app, is strictly prohibited. Our app monitors and records all screenshots and recordings. Violators will face strict legal action.

DISCLAIMER
THIS IS COPYRIGHTED CONTENT. Unauthorized use, including screenshots, copying, misuse, reuse, or resale of any content from this app, is strictly prohibited. Our app monitors and records all screenshots and recordings. Violators will face strict legal action.

DISCLAIMER

THIS IS COPYRIGHTED CONTENT. Unauthorized use, including screenshots, copying, misuse, reuse, or resale of any content from this app, is strictly prohibited. Our app monitors and records all screenshots and recordings. Violators will face strict legal action.

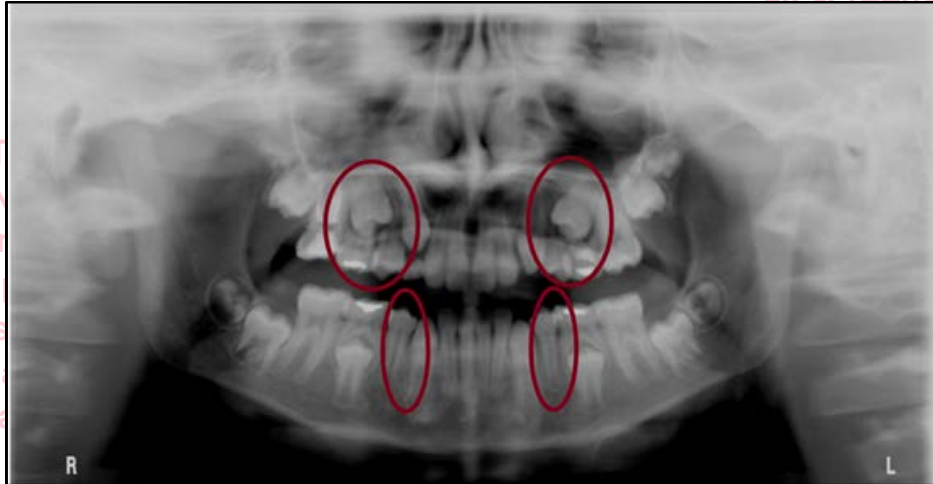
AGE DETERMINATION FROM OPG

Age determination on OPG:

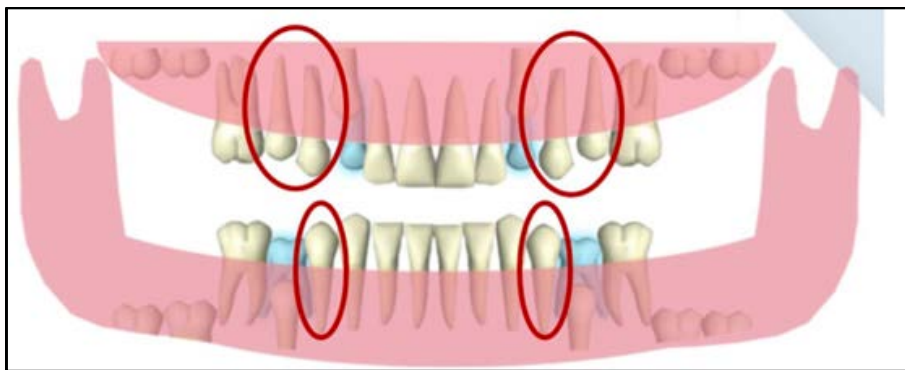
3) 10-12 years of age:

b) Middle stage: (age: 10-11 years)

- Maxillary 1st and 2nd premolars and mandibular 1st premolar erupt at the middle stage of 10-12 years of age.



- Age 10-11 years



THIS IS COPYRIGHTED CONTENT. Unauthorized use, including screenshots, copying, misuse, reuse, or resale of any content from this app, is strictly prohibited. Our app monitors and records all screenshots and recordings. Violators will face strict legal action.

DISCLAIMER

THIS IS COPYRIGHTED CONTENT. Unauthorized use, including screenshots, copying, misuse, reuse, or resale of any content from this app, is strictly prohibited. Our app monitors and records all screenshots and recordings. Violators will face strict legal action.

THIS IS COPYRIGHTED CONTENT. Unauthorized use, including screenshots, copying, misuse, reuse, or resale of any content from this app, is strictly prohibited. Our app monitors and records all screenshots and recordings. Violators will face strict legal action.

DISCLAIMER
THIS IS COPYRIGHTED CONTENT. Unauthorized use, including screenshots, copying, misuse, reuse, or resale of any content from this app, is strictly prohibited. Our app monitors and records all screenshots and recordings. Violators will face strict legal action.

THIS IS COPYRIGHTED CONTENT. Unauthorized use, including screenshots, copying, misuse, reuse, or resale of any content from this app, is strictly prohibited. Our app monitors and records all screenshots and recordings. Violators will face strict legal action.

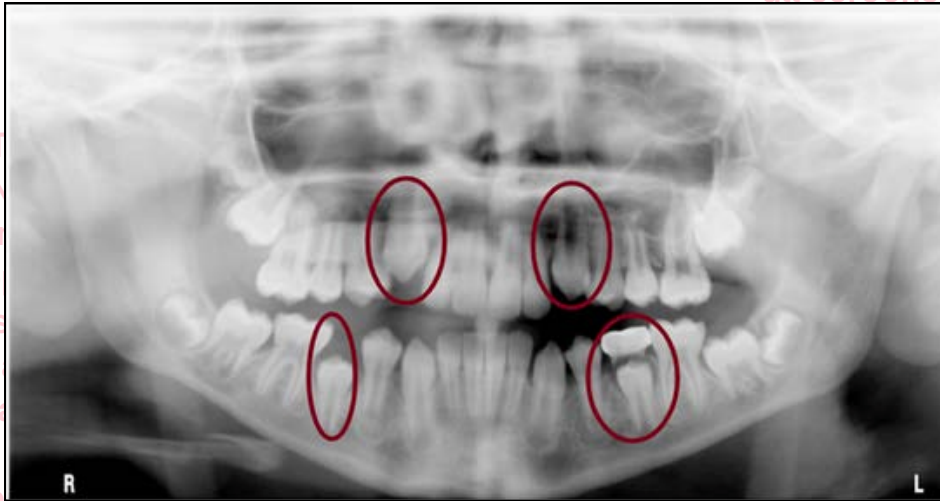
AGE DETERMINATION FROM OPG

Age determination on OPG:

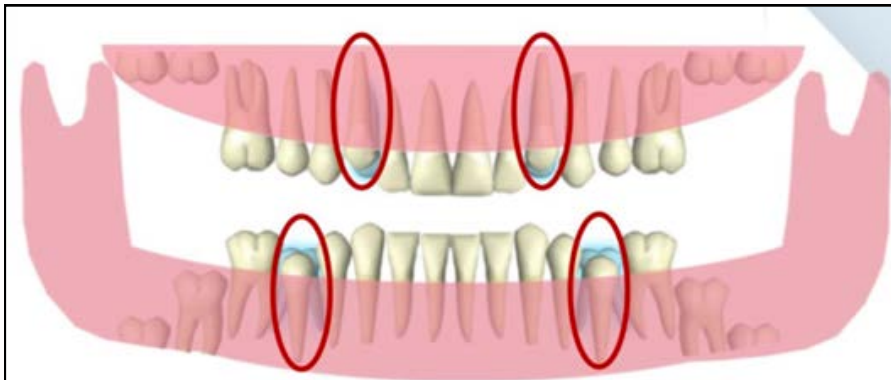
3) 10-12 years of age:

c) Late stage: (11-12 years of age)

- Maxillary canines and mandibular 2nd premolar are the last to erupt during the late stage of 10-12 years of age before the eruption of second molars.



- Age 11-12 years



Summary of teeth eruption stages in 10-12 years of age

EARLY STAGE (9-10) YEARS	MIDDLE STAGE (10-11) YEARS	LATE STAGE (11-12) YEARS
<ul style="list-style-type: none"> Mandibular Canines 	<ul style="list-style-type: none"> Maxillary 1st premolar Maxillary 2nd premolar Mandibular 1st premolar 	<ul style="list-style-type: none"> Maxillary canine Mandibular 2nd premolar

DISCLAIMER

THIS IS COPYRIGHTED CONTENT. Unauthorized use, including screenshots, copying, misuse, reuse, or resale of any content from this app, is strictly prohibited. Our app monitors and records all screenshots and recordings. Violators will face strict legal action.

DISCLAIMER
THIS IS COPYRIGHTED CONTENT. Unauthorized use, including screenshots, copying, misuse, reuse, or resale of any content from this app, is strictly prohibited. Our app monitors and records all screenshots and recordings. Violators will face strict legal action.

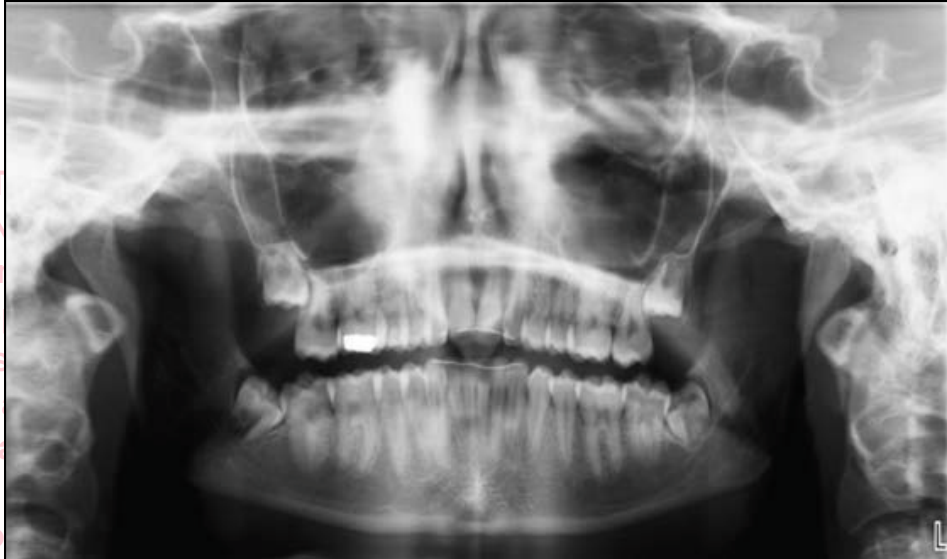THIS IS COPYRIGHTED CONTENT. Unauthorized use, including screenshots, copying, misuse, reuse, or resale of any content from this app, is strictly prohibited. Our app monitors and records all screenshots and recordings. Violators will face strict legal action.

AGE DETERMINATION FROM OPG

Age determination on OPG:

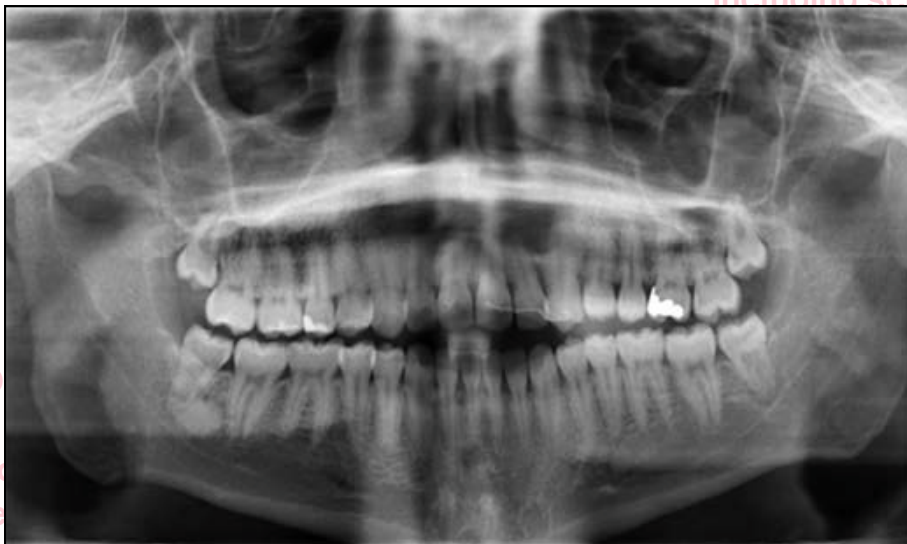4) 13-17 years of age:

- All permanent teeth are erupted except for 3rd molars.
- 28 permanent teeth, with no primary teeth in the oral cavity is seen.



5) 17 (+)

- Third molars if present erupt within 17-25 years of age resulting in all 32 permanent teeth in oral cavity.



DISCLAIMER

THIS IS COPYRIGHTED CONTENT. Unauthorized use, including screenshots, copying, misuse, reuse, or resale of any content from this app, is strictly prohibited. Our app monitors and records all screenshots and recordings. Violators will face strict legal action.

DISCLAIMER
THIS IS COPYRIGHTED CONTENT. Unauthorized use, including screenshots, copying, misuse, reuse, or resale of any content from this app, is strictly prohibited. Our app monitors and records all screenshots and recordings. Violators will face strict legal action.

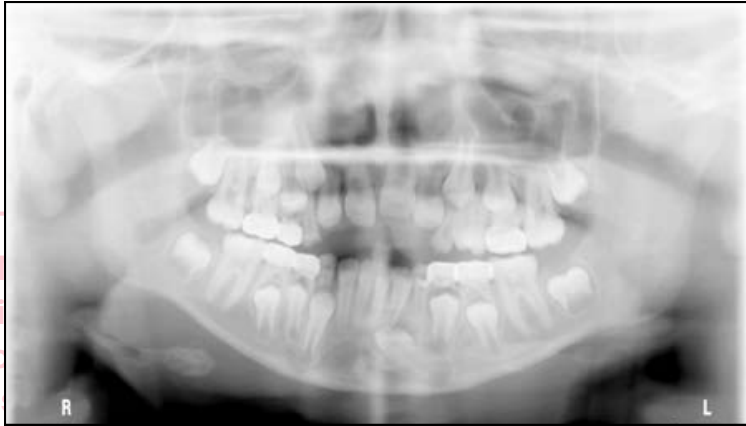DISCLAIMER
THIS IS COPYRIGHTED CONTENT. Unauthorized use, including screenshots, copying, misuse, reuse, or resale of any content from this app, is strictly prohibited. Our app monitors and records all screenshots and recordings. Violators will face strict legal action.

AGE DETERMINATION FROM OPG

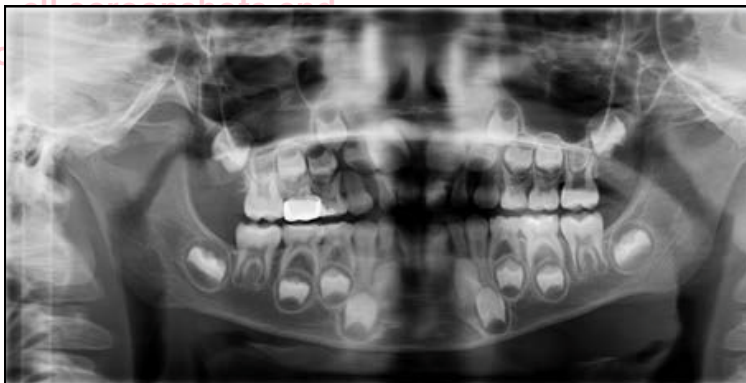Age determination on OPG:

5) 17 (+)

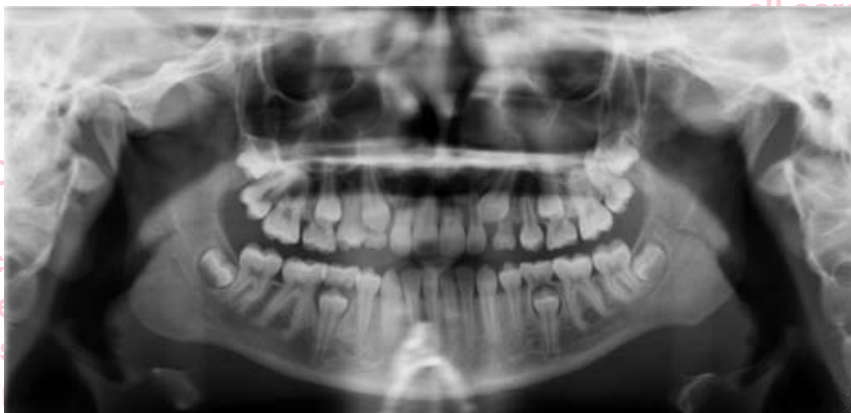- Examples



1) Fig: OPG of 7-9 years old child



2) Fig: OPG of 6-7 years of age



3) Image: OPG of 10-11 years old

DISCLAIMER

THIS IS COPYRIGHTED CONTENT. Unauthorized use, including screenshots, copying, misuse, reuse, or resale of any content from this app, is strictly prohibited. Our app monitors and records all screenshots and recordings. Violators will face strict legal action.

DISCLAIMER
THIS IS COPYRIGHTED CONTENT. Unauthorized use, including screenshots, copying, misuse, reuse, or resale of any content from this app, is strictly prohibited. Our app monitors and records all screenshots and recordings. Violators will face strict legal action.

THIS IS COPYRIGHTED CONTENT. Unauthorized use, including screenshots, copying, misuse, reuse, or resale of any content from this app, is strictly prohibited. Our app monitors and records all screenshots and recordings. Violators will face strict legal action.

THIS IS COPYRIGHTED CONTENT. Unauthorized use, including screenshots, copying, misuse, reuse, or resale of any content from this app, is strictly prohibited. Our app monitors and records all screenshots and recordings. Violators will face strict legal action.

THIS IS COPYRIGHTED CONTENT. Unauthorized use, including screenshots, copying, misuse, reuse, or resale of any content from this app, is strictly prohibited. Our app monitors and records all screenshots and recordings. Violators will face strict legal action.

THIS IS COPYRIGHTED CONTENT. Unauthorized use, including screenshots, copying, misuse, reuse, or resale of any content from this app, is strictly prohibited. Our app monitors and records all screenshots and recordings. Violators will face strict legal action.

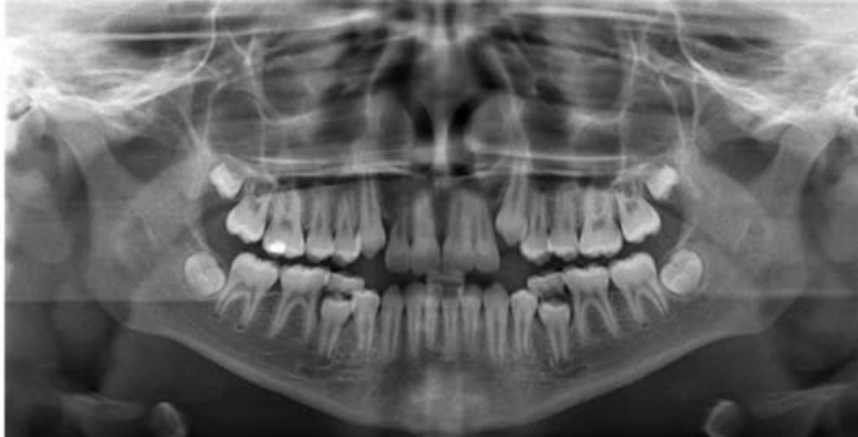
DISCLAIMER

AGE DETERMINATION FROM OPG

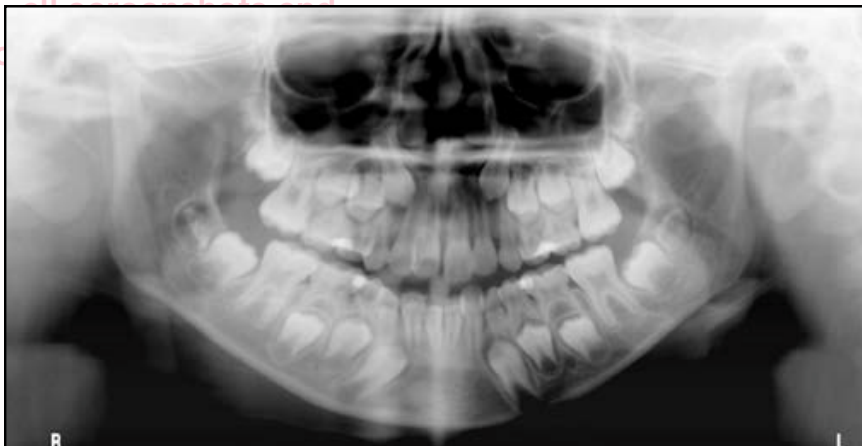Age determination on OPG:

5) 17 (+)

- Examples



4) Image: OPG of 11-12 years of age



5) Image: OPG of 8-9 years of age

THIS IS COPYRIGHTED CONTENT. Unauthorized use, including screenshots, copying, misuse, reuse, or resale of any content from this app, is strictly prohibited. Our app monitors and records all screenshots and recordings. Violators will face strict legal action.

DISCLAIMER

THIS IS COPYRIGHTED CONTENT. Unauthorized use, including screenshots, copying, misuse, reuse, or resale of any content from this app, is strictly prohibited. Our app monitors and records all screenshots and recordings. Violators will face strict legal action.

THIS IS COPYRIGHTED CONTENT. Unauthorized use, including screenshots, copying, misuse, reuse, or resale of any content from this app, is strictly prohibited. Our app monitors and records all screenshots and recordings. Violators will face strict legal action.

DISCLAIMER
THIS IS COPYRIGHTED CONTENT. Unauthorized use, including screenshots, copying, misuse, reuse, or resale of any content from this app, is strictly prohibited. Our app monitors and records all screenshots and recordings. Violators will face strict legal action.

THIS IS COPYRIGHTED CONTENT. Unauthorized use, including screenshots, copying, misuse, reuse, or resale of any content from this app, is strictly prohibited. Our app monitors and records all screenshots and recordings. Violators will face strict legal action.

PREVENTIVE DENTISTRY IN PEDIATRIC DENTISTRY

(Source- Article on Fluoride guidelines and Pit and fissure sealants (ADA), TG)

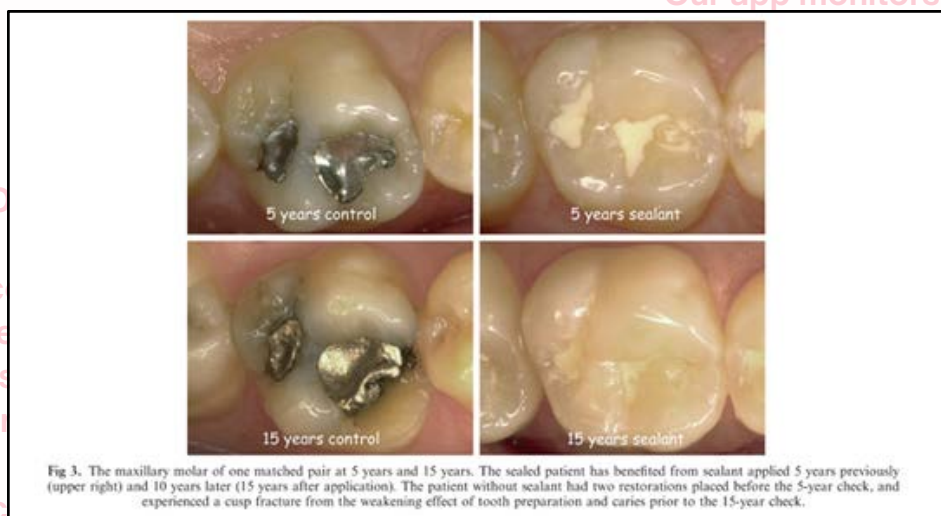- In dentistry, **Pit and fissure sealant application** to newly erupted posterior teeth and (occasionally) anterior teeth is the best method to prevent pit and fissure caries.
- **Fluoride use** is also a cornerstone for dental caries prevention.

1) Pit and Fissure sealants

- The term pit and fissure sealant are used to describe a chemically-active liquid material that is placed onto the occlusal pit and fissure of caries susceptible teeth.
- After application these pit and fissure sealants either cures chemically (auto polymerizing) or is cured with visible light cure (light source).
- It forms a micromechanically bonded protective layer that prevents the invasion of caries producing bacteria, and simultaneously cuts off the access of surviving caries- producing bacteria from their source of nutrients.
- The application of sealants for children at risk is not only cost effective, but long term a restoration preventive service. (This can be backed with evidence).

Advantages:

- Placement of resin-based sealants on the permanent molars of children and adolescent is effective for caries reduction.
- Evidence shows that children who have had sealants placed need less restorative work in future than those who did not have sealants placed.
- Also, the time between restorative treatments is greater in the sealed children, and the restoration did not need to be so extensive.
- Placement of pit and fissure sealants significantly reduces the percentage of non-cavitated carious lesions that progress in children, adolescents, and young adults that were sealed over, for as long as 5 years after sealant placement compared with teeth containing non cavitated carious lesions that remained unsealed.



strict legal action.

DISCLAIMER

THIS IS COPYRIGHTED CONTENT. Unauthorized use, including screenshots, copying, misuse, reuse, or resale of any content from this app, is strictly prohibited. Our app monitors and records all screenshots and recordings. Violators will face strict legal action.

DISCLAIMER

THIS IS COPYRIGHTED CONTENT. Unauthorized use, including screenshots, copying, misuse, reuse, or resale of any content from this app, is strictly prohibited. Our app monitors and records all screenshots and recordings. Violators will face strict legal action.

DISCLAIMER

THIS IS COPYRIGHTED CONTENT. Unauthorized use, including screenshots, copying, misuse, reuse, or resale of any content from this app, is strictly prohibited. Our app monitors and records all screenshots and recordings. Violators will face strict legal action.

PREVENTIVE DENTISTRY IN PEDIATRIC DENTISTRY

1) Pit and Fissure sealants

Conclusion of ADA expert Panel:

- (1) placement of resin-based sealants on the permanent molars of children and adolescents is effective for caries reduction;
- (2) reduction of caries incidence in children and adolescents after placement of resin-based sealants ranged from 86% at 1 year to 78.6% at 2 years and 58.6% at 4 years;
- (3) sealants are effective in reducing occlusal caries incidence in permanent first molars of children, with caries reductions of 76.3% at 4 years, when sealants were reapplied as needed. Caries reduction was 65% at 9 years from initial placement with no reapplication during the last 5 years;
- (4) pit and fissure sealants are retained on primary molars at a rate of 74.0 to 96.3% at 1 year and 70.6 to 76.5% at 2.8 years;
- (5) there is consistent evidence from private dental insurance and federal dental plan (Medicaid) databases that placement of sealants on first and second permanent molars in children and adolescents is

associated with reductions in the subsequent provision of restorative services;

- (6) evidence from Medicaid claims for children who were continuously enrolled for 4 years indicates that sealed permanent molars are less likely to receive restorative treatment, that the time between receiving sealants and restorative treatment is greater, and that the restorations were less extensive than those in permanent molars that were unsealed.

- Pit and fissure sealants can also be used to seal over an incipient lesion. When used as such, the lesion will not progress as long as the sealant remains intact and there is a seal to enamel around the periphery of the lesion. The downside of using sealants over incipient lesions is that when the sealant wears down to the point where the communication between the oral fluids and previously diagnosed incipient lesion occurs, the lesion is again susceptible to become active.
- Therefore, sealants must always be checked on re examination appointments to be certain that there is no pit or fissure area that is once again caries-susceptible through wear of the sealants.

DISCLAIMER

THIS IS COPYRIGHTED CONTENT. Unauthorized use, including screenshots, copying, misuse, reuse, or resale of any content from this app, is strictly prohibited. Our app monitors and records all screenshots and recordings. Violators will face strict legal action.

DISCLAIMER
THIS IS COPYRIGHTED CONTENT. Unauthorized use, including screenshots, copying, misuse, reuse, or resale of any content from this app, is strictly prohibited. Our app monitors and records all screenshots and recordings. Violators will face strict legal action.

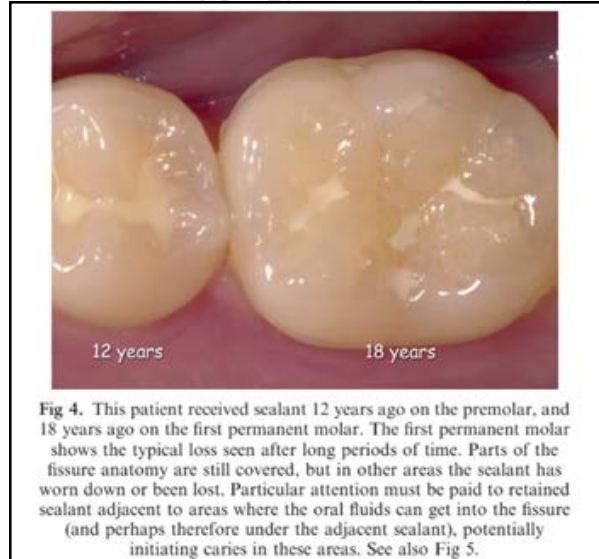
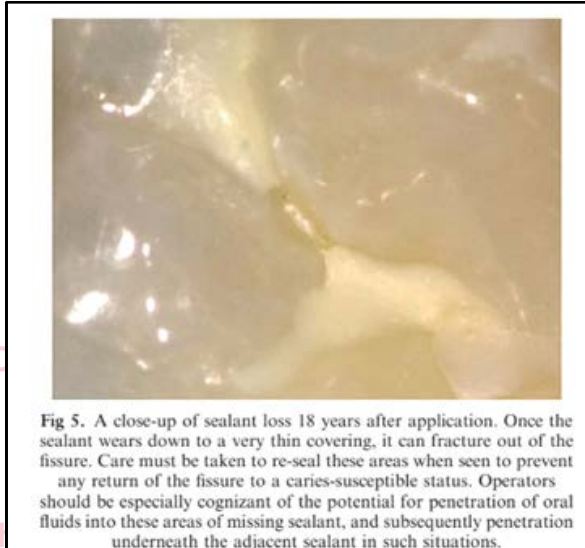
THIS IS COPYRIGHTED CONTENT. Unauthorized use, including screenshots, copying, misuse, reuse, or resale of any content from this app, is strictly prohibited. Our app monitors and records all screenshots and recordings. Violators will face strict legal action.

DISCLAIMER

PREVENTIVE DENTISTRY IN PEDIATRIC DENTISTRY

1) Pit and Fissure sealants

Conclusion of ADA expert Panel:



Material used for pit and fissure sealant:

- **Resin-based sealants** are the first choice of materials for dental sealants.
- **Glass-ionomer cements** can be used as an interim preventive agent, where there are indications for placement of resin-based cement, but, where concerns about moisture control may compromise such placement.

It can be concluded that glass-ionomer sealants, whether resealed or not, cannot be as cost-effective as resin-bonded sealants, when the expense of placement in time (and thus cost) along with retention rates are used as the basis of efficacy.⁶² However, there is a useful application for a glass-ionomer sealant, such as Fuji 7 (Triage), in situations of partially erupted molars where a complete and final sealant with a resin material is not possible due to moisture control issues. In this situation, the application of a glass-ionomer sealant as a temporary sealant that will release fluoride is indicated. This will minimize the chances for caries initiation until such a time as the tooth is fully erupted and can be sealed with a resin sealant in the conventional manner.

Image- source (Article)

DISCLAIMER

THIS IS COPYRIGHTED CONTENT. Unauthorized use, including screenshots, copying, misuse, reuse, or resale of any content from this app, is strictly prohibited. Our app monitors and records all screenshots and recordings. Violators will face strict legal action.

DISCLAIMER
THIS IS COPYRIGHTED CONTENT. Unauthorized use, including screenshots, copying, misuse, reuse, or resale of any content from this app, is strictly prohibited. Our app monitors and records all screenshots and recordings. Violators will face strict legal action.

THIS IS COPYRIGHTED CONTENT. Unauthorized use, including screenshots, copying, misuse, reuse, or resale of any content from this app, is strictly prohibited. Our app monitors and records all screenshots and recordings. Violators will face strict legal action.

PREVENTIVE DENTISTRY IN PEDIATRIC DENTISTRY

1) Pit and Fissure sealants

Discussion about use of resin based and Glass ionomer cement across literature

In 1996, Simonsen reviewed the literature on glass-ionomer sealants for a symposium at an Annual Session of the International Association for Dental Research. The conclusion was as follows: 'An objective assessment of the presently available scientific literature on the use of glass-ionomer materials as pit and fissure sealants is not encouraging in terms of retention, but appears somewhat more positive for caries prevention. At the time of this writing [1996], the published literature indicates that retention for resin-based sealants is better than for glass-ionomer sealants, but differences in caries prevention remain equivocal.'³⁷

Two studies published after the above review concluded that the resin-based sealant is not only superior in terms of retention, but also in caries prevention^{38,39} (in which, of course, retention plays the key role). Thus, traditional glass-ionomer cements are sparingly used in the United States as fissure sealants since their retention

- The retention of Glass ionomer cement is significantly inferior to the resin-based sealants.
- Although Glass ionomer cement have documented high levels of fluoride release, when used as a pit and fissure sealant, the traditional GIC has shown very poor retention rates as well as leakage when fully retained.
- It is known that the caries prevention of Glass ionomer sealant is dependent of both retention of sealant and fluoride release.

As a result of the poor retention of the glass-ionomer sealants, it has been suggested that polyalkenoate cements probably should be regarded as 'fluoride depot' materials rather than fissure sealants when used in this context.⁵¹ Additionally, other researchers have begun

- **Unfilled Sealant is superior** to filled or partially filled (filled sealant or flowable resin composite).
- This can be contributed to better penetration of unfilled sealant into the fissure owing to better flow.
- Studies have shown that, Unfilled light cure resin was significantly better retained than filled light-cured resin.

In addition to the above-mentioned disadvantage of lack of equivalent penetration of the filled sealants (or flowable resins, as they can be called), another disadvantage relates to occlusal adjustment. Unfilled sealant will abrade rapidly, usually within 24–48 hours, if it is left in occlusion with an opposing cusp tip.⁶ Filled sealant, however, will require occlusal adjustment included as a routine part of the application procedure. This not only increases the time and cost of the procedure but also, according to US local dental practice law, may prevent some auxiliaries who are allowed to apply sealant, from carrying out the occlusal adjustment phase, which essentially precludes the use of filled sealant in such jurisdictions. Tilliss *et al.* showed

strict legal action.

DISCLAIMER

THIS IS COPYRIGHTED CONTENT. Unauthorized use, including screenshots, copying, misuse, reuse, or resale of any content from this app, is strictly prohibited. Our app monitors and records all screenshots and recordings. Violators will face strict legal action.

DISCLAIMER

THIS IS COPYRIGHTED CONTENT. Unauthorized use, including screenshots, copying, misuse, reuse, or resale of any content from this app, is strictly prohibited. Our app monitors and records all screenshots and recordings. Violators will face strict legal action.

THIS IS COPYRIGHTED CONTENT. Unauthorized use, including screenshots, copying, misuse, reuse, or resale of any content from this app, is strictly prohibited. Our app monitors and records all screenshots and recordings. Violators will face strict legal action.

DISCLAIMER

PREVENTIVE DENTISTRY IN PEDIATRIC DENTISTRY

1) Pit and Fissure sealants

Discussion about use of resin based and Glass ionomer cement across literature

- A study has also concluded that topical fluorides may cause deterioration of filled sealants and glass ionomer sealants but not unfilled sealants.
- The use of a colored sealant is more preferred than clear sealants as it is easier to see the sealant during application, assess retention during follow ups, and also documentation over long period of time.
- Visible Light cured sealant or self-cured sealant is preferred over UV light cured sealants.

De Craene and co-workers showed that a visible-light-cured sealant (Heliocure) appeared to be as good as the self-cured sealants and better than the UV-light-cured sealants.¹² Thus, both self-cured and visible-light-cured materials should provide equal clinical effectiveness both in terms of retention and caries prevention.

Technique for sealant placement:

- Pit and fissure sealant is best applied to high-risk population by trained dental auxiliaries using auto cured colored sealant, applied under rubber dam or some alternative effective isolation technique (e.g., Isolite).
- This sealant should be applied onto an enamel surface that has been cleaned and etched with 35% phosphoric acid for 15 seconds.
- For maximum sealant effectiveness appropriate reapplication of sealant over time is necessary part of sealant maintenance.
- Studies have shown that pit and fissure sealant can be placed by dental auxiliaries in a **cost-effective** manner with a relatively high retention rate. (Hence, supports the delegation of sealants to well-trained dental auxiliaries)

an increased retention rate. In comparison to two-handed dentistry, four-handed delivery is associated with a 9% increase in the retention rate.²⁸ While sealant application is, inherently, a simple procedure, the details of the application procedure must be meticulously adhered to, particularly in terms of isolation of the teeth to be sealed. Failure to do so will result in sealant loss and a failure of the preventive procedure. Maintenance of a dry field is much simplified with a four-handed procedure, but a technique using a combined mouth prop, light source and high-volume suction device, such as the Isolite or Isodry (Isolite without the internal lighting) (Isolite Systems, Santa Barbara, CA, USA).

recordings. Violators will face strict legal action.

DISCLAIMER

THIS IS COPYRIGHTED CONTENT. Unauthorized use, including screenshots, copying, misuse, reuse, or resale of any content from this app, is strictly prohibited. Our app monitors and records all screenshots and recordings. Violators will face strict legal action.

DISCLAIMER
THIS IS COPYRIGHTED CONTENT. Unauthorized use, including screenshots, copying, misuse, reuse, or resale of any content from this app, is strictly prohibited. Our app monitors and records all screenshots and recordings. Violators will face strict legal action.

THIS IS COPYRIGHTED CONTENT. Unauthorized use, including screenshots, copying, misuse, reuse, or resale of any content from this app, is strictly prohibited. Our app monitors and records all screenshots and recordings. Violators will face strict legal action.

DISCLAIMER

PREVENTIVE DENTISTRY IN PEDIATRIC DENTISTRY

2) Fluoride Use in Dentistry:

- Fluoride use is the corner stone of caries prevention.

- a) **Community water fluoridation** at the level of 0.6-1.1 mg/L is an effective, efficient and acceptable approach in Australia.
- 2019 Guidelines for water fluoridation**

- (1) Water fluoridation should be continued as an effective, efficient, socially equitable and safe population approach to the prevention of caries in Australia.
- (2) Water fluoridation should be extended to as many non-fluoridated areas of Australia as possible, supported by all levels of Government.
- (3) The level of fluoride in the water supply should be within the range 0.6–1.1 mg/L.
- (4) For people who choose to consume bottled or filtered water containing fluoride, manufacturers should be encouraged to market bottled water containing approximately 1.0 mg/L fluoride and water filters that do not remove fluoride. All bottled water and water filters should be clearly labelled to indicate the concentration of fluoride in water consumed or resulting from the use of such products.
- (5) People in non-fluoridated areas should obtain the benefits of fluoride in drinking water using bottled water with fluoride at approximately 1 mg/L.

Note to Recommendation # 3: Individual states and territories have set targets and tolerances for fluoride in their water supplies with all being within the range 0.6–1.1 mg/L.

- b) **Self-use products**

i) Fluoridated toothpaste

Table 7. Recommended concentration of fluoride toothpaste according to age and risk of dental caries [NB1]

Toothpaste for people <u>not</u> at elevated risk of dental caries	
child younger than 18 months	twice-daily brushing without toothpaste
child 18 months to younger than 6 years	500 to 550 ppm (0.5 to 0.55 mg/g) fluoride twice daily, pea-sized amount [NB2]
child 6 years to adolescent	1000 to 1500 ppm (1 to 1.5 mg/g) fluoride twice daily
adolescent or adult	1000 to 1500 ppm (1 to 1.5 mg/g) fluoride twice daily
Toothpaste for people at elevated risk of dental caries [NB3]	
child younger than 18 months	twice-daily brushing with toothpaste may be recommended [NB2]
child 18 months to younger than 6 years	1000 ppm (1 mg/g) fluoride twice daily [NB2] OR more frequent use of 500 to 550 ppm (0.5 to 0.55 mg/g) fluoride [NB2]
child 6 years to adolescent	more frequent use of 1000 to 1500 ppm (1 to 1.5 mg/g) fluoride [NB2]
adolescent or adult	5000 ppm (5 mg/g) fluoride twice daily OR more frequent use of 1000 to 1500 ppm (1 to 1.5 mg/g) fluoride

ppm = parts per million

NB1: Spit out fluoride products to minimise ingestion; do not rinse the mouth after use to allow increased uptake of fluoride from the saliva.

NB2: Advise parents of the risk of fluorosis and the need to supervise toothbrushing.

NB3: Toothpaste use may be varied as needed, based on the dentist's clinical judgment.

Image: Source - TG

DISCLAIMER

THIS IS COPYRIGHTED CONTENT. Unauthorized use, including screenshots, copying, misuse, reuse, or resale of any content from this app, is strictly prohibited. Our app monitors and records all screenshots and recordings. Violators will face strict legal action.

DISCLAIMER
THIS IS COPYRIGHTED CONTENT. Unauthorized use, including screenshots, copying, misuse, reuse, or resale of any content from this app, is strictly prohibited. Our app monitors and records all screenshots and recordings. Violators will face strict legal action.

THIS IS COPYRIGHTED CONTENT. Unauthorized use, including screenshots, copying, misuse, reuse, or resale of any content from this app, is strictly prohibited. Our app monitors and records all screenshots and recordings. Violators will face strict legal action.

PREVENTIVE DENTISTRY IN PEDIATRIC DENTISTRY

2) Fluoride Use in Dentistry:

b) Self-use products

ii) Fluoride supplements:

- Supplements in the form of drops or tablets, to be chewed or swallowed should not be used.

iii) Fluoride mouth rinses:

- Children below the age of 6 years should not use fluoride rinses because of probability of its ingestion and risk of dental fluorosis.

neutral fluoride mouthwash 220 ppm (0.22 mg/mL)	Use in adults and children 6 years or older daily. Patients should rinse in the mouth for 1 minute at a time of day when toothpaste is not used [NB2].
neutral fluoride mouthwash 900 ppm (0.9 mg/mL)	Use in adults and children 6 years or older weekly or more frequently if indicated. Patients should rinse in the mouth for 1 minute at a time of day when toothpaste is not used [NB2].

Image Source - TG

2019 Guidelines:

- (12) Children below the age of 6 years should not use fluoride mouth rinse.
- (13) Fluoride mouth rinse might be used by people aged 6 years or more who have an elevated risk of developing caries. Fluoride mouth rinse should be used at a time of day when toothpaste is not used, and it should not be a substitute for brushing with fluoridated toothpaste. After rinsing, mouth rinse should be spat out, not swallowed.

b) Professionally Applied products:

i) Fluoride Varnishes:

- Fluoride varnish contains 22.6 mg/mL fluoride ion suspended in an alcohol and resin base. The most common product available in Australia is DURAPHAT.
- It is applied by dental or other health professionals directly to the dried teeth where it forms a waxy film that adheres to the teeth until it is worn off by chewing or brushing.

fluoride varnish 22 600 ppm (22.6 mg/mL)	Use in adults and children 1 year or older usually twice a year depending on dental caries risk. Applied by a dental practitioner to all at-risk dental surfaces.
---	--

DISCLAIMER

THIS IS COPYRIGHTED CONTENT. Unauthorized use, including screenshots, copying, misuse, reuse, or resale of any content from this app, is strictly prohibited. Our app monitors and records all screenshots and recordings. Violators will face strict legal action.

DISCLAIMER
THIS IS COPYRIGHTED CONTENT. Unauthorized use, including screenshots, copying, misuse, reuse, or resale of any content from this app, is strictly prohibited. Our app monitors and records all screenshots and recordings. Violators will face strict legal action.

DISCLAIMER

THIS IS COPYRIGHTED CONTENT. Unauthorized use, including screenshots, copying, misuse, reuse, or resale of any content from this app, is strictly prohibited. Our app monitors and records all screenshots and recordings. Violators will face strict legal action.

PREVENTIVE DENTISTRY IN PEDIATRIC DENTISTRY

2) Fluoride Use in Dentistry:

b) Professionally Applied products:

i) Fluoride Varnishes:

Fluoride varnish is effective in reducing caries in young children, adolescents and adults; for the prevention of coronal caries on all surfaces of the teeth; and for the prevention of root caries.⁴⁰ Their application up to four times a year has not been linked to an increased risk of dental fluorosis.⁴¹

opportunity for their use. Dental assistants with appropriate training might be involved in applying fluoride varnish. Other non-dental professionals who might be involved are usually registered or enrolled nurses, rural/remote health workers or Aboriginal health workers who have undergone specific training overseen by dental professionals. There is also scope for non-dental professionals' use of fluoride varnish to be included in the remit of residential-aged care workers and others who work with vulnerable populations.

ii) Fluoride Gel and Foam

- Fluoride gel contains high concentration of fluoride up to 12.3 mg/g.
- Applied by dental professionals using trays that retain the material in the teeth for several minutes.
- After removal of the trays the patient must spit out the residual gel.
- They are contraindicated in children below 10 years of age because large amount of fluoride can be ingested.
- Also, fluoride gel is more effective in permanent dentition.

more efficacious in the permanent dentition.^{43,44} The reviews found no evidence that the effect was dependent on frequency of applications. Like all forms of professionally provided fluoride, gels offer an alternative vehicle for caries prevention for individuals deemed to be at an elevated risk and in whom other fluoride modalities are not available or suitable.

There is no evidence to support the use of foam.⁴⁵

DISCLAIMER

THIS IS COPYRIGHTED CONTENT. Unauthorized use, including screenshots, copying, misuse, reuse, or resale of any content from this app, is strictly prohibited. Our app monitors and records all screenshots and recordings. Violators will face strict legal action.

DISCLAIMER

THIS IS COPYRIGHTED CONTENT. Unauthorized use, including screenshots, copying, misuse, reuse, or resale of any content from this app, is strictly prohibited. Our app monitors and records all screenshots and recordings. Violators will face strict legal action.

THIS IS COPYRIGHTED CONTENT. Unauthorized use, including screenshots, copying, misuse, reuse, or resale of any content from this app, is strictly prohibited. Our app monitors and records all screenshots and recordings. Violators will face strict legal action.

DISCLAIMER

PREVENTIVE DENTISTRY IN PEDIATRIC DENTISTRY

2) Fluoride Use in Dentistry:

b) Professionally Applied products:

ii) Fluoride Gel and Foam

acidulated phosphate fluoride gel or foam 12 300 ppm (12.3 mg/g)	<p>Use in adults and children 10 years or older usually twice a year depending on dental caries risk.</p> <p>Applied by a dental practitioner for up to 4 minutes using trays—evacuate excess [NB2].</p> <p>Acidulated phosphate fluoride is preferred to neutral fluoride products because it has better enamel uptake; however, avoid acidulated gels and foams in patients with ceramic crowns and bridgework, direct restorations containing glass particles, or poor salivary flow (eg patients undergoing head or neck irradiation).</p>
neutral fluoride gel or foam 5000 to 9000 ppm (5 to 9 mg/g)	<p>Use in adults and children (age restriction variable) usually twice a year depending on dental caries risk.</p> <p>Can be used for patients with ceramic crowns and bridgework, direct restorations containing glass particles, or poor salivary flow (eg patients undergoing head or neck irradiation).</p> <p>Applied by a dental practitioner for up to 4 minutes using trays—evacuate excess [NB2].</p> <p>Adults can use neutral fluoride gel or foam at home, according to recommended instructions.</p>

Image: Source - TG

iii) Silver Diamine fluoride:

- 38 % SDF twice yearly is effective in arresting active carious lesion in primary teeth and root caries in permanent teeth among elderly, and its major drawback is black staining of teeth.

the black staining of the carious lesion. SF has been found comparable to atraumatic restorations with GIC in very remote Indigenous children.⁴⁸ Its use might be indicated in situations where traditional treatment approaches to caries management might not be possible due to behavioural or medical management challenges, or where access to care is difficult or not available.

silver fluoride formulations	<p>Use in adults and children (age restriction variable) usually twice a year or as recommended by a dentist.</p> <p>Applied by a dental practitioner to arrest carious lesions, but can stain teeth black.</p>
------------------------------	---

DISCLAIMER

THIS IS COPYRIGHTED CONTENT. Unauthorized use, including screenshots, copying, misuse, reuse, or resale of any content from this app, is strictly prohibited. Our app monitors and records all screenshots and recordings. Violators will face strict legal action.

DISCLAIMER
THIS IS COPYRIGHTED CONTENT. Unauthorized use, including screenshots, copying, misuse, reuse, or resale of any content from this app, is strictly prohibited. Our app monitors and records all screenshots and recordings. Violators will face strict legal action.

THIS IS COPYRIGHTED CONTENT. Unauthorized use, including screenshots, copying, misuse, reuse, or resale of any content from this app, is strictly prohibited. Our app monitors and records all screenshots and recordings. Violators will face strict legal action.

DISCLAIMER

PREVENTIVE DENTISTRY IN PEDIATRIC DENTISTRY

2) Fluoride Use in Dentistry:

b) Professionally Applied products:

iv) Fluoride plus CPP-ACP formulations:

- Effective especially in ortho demineralization cases.

Formulation	Usual directions for use
fluoride+CPP-ACP 900 ppm+10% cream	Use in adults and children for noncavitated white spot lesions twice daily after brushing with usual fluoride toothpaste. Patients should apply the cream to the teeth, hold in the mouth for 3 to 5 minutes, spit out excess and avoid rinsing the mouth [NB2].
fluoride+CPP-ACP 22 600 ppm (22.6 mg/mL)+2% varnish	Use in adults and children for noncavitated white spot lesions usually twice a year depending on dental caries risk. Applied by a dental practitioner to all at-risk dental surfaces.
CPP-ACP = casein phosphopeptide-amorphous calcium phosphate NB1: Treatment choice is based on clinical judgment and requires a complete assessment of the patient (eg age, other medications, disease risk). NB2: Spit out fluoride products to minimise ingestion; do not rinse the mouth after use to allow increased uptake of fluoride from the saliva.	

DISCLAIMER

THIS IS COPYRIGHTED CONTENT. Unauthorized use, including screenshots, copying, misuse, reuse, or resale of any content from this app, is strictly prohibited. Our app monitors and records all screenshots and recordings. Violators will face strict legal action.

THIS IS COPYRIGHTED CONTENT. Unauthorized use, including screenshots, copying, misuse, reuse, or resale of any content from this app, is strictly prohibited. Our app monitors and records all screenshots and recordings. Violators will face strict legal action.

DISCLAIMER

THIS IS COPYRIGHTED CONTENT. Unauthorized use, including screenshots, copying, misuse, reuse, or resale of any content from this app, is strictly prohibited. Our app monitors and records all screenshots and recordings. Violators will face strict legal action.

THIS IS COPYRIGHTED CONTENT. Unauthorized use, including screenshots, copying, misuse, reuse, or resale of any content from this app, is strictly prohibited. Our app monitors and records all screenshots and recordings. Violators will face strict legal action.

DISCLAIMER
THIS IS COPYRIGHTED CONTENT. Unauthorized use, including screenshots, copying, misuse, reuse, or resale of any content from this app, is strictly prohibited. Our app monitors and records all screenshots and recordings. Violators will face strict legal action.

CHILDHOOD CARIES MANAGEMENT

(Sources- Article on Early childhood feeding practices and dental caries, Evans articles, TG, Internet for images, Rationale for Restoration of carious primary teeth article, Source- REVIEW article Front. Pediatr., 18 July 2017, Sec. Children and Health Volume 5 - 2017 Early Childhood Caries: Prevalence, Risk Factors, and Prevention)

Dental Caries in Children:

- **Early childhood caries (ECC)** is the presence of one or more decayed (cavitated and non-cavitated lesions), missing (due to caries), or filled tooth surfaces in any primary tooth in a child under the age of six. (Source-Early childhood feeding practices and dental caries article)
- **ECC** is the presence of one or more cavitated or non cavitated carious lesion before a child's sixth birthday.
- **Severe Early Childhood caries (S-ECC)** is smooth surface caries in a child less than 3 years old.

Figure 1. Definition of Early Childhood Caries [Ismail and Sohn, 1999]

Early Childhood Caries (ECC):

- dmfs* ≥ 1 in any 1^o tooth in a child ≤ 71 months old

Severe Early Childhood Caries (S-ECC):

- Any sign of smooth surface caries in a child < 3 y.o.
- dmfs ≥ 1 (smooth surface cavity) in 1^o maxillary anterior teeth at age 3-5 yrs
- dmfs ≥ 4 (age 3 yrs)
- dmfs ≥ 5 (age 4 yrs)
- dmfs ≥ 6 (age 5 yrs)

*d = non-cavitated or cavitated lesion, m = missing due to caries

Source- (Review on restoration of carious primary teeth article)

- Several research groups have attempted to develop classification systems for early childhood caries:

TABLE 1 | Classification based on the severity of ECC and etiology (73).

Type I (mild to moderate)	The existence of 'isolated carious lesion(s)' involving incisors and/or molars. The most common causes are usually a combination of semisolid or solid food and lack of oral hygiene.
Type II (moderate to severe)	ECC was described as 'labiolingual lesions' affecting maxillary incisors, with or without molar caries, depending on the age of the child and stage of the disease. Typically, the mandibular incisors are unaffected. The cause is usually inappropriate use of a feeding bottle or at-will breast-feeding or a combination of both, with or without poor oral hygiene.
Type III (severe)	ECC was described as carious lesions affecting almost all teeth including the mandibular incisors. A combination of cariogenic food substances and poor oral hygiene is the cause of this type of ECC.

TABLE 2 | Classification based on the pattern of ECC presentation (27).

Type 1	Lesions associated with developmental defects (pit and fissure defects and hypoplasia)
Type 2	Smooth surface lesions (labial-lingual lesions, approximal molar lesions)
Type 3	Rampant caries—having caries in 14 out of 20 primary teeth, including at least one mandibular incisor

TABLE 3 | Classification of ECC and Severe Early Childhood Caries (S-ECC) (1, 69).

Age (months)	Early childhood caries	Severe early childhood caries
<12	1 or more dmfs surfaces	1 or more smooth dmfs surfaces.
12-23	1 or more dmfs surfaces	1 or more smooth dmfs surfaces.
24-35	1 or more dmfs surfaces	1 or more smooth dmfs surfaces.
36-47	1 or more dmfs surfaces	1 or more cavitated, filled, or missing (due to caries) smooth surfaces in primary maxillary anterior teeth or dmfs score >4 .
48-59	1 or more dmfs surfaces	1 or more cavitated, filled, or missing (due to caries) smooth surfaces in primary maxillary anterior teeth or dmfs score >5 .

Source- REVIEW article
Front. Pediatr., 18 July 2017, Sec. Children and Health
Volume 5 - 2017 Early Childhood Caries: Prevalence, Risk Factors, and Prevention

DISCLAIMER

THIS IS COPYRIGHTED CONTENT. Unauthorized use, including screenshots, copying, misuse, reuse, or resale of any content from this app, is strictly prohibited. Our app monitors and records all screenshots and recordings. Violators will face strict legal action.

DISCLAIMER
THIS IS COPYRIGHTED CONTENT. Unauthorized use, including screenshots, copying, misuse, reuse, or resale of any content from this app, is strictly prohibited. Our app monitors and records all screenshots and recordings. Violators will face strict legal action.

THIS IS COPYRIGHTED CONTENT. Unauthorized use, including screenshots, copying, misuse, reuse, or resale of any content from this app, is strictly prohibited. Our app monitors and records all screenshots and recordings. Violators will face strict legal action.

CHILDHOOD CARIES MANAGEMENT

- ECC** occurs as a result of interaction in between fermentable carbohydrate and, predominantly free sugars and cariogenic microorganisms on a susceptible tooth and host over a period of time.

over a period of time (13, 14). This interaction is moderated by a range of proximal and distal determinants, including fluoride exposure, oral health practices, other dietary factors and feeding behaviors, maternal and family characteristics, socioeconomic status, access to and availability of dental and public health services, and other structural, political, and cultural influences

- Quality of life and the general health of infants and children with ECC can quickly diminish as the disease progresses and the associated pain and discomfort increases.
- ECC is a key determinant of the adult dental caries experience, with lasting health impacts throughout life.

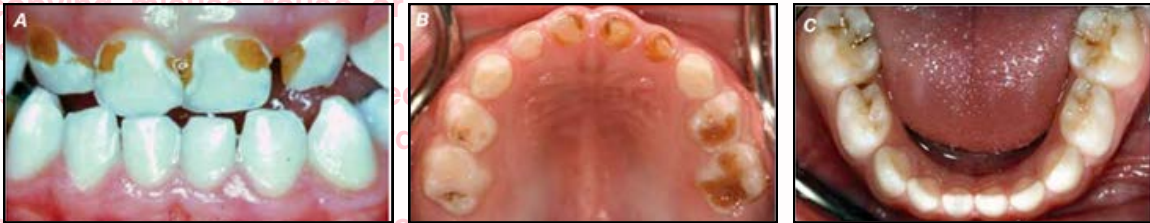

Image- a) ECC affecting primary maxillary incisor b) ECC involving both maxillary primary incisors and molars c) caries involving primary molars only

Relationship between ECC and breast-feeding practices:

- Studies have shown that there is no association between sustained breastfeeding to at least 1 years of age, nighttime breast feeding and early childhood caries by 2-3 years of age. Breast feeding practices were not associated with ECC.

In this cohort of preschoolers, neither the duration of breastfeeding nor nighttime breastfeeding practices at 1 y were associated with early childhood caries. However, the direction and size of the effect of the relationship between sustained breastfeeding and risk of ECC suggested a higher risk. To date,

- Breastfeeding should be promoted in line with global and national recommendations.
- To reduce the prevalence of ECC improved efforts are needed to limit foods high in free sugars.
- ECC is a significant problem for which main determinants are oral hygiene status, night feeding with sweetened beverages, bacterial infection and enamel defects. (Evans 2 article)
- This can be managed with professional use of efficacious primary caries prevention measures and secondary preventive non-invasive measures that can arrest non-cavitated caries lesions and lead to their remineralization.

DISCLAIMER

THIS IS COPYRIGHTED CONTENT. Unauthorized use, including screenshots, copying, misuse, reuse, or resale of any content from this app, is strictly prohibited. Our app monitors and records all screenshots and recordings. Violators will face strict legal action.

DISCLAIMER

THIS IS COPYRIGHTED CONTENT. Unauthorized use, including screenshots, copying, misuse, reuse, or resale of any content from this app, is strictly prohibited. Our app monitors and records all screenshots and recordings. Violators will face strict legal action.

THIS IS COPYRIGHTED CONTENT. Unauthorized use, including screenshots, copying, misuse, reuse, or resale of any content from this app, is strictly prohibited. Our app monitors and records all screenshots and recordings. Violators will face strict legal action.

DISCLAIMER

CHILDHOOD CARIES MANAGEMENT

Possible effects of ECC as mentioned across dental literature includes:

(Source- Rationale for Restoration of carious primary teeth article)

- Pain,
- Sepsis
- Space loss
- Disruption to quality of life
- Disruption of growth and development
- Possible disruption of intellectual development
- Higher incidence of hospitalization and emergency visits
- Increased treatment cost and time
- Greater risk of new carious lesion in both primary and permanent dentition.

Caries management system in children and adolescents

- Caries management system is a 10 step non invasive strategy to arrest remineralize early lesions and to enhance caries primary prevention.
- The governing principle for caries management is that it must include consideration of:
 - Patient at risk: The risk status of each patient is determined at the end of clinical assessment.
 - Status of each lesion
 - Patient management
 - Clinical management
 - Monitoring

Table 1. Ten-step summary of the Caries Management System

1	Diet assessment
2	Plaque assessment
3	Bitewing radiographic survey
4	Diagnosis and caries risk assessment
5	Preparation of oral care plan
6	Case presentation at which patient is informed about: <ul style="list-style-type: none"> Dental caries <ul style="list-style-type: none"> Arrest Reversal/Natural repair (Remineralization) Prevention Number and status of current lesions Role of dental practitioner in caries management Role of home care in caries prevention Current caries risk status Result of diet assessment and recommendations
7	Oral hygiene coaching
8	Clinical management <ul style="list-style-type: none"> Topical fluoride application (both professional and home care) Sealant or GIC application
9	Monitoring of plaque control and treatment outcomes at each visit
10	Recall programme tailored to caries risk status

DISCLAIMER

THIS IS COPYRIGHTED CONTENT. Unauthorized use, including screenshots, copying, misuse, reuse, or resale of any content from this app, is strictly prohibited. Our app monitors and records all screenshots and recordings. Violators will face strict legal action.

DISCLAIMER
THIS IS COPYRIGHTED CONTENT. Unauthorized use, including screenshots, copying, misuse, reuse, or resale of any content from this app, is strictly prohibited. Our app monitors and records all screenshots and recordings. Violators will face strict legal action.

DISCLAIMER

THIS IS COPYRIGHTED CONTENT. Unauthorized use, including screenshots, copying, misuse, reuse, or resale of any content from this app, is strictly prohibited. Our app monitors and records all screenshots and recordings. Violators will face strict legal action.

CHILDHOOD CARIES MANAGEMENT

Overall management involves:

A) Clinical examination:

- The teeth should be cleaned prior to examination, if necessary using a rubber cup.
- For inspection the teeth should be viewed when wet.
- Then, it should be air dried and viewed after 5 sections:
- ICDAS system is used for scoring the caries status for both primary and permanent teeth but especially useful in primary teeth:

The **ICDAS II** is more refined and precise version of ICDAS scoring.

Codes include from 0-6, Code (1-3) relate to increasingly progressive stages of enamel lesion and Code (4-6) relates to increasingly progressive stages of dentine lesion.

- **CODE 0- Sound Tooth Surface:** No evidence of caries, the tooth appears sound, with no caries-related discoloration or opacity after air drying.
- **CODE 1-First Visual Change in Enamel:** A white or brown opacity (non-cavitated lesion) appears on enamel surface or pits and fissures that can be detected only after drying the tooth surface (5 seconds with air)
- **CODE 2-Distinct Visual Change in enamel:** White or brown opacity visible without air drying (i.e. When wet)
- **CODE 3- Localized Enamel Breakdown (no visible dentin):** Represents a white or brown spot with enamel loss at surface level. There is Localized breakdown of enamel surface, creating a small cavity or rough area. Here the lesion has not extended to the dentin.
- **CODE 4-Underlying dark shadow from dentin (No cavitation):** A dark shadow (gray/brown) is visible through the enamel suggesting the caries has extended to the dentin. Surface may appear intact or minimally broken.
- **CODE 5- Distinct Cavity with Visible Dentin:** A cavity is clearly visible, with dentin exposed and accessible to visual inspection.
- **CODE 6- Extensive Distinct Cavity with Visible Dentin:** A large, extensive cavity (Frank cavitation) with visible dentin and significant structural loss of the tooth.

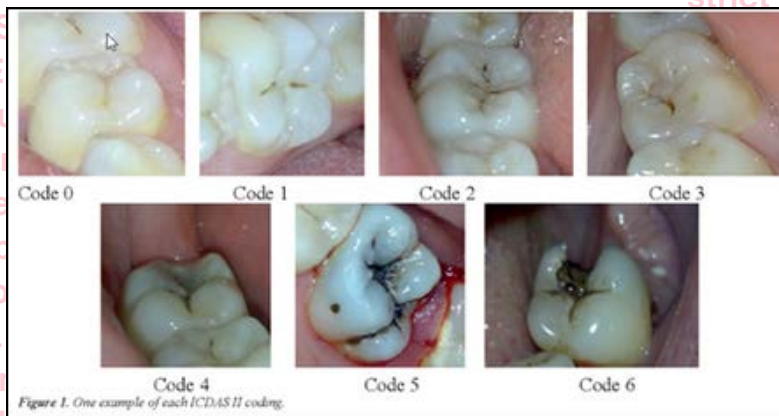


Figure 1. One example of each ICDAS II coding.

DISCLAIMER

THIS IS COPYRIGHTED CONTENT. Unauthorized use, including screenshots, copying, misuse, reuse, or resale of any content from this app, is strictly prohibited. Our app monitors and records all screenshots and recordings. Violators will face strict legal action.

THIS IS COPYRIGHTED CONTENT. Unauthorized use, including screenshots, copying, misuse, reuse, or resale of any content from this app, is strictly prohibited. Our app monitors and records all screenshots and recordings. Violators will face strict legal action.

THIS IS COPYRIGHTED CONTENT. Unauthorized use, including screenshots, copying, misuse, reuse, or resale of any content from this app, is strictly prohibited. Our app monitors and records all screenshots and recordings. Violators will face strict legal action.

DISCLAIMER

CHILDHOOD CARIES MANAGEMENT

Overall management involves:

A) Clinical examination:

When wet, surfaces may reveal... Normal appearance	White or brown spot lesions	A shadow from dentine plus/minus enamel loss	Cavitation with exposed dentine	Extensive cavitation
Code 0 or 1?	Code 2 or 3?	Code 4	Code 5	Code 6
But drying for 5 seconds exposes...				
Nothing else Code 0	Nothing else Code 2			
White or brown spot lesions Code 1	Enamel loss Code 3			

*Caries along restorations and sealants. Note that a non-carious defect along a restoration or sealant margin would be coded 0.

- To support the clinical examination, Radiographic examination can be done. Radiographs with bitewing technique are highly sensitive for detecting proximal caries that cannot be detected visually, it also helps in estimating the depth of lesion and monitoring disease progression.

B) Radiographic criteria for lesion progression include:

Criteria for Bitewing Radiolucency Scores	
C0	No radiolucency evident (not recorded)
C1	Radiolucency is evident within the <i>outer half</i> of enamel
C2	Radiolucency extends to the <i>inner half</i> of enamel and may reach the DEJ
C3	Radiolucency extends <i>just beyond</i> the DEJ
C4	Radiolucency is evident within the <i>outer third</i> of dentine
C5	Radiolucency extends to the <i>inner two thirds</i> of dentine and may reach the pulp

Outer 1/2 of Enamel	1
Inner 1/2 of Enamel	2
Just into Dentine	3
Outer 1/3 of Dentine	4
Inner 2/3 of Dentine	5

X-ray shadow	
C1	Outer 1/2 of enamel
C2	Inner 1/2 of enamel
C3	Just into dentine
C4	Outer 1/3 of dentine
C5	Inner 2/3 of dentine

THIS IS COPYRIGHTED CONTENT. Unauthorized use, including screenshots, copying, misuse, reuse, or resale of any content from this app, is strictly prohibited. Our app monitors and records all screenshots and recordings. Violators will face strict legal action.

DISCLAIMER

THIS IS COPYRIGHTED CONTENT. Unauthorized use, including screenshots, copying, misuse, reuse, or resale of any content from this app, is strictly prohibited. Our app monitors and records all screenshots and recordings. Violators will face strict legal action.

DISCLAIMER
THIS IS COPYRIGHTED CONTENT. Unauthorized use, including screenshots, copying, misuse, reuse, or resale of any content from this app, is strictly prohibited. Our app monitors and records all screenshots and recordings. Violators will face strict legal action.

copying, misuse, reuse, or resale of any content from this app, is strictly prohibited. Our app monitors and records all screenshots and recordings. Violators will face strict legal action.

THIS IS COPYRIGHTED CONTENT. Unauthorized use, including screenshots, copying, misuse, reuse, or resale of any content from this app, is strictly prohibited. Our app monitors and records all screenshots and recordings. Violators will face strict legal action.

DISCLAIMER

CHILDHOOD CARIES MANAGEMENT

Overall management involves:

C) Risk assessment criteria in Children:

- The assessment of caries risk of children and adolescent is solely on an analysis of the severity and extent of their presenting clinical and radiographic signs and not from epidemiologic type considerations of their histories of either favorable or unfavorable exposures to caries risk factor. (EVANS ARTICLE)
- Initially only two risk categories are assigned low risk and high risk.
- The specific criteria with reference to both ICDAS II scoring and radiographic codes in order to determine caries risk in young children who have primary dentition only or older children who have mixed or permanent dentition is described below:

Table 3. Criteria for caries risk for a child who has a primary dentition only

Caries risk	New patient	Recall patient
Low	<ul style="list-style-type: none"> dmfs = 0 ICDAS II codes < 2 No radiolucencies No sites with Plaque Index = 3 	<ul style="list-style-type: none"> < 1 new lesion per year* and no progression of existing lesions
At-risk	<ul style="list-style-type: none"> dmfs > 0 Demineralized enamel – ICDAS II codes > 1 C1 or greater radiolucencies 	<ul style="list-style-type: none"> 1 new lesion per year* and/or progression of existing lesions Any site with Plaque Index = 3 in cases where dmfs = 0
At-risk – High	<ul style="list-style-type: none"> Any site with Plaque Index = 3 in cases where dmfs = 0 Not assigned to new patient 	<ul style="list-style-type: none"> > 1 new lesion per year*

*...on approximal surfaces as diagnosed by bitewing scores C1 or greater or else on other surfaces diagnosed as ICDAS II code 2 or greater.

Table 4. Criteria for caries risk for a child who has a mixed or permanent dentition

Caries risk	New patient	Recall patient
Low	<ul style="list-style-type: none"> dmfs + DMFS = 0 ICDAS II codes < 2 No radiolucencies No sites with Plaque Index = 3 No hypomineralized or hypoplastic 6s or 7s 	<ul style="list-style-type: none"> < 1 new lesion per year* and no progression of existing lesions
At-risk	<ul style="list-style-type: none"> dmfs > 0 Demineralized enamel – ICDAS II codes > 1 or greater C1 or greater radiolucencies Any site with Plaque Index = 3 in cases where dmfs + DMFS = 0 dmfs + DMFT = 0 but 6s or 7s are hypomineralized or hypoplastic 	<ul style="list-style-type: none"> 1 new lesion per year* and/or progression of existing lesions Any site with Plaque Index = 3 in cases where dmfs + DMFS = 0 dmfs + DMFT = 0 but 6s or 7s are hypomineralized or hypoplastic
At-risk – High	<ul style="list-style-type: none"> Not assigned to new patient 	<ul style="list-style-type: none"> > 1 new lesion per year*

*...on approximal surfaces as diagnosed by bitewing codes C1 or greater or on other surfaces diagnosed as ICDAS II code 2 or greater.

Caries risk, as designated in Tables 3 and 4 is a classification based on clinical signs which is, nonetheless, an indirect but pragmatic measure of disease risk. More broadly, risk of disease is an epidemiologic question and entails an analysis of many contributing exposures and conditions.²⁷⁻²⁹ However, for a given diseased individual it is not possible to identify a specific combination of risk factors which may be presumed as causative and, therefore, the assignment of risk should not be dictated by measures of one or more specific factors, e.g., sugar exposure. On the other hand, it is important for patients to understand something about their risk status. Thus, exposure to

DISCLAIMER

THIS IS COPYRIGHTED CONTENT. Unauthorized use, including screenshots, copying, misuse, reuse, or resale of any content from this app, is strictly prohibited. Our app monitors and records all screenshots and recordings. Violators will face strict legal action.

DISCLAIMER

THIS IS COPYRIGHTED CONTENT. Unauthorized use, including screenshots, copying, misuse, reuse, or resale of any content from this app, is strictly prohibited. Our app monitors and records all screenshots and recordings. Violators will face strict legal action.

THIS IS COPYRIGHTED CONTENT. Unauthorized use, including screenshots, copying, misuse, reuse, or resale of any content from this app, is strictly prohibited. Our app monitors and records all screenshots and recordings. Violators will face strict legal action.

CHILDHOOD CARIES MANAGEMENT

Overall management involves:

D) Caries management:

- The risk- based caries management options are:
 - a. preventive,
 - b. preservative (non-invasive) and
 - c. operative (Invasive)
- Fundamentally, non cavitated lesions in primary and especially permanent teeth are managed by preservative non invasive means, only cavitated lesions whose base extend to dentine or those presumed to be cavitated in the absence of direct confirmation, are to be managed operatively.
- The thickness of enamel in deciduous teeth is less than on corresponding sites of permanent teeth and hence, is associated with increased risk of caries extension into dentine.
- At that stage risk of pulp exposure associated with operative intervention is elevated.
- This risk of pulp damage in deciduous teeth is minimized by following a less conservative approach than that proposed for permanent teeth.
- In the absence of direct confirmation of cavity extension to dentine in deciduous teeth, operative intervention is indicated on the basis of
 - a. Either, the combination of ICDAS II code 3 and an associated bitewing radiolucency coded greater than C3
 - b. Or, on an approximal surface which has an associated bitewing radiolucency coded greater than C3

THIS IS COPYRIGHTED CONTENT. Unauthorized use, including screenshots, copying, misuse, reuse, or resale of any content from this app, is strictly prohibited. Our app monitors and records all screenshots and recordings. Violators will face strict legal action.

DISCLAIMER

THIS IS COPYRIGHTED CONTENT. Unauthorized use, including screenshots, copying, misuse, reuse, or resale of any content from this app, is strictly prohibited. Our app monitors and records all screenshots and recordings. Violators will face strict legal action.

THIS IS COPYRIGHTED CONTENT. Unauthorized use, including screenshots, copying, misuse, reuse, or resale of any content from this app, is strictly prohibited. Our app monitors and records all screenshots and recordings. Violators will face strict legal action.

DISCLAIMER
THIS IS COPYRIGHTED CONTENT. Unauthorized use, including screenshots, copying, misuse, reuse, or resale of any content from this app, is strictly prohibited. Our app monitors and records all screenshots and recordings. Violators will face strict legal action.


DISCLAIMER

THIS IS COPYRIGHTED CONTENT. Unauthorized use, including screenshots, copying, misuse, reuse, or resale of any content from this app, is strictly prohibited. Our app monitors and records all screenshots and recordings. Violators will face strict legal action.

CHILDHOOD CARIES MANAGEMENT


Protocol for management of carious lesions

Table 5. Protocol for the management of lesions in primary teeth diagnosed clinically (ICDAS II) or from bitewing radiographic images in relation to children

Lesion code	Management
ICDAS II	
1-2	<ul style="list-style-type: none"> Apply fluoride varnish to arrest and remineralize active lesions and to maintain arrested lesions
3	<ul style="list-style-type: none"> Restore <i>only if</i> associated bitewing radiolucency extends deeper than C3 <i>otherwise</i> apply resin-based sealant or protect with GIC and review in 6 months (bitewings)
4-6	Restore
Bitewing	
C1	Do not restore – apply topical fluoride and monitor
C2	Do not restore – apply topical fluoride and monitor
C3	Do not restore <i>without further consideration</i>
C4	Restore now <i>only if</i> tooth is not due to exfoliate*
C5	Restore now <i>only if</i> tooth is not due to exfoliate*
	
Further consideration of C3 surfaces	<ul style="list-style-type: none"> Do not restore within 12 months of exfoliation* Restore if shadow is evident below marginal ridge Otherwise separate tooth to confirm cavitation and restore <i>only if</i> cavitated Implement preventive strategy to: <ul style="list-style-type: none"> – arrest active lesions – remineralize lesions – maintain arrested lesions – preserve first molars (take particular care)

*Clue – less than ½ of root remains.

Table 6. Protocol for the management of lesions in permanent teeth diagnosed clinically (ICDAS II) or from bitewing radiographic images in relation to children and adolescents

Lesion code	Management
ICDAS II	
1-2	<ul style="list-style-type: none"> Apply fluoride varnish to (1) arrest and remineralize active lesions and (2) maintain arrested lesions
3-4	<ul style="list-style-type: none"> Restore with UCSR* <i>only if</i> associated radiolucency extends deeper than C4 <i>otherwise</i> apply resin-based sealant and review in 6 months (bitewings)
5	Restore with UCSR*
6	Restore
Bitewing	
C1	Do not restore – apply topical fluoride and monitor
C2	Do not restore – apply topical fluoride and monitor
C3	Do not restore – apply topical fluoride and monitor
C4	Do not restore <i>without further consideration</i>
C5	Restore now
	
Further consideration of C4 surfaces	<ul style="list-style-type: none"> If possible, separate teeth and restore <i>only if</i> cavitated is revealed If <i>not possible to separate</i>, restore <i>only if</i> radiolucency extends <i>fully</i> ½ through dentine Otherwise, do not restore because it is more likely than not that the approximal surface: <ul style="list-style-type: none"> – is <i>not</i> cavitated – and lesion progression <i>could be</i> arrested or <i>has already</i> arrested Implement preventive strategy to: <ul style="list-style-type: none"> – arrest active lesions – remineralize lesions – maintain arrested lesions

*Ultra-conservative sealed restoration.

- **Non cavitated lesions** are managed by **home care measures** to control plaque principally by Brushing twice a day using fluoridated tooth paste (based on caries risk and age). This helps in arresting the lesion progression.

DISCLAIMER

THIS IS COPYRIGHTED CONTENT. Unauthorized use, including screenshots, copying, misuse, reuse, or resale of any content from this app, is strictly prohibited. Our app monitors and records all screenshots and recordings. Violators will face strict legal action.

THIS IS COPYRIGHTED CONTENT. Unauthorized use, including screenshots, copying, misuse, reuse, or resale of any content from this app, is strictly prohibited. Our app monitors and records all screenshots and recordings. Violators will face strict legal action.

THIS IS COPYRIGHTED CONTENT. Unauthorized use, including screenshots, copying, misuse, reuse, or resale of any content from this app, is strictly prohibited. Our app monitors and records all screenshots and recordings. Violators will face strict legal action.

CHILDHOOD CARIES MANAGEMENT

Protocol for management of carious lesions

Table 7. Recommended concentration of fluoride toothpaste according to age and risk of dental caries [NB1]	
Toothpaste for people not at elevated risk of dental caries	
child younger than 18 months	twice-daily brushing without toothpaste
child 18 months to younger than 6 years	500 to 550 ppm (0.5 to 0.55 mg/g) fluoride twice daily, pea-sized amount [NB2]
child 6 years to adolescent	1000 to 1500 ppm (1 to 1.5 mg/g) fluoride twice daily
adolescent or adult	1000 to 1500 ppm (1 to 1.5 mg/g) fluoride twice daily
Toothpaste for people at elevated risk of dental caries [NB3]	
child younger than 18 months	twice-daily brushing with toothpaste may be recommended [NB2]
child 18 months to younger than 6 years	1000 ppm (1 mg/g) fluoride twice daily [NB2] OR more frequent use of 500 to 550 ppm (0.5 to 0.55 mg/g) fluoride [NB2]
child 6 years to adolescent	more frequent use of 1000 to 1500 ppm (1 to 1.5 mg/g) fluoride [NB2]
adolescent or adult	5000 ppm (5 mg/g) fluoride twice daily OR more frequent use of 1000 to 1500 ppm (1 to 1.5 mg/g) fluoride

ppm = parts per million
 NB1: Spit out fluoride products to minimise ingestion; do not rinse the mouth after use to allow increased uptake of fluoride from the saliva.
 NB2: Advise parents of the risk of fluorosis and the need to supervise toothbrushing.
 NB3: Toothpaste use may be varied as needed, based on the dentist's clinical judgment.

Source - TG

- In addition, the combination of professionally applied fluoride varnish and home use of fluoridated tooth paste is necessary to ensure natural repair process of remineralization.

Table 7. Topical fluoride protocol for professional care of children and adolescents		
Caries risk	Fluoride varnish (Duraphat) 5% NaF (22 600 ppm) and GIC (Fuji 7)	Fluoride gel 1.23% NaF (12 300 ppm)
Low	<ul style="list-style-type: none"> Apply varnish to occlusal surfaces of all newly erupted primary and permanent molars If not drinking fluoridated water, apply varnish to occlusal surfaces of all molar teeth at each recall If not using fluoride toothpaste, apply varnish to occlusal surfaces of all molar teeth at each recall 	<p>Not to be used under the age of 10</p> <p>For age groups 10 and above:</p> <ul style="list-style-type: none"> At recall appointments to maintain lesion arrest
At-risk	<ul style="list-style-type: none"> Apply varnish or GIC (e.g., Fuji 7) to occlusal and approximal surfaces of newly erupted primary and permanent molars Apply varnish to surfaces with lesions (clinical and radiographic) and the respective apparently sound surfaces on homologous teeth at every treatment session, then Application as above at each review and recall appointment until patient becomes low risk. 	<p>Not to be used under the age of 10</p> <p>For age groups 10 and above:</p> <ul style="list-style-type: none"> At recall appointments instead of varnish (for whatever reason)

Table 8. Topical fluoride protocol for home care of children and adolescents				
Caries risk	Age	Toothbrushing with fluoride toothpaste	Fluoride rinse 0.05% NaF (neutral) (220 ppm) for one minute	Chlorhexidine 0.2% CHX
Low	Before 18 months	No fluoride toothpaste	Not to be used	Not applicable
	18 months to 5 yrs	Twice daily use 400 ppm toothpaste (smear/small pea size only)	Not to be used	
	18 months to 5 yrs	If not drinking fluoridated water, twice daily use 1000 ppm toothpaste (smear/small pea size only)	Not to be used	
At-risk	6-17 years	Twice daily use 1000 ppm toothpaste (pea size)	Not to be used	Not applicable
	Before 18 months	Twice daily use 400 ppm toothpaste (smear/small pea size only)	Not to be used	
	18 months to 5 yrs	Twice daily use 1000 ppm toothpaste (smear/small pea size only)	Not to be used	
	6-17 years	Twice daily use 1000 ppm toothpaste (pea size)	No use before age 10	
At-risk - high	10-17 years	If caries incidence is > 1 new lesions per year or see below,* then twice daily use 5000 ppm toothpaste (pea size)	Once daily at a separate time from toothbrushing	Once daily before bedtime
	10-17 years		Once daily at a separate time from toothbrushing	

*Patients with hyposalivation, or who have active lesions on anterior teeth, or who have active lesions on buccal surfaces of posterior teeth.

strict legal action.

DISCLAIMER

THIS IS COPYRIGHTED CONTENT. Unauthorized use, including screenshots, copying, misuse, reuse, or resale of any content from this app, is strictly prohibited. Our app monitors and records all screenshots and recordings. Violators will face strict legal action.

THIS IS COPYRIGHTED CONTENT. Unauthorized use, including screenshots, copying, misuse, reuse, or resale of any content from this app, is strictly prohibited. Our app monitors and records all screenshots and recordings. Violators will face strict legal action.

THIS IS COPYRIGHTED CONTENT. Unauthorized use, including screenshots, copying, misuse, reuse, or resale of any content from this app, is strictly prohibited. Our app monitors and records all screenshots and recordings. Violators will face strict legal action.

DISCLAIMER
 THIS IS COPYRIGHTED CONTENT. Unauthorized use, including screenshots, copying, misuse, reuse, or resale of any content from this app, is strictly prohibited. Our app monitors and records all screenshots and recordings. Violators will face strict legal action.

CHILDHOOD CARIES MANAGEMENT

Overall management involves:

E) Monitoring:

- Patients are recalled at regular intervals, determined on the basis of their caries risk status for monitoring caries activity and tooth brushing competence, and oral hygiene coaching and the reapplication of topical fluoride.

Caries risk	Monitoring lesion activity and patient behaviour	Bitewing survey
Low	<ul style="list-style-type: none"> 12 months after first visit Note: Oral hygiene review and coaching at each visit 3-monthly until lesion progression has arrested, i.e., evidence of (1) no extension of demineralization or (2) that GIC sealant remains intact Note: Oral hygiene review and coaching at each visit 	<ul style="list-style-type: none"> At first visit Then every 12 months At first visit
At-risk ... where evidence is: ICDAS II codes > 1	<ul style="list-style-type: none"> 3-monthly for (1) F varnish and (2) oral hygiene monitoring until lesion progression has arrested and patient is reclassified as low risk Note: Oral hygiene review and coaching at each visit 	<ul style="list-style-type: none"> Then every 6 months until patient is classified as low risk At first visit
At-risk ... where evidence is: Bitewing codes > C2 for primary teeth > C3 for permanent teeth	<ul style="list-style-type: none"> One week following first visit to review and coach tooth brushing competence Then one month later for same 	<ul style="list-style-type: none"> Then every 6 months until patient is classified as low risk
At-risk ... where <i>only</i> evidence is: Sites with Plaque Index = 3		

- When it is judged that the lesions are arrested, yearly radiographic review is recommended.
- For screening purposes, children and adolescents who are assessed as low risk should be scheduled for bitewing annually.
- (It may be suggested that 18 or 24 months is preferable interval for low-risk individual, but risk status can change and caries initiation and progression can be swift).
- Hence, it is better to be on the side of caution and screen annually.
- For professional care, for patients who remain at risk, the priority is to:
 - Impress on the need for regular attendance for professional application of fluoride varnish.
 - Use higher concentration fluoride toothpaste at home (As per age)
 - Use fissure sealants in an increased attempt to arrest and remineralize lesions, therefore, reduce the possibility of any operative intervention as much as possible.
- At each and every appointment, the plaque distribution and Overall plaque Index (PI) score is recorded.
- Ongoing oral hygiene coaching at each visit, review of serial findings and linkage of oral hygiene with other aspects of grooming increases the self-esteem and confidence in children and adolescents.
- Diet change also occurs as the children get older.
- Dental practitioner should be alert to sudden changes in caries risk and be prepared to discover the reason for such change.
- In such cases, it will be necessary to investigate between meal snacking patterns and caution against overexposure to cariogenic dietary items.

DISCLAIMER

THIS IS COPYRIGHTED CONTENT. Unauthorized use, including screenshots, copying, misuse, reuse, or resale of any content from this app, is strictly prohibited. Our app monitors and records all screenshots and recordings. Violators will face strict legal action.

DISCLAIMER
THIS IS COPYRIGHTED CONTENT. Unauthorized use, including screenshots, copying, misuse, reuse, or resale of any content from this app, is strictly prohibited. Our app monitors and records all screenshots and recordings. Violators will face strict legal action.

DEVELOPMENTAL DEFECTS ON TEETH

(Sources: Handbook of Pediatric Dentistry by Angus Cameron and Richard Widmer, Odell 3rd edition and 4th edition case 27)

Developmental defects of enamel

It can be inherited or acquired. It includes:

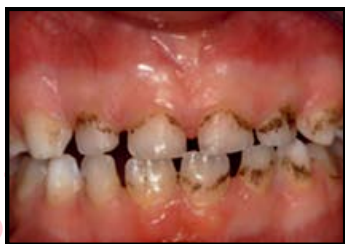Chronological disturbances:

- Any severe systemic event during the development of the teeth (i.e., from 3 months in-utero to 20 years of age) may result in some dental abnormality
- Different teeth will show defects at different levels of the crown depending on the stage of crown formation at the time the disturbance occurred.
- The resulting enamel may be reduced in quantity (hypoplasia) and/or quality (usually hypo mineralization).

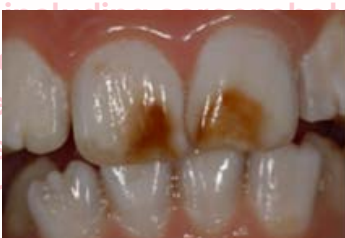*Hypoplasia- Pitting type of defects, Irregular surface due to deficiency of protein matrix

*Hypo mineralization- Deficiency in mineral content resulting in opaque or bright white spots on smooth surface.

- Defects can be
 - Localized:** A defect is described as localized when one or more teeth are affected, in an asymmetrical way, and
 - Generalized:** When there is a symmetrical disturbance on teeth of the same type on both left and right sides (and in both maxillary and mandibular teeth).
- More than 100 etiological agents have been reported to cause developmental defects of enamel.
- Developmental defects of enamel can be considered according to their clinical appearance:
 - Discoloration:** Tooth discoloration may be extrinsic or intrinsic in nature. Extrinsic staining is superficial and occurs after tooth eruption. Intrinsic discoloration may result from a developmental defect of enamel or internal staining of the tooth



1. Brown-black superficial staining from chromogenic bacteria



2. Brown discoloration due to incorporation of blood pigments into the enamel following trauma to the primary dentition

DISCLAIMER

THIS IS COPYRIGHTED CONTENT. Unauthorized use, including screenshots, copying, misuse, reuse, or resale of any content from this app, is strictly prohibited. Our app monitors and records all screenshots and recordings. Violators will face strict legal action.

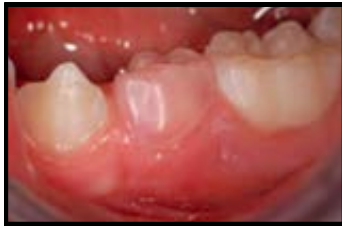DISCLAIMER

THIS IS COPYRIGHTED CONTENT. Unauthorized use, including screenshots, copying, misuse, reuse, or resale of any content from this app, is strictly prohibited. Our app monitors and records all screenshots and recordings. Violators will face strict legal action.

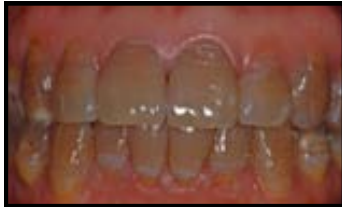THIS IS COPYRIGHTED CONTENT. Unauthorized use, including screenshots, copying, misuse, reuse, or resale of any content from this app, is strictly prohibited. Our app monitors and records all screenshots and recordings. Violators will face strict legal action.

DISCLAIMER

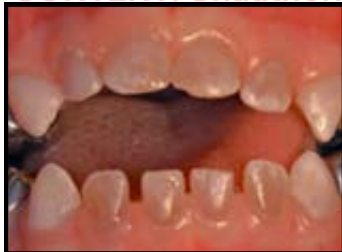DEVELOPMENTAL DEFECTS ON TEETH



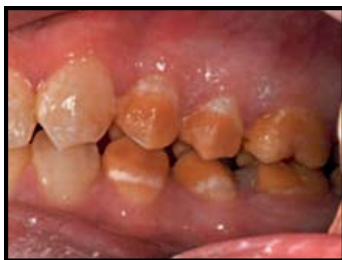3. Pink discoloration caused internal resorption of the tooth



4. Tetracycline staining in a child from South-east Asia

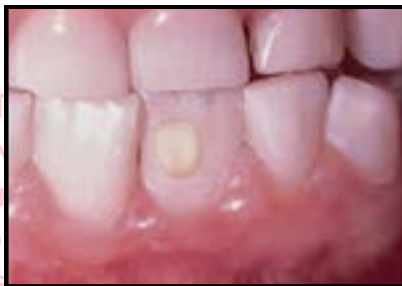

5. Blue-brown appearance of dentinogenesis imperfect

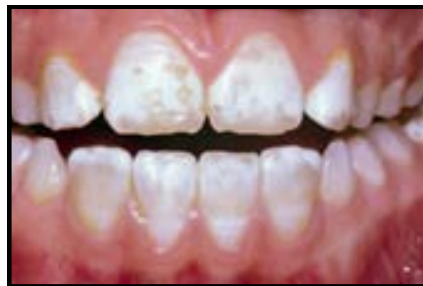

6. Chronological discoloration of an unknown etiology. There is a precise pattern to the hypo mineralization and appearance of the posterior teeth, however, the anterior teeth, in particular, the canines that are developing at the same age are unaffected.

- b. **Opacity:** Opacities result from a defect in the quality of the enamel, affecting the translucency of the tissue. Hypo mineralization results in a change in the porosity of the enamel, causing opacity. This may be located below the enamel surface, which remains intact.



a.



b.

Image a) Localized enamel opacity caused by the root apex of a traumatized primary incisor.

Image b) Fluorosis – uniform opacity-type defects throughout the crown. Some of the hypo mineralized enamel has been lost on the incisal edge revealing normal enamel underneath.

DISCLAIMER

THIS IS COPYRIGHTED CONTENT. Unauthorized use, including screenshots, copying, misuse, reuse, or resale of any content from this app, is strictly prohibited. Our app monitors and records all screenshots and recordings. Violators will face strict legal action.

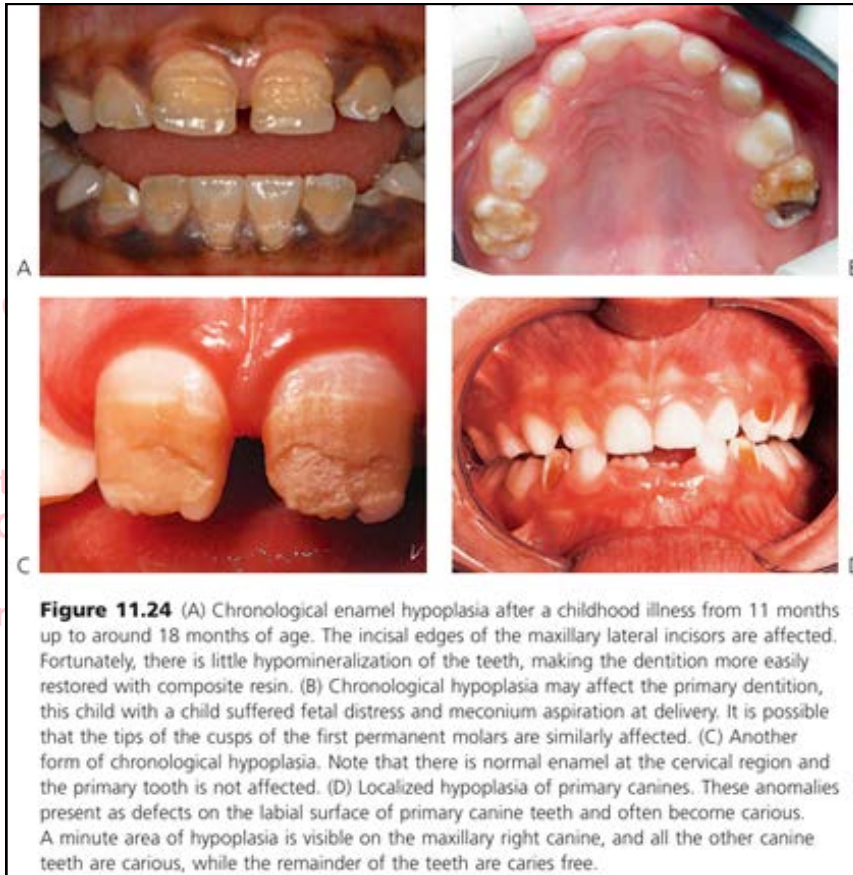
DISCLAIMER
THIS IS COPYRIGHTED CONTENT. Unauthorized use, including screenshots, copying, misuse, reuse, or resale of any content from this app, is strictly prohibited. Our app monitors and records all screenshots and recordings. Violators will face strict legal action.

THIS IS COPYRIGHTED CONTENT. Unauthorized use, including screenshots, copying, misuse, reuse, or resale of any content from this app, is strictly prohibited. Our app monitors and records all screenshots and recordings. Violators will face strict legal action.

DISCLAIMER

DEVELOPMENTAL DEFECTS ON TEETH

- c. **Hypoplasia:** A defect in quantity that causes an altered contour of the surface of the enamel. This is usually caused by initial failure of the deposition of enamel protein, but the same clinical effect could also result if there is a mineralization defect that leads to loss of enamel substance after eruption.



THIS IS COPYRIGHTED
CONTENT. Unauthorized use,
including screenshots,
copying, misuse, reuse, or
resale of any content from
this app, is strictly prohibited.
Our app monitors and records
all screenshots and
recordings. Violators will face
strict legal action.

DISCLAIMER

THIS IS COPYRIGHTED CONTENT. Unauthorized use, including screenshots, copying, misuse, reuse, or resale of any content from this app, is strictly prohibited. Our app monitors and records all screenshots and recordings. Violators will face strict legal action.

DISCLAIMER
THIS IS COPYRIGHTED CONTENT. Unauthorized use, including screenshots, copying, misuse, reuse, or resale of any content from this app, is strictly prohibited. Our app monitors and records all screenshots and recordings. Violators will face strict legal action.

THIS IS COPYRIGHTED
CONTENT. Unauthorized use,
including screenshots,
copying, misuse, reuse, or
resale of any content from
this app, is strictly prohibited.
Our app monitors and records
all screenshots and
recordings. Violators will face
strict legal action.

THIS IS COPYRIGHTED CONTENT. Unauthorized use, including screenshots, copying, misuse, reuse, or resale of any content from this app, is strictly prohibited. Our app monitors and records all screenshots and recordings. Violators will face strict legal action.

DISCLAIMER

DEVELOPMENTAL DEFECTS ON TEETH

Some common defects are:

A) Fluorosis:

- In mild forms, fluorosis is manifested as hypo mineralization of the enamel, leading to opacities.
- These can range from tiny white flecks to confluent opacities throughout the enamel, making the crown totally lacking in translucency.
- Hypoplasia occurs at higher concentrations of fluoride. When the tooth first erupts, the surface of even the most severely affected enamel may be intact, however, with wear, areas of enamel are lost and stains are taken up into the porosities.
- At 1 ppm of fluoride in public water supplies, up to 10% of the population will show very mild opacities attributable to fluorosis (this depends on individual water consumption)
- Severely affected cases may require micro abrasion or restoration with composite resin, either in a localized or a more generalized manner, or porcelain veneers.

Management of stains and opacities:

- Extrinsic stains can be removed with abrasives.
- Mild discoloration may be improved using peroxide-based bleaching agents.
- Intrinsic stains, if superficial, may be removed with micro-abrasion techniques

B) Molar-Incisor Hypomineralization:

- **Molar-incisor hypomineralization (MIH)** is a condition that presents as a **qualitative change in enamel** that, initially, is of normal thickness, ranging from localized opacity through opacity with discoloration and obvious poor quality to **post eruptive enamel breakdown**.
- The cervical enamel appears to be normal in most affect first permanent molars.
- One or more first permanent molars may be affected in a partially chronological but inconsistent manner together with (usually lesser) effects on one or more incisors
- Often affected teeth are extremely sensitive, and this is often an indicator to poor ability to gain complete anesthesia of the affected teeth.
- Use of low viscosity GIC sealants soon after eruption and also remineralizing agents such as CPP-ACP can help decrease sensitivity and reduce post-eruptive breakdown.
- Many possible etiological factors are suggested including familial tendency, childhood diseases, maternal illness especially in 3rd trimester. But Irrespective of the exact etiology of MIH, it is important to recognize that this condition represents a chronological disturbance in tooth formation between birth and 24 months of age.

DISCLAIMER

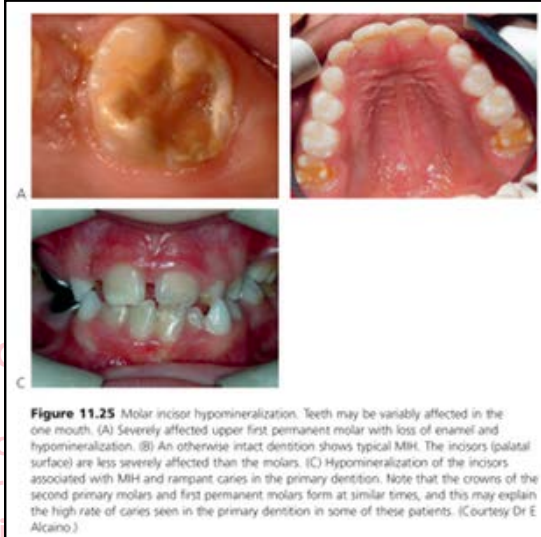THIS IS COPYRIGHTED CONTENT. Unauthorized use, including screenshots, copying, misuse, reuse, or resale of any content from this app, is strictly prohibited. Our app monitors and records all screenshots and recordings. Violators will face strict legal action.

DISCLAIMER
THIS IS COPYRIGHTED CONTENT. Unauthorized use, including screenshots, copying, misuse, reuse, or resale of any content from this app, is strictly prohibited. Our app monitors and records all screenshots and recordings. Violators will face strict legal action.

DEVELOPMENTAL DEFECTS ON TEETH

Some common defects are:

B) Molar-Incisor Hypomineralization:



Management of MIH

- The ideal restorative approach for these cases is yet to be determined.
- If intra-coronal restorations are planned composite resin should be used.
- Stainless steel crowns are an option for severely affected teeth, however it must be explained to both the child and parent that this is an intermediate phase of treatment and further restorative work should be done at maturity.
- Some research indicates that pre-treating the enamel with 5% sodium hypochlorite after etching increases bond-strengths significantly.

C) Amelogenesis Imperfecta

- Amelogenesis imperfecta is inherited defects of the enamel of both primary and permanent teeth.

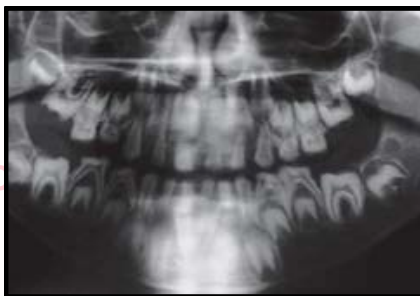

Fig: Panoramic radiograph showing absent or very thin enamel in this form of amelogenesis imperfecta.

- Numerous types of Amelogenesis imperfecta are present.
- It affects all teeth, though some forms are much milder in the deciduous dentition.

DISCLAIMER

THIS IS COPYRIGHTED CONTENT. Unauthorized use, including screenshots, copying, misuse, reuse, or resale of any content from this app, is strictly prohibited. Our app monitors and records all screenshots and recordings. Violators will face strict legal action.

THIS IS COPYRIGHTED CONTENT. Unauthorized use, including screenshots, copying, misuse, reuse, or resale of any content from this app, is strictly prohibited. Our app monitors and records all screenshots and recordings. Violators will face strict legal action.

DISCLAIMER
THIS IS COPYRIGHTED CONTENT. Unauthorized use, including screenshots, copying, misuse, reuse, or resale of any content from this app, is strictly prohibited. Our app monitors and records all screenshots and recordings. Violators will face strict legal action.

THIS IS COPYRIGHTED CONTENT. Unauthorized use, including screenshots, copying, misuse, reuse, or resale of any content from this app, is strictly prohibited. Our app monitors and records all screenshots and recordings. Violators will face strict legal action.

DISCLAIMER

DEVELOPMENTAL DEFECTS ON TEETH

Some common defects are:

C) Amelogenesis Imperfecta

- Color change varies and is secondary to either hypoplasia (thin hard translucent enamel through which dentine is visible), hypocalcification (chalky white opaque soft enamel) and hypo maturation (patchy distribution of white opacities).
- Affected areas may also take up extrinsic stain.
- Tooth shape may be normal and some types have a vertical banding, pitting or ridging pattern.
- Family history will be positive in many cases.
- Mild types are difficult to distinguish from fluorosis.
- It can present as markedly hypoplastic (thin enamel), or varying degrees of hypomineralization or both hypoplasia and hypomineralization seen together.

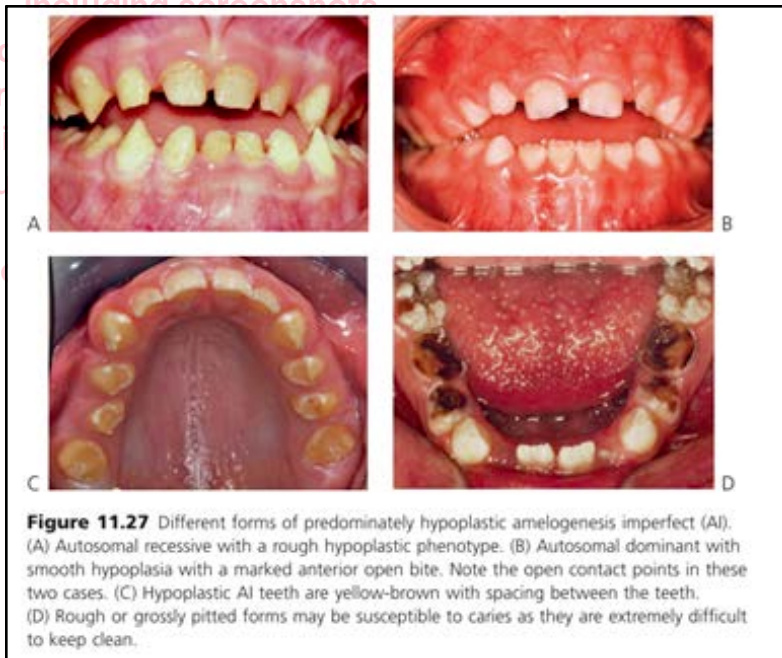

Fig: Predominantly hypoplastic Amelogenesis Imperfecta (AI)

- In X-linked amelogenesis imperfecta females exhibit vertical bands of altered enamel. There may be vertical grooves (because of hypoplasia) or vertical bands of enamel of altered color or lucency (because of hypomineralization) or a combination of the two.

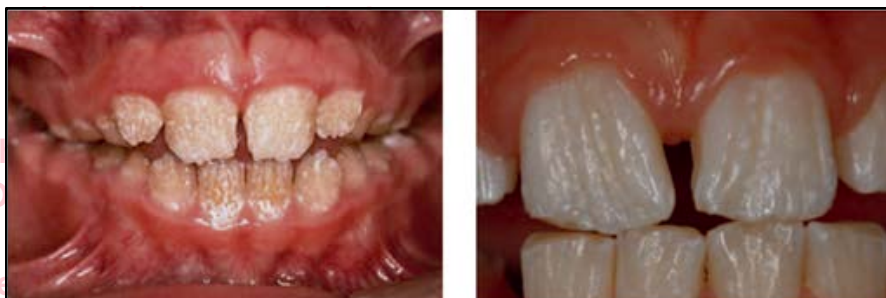

Image: Typical appearance of vertical hypoplastic grooves in females (X linked AI)

DISCLAIMER

THIS IS COPYRIGHTED CONTENT. Unauthorized use, including screenshots, copying, misuse, reuse, or resale of any content from this app, is strictly prohibited. Our app monitors and records all screenshots and recordings. Violators will face strict legal action.

THIS IS COPYRIGHTED CONTENT. Unauthorized use, including screenshots, copying, misuse, reuse, or resale of any content from this app, is strictly prohibited. Our app monitors and records all screenshots and recordings. Violators will face strict legal action.

DISCLAIMER
THIS IS COPYRIGHTED CONTENT. Unauthorized use, including screenshots, copying, misuse, reuse, or resale of any content from this app, is strictly prohibited. Our app monitors and records all screenshots and recordings. Violators will face strict legal action.

DEVELOPMENTAL DEFECTS ON TEETH

Some common defects are:

C) Amelogenesis Imperfecta

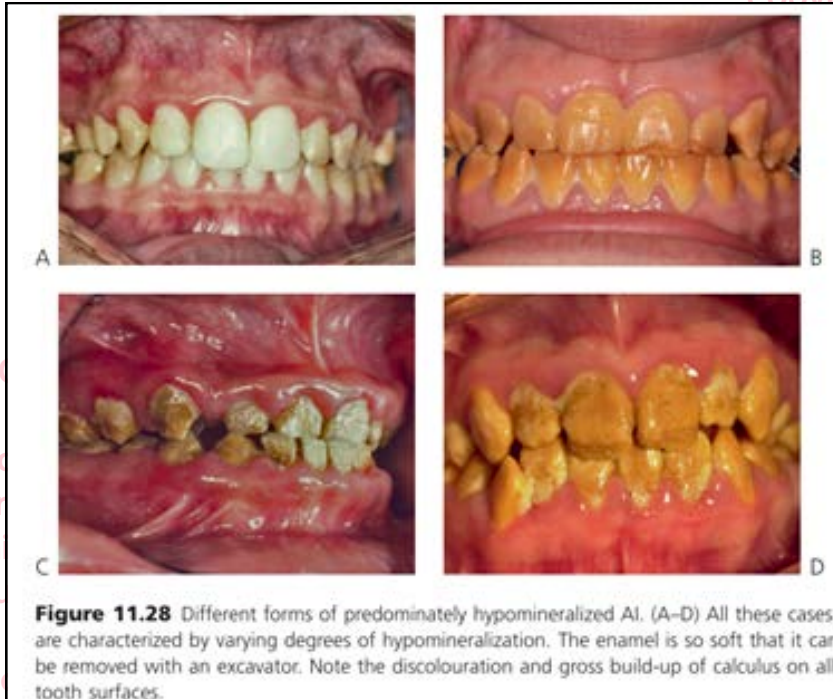

Fig: Predominantly hypomineralized amelogenesis imperfecta (AI)

Developmental defects of Dentine:

A) Dentinogenesis Imperfecta

- Dentinogenesis imperfecta is an inherited disorder of dentine, which may or may not be associated with osteogenesis imperfecta.
- The term 'hereditary opalescent dentine' is sometimes used for the isolated condition.
- All teeth appear even grey-brown color with altered translucency. The shape of the tooth crowns is normal but the roots are thin and taper sharply. There is gradual pulpal obliteration by dentine. There may be a family history and, in some cases, osteogenesis imperfecta is associated. Enamel fractures from the dentine and severe wear follow shortly after eruption. (Odell)
- Both osteogenesis imperfecta and dentinogenesis imperfecta are transmitted as autosomal dominant traits and are clinically indistinguishable dentally, although they have a different genetic basis.
- The possibility of osteogenesis imperfecta should be considered in children presenting with dentinogenesis imperfecta and investigated by measurement of bone density if necessary.
- The presence of blue sclera or a history of bone fractures should alert the clinician to osteogenesis imperfecta.

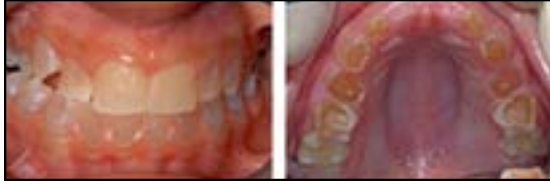DISCLAIMER

THIS IS COPYRIGHTED CONTENT. Unauthorized use, including screenshots, copying, misuse, reuse, or resale of any content from this app, is strictly prohibited. Our app monitors and records all screenshots and recordings. Violators will face strict legal action.

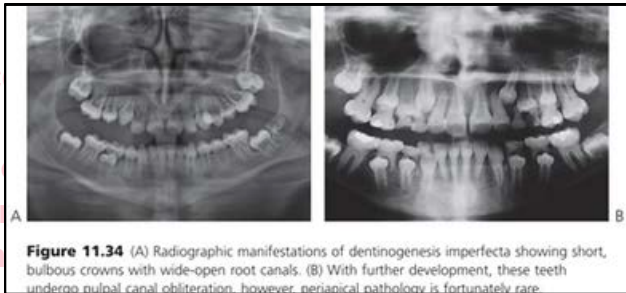
DEVELOPMENTAL DEFECTS ON TEETH

Dental manifestations of Dentinogenesis imperfecta:

1. Amber, grey to purple-bluish discoloration or opalescence.



2. Pulpal obliteration.



3. Relatively bulbous crowns.
 4. Short, narrow roots.
 5. Enamel may be lost after tooth eruption, exposing the soft dentine, which rapidly wears. This is probably due to inherent weakness in the dentine rather than because of an enamel defect or abnormality at the dentino-enamel junction.
 6. Mantle dentine appears normal.
 7. Circum-pulpal dentine has poorly formed dentine with abnormal direction of tubules. Small soft-tissue inclusions represent remnants of pulpal tissue
- All these dentine anomalies are autosomal dominant in inheritance.
 - It can be classified as: (Odell 4th edition Case 27)
 - a. **Dentinogenesis imperfecta Type I** – disorder of type I collagen: Bluish or brown in appearance, opalescence on transillumination
 - b. **Type II – hereditary opalescent dentine**: Opalescent primary teeth, Enamel chips away to expose DEJ. Once dentine exposed, teeth show brown discoloration.
 - c. **Type III – Brandywine isolate hereditary opalescent dentine**: Outwardly similar appearance to types I and II, Multiple pulpal exposures in primary dentition, Dentine production ceases after mantle dentine has formed

DISCLAIMER

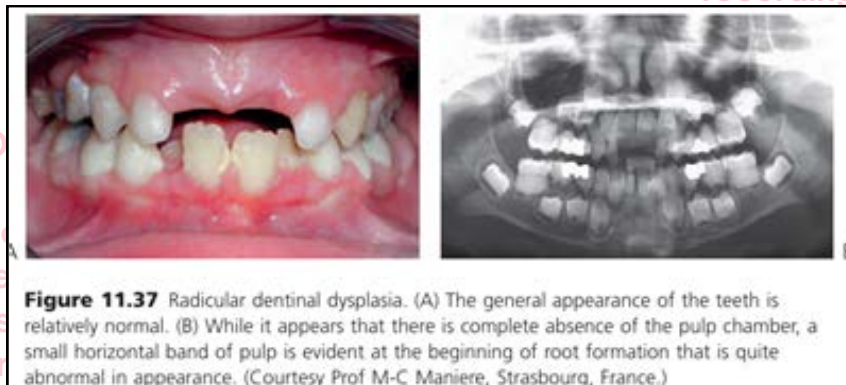
THIS IS COPYRIGHTED CONTENT. Unauthorized use, including screenshots, copying, misuse, reuse, or resale of any content from this app, is strictly prohibited. Our app monitors and records all screenshots and recordings. Violators will face strict legal action.

DISCLAIMER
THIS IS COPYRIGHTED CONTENT. Unauthorized use, including screenshots, copying, misuse, reuse, or resale of any content from this app, is strictly prohibited. Our app monitors and records all screenshots and recordings. Violators will face strict legal action.

DEVELOPMENTAL DEFECTS ON TEETH

B) Dentinal dysplasia – radicular dentinal dysplasia (Shields type I DD) (Cameron)

- It was originally described as rootless teeth, and it appears to be a distinct entity from dentinogenesis imperfecta.
- Both dentitions are equally affected.
- The teeth may be lost early due to periapical infection or spontaneous exfoliation caused by the short roots.
- Teeth with very short or absent roots but clinically normal crowns.



- Total or partial obliteration of radicular pulp prior to eruption but with demilune of coronal pulp shown on the radiographs of molar teeth.

C) Dentinal dysplasia – coronal dentinal dysplasia (Shields type II DD)

- This is a variant of dentinogenesis imperfecta rather than a distinct entity.
- The primary teeth have a typical amber discoloration and undergo tooth wear associated with loss of the enamel and the appearance of 'shell teeth' radiographically.
- Normal crown and root form.
- Varying degrees of pulp canal obliteration.
- Altered pulp morphology resembling a 'thistle-shaped' pulp chamber.
- Intra-pulpal calcifications (pulp stones).

THIS IS COPYRIGHTED
CONTENT. Unauthorized use,
including screenshots,
copying, misuse, reuse, or
resale of any content from
this app, is strictly prohibited.
Our app monitors and records
all screenshots and
recordings. Violators will face
strict legal action.

DISCLAIMER

THIS IS COPYRIGHTED CONTENT. Unauthorized use, including screenshots, copying, misuse, reuse, or resale of any content from this app, is strictly prohibited. Our app monitors and records all screenshots and recordings. Violators will face strict legal action.

DISCLAIMER
THIS IS COPYRIGHTED CONTENT. Unauthorized use, including screenshots, copying, misuse, reuse, or resale of any content from this app, is strictly prohibited. Our app monitors and records all screenshots and recordings. Violators will face strict legal action.

DISCLAIMER
THIS IS COPYRIGHTED CONTENT. Unauthorized use, including screenshots, copying, misuse, reuse, or resale of any content from this app, is strictly prohibited. Our app monitors and records all screenshots and recordings. Violators will face strict legal action.

VITAL PULP THERAPY

Sources: Articles on Conservative Pulp therapy in management of reversible and irreversible pulpitis, Clinical application of Silicate based cements, VPT in primary and permanent teeth, VPT in permanent teeth with diagnosis of irreversible pulpitis)

- Vital teeth with deep caries with actual or potential pulp involvement can be treated successfully with vital pulp therapy (VPT).
- The primary objective of pulp therapy is to maintain integrity and health of the teeth and the supporting tissues.
- The treatment objective is to maintain the vitality of the pulp of tooth affected by caries or traumatic injury.

caries or traumatic injury. Especially in young permanent teeth with immature roots, the pulp is integral to continue apexogenesis (root formation in immature apex) and root maturation. Long-term retention of a permanent tooth requires a root with a favourable crown/root ratio and dentinal walls that are thick enough to withstand normal function. Therefore, pulp preservation is a primary goal for treatment of the young permanent dentition. A tooth without a vital pulp, however, can remain clinically functional. The

- The use of rubber dam in managing teeth with deep carious lesions or pulpal exposures is mandatory.
- The soundness of the restoration has an important and considerable impact on the prognosis of the tooth.
- Younger teeth have better prognosis.
- The outcome of Pulp therapies is maintenance of pulpal health in 80-100% of the cases depending on treatment type and material used.
- When the pulp inflammation is irreversible Non- Vital Pulp therapies (Root canal treatment) are usually indicated.
- The indication of Vital pulp therapy is depended on the clinical diagnosis of pulpal health.
- Pulp can be diagnosed as one of the following:
 - a. Vital or normal pulp: Symptom free and normally responsive to thermal pulp sensibility testing)
 - b. Reversible pulpitis: Pulp that is capable of healing.
 - c. Symptomatic or Asymptomatic irreversible pulpitis: Severely inflamed pulp that is incapable of healing.
 - d. Necrotic infected pulp.
- Ideally, only teeth diagnosed with a normal pulp requiring pulp therapy or with reversible pulpitis should be treated with vital pulp procedures.
- Vital Pulp therapy can also be considered as a viable treatment alternative for mature teeth with carious exposure diagnosed with irreversible pulpitis as per recent studies and clinical trials. As per AAE position, the direct visualization of exposed pulp is an important diagnostic determination when considering pulpotomy as treatment option. (ADA article on VPT for irreversible pulpitis diagnosis 2023)

DISCLAIMER

THIS IS COPYRIGHTED CONTENT. Unauthorized use, including screenshots, copying, misuse, reuse, or resale of any content from this app, is strictly prohibited. Our app monitors and records all screenshots and recordings. Violators will face strict legal action.

DISCLAIMER

THIS IS COPYRIGHTED CONTENT. Unauthorized use, including screenshots, copying, misuse, reuse, or resale of any content from this app, is strictly prohibited. Our app monitors and records all screenshots and recordings. Violators will face strict legal action.

DISCLAIMER

THIS IS COPYRIGHTED CONTENT. Unauthorized use, including screenshots, copying, misuse, reuse, or resale of any content from this app, is strictly prohibited. Our app monitors and records all screenshots and recordings. Violators will face strict legal action.

VITAL PULP THERAPY

- Rationale for VPT as a treatment option in teeth with irreversible pulpitis:

Clinicians currently make an educated guess about the histological status of the pulp from preoperative clinical signs and symptoms, sensibility tests and radiographic examination. Moreover, intraoperative clinical examination from direct evaluation of the pulp under magnification is also important for the diagnosis of pulp status.

Based on histobacteriological findings of pulp status beneath a carious exposure in teeth with symptoms of irreversible pulpitis, current recommendations consider direct and indirect pulp capping unacceptable treatment in such teeth, because inflammation and bacterial invasion have extended into the pulp tissue.

- To come to a clinical diagnosis following should be considered.

- A comprehensive medical history.
- A review of past and present dental history and treatment, including current symptoms and chief complaint.
- A subjective evaluation of the area associated with the current symptoms/chief complaint by questioning the child and parent on the location, intensity, duration, stimulus, relief, and spontaneity.
- An objective extra-oral examination as well as examination of the intra-oral soft and hard tissues.
- Radiograph(s) to assess the involved tooth, furcation, peri-radicular region, and the surrounding bone. The presence in radiographs of loss of lamina dura, small periapical radiolucency and/or periapical sclerosis, are not necessarily indicative of an irreversible condition but can be useful to assist in identifying the offending tooth in a painful case.
- Clinical tests such as palpation, percussion, and mobility. In permanent teeth, thermal (CO₂) pulp tests are required and electric pulp tests in certain circumstances may be helpful. (2,3)

THIS IS COPYRIGHTED CONTENT. Unauthorized use, including screenshots, copying, misuse, reuse, or resale of any content from this app, is strictly prohibited. Our app monitors and records all screenshots and recordings. Violators will face strict legal action.

DISCLAIMER
THIS IS COPYRIGHTED CONTENT. Unauthorized use, including screenshots, copying, misuse, reuse, or resale of any content from this app, is strictly prohibited. Our app monitors and records all screenshots and recordings. Violators will face strict legal action.

THIS IS COPYRIGHTED CONTENT. Unauthorized use, including screenshots, copying, misuse, reuse, or resale of any content from this app, is strictly prohibited. Our app monitors and records all screenshots and recordings. Violators will face strict legal action.

DISCLAIMER

THIS IS COPYRIGHTED CONTENT. Unauthorized use, including screenshots, copying, misuse, reuse, or resale of any content from this app, is strictly prohibited. Our app monitors and records all screenshots and recordings. Violators will face strict legal action.

VITAL PULP THERAPY

Various Types of Vital Pulp Therapies:

A) Indirect pulp capping (IPC):

- It is a procedure performed in a tooth with deep carious lesion approximating the pulp but without signs and symptoms of pulp degeneration.
- The caries surrounding the pulp is left in place to avoid pulp exposure and is covered with biocompatible material.
- Complete caries removal is not needed for success if the restoration is well sealed. **(SEAL IS THE DEAL)**
- Partial caries removal is supported by current clinical and microbiological studies and systematic reviews.
- Clinical Procedure involves:

Clinical Procedure

- Take a periapical radiograph to confirm the appropriateness of treatment.
- Secure local anaesthesia.
- Isolate the tooth with rubber dam.
- Excavate caries as appropriate; a small area of infected dentine adjacent to a vital pulp could be left permanently (partial caries removal).
- Place a hard-setting calcium hydroxide liner on the remaining innermost layer dentine to stimulate the pulp to produce reparative dentine.
- Place a well-sealed restoration permanently.

- The restoration should be done under rubber dam as the use of rubber dam will minimize moisture and bacterial contamination of the operative field. Unsupported enamel rods should be removed. The small area of incomplete caries removal should be covered with cavity liner like hard setting calcium hydroxide to achieve reparative dentin formation.
- Self-Cure GIC should be used as a Base that should be followed by a final restoration of Clinicians Choice.

The above points are keys to a well-sealed restoration, which will deny bacteria substrate from further acid production and will assist arrest the carious lesion. The type of liner appears to be less important than the restoration seal (11).

Follow up:

Examinations are mandatory in 6 months for the evaluation of pulp sensitivity and the apical health status (9).

B) Direct Pulp Capping (DPC)

- DPC involves placement of medicament/material in direct contact with pulp tissue following non carious pulp exposure in asymptomatic teeth or reversible pulpitis.

DISCLAIMER

THIS IS COPYRIGHTED CONTENT. Unauthorized use, including screenshots, copying, misuse, reuse, or resale of any content from this app, is strictly prohibited. Our app monitors and records all screenshots and recordings. Violators will face strict legal action.

DISCLAIMER

THIS IS COPYRIGHTED CONTENT. Unauthorized use, including screenshots, copying, misuse, reuse, or resale of any content from this app, is strictly prohibited. Our app monitors and records all screenshots and recordings. Violators will face strict legal action.

THIS IS COPYRIGHTED CONTENT. Unauthorized use, including screenshots, copying, misuse, reuse, or resale of any content from this app, is strictly prohibited. Our app monitors and records all screenshots and recordings. Violators will face strict legal action.

DISCLAIMER

VITAL PULP THERAPY

Various Types of Vital Pulp Therapies:

C) Partial Pulpotomy

- **Pulpotomy** is the term used for partial or complete removal of diseased coronal pulp tissue.
- **If only** partial portion of the coronal pulp tissue is removed it is partial pulpotomy.
- **Only 2-3 mm** of coronal pulp is removed.
- After hemostasis is achieved a biomaterial is placed on the remaining vital pulp tissue.

D) Complete Pulpotomy

- It is the complete removal of full coronal pulp tissue to the orifice level is conducted it is known as complete pulpotomy.
- This preserves the vitality of radicular pulp as an alternative to RCT.
- Darker pulpal blood, calcifications in the coronal pulp, or pronounced bleeding on exposure is indicative of more severe inflammation.
- After hemostasis is achieved a biomaterial is placed on the remaining vital pulp tissue.

Non-Vital Pulp therapies:

- It includes pulpectomy and extraction and should be carried out when the pulpal condition is deemed irreversible.

THIS IS COPYRIGHTED
CONTENT. Unauthorized use,
including screenshots,
copying, misuse, reuse, or
resale of any content from
this app, is strictly prohibited.
Our app monitors and records
all screenshots and
recordings. Violators will face
strict legal action.

DISCLAIMER

THIS IS COPYRIGHTED CONTENT. Unauthorized use, including screenshots, copying, misuse, reuse, or resale of any content from this app, is strictly prohibited. Our app monitors and records all screenshots and recordings. Violators will face strict legal action.

THIS IS COPYRIGHTED
CONTENT. Unauthorized use,
including screenshots,
copying, misuse, reuse, or
resale of any content from
this app, is strictly prohibited.
Our app monitors and records
all screenshots and
recordings. Violators will face
strict legal action.

THIS IS COPYRIGHTED
CONTENT. Unauthorized use,
including screenshots,
copying, misuse, reuse, or
resale of any content from
this app, is strictly prohibited.
Our app monitors and records
all screenshots and
recordings. Violators will face
strict legal action.

DISCLAIMER
THIS IS COPYRIGHTED CONTENT. Unauthorized use, including screenshots, copying, misuse, reuse, or resale of any content from this app, is strictly prohibited. Our app monitors and records all screenshots and recordings. Violators will face strict legal action.

VITAL PULP THERAPY

Summary of Indications of various types of Pulp therapies depending on situations, signs and symptoms.

Type of Pulp therapy based on the Extent reason and dentition of pulpal involvement is summarized in the table below:
(For Pulpal Diagnosis of reversible Pulpitis)

	Primary Teeth	Immature Permanent Teeth	Mature Permanent Teeth
Indirect Pulp Capping (IPC)	Teeth with normal Pulp or symptoms of reversible pulpitis. (When any further removal of caries will lead to pulp exposure)	Teeth with normal Pulp or symptoms of reversible pulpitis. (When any further removal of caries will lead to pulp exposure)	Teeth with normal Pulp or symptoms of reversible pulpitis. (When any further removal of caries will lead to pulp exposure)
Direct Pulp Capping (DPC)	DPC is considered for Non carious exposures only. <ul style="list-style-type: none"> Pin point iatrogenic exposures during cavity preparations. 	All Pin point exposures- a) Pinpoint iatrogenic b) Pinpoint carious c) Pinpoint traumatic exposures.	DPC is considered for Non carious exposures only. <ul style="list-style-type: none"> Pin point iatrogenic exposures during cavity preparations
Pulpotomy a) Partial Pulpotomy Complete Pulpotomy.	1) Partial Pulpotomy: Traumatic or Carious Pin point/ Small exposures: 2) Cervical/ Complete Pulpotomy: Larger Exposures	1) Partial Pulpotomy: Larger traumatic/ carious exposures where bleeding is controlled within 5-10 minutes. 2) Complete Pulpotomy: Large exposures where bleeding is not controlled.	1) Partial Pulpotomy: Red and healthy pulp is exposed while removing the caries (carious exposure). And Traumatic exposures. 2) Complete Pulpotomy: Dark bleeding cervical pulp but healthy radicular pulp is exposed.

The AAE position statement on VPT states that haemostasis is usually achieved in 5–10 min when the exposed pulp wound is bathed with NaOCl either as direct passive irrigation or using a soaked cotton pellet.¹⁶ The concentration of NaOCl used is not a concern to the vitality of the exposed pulp.⁶⁵ The ESE position statement recommends using cotton pellets either soaked with NaOCl (0.5%–5%) or chlorhexidine (0.2%–2%).¹⁵ The critical clinical factor is not the concentration of the NaOCl as long as haemostasis is achieved. This might involve progressing from a partial to a full pulpotomy or a pulpectomy if bleeding is not controlled.

Image -2023 VPT article

DISCLAIMER

THIS IS COPYRIGHTED CONTENT. Unauthorized use, including screenshots, copying, misuse, reuse, or resale of any content from this app, is strictly prohibited. Our app monitors and records all screenshots and recordings. Violators will face strict legal action.

DISCLAIMER
THIS IS COPYRIGHTED CONTENT. Unauthorized use, including screenshots, copying, misuse, reuse, or resale of any content from this app, is strictly prohibited. Our app monitors and records all screenshots and recordings. Violators will face strict legal action.

THIS IS COPYRIGHTED CONTENT. Unauthorized use, including screenshots, copying, misuse, reuse, or resale of any content from this app, is strictly prohibited. Our app monitors and records all screenshots and recordings. Violators will face strict legal action.

DISCLAIMER

VITAL PULP THERAPY

THIS IS COPYRIGHTED

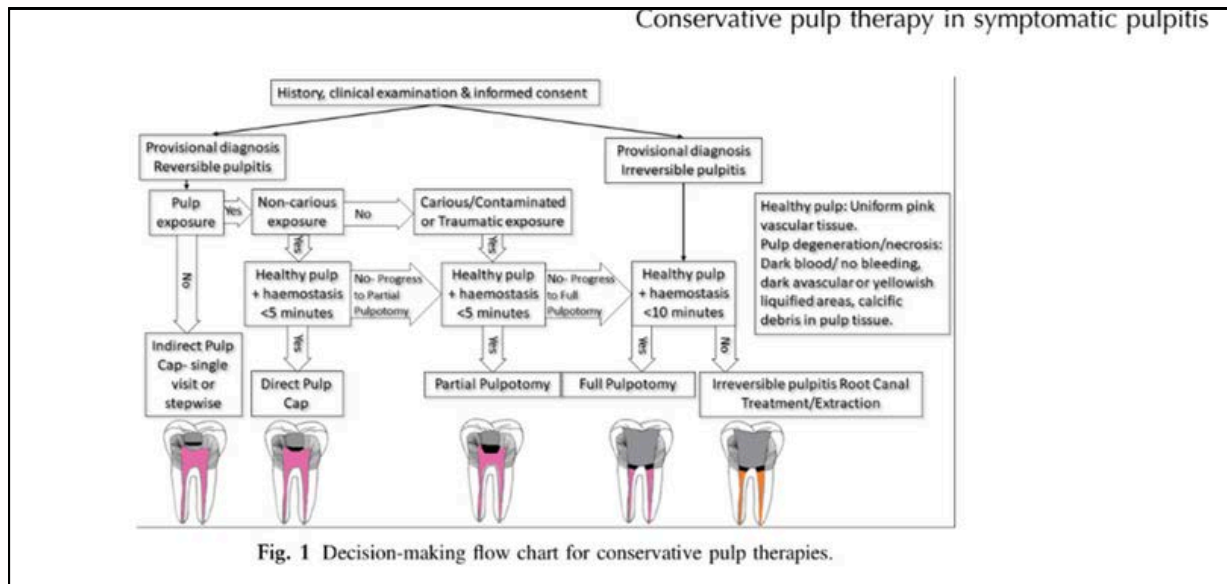
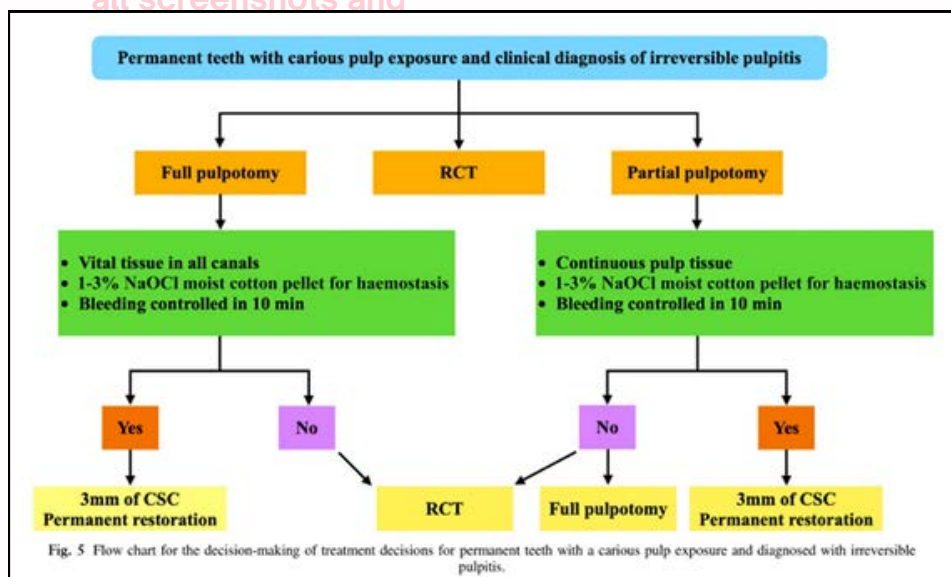


Image: ADA Conservative Pulp Therapy Article

Summary for decision making of treatment decisions for permanent teeth with carious pulp exposure and diagnosed with Irreversible Pulpitis.



THIS IS COPYRIGHTED
CONTENT. Unauthorized use,
including screenshots,
copying, misuse, reuse, or
resale of any content from
this app, is strictly prohibited.
Our app monitors and records
all screenshots and
recordings. Violators will face
strict legal action.

DISCLAIMER

THIS IS COPYRIGHTED CONTENT. Unauthorized use, including screenshots, copying, misuse, reuse, or resale of any content from this app, is strictly prohibited. Our app monitors and records all screenshots and recordings. Violators will face strict legal action.

DISCLAIMER
THIS IS COPYRIGHTED CONTENT. Unauthorized use, including screenshots, copying, misuse, reuse, or resale of any content from this app, is strictly prohibited. Our app monitors and records all screenshots and recordings. Violators will face strict legal action.

DISCLAIMER

THIS IS COPYRIGHTED CONTENT. Unauthorized use, including screenshots, copying, misuse, reuse, or resale of any content from this app, is strictly prohibited. Our app monitors and records all screenshots and recordings. Violators will face strict legal action.

VITAL PULP THERAPY

Type of Material Used and recommended in Pulp therapies:

- Historically, Calcium Hydroxide was the most common material used in VPT. However, with the introduction of Hydraulic Calcium silicate Cements (CSCs), they have become the gold standard for VPTs as recommended by AAE and ESE position statements, which is based on most recent clinical trials.
- Examples of these Hydraulic CSCs are:
 - i. MTA
 - ii. Bio dentine
 - iii. Total Fill
 - iv. Neo MTA
 - v. iRoot BP Plus/ Endo Sequence Putty
- a) **For Indirect Pulp capping:** Cavity liner like Hard setting Calcium Hydroxide followed by GIC base and final restoration. (Key is Well sealed restoration)
- b) **For direct Pulp Capping:** Calcium Silicate based cements. MTA, Calcium Hydroxide, Bio dentine can be used. In a recent study MTA had better success than calcium hydroxide for pulp capping.

especially with the advent of CSCs. A recent meta-analysis reported that MTA had significantly better success than $\text{Ca}(\text{OH})_2$ for direct pulp capping.⁹⁹ Accordingly, the success rate of $\text{Ca}(\text{OH})_2$ was 74% at 6 months and decreased to 59% at 2–3 years, while the success rate of MTA was 91% and decreased to 84% at the same time points.⁹⁹ The poor outcome with $\text{Ca}(\text{OH})_2$ might be associated with poor sealing ability and formation of tunnel defects in the newly formed calcific bridges.¹⁰⁰ In a previous study, MTA resulted in less pulpal inflammation and more predictable hard tissue barrier formation than $\text{Ca}(\text{OH})_2$ when used as a direct pulp capping agent.¹⁰¹ According to a recent study, CSC (iRoot BP Plus) was the

THIS IS COPYRIGHTED CONTENT. Unauthorized use, including screenshots, copying, misuse, reuse, or resale of any content from this app, is strictly prohibited. Our app monitors and records all screenshots and recordings. Violators will face strict legal action.

DISCLAIMER

THIS IS COPYRIGHTED CONTENT. Unauthorized use, including screenshots, copying, misuse, reuse, or resale of any content from this app, is strictly prohibited. Our app monitors and records all screenshots and recordings. Violators will face strict legal action.

DISCLAIMER
THIS IS COPYRIGHTED CONTENT. Unauthorized use, including screenshots, copying, misuse, reuse, or resale of any content from this app, is strictly prohibited. Our app monitors and records all screenshots and recordings. Violators will face strict legal action.

THIS IS COPYRIGHTED CONTENT. Unauthorized use, including screenshots, copying, misuse, reuse, or resale of any content from this app, is strictly prohibited. Our app monitors and records all screenshots and recordings. Violators will face strict legal action.

THIS IS COPYRIGHTED CONTENT. Unauthorized use, including screenshots, copying, misuse, reuse, or resale of any content from this app, is strictly prohibited. Our app monitors and records all screenshots and recordings. Violators will face strict legal action.

DISCLAIMER

VITAL PULP THERAPY

Type of Material Used and recommended in Pulp therapies:

c) For Pulpotomy:

- Calcium silicate cements are an effective material used in both partial and complete pulpotomy cases with teeth presenting with symptoms of reversible and irreversible pulpitis when pulpotomy is chosen as a treatment option based on many systematic reviews and trials.
- MTA has the highest success rate in all cases.
- Despite high success rate of Calcium silicate Cements (CSC) in VPT, tooth discoloration has been confirmed as an adverse effect especially with MTA.

effect, especially with MTA.¹²² Although most CSCs are associated with some degree of tooth discoloration, possibly due to blood contamination in VPT, bismuth oxide in MTA can exacerbate this situation.¹²³ However, recent literature indicates that newer CSCs are suitable alternatives for MTA.^{109,123}

- In VPT, it is of utmost importance to place the permanent restoration as soon as practically possible, preferably in the same session to avoid potential contamination.

Many clinical studies using a single-visit protocol in VPT with various CSCs including MTA, Biodentine, iRoot BP Plus and TotalFill have reported high success rates.^{109-111,113,115,123,125}

factors, which are released in response to caries.¹⁹ Furthermore, calcium silicate-based cements (CSCs) like MTA and Biodentine induce the release of these factors which modulate inflammation and drive the repair process by stimulating the recruitment of odontoblast-like cells with hard-tissue formation capacity.^{17,18,20} The

THIS IS COPYRIGHTED
CONTENT. Unauthorized use,
including screenshots,
copying, misuse, reuse, or
resale of any content from
this app, is strictly prohibited.
Our app monitors and records
all screenshots and
recordings. Violators will face
strict legal action.

DISCLAIMER

THIS IS COPYRIGHTED CONTENT. Unauthorized use, including screenshots, copying, misuse, reuse, or resale of any content from this app, is strictly prohibited. Our app monitors and records all screenshots and recordings. Violators will face strict legal action.

DISCLAIMER
THIS IS COPYRIGHTED CONTENT. Unauthorized use, including screenshots, copying, misuse, reuse, or resale of any content from this app, is strictly prohibited. Our app monitors and records all screenshots and recordings. Violators will face strict legal action.

VITAL PULP THERAPY

Various Examples of Vital Pulp therapies with X rays and Pictures in cases of diagnosis with irreversible Pulpitis:

1) Partial Pulpotomy

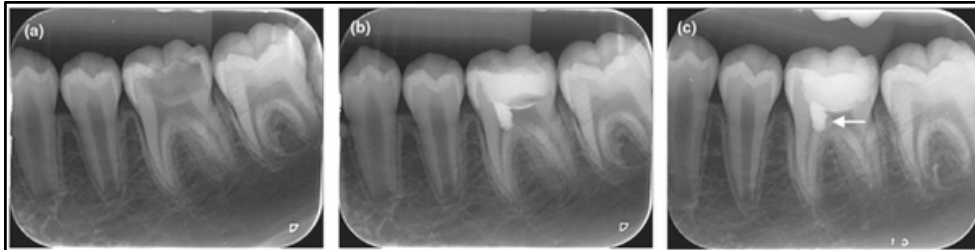


Fig. 1 Left mandibular first molar (#36) had caries close to the pulp with a poor occlusal filling, in a 11-year-old girl. (a) A PA preoperative radiograph. (b) Immediate postoperative radiograph after partial pulpotomy. (c) PA radiograph at 6-month follow-up showing the dentine bridge formed on the distal side of iRoot BP Plus (arrow).

2) Full Pulpotomy

Example 1:

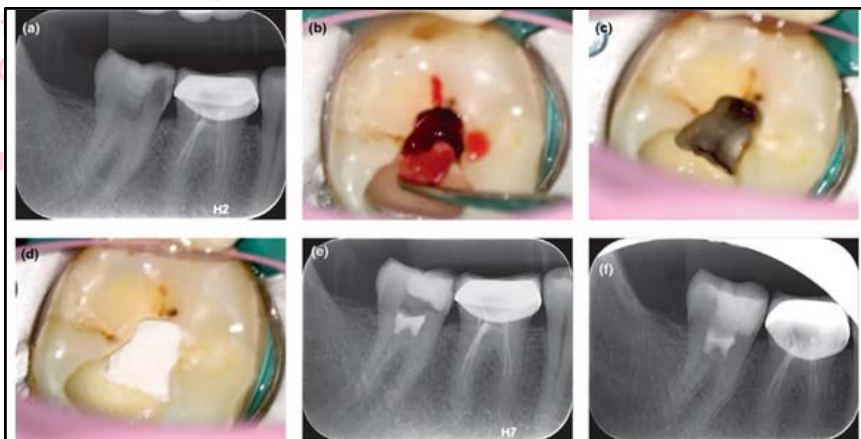


Fig. 2 Right mandibular second molar (#47) had mesial caries into the pulp, in a 32-year-old man. (a) A preoperative PA radiograph. (b) A clinical photograph showing the pulp wound. (c) A clinical photograph showing haemostasis and bleeding control during the pulpotomy. (d) A clinical photograph showing capping of wound with iRoot BP Plus after full pulpotomy. (e) Immediate postoperative radiograph. (f) A PA radiograph at a 12-month follow-up. The tooth had been permanently restored.

Example 2:

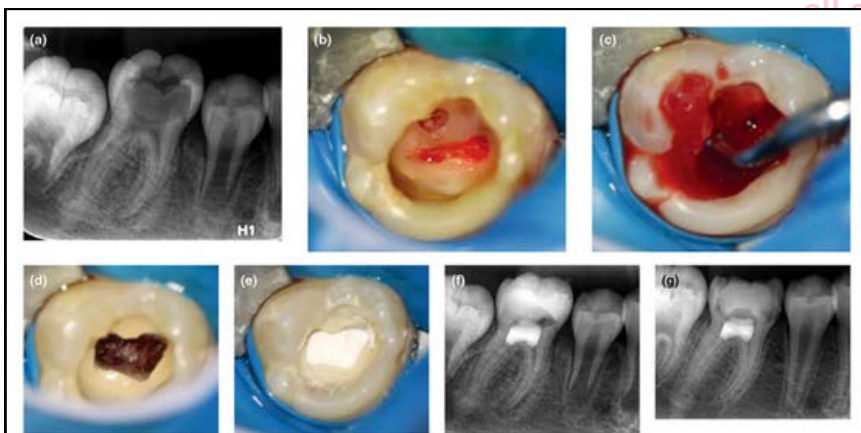


Fig. 3 Right first mandibular molar tooth (#46) had deep and large occlusal caries into the pulp, in a 11-year-old girl. (a) A preoperative PA radiograph showing periapical lesion (PAI score=3). (b) A clinical photograph showing the initial pulp exposure after caries removal. (c) A clinical photograph of pulp bleeding. (d) A clinical photograph when haemostasis was obtained. (e) A clinical photograph showing capping of wound with iRoot BP Plus. (f) Immediate postoperative radiograph showing a full pulpotomy. (g) A PA radiograph at a 20-month follow-up. The patient was referred for a new restoration due to recurrent caries.

DISCLAIMER

THIS IS COPYRIGHTED CONTENT. Unauthorized use, including screenshots, copying, misuse, reuse, or resale of any content from this app, is strictly prohibited. Our app monitors and records all screenshots and recordings. Violators will face strict legal action.

DISCLAIMER
THIS IS COPYRIGHTED CONTENT. Unauthorized use, including screenshots, copying, misuse, reuse, or resale of any content from this app, is strictly prohibited. Our app monitors and records all screenshots and recordings. Violators will face strict legal action.

THIS IS COPYRIGHTED CONTENT. Unauthorized use, including screenshots, copying, misuse, reuse, or resale of any content from this app, is strictly prohibited. Our app monitors and records all screenshots and recordings. Violators will face strict legal action.

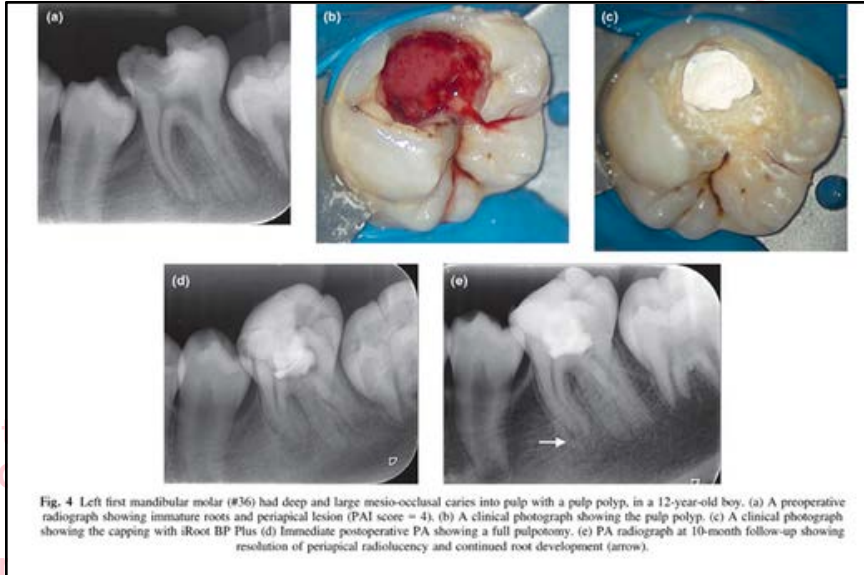
DISCLAIMER

VITAL PULP THERAPY

Various Examples of Vital Pulp therapies with X rays and Pictures in cases of diagnosis with irreversible Pulpitis:

2) Full Pulpotomy

Example 3:



strict legal action.

THIS IS COPYRIGHTED CONTENT. Unauthorized use, including screenshots, copying, misuse, reuse, or resale of any content from this app, is strictly prohibited. Our app monitors and records all screenshots and recordings. Violators will face strict legal action.

DISCLAIMER

THIS IS COPYRIGHTED CONTENT. Unauthorized use, including screenshots, copying, misuse, reuse, or resale of any content from this app, is strictly prohibited. Our app monitors and records all screenshots and recordings. Violators will face strict legal action.

THIS IS COPYRIGHTED CONTENT. Unauthorized use, including screenshots, copying, misuse, reuse, or resale of any content from this app, is strictly prohibited. Our app monitors and records all screenshots and recordings. Violators will face strict legal action.

THIS IS COPYRIGHTED CONTENT. Unauthorized use, including screenshots, copying, misuse, reuse, or resale of any content from this app, is strictly prohibited. Our app monitors and records all screenshots and recordings. Violators will face strict legal action.

DISCLAIMER
THIS IS COPYRIGHTED CONTENT. Unauthorized use, including screenshots, copying, misuse, reuse, or resale of any content from this app, is strictly prohibited. Our app monitors and records all screenshots and recordings. Violators will face strict legal action.