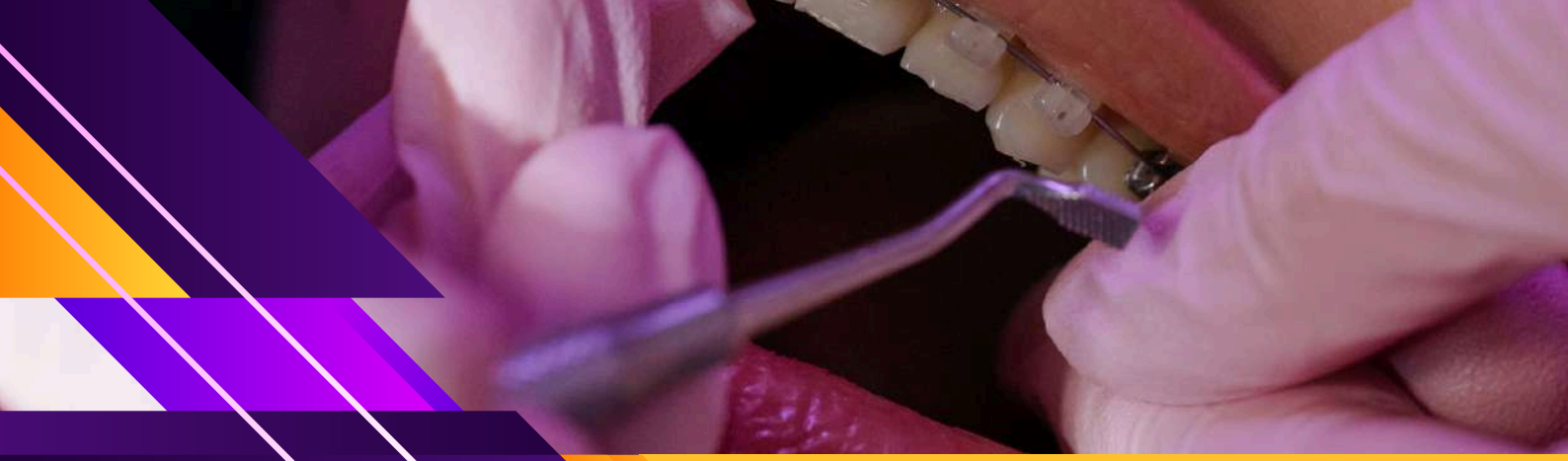

WINSPERT

WINSPERT

P.O.W.E.R

PREPARATION OF ADC WITH WINSPERT EXPERT REVIEW

NOTES

By Dr. Jigyasa Sharma

Dear Students,

We'd like to remind you about the importance of respecting the integrity of the resources provided in our app.

Please be aware that **WINSPERT POWERNOTES ARE COPYRIGHTED CONTENT. Unauthorized use, including screenshots, copying, misuse, reuse, or resale of any content from this app, is strictly prohibited.**

Our app monitors and records all screenshots and recordings. Violators will face strict legal action.

We're committed to providing you with the best tools for your success, and we appreciate your cooperation in maintaining a fair and secure learning environment.

Thank you for your understanding and continued dedication.

Best regards,
WINSPERT TEAM

MMF VARIATIONS

DISCLAIMER
THIS IS COPYRIGHTED CONTENT. Unauthorized use, including screenshots, copying, misuse, reuse, or resale of any content from this app, is strictly prohibited. Our app monitors and records all screenshots and recordings. Violators will face strict legal action.

SBQ 1

GIRL WITH RECESSION 31, ONLY 41 IN CROSSBITE (OLD CASE) MMF

I. Which splints to use?

A. Soft occlusal splint
B. Hard occlusal splint
C. Flexisplint
D. Mandibular advancement retraction splint

II. Question said non-orthodontic Immediate treatment to stop further \ recession. What will be the first thing you will do for her?

A. Fluoride varnish and occlusal splint
B. Fluoride varnish and fluoride toothpaste
C. Reduction of 41
D. Chlorhexidine mouthwash and oral hygiene instructions
E. Composite and fluoride

P.O.W.E.R NOTES SBQ 1

I. Soft splint is linked increased parafunctional habits. It can trigger parafunctional habits. Therefore, options (A) and (C) are ruled out. Mandibular advancement splint is used in sleep apnoea.

II. When cross bite is involving only 1 or 2 teeth / when supra eruption can only be seen in 1 or 2 teeth; management can be done by the reduction of the incisal edge/ by doing enameloplasty.
When the cross bite is involving the entire segment, you cannot do the reduction of the entire segment. It needs to be corrected with orthodontic Rx. Cross bite can hinder the growth of maxilla. It should be immediately addressed in a growing child.

DISCLAIMER
THIS IS COPYRIGHTED CONTENT. Unauthorized use, including screenshots, copying, misuse, reuse, or resale of any content from this app, is strictly prohibited. Our app monitors and records all screenshots and recordings. Violators will face strict legal action.

DISCLAIMER
THIS IS COPYRIGHTED CONTENT. Unauthorized use, including screenshots, copying, misuse, reuse, or resale of any content from this app, is strictly prohibited. Our app monitors and records all screenshots and recordings. Violators will face strict legal action.

DISCLAIMER
THIS IS COPYRIGHTED CONTENT. Unauthorized use, including screenshots, copying, misuse, reuse, or resale of any content from this app, is strictly prohibited. Our app monitors and records all screenshots and recordings. Violators will face strict legal action.

WINSPERT

MMF VARIATIONS

SBQ 2

A 8Y YOUNG GIRL AND PHOTO IS GIVEN WHICH SHOWS ANTERIOR TEETH WITH DEEP BITE OCCLUSION. DENTAL CHARTING WAS GIVEN(IT WAS CORRECT) -- ERUPTED 22&23 UNERUPTED 12 (11YEAR OLD GIRL)
MMF 23 ERUPTED BEFORE 12,
SAME QUESTIONS JUST THIS QUESTION EXTRA.
IN MMF WE NOTICE THAT 12 WAS CONGENITALLY MISSING BUT IN MARCH 22 EXAM THEY GAVE AN IOPA WHICH SHOWED THE PRESENCE OF 12 AS IMPACTED TOOTH.
PATIENT WITH INVERTED MESIODENS, IOPA GIVEN. IT HAD DEEP BITE. (12 NOT ERUPTED)

I. What do you see in between both the incisors?

A. Taurodontism
B. Inverted mesiodens
C. Transposition of 13
D. Dilaceration

II. What's the main concern according to the chart:

A. 23 erupted before 12
B. 22 erupted before 12
C. Nothing abnormal
D. Presence Of All Second Primary Molars(75,85,55,45) at the age of 10

III. Apart from the charting, what's obvious finding from pt picture:

A. Deep bite
B. Gingivitis
C. Dental caries

IV. Treatment of patient condition, Immediate intervention what treatment you prefer ??

A. Bite plane to allow eruption of molars and intrusion of incisors
B. Removable appliance to arrange teeth and it can allow other correction
C. Fixed ortho treatment during growth spurts period

DISCLAIMER
THIS IS COPYRIGHTED CONTENT. Unauthorized use, including screenshots, copying, misuse, reuse, or resale of any content from this app, is strictly prohibited. Our app monitors and records all screenshots and recordings. Violators will face strict legal action.

DISCLAIMER
THIS IS COPYRIGHTED CONTENT. Unauthorized use, including screenshots, copying, misuse, reuse, or resale of any content from this app, is strictly prohibited. Our app monitors and records all screenshots and recordings. Violators will face strict legal action.

DISCLAIMER
THIS IS COPYRIGHTED CONTENT. Unauthorized use, including screenshots, copying, misuse, reuse, or resale of any content from this app, is strictly prohibited. Our app monitors and records all screenshots and recordings. Violators will face strict legal action.

WINSPERT

MMF VARIATIONS

THIS IS COPYRIGHTED CONTENT. Unauthorized use, including screenshots, copying, misuse, reuse, or resale of any content from this app, is strictly prohibited. Our app monitors and records all screenshots and recordings. Violators will face strict legal action.

SBQ 2

V. OPG and Intraoral radiograph given. Which teeth are missing in the radiograph?

A. All wisdom teeth
B. All first premolar
C. All first molars

P.O.W.E.R NOTES SBQ 2

I. A mesiodense is a type of supernumerary tooth that occurs in the middle of the upper front teeth (the maxillary incisors). It's an extra tooth that usually appears between the two central incisors. These extra teeth can sometimes cause alignment issues or be associated with other dental problems, so they often need to be monitored or removed by a dentist if they interfere with normal tooth development or function

II. At the age of 8yr or 11yrs it's very soon for a maxillary canine to be erupted.

III. Patient has extreme deep bite which is natural in a mixed dentition period. When the posteriors erupt, deep bite is normally getting self-corrected.

IV. Deep bite should not be corrected during mixed dentition period. You must wait for it get self-corrected. If the deep bite still persists even after the mixed dentition period, then can proceed ahead with the fixed orthodontic Rx in the permanent dentition. High chances of relapses are seen with the removable appliances.

V. Wisdom teeth don't get start to even calcify at the age of 8-11yrs, so, they are missing in the OPG.

DISCLAIMER
THIS IS COPYRIGHTED CONTENT. Unauthorized use, including screenshots, copying, misuse, reuse, or resale of any content from this app, is strictly prohibited. Our app monitors and records all screenshots and recordings. Violators will face strict legal action.

DISCLAIMER
THIS IS COPYRIGHTED CONTENT. Unauthorized use, including screenshots, copying, misuse, reuse, or resale of any content from this app, is strictly prohibited. Our app monitors and records all screenshots and recordings. Violators will face strict legal action.

DISCLAIMER
THIS IS COPYRIGHTED CONTENT. Unauthorized use, including screenshots, copying, misuse, reuse, or resale of any content from this app, is strictly prohibited. Our app monitors and records all screenshots and recordings. Violators will face strict legal action.

MMF VARIATIONS

SBQ 3

YOU OBSERVED THAT IT TOOK 60 SECS FOR HIS MINOR SALIVARY GLANDS TO FORM A FEW SALIVARY DROPLETS AND WHAT WILL BE YOUR NEXT INVESTIGATION?

A. Stimulated salivary flow (5ml/5min)
B. Low buffering capacity of saliva
C. Saliva pH of 6.8 and above
D. High buffering capacity
E. Streptococcus and lactobacillus count

P.O.W.E.R NOTES SBQ 3

STEP 1: Resting flow rate / Unstimulated salivary rate

Greater than 60 seconds:	Resting flow rate	Low
Between 30-60 seconds:	Resting flow rate	Normal
Less than 30 seconds:	Resting flow rate	High

STEP 2: Salivary consistency

Step 2 - Salivary Consistency:
Visually assess the resting salivary consistency in the oral cavity

Sticky frothy saliva:	Residues
Frothy bubbly saliva:	Increased Viscosity
Watery clear saliva:	Normal Viscosity

STEP 3: Testing PH – resting saliva

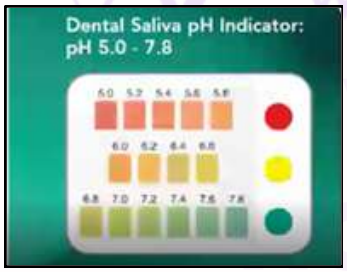

STEP 4: Testing quantity – stimulated saliva

Volume of Saliva/Value

<3.5mL	3.5- 5.0mL	>5.0mL
Very Low	Low	Normal

STEP 5: testing PH – stimulated saliva

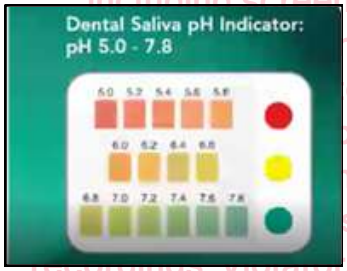

STEP 6: testing buffering - stimulated saliva

Buffering Ability

0 - 5	6 - 9	10 - 12
Very Low	Low	Normal

THIS IS COPYRIGHTED CONTENT. Unauthorized use, including screenshots, copying, misuse, reuse, or resale of any content from this app, is strictly prohibited. Our app monitors and records all screenshots and recordings. Violators will face strict legal action.

DISCLAIMER
THIS IS COPYRIGHTED CONTENT. Unauthorized use, including screenshots, copying, misuse, reuse, or resale of any content from this app, is strictly prohibited. Our app monitors and records all screenshots and recordings. Violators will face strict legal action.

DISCLAIMER
THIS IS COPYRIGHTED CONTENT. Unauthorized use, including screenshots, copying, misuse, reuse, or resale of any content from this app, is strictly prohibited. Our app monitors and records all screenshots and recordings. Violators will face strict legal action.

DISCLAIMER
THIS IS COPYRIGHTED CONTENT. Unauthorized use, including screenshots, copying, misuse, reuse, or resale of any content from this app, is strictly prohibited. Our app monitors and records all screenshots and recordings. Violators will face strict legal action.

WINSPERT

MMF VARIATIONS

SBQ 4

DISABILITY PATIENT. HE CAN'T CLEAN HIS TEETH WITH A TOOTHBRUSH AND HAS A CARER. COULDN'T USE CHX MOUTH RINSE ALSO. HOW CAN HE MAINTAIN HIS ORAL HYGIENE? (SAME OPTIONS LIKE IN DISABILITY ARTICLE) ITS ABOUT COVID RESTRICTION 1 ALSO SPECIFIED

A. Carer Soaks sponge in chx and wipes on teeth.
B. Perform non aerosol generating procedure
C. Hold the suction in the mouth while pt do mouth rinse

P.O.W.E.R NOTES SBQ 4

Reference:

If patients are unable to undertake a pre procedural mouth rinse (e.g. young or special needs) consider providing topical mouth cleansing with gauze soaked in mouth rise. Focus on wiping the buccal mucosa and dorsal tongue surface.

DISCLAIMER
THIS IS COPYRIGHTED CONTENT. Unauthorized use, including screenshots, copying, misuse, reuse, or resale of any content from this app, is strictly prohibited. Our app monitors and records all screenshots and recordings. Violators will face strict legal action.

DISCLAIMER
THIS IS COPYRIGHTED CONTENT. Unauthorized use, including screenshots, copying, misuse, reuse, or resale of any content from this app, is strictly prohibited. Our app monitors and records all screenshots and recordings. Violators will face strict legal action.

DISCLAIMER
THIS IS COPYRIGHTED CONTENT. Unauthorized use, including screenshots, copying, misuse, reuse, or resale of any content from this app, is strictly prohibited. Our app monitors and records all screenshots and recordings. Violators will face strict legal action.

DISCLAIMER
THIS IS COPYRIGHTED CONTENT. Unauthorized use, including screenshots, copying, misuse, reuse, or resale of any content from this app, is strictly prohibited. Our app monitors and records all screenshots and recordings. Violators will face strict legal action.

MMF VARIATIONS

SBQ 5

SAME SCENARIO OF TMJ DELAYED REDUCTION, WITH ONE EXTRA QUESTION: PATIENT HAD MILD CROWDING OF LOWER ANTERIOR TEETH AND WOULD LIKE TO HAVE ORTHO TREATMENT. WHAT WILL YOU ADVISE REGARDING ORTHO TREATMENT (16 YEARS OLD GIRL).

I. Mother concerned about mild crowding and Enquiring about the ortho treatment?

A. Ortho treatment will help with the TMJ problem
B. Ortho treatment should be avoided until TMJ condition improves/stabilizes
C. Ortho treatment will not affect TMJ condition

II. What is the treatment?

A. Michigan splint
B. Mandibular advancement splint
C. Morning anterior repositioning
D. Mandibular stabilization splint
E. No splint given below 16 yrs till jaw growth is complete

P.O.W.E.R NOTES SBQ 5

I. When providing orthodontic Rx of patients with TMD, the symptoms and constantly changing occlusion caused by an unstable condylar position prevents assigning reliable criteria for orthodontic Rx planning. Therefore, the TMJ structures of such patients should be stabilized before active tooth movement to identify and maintain the true mandibular position. Biomechanics to prevent TMJ structures from being affected by unreliable mechanical loads associated with Rx is also recommended. The use of TSAD can be helpful in some patients to accomplish orthodontic Rx objectives that improve TMJ function and facial aesthetics.

II. Michigan splint- for MPDS
Mandibular advancement splint- sleep apnoea. It will lead to posterior open bite, so, should be avoided.

DISCLAIMER
THIS IS COPYRIGHTED CONTENT. Unauthorized use, including screenshots, copying, misuse, reuse, or resale of any content from this app, is strictly prohibited. Our app monitors and records all screenshots and recordings. Violators will face strict legal action.

DISCLAIMER
THIS IS COPYRIGHTED CONTENT. Unauthorized use, including screenshots, copying, misuse, reuse, or resale of any content from this app, is strictly prohibited. Our app monitors and records all screenshots and recordings. Violators will face strict legal action.

DISCLAIMER
THIS IS COPYRIGHTED CONTENT. Unauthorized use, including screenshots, copying, misuse, reuse, or resale of any content from this app, is strictly prohibited. Our app monitors and records all screenshots and recordings. Violators will face strict legal action.

WINSPERT

MMF VARIATIONS

SBQ 6

WHAT IS MASKING HIS PERIO CONDITION (FROM METHAMPHETAMINE SBQ)

A. Increased gingival blood supply (in march it was reduced)
B. Recent cigarette smoking
C. Overall suppression of inflammation in the body
D. Improved oral hygiene

P.O.W.E.R NOTES SBQ 6

In methamphetamine users, the 2 main reasons behind reduced gum bleeding:

- Reduced gingival blood supply because methamphetamine reduces the blood supply to the gingiva
- Excessive inflammatory response within the gingiva

The patient stopped methamphetamine use but started smoking. Smoking is masking his periodontal condition. Smoking has a local vasoconstrictive action.

Reference:

Impact on oral health:

- Dry mouth- meth has a tendency to reduce the salivary production. A dry mouth increases craving for sugary carbonated beverages and food, which can damage teeth and gums. Saliva helps to rinse away food debris and decay causing acids.
- Tooth decay—the very high sugar content in the diets of meth users, along with ineffective oral hygiene, allows bacteria in the plaque to create acids that dissolve their teeth, especially around the gum lime where the concentration of plaque is the highest. This is what causes rampant tooth decay.
- Gum or periodontal disease- meth causes the vessels in the oral cavity to shrink, which reduces the blood supply to the gums and can seriously damage or kill the tissue. In addition, meth users are susceptible to infection and gum disease, since their immune system is not able to fight of the germs that live in the mouth.
- Broken or cracked teeth- meth users tend to clench or grind their teeth due to nervousness or stress from drug reaction. This can cause jaw to ache and already weakened teeth to crack and break.

DISCLAIMER
THIS IS COPYRIGHTED CONTENT. Unauthorized use, including screenshots, copying, misuse, reuse, or resale of any content from this app, is strictly prohibited. Our app monitors and records all screenshots and recordings. Violators will face strict legal action.

DISCLAIMER
THIS IS COPYRIGHTED CONTENT. Unauthorized use, including screenshots, copying, misuse, reuse, or resale of any content from this app, is strictly prohibited. Our app monitors and records all screenshots and recordings. Violators will face strict legal action.

DISCLAIMER
THIS IS COPYRIGHTED CONTENT. Unauthorized use, including screenshots, copying, misuse, reuse, or resale of any content from this app, is strictly prohibited. Our app monitors and records all screenshots and recordings. Violators will face strict legal action.

WINSPERT

MMF VARIATIONS

SBQ 7

CARIES EXCAVATION DONE TILL DEJ. FURTHER REMOVAL OF SOFT PULPAL CARIES WILL RESULT IN PULP EXPOSURE. WHAT IS YOUR NEXT STEP?

A. Remove from the peripheries, maintaining a margin of dentin around and restore with GIC and composite
B. Partial Pulpotomy and GIC restoration
C. Partial Pulpotomy, CaOH, and GIC restoration
D. Partial Pulpotomy, MTA, and GIC restoration
E. Pulpectomy

P.O.W.E.R NOTES SBQ 7

According to the minimal invasive dentistry, we can remove the caries from the peripheries and we can leave a little amount of the infected dentin just above the exposure point and seal the cavity. “seal is the deal”.

THIS IS COPYRIGHTED CONTENT. Unauthorized use, including screenshots, copying, misuse, reuse, or resale of any content from this app, is strictly prohibited. Our app monitors and records all screenshots and recordings. Violators will face strict legal action.

DISCLAIMER

THIS IS COPYRIGHTED CONTENT. Unauthorized use, including screenshots, copying, misuse, reuse, or resale of any content from this app, is strictly prohibited. Our app monitors and records all screenshots and recordings. Violators will face strict legal action.

DISCLAIMER

THIS IS COPYRIGHTED CONTENT. Unauthorized use, including screenshots, copying, misuse, reuse, or resale of any content from this app, is strictly prohibited. Our app monitors and records all screenshots and recordings. Violators will face strict legal action.

DISCLAIMER

THIS IS COPYRIGHTED CONTENT. Unauthorized use, including screenshots, copying, misuse, reuse, or resale of any content from this app, is strictly prohibited. Our app monitors and records all screenshots and recordings. Violators will face strict legal action.

DISCLAIMER

THIS IS COPYRIGHTED CONTENT. Unauthorized use, including screenshots, copying, misuse, reuse, or resale of any content from this app, is strictly prohibited. Our app monitors and records all screenshots and recordings. Violators will face strict legal action.

WINSPERT

MMF VARIATIONS

SBQ 8

WHAT IS THE ROLE OF FLUORIDES? IT'S A STAND ALONE QUESTION

A. Xerostomia
B. Sensitivity prevention
C. Remineralisation

P.O.W.E.R NOTES SBQ 8

Fluoride is a re-mineralising agent.

DISCLAIMER
THIS IS COPYRIGHTED CONTENT. Unauthorized use, including screenshots, copying, misuse, reuse, or resale of any content from this app, is strictly prohibited. Our app monitors and records all screenshots and recordings. Violators will face strict legal action.

DISCLAIMER
THIS IS COPYRIGHTED CONTENT. Unauthorized use, including screenshots, copying, misuse, reuse, or resale of any content from this app, is strictly prohibited. Our app monitors and records all screenshots and recordings. Violators will face strict legal action.

DISCLAIMER
THIS IS COPYRIGHTED CONTENT. Unauthorized use, including screenshots, copying, misuse, reuse, or resale of any content from this app, is strictly prohibited. Our app monitors and records all screenshots and recordings. Violators will face strict legal action.

DISCLAIMER
THIS IS COPYRIGHTED CONTENT. Unauthorized use, including screenshots, copying, misuse, reuse, or resale of any content from this app, is strictly prohibited. Our app monitors and records all screenshots and recordings. Violators will face strict legal action.

DISCLAIMER
THIS IS COPYRIGHTED CONTENT. Unauthorized use, including screenshots, copying, misuse, reuse, or resale of any content from this app, is strictly prohibited. Our app monitors and records all screenshots and recordings. Violators will face strict legal action.

DISCLAIMER
THIS IS COPYRIGHTED CONTENT. Unauthorized use, including screenshots, copying, misuse, reuse, or resale of any content from this app, is strictly prohibited. Our app monitors and records all screenshots and recordings. Violators will face strict legal action.

WINSPERT

MMF VARIATIONS

SBQ 9

WHAT'S THE FIRST STEP IN OCCLUSION REGISTRATION APPOINTMENT :

A. VDO
B. Centric relation
C. Maxillary occlusal rim plane

P.O.W.E.R NOTES SBQ 9

When you start taking the jaw relationship, you follow the below steps:

- Orientation jaw relation (maxillary occlusal rim plane)
- Vertical dimension
- Centric jaw relation

DISCLAIMER
THIS IS COPYRIGHTED CONTENT. Unauthorized use, including screenshots, copying, misuse, reuse, or resale of any content from this app, is strictly prohibited. Our app monitors and records all screenshots and recordings. Violators will face strict legal action.

DISCLAIMER
THIS IS COPYRIGHTED CONTENT. Unauthorized use, including screenshots, copying, misuse, reuse, or resale of any content from this app, is strictly prohibited. Our app monitors and records all screenshots and recordings. Violators will face strict legal action.

DISCLAIMER
THIS IS COPYRIGHTED CONTENT. Unauthorized use, including screenshots, copying, misuse, reuse, or resale of any content from this app, is strictly prohibited. Our app monitors and records all screenshots and recordings. Violators will face strict legal action.

DISCLAIMER
THIS IS COPYRIGHTED CONTENT. Unauthorized use, including screenshots, copying, misuse, reuse, or resale of any content from this app, is strictly prohibited. Our app monitors and records all screenshots and recordings. Violators will face strict legal action.

WINSPERT

MMF VARIATIONS

SBQ 10

FOR NITROUS OXIDE WHAT IS AN ABSOLUTE CONTRAINDICATION YOU SHOULD ENQUIRE HER NEXT (OLD PEDO SBQ WITH LOW WEIGHT CHILD)

A. Latex allergy (but not given in history)
B. Her 15th weight percentile
C. Recent exacerbation of asthma
D. White blood cell count

P.O.W.E.R NOTES SBQ 10

N2O is contraindicated in recent asthma episodes and in severe asthma. 15th weight percentile is a low weight range but it's not malnourished.

DISCLAIMER
THIS IS COPYRIGHTED CONTENT. Unauthorized use, including screenshots, copying, misuse, reuse, or resale of any content from this app, is strictly prohibited. Our app monitors and records all screenshots and recordings. Violators will face strict legal action.

DISCLAIMER
THIS IS COPYRIGHTED CONTENT. Unauthorized use, including screenshots, copying, misuse, reuse, or resale of any content from this app, is strictly prohibited. Our app monitors and records all screenshots and recordings. Violators will face strict legal action.

DISCLAIMER
THIS IS COPYRIGHTED CONTENT. Unauthorized use, including screenshots, copying, misuse, reuse, or resale of any content from this app, is strictly prohibited. Our app monitors and records all screenshots and recordings. Violators will face strict legal action.

DISCLAIMER
THIS IS COPYRIGHTED CONTENT. Unauthorized use, including screenshots, copying, misuse, reuse, or resale of any content from this app, is strictly prohibited. Our app monitors and records all screenshots and recordings. Violators will face strict legal action.

DISCLAIMER
THIS IS COPYRIGHTED CONTENT. Unauthorized use, including screenshots, copying, misuse, reuse, or resale of any content from this app, is strictly prohibited. Our app monitors and records all screenshots and recordings. Violators will face strict legal action.

WINSPERT

MMF VARIATIONS

SBQ 11

WHAT YOU SHOULD DO BEFORE FINAL RESTORATION FOR DEEP CARIES IN REVERSIBLE PULPITIS

A. Remove caries place zoe
B. Remove caries place gic
C. Remove caries place composite

P.O.W.E.R NOTES SBQ 11

Final restoration for reversible pulpitis is composite.
But in the question, it's asked "before the final restoration" so, GIC is the best answer among the given. GIC is a temporary material.

THIS IS COPYRIGHTED CONTENT. Unauthorized use, including screenshots, copying, misuse, reuse, or resale of any content from this app, is strictly prohibited. Our app monitors and records all screenshots and recordings. Violators will face strict legal action.

DISCLAIMER
THIS IS COPYRIGHTED CONTENT. Unauthorized use, including screenshots, copying, misuse, reuse, or resale of any content from this app, is strictly prohibited. Our app monitors and records all screenshots and recordings. Violators will face strict legal action.

DISCLAIMER
THIS IS COPYRIGHTED CONTENT. Unauthorized use, including screenshots, copying, misuse, reuse, or resale of any content from this app, is strictly prohibited. Our app monitors and records all screenshots and recordings. Violators will face strict legal action.

DISCLAIMER
THIS IS COPYRIGHTED CONTENT. Unauthorized use, including screenshots, copying, misuse, reuse, or resale of any content from this app, is strictly prohibited. Our app monitors and records all screenshots and recordings. Violators will face strict legal action.

DISCLAIMER
THIS IS COPYRIGHTED CONTENT. Unauthorized use, including screenshots, copying, misuse, reuse, or resale of any content from this app, is strictly prohibited. Our app monitors and records all screenshots and recordings. Violators will face strict legal action.

WINSPERT

MMF VARIATIONS

SBQ 12

BOY WITH MEASLES AS WE DID IN COMPILATION.

I. Mum called that child developed facial swelling , What will you do?

A. Do sterilisation 2 times
B. First patent of the day
C. P2 n95 mask
D. Use a surgical mask
E. Do patient with staff who had already developed measles in childhood
F. Do surface cleaning twice

P.O.W.E.R NOTES SBQ 12

A patient with a facial swelling should be addressed immediately and can't defer even though the patient is suffering from mumps. Need to follow up the transmission-based precautions.

Reference: ICG

- The patient is seen as the last patient of the day
- Ensuring that the staff providing the Rx have been immunised against the current circulating influenza strains
- Use of a preprocedural mouth rinse
- Use of dental dam for restorative procedures
- Minimising the use of aerosol generating techniques
- Applying two complete cycles of cleaning for environmental surfaces
- If the patient is seen during the day, allowing of 30mins of fallow time before the room is used for further procedures on the same day.

*For effective airborne precautions, a P2 (N95) surgical respirator is required.

In this question it's given the options as "the 1st patient of the day" so, it's an incorrect answer. If it was given as "the last patient of the day" then that would be the best answer when compared to the option "N95".

DISCLAIMER
THIS IS COPYRIGHTED CONTENT. Unauthorized use, including screenshots, copying, misuse, reuse, or resale of any content from this app, is strictly prohibited. Our app monitors and records all screenshots and recordings. Violators will face strict legal action.

DISCLAIMER
THIS IS COPYRIGHTED CONTENT. Unauthorized use, including screenshots, copying, misuse, reuse, or resale of any content from this app, is strictly prohibited. Our app monitors and records all screenshots and recordings. Violators will face strict legal action.

DISCLAIMER
THIS IS COPYRIGHTED CONTENT. Unauthorized use, including screenshots, copying, misuse, reuse, or resale of any content from this app, is strictly prohibited. Our app monitors and records all screenshots and recordings. Violators will face strict legal action.

WINSPERT

MMF VARIATIONS

SBQ 13

HSV CASE

SCENARIO WITH PATIENT CAME BACK WITH LESION ON LIP. PATIENT IS A STUDENT WITH A LOT OF STRESS. PATIENT WITH LESION ON THE LIPS.

I. The patient came the next day after you did a filling in the molar or premolar complaining that you injured him during the procedure. What can be the cause of this lesion?

A. You injure him with the filling
B. The material that you use for the filling spill to the corner of the mouth
C. The patient bite himself being numb by the anesthesia

OR

What is the cause if he would have gotten it from the clinic?

A. Burn from the hot hand instrument.
B. Dull injury with instrument.
C. Patient bite on lip while numb. (not in some centers)
D. Smoking while numb
E. Herpes labialis

II. What will you prescribe for the lesions?

A. Betamethasone dipropionate 0.05% twice daily after food
B. Acyclovir 5% cream 4 hourly for 4 days
C. Miconazole 2% 4 hourly for 4 days
D. Benzydamine 1%

DISCLAIMER
THIS IS COPYRIGHTED CONTENT. Unauthorized use, including screenshots, copying, misuse, reuse, or resale of any content from this app, is strictly prohibited. Our app monitors and records all screenshots and recordings. Violators will face strict legal action.

DISCLAIMER
THIS IS COPYRIGHTED CONTENT. Unauthorized use, including screenshots, copying, misuse, reuse, or resale of any content from this app, is strictly prohibited. Our app monitors and records all screenshots and recordings. Violators will face strict legal action.

DISCLAIMER
THIS IS COPYRIGHTED CONTENT. Unauthorized use, including screenshots, copying, misuse, reuse, or resale of any content from this app, is strictly prohibited. Our app monitors and records all screenshots and recordings. Violators will face strict legal action.

DISCLAIMER
THIS IS COPYRIGHTED CONTENT. Unauthorized use, including screenshots, copying, misuse, reuse, or resale of any content from this app, is strictly prohibited. Our app monitors and records all screenshots and recordings. Violators will face strict legal action.

WINSPERT

MMF VARIATIONS

P.O.W.E.R NOTES SBQ 13

I. Herpes simples labialis is not given as an option. Among the given options (C) is the best. Injuring during the procedure or materials spilling on the corner of the mouth won't give rise to blisters like that which present on the picture.
OR
(C), (D) and (E) can be rued out as they are not iatrogenic causes. Dental injury with a hot instrument handling by the dentist is likely to happen. (A) is more likely to happen when compared with (B).

II. Inform the patient that it is recurrent herpes infection. In recurrent HSV, 5%acyclovir 5times a day for 5days or famciclovir 1500mg orally as a single dose is prescribed.

DISCLAIMER
THIS IS COPYRIGHTED CONTENT. Unauthorized use, including screenshots, copying, misuse, reuse, or resale of any content from this app, is strictly prohibited. Our app monitors and records all screenshots and recordings. Violators will face strict legal action.

DISCLAIMER
THIS IS COPYRIGHTED CONTENT. Unauthorized use, including screenshots, copying, misuse, reuse, or resale of any content from this app, is strictly prohibited. Our app monitors and records all screenshots and recordings. Violators will face strict legal action.

DISCLAIMER
THIS IS COPYRIGHTED CONTENT. Unauthorized use, including screenshots, copying, misuse, reuse, or resale of any content from this app, is strictly prohibited. Our app monitors and records all screenshots and recordings. Violators will face strict legal action.

DISCLAIMER
THIS IS COPYRIGHTED CONTENT. Unauthorized use, including screenshots, copying, misuse, reuse, or resale of any content from this app, is strictly prohibited. Our app monitors and records all screenshots and recordings. Violators will face strict legal action.

MMF VARIATIONS

SBQ 14

(VARIATION) APPLICATION OF SEALANT AND VARNISH

PATIENT PRESENTS TO YOU WITH THEIR CHILD. THE PREVIOUS DENTIST SHIFTED TO SOME OTHER CITY. DENTIST HAD APPLIED VARNISH AND SEALANT TO 55 AND 65 AND ASKED TO VISIT AFTER 6 MONTHS. WHAT ELSE HAS BEEN NOT DONE BY THE DENTIST? NOW ALL THE TEETH WERE GROSSLY DESTROYED EXCEPT 55 AND 65.

I. What should have previous dentist done to stabilize/ prevent her high caries risk?

A. Categorizing the child as high caries and early child intervention
B. Early prevention and intervention should have been applied
C. No need to do anything previous dentist have done the preventive treatment
D. Should have extracted incisors and other teeth with poor prognosis.

II. It was asked what will be your immediate and important management to address with respect to the chief complaint?

A. Remove the unrestorable poor prognosis maxillary anteriors (51 just had small proximal caries, wasn't grossly carious).
B. Remove 54 and 64 were only root stump
C. Pulpotomy and restore 75
D. Pulpectomy and restore 54 pulpectomy and stainless steel crown with respect to 54(had caries involved until furcation area in IOPA
E. Extract all the unrestorable teeth in the first visit.

P.O.W.E.R NOTES SBQ 14

I. In a high caries risk patient emergency Mx is required. Removal of poorly prognostic teeth, performing preventive methods for caries stabilisation.

II. Incomplete Hx in the given question. Chief compliant is not given.

DISCLAIMER
THIS IS COPYRIGHTED CONTENT. Unauthorized use, including screenshots, copying, misuse, reuse, or resale of any content from this app, is strictly prohibited. Our app monitors and records all screenshots and recordings. Violators will face strict legal action.

DISCLAIMER
THIS IS COPYRIGHTED CONTENT. Unauthorized use, including screenshots, copying, misuse, reuse, or resale of any content from this app, is strictly prohibited. Our app monitors and records all screenshots and recordings. Violators will face strict legal action.

DISCLAIMER
THIS IS COPYRIGHTED CONTENT. Unauthorized use, including screenshots, copying, misuse, reuse, or resale of any content from this app, is strictly prohibited. Our app monitors and records all screenshots and recordings. Violators will face strict legal action.

MMF VARIATIONS

SBQ 15

ABORIGINAL VARIATION

A 34 YEAR OLD ABORIGINAL PATIENT WITH HYPERPLASTIC PULPITIS AND PAIN CAME WITH HIS SON WHO IS 14 YEARS OLD. HE HAS A HISTORY OF RHEUMATIC FEVER AS A CHILD. YOU TOOK AN IOPA OF THE PATIENT.

I. Why is his son not the best choice of an interpreter?

A. Because it is difficult to find a translator
B. As it was a serious case
C. You can use as 14 year old is a mature minor
D. You can use in an emergency
E. Usually relatives do not give the correct/exact history.

II. You are considering extraction, what will be the endocarditis related prophylaxis regime?

A. Amoxicillin 2g 60 min before the procedure
B. Amoxicillin 3g 60 min prior to the treatment
C. Clindamycin 2g 60 min before the procedure

III. You diagnose his condition as chronic hyperplastic pulpitis, what will be further management. (only two walls were remaining, and very thin)

A. Extract the 37 and send for pathology
B. Remove the growth of the tissue and send to lab and do root canal treatment
C. Do Endo treatment but no need to send anything for pathology

P.O.W.E.R NOTES SBQ 15

I. In an emergency situation, son can take the role of the interpreter. As they don't give the correct information / interpretation they are not the best choice of interpreter.

II. He needs prophylactic AB dose to prevent endocarditis. Amoxicillin 2g 60min before or clindamycin 600mg 6omin before can be given.

III. According to the question, there's not enough tooth structure. Therefore, extraction is preferred.

DISCLAIMER
THIS IS COPYRIGHTED CONTENT. Unauthorized use, including screenshots, copying, misuse, reuse, or resale of any content from this app, is strictly prohibited. Our app monitors and records all screenshots and recordings. Violators will face strict legal action.

DISCLAIMER
THIS IS COPYRIGHTED CONTENT. Unauthorized use, including screenshots, copying, misuse, reuse, or resale of any content from this app, is strictly prohibited. Our app monitors and records all screenshots and recordings. Violators will face strict legal action.

DISCLAIMER
THIS IS COPYRIGHTED CONTENT. Unauthorized use, including screenshots, copying, misuse, reuse, or resale of any content from this app, is strictly prohibited. Our app monitors and records all screenshots and recordings. Violators will face strict legal action.

WINSPERT

MMF VARIATIONS

SBQ 16

MOUTHGUARD VARIATION

YOU ARE VISITING A CLUB WHERE PLAYERS PLAY RUGBY. COACH TOLD YOU THAT THE PLAYERS WEAR MOUTH GUARDS WHILE PLAYING. YOU NOTICED PLAYERS DRINK SPORTS DRINKS BEFORE WEARING MOUTH GUARDS AND DO NOT DRINK MUCH WATER.

I. Based on the coach's information given to you, what effect will you find on players teeth?

A. Dental trauma
B. Erosion
C. Bruxism

II. Which type of mouthguard is recommended for rugby players 14-15 years?

A. Custom made
B. Stock made
C. Bimaxillary
D. Laminated

III. What advice will you give to the players to prevent caries and erosions. Coach said that players are wearing mouth guards during practices and matches. You notice that they were drinking sports drinks for hydration and electrolytes before wearing the mouth guard.

A. Substitute sport drinks with water
B. Drink sports drink after wearing the mouth guard
C. Alternate between sports drink and water
D. Drink only sugar free drinks

DISCLAIMER
THIS IS COPYRIGHTED CONTENT. Unauthorized use, including screenshots, copying, misuse, reuse, or resale of any content from this app, is strictly prohibited. Our app monitors and records all screenshots and recordings. Violators will face strict legal action.

DISCLAIMER
THIS IS COPYRIGHTED CONTENT. Unauthorized use, including screenshots, copying, misuse, reuse, or resale of any content from this app, is strictly prohibited. Our app monitors and records all screenshots and recordings. Violators will face strict legal action.

DISCLAIMER
THIS IS COPYRIGHTED CONTENT. Unauthorized use, including screenshots, copying, misuse, reuse, or resale of any content from this app, is strictly prohibited. Our app monitors and records all screenshots and recordings. Violators will face strict legal action.

DISCLAIMER
THIS IS COPYRIGHTED CONTENT. Unauthorized use, including screenshots, copying, misuse, reuse, or resale of any content from this app, is strictly prohibited. Our app monitors and records all screenshots and recordings. Violators will face strict legal action.

WINSPERT

MMF VARIATIONS

P.O.W.E.R NOTES SBQ 16

I. Consumption of sports drinks before waring mouth guard is associated with erosion.

II. In high impact professional sports in permanent dentition; custom made trilaminar mouth guard
In high impact professional sports in mixed dentition up to 13yrs; custom made bilaminar mouth guard.

III. Consumptions of sports drinks while they are wearing the mouth guards on helps to prevent getting caries and erosion.

DISCLAIMER
THIS IS COPYRIGHTED CONTENT. Unauthorized use, including screenshots, copying, misuse, reuse, or resale of any content from this app, is strictly prohibited. Our app monitors and records all screenshots and recordings. Violators will face strict legal action.

DISCLAIMER
THIS IS COPYRIGHTED CONTENT. Unauthorized use, including screenshots, copying, misuse, reuse, or resale of any content from this app, is strictly prohibited. Our app monitors and records all screenshots and recordings. Violators will face strict legal action.

DISCLAIMER
THIS IS COPYRIGHTED CONTENT. Unauthorized use, including screenshots, copying, misuse, reuse, or resale of any content from this app, is strictly prohibited. Our app monitors and records all screenshots and recordings. Violators will face strict legal action.

DISCLAIMER
THIS IS COPYRIGHTED CONTENT. Unauthorized use, including screenshots, copying, misuse, reuse, or resale of any content from this app, is strictly prohibited. Our app monitors and records all screenshots and recordings. Violators will face strict legal action.

WINSPERT

MMF VARIATIONS

SBQ 17

FPD FRACTURE - MMF PAPER 2 SBQ 2 VARIATION

A MALE PATIENT PRESENTED TO YOUR CLINIC WITH CHIPPED PORCELAIN. HE HAS TO ATTEND A MEETING SOON,ON PICTURES EDGE TO EDGE BITE IS SEEN. PORCELAIN IS CHIPPED OFF IN THE REGION OF 11 AND 21 (METAL IS SEEN ONLY ON 11) BRIDGE SPAN WAS 12-23.

(CANINE HAD A CROWN, AS WELL AS ABRASION AND THE CROWN WAS NOT COVERING THE ABRASION. ONLY TOOTH 11 WAS TOUCHING LOWER TEETH,SO THE BRIDGE WAS IN HYPER OCCLUSION ONLY AT 11 LOCATION. AND IT WAS CLEARLY SEEN THAT 21 WAS NOT TOUCHING THE LOWER ANTERIOR TOOTH.)

I. How will you prevent this from happening in the new fixed prosthesis?

A. Construct a new prosthesis with canine guided occlusion.
B. Build zirconia prosthesis
C. Construct occlusal splint
D. Construct high strength porcelain bridge
E. Give implant on 21

II. You choose to make a metal free fixed partial denture this time. What material will you use for the same?

A. Zirconia
B. Something composite
C. Leucite reinforced
D. Lithium reinforced
E. Cad Cam

III. If you want to repair the fractured porcelain in the chair, what will you do?

A. Etching with 4% hydrofluoric acid, for 20 sec, apply silane and composite
B. Etching with 4% hydrofluoric acid for 5 min add silane and composite

DISCLAIMER
THIS IS COPYRIGHTED CONTENT. Unauthorized use, including screenshots, copying, misuse, reuse, or resale of any content from this app, is strictly prohibited. Our app monitors and records all screenshots and recordings. Violators will face strict legal action.

DISCLAIMER
THIS IS COPYRIGHTED CONTENT. Unauthorized use, including screenshots, copying, misuse, reuse, or resale of any content from this app, is strictly prohibited. Our app monitors and records all screenshots and recordings. Violators will face strict legal action.

DISCLAIMER
THIS IS COPYRIGHTED CONTENT. Unauthorized use, including screenshots, copying, misuse, reuse, or resale of any content from this app, is strictly prohibited. Our app monitors and records all screenshots and recordings. Violators will face strict legal action.

WINSPERT

MMF VARIATIONS

P.O.W.E.R NOTES SBQ 17

I. Bridge was in hyper occlusion. So, it's better to give a high strength prosthesis e.g. zirconia. And good to recommend wearing a splint. Canine is in the part of the FPD, so, we must not give canine guided occlusion. Implants are not indicated in hyper occlusion situation with heavy loads.

II. Among the given zirconia has highest tensile and compressive strength.

III. Repairing fractured porcelain in the dental chair:
Etching with 4% hydrofluoric acid for 5mins and add silane and composite.

THIS IS COPYRIGHTED CONTENT. Unauthorized use, including screenshots, copying, misuse, reuse, or resale of any content from this app, is strictly prohibited. Our app monitors and records all screenshots and recordings. Violators will face strict legal action.

DISCLAIMER
THIS IS COPYRIGHTED CONTENT. Unauthorized use, including screenshots, copying, misuse, reuse, or resale of any content from this app, is strictly prohibited. Our app monitors and records all screenshots and recordings. Violators will face strict legal action.

DISCLAIMER
THIS IS COPYRIGHTED CONTENT. Unauthorized use, including screenshots, copying, misuse, reuse, or resale of any content from this app, is strictly prohibited. Our app monitors and records all screenshots and recordings. Violators will face strict legal action.

DISCLAIMER
THIS IS COPYRIGHTED CONTENT. Unauthorized use, including screenshots, copying, misuse, reuse, or resale of any content from this app, is strictly prohibited. Our app monitors and records all screenshots and recordings. Violators will face strict legal action.

DISCLAIMER
THIS IS COPYRIGHTED CONTENT. Unauthorized use, including screenshots, copying, misuse, reuse, or resale of any content from this app, is strictly prohibited. Our app monitors and records all screenshots and recordings. Violators will face strict legal action.

WINSPERT

MMF VARIATIONS

SBQ 18

ANOTHER PATIENT CAME TO YOU.THERE WAS NO DENTAL HISTORY MENTIONED ABOUT ORAL HYGIENE OR TOOTHPASTE, SHE HAS ARRESTED CARIES AND ALSO HAS EROSION.

I. What toothpaste will you prescribe for her sensitivity?

A. Toothpaste containing Sodium monofluorophosphate
B. Toothpaste containing stannous salt
C. Toothpaste containing Triclosan salt
D. Mouth wash

P.O.W.E.R NOTES SBQ 18

I. Patient has both caries and sensitive teeth. Among the given sodium monofluorophosphate address both the concerns.

THIS IS COPYRIGHTED CONTENT. Unauthorized use, including screenshots, copying, misuse, reuse, or resale of any content from this app, is strictly prohibited. Our app monitors and records all screenshots and recordings. Violators will face strict legal action.

DISCLAIMER

THIS IS COPYRIGHTED CONTENT. Unauthorized use, including screenshots, copying, misuse, reuse, or resale of any content from this app, is strictly prohibited. Our app monitors and records all screenshots and recordings. Violators will face strict legal action.

DISCLAIMER

THIS IS COPYRIGHTED CONTENT. Unauthorized use, including screenshots, copying, misuse, reuse, or resale of any content from this app, is strictly prohibited. Our app monitors and records all screenshots and recordings. Violators will face strict legal action.

DISCLAIMER

THIS IS COPYRIGHTED CONTENT. Unauthorized use, including screenshots, copying, misuse, reuse, or resale of any content from this app, is strictly prohibited. Our app monitors and records all screenshots and recordings. Violators will face strict legal action.

DISCLAIMER

THIS IS COPYRIGHTED CONTENT. Unauthorized use, including screenshots, copying, misuse, reuse, or resale of any content from this app, is strictly prohibited. Our app monitors and records all screenshots and recordings. Violators will face strict legal action.

WINSPERT

MMF VARIATIONS

SBQ 19

A CHILD PATIENT PRESENTS TO YOU WITH HER PARENTS, SHE CONSUMES COLA UPON CLINICAL EXAMINATION, PLAQUE IS PRESENT, GINGIVITIS IS SEEN,AND STAINS BETWEEN FRONT TEETH. WHAT WOULD SUGGESTTHAT THE PATIENT IS HAVING POOR ORAL HYGIENE?

A. Gingival inflammation present
B. Stains are present
C. Bleeding

P.O.W.E.R NOTES SBQ 19

Among option (A) vs (C), (C) is the direct indicator of the poor oral hygiene. Bleeding is more quantifiable.

THIS IS COPYRIGHTED CONTENT. Unauthorized use, including screenshots, copying, misuse, reuse, or resale of any content from this app, is strictly prohibited. Our app monitors and records all screenshots and recordings. Violators will face strict legal action.

DISCLAIMER

THIS IS COPYRIGHTED CONTENT. Unauthorized use, including screenshots, copying, misuse, reuse, or resale of any content from this app, is strictly prohibited. Our app monitors and records all screenshots and recordings. Violators will face strict legal action.

DISCLAIMER

THIS IS COPYRIGHTED CONTENT. Unauthorized use, including screenshots, copying, misuse, reuse, or resale of any content from this app, is strictly prohibited. Our app monitors and records all screenshots and recordings. Violators will face strict legal action.

DISCLAIMER

THIS IS COPYRIGHTED CONTENT. Unauthorized use, including screenshots, copying, misuse, reuse, or resale of any content from this app, is strictly prohibited. Our app monitors and records all screenshots and recordings. Violators will face strict legal action.

DISCLAIMER

THIS IS COPYRIGHTED CONTENT. Unauthorized use, including screenshots, copying, misuse, reuse, or resale of any content from this app, is strictly prohibited. Our app monitors and records all screenshots and recordings. Violators will face strict legal action.

WINSPERT

MMF VARIATIONS

SBQ 20

TONGUE PIERCING AND HOCKEY PLAYER

A TEENAGERWANTS TO GET TONGUE PIERCING. SHE SAYS SHE KEEPS WORRYING ABOUT A LOT OF THINGS AND HER GENERAL APPEARANCE LOOKS UNKEMPT. SHE SAYS SHE IS STRESSED ABOUT ALL SORTS OF THINGS. HER MOTHER IS DIVORCED AND A BUSY LAWYER, HOWEVER WHEN YOU ASK HER ABOUT HOCKEY, SHE BECOMES VERY ENTHUSIASTIC. THE PATIENT IS FEELING TIRED AND LETHARGIC FOR SOME TIME.

I. About mouthguard for soccer: What will you advise her while playing hockey?

A. Boil and bite
B. 4mm Custom made tray extending till distal of 1st molar
C. 6mm custom made tray extending up to distal of 2nd molar
D. 6.6mm 6.8 mm custom made tray having full occlusal coverage

II. Mouth guard question. Which has least impact on training and advanced sports and making breathing easy?

A. Custom made
B. Boil and bite
C. Stock
D. Bimaxillary

P.O.W.E.R NOTES SBQ 20

I. In mouth guards it's always preferred to wear the custom-made ones. Therefore, option (A) is ruled out.
She's a teenager. So, she's having all permanent teeth. In kids younger than 12 years it is recommended to make mouth guards till the distal of 1st molar. In her case, as she is a teenager all her 2nd molars are erupted, so, it's made up to distal of 2nd molar. Option (B) is ruled out.

II. Bimaxillary require a breathing channel. Option (D) is ruled out. Bimaxillary is indicated in professional level boxing and martial arts.
Custom made- least impact on breathing and making breathing easy. Even in the advanced sports still the custom made is indicated.

DISCLAIMER
THIS IS COPYRIGHTED CONTENT. Unauthorized use, including screenshots, copying, misuse, reuse, or resale of any content from this app, is strictly prohibited. Our app monitors and records all screenshots and recordings. Violators will face strict legal action.

DISCLAIMER
THIS IS COPYRIGHTED CONTENT. Unauthorized use, including screenshots, copying, misuse, reuse, or resale of any content from this app, is strictly prohibited. Our app monitors and records all screenshots and recordings. Violators will face strict legal action.

DISCLAIMER
THIS IS COPYRIGHTED CONTENT. Unauthorized use, including screenshots, copying, misuse, reuse, or resale of any content from this app, is strictly prohibited. Our app monitors and records all screenshots and recordings. Violators will face strict legal action.

WINSPERT

MMF VARIATIONS

SBQ 21

RETAINED CANINE

SAME AS MEGA MASTERRETAINED PRIMARY CANINE QUESTION WITH TOO WHITE AND BRIGHT RESTORATION OVER CONTOURED, THIS TIME THE CANINE WAS MOBILE. OPG WAS PROVIDED, CLINICAL PICTURE WAS ALSO GIVEN, CANINE SHOWED ROOT RESORPTION.
LADY WITH A VENEER ON RETAINED PRIMARY CANINENOT HAPPY WITH HOW IT LOOKS SHE FEELS LIKE IT'S GETTING LOOSE.

I. You see something around her gingivalregion of tooth adjacent to her retained primary canine (on picture you could see lateral incisor had abrasion)

A. Caries
B. Non-Carious tooth wear (abrasion)
C. Developmental defect

II. She wants bleaching, and you are worried about sensitivity

A. You restore22 and then give bleaching
B. You do bleaching first and if sensitivity develops then restore 22
C. You give remineralizing toothpaste to use concurrently along with home bleaching with trays
D. You do bleach first and if give desensitizing toothpaste

III. She wants a treatment which is not expensive and minimally invasive. What is your treatment plan.

A. Give a Porcelains veneer on her primary retained canine
B. Exo and place implant
C. Exo and indirect fiber resin bonded bridge
D. Exo and direct resin bonded bridge

IV. Patient is going to attend a wedding in two days and doesn't want an extraction. What is the immediate procedure you can do?

A. Crown
B. Multilayered composite restoration
C. Single layer composite restoration
D. Porcelain veneer

DISCLAIMER
THIS IS COPYRIGHTED CONTENT. Unauthorized use, including screenshots, copying, misuse, reuse, or resale of any content from this app, is strictly prohibited. Our app monitors and records all screenshots and recordings. Violators will face strict legal action.

DISCLAIMER
THIS IS COPYRIGHTED CONTENT. Unauthorized use, including screenshots, copying, misuse, reuse, or resale of any content from this app, is strictly prohibited. Our app monitors and records all screenshots and recordings. Violators will face strict legal action.

DISCLAIMER
THIS IS COPYRIGHTED CONTENT. Unauthorized use, including screenshots, copying, misuse, reuse, or resale of any content from this app, is strictly prohibited. Our app monitors and records all screenshots and recordings. Violators will face strict legal action.

WINSPERT

MMF VARIATIONS

P.O.W.E.R NOTES SBQ 21

I. Abrasion can be seen on the adjacent tooth. It's a non-carious tooth wear.

II. As abrasion present on the lateral incisor, it can be more sensitive if bleaching is done. Therefore, needed to stabilize the oral environment before doing bleaching. Temporisation is the best treatment to stabilize the oral condition. Cannot give the permanent restorations before bleaching as the colour of the teeth might get changed after bleaching and the filling may not match with that colour.
Dentine sealers/ re-mineralising toothpaste can use to seal the dentinal tubules concurrently with the home bleaching with trays. Sensitivity must be milder in this case. Less sensitivity can happen because of the milder doses of peroxide in home bleaching technique. Even the soft tissues and dentinal tubules are safe in-home bleaching technique. It's the safest conservative management.

- Office beaching – 20% peroxide
- Home bleaching -3% peroxide

Among the given option (C) is the best answer.

III. Primary retained canine is mobile now therefore, can't give the porcelain veneers over that tooth. Option (A) is ruled out.
Patient is looking for a treatment which is not expensive and minimal invasive. Therefore, option (B) is ruled out.
both direct and indirect composite veneers are cheap as they are made up with composite. Direct resin bonded bridge is a temporary solution. It's not strong enough to withstand the biting forces. Indirect fibre resin bonded bridge which is made in the lab; has the pontics and retainer wings as a one-unit block.
Therefore, indirect resin bonded bridge has more strength, rigidity and retention compared to the direct resin bonded bridge. And they are less prone to shrinkage and marginal/micro leakage too. So, among these 2 options indirect resin bonded bridge is a more permanent solution. Option (C) is the best answer among the given.

IV. Tooth will be extracted later but for the time being needed to give her the best looks for the wedding. Options (A) and (D) are permanent options and they can be ruled out. Single layer composite is inferior compared to multilayered composite.

DISCLAIMER
THIS IS COPYRIGHTED CONTENT. Unauthorized use, including screenshots, copying, misuse, reuse, or resale of any content from this app, is strictly prohibited. Our app monitors and records all screenshots and recordings. Violators will face strict legal action.

DISCLAIMER
THIS IS COPYRIGHTED CONTENT. Unauthorized use, including screenshots, copying, misuse, reuse, or resale of any content from this app, is strictly prohibited. Our app monitors and records all screenshots and recordings. Violators will face strict legal action.

DISCLAIMER
THIS IS COPYRIGHTED CONTENT. Unauthorized use, including screenshots, copying, misuse, reuse, or resale of any content from this app, is strictly prohibited. Our app monitors and records all screenshots and recordings. Violators will face strict legal action.

WINSPERT

MMF VARIATIONS

SBQ 22

TOOTH 74- SIMILAR PICTURE (GINGIVA SEEN BELOW THE CAVITY -NO GINGIVAL SEAT) HOW DO YOU RESTORE?

A. Composite
B. Gic
C. Rmgic
D. Pulpotomy

P.O.W.E.R NOTES SBQ 22

The authors concluded that conventional GIC s cannot be recommended for class II restorations in primary molars. They noted however, that evidence supports the use of RMGIC for small to moderate sized class II restorations.
As resin-based composites are the most time consuming and most technique sensitive materials and have potential for marginal leakage, they are generally unsuitable for class II intra-coronal restorations in primary teeth, particularly if the child is uncooperative or at high caries risk.
Placement of compomer is more time consuming and technically demanding than placement of GIC, isolation with rubber dam is recommended.
In primary molars with proximal cavities, use of RMGIC, compared with GIC, composite and compomer, resulted in highest clinical success rate (89%) when followed for at least 1 year.

DISCLAIMER
THIS IS COPYRIGHTED CONTENT. Unauthorized use, including screenshots, copying, misuse, reuse, or resale of any content from this app, is strictly prohibited. Our app monitors and records all screenshots and recordings. Violators will face strict legal action.

DISCLAIMER
THIS IS COPYRIGHTED CONTENT. Unauthorized use, including screenshots, copying, misuse, reuse, or resale of any content from this app, is strictly prohibited. Our app monitors and records all screenshots and recordings. Violators will face strict legal action.

DISCLAIMER
THIS IS COPYRIGHTED CONTENT. Unauthorized use, including screenshots, copying, misuse, reuse, or resale of any content from this app, is strictly prohibited. Our app monitors and records all screenshots and recordings. Violators will face strict legal action.

DISCLAIMER
THIS IS COPYRIGHTED CONTENT. Unauthorized use, including screenshots, copying, misuse, reuse, or resale of any content from this app, is strictly prohibited. Our app monitors and records all screenshots and recordings. Violators will face strict legal action.

WINSPERT

MMF VARIATIONS

SBQ 23

A SIMILAR PIC WAS GIVEN AND ASKED WHAT IS THE CONSEQUENCE IF THE LOWER 3RD MOLAR IS NOT REMOVED?

A. Caries in 47
B. Displacement of 47
C. Resorption 47
D. No change

P.O.W.E.R NOTES SBQ 23

There's high chance of food impaction in this area as it's difficult to clean this area. More plaque and debris lead to caries.

DISCLAIMER
THIS IS COPYRIGHTED CONTENT. Unauthorized use, including screenshots, copying, misuse, reuse, or resale of any content from this app, is strictly prohibited. Our app monitors and records all screenshots and recordings. Violators will face strict legal action.

DISCLAIMER
THIS IS COPYRIGHTED CONTENT. Unauthorized use, including screenshots, copying, misuse, reuse, or resale of any content from this app, is strictly prohibited. Our app monitors and records all screenshots and recordings. Violators will face strict legal action.

DISCLAIMER
THIS IS COPYRIGHTED CONTENT. Unauthorized use, including screenshots, copying, misuse, reuse, or resale of any content from this app, is strictly prohibited. Our app monitors and records all screenshots and recordings. Violators will face strict legal action.

DISCLAIMER
THIS IS COPYRIGHTED CONTENT. Unauthorized use, including screenshots, copying, misuse, reuse, or resale of any content from this app, is strictly prohibited. Our app monitors and records all screenshots and recordings. Violators will face strict legal action.