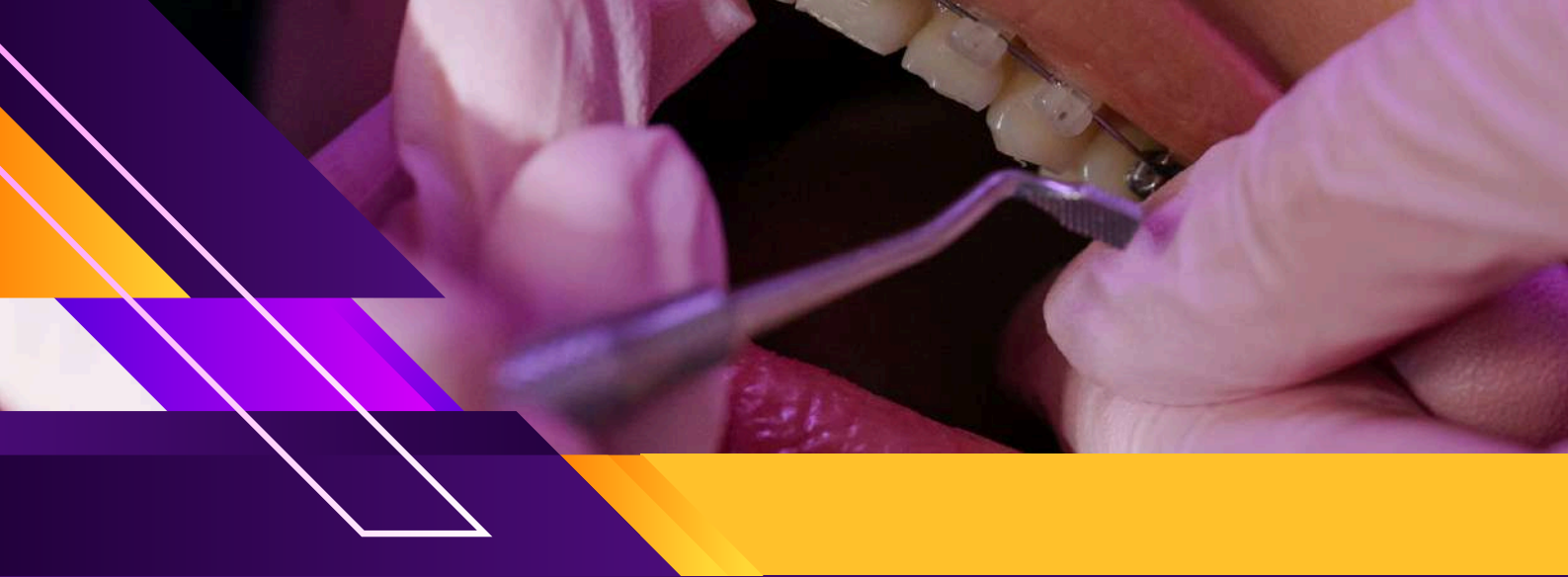



WINSPERT

WINSPERT

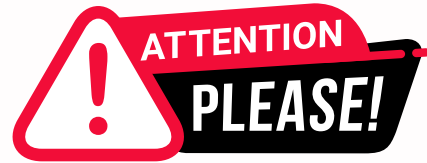P.O.W.E.R

PREPARATION OF ADC WITH WINSPERT EXPERT REVIEW

NOTES

By Dr. Jigyasa Sharma





Dear Students,

We'd like to remind you about the importance of respecting the integrity of the resources provided in our app.

Please be aware that **WINSPERT POWERNOTES ARE COPYRIGHTED CONTENT. Unauthorized use, including screenshots, copying, misuse, reuse, or resale of any content from this app, is strictly prohibited.**

Our app monitors and records all screenshots and recordings. Violators will face strict legal action.

We're committed to providing you with the best tools for your success, and we appreciate your cooperation in maintaining a fair and secure learning environment.

Thank you for your understanding and continued dedication.

Best regards,
WINSPERT TEAM

ORAL MEDICINE

SBQ 1

PATIENT HAS HIV AND HE SAID HE HAS LATENT PULMONARY TUBERCULOSIS, SHOWS YOU HIS LATEST MANTOUX TEST POSITIVE, TAKING RIFAMPICIN FOR 2 MONTHS AND HAS TO CONTINUE FOR TWO MONTHS ACCORDING TO HIS DOCTOR, VARIOUSLY 25 OR 27. NEEDS EXTRACTION.

I. The dentist decided to work with standard precautions but the nurse is apprehensive, so the dentist checked the immunisation status of staff for tb, all are vaccinated, his reason for choosing standard precautions?

- A. Mantoux test positive
- B. Staff's immunisation status
- C. 2 months since on rifampicin pt on rifampicin HIV
- D. Latent TB

II. After the procedure, how will the dentist dispose off the waste? You have already discarded the tooth as per the local regulations. How will you segregate the rest of the waste as?

- A. General
- B. Medical
- C. Hazardous
- D. Contaminated

III. The dentist had got hep-c 2 years ago, got treated for it and got an RNA test negative after 12 months, i.e. one year ago. What should he do next?

- A. Tell the pt about it before performing extraction
- B. Take clearance from medical professional for exposure based cases
- C. Keep documented 12 monthly antibody report on hep c
- D. Tell another dentist who has immunity to treat this pt
- E. Should not perform exposure prone procedure on hiv patient

IV. While doing his oral examination what will cause you to alert his general practitioner?

- A. Hairy leukoplakia
- B. Melanotic macule
- C. Lichen planus
- D. Leukoplakia

V. On what basis will you decide that the tooth will go for normal extraction or by standard aseptic non touch sterile technique (invasive)?

- A. Take x-ray before
- B. Check hiv level
- C. Viral load for last
- D. Dentists hep-c level 6 months records

DISCLAIMER

THIS IS COPYRIGHTED CONTENT. Unauthorized use, including screenshots, copying, misuse, reuse, or resale of any content from this app, is strictly prohibited. Our app monitors and records all screenshots and recordings. Violators will face strict legal action.

DISCLAIMER

THIS IS COPYRIGHTED CONTENT. Unauthorized use, including screenshots, copying, misuse, reuse, or resale of any content from this app, is strictly prohibited. Our app monitors and records all screenshots and recordings. Violators will face strict legal action.

THIS IS COPYRIGHTED CONTENT. Unauthorized use, including screenshots, copying, misuse, reuse, or resale of any content from this app, is strictly prohibited. Our app monitors and records all screenshots and recordings. Violators will face strict legal action.

DISCLAIMER

ORAL MEDICINE

P.O.W.E.R NOTES SBQ 1

- I. In case of HIV and latent tuberculosis we follow up procedures with standard precautions.

| PHASE 1-LATENT TB INFECTION | PHASE2- ACTIVE TB DISEASE |
|---|---|
| TB germs are “asleep” in your body. This phase can last for a very long time even many years. | TB germs are active and spreading. They are damaging the tissue in your body. |
| You don’t look or feel sick. Your chest x-ray is usually normal. | You usually feel sick. Your doctor will do special tests to find where TB is harming your body. |
| You can’t spread TB to other people. | If the TB germ are in your lungs, you can spread TB to other people by coughing, sneezing talking or singing. |
| Usually treated by taking one medicine (Rifampicin) for 9 months. | Treated by taking 3-4 medicine for at least 6months. |
| Standard precautions | Transmission based precautions |

How can I tell if I have latent TB infection?

A TB skin test (Mantoux) can show if you have latent TB infection. You could have latent TB infection if you have ever spent time close to someone with active TB disease (even if you didn’t know they were sick). Your health care provider will use a small needle to inject some harmless testing fluid (called “tuberculin”) under the skin on your arm.

Your health care provider **MUST** check your arm 2 or 3 days after the T skin test, even if your arm looks OK to you.

If you have a reaction to the test, it will look like a raised bump. Your health care provider will measure the size of the reaction. If there is a bump, it will go away in a few weeks.

- II. Tooth with the blood stains are categorised in medical waste.

WHO defines medical waste as waste generated by health care activities, ranging from used needles and syringes to soiled dressings, body parts, diagnostic samples, blood, chemicals, pharmaceuticals, medical devices and radioactive materials.

DISCLAIMER

THIS IS COPYRIGHTED CONTENT. Unauthorized use, including screenshots, copying, misuse, reuse, or resale of any content from this app, is strictly prohibited. Our app monitors and records all screenshots and recordings. Violators will face strict legal action.

ORAL MEDICINE

P.O.W.E.R NOTES SBQ 1

III. Reference: BBV article

Viral load monitoring and ongoing clearance for HCWs with HCV performing EPPs

HCWs who have been successfully treated for HCV infection, that is HCV RNA negative after 12 weeks after the cessation of treatment must have additional HCV RNA testing 12 months after treatment, to determine relapse or infection has occurred.

If the test performed 12 months after treatment is negative, the HCW is no longer considered to be infected with HCV and should resume the prescribed BBV test as specified in section.

If HCV RNA is detected, the HCW must be immediately restricted from carrying out EPPs until once again undergoing successful treatment as assessed by their treating doctors.

Resuming EPPs

Returning to EPP activities within 12 weeks of the treatment completion

The HCW must not return to perform EPPs less than 12 weeks after completion of the treatment.

Returning to EPP activities after 12 weeks but before 12 months since treatment completion

The HCW must provide proof of successful treatment by negative HCV RNA test at least 12 weeks after completion of treatment and clearance by their treating doctor. In addition, the HCW must have their HCV RNA tested 12 months after completion of their treatment.

Returning to EPP activities 12 months after treatment

The HCW must be HCV RNA negative and have clearance by their treating doctor.

IV. Lichen planus and leucoplakia are not linked with HIV. They are linked with alcohol and smoking.

The chief manifestation of EBV in people with HIV infection is oral hairy leucoplakia. EBV has linked to ulceration in patients with HIV infection.

OHL has rarely been reported in immunocompetent people without HIV infection and may be considered a marker of disease progression. As CD4 cell count fall in the context of HIV infection, OHL is increasingly found and it's common when the CD4 count drops below 150 cells/ μ l.

DISCLAIMER

THIS IS COPYRIGHTED CONTENT. Unauthorized use, including screenshots, copying, misuse, reuse, or resale of any content from this app, is strictly prohibited. Our app monitors and records all screenshots and recordings. Violators will face strict legal action.

DISCLAIMER

THIS IS COPYRIGHTED CONTENT. Unauthorized use, including screenshots, copying, misuse, reuse, or resale of any content from this app, is strictly prohibited. Our app monitors and records all screenshots and recordings. Violators will face strict legal action.

DISCLAIMER

THIS IS COPYRIGHTED CONTENT. Unauthorized use, including screenshots, copying, misuse, reuse, or resale of any content from this app, is strictly prohibited. Our app monitors and records all screenshots and recordings. Violators will face strict legal action.

ORAL MEDICINE

P.O.W.E.R NOTES SBQ 1

V. In dentistry aseptic non touch sterile technique (ANTT) is rarely used.

ANTT has a key part (key part of the instrument which touches the tissue) and a key site (the tissue in which the key part is operated on).

Surgical ANTT is done where the key part is not touched by any other part and the key site is not touched by any other instrument.

Usually surgical ANTT is done in kidney/cardiac/lug surgeries.

x-rays will be helpful in deciding whether the tooth requires a complicated surgery or an easy tooth extraction. Depending on that we can decide whether we can perform ANTT or not.

THIS IS COPYRIGHTED CONTENT. Unauthorized use, including screenshots, copying, misuse, reuse, or resale of any content from this app, is strictly prohibited. Our app monitors and records all screenshots and recordings. Violators will face strict legal action.

THIS IS COPYRIGHTED CONTENT. Unauthorized use, including screenshots, copying, misuse, reuse, or resale of any content from this app, is strictly prohibited. Our app monitors and records all screenshots and recordings. Violators will face strict legal action.

THIS IS COPYRIGHTED CONTENT. Unauthorized use, including screenshots, copying, misuse, reuse, or resale of any content from this app, is strictly prohibited. Our app monitors and records all screenshots and recordings. Violators will face strict legal action.

DISCLAIMER

THIS IS COPYRIGHTED CONTENT. Unauthorized use, including screenshots, copying, misuse, reuse, or resale of any content from this app, is strictly prohibited. Our app monitors and records all screenshots and recordings. Violators will face strict legal action.

DISCLAIMER
THIS IS COPYRIGHTED CONTENT. Unauthorized use, including screenshots, copying, misuse, reuse, or resale of any content from this app, is strictly prohibited. Our app monitors and records all screenshots and recordings. Violators will face strict legal action.

ORAL MEDICINE

SBQ 2

LADY 30 Y/O COMES WITH A SEVERE BURNING SENSATION IN THE TIP AND LATERAL PART OF THE TONGUE SINCE 3 MONTHS. A METALLIC TASTE AND PAIN IS INTENSE AND PRESENT THE ENTIRE DAY AND SOMETIMES DO NOT ALLOW HER TO SLEEP AT NIGHT OR WAKE HER UP. (NO PICTURE GIVEN) THERE ARE ABNORMALITIES. PATIENT IS NOT TAKING ANY MEDICATIONS AND THERE IS NO OTHER MEDICAL HISTORY.

I. What will you ask in history to help you to diagnose her condition?

- A. Something related to her psychological stress situation.
- B. Changes to toothpaste
- C. Recent changes in spices
- D. Recent dental restorations placed
- E. Any parafunctional habits

II. Diagnosis based on history and clinical findings, what will your differential diagnosis be?

- A. EM
- B. Sjögren's syndrome
- C. Candidiasis
- D. Glossodynia
- E. Lichenoid reaction

III. What will be the best test to diagnose?

- A. Smear of oral mucosa
- B. Biopsy
- C. Salivary flow test
- D. Blood profile

IV. How will you manage? What will you tell patients regarding the condition?

- A. It will improve after 3 or 6 months by itself
- B. Systemic steroids for long time
- C. You need to get a Biopsy done if it doesn't improve in 1 month
- D. Treatment with complete resolution of symptoms is possible but you may have to go through a lot of topical and systemic medications for it.
- E. The symptoms will not resolve with treatment
- F. The symptoms may improve after a few weeks or months or maybe even years. But may also not resolve.

DISCLAIMER

THIS IS COPYRIGHTED CONTENT. Unauthorized use, including screenshots, copying, misuse, reuse, or resale of any content from this app, is strictly prohibited. Our app monitors and records all screenshots and recordings. Violators will face strict legal action.

DISCLAIMER

THIS IS COPYRIGHTED CONTENT. Unauthorized use, including screenshots, copying, misuse, reuse, or resale of any content from this app, is strictly prohibited. Our app monitors and records all screenshots and recordings. Violators will face strict legal action.

THIS IS COPYRIGHTED CONTENT. Unauthorized use, including screenshots, copying, misuse, reuse, or resale of any content from this app, is strictly prohibited. Our app monitors and records all screenshots and recordings. Violators will face strict legal action.

DISCLAIMER

ORAL MEDICINE

SBQ 2

V. She comes after 6 months and all her previous symptoms were gone. Was happy about it. But there is spontaneous pain with severe pain on right side of the base of the tongue, right posterior part of the mandible and right oropharynx, the pain is worse while speaking, swallowing and yawning. You do the check-up but there are no abnormalities. Ear and oropharynx were checked by ENT and there were no problems (no picture given). Most likely diagnosis is:

- A. Trigeminal neuralgia
- B. Glossopharyngeal neuralgia
- C. Oral dysesthesia
- D. Atypical facial pain
- E. Atypical migraine

P.O.W.E.R NOTES SBQ 2

- I. Patients with BMS, psychiatric examination is always needed. About 50% of the patients presented psychiatric disorders such as anxiety, depression, obsessive or psychosomatic symptoms.
- II. BMS is also known as glossodynia. It's a chronic pain disorder characterised by continuous burning sensation that fluctuate in intensity and often are associated with taste alterations (dysgeusia) and dry mouth (xerostomia). These symptoms most often affect anterior 2/3 rd of the tongue and other oropharyngeal structures.
- III. Systemic diseases are the most likely causes of the pain in the mouth. So, they must be ruled out by doing blood test.

Diagnostic tests useful in the diagnosis of BMS

Common laboratory tests

CBC, ESR, serum iron, serum ferritin concentration, iron binding capacity, the concentration of circulating folic acid, vit B12, zinc etc, blood glucose levels, determination of serum hormone levels in women.

Other lab tests

Sialometry, specific investigation of systemic disease, allergic epicutaneous tests, fungal culture for the isolation of candida from oral mucosa.

THIS IS COPYRIGHTED CONTENT. Unauthorized use, including screenshots, copying, misuse, reuse, or resale of any content from this app, is strictly prohibited. Our app monitors and records all screenshots and recordings. Violators will face strict legal action.

DISCLAIMER

THIS IS COPYRIGHTED CONTENT. Unauthorized use, including screenshots, copying, misuse, reuse, or resale of any content from this app, is strictly prohibited. Our app monitors and records all screenshots and recordings. Violators will face strict legal action.

ORAL MEDICINE

P.O.W.E.R NOTES SBQ 2

IV. Multidisciplinary management is required. It's not an autoimmune condition to be treated with steroids. '

The major therapies used in BMS

| SYMPTOMATIC THERAPY | CORRECTION THERAPY | PSYCHOPHARMACOLOGICAL THERAPY |
|---------------------------------------|--------------------|--------------------------------------|
| Solution 3% benzydamine hydrochloride | Iron | Benzodiazepines |
| Antihistamines | Vit B12/ folate | Tricyclic antidepressants (TCA) |
| Sucralfate | Vit B1, B2 B6 | Monoamine oxidase inhibitors (MAOIs) |
| Lidocaine | Estrogen therapy | Serotonergic antidepressants |
| Capsaicin | Neuroleptics | Antipsychotics |
| Salivary substitutes | Topical antifungal | Hypnosis |

With the above treatment options, the symptoms may or may not resolve.

V. Glossopharyngeal nerve (or cranial nerve IX or simply CN IX).

Field of innervation:

Afferent: posterior one-third of tongue, palatine tonsils, oropharynx, mucosa of the middle ear, auditory tube and the mastoid air cells, carotid body, taste

Efferent: parotid gland, stylopharyngeus muscle, superior pharyngeal constrictor muscle

Branches:

Tympanic nerve

Carotid sinus nerve

Pharyngeal nerves

Muscular branch to stylopharyngeus

Tonsillar branch

Lingual nerves

Mnemonic: This Could Pull Me To Love

Glossopharyngeal neuralgia (GPN)

is a rare condition that affects the glossopharyngeal nerve, which lies deep within the neck. GPN causes episodes of severe stabbing pain in the throat, tongue and ears. These excruciating bouts last anywhere from several seconds to a few minutes. Pain is worse while speaking, swallowing and yawning.

DISCLAIMER

THIS IS COPYRIGHTED CONTENT. Unauthorized use, including screenshots, copying, misuse, reuse, or resale of any content from this app, is strictly prohibited. Our app monitors and records all screenshots and recordings. Violators will face strict legal action.

DISCLAIMER

THIS IS COPYRIGHTED CONTENT. Unauthorized use, including screenshots, copying, misuse, reuse, or resale of any content from this app, is strictly prohibited. Our app monitors and records all screenshots and recordings. Violators will face strict legal action.

THIS IS COPYRIGHTED CONTENT. Unauthorized use, including screenshots, copying, misuse, reuse, or resale of any content from this app, is strictly prohibited. Our app monitors and records all screenshots and recordings. Violators will face strict legal action.

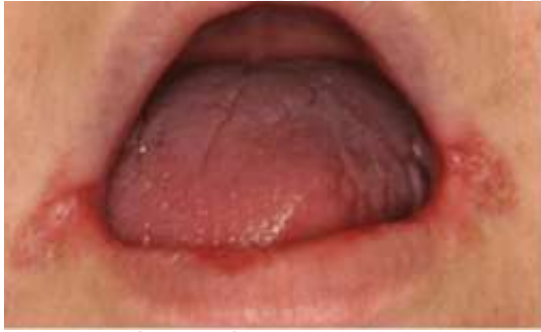DISCLAIMER

ORAL MEDICINE

SBQ 3

ANGULAR CHEILITIS CASE:

PATIENT USES THE DENTURE 24 HOURS PER DAY. PICTURE GIVEN WITH CLOSED MOUTH SHOWING ANGULAR CHEILITIS. HE WENT TO GP & WAS DIAGNOSED TO BE HAVING ANGULAR CHEILITIS & HE WAS GIVEN VASELINE WHICH DIDN'T WORK. THE PATIENT COMES TO YOU.



I. What is the most likely diagnosis?

- A. Angular cheilitis
- B. Candidiasis
- C. Herpes labialis
- D. Erythema multiforme

II. How will you manage this patient?

- A. Clotrimazole 1% twice daily for 14 days & after
- B. Instructions on denture care and oral hygiene
- C. Acyclovir
- D. Antibiotics

III. At the first instinct what will be helpful to diagnose it? (angular Cheilitis)

- A. Swab from lesion
- B. Swab from denture
- C. History and examination
- D. Culture and sensitivity
- E. Biopsy

THIS IS COPYRIGHTED CONTENT. Unauthorized use, including screenshots, copying, misuse, reuse, or resale of any content from this app, is strictly prohibited. Our app monitors and records all screenshots and recordings. Violators will face strict legal action.

DISCLAIMER

THIS IS COPYRIGHTED CONTENT. Unauthorized use, including screenshots, copying, misuse, reuse, or resale of any content from this app, is strictly prohibited. Our app monitors and records all screenshots and recordings. Violators will face strict legal action.

THIS IS COPYRIGHTED CONTENT. Unauthorized use, including screenshots, copying, misuse, reuse, or resale of any content from this app, is strictly prohibited. Our app monitors and records all screenshots and recordings. Violators will face strict legal action.

THIS IS COPYRIGHTED CONTENT. Unauthorized use, including screenshots, copying, misuse, reuse, or resale of any content from this app, is strictly prohibited. Our app monitors and records all screenshots and recordings. Violators will face strict legal action.

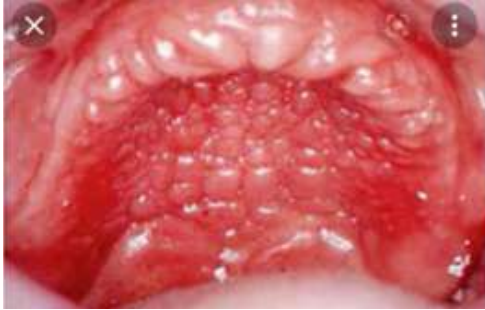DISCLAIMER
THIS IS COPYRIGHTED CONTENT. Unauthorized use, including screenshots, copying, misuse, reuse, or resale of any content from this app, is strictly prohibited. Our app monitors and records all screenshots and recordings. Violators will face strict legal action.

DISCLAIMER

THIS IS COPYRIGHTED CONTENT. Unauthorized use, including screenshots, copying, misuse, reuse, or resale of any content from this app, is strictly prohibited. Our app monitors and records all screenshots and recordings. Violators will face strict legal action.

ORAL MEDICINE

SBQ 3



IV. Picture now given separately for this question. Most likely diagnosis (almost similar image)

- A. Idiopathic hypertrophic stomatitis
- B. Acute hypertrophic
- C. Chronic atrophic denture stomatitis
- D. Chronic hyperplastic/ hypertrophic stomatitis
- E. Acute papillary hyperplasia
- F. Chronic inflammatory papillary hyperplasia

V. How would you initially treat this condition (was asking palatal lesion)

- A. Oral hygiene and denture hygiene
- B. Antifungals
- C. Antibiotics
- D. Referrals to make a new denture

VI. Why is it important to treat his IPH/ DENTURE STOMATITIS?

- A. It can become neoplastic
- B. It can keep growing in size and displace the denture
- C. It can become Supra Infected and painful
- D. It is "impossible" to gain retention for new dentures with it being present
- E. It can reinfect angular cheilitis

VII. Regarding the denture hygiene, What is contraindicated in cleaning CrCo denture?

- A. Sodium hypochlorite
- B. White vinegar

THIS IS COPYRIGHTED CONTENT. Unauthorized use, including screenshots, copying, misuse, reuse, or resale of any content from this app, is strictly prohibited. Our app monitors and records all screenshots and recordings. Violators will face strict legal action.

DISCLAIMER
THIS IS COPYRIGHTED CONTENT. Unauthorized use, including screenshots, copying, misuse, reuse, or resale of any content from this app, is strictly prohibited. Our app monitors and records all screenshots and recordings. Violators will face strict legal action.

DISCLAIMER

THIS IS COPYRIGHTED CONTENT. Unauthorized use, including screenshots, copying, misuse, reuse, or resale of any content from this app, is strictly prohibited. Our app monitors and records all screenshots and recordings. Violators will face strict legal action.

THIS IS COPYRIGHTED CONTENT. Unauthorized use, including screenshots, copying, misuse, reuse, or resale of any content from this app, is strictly prohibited. Our app monitors and records all screenshots and recordings. Violators will face strict legal action.

DISCLAIMER

ORAL MEDICINE

P.O.W.E.R NOTES SBQ 3

I. Angular cheilitis is a common skin condition affecting the corners of your mouth. It leads to painful, cracked sores. This condition usually goes away with special skin ointments, medication or diet changes. Angular cheilitis is an oral candidial infection involving either or both the commissures of the mouth. It is a mixed microbial infection caused by *Candida albicans* and *Staphylococcus aureus*.

II. Reference: TG

Antifungal therapy for angular cheilitis

Treat angular cheilitis with a topical antifungal cream. Use:

- Clotrimazole 1% cream topically to the angle of the mouth, twice daily at least for 14 days; continue treatment for 14 days after symptoms resolve
- Miconazole 2% cream topically to the angle of the mouth, twice daily at least for 14 days; continue treatment for 14 days after symptoms resolve

A mild topical corticosteroid can be used in addition to the topical antifungal, to treat the associated inflammatory dermatitis. Use:

Hydrocortisone 1% cream topically to the angles of the mouth, twice daily until inflammation subsides.

III. Proper history and examination will be helpful in diagnosis. And then you can confirm the diagnosis.

IV. Newton's classification of denture stomatitis

- Type 1- localised inflammation
- Type 2- diffuse erythema (redness) without hyperplasia
- Type 3- inflammation, erythema and involves papillary hyperplasia

V. The initial management of inflammatory papillary hyperplasia is to maintain oral hygiene and denture hygiene. Due to poor oral hygiene, more likely to get fungal infection.

Reference: TG

Advise the patient to optimise denture hygiene and to remove the denture at night, clean them, then store them dry overnight.

Dental review to assess the fit of dentures.

If symptoms do not resolve in 1 month of oral and denture hygiene, use topical antifungal therapy for oral candidiasis.

VI. IPH will change the denture bearing area, its size and shape. IPH is non neoplastic. We can treat it with tissue conditioners, denture re-liners, antifungals, surgical correction.

VII. Sodium hypochlorite is contraindicated in Co-Cr dentures. Because metal based RPD's get corroded with Sodium hypochlorite. Chlorhexidine can be used to clean metal-based dentures.

DISCLAIMER

THIS IS COPYRIGHTED CONTENT. Unauthorized use, including screenshots, copying, misuse, reuse, or resale of any content from this app, is strictly prohibited. Our app monitors and records all screenshots and recordings. Violators will face strict legal action.

ORAL MEDICINE

SBQ 4

PREGNANT LADY WITH GINGIVITIS CASE:

PREGNANT WOMAN WITH HISTORY OF MISCARRIAGES & HAS HYPERTENSION & ASTHMA.

I. Which period is earliest you can take x-rays according to the latest Australian radiation guidelines for X-ray?

- A. First
- B. Second
- C. Third trimester
- D. Postpartum
- E. No preference for taking radiographs in pregnancy (this was an option in a centre. We are not sure)

II. Which systemic condition of her's concerns you to talk to her medical practitioner first before you proceed with the extraction?

- A. Hypertension
- B. Asthma
- C. Gestation diabetes
- D. Gestational hypertension (in my centre I had this others didn't)

III. If you were to give a presentation on important of dental health in pregnancy. Which topic would be most relevant for discussion as per this patient's case?

- A. Meet your dentist to check for gum disease.
- B. Pregnancy causes caries
- C. Periodontal health in pregnancy
- D. Hypertension causes preterm birth

THIS IS COPYRIGHTED
CONTENT. Unauthorized use,
including screenshots,
copying, misuse, reuse, or
resale of any content from
this app, is strictly prohibited.
Our app monitors and records
all screenshots and
recordings. Violators will face
strict legal action.

DISCLAIMER

THIS IS COPYRIGHTED CONTENT. Unauthorized use, including screenshots, copying, misuse, reuse, or resale of any content from this app, is strictly prohibited. Our app monitors and records all screenshots and recordings. Violators will face strict legal action.

THIS IS COPYRIGHTED
CONTENT. Unauthorized use,
including screenshots,
copying, misuse, reuse, or
resale of any content from
this app, is strictly prohibited.
Our app monitors and records
all screenshots and
recordings. Violators will face
strict legal action.

THIS IS COPYRIGHTED
CONTENT. Unauthorized use,
including screenshots,
copying, misuse, reuse, or
resale of any content from
this app, is strictly prohibited.
Our app monitors and records
all screenshots and
recordings. Violators will face
strict legal action.

DISCLAIMER
THIS IS COPYRIGHTED CONTENT. Unauthorized use, including screenshots, copying, misuse, reuse, or resale of any content from this app, is strictly prohibited. Our app monitors and records all screenshots and recordings. Violators will face strict legal action.

ORAL MEDICINE

P.O.W.E.R NOTES SBQ 4

- I. Whenever you need to take an x-ray it's allowed to take x-ray in pregnancy. There's no contraindication for that. But always try to take only when it's actually needed.
- II. Preeclampsia is associated with premature births and miscarriages. This lady has a history of miscarriages therefore, the BP is now under controlled. Their BP is measured several times in a day. Gestational diabetes is usually monitored. Systemic corticosteroids might have been given to control asthma. Steroids can cause adrenal insufficiency and adrenal crisis in a pregnant woman. It can cause risk to both mother and the foetus. In case of that u need to get the steroid dose monitored.
- III. Periodontal health has an impact on pregnancy. If it's not maintained properly there's a risk of developing preeclampsia and premature birth. In the question it specifically mentioned "importance of dental health in pregnancy". So, option (D) is ruled out.

THIS IS COPYRIGHTED CONTENT. Unauthorized use, including screenshots, copying, misuse, reuse, or resale of any content from this app, is strictly prohibited. Our app monitors and records all screenshots and recordings. Violators will face strict legal action.

DISCLAIMER

THIS IS COPYRIGHTED CONTENT. Unauthorized use, including screenshots, copying, misuse, reuse, or resale of any content from this app, is strictly prohibited. Our app monitors and records all screenshots and recordings. Violators will face strict legal action.

THIS IS COPYRIGHTED CONTENT. Unauthorized use, including screenshots, copying, misuse, reuse, or resale of any content from this app, is strictly prohibited.

Our app monitors and records all screenshots and recordings. Violators will face strict legal action.

THIS IS COPYRIGHTED CONTENT. Unauthorized use, including screenshots, copying, misuse, reuse, or resale of any content from this app, is strictly prohibited. Our app monitors and records all screenshots and recordings. Violators will face strict legal action.

WINSPERT
P.O.W.E.R
NOTES

DISCLAIMER
THIS IS COPYRIGHTED CONTENT. Unauthorized use, including screenshots, copying, misuse, reuse, or resale of any content from this app, is strictly prohibited. Our app monitors and records all screenshots and recordings. Violators will face strict legal action.

DISCLAIMER

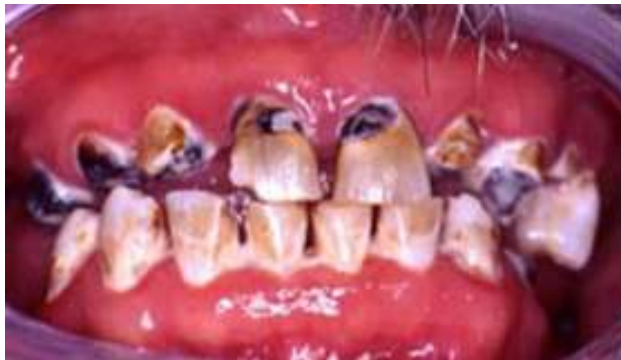THIS IS COPYRIGHTED CONTENT. Unauthorized use, including screenshots, copying, misuse, reuse, or resale of any content from this app, is strictly prohibited. Our app monitors and records all screenshots and recordings. Violators will face strict legal action.

ORAL MEDICINE

SBQ 5

RADIATION CARIES CASE (ODELL CASE)

PATIENT WITH GENERALISED CARIES DUE TO RADIOTHERAPY TAKEN 5YEARS AGO. A MAN IN HIS 40'S COMES TO YOUR CLINIC COMPLAINING "MY TEETH ARE ROTTEN" HE HAS UNDERGONE RADIOTHERAPY DUE TO HIS ORAL SCC ON THE BUCCAL OF POSTERIOR MOLAR 5YEARS AGO. PICTURE GIVEN ALL TEETH ARE DECAYED BLACK CARIES IS SEEN ALL OVER THE DENTITION, IN LOWER ARCH THERE WERE ONLY ROOT STUMPS LEFT WITH BLACK SPOTS ALL OVER, SOME MISSING AND BROKEN TEETH ARE ALSO SEEN. OBVIOUS DRY MOUTH.



I. What is it linked to? (what is the most significant factor that is attributed to his present caries status?)

- A. Dose he received from radiotherapy
- B. The medications used for the treatment
- C. Amount of existing caries in the mouth (His previous carious experience)
- D. The patient wasn't able to keep up with the fluoride.
- E. Combination of chemotherapy and Radiotherapy.

II. How to restore his front upper teeth?

- A. RMGIC
- B. Resin composite/ Compomer (in few centres)
- C. Porcelain
- D. GIC
- E. Veneer

III. He complains of dry mouth. You found out that it took 30seconds (or more) before the saliva is produced from the orifices of his minor salivary gland. What test will also help that about his saliva?

- A. Stimulated salivary flow test (5ml/ 5min)
- B. Low buffering capacity of saliva
- C. Saliva ph of 6.8 and above
- D. High buffering capacity of saliva

DISCLAIMER

THIS IS COPYRIGHTED CONTENT. Unauthorized use, including screenshots, copying, misuse, reuse, or resale of any content from this app, is strictly prohibited. Our app monitors and records all screenshots and recordings. Violators will face strict legal action.

DISCLAIMER

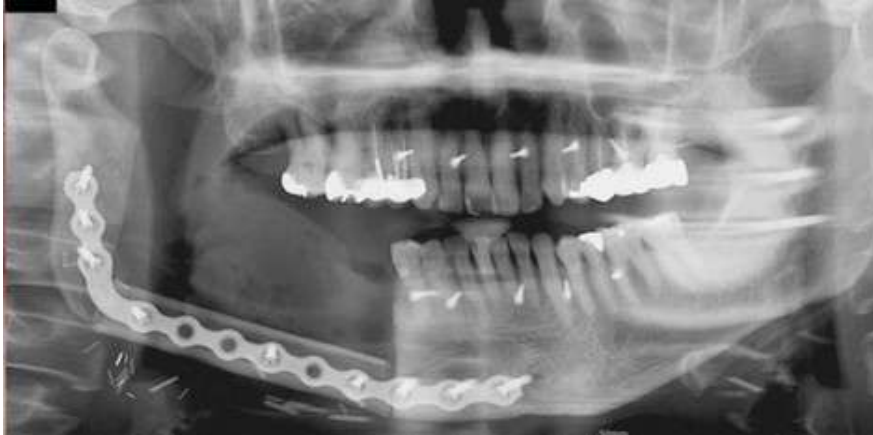THIS IS COPYRIGHTED CONTENT. Unauthorized use, including screenshots, copying, misuse, reuse, or resale of any content from this app, is strictly prohibited. Our app monitors and records all screenshots and recordings. Violators will face strict legal action.

THIS IS COPYRIGHTED CONTENT. Unauthorized use, including screenshots, copying, misuse, reuse, or resale of any content from this app, is strictly prohibited. Our app monitors and records all screenshots and recordings. Violators will face strict legal action.

DISCLAIMER

ORAL MEDICINE

SBQ 5



IV. Opg given with a material placed on the right side of the mandible with screws and plates. Asking the radiopaque circular objects on the distal superior left side (near the 28)

- A. Ghost images of screws and plates
- B. Antral calcification
- C. Salivary gland stones
- D. Developer artifacts

P.O.W.E.R NOTES SBQ 5

I. Reference:

The full curative dose for most head and neck cancers is 60-65Gy. But mild salivary gland damage can be detected after only 4Gy, and severe permanent damage occurs with dose above 30Gy to the glands. Some protection is provided by the fractionation, delivering the total dose in small daily amounts of fractions, usually 2Gy each weekday for 6 weeks. Fractionation allows some recovery time between treatments, thus reducing toxicity to normal tissues.

However, if the salivary glands lie in the path of the beam as it passes from skin to cancer fractionation offers insufficient protection and complete dry mouth will occur during treatment, with partial and slow recovery afterwards.

II. Resin composite is the best restorative material for radiation caries, class v, NCCL. Compomer is the 2nd best choice. RMGIC is the choice of restorative material for primary teeth and root caries.

III. According to the latest articles the sequence of salivary tests is

- Step 1: Resting Flow Rate
- Step 2: Salivary consistency
- Step 3: Salivary PH of resting saliva
- Step 4: Testing Quantity - Stimulated Saliva
- Step 5: Testing pH - Stimulated Saliva
- Step 6: Testing Buffering - Stimulated Saliva

As per this sequence answer should be (C) which is Testing the PH of Resting

Saliva

THIS IS COPYRIGHTED CONTENT. Unauthorized use, including screenshots, copying, misuse, reuse, or resale of any content from this app, is strictly prohibited. Our app monitors and records all screenshots and recordings. Violators will face strict legal action.

THIS IS COPYRIGHTED CONTENT. Unauthorized use, including screenshots, copying, misuse, reuse, or resale of any content from this app, is strictly prohibited. Our app monitors and records all screenshots and recordings. Violators will face strict legal action.

DISCLAIMER
THIS IS COPYRIGHTED CONTENT. Unauthorized use, including screenshots, copying, misuse, reuse, or resale of any content from this app, is strictly prohibited. Our app monitors and records all screenshots and recordings. Violators will face strict legal action.

ORAL MEDICINE

P.O.W.E.R NOTES SBQ 5

IV. A ghost image in an orthopantomogram (OPG), is a common artefact that can complicate the interpretation of the image. These ghost images are typically faint, mirror-image duplicates of structures that appear on the opposite side of the X-ray.

Causes of Ghost Images in OPG:

- **High-Density Objects:** Ghost images often arise from high-density objects like metal dental restorations, jewellery, or hearing aids. These objects can block X-rays, creating shadows or reflections that appear as ghost images on the opposite side of the radiograph.
- **Patient Positioning:** Incorrect positioning of the patient can lead to distortions and ghost images. If the patient is not aligned properly, certain anatomical structures can be projected twice, once as the real image and again as a ghost image.
- **Technical Factors:** Issues with the X-ray machine itself, such as the alignment of the X-ray beam or the rotation of the X-ray source and detector, can also produce ghost images.

GHOST IMAGE

- Opposite side
- Higher up in position
- Larger in size
- Blurred mode in opposite dimension

THIS IS COPYRIGHTED CONTENT. Unauthorized use, including screenshots, copying, misuse, reuse, or resale of any content from this app, is strictly prohibited. Our app monitors and records all screenshots and recordings. Violators will face strict legal action.

DISCLAIMER

THIS IS COPYRIGHTED CONTENT. Unauthorized use, including screenshots, copying, misuse, reuse, or resale of any content from this app, is strictly prohibited. Our app monitors and records all screenshots and recordings. Violators will face strict legal action.

DISCLAIMER
THIS IS COPYRIGHTED CONTENT. Unauthorized use, including screenshots, copying, misuse, reuse, or resale of any content from this app, is strictly prohibited. Our app monitors and records all screenshots and recordings. Violators will face strict legal action.

DISCLAIMER
THIS IS COPYRIGHTED CONTENT. Unauthorized use, including screenshots, copying, misuse, reuse, or resale of any content from this app, is strictly prohibited. Our app monitors and records all screenshots and recordings. Violators will face strict legal action.

ORAL MEDICINE

SBQ 6

PATIENT IS ON ANTIDEPRESSANTS, HE HAS TAKEN A DIVORCE AND IS NOW FIGHTING FOR CHILD'S CUSTODY. HE IS ALSO HAVING FINANCIAL CONSTRAINTS & IS PLANNING TO SWITCH HIS ANTIDEPRESSANTS TO SOME HOLISTIC APPROACH AS THE CURRENT MEDICATIONS GIVES HIM BAD REFLUX AND HIS LIFE IS BEING AFFECTED AND IMPAIRED BY IT. HE HAS BRUXISM.

I. He asked you on advice about painkillers What would your answer be?

- A. All pharmacological prescriptions for pain is prescribed by GP
- B. Just refer to GP
- C. Tell him pain is a vast area, it might be caused by different reasons and send him to GP
- D. Show him empathy, prescribe him only dental related solutions and send him for medical referral for further medications.

II. Which denture would you give him?

- A. Cobalt chromium framework & acrylic base
- B. Acrylic denture with a metal clasp
- C. Implant supported RPD
- D. All acrylic RPD

III. Which material is contraindication to cleaning Cobalt chromium denture?

- A. Hypochlorite
- B. Vinegar
- C. Chlorhexidine
- D. Hydrogen peroxide

IV. Which analgesic cannot be given to him?

- A. Ibuprofen
- B. Paracetamol
- C. Codeine
- D. Oxycodone

THIS IS COPYRIGHTED CONTENT. Unauthorized use, including screenshots, copying, misuse, reuse, or resale of any content from this app, is strictly prohibited. Our app monitors and records all screenshots and recordings. Violators will face strict legal action.

DISCLAIMER

THIS IS COPYRIGHTED CONTENT. Unauthorized use, including screenshots, copying, misuse, reuse, or resale of any content from this app, is strictly prohibited. Our app monitors and records all screenshots and recordings. Violators will face strict legal action.

DISCLAIMER
THIS IS COPYRIGHTED CONTENT. Unauthorized use, including screenshots, copying, misuse, reuse, or resale of any content from this app, is strictly prohibited. Our app monitors and records all screenshots and recordings. Violators will face strict legal action.

DISCLAIMER

THIS IS COPYRIGHTED CONTENT. Unauthorized use, including screenshots, copying, misuse, reuse, or resale of any content from this app, is strictly prohibited. Our app monitors and records all screenshots and recordings. Violators will face strict legal action.

ORAL MEDICINE

P.O.W.E.R NOTES SBQ 6

- I. Analgesics can be prescribed by both dental and medical practitioners. So, option (A) is ruled out. Cannot refer the patient to the GP without saying anything. So, option (B) is ruled out. Explaining about pain with many jargons will not be helpful for the patient. So, option (C) is ruled out. Therefore, it's good to show empathy and do dental management and refer the patient for the GP for the medical management.
- II. Even though the patient has financial constraints, we need to give him a treatment plan within those constraints. Patient is taking many medical treatments which also requires a financial commitment. This indicates that the patient is not very poor and can afford getting the dental treatment.
Implant supported RPD are not suitable for a patient who has financial constraints. And implants are contraindicated in bruxism. Option (C) is ruled out.
All acrylic RPD and acrylic denture with metal clasp would not be an ideal outcome as he's a bruxer, therefore, he needs a rigid RPD which can withstand the excessive grinding forces. So, options (B) and (D) are ruled out.
Considering the cost and the benefit ratio, option (A) is the best answer.
- III. Hypochlorite leads to the corrosion of the Co-Cr denture. Vinegar, CHX and H₂O₂ can be used to clean Co-Cr denture.
- IV. **Reference: TG pg. no.53-54**
Immediate release opioids commonly used for acute pain management in dentistry include **oxycodone**, **tramadol** and **tapentadol**.

Codeine is no longer recommended for the pain management because its use is associated with more harm than benefit. There is no good evidence that codeine (even in doses of 60mg) is any more effective than PCM or NSAIDs or improves analgesia when combine with PCM or an NSAID. Codeine containing preparations have been abused. Codeine is a prodrug that is metabolised to morphine. Some patients experience either minimal analgesic effect or morphine toxicity. There's no contraindication to NSAIDs in his case. The reflux is due to the side effect of the medication that he's taking and not because of any active gastric ulcer/ GERD.

So, there's no contraindication to NSAIDs, PCM and oxycodone, but codeine is contraindicated for it's uses in dentistry at the present.

including screenshots,
copying, misuse, reuse, or
resale of any content from
this app, is strictly prohibited.
Our app monitors and records
all screenshots and
recordings. Violators will face
strict legal action.

DISCLAIMER

THIS IS COPYRIGHTED CONTENT. Unauthorized use, including screenshots, copying, misuse, reuse, or resale of any content from this app, is strictly prohibited. Our app monitors and records all screenshots and recordings. Violators will face strict legal action.

DISCLAIMER

THIS IS COPYRIGHTED CONTENT. Unauthorized use, including screenshots, copying, misuse, reuse, or resale of any content from this app, is strictly prohibited. Our app monitors and records all screenshots and recordings. Violators will face strict legal action.

THIS IS COPYRIGHTED CONTENT. Unauthorized use, including screenshots, copying, misuse, reuse, or resale of any content from this app, is strictly prohibited. Our app monitors and records all screenshots and recordings. Violators will face strict legal action.

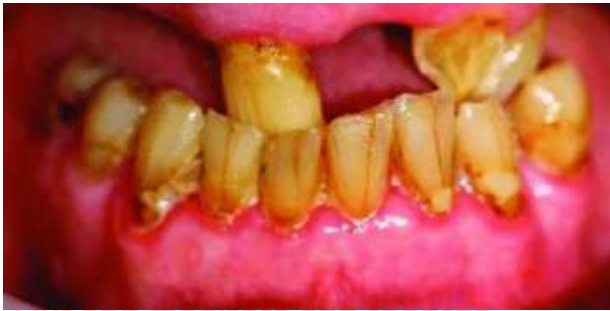DISCLAIMER

ORAL MEDICINE

SBQ 7

MR. ANTONIO, 74 YEARS OLD, WHO HAS ITALIAN BACKGROUND, WHO CAN UNDERSTAND ENGLISH FAIRLY, AFTER HIS WIFE PASSED AWAY, MOVED TO HIS DAUGHTER ANGELA'S HOUSE THAT IS NEAR TO YOUR DENTAL CLINIC. HE CAME TO YOUR PRACTICE WITH HIS DAUGHTER. HIS DAUGHTER IS COMPLAINING THAT HER FATHER IS NOT EATING WELL FOR THE LAST 3 DAYS AND IS LOSING WEIGHT.

PATIENT IS HYPERTENSIVE, TAKING ANTIHYPERTENSIVES AND ANTIDEPRESSANTS, AND ALSO HAS A HISTORY OF DIABETES. HIS DAUGHTER SAYS LAST TIME HIS DOCTOR SAID HIS DIABETES WAS UNDER CONTROL.



I. As the complaint mentioned in the history that he is not eating well. What is the first question you will ask him to know more about his complaint?

- A. Ask him if it hurts while swallowing
- B. Ask him why is he not eating well
- C. Ask him is his teeth hurt when having cold
- D. Ask him if his teeth hurt while chewing
- E. Ask him about the dental and medical history

II. What do you think is the cause of his complaint which puts him in the category of severe malnutrition? (Clinical picture given, badly broken 12 and only few anteriors remaining in the upper, no posterior teeth. Lower has more teeth but has poor oral hygiene in general)

- A. Poor oral hygiene
- B. Insufficient occlusal contacts
- C. Perio disease

THIS IS COPYRIGHTED CONTENT. Unauthorized use, including screenshots, copying, misuse, reuse, or resale of any content from this app, is strictly prohibited. Our app monitors and records all screenshots and recordings. Violators will face strict legal action.

DISCLAIMER

THIS IS COPYRIGHTED CONTENT. Unauthorized use, including screenshots, copying, misuse, reuse, or resale of any content from this app, is strictly prohibited. Our app monitors and records all screenshots and recordings. Violators will face strict legal action.

DISCLAIMER

THIS IS COPYRIGHTED CONTENT. Unauthorized use, including screenshots, copying, misuse, reuse, or resale of any content from this app, is strictly prohibited. Our app monitors and records all screenshots and recordings. Violators will face strict legal action.

THIS IS COPYRIGHTED CONTENT. Unauthorized use, including screenshots, copying, misuse, reuse, or resale of any content from this app, is strictly prohibited. Our app monitors and records all screenshots and recordings. Violators will face strict legal action.

DISCLAIMER

ORAL MEDICINE

SBQ 7

III. Insufficient number of teeth Inflammation of gingival margins Because of his drugs. Daughter wants to extract 12 on the same day as she has no time to bring her father to the dentist due to her work as she is really busy. You heard her talking to her dad in Italian very loudly and sounds very demanding, overpowering and aggressive. What should you do to manage the situation immediately?

- A. Give brochures and information to daughter regarding treatment options.
- B. Send daughter outside and ask her to wait till you finish your further investigation
- C. Tell his daughter that there are other options that are more appropriate.
- D. Go ahead with the extractions
- E. Tell her that you don't like her attitude
- F. Tell her that Mr. Antonio needs to make an informed decision after you complete the examination

IV. Antonio agrees with daughter and requests to do whatever his daughter says because he doesn't want her to get in trouble at her work for getting late. You are concerned. He doesn't understand all your questions properly and you are uncomfortable after the whole shouting scene of the daughter and you thought the daughter did not have literacy for medical treatment. What will you do to ensure (or maybe how will you ensure) that the patient meets his treatment needs?

- A. Talk with his daughter over the phone and discuss treatment plan.
- B. Arrange an interpreter/ translator for the patient when Angela is not present.
- C. Talk with him regarding only around the treatment that Angela understands and wants for him.
- D. Provide him brochure explaining advantages and disadvantage of all the treatment options

THIS IS COPYRIGHTED
CONTENT. Unauthorized use,
including screenshots,
copying, misuse, reuse, or
resale of any content from
this app, is strictly prohibited.
Our app monitors and records
all screenshots and
recordings. Violators will face
strict legal action.

DISCLAIMER

THIS IS COPYRIGHTED CONTENT. Unauthorized use, including screenshots, copying, misuse, reuse, or resale of any content from this app, is strictly prohibited. Our app monitors and records all screenshots and recordings. Violators will face strict legal action.

DISCLAIMER
THIS IS COPYRIGHTED CONTENT. Unauthorized use, including screenshots, copying, misuse, reuse, or resale of any content from this app, is strictly prohibited. Our app monitors and records all screenshots and recordings. Violators will face strict legal action.

ORAL MEDICINE

P.O.W.E.R NOTES SBQ 7

- I. Should always ask open ended questions from the patient rather than asking the leading questions.
Options (A), (C) and (D) are ruled out as they are leading questions. Dental and medical hx come after addressing the chief complaint.
- II. According to the given picture the occlusal contacts are insufficient for him to chew food which puts him in the category of severe malnutrition. There's a requirement of replacing the missing teeth.
- III. As a healthcare professional you can't involve in their personal conversations and complicate the situation. Mr. Antonio has the full capacity to give the consent therefore, it's not required to educate his daughter about the treatment plan. Always try to make the patient understand about the procedure and get the informed consent.
- IV. Family members are not taken as the translators when the patient doesn't understand the language. According to COC we must arrange a translator for the patient.

DISCLAIMER

THIS IS COPYRIGHTED CONTENT. Unauthorized use, including screenshots, copying, misuse, reuse, or resale of any content from this app, is strictly prohibited. Our app monitors and records all screenshots and recordings. Violators will face strict legal action.

THIS IS COPYRIGHTED CONTENT. Unauthorized use, including screenshots, copying, misuse, reuse, or resale of any content from this app, is strictly prohibited. Our app monitors and records all screenshots and recordings. Violators will face strict legal action.

DISCLAIMER

THIS IS COPYRIGHTED CONTENT. Unauthorized use, including screenshots, copying, misuse, reuse, or resale of any content from this app, is strictly prohibited. Our app monitors and records all screenshots and recordings. Violators will face strict legal action.

THIS IS COPYRIGHTED CONTENT. Unauthorized use, including screenshots, copying, misuse, reuse, or resale of any content from this app, is strictly prohibited. Our app monitors and records all screenshots and recordings. Violators will face strict legal action.

DISCLAIMER
THIS IS COPYRIGHTED CONTENT. Unauthorized use, including screenshots, copying, misuse, reuse, or resale of any content from this app, is strictly prohibited. Our app monitors and records all screenshots and recordings. Violators will face strict legal action.

ORAL MEDICINE

SBQ 8

MR. X, 72YR OLD LIVES IN A NURSING HOME. HE TAKES A CHOLINESTERASE INHIBITOR FOR HIS DEMENTIA, HAS MILD TYPE 2 DIABETES, TAKES SALBUTAMOL FOR ASTHMA, TAKES ALENDRONATE FOR HIS OSTEOPOROSIS. HIS WIFE IS THE PERSON WHO IS RESPONSIBLE FOR CONSENT AND HE HAS POOR ORAL HYGIENE BUT ALL HIS TEETH ARE IN GOOD CONDITION (ALL THIS WAS MENTIONED). DIAGRAMMATIC REPRESENTATION OF THE TEETH PICTURE WAS GIVEN AND IN THAT BOTH UPPER AND LOWER LEFT POSTERIOIRS WERE MISSING. HIS WIFE COMES THREE TIMES A WEEK TO VISIT HIM AND IS WORRIED ABOUT THE GENERAL HEALTH OF HER HUSBAND. HE HAS POOR ORAL HYGIENE.

DIAGRAM: UPPER 6-4 LOWER 6-4

I. His wife was very much worried about his nutrition and says missing teeth affects his nutrition. What would you suggest to her?

- A. Missing teeth won't affect his general health
- B. He has stable remaining dentition to allow him adequate nutrition
- C. It may give him tmj problem

II. She is concerned about his oral health and says the nurse keeps changing, asking what will you do to maintain his dentition for "as long as possible"?

- A. Regular debridement and oral hygiene maintenance
- B. Find a nurse who will be responsible for his overall oral health or hygiene
- C. Educate the patient about oral hygiene

III. His wife is very much interested in implants. Says it will give him psychological benefit. What is the first thing you will consider regarding implants for this specific patient?

- A. Age
- B. Poor plaque control
- C. Dry mouth
- D. Dementia
- E. Osteoporosis
- F. Diabetes

IV. Patient is having root caries in multiple teeth. He is apprehensive and cannot sit for longer. What could be the appropriate management in this patient?

- A. High speed rotary with composite
- B. Excavating with hand instrument and GIC
- C. Cleaning with pumice and fluoride varnish

V. You see his saliva is less than 0.25ml/min, unstimulated. Nurse tells you he gets up at night 3-4 times to drink water. What is the reason for all this?

- A. Acetylcholinesterase
- B. Salbutamol
- C. Mild Diabetes

DISCLAIMER

THIS IS COPYRIGHTED CONTENT. Unauthorized use, including screenshots, copying, misuse, reuse, or resale of any content from this app, is strictly prohibited. Our app monitors and records all screenshots and recordings. Violators will face strict legal action.

DISCLAIMER

THIS IS COPYRIGHTED CONTENT. Unauthorized use, including screenshots, copying, misuse, reuse, or resale of any content from this app, is strictly prohibited. Our app monitors and records all screenshots and recordings. Violators will face strict legal action.

THIS IS COPYRIGHTED CONTENT. Unauthorized use, including screenshots, copying, misuse, reuse, or resale of any content from this app, is strictly prohibited. Our app monitors and records all screenshots and recordings. Violators will face strict legal action.

DISCLAIMER

ORAL MEDICINE

P.O.W.E.R NOTES SBQ 8

- I. In both upper and lower dental arches, posterior teeth are missing but the patient has 4-6 teeth in both upper and lower dental arches which is adequate for him to chew food properly. If teeth are present up to premolars, then teeth area taking enough load and the TMJ may not get affected. Option (C) can be a true statement but it doesn't address the patient's concern. Therefore, he has stable remaining dentition to allow him adequate nutrition.
- II. Nurses do get changed every time therefore, we can't depend on the nurse. So, it's good to conduct a seminar in a residential care and train all the nurses who are responsible for these types of patients. So, it will be helpful to maintain the regular oral hygiene.
- III. Poor plaque control is the absolute contraindication for the implant treatment as it can lead to peri-implantitis and implant failure.
DM, osteoporosis, dementia, dry mouth, age are relative contraindications which can be managed. Implants can be given in patients with dementia and psychiatric disorders.
In case of dementia, replacement would be only recommended when the patient is unable to chew with the remaining dentition. Otherwise it should be deferred.
- IV. High speed rotary can be apprehensive as the sounds generate from this equipment can trigger them. And, they can't sit for longer. Therefore, ART is recommended for these patients.
- V. The normal stimulated salivary flow rate averages 1.5–2.0 mL/min while the unstimulated salivary flow rate is approximately 0.3–0.4 mL/min.
Patient's unstimulated salivary flow rate is 0.25ml/min which indicates that the patient is suffering from dry mouth.
Acetylcholinesterase is used to treat dry mouth as it's a cholinergic drug therefore, it produces secretions. Anticholinergic drugs reduce secretions.
Salbutamol is associated with dry mouth.

THIS IS COPYRIGHTED
CONTENT. Unauthorized use,
including screenshots,
copying, misuse, reuse, or
resale of any content from
this app, is strictly prohibited.
Our app monitors and records
all screenshots and
recordings. Violators will face
strict legal action.

DISCLAIMER

THIS IS COPYRIGHTED CONTENT. Unauthorized use, including screenshots, copying, misuse, reuse, or resale of any content from this app, is strictly prohibited. Our app monitors and records all screenshots and recordings. Violators will face strict legal action.

DISCLAIMER
THIS IS COPYRIGHTED CONTENT. Unauthorized use, including screenshots, copying, misuse, reuse, or resale of any content from this app, is strictly prohibited. Our app monitors and records all screenshots and recordings. Violators will face strict legal action.

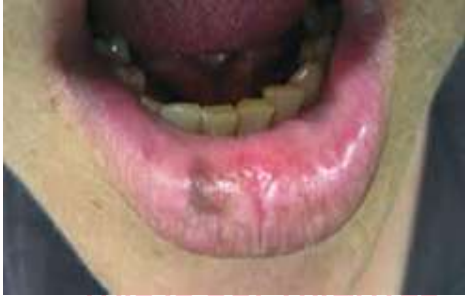DISCLAIMER

THIS IS COPYRIGHTED CONTENT. Unauthorized use, including screenshots, copying, misuse, reuse, or resale of any content from this app, is strictly prohibited. Our app monitors and records all screenshots and recordings. Violators will face strict legal action.

ORAL MEDICINE

SBQ 9

ADAM 30YR OLD, CAME TO YOUR CLINIC FOR A REGULAR VISIT. HE IS A RESCUER, DOES SURFING VERY OFTEN. A PICTURE OF HIS LOWER LIP WAS GIVEN WHICH HAD A BROWN DISCOLORATION. THE PATIENT WORKS AS A SURFER AND STAYS OUT IN SUN FOR A LONG TIME.



I. What is the provisional diagnosis for the brown lesion?

- A. Malignant Melanoma
- B. Melanocytic Nevi
- C. Melanotic macule
- D. Melasma

II. What was the cause of redness on the lower lip?

- A. Actinic cheilitis
- B. Lichen planus
- C. Erythroplakia
- D. Hyperpigmented Hyperkeratotic plaque
- E. Scar tissue

III. What is the highest risk complication?

- A. SCC
- B. Lichen planus
- C. Erythema migraines

IV. After doing a thorough history and examination you come to a conclusion that this lesion needs management, considering his risk, how will you manage this?

- A. Many lip application options like water based sunblock
- B. Inc ointment
- C. Refer to oral medicine as soon as possible
- D. Tretionic acid
- E. Lip balm

V. He says his lips are very dry and chappy and asks what can be done to prevent it and treat it? What will you apply to prevent this?

- A. Acyclovir cream
- B. Lanolin cream
- C. Zinc with something
- D. Water based Sunblock every 2 hours
- E. Highly humectant based something applied every few hours.

DISCLAIMER

THIS IS COPYRIGHTED CONTENT. Unauthorized use, including screenshots, copying, misuse, reuse, or resale of any content from this app, is strictly prohibited. Our app monitors and records all screenshots and recordings. Violators will face strict legal action.

DISCLAIMER

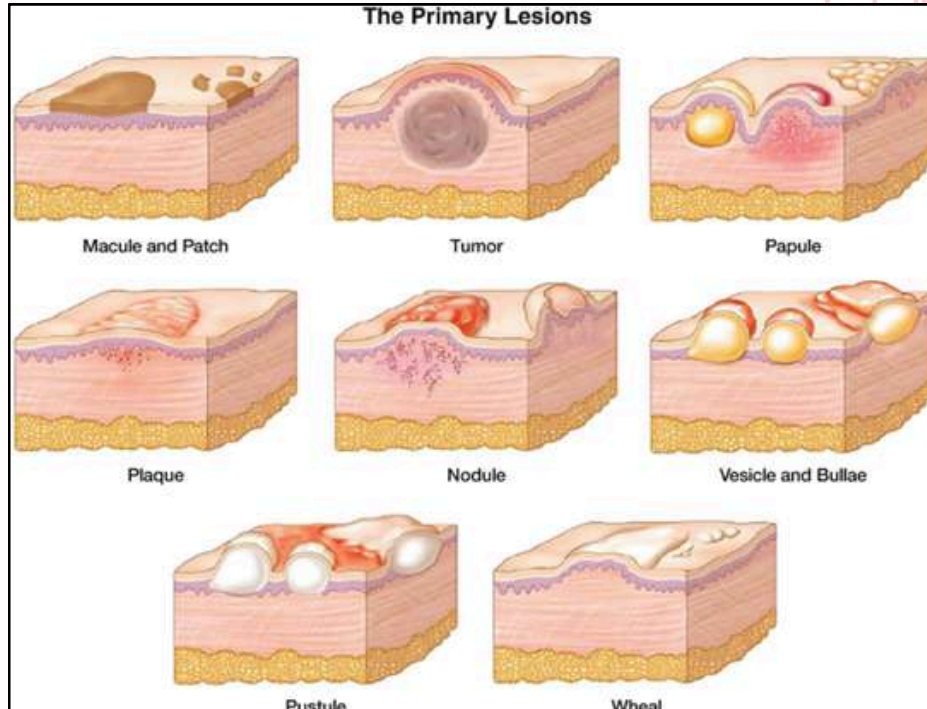
THIS IS COPYRIGHTED CONTENT. Unauthorized use, including screenshots, copying, misuse, reuse, or resale of any content from this app, is strictly prohibited. Our app monitors and records all screenshots and recordings. Violators will face strict legal action.

THIS IS COPYRIGHTED CONTENT. Unauthorized use, including screenshots, copying, misuse, reuse, or resale of any content from this app, is strictly prohibited. Our app monitors and records all screenshots and recordings. Violators will face strict legal action.

DISCLAIMER

ORAL MEDICINE

P.O.W.E.R NOTES SBQ 9



I. Explanation of the above given diagram:

- **Macule and patch**- brown pigmentation which is smaller in size is a macule and which is larger in size is a patch.
- **Tumour**- growth under the skin which is hard in consistency
- **Papule** – small raised bump. Not fluid filled.
- **Plaque**- flat raised larger area. Not fluid filled.
- **Nodule**- irregular raised large area. Not fluid filled.
- **Vesicle and bullae**- Blisters are classified as vesicles if they are 0.5 cm (0.2 inch) or less in diameter and as bullae if they are larger. They are fluid filled bumps.
- **Pustule**- it's a vesicle filled with pus rather than clear fluid.
- **Wheel**- completely flat raised surface. Can be seen in allergies.

Malignancy is not usually included in the differential diagnosis as the biopsy is required to confirm it.

And according to the given picture it looks benign as it's just a pigmented spot and there's a hx of sun exposure. It's **actinic cheilitis** and the pigmentation is the **melanotic macule** which is usually seen on the lip.

Melanocytic nevi are the accumulation of the melanocytes, present under the dermis or epidermis, which gives a deep blue lesion. Seen mostly in the early childhood. Can be both intraoral and extraoral.

Melasma is a pigment on the skin. It's seen mostly on the skin/ cheeks and it's mostly associated with the pregnant women.

DISCLAIMER

THIS IS COPYRIGHTED CONTENT. Unauthorized use, including screenshots, copying, misuse, reuse, or resale of any content from this app, is strictly prohibited. Our app monitors and records all screenshots and recordings. Violators will face strict legal action.

THIS IS COPYRIGHTED CONTENT. Unauthorized use, including screenshots, copying, misuse, reuse, or resale of any content from this app, is strictly prohibited. Our app monitors and records all screenshots and recordings. Violators will face strict legal action.

DISCLAIMER
THIS IS COPYRIGHTED CONTENT. Unauthorized use, including screenshots, copying, misuse, reuse, or resale of any content from this app, is strictly prohibited. Our app monitors and records all screenshots and recordings. Violators will face strict legal action.

ORAL MEDICINE

P.O.W.E.R NOTES SBQ 9

II. According to the given hx, patient stays out in the sun for a long time.

Actinic cheilitis is a precancerous condition caused by long-term sun exposure. It leads to rough, scaly, discoloured patches on your lips. It's more common in men, people with fair skin, those who work outside and populations in places where the sun is stronger. **It's due to the excessive melanin deposition and not due to the accumulation of melanocytes.**

Erythroplakia and hyperkeratotic plaque are white lesions. Lichen planus is a white-red lesion. There's no scar tissue formation associated with lichen planus.

III. If left untreated, actinic cheilitis can potentially progress to squamous cell carcinoma (SCC), a type of skin cancer.

Transformation to SCC:

Risk Factors:

- **Chronic Sun Exposure:** Continuous UV exposure damages the skin and increases the risk of malignant transformation.
- **Immunosuppression:** Conditions or medications that weaken the immune system can elevate the risk of cancer development.
- **Tobacco Use:** Smoking or chewing tobacco can exacerbate the condition and increase cancer risk.
- **Other Factors:** Fair skin, older age, and a history of actinic damage also contribute to the risk.

IV. Reference:

Management of actinic cheilitis

- All patients with actinic cheilitis, whether mild, moderate or severe should be advised to limit further sun exposure especially between 10am and 2pm (or 11am and 3pm in daylight saving time)
- Wear a protective broad brimmed hat
- **Use a SPF 30+ broad spectrum and water-resistant sunscreen lip balm regularly (every morning) with reapplication every 2hrs when outdoors.**
- The prescription of an emollient to moisturize the lip
- Early review of the lip fissure to ensure progress is satisfactory
- The decision of the melanotic macule, review or excise.
- Further treatment choices will depend on the nature and the extent of the disease and other patient considerations. Mild case can be reviewed regularly and **if there is any indication of clinical progression, they should be referred to the patient's medical practitioner, dermatologist or specialist in oral medicine for further assessment, investigation and possible treatment. Any patient with more significant disease should be referred immediately.**

V. Reference for this question is given above. Check question (IV).

DISCLAIMER

THIS IS COPYRIGHTED CONTENT. Unauthorized use, including screenshots, copying, misuse, reuse, or resale of any content from this app, is strictly prohibited. Our app monitors and records all screenshots and recordings. Violators will face strict legal action.

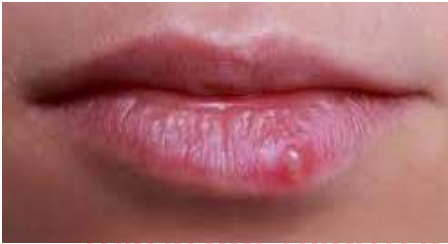THIS IS COPYRIGHTED CONTENT. Unauthorized use, including screenshots, copying, misuse, reuse, or resale of any content from this app, is strictly prohibited. Our app monitors and records all screenshots and recordings. Violators will face strict legal action.

DISCLAIMER
THIS IS COPYRIGHTED CONTENT. Unauthorized use, including screenshots, copying, misuse, reuse, or resale of any content from this app, is strictly prohibited. Our app monitors and records all screenshots and recordings. Violators will face strict legal action.

ORAL MEDICINE

SBQ 10

HERPES LABIALIS(PIC GIVEN NOT A TYPICAL ONE, NOT EXACT, THAT WAS A PERFECTLY FLUID FILLED INTACT VESICLE/BLISTER) HISTORY GIVEN THAT A 30 YR MALE HAS A RECURRENT INFECTION EVERY SUMMER. HE LOVES WORKING OUTSIDE AS A PARK RANGER IN THE SUN AND SPENDS A LOT OF TIME WITH HIS DAUGHTER PLAYING OUTSIDE, WHO IS 1 YR OLD.



I. What is this lesion? (it was fluid filled)

- A. Blister
- B. Pustule
- C. Vesicle
- D. Nodule
- E. Macule

II. What sensation does he feel before this lesion occurs?

- A. Prickling sensation
- B. Dull ache
- C. Sharp pain
- D. Throbbing pain
- E. Stabbing pain

III. What can he do so that he doesn't transfer this lesion to his daughter?

- A. Spend less time or limit his time with his daughter to 15 mins
- B. Avoid direct contact of the lesion with his daughter and her toys
- C. Wear a mask when with your daughter
- D. Apply acyclovir cream four times a day for 5 days, before playing with his daughter

IV. He gets annoyed that he has to be away from her daughter due to this lesion and that can affect his time with his daughter. What can he do to prevent this lesion?

- A. Immune booster
- B. Advise him to have balanced diet
- C. Use Sunscreen on lips and face
- D. Ask him to take over the counter vitamin supplements to increase his immunity

V. How will you confirm the diagnosis?

- A. Clinical examination and history
- B. PCR
- C. Serology, IgG
- D. Smear

DISCLAIMER

THIS IS COPYRIGHTED CONTENT. Unauthorized use, including screenshots, copying, misuse, reuse, or resale of any content from this app, is strictly prohibited. Our app monitors and records all screenshots and recordings. Violators will face strict legal action.

DISCLAIMER

THIS IS COPYRIGHTED CONTENT. Unauthorized use, including screenshots, copying, misuse, reuse, or resale of any content from this app, is strictly prohibited. Our app monitors and records all screenshots and recordings. Violators will face strict legal action.

THIS IS COPYRIGHTED CONTENT. Unauthorized use, including screenshots, copying, misuse, reuse, or resale of any content from this app, is strictly prohibited. Our app monitors and records all screenshots and recordings. Violators will face strict legal action.

DISCLAIMER

ORAL MEDICINE

P.O.W.E.R NOTES SBQ 10

- I. • **Blister**, a rounded elevation of the skin containing clear fluid, caused by a separation either between layers of the epidermis or between the epidermis and the dermis. Blisters are classified as vesicles if they are 0.5 cm (0.2 inch) or less in diameter and as bullae if they are larger. The size is not mentioned in the question and from a pic you can't exactly tell a size. So, option (C) is ruled out.
 - **Pustule** is filled with pus. Option (B) is ruled out.
 - **Nodule** is a solid growth and bump. Not fluid filled. Option (D) is ruled out.
 - **Macule** is a flat pigmented lesion. Option (E) is ruled out.

II. Itching will be the prodromal sign. Therefore, prickling sensation happens before any kind of pain.

III. It will not spread through air or with droplets. (not an aerosol contact). Not spreading through respiratory route. So, wearing mask will not be helpful. It spreads through direct contact.

Reference: TG

To reduce the risk of virus transmission, advice the patients with an active HSV infection to avoid direct contact of the lesion with other people.

IV. It's not a condition that involves the immune system. therefore, vaccination/immune booster is not required. Option (A) is ruled out.

There are not nutritional disturbances associated with this. Option (B) and (D) are ruled out.

As the management:

- Use a topical acyclovir application
- Prevent getting exposure to sun. (sun is the main triggering factor). Sunscreen is found to give some prevention

V. It's not required to get the microbiological or swab testing. Thorough history and clinical examination are needed to confirm the diagnosis.

Reference: TG

HSV lesion affecting the oral mucosa can not be differentiated from an aphthous or traumatic ulcer using microbiological testing. Most adults will have positive serology for the HSV from previous exposure, and viral DNA may be detected on swab of aphthous or traumatic ulcers. Instead diagnosis requires a thorough history and examination.

including screenshots, copying, misuse, reuse, or resale of any content from this app, is strictly prohibited. Our app monitors and records all screenshots and recordings. Violators will face strict legal action.

DISCLAIMER

THIS IS COPYRIGHTED CONTENT. Unauthorized use, including screenshots, copying, misuse, reuse, or resale of any content from this app, is strictly prohibited. Our app monitors and records all screenshots and recordings. Violators will face strict legal action.

DISCLAIMER

THIS IS COPYRIGHTED CONTENT. Unauthorized use, including screenshots, copying, misuse, reuse, or resale of any content from this app, is strictly prohibited. Our app monitors and records all screenshots and recordings. Violators will face strict legal action.

THIS IS COPYRIGHTED CONTENT. Unauthorized use, including screenshots, copying, misuse, reuse, or resale of any content from this app, is strictly prohibited. Our app monitors and records all screenshots and recordings. Violators will face strict legal action.

DISCLAIMER

ORAL MEDICINE

SBQ 11

MINOR APHTHOUS ULCER

APHTHOUS ULCER GIVEN ON CORNER OF LOWER LIP. PATIENT IS HAVING SERIOUS GERD, WHICH IS AFFECTING HIS LIFE AND NOT ABLE TO MAINTAIN HIS DIET AND NUTRITION

I. What will be the first thing you will ask the patient to make the diagnosis?

- A. Recurrence of ulcer at same sight
- B. Ulcer somewhere else on body
- C. Pain on ulcer
- D. Change in shape of ulcer

II. What will be the test to make a diagnosis?

- A. Biopsy
- B. Smear
- C. Clinical examination and history
- D. Immunofluorescence

III. What will you advise the patient to reduce the occurrence of ulcer?

- A. Brush properly
- B. Maintain nutrition and diet
- C. Prescribe a mouthwash
- D. Prescribe fluoride gel
- E. Prevent sun exposure

IV. What is the reason for the lesion?

- A. Smoking, alcohol
- B. Family history
- C. Stress
- D. Trauma

V. How to prevent this lesion from reoccurring?

- A. Avoid biting cheek and lips
- B. Balanced diet
- C. Stress counseling
- D. Vitamin supplement
- E. Sunscreen

THIS IS COPYRIGHTED CONTENT. Unauthorized use, including screenshots, copying, misuse, reuse, or resale of any content from this app, is strictly prohibited. Our app monitors and records all screenshots and recordings. Violators will face strict legal action.

DISCLAIMER

THIS IS COPYRIGHTED CONTENT. Unauthorized use, including screenshots, copying, misuse, reuse, or resale of any content from this app, is strictly prohibited. Our app monitors and records all screenshots and recordings. Violators will face strict legal action.

DISCLAIMER
THIS IS COPYRIGHTED CONTENT. Unauthorized use, including screenshots, copying, misuse, reuse, or resale of any content from this app, is strictly prohibited. Our app monitors and records all screenshots and recordings. Violators will face strict legal action.

THIS IS COPYRIGHTED CONTENT. Unauthorized use, including screenshots, copying, misuse, reuse, or resale of any content from this app, is strictly prohibited. Our app monitors and records all screenshots and recordings. Violators will face strict legal action.

DISCLAIMER

ORAL MEDICINE

P.O.W.E.R NOTES SBQ 11

- I. Genetic transmission, stress and nutritional deficiency are associated mainly with aphthous ulcers. According to this case nutritional deficiency is predominant.

Reference:

At least 40%-50% of patients report a familial trait and, in many cases, this correlates with both earlier onset and more severe disease. It seems like there is a genetic basis to the condition with both circumstantial and laboratory-based evidence. Patient should be aware of the strong possibility of genetic transmission.

Conditions related to the onset of the of RAU in some patients (triggering factors)

- **Physical trauma**- tooth brushing, orthodontic brackets
- **Chemical trauma**- chemical burns
- **Medications**- NSAIDs, cardio selective beta blockers
- **Psychological**- personal/work related stress
- **Nutritional**- iron deficiency, folate deficiency (related to GI disease), vitamin B1, B2, B6, B12
- **Gastrointestinal disease** - malabsorption syndrome, crohn's disease, coeliac disease (gluten sensitive enteropathy), ulcerative colitis.
- **Endocrinological** (premenstrual)
- **Haematological**- cyclic neutropenia, anaemias, haematological malignancies
- **Immunological**- immunodeficiency status, HIV infection
- **Allergy/ hypersensitivity**- foods (tomatoes, chocolates, nuts, dairy, wheat), metals (nickel based oral appliances)
- **Microbiological**- streptococci, herpes virus, Epstein bar virus
- **Syndrome associations**- Bechet's disease (multi organ involvement including oral, genital and eye lesions), PFAPA (periodic fever, aphthae, pharyngitis, cervical adenitis, MAGIC syndrome)

Taking the history of aphthous ulcer:

- **General medical history**
- **History of ulcerative disease**- age at onset, duration of condition, frequency of recurrence, remission periods, exacerbation factors/events/medications, food intolerance (dairy, wheat, nuts, tomatoes, chocolates) role of trauma, associated with stress and anxiety, familial history
- **Clinical features of the lesions**- historical single or multiple, average size, margins, vesicular or non-vesicular, duration of the individual lesions, tissue morbidity, level of functional morbidity, restriction rate of onset
- **Extra oral features**- ocular or genital lesions, skin lesions, GIT symptoms, haematological abnormality, pharyngitis, chondritis

DISCLAIMER

THIS IS COPYRIGHTED CONTENT. Unauthorized use, including screenshots, copying, misuse, reuse, or resale of any content from this app, is strictly prohibited. Our app monitors and records all screenshots and recordings. Violators will face strict legal action.

THIS IS COPYRIGHTED CONTENT. Unauthorized use, including screenshots, copying, misuse, reuse, or resale of any content from this app, is strictly prohibited. Our app monitors and records all screenshots and recordings. Violators will face strict legal action.

DISCLAIMER
THIS IS COPYRIGHTED CONTENT. Unauthorized use, including screenshots, copying, misuse, reuse, or resale of any content from this app, is strictly prohibited. Our app monitors and records all screenshots and recordings. Violators will face strict legal action.

ORAL MEDICINE

P.O.W.E.R NOTES SBQ 11

- II. It's not required to get the microbiological or swab testing. Thorough history and clinical examination are needed to confirm the diagnosis.
- III. By suppressing the trigger factors, we can reduce the occurrence of the aphthous ulcer. According to this case nutritional deficiency is predominant. Therefore, maintaining nutrition and diet is most important. Sun exposure is a trigger factor associated with HSV infection.
- IV. Reason for the lesion is the familial history. Explanation is given above.
- V. According to this patient it's the nutritional deficiency due to GERD. Therefore, maintaining a balanced diet is more important to prevent the recurrence of the lesion.

including screenshots, copying, misuse, reuse, or resale of any content from this app, is strictly prohibited. Our app monitors and records all screenshots and recordings. Violators will face strict legal action.

THIS IS COPYRIGHTED CONTENT. Unauthorized use, including screenshots, copying, misuse, reuse, or resale of any content from this app, is strictly prohibited. Our app monitors and records all screenshots and recordings. Violators will face strict legal action.

THIS IS COPYRIGHTED CONTENT. Unauthorized use, including screenshots, copying, misuse, reuse, or resale of any content from this app, is strictly prohibited. Our app monitors and records all screenshots and recordings. Violators will face strict legal action.

DISCLAIMER

THIS IS COPYRIGHTED CONTENT. Unauthorized use, including screenshots, copying, misuse, reuse, or resale of any content from this app, is strictly prohibited. Our app monitors and records all screenshots and recordings. Violators will face strict legal action.

DISCLAIMER

THIS IS COPYRIGHTED CONTENT. Unauthorized use, including screenshots, copying, misuse, reuse, or resale of any content from this app, is strictly prohibited. Our app monitors and records all screenshots and recordings. Violators will face strict legal action.

DISCLAIMER

THIS IS COPYRIGHTED CONTENT. Unauthorized use, including screenshots, copying, misuse, reuse, or resale of any content from this app, is strictly prohibited. Our app monitors and records all screenshots and recordings. Violators will face strict legal action.

ORAL MEDICINE

SBQ 12

LADY W/ VOMITING DISORDER, IN TREATMENT WITH GP, TREATMENT NOT HELPING MUCH. ALSO SHE'S REALLY OBSESSIVE IN BRUSHING HER TEETH, LACTOSE INTOLERANT

I. You are working with her nutritionist to help him to make sure she has stopped the habit. How would you check if the lesions on her teeth are still active?

- A. The expose dentine is not stained
- B. Stage 2 wear index
- C. Margins of restoration raise on tooth
- D. Smooth, shiny, define round margins of the teeth

II. Dentist determines she needs to increase her calcium intake to help with restoring dentition. How is this best managed?

- A. Tell her to eat more dairy food
- B. Advise her to eat food high in calcium
- C. Refer to dietitian for adjustment of calcium in her diet
- D. Refer to GP for an bone densitometry to determine the need of calcium
- E. Tell her to buy over the counter calcium supplements
- F. Refer to oral therapist for advice.

III. What will you advise her about to avoid further damage to her teeth?

- A. Brush it 60min after vomiting
- B. Use mouthwash 900ppm after vomiting
- C. Wait 60min after vomiting to brush
- D. Rinse with water after vomiting
- E. Apply small circulation with soft toothbrush

IV. What are the most affected areas which result in exposed dentin?

- A. Anterior buccal of maxillary teeth
- B. Oclusal areas of mandibular posterior
- C. Palatal of maxillary posterior
- D. Incisal edge of mandibular anterior

THIS IS COPYRIGHTED
CONTENT. Unauthorized use,
including screenshots,
copying, misuse, reuse, or
resale of any content from
this app, is strictly prohibited.
Our app monitors and records
all screenshots and
recordings. Violators will face
strict legal action.

DISCLAIMER

THIS IS COPYRIGHTED CONTENT. Unauthorized use, including screenshots, copying, misuse, reuse, or resale of any content from this app, is strictly prohibited. Our app monitors and records all screenshots and recordings. Violators will face strict legal action.

DISCLAIMER

THIS IS COPYRIGHTED CONTENT. Unauthorized use, including screenshots, copying, misuse, reuse, or resale of any content from this app, is strictly prohibited. Our app monitors and records all screenshots and recordings. Violators will face strict legal action.

THIS IS COPYRIGHTED CONTENT. Unauthorized use, including screenshots, copying, misuse, reuse, or resale of any content from this app, is strictly prohibited. Our app monitors and records all screenshots and recordings. Violators will face strict legal action.

DISCLAIMER

ORAL MEDICINE

P.O.W.E.R NOTES SBQ 12

- I. Staging indicates only the extent of the damage. It doesn't indicate whether lesions are active or inactive. Due to erosions margins of the restorations would be raised, smooth, shiny, define rounded margins of the teeth would be present, but these factors won't determine how active or inactive the lesion is. In the presence of active erosion, there won't be stained teeth in the oral cavity.
- II. Female patient with lactose intolerance and she needs to increase her calcium intake. As dentists we can't prescribe calcium supplements. Options (A), (B), (E) and (F) are ruled out. Diet advice should be best taken from a dietitian. Bone densitometry is not needed as an initial management. It comes in the later stages.
- III. Vomiting disorder is linked with erosion. Brushing technique, frequency of brushing and timings of brushing is more important to prevent getting erosions. They should reduce brushing for twice a day. If they need to brush after vomiting due to the altered taste, they must wait for at least 30mins for brushing. Most important thing to do after vomiting is to rinse mouth with water.
- IV. Occlusal surface of the molars, palatal surfaces of the anterior are the most affected areas which result in exposed dentin due to erosion.

DISCLAIMER

THIS IS COPYRIGHTED CONTENT. Unauthorized use, including screenshots, copying, misuse, reuse, or resale of any content from this app, is strictly prohibited. Our app monitors and records all screenshots and recordings. Violators will face strict legal action.

THIS IS COPYRIGHTED CONTENT. Unauthorized use, including screenshots, copying, misuse, reuse, or resale of any content from this app, is strictly prohibited. Our app monitors and records all screenshots and recordings. Violators will face strict legal action.

DISCLAIMER

THIS IS COPYRIGHTED CONTENT. Unauthorized use, including screenshots, copying, misuse, reuse, or resale of any content from this app, is strictly prohibited. Our app monitors and records all screenshots and recordings. Violators will face strict legal action.

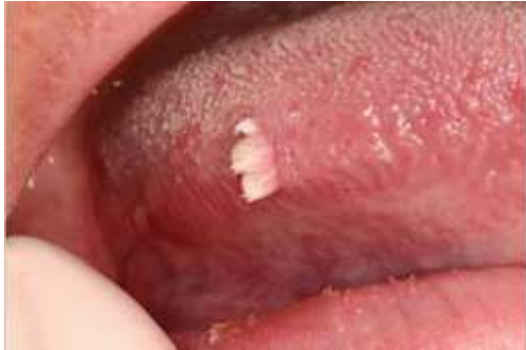DISCLAIMER

THIS IS COPYRIGHTED CONTENT. Unauthorized use, including screenshots, copying, misuse, reuse, or resale of any content from this app, is strictly prohibited. Our app monitors and records all screenshots and recordings. Violators will face strict legal action.

ORAL MEDICINE

SBQ 13

WHAT IS YOUR LIKELY DIAGNOSIS ? ONLY PHOTO WAS ATTACHED



- A. Papilloma
- B. Condyloma Acuminata
- C. SCC
- D. Lichen planus

P.O.W.E.R NOTES SBQ 13

- I. Clinical diagnosis is papilloma. Biopsy is required to confirm whether is it associated with HPV or not.

Papillomas are benign tumours that typically arise from epithelial tissue. They can appear as warts or growths on various body parts, including the skin, mucous membranes, or internal organs. The term "papilloma" generally refers to any such growth, but there are different types depending on their location and appearance.

Papillomas are usually non-cancerous, but some types, especially those associated with HPV, can have the potential to progress to cancer if not monitored or treated. HPV associated papillomas are squamous papilloma, condyloma acuminata, verrucosus vulgaris.

THIS IS COPYRIGHTED CONTENT. Unauthorized use, including screenshots, copying, misuse, reuse, or resale of any content from this app, is strictly prohibited. Our app monitors and records all screenshots and recordings. Violators will face strict legal action.

DISCLAIMER

THIS IS COPYRIGHTED CONTENT. Unauthorized use, including screenshots, copying, misuse, reuse, or resale of any content from this app, is strictly prohibited. Our app monitors and records all screenshots and recordings. Violators will face strict legal action.

THIS IS COPYRIGHTED CONTENT. Unauthorized use, including screenshots, copying, misuse, reuse, or resale of any content from this app, is strictly prohibited. Our app monitors and records all screenshots and recordings. Violators will face strict legal action.

DISCLAIMER

THIS IS COPYRIGHTED CONTENT. Unauthorized use, including screenshots, copying, misuse, reuse, or resale of any content from this app, is strictly prohibited. Our app monitors and records all screenshots and recordings. Violators will face strict legal action.

THIS IS COPYRIGHTED CONTENT. Unauthorized use, including screenshots, copying, misuse, reuse, or resale of any content from this app, is strictly prohibited. Our app monitors and records all screenshots and recordings. Violators will face strict legal action.

DISCLAIMER

ORAL MEDICINE

SBQ 14

ANXIOUS OBESE

PATIENT FALLS ON THE FLOOR AFTER STANDING FROM THE CHAIR AFTER EXTRACTION, WHEN HE GETS UP FROM THE DENTAL CHAIR. HE WAS DIABETIC TYPE 1

I. What is the cause?

- A. Hypotension
- B. Anaphylaxis
- C. Orthostatic hypotension
- D. Vaso vagal response

II. He didn't gain consciousness but breathing normally, management?

- A. Lay him flat on his back and rises his legs
- B. Put the pt on his left side
- C. Give oxygen
- D. Start cpr
- E. Cool napkin on his head.

Our app monitors and records all screenshots and recordings. Violators will face strict legal action.

THIS IS COPYRIGHTED CONTENT. Unauthorized use, including screenshots, copying, misuse, reuse, or resale of any content from this app, is strictly prohibited. Our app monitors and records all screenshots and recordings. Violators will face strict legal action.

DISCLAIMER

THIS IS COPYRIGHTED CONTENT. Unauthorized use, including screenshots, copying, misuse, reuse, or resale of any content from this app, is strictly prohibited. Our app monitors and records all screenshots and recordings. Violators will face strict legal action.

THIS IS COPYRIGHTED CONTENT. Unauthorized use, including screenshots, copying, misuse, reuse, or resale of any content from this app, is strictly prohibited. Our app monitors and records all screenshots and recordings. Violators will face strict legal action.

THIS IS COPYRIGHTED CONTENT. Unauthorized use, including screenshots, copying, misuse, reuse, or resale of any content from this app, is strictly prohibited. Our app monitors and records all screenshots and recordings. Violators will face strict legal action.

DISCLAIMER
THIS IS COPYRIGHTED CONTENT. Unauthorized use, including screenshots, copying, misuse, reuse, or resale of any content from this app, is strictly prohibited. Our app monitors and records all screenshots and recordings. Violators will face strict legal action.

ORAL MEDICINE

P.O.W.E.R NOTES SBQ 14

- I. Postural hypotension, also known as orthostatic hypotension, is a condition where a person experiences a sudden drop in blood pressure when standing up from a sitting or lying position. This can lead to symptoms such as dizziness, light-headedness, blurred vision, or even fainting.

Causes: It can be caused by a variety of factors, including dehydration, prolonged bed rest, medications (like diuretics or antihypertensives), or underlying health conditions (such as diabetes, Parkinson's disease, or cardiovascular issues).

Diagnosis: Diagnosis typically involves measuring blood pressure while the patient is lying down, sitting, and then standing. A significant drop in blood pressure upon standing confirms the condition.

- II. **Supine hypotensive syndrome** is a condition that occurs when a pregnant woman experiences a drop in blood pressure while lying on her back (supine position). This can lead to reduced blood flow to the heart and, subsequently, to the fetus. Pressure on the inferior vena cava (IVC) can lead to this. The SVC is a major vein that carries deoxygenated blood from the head, neck, arms, and upper torso back to the heart. When pressure or obstruction occurs in this vein, it can disrupt normal blood flow and cause various symptoms.

Positioning: The primary method to manage and prevent supine hypotensive syndrome is to avoid lying flat on the back. Instead, pregnant women should lie on their left side, which helps alleviate pressure on the inferior vena cava and improves blood flow.

Even an obese patient can experience the same situation due to the compression of SVC in supine position.

No need of oxygen or CPR as the patient breathes normally.

DISCLAIMER

THIS IS COPYRIGHTED CONTENT. Unauthorized use, including screenshots, copying, misuse, reuse, or resale of any content from this app, is strictly prohibited. Our app monitors and records all screenshots and recordings. Violators will face strict legal action.

DISCLAIMER
THIS IS COPYRIGHTED CONTENT. Unauthorized use, including screenshots, copying, misuse, reuse, or resale of any content from this app, is strictly prohibited. Our app monitors and records all screenshots and recordings. Violators will face strict legal action.

DISCLAIMER

THIS IS COPYRIGHTED CONTENT. Unauthorized use, including screenshots, copying, misuse, reuse, or resale of any content from this app, is strictly prohibited. Our app monitors and records all screenshots and recordings. Violators will face strict legal action.

ORAL MEDICINE

SBQ 15

SIGN OF METASTASIS OF CANCER IN LYMPH NODES

- A. Larger
- B. Tender
- C. Fixed
- D. Mobile

P.O.W.E.R NOTES SBQ 13

- I. Lymph nodes that are associated with malignancy are often fixed to the skin or the surrounding tissues. They are non-tender. Tenderness can be seen in infections.

THIS IS COPYRIGHTED CONTENT. Unauthorized use, including screenshots, copying, misuse, reuse, or resale of any content from this app, is strictly prohibited. Our app monitors and records all screenshots and recordings. Violators will face strict legal action.

THIS IS COPYRIGHTED CONTENT. Unauthorized use, including screenshots, copying, misuse, reuse, or resale of any content from this app, is strictly prohibited. Our app monitors and records all screenshots and recordings. Violators will face strict legal action.

THIS IS COPYRIGHTED CONTENT. Unauthorized use, including screenshots, copying, misuse, reuse, or resale of any content from this app, is strictly prohibited. Our app monitors and records all screenshots and recordings. Violators will face strict legal action.

DISCLAIMER

THIS IS COPYRIGHTED CONTENT. Unauthorized use, including screenshots, copying, misuse, reuse, or resale of any content from this app, is strictly prohibited. Our app monitors and records all screenshots and recordings. Violators will face strict legal action.

DISCLAIMER

THIS IS COPYRIGHTED CONTENT. Unauthorized use, including screenshots, copying, misuse, reuse, or resale of any content from this app, is strictly prohibited. Our app monitors and records all screenshots and recordings. Violators will face strict legal action.

DISCLAIMER

THIS IS COPYRIGHTED CONTENT. Unauthorized use, including screenshots, copying, misuse, reuse, or resale of any content from this app, is strictly prohibited. Our app monitors and records all screenshots and recordings. Violators will face strict legal action.

ORAL MEDICINE

SBQ 16

HEALTHY AND FIT PATIENT, NO MEDICATION TAKING, WHILE EXERCISING HAS DRY MOUTH 0.2 UNSTIMULATED SALIVARY FLOW AND STIMULATED 0.9.

- A. Check watery intake 2 L per day
- B. Prescribe cholinergic
- C. Give occlusal splint

P.O.W.E.R NOTES SBQ 16

- I. The normal stimulated salivary flow rate averages 1.5–2.0 mL/min while the unstimulated salivary flow rate is approximately 0.3–0.4 mL/min. General exercises related dry mouth can be managed with increasing water intake. During exercises the patient can be dehydrated. Hydration/drinking water is the 1st management in dry mouth.

THIS IS COPYRIGHTED CONTENT. Unauthorized use, including screenshots, copying, misuse, reuse, or resale of any content from this app, is strictly prohibited. Our app monitors and records all screenshots and recordings. Violators will face strict legal action.

THIS IS COPYRIGHTED CONTENT. Unauthorized use, including screenshots, copying, misuse, reuse, or resale of any content from this app, is strictly prohibited. Our app monitors and records all screenshots and recordings. Violators will face strict legal action.

THIS IS COPYRIGHTED CONTENT. Unauthorized use, including screenshots, copying, misuse, reuse, or resale of any content from this app, is strictly prohibited. Our app monitors and records all screenshots and recordings. Violators will face strict legal action.

DISCLAIMER

THIS IS COPYRIGHTED CONTENT. Unauthorized use, including screenshots, copying, misuse, reuse, or resale of any content from this app, is strictly prohibited. Our app monitors and records all screenshots and recordings. Violators will face strict legal action.

DISCLAIMER

THIS IS COPYRIGHTED CONTENT. Unauthorized use, including screenshots, copying, misuse, reuse, or resale of any content from this app, is strictly prohibited. Our app monitors and records all screenshots and recordings. Violators will face strict legal action.

DISCLAIMER

THIS IS COPYRIGHTED CONTENT. Unauthorized use, including screenshots, copying, misuse, reuse, or resale of any content from this app, is strictly prohibited. Our app monitors and records all screenshots and recordings. Violators will face strict legal action.

ORAL MEDICINE

SBQ 17

CHEN WITH ANUG PHOTO OF A PATIENT WITH ACUTE ULKERATIVE GINGIVITIS. OLD MAN, WORKS AT SOME INDUSTRY/FACORY, SMOKES 20 CIGARETTES PER DAY AND CONSUMES ALCOHOL 3 STANDARD DRINKS PER DAY. WOKE UP ONE MORNING WITH ACUTE PAIN IN THE GUMS AND FEVER OF 38 DEGREES. YOU EXAMINE HIM.

I. From the history and clinical examination, what do you think is the probable diagnosis?

- A. Acute ulcerative gingivitis
- B. Chronic necrotising ulcerative Periodontitis
- C. Periodontal Abscess
- D. Gingivostomatitis

II. What is the immediate management or this condition?

- A. Oral hygiene instructions
- B. Removal of plaque and necrotic tissue(debris).
- C. Local anesthesia if required for temporary relief.
- D. Gentle debridement followed with 0.2% chlorhexidine irrigation
- E. Gentle debridement followed with 20% hydrogen peroxide irrigation

III. What will you give for systemic symptoms?

- A. Amoxicillin 500mg for 5days
- B. Metronidazole 400mg 12hourly for 5days
- C. Clindamycin for 5days regime

IV. What is the primary reason for this condition?

- A. Smoking
- B. Change occupation
- C. Acidic Fumes

V. Why will primary herpetic gingivostomatitis not be a common occurrence in this patient?

- A. Because smoking and alcohol are risk factors for herpatic gingivostomatitis.
- B. Its common more in females than males
- C. Because early exposure in childhood would have led to formation of antibodies against it
- D. Because those adults/infected patients get themselves treated immediately by antiviral , during the prodromal phase of the viral infection.
- E. It is becoming more common nowadays because of late age exposure to the virus
- F. Because acidic fumes in the work environment poses as a risk factor for HG.

DISCLAIMER

THIS IS COPYRIGHTED CONTENT. Unauthorized use, including screenshots, copying, misuse, reuse, or resale of any content from this app, is strictly prohibited. Our app monitors and records all screenshots and recordings. Violators will face strict legal action.

DISCLAIMER

THIS IS COPYRIGHTED CONTENT. Unauthorized use, including screenshots, copying, misuse, reuse, or resale of any content from this app, is strictly prohibited. Our app monitors and records all screenshots and recordings. Violators will face strict legal action.

THIS IS COPYRIGHTED CONTENT. Unauthorized use, including screenshots, copying, misuse, reuse, or resale of any content from this app, is strictly prohibited. Our app monitors and records all screenshots and recordings. Violators will face strict legal action.

DISCLAIMER

ORAL MEDICINE

P.O.W.E.R NOTES SBQ 17

- I. Location is the predominant factor which distinguishes between primary herpetic gingivostomatitis and ANUG. ANUG can be seen on the interdental papillae while primary herpetic gingivostomatitis is generalised. Smoking is a risk factor for developing ANUG.
- II. **Reference: TG**
Management of ANUG
- Gentle removal of as much plaque and necrotic debris as possible, using local anaesthetic if necessary.
 - Local irrigation with 0.2% CHX mouth wash or 3% H₂O₂ solution.
 - Antibiotic therapy and analgesics
 - Advise to stop smoking
 - If pain and inflammation restrict oral hygiene practice, recommend short term use of a mouth wash to reduce plaque formation.
- Review the patient in 48 to 72 hours; perform a periodontal examination and provide the patient with advice on oral hygiene.
- III. ANUS is a spirochaetal infection which is managed with metronidazole. Amoxicillin and clindamycin will not be helpful in managing ANUG.
- IV. Smoking is a risk factor for developing ANUG.
- V. Early childhood exposure to HSV would have led to form antibodies. Option (E) would be the answer if the question asks about "why the patient is likely to get primary herpetic gingivostomatitis".

ORAL MEDICINE

SBQ 18

REGULAR PATIENT WITH PAIN DUE TO INDIGESTION, HE THINKS HE HAS SOME GASTRIC PROBLEMS GOING ON, GETS TO YOUR PRACTICE BREATHLESS AFTER CLIMBING UP THE STAIRS, PALLOR, NEEDS TO REST TO CATCH HIS BREATH, HE IS HYPERTENSIVE AND OBESE TAKING CALCIUM CHANNEL BLOCKER AND FUROSEMIDE. CAME IN FOR A CHECK-UP AND DISLODGED LARGE AMALGAM RESTORATION BUT YOU ARE CONCERNED WITH HIS SIGNS. DIDN'T SLEPT WELL LAST NIGHT.

I. Which vital sign defines accurately his present condition

- A. Pallor
- B. Noisy breathing
- C. Tingling on fingers, toes and lips
- D. Pain due to indigestion (this option was not there, in this question).
(the option was - facial weakness)
- E. Slurred speech

II. After a few times he vomit into a bag , so which sign you will check first

- A. Body temperature
- B. Breathing
- C. BP

III. He starts coughing, what you do

- A. Check Effectiveness of cough
- B. Give Oxygen
- C. Give 10 thrust or back blows

IV. You called 000 and your attendant asked why didn't you give Mr Bradman external defibrillation. So, in what condition of Mr Bradman You are suppose to give defibrillation

- A. Unconsciousness
- B. Severe chest pain
- C. Atrial fibrillation
- D. Bradycardia

V. First management should you do, what medication to give to him if u suspect heart attack

- A. Aspirin
- B. Salbutamol
- C. Adrenaline
- D. Paracetamol

DISCLAIMER

THIS IS COPYRIGHTED CONTENT. Unauthorized use, including screenshots, copying, misuse, reuse, or resale of any content from this app, is strictly prohibited. Our app monitors and records all screenshots and recordings. Violators will face strict legal action.

DISCLAIMER

THIS IS COPYRIGHTED CONTENT. Unauthorized use, including screenshots, copying, misuse, reuse, or resale of any content from this app, is strictly prohibited. Our app monitors and records all screenshots and recordings. Violators will face strict legal action.

THIS IS COPYRIGHTED CONTENT. Unauthorized use, including screenshots, copying, misuse, reuse, or resale of any content from this app, is strictly prohibited. Our app monitors and records all screenshots and recordings. Violators will face strict legal action.

DISCLAIMER

ORAL MEDICINE

P.O.W.E.R NOTES SBQ 18

- I. Patient is hypertensive and obese and takes a calcium channel blocker, furosemide. Patient may have a risk to develop cardiac condition (cardiac ischemic attack) according to his medical history and with the presence of the symptoms, difficulty in breathing, difficulty in climbing and pallor. Cyanosis and dyspnoea are signs of MI. Among options (A) and (B), option (B) is more important. Tingling on fingers, toes and lips, facial weakness, slurred speech are signs of stroke.
- II. When the patient vomits, there's a high chance of airway obstruction. Therefore, breathing is checked first. Then other signs will be checked.
- III. Vomit must have been aspirated that's why the patient started coughing. When something is aspirated, you must follow the below steps.

Reference: TG

Box 48. Management of an inhaled or swallowed object [NB1]

In the event that an object appears to have fallen down the oropharynx:

- Stop dental treatment.
- Check whether the object is present in the patient's mouth or clothes and, if so, remove it.
- If the object is not found, put the patient into an upright position.
- Although the majority of ingested foreign bodies will pass through the gastrointestinal tract without incident, refer the patient for further medical assessment and management. If the patient is stable and asymptomatic, it may be appropriate to complete dental treatment before doing so.

If the patient is conscious with signs of airway obstruction (see Table 26; p.257):

- Call 000.
- Reassure the patient and encourage them to relax, breathe deeply and try to dislodge the object by coughing.
- If coughing is ineffective, give up to 5 back blows between the shoulder blades using the heel of the hand (checking for effectiveness between each blow).
- If back blows are unsuccessful, give up to 5 chest thrusts delivered at the same compression point as for CPR (checking for effectiveness between each chest thrust).
- Continue to alternate between back blows and chest thrusts until the obstruction is relieved or assistance arrives.

If the patient with airway obstruction becomes unconscious:

- Call 000.
- Inspect the back of the throat for the foreign object and remove it if possible.
- Start CPR (for 'Basic life support flow chart', see Figure 8; p.235).
- Clinicians with appropriate expertise and equipment should consider performing cricothyroidotomy.
- Abdominal thrusts, such as those described in the Heimlich manoeuvre, can cause internal organ damage so are not recommended.

CPR = cardiopulmonary resuscitation
NB1: A flow chart for the management of choking can be downloaded from the Australian Resuscitation Council website <resus.org.au/guidelines/flowcharts-3/>.

emergencies in dental

- IV. External defibrillation is the advanced life support (ALS). BLS and ALS are given when the patient loses consciousness or loss of any other vitals. No pulse, no breath, loss of consciousness are the 3 indicators for giving BLS and ALS.
- V. Amongst the given, aspirin is the life saving drug for heart attack.

DISCLAIMER

THIS IS COPYRIGHTED CONTENT. Unauthorized use, including screenshots, copying, misuse, reuse, or resale of any content from this app, is strictly prohibited. Our app monitors and records all screenshots and recordings. Violators will face strict legal action.

THIS IS COPYRIGHTED CONTENT. Unauthorized use, including screenshots, copying, misuse, reuse, or resale of any content from this app, is strictly prohibited. Our app monitors and records all screenshots and recordings. Violators will face strict legal action.

DISCLAIMER
THIS IS COPYRIGHTED CONTENT. Unauthorized use, including screenshots, copying, misuse, reuse, or resale of any content from this app, is strictly prohibited. Our app monitors and records all screenshots and recordings. Violators will face strict legal action.

ORAL MEDICINE

SBQ 19

QUESTION SAID WE ARE PART OF A STUDY GROUP AND IN CASE THE BELOW WERE DISCUSSED.

- I. Case of latent TB in Aboriginal pt. Camping in indigenous community. What precautions would you use for the above pt.
 - A. General clinical mask
 - B. N95
 - C. Double gloving
 - D. Negative pressure room the dentist was visiting an aboriginal community
- II. You discuss a case where a patient was abusive/aggressive to your reception staff. What will you do as a dentist?
 - A. Ignore the problem and focus only on the patient's treatment
 - B. Call the patient to a separate room and ask what is his concern and solve it before treatment
 - C. For the safety of the staff don't perform any treatment for the patient
 - D. Don't perform any treatment unless the patient apologizes to the receptionist.
 - E. Call police
- III. Dr "C" presents a case of Domestic violence. Couple came because the lady had an accident on face. Patient's partner was agitated when asked about injuries, how can you manage this case?
 - A. Discretely pass social contact to patient
 - B. Confront partner
 - C. Call police
 - D. You should only bother about dental issues
 - E. Do not commence treatment unless you get the full history of trauma
- IV. Your colleague - explained his patient about Root canal cost - forgot to inform patient about crown charges - but patient thought crown charges also included in the RCT charge - so patient disputing going on! How to manage?
 - A. Reduce crown charges
 - B. Give crown for free
 - C. Apologize to patient, but get full charge
 - D. Give bleaching as complementary and charge for crown
 - E. Pay half half

DISCLAIMER

THIS IS COPYRIGHTED CONTENT. Unauthorized use, including screenshots, copying, misuse, reuse, or resale of any content from this app, is strictly prohibited. Our app monitors and records all screenshots and recordings. Violators will face strict legal action.

DISCLAIMER

THIS IS COPYRIGHTED CONTENT. Unauthorized use, including screenshots, copying, misuse, reuse, or resale of any content from this app, is strictly prohibited. Our app monitors and records all screenshots and recordings. Violators will face strict legal action.

THIS IS COPYRIGHTED CONTENT. Unauthorized use, including screenshots, copying, misuse, reuse, or resale of any content from this app, is strictly prohibited. Our app monitors and records all screenshots and recordings. Violators will face strict legal action.

DISCLAIMER

ORAL MEDICINE

P.O.W.E.R NOTES SBQ 19

- I. Latent TB can turn in to active TB in aboriginal/ indigenous community. There's a high TB population in indigenous community. Therefore, must use a N95 mask. Double gloving is not needed as TB spreads through respiratory route. Option (C) is ruled out. Negative pressure room can't be created in an aboriginal community in an outdoor camp. Option (D) is ruled out.
- II. No need to call the police unless there's an act of violence. Option (E) is ruled out. You can't ask the patient to apologize unless you know about the situation properly. Option (D) is ruled out. As a dentist you can't avoid doing the treatment due a trouble. Option (C) is ruled out. When there's already a problem you can't avoid it and proceed ahead with the treatment. Option (A) is ruled out.
- III. If it's a domestic abuse case, we must report to the authorities, but only after getting it confirmed. Thorough history taking is required. The injuries should match with the history. If not it's a suspicious case. Every state has a guideline. Dental practitioners should attempt to provide a safe and compassionate environment to discuss issues of abuse and violence and have appropriate referral pathways in place.
Dental practitioners are in a position to detect, support and provide advice to the patients who present suffering from abuse and violence.
- IV. It's not a life-threatening mistake that a complaint or a mandatory notification is needed. It's a failure to obtain a financial consent at an appropriate time. So, you can still apologize for the mistake and can get the full charge.

- V. Amongst the given, aspirin is the life saving drug for heart attack.

DISCLAIMER

THIS IS COPYRIGHTED CONTENT. Unauthorized use, including screenshots, copying, misuse, reuse, or resale of any content from this app, is strictly prohibited. Our app monitors and records all screenshots and recordings. Violators will face strict legal action.

DISCLAIMER

THIS IS COPYRIGHTED CONTENT. Unauthorized use, including screenshots, copying, misuse, reuse, or resale of any content from this app, is strictly prohibited. Our app monitors and records all screenshots and recordings. Violators will face strict legal action.

DISCLAIMER

THIS IS COPYRIGHTED CONTENT. Unauthorized use, including screenshots, copying, misuse, reuse, or resale of any content from this app, is strictly prohibited. Our app monitors and records all screenshots and recordings. Violators will face strict legal action.

ORAL MEDICINE

SBQ 20

PATIENT IS GOING TO START BISPHOSPHONATE THERAPY NEXT FRIDAY. HE ATTENDED HIS MEDICAL PRACTITIONER AND CAME TO SEE YOU WITH A MEDICAL RECORD, SAYING GONNA START IV ZOLEDRONIC ACID MEDICATION NEXT FRIDAY. (OPG GIVEN - DENTATE - MILD BONE LOSS, MULTIPLE RC TREATED TEETH WITHOUT CROWNS, MULTIPLE SMALL DC)

I. What's your immediate concern

- A. Oral hygiene measures
- B. Restoring rc treated teeth
- C. Extract non-restorable teeth
- D. Restorations

II. What advice you would send to GP

- A. Defer bisphosphonate therapy
- B. Change IV to oral Bisphosphonates
- C. I'm doing only palliative treatment, so proceed with your plan
- D. Postpone her treatment

III. After thorough clinical examination, you find, 36 tooth RC treated - non restorable and plan to extract, when is the best time to extract?

- A. Anytime, coz anyway risk is the same
- B. Immediately, as BP therapy gonna start next friday
- C. In between 2 injections, mid date
- D. Temporary cease IV BP for 2 weeks and extract

IV. What would make extraction difficult?

- A. Its close proximity to 35 root
- B. Brittleness as its rc treated
- C. Hypercementosis of bulbous mesial root

THIS IS COPYRIGHTED CONTENT. Unauthorized use, including screenshots, copying, misuse, reuse, or resale of any content from this app, is strictly prohibited. Our app monitors and records all screenshots and recordings. Violators will face strict legal action.

DISCLAIMER

THIS IS COPYRIGHTED CONTENT. Unauthorized use, including screenshots, copying, misuse, reuse, or resale of any content from this app, is strictly prohibited. Our app monitors and records all screenshots and recordings. Violators will face strict legal action.

DISCLAIMER
THIS IS COPYRIGHTED CONTENT. Unauthorized use, including screenshots, copying, misuse, reuse, or resale of any content from this app, is strictly prohibited. Our app monitors and records all screenshots and recordings. Violators will face strict legal action.

THIS IS COPYRIGHTED CONTENT. Unauthorized use, including screenshots, copying, misuse, reuse, or resale of any content from this app, is strictly prohibited. Our app monitors and records all screenshots and recordings. Violators will face strict legal action.

DISCLAIMER

ORAL MEDICINE

P.O.W.E.R NOTES SBQ 20

- I. Patient is about to start IV bisphosphonates and no hx of cancer given. There's no active periodontal disease. Depending on these factors, this patient falls into the low risk category. It's always good to extract the non-restorable teeth to prevent getting MRONJ in the future.
- II. We don't follow up drug holidays in IV bisphosphonates therefore, not needed to defer the treatment. You can proceed ahead with your plan as it's a low risk case.
- III. Risk of getting MRONJ is higher when we perform dental treatment after the administration of bisphosphonates. So, it's always good to do dental treatment before administration of bisphosphonates.
- IV. Hypercementosis makes the extractions difficult. If hypercementosis is not given as an option, RC treated tooth will be the 2nd best answer.

THIS IS COPYRIGHTED CONTENT. Unauthorized use, including screenshots, copying, misuse, reuse, or resale of any content from this app, is strictly prohibited. Our app monitors and records all screenshots and recordings. Violators will face strict legal action.

THIS IS COPYRIGHTED CONTENT. Unauthorized use, including screenshots, copying, misuse, reuse, or resale of any content from this app, is strictly prohibited. Our app monitors and records all screenshots and recordings. Violators will face strict legal action.

THIS IS COPYRIGHTED CONTENT. Unauthorized use, including screenshots, copying, misuse, reuse, or resale of any content from this app, is strictly prohibited. Our app monitors and records all screenshots and recordings. Violators will face strict legal action.

- V. Amongst the given, aspirin is the life saving drug for heart attack.

DISCLAIMER

THIS IS COPYRIGHTED CONTENT. Unauthorized use, including screenshots, copying, misuse, reuse, or resale of any content from this app, is strictly prohibited. Our app monitors and records all screenshots and recordings. Violators will face strict legal action.

DISCLAIMER

THIS IS COPYRIGHTED CONTENT. Unauthorized use, including screenshots, copying, misuse, reuse, or resale of any content from this app, is strictly prohibited. Our app monitors and records all screenshots and recordings. Violators will face strict legal action.

DISCLAIMER

THIS IS COPYRIGHTED CONTENT. Unauthorized use, including screenshots, copying, misuse, reuse, or resale of any content from this app, is strictly prohibited. Our app monitors and records all screenshots and recordings. Violators will face strict legal action.

ORAL MEDICINE

SBQ 21

PATIENT - WHILE CASUALLY TALKING TO YOU - SAYS HATES GOING TO DENTISTS - EVERY TIME COMING BACK WITH A 'CRUSHING HEADACHE' YOU ASK HER DETAILED HISTORY, SHE SAYS - EVERY TIME I GO TO DENTIST AND GET TREATMENT DONE, I GET PAIN IN MY CHEEKS, TEMPLE N SIDE OF NECK ETC. HAD EARLIER GOT ROOT CANAL FONE OF 4 TEETH - DON'T REMEMBER THE TOOTH NO MAYBE 36 37 46 47 AND CROWNS ALSO

I. You palpated the below areas. In which area the patient might be having pain on palpation?

- A. Over the masseter muscle
- B. Over the coronoid
- C. In front of the external auditory meatus
- D. Superior border of lateral pterygoid muscle

II. What could be the reason?

- A. Muscle tension
- B. Disk derangement
- C. Tmj dysfunction
- D. Muscle inflammation
- E. Malocclusion

III. In the past 3 years - rct and crown done in 4 of the molar teeth - so now what could be the reason for the above history?

- A. Prolonged mouth opening, so muscle tension
- B. Occlusal interferences
- C. Tmj instability

IV. You decide to give her occlusal splints. Why?

- A. To relieve muscles
- B. To correct malocclusion

V. What can be the treatment modality in her case?

- A. Michigan splint
- B. Morning reposition splint
- C. Night guard

THIS IS COPYRIGHTED CONTENT. Unauthorized use, including screenshots, copying, misuse, reuse, or resale of any content from this app, is strictly prohibited. Our app monitors and records all screenshots and recordings. Violators will face strict legal action.

DISCLAIMER

THIS IS COPYRIGHTED CONTENT. Unauthorized use, including screenshots, copying, misuse, reuse, or resale of any content from this app, is strictly prohibited. Our app monitors and records all screenshots and recordings. Violators will face strict legal action.

DISCLAIMER

THIS IS COPYRIGHTED CONTENT. Unauthorized use, including screenshots, copying, misuse, reuse, or resale of any content from this app, is strictly prohibited. Our app monitors and records all screenshots and recordings. Violators will face strict legal action.

THIS IS COPYRIGHTED CONTENT. Unauthorized use, including screenshots, copying, misuse, reuse, or resale of any content from this app, is strictly prohibited. Our app monitors and records all screenshots and recordings. Violators will face strict legal action.

DISCLAIMER

ORAL MEDICINE

P.O.W.E.R NOTES SBQ 21

- I. Patient suffered from cheek pain, temple pain and neck pain after prolonging dental procedures. The diagnosis would be MPDS. In case of MPDS, the patient may feel **over the masseter muscle**, on palpation.

If it's a case of disc derangement, clicking would be present. If clicking is not there, then disc and condyle problem won't be there. If it's a case of disc derangement, pain would be present in front of the external auditory meatus. Lateral pterygoid muscle and coronoid can't be palpate externally.

- II. Reason could be the muscle tension because of the prolong opening.

- III. Occlusal interferences do not lead to MPDS or TMJ problems. Reason could be the muscle tension because of the prolong opening.

- IV. Occlusal splints are given to relieve the muscles because the muscles are tensed and that is why pain is associated with it.

- V. Anterior reposition splint and morning reposition splints are for TMJ problems. Michigan splint is used for MPDS. Night guard is used in bruxism.

all screenshots and recordings. Violators will face strict legal action.

WINSPERT
P.O.W.E.R
NOTES

THIS IS COPYRIGHTED CONTENT. Unauthorized use, including screenshots, copying, misuse, reuse, or resale of any content from this app, is strictly prohibited. Our app monitors and records all screenshots and recordings. Violators will face strict legal action.

THIS IS COPYRIGHTED CONTENT. Unauthorized use, including screenshots, copying, misuse, reuse, or resale of any content from this app, is strictly prohibited. Our app monitors and records all screenshots and recordings. Violators will face strict legal action.

- V. Amongst the given, aspirin is the life saving drug for heart attack.

DISCLAIMER

THIS IS COPYRIGHTED CONTENT. Unauthorized use, including screenshots, copying, misuse, reuse, or resale of any content from this app, is strictly prohibited. Our app monitors and records all screenshots and recordings. Violators will face strict legal action.

ORAL MEDICINE

SBQ 22

ELDERLY PATIENT (AROUND 80YO) IN THE EARLY STAGE OF PARKINSON AND /OR DEMENTIA. HE IS FRAIL BUT NO COGNITIVE DECLINE. HE IS STILL AWARE OR ABLE TO MAKE DECISIONS FOR HIMSELF (SOMETHING LIKE THAT). HE CAME FOR EXTRACTION AND ALSO NEEDED PERIO TREATMENT I THINK. (MY CENTRE DIDN'T MENTION HE IS STILL AWARE OR WHATEVER, IT JUST SAID - HE HAS DEMENTIA AND IN ELDER CARE, WIFE ONLY HAS TO GIVE CONSENT FOR MEDICAL CARE RELATED)

I. Also wife also getting old, so cannot visit often and take care of husband like before. Nurse also keeps changing, so what to do about his oral hygiene status?

- A. Advise the patient to use F tooth paste
- B. Advise patient about mouthwash
- C. Ask wife to attend regularly to maintain husband oral hygiene
- D. Train nurse to take care of his oral hygiene (was framed differently)
- E. You do regular checkup and offer oral hygiene measures (something like that, was framed differently, if someone remembers, please do change appropriately)

II. Daughter informs you that her father won't be attending the next sessions because treatment was too expensive. How you manage?

- A. Offer payment plan (options instead of plan at my center)
- B. Explain to patient the consequences of not continue with treatment
- C. Report elderly abuse to police
- D. Let the pt decide

P.O.W.E.R NOTES SBQ 22

- I. Nurses do get changed every time therefore, we can't depend on the nurse. So, it's good to conduct a seminar in a residential care and train all the nurses who are responsible for these types of patients. So, it will be helpful to maintain the regular oral hygiene.
- II. Payment plans for dental treatments can make managing costs more manageable, especially given that dental care can sometimes be expensive.

THIS IS COPYRIGHTED CONTENT. Unauthorized use, including screenshots, copying, misuse, reuse, or resale of any content from this app, is strictly prohibited. Our app monitors and records all screenshots and recordings. Violators will face strict legal action.

DISCLAIMER

THIS IS COPYRIGHTED CONTENT. Unauthorized use, including screenshots, copying, misuse, reuse, or resale of any content from this app, is strictly prohibited. Our app monitors and records all screenshots and recordings. Violators will face strict legal action.

DISCLAIMER

THIS IS COPYRIGHTED CONTENT. Unauthorized use, including screenshots, copying, misuse, reuse, or resale of any content from this app, is strictly prohibited. Our app monitors and records all screenshots and recordings. Violators will face strict legal action.

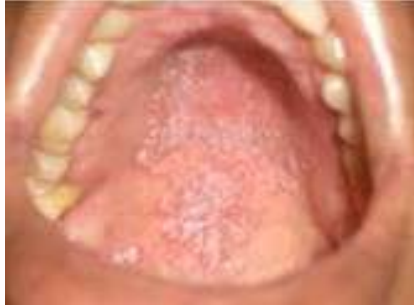THIS IS COPYRIGHTED CONTENT. Unauthorized use, including screenshots, copying, misuse, reuse, or resale of any content from this app, is strictly prohibited. Our app monitors and records all screenshots and recordings. Violators will face strict legal action.

DISCLAIMER

ORAL MEDICINE

SBQ 23

WHITE LESION ON THE PALATE HIV PT - WHITE LESION



- THIS IS COPYRIGHTED CONTENT. Unauthorized use, including screenshots, copying, misuse, reuse, or resale of any content from this app, is strictly prohibited. Our app monitors and records all screenshots and recordings. Violators will face strict legal action.
- A. Candidiasis
 - B. OLP
 - C. Lichenoid reaction
 - D. Erythematous

P.O.W.E.R NOTES SBQ 23

- THIS IS COPYRIGHTED CONTENT. Unauthorized use, including screenshots, copying, misuse, reuse, or resale of any content from this app, is strictly prohibited. Our app monitors and records all screenshots and recordings. Violators will face strict legal action.
- I. • **Candidiasis** is associated with HIV patients. Candidiasis is an opportunistic infection. Opportunistic infections are infections that occur more frequently or are more severe in individuals with weakened immune systems. They are a significant concern for people with conditions such as HIV/AIDS, cancer, or those undergoing immunosuppressive treatments.
 - **OLP** can be seen mostly on the buccal mucosa and it's associated with **Wickham striae**. OLP is not very common in HIV patient.
 - **Lichenoid reaction** is linked with amalgam restorations, antihypertensives, NSAIDs, drugs that treat thyroid disorders etc. (reference: TG pg.no 103)
 - In the given picture, it's a white patch rather than an **erythematous lesion**.
- THIS IS COPYRIGHTED CONTENT. Unauthorized use, including screenshots, copying, misuse, reuse, or resale of any content from this app, is strictly prohibited. Our app monitors and records all screenshots and recordings. Violators will face strict legal action.

THIS IS COPYRIGHTED CONTENT. Unauthorized use, including screenshots, copying, misuse, reuse, or resale of any content from this app, is strictly prohibited. Our app monitors and records all screenshots and recordings. Violators will face strict legal action.

DISCLAIMER

THIS IS COPYRIGHTED CONTENT. Unauthorized use, including screenshots, copying, misuse, reuse, or resale of any content from this app, is strictly prohibited. Our app monitors and records all screenshots and recordings. Violators will face strict legal action.

DISCLAIMER
THIS IS COPYRIGHTED CONTENT. Unauthorized use, including screenshots, copying, misuse, reuse, or resale of any content from this app, is strictly prohibited. Our app monitors and records all screenshots and recordings. Violators will face strict legal action.

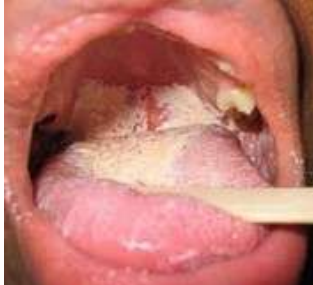THIS IS COPYRIGHTED CONTENT. Unauthorized use, including screenshots, copying, misuse, reuse, or resale of any content from this app, is strictly prohibited. Our app monitors and records all screenshots and recordings. Violators will face strict legal action.

DISCLAIMER

ORAL MEDICINE

SBQ 24

HIV PATIENT PRESENTED WITH THE BELOW LESION IN HIS MOUTH. WHAT CAN BE THE DIAGNOSIS? -----ORAL MED



- A. Candidiasis
- B. OSMF
- C. Lichen planus

P.O.W.E.R NOTES SBQ 24

REFER TO SBQ 23 POWER NOTES FOR EXPLANATION

Our app monitors and records all screenshots and recordings. Violators will face strict legal action.

THIS IS COPYRIGHTED CONTENT. Unauthorized use, including screenshots, copying, misuse, reuse, or resale of any content from this app, is strictly prohibited. Our app monitors and records all screenshots and recordings. Violators will face strict legal action.

THIS IS COPYRIGHTED CONTENT. Unauthorized use, including screenshots, copying, misuse, reuse, or resale of any content from this app, is strictly prohibited. Our app monitors and records all screenshots and recordings. Violators will face strict legal action.

THIS IS COPYRIGHTED CONTENT. Unauthorized use, including screenshots, copying, misuse, reuse, or resale of any content from this app, is strictly prohibited. Our app monitors and records all screenshots and recordings. Violators will face strict legal action.

DISCLAIMER

THIS IS COPYRIGHTED CONTENT. Unauthorized use, including screenshots, copying, misuse, reuse, or resale of any content from this app, is strictly prohibited. Our app monitors and records all screenshots and recordings. Violators will face strict legal action.

DISCLAIMER

THIS IS COPYRIGHTED CONTENT. Unauthorized use, including screenshots, copying, misuse, reuse, or resale of any content from this app, is strictly prohibited. Our app monitors and records all screenshots and recordings. Violators will face strict legal action.

ORAL MEDICINE

SBQ 25

BULIMIC PATIENT WHO VOMITS A LOT. HER PSYCHOTHERAPIST, GEORGE, HAS BEEN UNSUCCESSFUL IN CONTROLLING HER VOMITING HABIT. YOU ARE WORKING IN COORDINATION WITH HER PSYCHIATRIST.

I. How to confirm an active erosion?

- A. Enamel lost lustre on drying
- B. Dentine lost sensitivity on probing with ball end probe
- C. Minimal lingual calculus on mandibular incisors
- D. Basic erosive index less than 2

II. Pt is bulimic and has obsessive cleaning habit using electric brush. What you should give?

- A. Gentle circular motion around teeth
- B. Avoid brushing at least 60 minutes after vomiting

P.O.W.E.R NOTES SBQ 25

- I.
 - Enamel lost lustre on drying or shiny enamel may be due to past incidence of erosion. So, option (A) is ruled out.
 - Loss of dentine sensitivity means that the secondary and tertiary dentine must have been deposited. That shows that erosion has led to that. But it doesn't indicate that the erosion is active/inactive. So, option (B) is ruled out.
 - Absence of lower lingual calculus means that the Ph is considerably lower. When the Ph level is high, calculus deposition is high.
 - Staging indicates only the extent of the damage. It doesn't indicate whether lesions are active or inactive. So, option (D) is ruled out.
- II. Vomiting disorder is linked with erosion. Brushing technique, frequency of brushing and timings of brushing is more important to prevent getting erosions. They should reduce brushing for twice a day. If they need to brush after vomiting due to the altered taste, they must wait for at least 30mins for brushing. Most important thing to do after vomiting is to rinse mouth with water.

THIS IS COPYRIGHTED CONTENT. Unauthorized use, including screenshots, copying, misuse, reuse, or resale of any content from this app, is strictly prohibited. Our app monitors and records all screenshots and recordings. Violators will face strict legal action.

DISCLAIMER

THIS IS COPYRIGHTED CONTENT. Unauthorized use, including screenshots, copying, misuse, reuse, or resale of any content from this app, is strictly prohibited. Our app monitors and records all screenshots and recordings. Violators will face strict legal action.

DISCLAIMER

THIS IS COPYRIGHTED CONTENT. Unauthorized use, including screenshots, copying, misuse, reuse, or resale of any content from this app, is strictly prohibited. Our app monitors and records all screenshots and recordings. Violators will face strict legal action.

THIS IS COPYRIGHTED CONTENT. Unauthorized use, including screenshots, copying, misuse, reuse, or resale of any content from this app, is strictly prohibited. Our app monitors and records all screenshots and recordings. Violators will face strict legal action.

DISCLAIMER

ORAL MEDICINE

SBQ 26

PATIENT IS IMMUNOCOMPROMISED WITH RHEUMATOID ARTHRITIS, TAKES CYCLOSPORINE AND FUROSEMIDE. HE HAS CONTROLLED DIABETES REGULAR ATTENDEE OF YOUR PRACTICE WITH A HISTORY OF GOOD PLAQUE CONTROL. SHE SAYS SHE IS FINDING IT HARD TO BRUSH HER TEETH LATELY BECAUSE OF DECREASING MANUAL DEXTERITY.

I. On her recent visit there is a plaque, What will you advise her for motivation?

- A. Use soft toothbrush
- B. Use an electric toothbrush
- C. Teach her circular movements for tooth brushing
- D. Use of mouth rinse

II. What do you expect to find in her mouth related to her medical condition?

- A. Gingival enlargement
- B. Root caries
- C. Corrugated tongue
- D. Dry Mouth

III. Based on her medical history of rheumatoid arthritis, which of the following is her X-ray?

- A. 4 different tmj X-rays given labelled as A B C D

IV. Pt comes with the complaint that trismus had an interincisal opening of 21 mm, deviation towards right, and also had a history of rheumatoid arthritis. She bit something hard. What may be the cause of this?

- A. Myofascial spasm
- B. Internal derangement of tmj
- C. Post operative infection
- D. Haematoma

THIS IS COPYRIGHTED CONTENT. Unauthorized use, including screenshots, copying, misuse, reuse, or resale of any content from this app, is strictly prohibited. Our app monitors and records all screenshots and recordings. Violators will face strict legal action.

DISCLAIMER

THIS IS COPYRIGHTED CONTENT. Unauthorized use, including screenshots, copying, misuse, reuse, or resale of any content from this app, is strictly prohibited. Our app monitors and records all screenshots and recordings. Violators will face strict legal action.

DISCLAIMER

THIS IS COPYRIGHTED CONTENT. Unauthorized use, including screenshots, copying, misuse, reuse, or resale of any content from this app, is strictly prohibited. Our app monitors and records all screenshots and recordings. Violators will face strict legal action.

THIS IS COPYRIGHTED CONTENT. Unauthorized use, including screenshots, copying, misuse, reuse, or resale of any content from this app, is strictly prohibited. Our app monitors and records all screenshots and recordings. Violators will face strict legal action.

DISCLAIMER

ORAL MEDICINE

P.O.W.E.R NOTES SBQ 26

I. Reference: TG


Maintaining oral hygiene is often hampered by cognitive or physical impairment (e.g. dementia, poor manual dexterity, blindness). Promote oral hygiene the use of powered toothbrush and alcohol-free mouthwash are effective strategies to prevent dental caries and periodontal disease.

II. Reference:

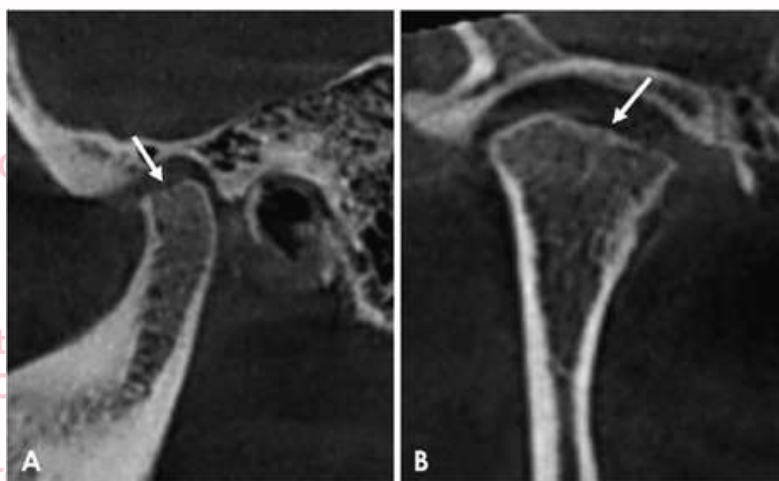
Oral manifestation of rheumatoid arthritis:

vulnerability to periodontitis is confirmed in one of the largest samples ever studied of patients with rheumatoid arthritis (RA). Also, there is evidence of hyposialia (decrease in salivary rate) in RA patients without Sjogren's syndrome.

III. • In case of rheumatoid arthritis radiograph, you would be able to appreciate erosion or absorption of the condyle.



Schematic drawing showing four types of osseous changes in the condyle. Type I, a condyle showing abnormal signal intensity of the bone marrow without erosion or absorption. Type II, a condyle with erosion in the cortex. Type III, a condyle with bone absorption extending within half of the condyle. Type IV, a condyle with bone absorption extending over half of the condyle



strict legal action.

DISCLAIMER

THIS IS COPYRIGHTED CONTENT. Unauthorized use, including screenshots, copying, misuse, reuse, or resale of any content from this app, is strictly prohibited. Our app monitors and records all screenshots and recordings. Violators will face strict legal action.

DISCLAIMER

THIS IS COPYRIGHTED CONTENT. Unauthorized use, including screenshots, copying, misuse, reuse, or resale of any content from this app, is strictly prohibited. Our app monitors and records all screenshots and recordings. Violators will face strict legal action.

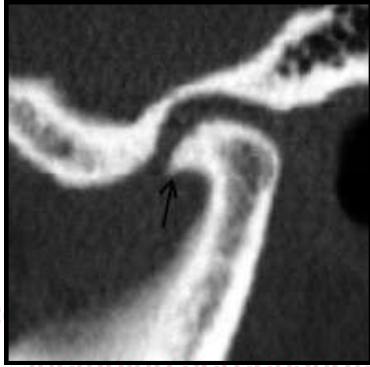THIS IS COPYRIGHTED CONTENT. Unauthorized use, including screenshots, copying, misuse, reuse, or resale of any content from this app, is strictly prohibited. Our app monitors and records all screenshots and recordings. Violators will face strict legal action.

DISCLAIMER

ORAL MEDICINE

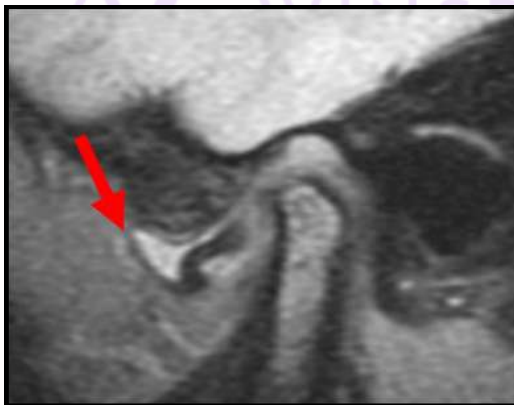P.O.W.E.R NOTES SBQ 26

- III. • In case of osteoarthritis radiograph, you would be able to appreciate Hook-like osteophytes



Osteophytes can form early in the development of OA and can be seen prior to joint space narrowing. Osteophytes can have a significant clinical impact and can be a source of pain and loss of function. The latter mainly through nerve compression, limitation of joint mobility and obstruction of tissues and organs.

- In case of disc derangement without reduction, you would be able to appreciate disc ahead of the condyle both in open and close positions. To see disc derangement MRI is needed. Other radiographs won't be helpful.



- IV. In case of rheumatoid arthritis the condylar gets resorbed so, the disc has got the likeliness to get deranged.

including screenshots, copying, misuse, reuse, or resale of any content from this app, is strictly prohibited. Our app monitors and records all screenshots and recordings. Violators will face strict legal action.

DISCLAIMER

THIS IS COPYRIGHTED CONTENT. Unauthorized use, including screenshots, copying, misuse, reuse, or resale of any content from this app, is strictly prohibited. Our app monitors and records all screenshots and recordings. Violators will face strict legal action.

THIS IS COPYRIGHTED CONTENT. Unauthorized use, including screenshots, copying, misuse, reuse, or resale of any content from this app, is strictly prohibited. Our app monitors and records all screenshots and recordings. Violators will face strict legal action.

THIS IS COPYRIGHTED CONTENT. Unauthorized use, including screenshots, copying, misuse, reuse, or resale of any content from this app, is strictly prohibited. Our app monitors and records all screenshots and recordings. Violators will face strict legal action.

DISCLAIMER
THIS IS COPYRIGHTED CONTENT. Unauthorized use, including screenshots, copying, misuse, reuse, or resale of any content from this app, is strictly prohibited. Our app monitors and records all screenshots and recordings. Violators will face strict legal action.

DISCLAIMER

THIS IS COPYRIGHTED CONTENT. Unauthorized use, including screenshots, copying, misuse, reuse, or resale of any content from this app, is strictly prohibited. Our app monitors and records all screenshots and recordings. Violators will face strict legal action.

ORAL MEDICINE

SBQ 27

LICHENOID LESION CASE:

PICTURE GIVEN. THE PATIENT HAS A HISTORY OF ANTIHYPERTENSIVE DRUGS FOR 10 YRS. THE LESION HAD WHITE LINES ON THE BUCCAL MUCOSA AND ALSO THERE WAS AN AMALGAM RESTORATION ON 37 ASSOCIATED WITH THE LESION. NO HISTORY OF AMALGAM RESTORATION WHEN IT WAS DONE.

I. They were asking the reason for the white lesion. She had bruxism. It looked like linea alba.

- A. Antihypertensives
- B. Amalgams
- C. This is Due to bruxism
- D. Lichen Planus
- E. Lichenoid reaction

II. Another Patient had bruxism and also had Psoriasis. There was a widespread white line on the buccal mucosa. Question asked what the lesion was related to?

- A. Her bruxism
- B. Her psoriasis
- C. Medication

THIS IS COPYRIGHTED
CONTENT. Unauthorized use,
including screenshots,
copying, misuse, reuse, or
resale of any content from
this app, is strictly prohibited.
Our app monitors and records
all screenshots and
recordings. Violators will face
strict legal action.

DISCLAIMER

THIS IS COPYRIGHTED CONTENT. Unauthorized use, including screenshots, copying, misuse, reuse, or resale of any content from this app, is strictly prohibited. Our app monitors and records all screenshots and recordings. Violators will face strict legal action.

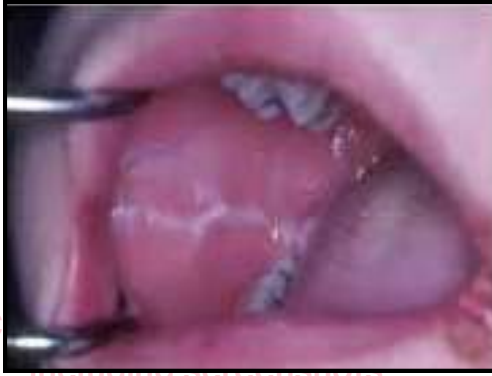DISCLAIMER
THIS IS COPYRIGHTED CONTENT. Unauthorized use, including screenshots, copying, misuse, reuse, or resale of any content from this app, is strictly prohibited. Our app monitors and records all screenshots and recordings. Violators will face strict legal action.

DISCLAIMER
THIS IS COPYRIGHTED CONTENT. Unauthorized use, including screenshots, copying, misuse, reuse, or resale of any content from this app, is strictly prohibited. Our app monitors and records all screenshots and recordings. Violators will face strict legal action.

ORAL MEDICINE

P.O.W.E.R NOTES SBQ 27

- I. Single white line parallel to the occlusal plane would be linear alba/ frictional keratosis. It can happen due to bruxism.



- II. Linear alba is a condition that manifests as a horizontal white line on the inner cheek mucosa. It is associated with chronic irritation or friction, often due to habits such as teeth grinding or clenching, which are common in bruxism.

THIS IS COPYRIGHTED CONTENT. Unauthorized use, including screenshots, copying, misuse, reuse, or resale of any content from this app, is strictly prohibited. Our app monitors and records all screenshots and recordings. Violators will face strict legal action.

DISCLAIMER
THIS IS COPYRIGHTED CONTENT. Unauthorized use, including screenshots, copying, misuse, reuse, or resale of any content from this app, is strictly prohibited. Our app monitors and records all screenshots and recordings. Violators will face strict legal action.

Our app monitors and records all screenshots and recordings. Violators will face strict legal action.

THIS IS COPYRIGHTED CONTENT. Unauthorized use, including screenshots, copying, misuse, reuse, or resale of any content from this app, is strictly prohibited. Our app monitors and records all screenshots and recordings. Violators will face strict legal action.

THIS IS COPYRIGHTED CONTENT. Unauthorized use, including screenshots, copying, misuse, reuse, or resale of any content from this app, is strictly prohibited. Our app monitors and records all screenshots and recordings. Violators will face strict legal action.

DISCLAIMER

THIS IS COPYRIGHTED CONTENT. Unauthorized use, including screenshots, copying, misuse, reuse, or resale of any content from this app, is strictly prohibited. Our app monitors and records all screenshots and recordings. Violators will face strict legal action.

ORAL MEDICINE

SBQ 28

IN THIS SCENARIO THE PATIENT WAS HAVING MEDICAL HISTORY PT WAS TAKING THYROXINE FOR HASHIMOTO'S THYROIDITIS TAKING 100 MCG OF THYROXINE IN THE MORNING, FUROSEMIDE, VIT D FOR OSTEOPOROSIS , INHALED CORTICOSTEROID FOR ASTHMA THERE WERE ANOTHER 3 DRUGS, METHOTREXATE FOR RHEUMATOID ARTHRITIS, HE WAS TAKING WARFARIN ALSO, YOU DIAGNOSE THE CONDITION ON THE PALATE AS PSEUDOMEMBRANOUS CANDIDIASIS . YOU WERE PLANNING TO GIVE MICONAZOLE GEL.

I. Which drug will contraindicate use of miconazole?

- A. Warfarin (in some centres warfarin was not there)
- B. Vit D
- C. Inhaled steroid
- D. Methotrexate
- E. Thyroxine

II. What factors will you consider to give anaesthesia to this patient?

- A. Adrenaline is contraindicated with thyroxine
- B. There is local inflammation in the tissues
- C. Injection of local anaesthesia into the infected site will lead to the spread of infection
- D. Articaine which has good bone penetration is contraindicated in nerve blocks

III. Opg was given on this patient, 38 is the culprit tooth. What will be your management?

- A. You will treat this patient
- B. Refer to the hospital
- C. Refer to oral surgeon

THIS IS COPYRIGHTED CONTENT. Unauthorized use, including screenshots, copying, misuse, reuse, or resale of any content from this app, is strictly prohibited. Our app monitors and records all screenshots and recordings. Violators will face strict legal action.

DISCLAIMER

THIS IS COPYRIGHTED CONTENT. Unauthorized use, including screenshots, copying, misuse, reuse, or resale of any content from this app, is strictly prohibited. Our app monitors and records all screenshots and recordings. Violators will face strict legal action.

DISCLAIMER
THIS IS COPYRIGHTED CONTENT. Unauthorized use, including screenshots, copying, misuse, reuse, or resale of any content from this app, is strictly prohibited. Our app monitors and records all screenshots and recordings. Violators will face strict legal action.

THIS IS COPYRIGHTED CONTENT. Unauthorized use, including screenshots, copying, misuse, reuse, or resale of any content from this app, is strictly prohibited. Our app monitors and records all screenshots and recordings. Violators will face strict legal action.

DISCLAIMER

ORAL MEDICINE

P.O.W.E.R NOTES SBQ 28

- I. Warfarin has major drug interaction with miconazole.

Miconazole, an antifungal medication, can interact with warfarin, a commonly used anticoagulant. The interaction primarily occurs because miconazole can inhibit certain enzymes in the liver that are responsible for metabolizing warfarin. This inhibition can lead to increased levels of warfarin in the blood, which in turn raises the risk of bleeding complications.

- II. **Adrenaline** can exaggerate its reaction (adrenergic effects) when thyroxine is taken by the patient. You must talk to the doctor before using levothyroxine with epinephrine. Combining these medications may increase the risk of CVS side effects such as high blood pressure, palpitations, chest pain and irregular heartbeat. If the patient has pre-existing heart disease; the condition may worsen. Patient may need a dose adjustment or more frequent monitoring by the doctor to safely use both medications.

Adrenaline is completely contraindicated in **uncontrolled hyperthyroidism**.

Local inflammation in the tissue is not a contraindication to give LA.

Plain mepivacaine can be given in these cases. Sometimes very minimal amount of LA with lignocaine can be given. But most importantly need to get the medical practitioners advise in these cases.

- III. Patient is on methotrexate which is an immunosuppressant. Patient also is taking other drugs such as corticosteroids, thyroxine and warfarin which makes medical history complicated. So, this patient should be referred to the specialist.

THIS IS COPYRIGHTED
CONTENT. Unauthorized use,
including screenshots,
copying, misuse, reuse, or
resale of any content from
this app, is strictly prohibited.
Our app monitors and records
all screenshots and
recordings. Violators will face
strict legal action.

DISCLAIMER

THIS IS COPYRIGHTED CONTENT. Unauthorized use, including screenshots, copying, misuse, reuse, or resale of any content from this app, is strictly prohibited. Our app monitors and records all screenshots and recordings. Violators will face strict legal action.

DISCLAIMER

THIS IS COPYRIGHTED CONTENT. Unauthorized use, including screenshots, copying, misuse, reuse, or resale of any content from this app, is strictly prohibited. Our app monitors and records all screenshots and recordings. Violators will face strict legal action.

THIS IS COPYRIGHTED CONTENT. Unauthorized use, including screenshots, copying, misuse, reuse, or resale of any content from this app, is strictly prohibited. Our app monitors and records all screenshots and recordings. Violators will face strict legal action.

DISCLAIMER

ORAL MEDICINE

SBQ 29

ON EXAMINATION 2 LESIONS WERE PRESENT, ONE ON THE VENTRAL SURFACE OF THE TONGUE ON BOTH SIDES AND ONE ON THE LATERAL BORDER CLOSE TO THE FIRST ONE (FOR SOME CENTRES ONE SIDE AND FOR OTHER BOTH SIDES). (TWO LESIONS ON VENTRAL AND LATERAL SURFACE ON SAME SIDE OF TONGUE IN SOME CENTRES) PATIENT IS AN ALCOHOLIC, SMOKER. YOU ARE DOUBTFUL ABOUT THE CONSUMPTION OF THE NUMBER OF DRINKS HE HAS DISCLOSED.

- I. It mentioned both the lesions were non scrapable with white and yellow slough over them. Under differential diagnosis, what will you exclude? (Healing ulcer)
 - A. Lichen planus
 - B. Scc
 - C. Frictional hyperkeratosis
 - D. Pseudomembranous candidiasis
- II. on further examination, you find a broken amalgam restoration next to both lesions. You immediately proceed to treat the fractured restoration. What will be your next step?
 - A. Wait for 2 weeks then refer to specialist
 - B. Wait 1 week then refer to specialist
 - C. Immediately refer to specialist after fixing the restoration
 - D. Wait for 2 months then refer to specialist
- III. Patient is concerned about his health and he says that he wants to manage his alcohol intake. He asks, "Do I have cancer?" What is the best response to this?
 - A. Probably yes, because you smoke and drink a lot
 - B. Probably no, but let's talk about it again (we will check it after 2 weeks and then discuss)
 - C. Unlikely , but we can only know once you're back and after some investigation been done
 - D. No, you don't have cancer
- IV. Patient came back after 2 weeks and the lesion has disappeared. What is the diagnosis?
 - A. Healing ulcer / Healed ulcerations
 - B. S.s.c.
 - C. Leukoplakia
 - D. Frictional hyperkeratosis

DISCLAIMER

THIS IS COPYRIGHTED CONTENT. Unauthorized use, including screenshots, copying, misuse, reuse, or resale of any content from this app, is strictly prohibited. Our app monitors and records all screenshots and recordings. Violators will face strict legal action.

DISCLAIMER

THIS IS COPYRIGHTED CONTENT. Unauthorized use, including screenshots, copying, misuse, reuse, or resale of any content from this app, is strictly prohibited. Our app monitors and records all screenshots and recordings. Violators will face strict legal action.

DISCLAIMER

THIS IS COPYRIGHTED CONTENT. Unauthorized use, including screenshots, copying, misuse, reuse, or resale of any content from this app, is strictly prohibited. Our app monitors and records all screenshots and recordings. Violators will face strict legal action.

ORAL MEDICINE

P.O.W.E.R NOTES SBQ 29

- I. Healing ulcer can be still associated with the white slough.
In the given history, it's a non-scrapable yellow slough. Since pseudomembranous candidiasis is a scrapable lesion, it can be ruled out.
- II. There are "Red Flags" associated with this ulcer. Ulcer is present on the ventral surface and the lateral border of the tongue which are the high-risk areas for the oral cancer. (reference: box12 TG). In case of "Red Flag" features we need to refer the patient to specialist immediately.
- III. We can't say the patient "probably yes" or "probably no" without taking a biopsy. Therefore, need to mention the patient that investigations are needed to give a definitive diagnosis.
- IV. Single white line parallel to the occlusal plane would be linear alba/ frictional keratosis. It can happen due to bruxism. And it will not disappear like that. Lesions present in SCC and leucoplakia will not just disappear in 2 week time like that.
So, it's probably a healing ulcer.

THIS IS COPYRIGHTED CONTENT. Unauthorized use, including screenshots, copying, misuse, reuse, or resale of any content from this app, is strictly prohibited. Our app monitors and records all screenshots and recordings. Violators will face strict legal action.

DISCLAIMER

THIS IS COPYRIGHTED CONTENT. Unauthorized use, including screenshots, copying, misuse, reuse, or resale of any content from this app, is strictly prohibited. Our app monitors and records all screenshots and recordings. Violators will face strict legal action.

THIS IS COPYRIGHTED CONTENT. Unauthorized use, including screenshots, copying, misuse, reuse, or resale of any content from this app, is strictly prohibited. Our app monitors and records all screenshots and recordings. Violators will face strict legal action.

THIS IS COPYRIGHTED CONTENT. Unauthorized use, including screenshots, copying, misuse, reuse, or resale of any content from this app, is strictly prohibited. Our app monitors and records all screenshots and recordings. Violators will face strict legal action.

DISCLAIMER

THIS IS COPYRIGHTED CONTENT. Unauthorized use, including screenshots, copying, misuse, reuse, or resale of any content from this app, is strictly prohibited. Our app monitors and records all screenshots and recordings. Violators will face strict legal action.

DISCLAIMER

THIS IS COPYRIGHTED CONTENT. Unauthorized use, including screenshots, copying, misuse, reuse, or resale of any content from this app, is strictly prohibited. Our app monitors and records all screenshots and recordings. Violators will face strict legal action.

ORAL MEDICINE

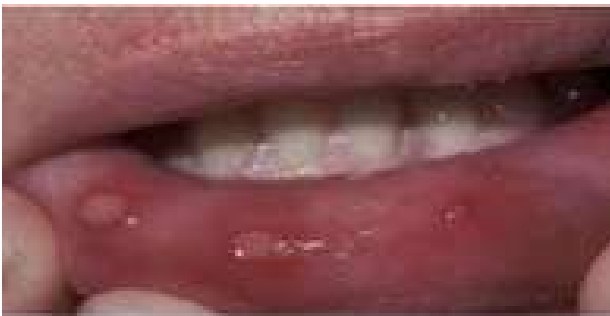SBQ 30

APHTHOUS ULCER CASE

PATIENT RECENTLY GOT TO KNOW THAT SHE HAS MULTIPLE SCLEROSIS AND IS VERY STRESSED AND NEGLECTING THE DIAGNOSIS. SHE HAS STARTED TAKING OCRELIZUMAB.

SHE HAD A PREVIOUS HISTORY OF ULCERS. THE PATIENT HAS HAD FLARE UPS RECENTLY AFTER TREATMENT, SHE HAS PAIN AND DISCOMFORT. SHE COULD NOT GET THE APPOINTMENT FOR HER MEDICAL DOCTOR, THAT'S WHY SHE CAME TO YOU.

PICTURE GIVEN: PATIENT RETRACTING LOWER LIP AND SHOWING 3 MINOR ULCERS ON THE LABIAL MUCOSA.



YOU RESEARCHED ABOUT THE MEDICATION AND THE PHARMACOKINETIC PROPERTIES WERE AS FOLLOWS: IT IS A HUMANIZED ANTI-CD20 MONOCLONAL ANTIBODY. IT TARGETS CD20 MARKERS ON B LYMPHOCYTES. IT TARGETS B CELLS AND DECREASES T CELLS.

I. What category does this drug belong to?

- A. Immunosuppressant
- B. Antimetabolite
- C. Genetic
- D. Metabolic
- E. Antiviral

II. What is the pathological cause of these ulcers?

OR

Due to what discomfort of the oral mucosa she would have come to you?

- A. Atrophic
- B. Dystrophic
- C. Inflammatory
- D. Metabolic
- E. Suppuration(in some centers)
- F. Infection

DISCLAIMER

THIS IS COPYRIGHTED CONTENT. Unauthorized use, including screenshots, copying, misuse, reuse, or resale of any content from this app, is strictly prohibited. Our app monitors and records all screenshots and recordings. Violators will face strict legal action.

DISCLAIMER

THIS IS COPYRIGHTED CONTENT. Unauthorized use, including screenshots, copying, misuse, reuse, or resale of any content from this app, is strictly prohibited. Our app monitors and records all screenshots and recordings. Violators will face strict legal action.

THIS IS COPYRIGHTED CONTENT. Unauthorized use, including screenshots, copying, misuse, reuse, or resale of any content from this app, is strictly prohibited. Our app monitors and records all screenshots and recordings. Violators will face strict legal action.

DISCLAIMER

ORAL MEDICINE

SBQ 30

III. What are the causes of ulcer other than folate deficiency, iron deficiency and zinc deficiency?

- A. Vitamin B12
- B. Vitamin D
- C. Vitamin A
- D. Vitamin C

IV. What will cause you to refer this patient to the specialist?

- A. Pseudomembrane
- B. Indurated margins
- C. Slough
- D. White striation
- E. Suppuration

V. You decide not to give corticosteroids until you have a definite diagnosis. How will you provide (topical) symptomatic relief?

- A. Chlorhexidine 0.12% or 0.2%?
- B. Benzydamine gel
- C. Hydrogen peroxide
- D. Saline
- E. Betamethasone dipropionate

OR

To avoid application of steroids which mouthwash will you recommend to relief pain topically?

- A. Chlorhexidine
- B. Methyl salicylate
- C. Benzydamine
- D. Warm salt water

THIS IS COPYRIGHTED CONTENT. Unauthorized use, including screenshots, copying, misuse, reuse, or resale of any content from this app, is strictly prohibited. Our app monitors and records all screenshots and recordings. Violators will face strict legal action.

DISCLAIMER

THIS IS COPYRIGHTED CONTENT. Unauthorized use, including screenshots, copying, misuse, reuse, or resale of any content from this app, is strictly prohibited. Our app monitors and records all screenshots and recordings. Violators will face strict legal action.

DISCLAIMER
THIS IS COPYRIGHTED CONTENT. Unauthorized use, including screenshots, copying, misuse, reuse, or resale of any content from this app, is strictly prohibited. Our app monitors and records all screenshots and recordings. Violators will face strict legal action.

THIS IS COPYRIGHTED CONTENT. Unauthorized use, including screenshots, copying, misuse, reuse, or resale of any content from this app, is strictly prohibited. Our app monitors and records all screenshots and recordings. Violators will face strict legal action.

DISCLAIMER

ORAL MEDICINE

P.O.W.E.R NOTES SBQ 30

- I. **Ocrelizumab**, sold under the brand name **Ocrevus**, is a medication used for the treatment of multiple sclerosis (MS). It is a humanized anti-CD20 monoclonal antibody.^[8] It targets CD20 marker on B lymphocytes and is an immunosuppressive drug.
- II. Oral aphthous ulcers are mucosal ulcerations with a varied inflammatory infiltrate and large granular lymphocytes. These cells and inflammatory infiltrate predominate in the pre ulcerative and healing phases, keeping this in mind histology can be performed to make a diagnosis.
- III.
 - **Immune System Impact:** Vitamin B12 is important for proper immune function. A deficiency can lead to immune system irregularities, which might contribute to the development of aphthous ulcers.
 - **Cellular Health:** B12 is involved in cell reproduction and repair. Inadequate levels can impair the regeneration of cells in the mucous membranes of the mouth, potentially leading to the formation of ulcers.
 - **Neurological Effects:** B12 deficiency can cause neurological issues, which might affect the mucous membranes and contribute to the development of painful sores.
- IV. Indurated margins are a "RED FLAG" feature, which requires specialist referral. If option (B) is not given, the next best option is white striation. White striations are seen in lichen planus. Any suspicion of lichen planus will make u send the patient to the specialist.
- V. Management of recurrent aphthous ulcer: (reference: TG pg no 109)
 - Hydrocortisone 1% cream or ointment topically to the lesions, 2 to 3 times daily after meals.
 - Benzydamine 1% gel topically to the lesion 2-3 hourly as necessary.
 - Lidocaine 2% viscous solution, use the lowest dose necessary up to 15ml, rinsed in the mouth for 30 seconds then spat out, 3hourly as necessary, maximum 8 doses in 24hours.

Since corticosteroids can't be given, benzydamine option is chosen. Lidocaine 2% viscous solution is given in the hospital set up.

DISCLAIMER

THIS IS COPYRIGHTED CONTENT. Unauthorized use, including screenshots, copying, misuse, reuse, or resale of any content from this app, is strictly prohibited. Our app monitors and records all screenshots and recordings. Violators will face strict legal action.

DISCLAIMER

THIS IS COPYRIGHTED CONTENT. Unauthorized use, including screenshots, copying, misuse, reuse, or resale of any content from this app, is strictly prohibited. Our app monitors and records all screenshots and recordings. Violators will face strict legal action.

THIS IS COPYRIGHTED CONTENT. Unauthorized use, including screenshots, copying, misuse, reuse, or resale of any content from this app, is strictly prohibited. Our app monitors and records all screenshots and recordings. Violators will face strict legal action.

DISCLAIMER

ORAL MEDICINE

SBQ 31

BRUXISM NEW

A 20-25 YEAR OLD BOY FEELS PAIN IN THE RIGHT SIDE. HE HAD ACADEMIC STRESS, HE WAS A MEDICAL STUDENT, AND RECENTLY HAD EXAMS; HAS JAW CLICKING.

I. Which key component defines bruxism?

- A. Excessive tooth wear
- B. Temporo- mandibular disorder
- C. Muscle tenderness

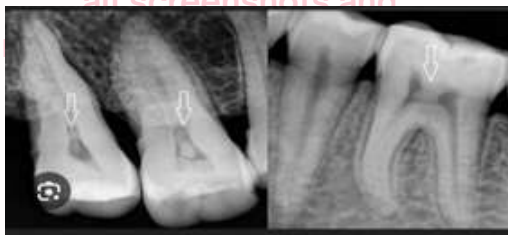II. What is the nature of the patient's pain that supports your diagnosis?

(Type of pain patient will feel in muscles)
OR

What is the pathognomonic type of pain for bruxism?

- A. Sharp
- B. Aching
- C. Stabbing
- D. Burning

III. What are the signs of bruxism seen in OPG and periapicals?



- A. Bone loss
- B. Thick enamel
- C. Pulp stones
- D. Normal thickness enamel surface 3rd molars (no opposing 3rd molars)

IV. Which is the initial treatment you can suggest for sleep bruxism?

- A. Cognitive behavioral therapy
- B. Hard occlusal splint
- C. Soft occlusal splint
- D. Some medications

V. What was the contributing factor to the bruxism condition?

- A. Academic Stress
- B. Malocclusion
- C. TMJ dysfunction

VI. Patient had worn out detention. What question should you ask in history?

- A. Clicking in tmj while opening and closing
- B. Diet and acid consumption
- C. Grinding at night

DISCLAIMER

THIS IS COPYRIGHTED CONTENT. Unauthorized use, including screenshots, copying, misuse, reuse, or resale of any content from this app, is strictly prohibited. Our app monitors and records all screenshots and recordings. Violators will face strict legal action.

DISCLAIMER

THIS IS COPYRIGHTED CONTENT. Unauthorized use, including screenshots, copying, misuse, reuse, or resale of any content from this app, is strictly prohibited. Our app monitors and records all screenshots and recordings. Violators will face strict legal action.

THIS IS COPYRIGHTED CONTENT. Unauthorized use, including screenshots, copying, misuse, reuse, or resale of any content from this app, is strictly prohibited. Our app monitors and records all screenshots and recordings. Violators will face strict legal action.

DISCLAIMER

ORAL MEDICINE

P.O.W.E.R NOTES SBQ 31

- I. Bruxism is not a diagnosis, it's a symptom/sign. Both excessive tooth wear and muscle tenderness define bruxism. But according to the TMJ article toothwear is always present with bruxism and pain may or may not be present with bruxism.. So the most defining feature is toothwear.
- II. In bruxism, tenderness of the muscle or tenderness in TMJ is present which is an aching type of pain. Sharp, shooting stabbing pain is present in pulpal pain. Burning pain is present in BMS, lichen planus and etc.
- III. According to various researches there's no relationship was found between bruxism and pulpal calcification. Thin enamel would be able to appreciate due to tooth wear. Excessive bone deposition and buttress bone deposition is seen instead of bone loss in bruxism.
- IV. Reference: TG pg no. 149/150
 - Sleep bruxism can be managed by avoiding risk factors, relaxation techniques, hypnotherapy, biofeedback, cognitive behavioural therapy and improving oral hygiene.
 - Full coverage extra oral occlusal appliances (splints or dental guards) can be used to protect the teeth from attrition during sleep bruxism.

Among the given, cognitive behavioural therapy is the initial treatment to suggest for sleep bruxism.
- V. Malocclusion is not associated with bruxism. According to the hx, patient is undergoing stress. So, academic stress is the contributing factor for bruxism.
- VI. Based on the given hx (Patient is undergoing stress, pain in the right side and jaw clicking), provision diagnosis would be TMD, involving both disc and muscle. Clicking is already given in the hx so, it's not needed to ask this information again. therefore, option (A) is ruled out. Next important question to ask is the grinding habits. Diet and aid consumption are associated with dental caries and erosion.

THIS IS COPYRIGHTED CONTENT. Unauthorized use, including screenshots, copying, misuse, reuse, or resale of any content from this app, is strictly prohibited. Our app monitors and records all screenshots and recordings. Violators will face strict legal action.

DISCLAIMER

THIS IS COPYRIGHTED CONTENT. Unauthorized use, including screenshots, copying, misuse, reuse, or resale of any content from this app, is strictly prohibited. Our app monitors and records all screenshots and recordings. Violators will face strict legal action.

DISCLAIMER

THIS IS COPYRIGHTED CONTENT. Unauthorized use, including screenshots, copying, misuse, reuse, or resale of any content from this app, is strictly prohibited. Our app monitors and records all screenshots and recordings. Violators will face strict legal action.

DISCLAIMER

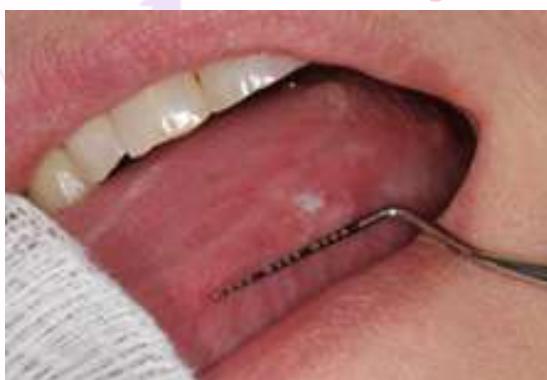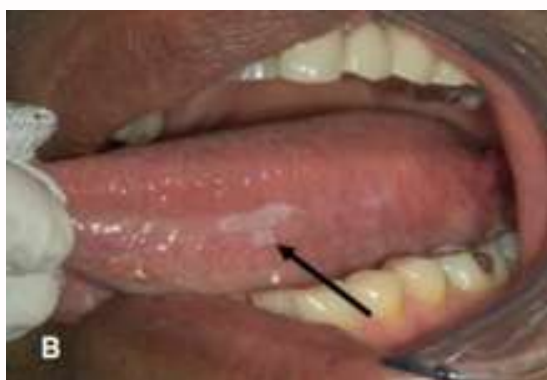THIS IS COPYRIGHTED CONTENT. Unauthorized use, including screenshots, copying, misuse, reuse, or resale of any content from this app, is strictly prohibited. Our app monitors and records all screenshots and recordings. Violators will face strict legal action.

ORAL MEDICINE

SBQ 32

ULCERATION ON TONGUE

PATIENT WITH 2 HOMOGENOUS LESIONS ON THE LATERAL BORDER OF THE TONGUE AND DORSUM OF THE TONGUE. THERE IS HISTORY OF SMOKING AND ALCOHOL USE AND MULTIPLE BROKEN RESTORATION NEXT TO THE LESION. THE LESIONS WERE WHITE AND YELLOW WITHOUT ANY REDNESS AROUND OR INFLAMMATION, THE PATIENT DIDN'T HAVE ANY PAIN. 1ST PIC - LESION WAS MORE WHITISH IN COLOR AND NOT SHINY LIKE IN PIC. 2ND PIC - ALMOST SIMILAR, JUST (1ST PIC - LESION WAS MORE WHITISH IN COLOR AND NOT SHINY LIKE IN PIC) (2ND PIC - ALMOST SIMILAR, JUST 2-3 MM MORE LARGE IN SIZE)



I. What is the likely diagnosis for this lesion?

- A. Candidiasis
- B. Scc
- C. Leukoplakia
- D. Frictional keratosis

II. What is your management after correcting the broken restoration?

- A. Immediately refer to oral specialist after correcting the restoration
- B. Wait for 2 weeks and recall
- C. Wait for 2 months and recall

III. Patient came after 2 weeks and there was no lesion anymore. it was healed.

What is your diagnosis?

- A. Healed aphthous ulcer
- B. Frictional keratosis
- C. Squamous cell carcinoma
- D. Traumatic ulcer

THIS IS COPYRIGHTED CONTENT. Unauthorized use, including screenshots, copying, misuse, reuse, or resale of any content from this app, is strictly prohibited. Our app monitors and records all screenshots and recordings. Violators will face strict legal action.

DISCLAIMER

THIS IS COPYRIGHTED CONTENT. Unauthorized use, including screenshots, copying, misuse, reuse, or resale of any content from this app, is strictly prohibited. Our app monitors and records all screenshots and recordings. Violators will face strict legal action.

DISCLAIMER
THIS IS COPYRIGHTED CONTENT. Unauthorized use, including screenshots, copying, misuse, reuse, or resale of any content from this app, is strictly prohibited. Our app monitors and records all screenshots and recordings. Violators will face strict legal action.

THIS IS COPYRIGHTED CONTENT. Unauthorized use, including screenshots, copying, misuse, reuse, or resale of any content from this app, is strictly prohibited. Our app monitors and records all screenshots and recordings. Violators will face strict legal action.

DISCLAIMER

ORAL MEDICINE

P.O.W.E.R NOTES SBQ 32

- I. pseudomembranous candidiasis is a scrapable lesion, it can be ruled out.
Single white line parallel to the occlusal plane would be linear alba/ frictional keratosis. It can be ruled out.
Both leucoplakia and SCC are associated with alcohol use and smoking.
There are “Red Flags” associated with this ulcer. Ulcer is present on the lateral border of the tongue which is a high-risk area for the oral cancer. Therefore, option (B) is the best answer comparing with option (C).
- II. There is a “Red Flags” associated with this ulcer. Ulcer is present on the lateral border of the tongue which is a high-risk area for the oral cancer. (reference: box12 TG). In case of “Red Flag” features we need to refer the patient to specialist immediately.
- III. Single white line parallel to the occlusal plane would be linear alba/ frictional keratosis. It can happen due to bruxism. And it will not disappear like that. Lesions present in SCC will not just disappear in 2 week time like that. So, it's probably a traumatic ulcer.

DISCLAIMER

THIS IS COPYRIGHTED CONTENT. Unauthorized use, including screenshots, copying, misuse, reuse, or resale of any content from this app, is strictly prohibited. Our app monitors and records all screenshots and recordings. Violators will face strict legal action.

DISCLAIMER

THIS IS COPYRIGHTED CONTENT. Unauthorized use, including screenshots, copying, misuse, reuse, or resale of any content from this app, is strictly prohibited. Our app monitors and records all screenshots and recordings. Violators will face strict legal action.

DISCLAIMER

THIS IS COPYRIGHTED CONTENT. Unauthorized use, including screenshots, copying, misuse, reuse, or resale of any content from this app, is strictly prohibited. Our app monitors and records all screenshots and recordings. Violators will face strict legal action.

ORAL MEDICINE

SBQ 33

PATIENT HAS HYPERTENSION AND CONTROLLED DIABETES TAKING PROPRANOLOL FUROSEMIDE AND POTASSIUM CHLORIDE AND INSULIN, WHAT IS EFFECT OF DRUG ON ORAL HEALTH OR MEDICATION BASED REASON FOR PATIENT'S CARIES RISK

- A. Dry mouth
- B. Gingival enlargement
- C. MRONJ

P.O.W.E.R NOTES SBQ 33

- I. Propranolol is a beta blocker. Furosemide is diuretic. They both cause dry mouth. Antihypertensives are associated with gingival enlargement. Dry mouth is associated caries risk.

THIS IS COPYRIGHTED CONTENT. Unauthorized use, including screenshots, copying, misuse, reuse, or resale of any content from this app, is strictly prohibited. Our app monitors and records all screenshots and recordings. Violators will face strict legal action.

DISCLAIMER

THIS IS COPYRIGHTED CONTENT. Unauthorized use, including screenshots, copying, misuse, reuse, or resale of any content from this app, is strictly prohibited. Our app monitors and records all screenshots and recordings. Violators will face strict legal action.

THIS IS COPYRIGHTED CONTENT. Unauthorized use, including screenshots, copying, misuse, reuse, or resale of any content from this app, is strictly prohibited. Our app monitors and records all screenshots and recordings. Violators will face strict legal action.

THIS IS COPYRIGHTED CONTENT. Unauthorized use, including screenshots, copying, misuse, reuse, or resale of any content from this app, is strictly prohibited. Our app monitors and records all screenshots and recordings. Violators will face strict legal action.

ORAL MEDICINE

SBQ 34

DRY MOUTH

PATIENT NAMED VERMA, IS STRESSED, DRINKS COPIOUS AMOUNTS OF ALCOHOL AND COFFEE. WORK RELATED STRESS AND TAKING SSRI, AS A SIDE EFFECT OF SSRI SHE SWEATS A LOT. OFTEN HAS ALCOHOL AND COFFEE WITH FRIENDS TO RELIEVE HER STRESS AND OCCASIONALLY FEELS DRY.

I. Reason for her dry mouth?

- A. Exercise
- B. Excessive sweating
- C. Stress (in some centers only)
- D. High caffeine intake
- E. Inadequate water intake
- F. Dehydration

II. What advice would you give her to correct her dry mouth ?

- A. Reduce alcohol and caffeine intake
- B. Chewing sugar free gums
- C. Reduce dose SSRI
- D. Salivary substitutes

P.O.W.E.R NOTES SBQ 34

- I. Alcohol, coffee, stress and SSRI are associated with dry mouth and these are given in the patient's hx.

According to TG the below given 5 factors come 1st.

- Dehydration
- Alcohol
- Anxiety
- Mouth breathing
- Drugs

Patient is taking SSRI to control her stress condition. So, her stress is under control. Option (C) is ruled out. The best answer would be (D) among the given options (E) and (F) are not given in the hx. Caffeine is a natural diuretic.

- II. We are not medical practitioners to reduce alter her SSRI dose. All the options (A), (B) and (D) are correct. Among them option (A) is the best answer as we must remove the etiological factor 1st.

DISCLAIMER

THIS IS COPYRIGHTED CONTENT. Unauthorized use, including screenshots, copying, misuse, reuse, or resale of any content from this app, is strictly prohibited. Our app monitors and records all screenshots and recordings. Violators will face strict legal action.

DISCLAIMER

THIS IS COPYRIGHTED CONTENT. Unauthorized use, including screenshots, copying, misuse, reuse, or resale of any content from this app, is strictly prohibited. Our app monitors and records all screenshots and recordings. Violators will face strict legal action.

THIS IS COPYRIGHTED CONTENT. Unauthorized use, including screenshots, copying, misuse, reuse, or resale of any content from this app, is strictly prohibited. Our app monitors and records all screenshots and recordings. Violators will face strict legal action.

DISCLAIMER