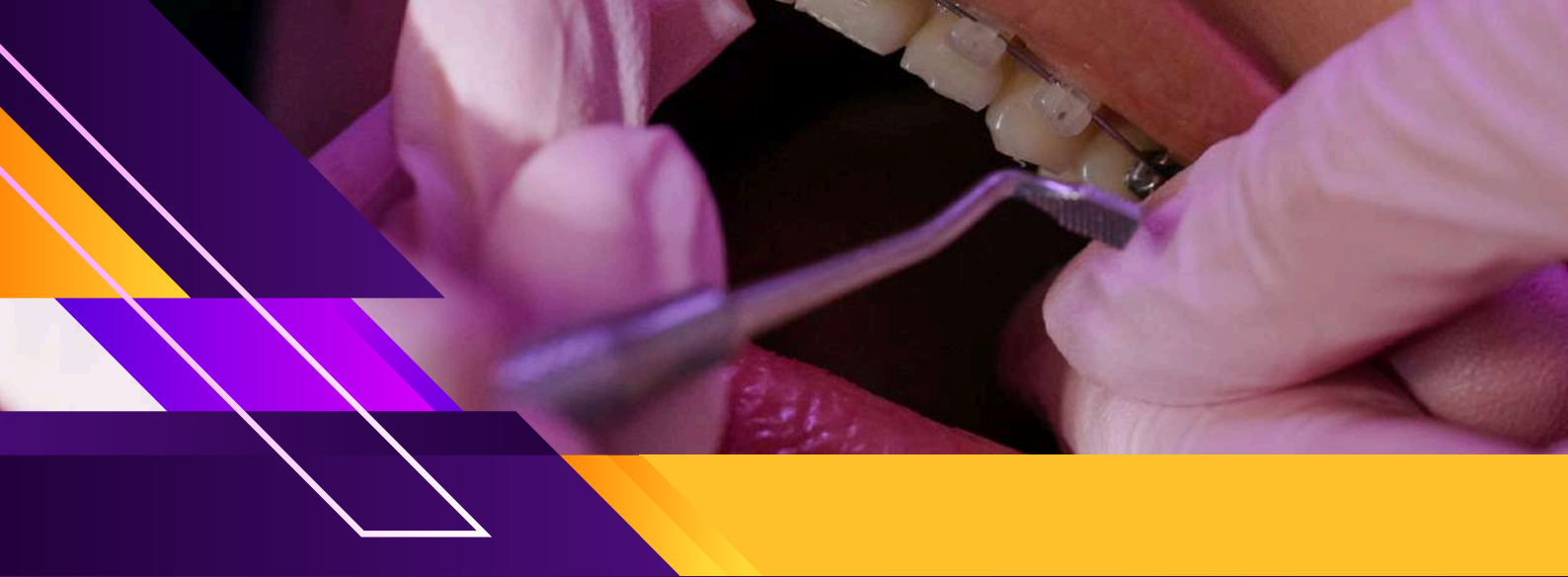



WINSPERT

WINSPERT

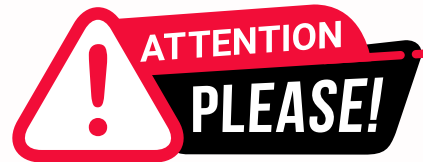P.O.W.E.R

PREPARATION OF ADC WITH WINSPERT EXPERT REVIEW

NOTES

By Dr. Jigyasa Sharma





Dear Students,

We'd like to remind you about the importance of respecting the integrity of the resources provided in our app.

Please be aware that **WINSPERT POWERNOTES ARE COPYRIGHTED CONTENT. Unauthorized use, including screenshots, copying, misuse, reuse, or resale of any content from this app, is strictly prohibited.**

Our app monitors and records all screenshots and recordings. Violators will face strict legal action.

We're committed to providing you with the best tools for your success, and we appreciate your cooperation in maintaining a fair and secure learning environment.

Thank you for your understanding and continued dedication.

Best regards,
WINSPERT TEAM

PERIODONTICS

SBQ 1

PATIENT IS ABOUT 50 YEARS OLD, WITH CHRONIC PERIODONTITIS, BAD ORAL HYGIENE, GREAT AMOUNT OF PLAQUE, GREAT LOSS OF ATTACHMENT, MOBILE TEETH, SMOKER (SMOKING MORE THAN 20 CIGARETTES A DAY) AND HEAVY DRINKER. HE WANTS TO EXTRACT MOBILE TEETH AND RECEIVE A DENTURE TO REPLACE THEM. OPG & INTRA ORAL PIC GIVEN WITH FOLLOWING FINDINGS:

EXCESSIVE CALCULUS DEPOSITS, EXCESSIVE RIDGE DEFECTS, MULTIPLE MISSING TEETH MOSTLY IN UPPER LEFT QUADRANT, FLARED AND DRIFTED UPPER ANTERIOR TEETH, AT LEAST GRADE 2 FURCATION INVOLVEMENT IN ALL MOLARS AND GRADE 3 IN SOME LOWER MOLARS, WHILE GRADE 4 FURCATION OF UPPER RIGHT MOLARS. ROOT STUMPS IN 15. HE WAS A POOR PATIENT (FINANCES WERE MENTIONED). HE WANTED TREATMENT IN THE LIMIT OF EXPENSE. TEETH PRESENT ARE:

UPPER-17 16 15 14 13 12 XX 22 23 24 25

LOWER- 47 46 45 44 43 42 XX 32 33 34 X 36 37 38(HEAVIER DEPOSITS THAN IMAGE PROVIDED)

I. How will you classify the periodontal disease of this patient?

- A. Stage 3 grade B
- B. Stage 3 grade C
- C. Stage 4 grade B
- D. Stage 4 grade C

II. You decide to extract the following teeth 15 16 17 25 47 38. You did initial scaling and the chart was given with all the details and then asked what's the classification now? What will be the classification now? Perio charting provided with excessive pocket depths and CAL.

- A. Stage 3 grade b
- B. Stage 4 grade b
- C. Stage 3 grade c
- D. Stage 2 grade c
- E. Stage 4 grade c

III. What is the Kennedy classification of this patient after extractions ?

- A. Upper Class 1 mod 1 & lower class 2 mod 1
- B. Upper Class 2 mod 2 & lower class 2 mod 2
- C. Upper class 1 mod 2 & lower class 1 mod 2
- D. Upper class 1 mod 1 & lower class 2 mod 2
- E. Class II mod I upper; Class III lower mod 2
- F. Class II mod I upper & Class III lower mod I

DISCLAIMER

THIS IS COPYRIGHTED CONTENT. Unauthorized use, including screenshots, copying, misuse, reuse, or resale of any content from this app, is strictly prohibited. Our app monitors and records all screenshots and recordings. Violators will face strict legal action.

DISCLAIMER

THIS IS COPYRIGHTED CONTENT. Unauthorized use, including screenshots, copying, misuse, reuse, or resale of any content from this app, is strictly prohibited. Our app monitors and records all screenshots and recordings. Violators will face strict legal action.

THIS IS COPYRIGHTED CONTENT. Unauthorized use, including screenshots, copying, misuse, reuse, or resale of any content from this app, is strictly prohibited. Our app monitors and records all screenshots and recordings. Violators will face strict legal action.

DISCLAIMER

PERIODONTICS

SBQ 1

IV. Patient doesn't want to stop smoking and doesn't want to proceed with periodontal treatment. He just wants extraction and replacement of mobile teeth. What will you do?

- A. Proceed with extraction and give prosthesis with everything documented in your notes
- B. Proceed with extractions and give prosthesis with a patient's signature to write off a waiver Refuse treatment until he quit smoking
- C. Refuse treatment until periodontal situation is solved
- D. Refuse treatment until smoking cessation and periodontal treatment is done

V. Which type of denture for each arch is most ideally indicated for this case scenario?

- A. Acrylic or chromium cobalt especially the word ideal treatment
- B. Acrylic upper and cobalt chrome lower
- C. Both upper and lower acrylic
- D. Both cobalt chrome
- E. Cobalt chrome lower acrylic upper
- F. Implant supported fpd
- G. Implant supported rpd

VI. You performed scaling root planing. What will you inform the patient before discharging him? (perio management)

- A. Sensitivity
- B. Pain
- C. Bleeding

THIS IS COPYRIGHTED CONTENT. Unauthorized use, including screenshots, copying, misuse, reuse, or resale of any content from this app, is strictly prohibited. Our app monitors and records all screenshots and recordings. Violators will face strict legal action.

DISCLAIMER

THIS IS COPYRIGHTED CONTENT. Unauthorized use, including screenshots, copying, misuse, reuse, or resale of any content from this app, is strictly prohibited. Our app monitors and records all screenshots and recordings. Violators will face strict legal action.

THIS IS COPYRIGHTED CONTENT. Unauthorized use, including screenshots, copying, misuse, reuse, or resale of any content from this app, is strictly prohibited. Our app monitors and records all screenshots and recordings. Violators will face strict legal action.

THIS IS COPYRIGHTED CONTENT. Unauthorized use, including screenshots, copying, misuse, reuse, or resale of any content from this app, is strictly prohibited. Our app monitors and records all screenshots and recordings. Violators will face strict legal action.

WINSPERT
P.O.W.E.R
NOTES

DISCLAIMER
THIS IS COPYRIGHTED CONTENT. Unauthorized use, including screenshots, copying, misuse, reuse, or resale of any content from this app, is strictly prohibited. Our app monitors and records all screenshots and recordings. Violators will face strict legal action.

PERIODONTICS

P.O.W.E.R NOTES SBQ 1

I. FEATURES OF STAGE IV

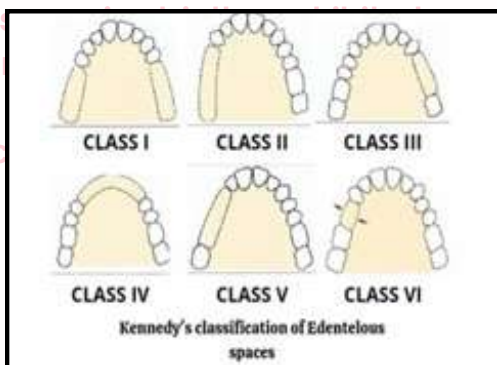
- Masticatory dysfunction
- Secondary occlusal trauma (tooth mobility degree >2)
- Severe ridge defect
- Bite collapse, drifting, flaring
- Less than 20 remaining teeth
- Multiple attachment loss and furcation involvement

So, based on the remaining bone, drifting and flaring you can decide the staging.

According to the given history patient comes under stage IV and grade C as the patient smokes 20 cigarettes per day.

- II. If the smoking is not reduced the grading won't change. Even if we perform Rx, stage will not change.

III.



- IV. Without periodontal stabilisation we can't give a prosthesis as the prosthesis will become more plaque retentive site and it will worsen the patient's condition. Without smoking cessation, we can't proceed ahead with periodontal Rx or another Rx s.

- V. Smoking will remain at a great risk for them. It's a stage 4 grade 3 case. Even after treatment you may not know about the OH maintenance. So in the future if more teeth are needed to be added, then acrylic dentures would be ideal in this case as adding teeth is easier with acrylic.

- VI. Because of shrinkage of gingiva and slight exposure of the cementum/ dentine patient may feel sensitivity after the scaling.

DISCLAIMER

THIS IS COPYRIGHTED CONTENT. Unauthorized use, including screenshots, copying, misuse, reuse, or resale of any content from this app, is strictly prohibited. Our app monitors and records all screenshots and recordings. Violators will face strict legal action.

DISCLAIMER
THIS IS COPYRIGHTED CONTENT. Unauthorized use, including screenshots, copying, misuse, reuse, or resale of any content from this app, is strictly prohibited. Our app monitors and records all screenshots and recordings. Violators will face strict legal action.

THIS IS COPYRIGHTED CONTENT. Unauthorized use, including screenshots, copying, misuse, reuse, or resale of any content from this app, is strictly prohibited. Our app monitors and records all screenshots and recordings. Violators will face strict legal action.

DISCLAIMER

PERIODONTICS

SBQ 2

PATIENT WITH GINGIVITIS HAS NOT BEEN TO A DENTIST FOR 3 YEARS. WE COULD SEE THE ENLARGEMENT AND LOTS OF PLAQUE. THE PATIENT HAD GENERALISED SWELLING (MENTIONED IN THE QUESTION) AND PAIN SINCE FEW (DAYS/WEEKS/MONTHS?). WAS DIAGNOSED WITH EPILEPSY 6 MONTHS BACK AND TAKING DILANTIN SINCE 3 MONTHS (I HAD IT SAYING DILATION FOR 6 MONTHS).PATIENT WAS ALSO ON SSRIS, ESCITALOPRAM 10MG FOR MILD ANXIETY & DEPRESSION. RECENTLY NOTICED GUMS STARTED BLEEDING WHEN SHE CHEWS OR BRUSHES. SPONTANEOUS BLEEDING,(CANNOT REMEMBER WHETHER WE HAD "SPONTANEOUS" WORD BUT IT WAS MENTIONED THAT HAD BLOOD STAINS ON PILLOW) THERE WAS BLOOD ON HER PILLOW. (DIDN'T MENTION ABOUT FEVER OR LYMPHADENOPATHY) (HAD A PICTURE WITH VISIBLE PLAQUE DEPOSITS AND GENERALISED HYPERPLASIA)

- I. What's the cause for her spontaneous bleeding?
 - A. Acute myelogenous leukaemia
 - B. Drug induced gingivitis
 - C. Anug
 - D. Acute periodontal disease
 - E. SSRIs(Escitalopram)
- II. What will you give her to use at home for two weeks?
 - A. 0.12% Chlorhexidine
 - B. 1.5 % H2O2
 - C. Salt water
 - D. Essential oil m/w
- III. Which drug causes gingival enlargement?
 - A. Mao inhibitors
 - B. Phenobarbitone
 - C. Tetracycline
- IV. Dentist wants to know about her condition and also wants to keep baseline records. What investigation does he need to do?
 - A. Opg
 - B. Left and right bitewings
 - C. Periapicals
 - D. OPG & Periapicals
- V. Dentist wants to scale sextant two which has deep pockets. What should he use?
 - A. Sickel Scaler
 - B. Gracey 1 and 2
 - C. Gracey 13 and 14
 - D. Gracey 15 and 16
 - E. Columbia curettes

DISCLAIMER

THIS IS COPYRIGHTED CONTENT. Unauthorized use, including screenshots, copying, misuse, reuse, or resale of any content from this app, is strictly prohibited. Our app monitors and records all screenshots and recordings. Violators will face strict legal action.

DISCLAIMER

THIS IS COPYRIGHTED CONTENT. Unauthorized use, including screenshots, copying, misuse, reuse, or resale of any content from this app, is strictly prohibited. Our app monitors and records all screenshots and recordings. Violators will face strict legal action.

DISCLAIMER

THIS IS COPYRIGHTED CONTENT. Unauthorized use, including screenshots, copying, misuse, reuse, or resale of any content from this app, is strictly prohibited. Our app monitors and records all screenshots and recordings. Violators will face strict legal action.

PERIODONTICS

P.O.W.E.R NOTES SBQ 2

- I. Dilantin is known to cause gingival enlargement. SSRI are not causing gingival enlargement.

GINGIVAL ENLARGEMENT



PLAQUE ENTRAPMENT



SUPERFICIAL INFLAMMATION AND GINGIVITIS



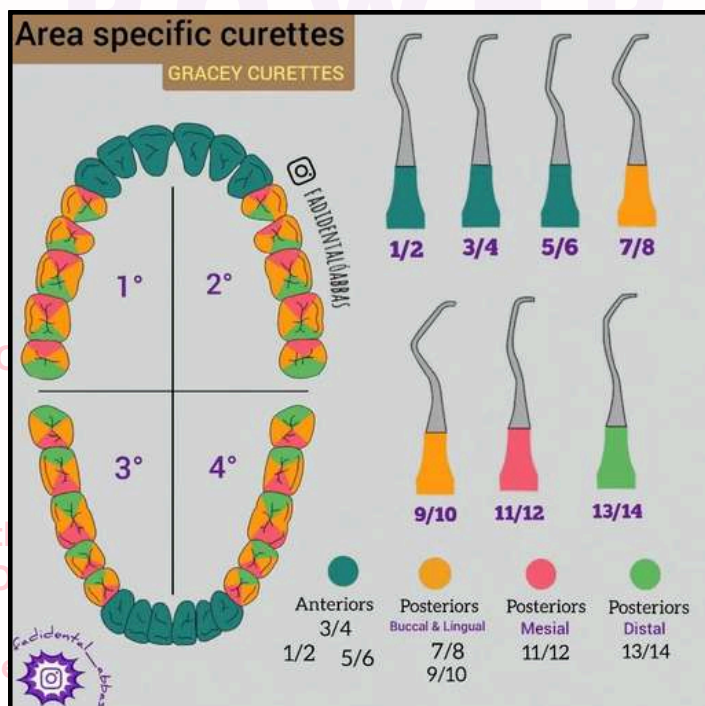
PROFUSE BLEEDING

There's no fever, no lymphadenopathy, no fatigue. Therefore, it's not linked with leukemia.

Based on the signs and symptoms (B) would be the cause.

- II. Among the given CHX is the best for gingivitis. It's given only for 2 weeks as longer use can cause discolouration and taste alteration.
- III. Barbiturates cause gingival enlargement.
- IV. This is gingivitis and not periodontitis. So, we don't require periapical radiographs and bitewings. Only OPG is enough as there's no bone involvement, no attachment loss or no mobility.

V.



DISCLAIMER

THIS IS COPYRIGHTED CONTENT. Unauthorized use, including screenshots, copying, misuse, reuse, or resale of any content from this app, is strictly prohibited. Our app monitors and records all screenshots and recordings. Violators will face strict legal action.

DISCLAIMER
THIS IS COPYRIGHTED CONTENT. Unauthorized use, including screenshots, copying, misuse, reuse, or resale of any content from this app, is strictly prohibited. Our app monitors and records all screenshots and recordings. Violators will face strict legal action.

DISCLAIMER

THIS IS COPYRIGHTED CONTENT. Unauthorized use, including screenshots, copying, misuse, reuse, or resale of any content from this app, is strictly prohibited. Our app monitors and records all screenshots and recordings. Violators will face strict legal action.

PERIODONTICS

SBQ 3

PERIODONTAL SCREENING READING GIVEN TO A PREGNANT PATIENT WHO IS 10 WEEKS PREGNANT. DURING THE BASIC PERIODONTAL EXAMINATION (BPE), SHE SAYS THAT SHE IS DRINKING A LOT OF SUGARY DRINKS, SHE TRIES TO QUIT BUT SHE COULD NOT QUIT AT THIS POINT OF TIME. THERE WAS INFLAMMATION OF MARGINAL GINGIVA AND ROLLED MARGIN. THEY MENTIONED THE DIAGNOSIS AS MILD TO MODERATE MARGINAL GINGIVAL INFLAMMATION WITH THE BPE

BPE SCORES:

2 1 2

1 2 1

I. Based on the readings above, what will be the treatment for her?

- A. Do not do any perio assessment and just give oral hygiene instruction
- B. Do not do any perio assessment and just give scaling and ohi
- C. Complete periodontal assessment and give oral hygiene instructions
- D. Do a complete periodontal assessment and do scaling for her and give ohi
- E. Do a complete periodontal assessment and do scaling and root planing and ohi

II. How will you protect her teeth from sugary drinks?

- A. Ask her to drink the sugar free drink with a straw, immediately Gargle with tap water and ask her to use fluoride toothpaste 5000 ppm twice a day
- B. Ask her drink with the straw and immediately brush with fluoride 1250 ppm toothpaste
- C. Drink sugar free cola with straw, during meals, and gargle with water after the meal, brush 1 hour after with 1450 ppm fluoride toothpaste
- D. Drink cola with straw during meal, gargle with water after the meal, brush 1 hour after with 1450 ppm fluoride toothpaste

III. Clinical signs of gingivitis are:

- A. Inflammation of interdental papilla
- B. Rolled margins
- C. Attached gingiva inflammation
- D. Calculus

IV. She asked about the future child and how to clean the child's teeth?

- A. Brush with 500-550 ppm toothpaste pea sized at 18 months At 24 months brush with 1000 ppm smear of it
- B. Clean with 500-550 ppm FL toothpaste at 6 months of interval.

V. If the dentist were to do a health promotion event. What advice should be in particular to pregnant patients? (Language was similar)

- A. Pregnancy will cause dental caries
- B. Meet your dentist to avoid gum disease
- C. Get the treatment for Periodontal disease (language was a bit different, but it meant this)
- D. Pregnancy always causes gingivitis

DISCLAIMER

THIS IS COPYRIGHTED CONTENT. Unauthorized use, including screenshots, copying, misuse, reuse, or resale of any content from this app, is strictly prohibited. Our app monitors and records all screenshots and recordings. Violators will face strict legal action.

DISCLAIMER

THIS IS COPYRIGHTED CONTENT. Unauthorized use, including screenshots, copying, misuse, reuse, or resale of any content from this app, is strictly prohibited. Our app monitors and records all screenshots and recordings. Violators will face strict legal action.

THIS IS COPYRIGHTED CONTENT. Unauthorized use, including screenshots, copying, misuse, reuse, or resale of any content from this app, is strictly prohibited. Our app monitors and records all screenshots and recordings. Violators will face strict legal action.

DISCLAIMER

PERIODONTICS

P.O.W.E.R NOTES SBQ 3

I.

Probing depth	Observation	BPE Score
Black band completely visible	No probing depths >3.5 mm, no calculus/overhangs, no bleeding after probing	0
Black band completely visible	No probing depths >3.5 mm, no calculus/overhangs, but bleeding after probing	1
Black band completely visible	No probing depths >3.5 mm, but supra- or sub-gingival calculus/overhangs present	2
Black band partially visible	Probing depth(s) of 3.5 – 5.5 mm present	3
Black band entirely within the pocket	Probing depth(s) of 6 mm or more present	4
N/A	Furcation involvement	*

BPE Score	Guidance on Further Assessment and Treatment
0	Periodontal treatment is not required
1	Plaque and gingivitis charting and oral hygiene demonstration.
2	As for code 1 plus remove supra-gingival plaque, calculus and stain, and if necessary sub-gingival plaque and calculus, using an appropriate method.
3	As for code 2 plus full periodontal examination of all teeth and root surface instrumentation where necessary (N.B. Where code 3 is observed in only one sextant, carry out full periodontal examination and root surface instrumentation of affected teeth in that sextant only).
4	As for code 2 plus full periodontal examination of all teeth and root surface instrumentation where necessary (more time is required for root surface instrumentation than for score 3). Assess the need for more complex treatment and consider referral to a specialist.
*	Treatment need will depend on the BPE scores of 0 to 4 for that sextant. Assess the need for more complex treatment and consider referral to a specialist.

DISCLAIMER
THIS IS COPYRIGHTED CONTENT. Unauthorized use, including screenshots, copying, misuse, reuse, or resale of any content from this app, is strictly prohibited. Our app monitors and records all screenshots and recordings. Violators will face strict legal action.

DISCLAIMER

THIS IS COPYRIGHTED CONTENT. Unauthorized use, including screenshots, copying, misuse, reuse, or resale of any content from this app, is strictly prohibited. Our app monitors and records all screenshots and recordings. Violators will face strict legal action.

PERIODONTICS

P.O.W.E.R NOTES SBQ 3

- II. When we compare (A) and (C), (C) is better as it's mentioned to drink cola during the meal.
In option (B) it's mentioned to brush immediately which is not good.
In option (D) the sugar free option is not given.
- III. In gingivitis interdental papilla gets involved before the marginal gingiva.
- IV. According to TG 500-550ppm toothpaste can be used from 18 months to 6 yrs old.
- V. Prevention is better than cure. In health promotion we should promote prevention. Therefore option (B) is better than (C).

including screenshots, copying, misuse, reuse, or resale of any content from this app, is strictly prohibited. Our app monitors and records all screenshots and recordings. Violators will face strict legal action.

THIS IS COPYRIGHTED CONTENT. Unauthorized use, including screenshots, copying, misuse, reuse, or resale of any content from this app, is strictly prohibited. Our app monitors and records all screenshots and recordings. Violators will face strict legal action.

THIS IS COPYRIGHTED CONTENT. Unauthorized use, including screenshots, copying, misuse, reuse, or resale of any content from this app, is strictly prohibited. Our app monitors and records all screenshots and recordings. Violators will face strict legal action.

DISCLAIMER

THIS IS COPYRIGHTED CONTENT. Unauthorized use, including screenshots, copying, misuse, reuse, or resale of any content from this app, is strictly prohibited. Our app monitors and records all screenshots and recordings. Violators will face strict legal action.

DISCLAIMER
THIS IS COPYRIGHTED CONTENT. Unauthorized use, including screenshots, copying, misuse, reuse, or resale of any content from this app, is strictly prohibited. Our app monitors and records all screenshots and recordings. Violators will face strict legal action.

PERIODONTICS

SBQ 4

IMPLANT QUESTION

OPG GIVEN. ON OPG, 25-POST AND CORE WITH 25. IMPLANT ABUTMENT 46. NO CROWN. SHE DIDN'T HAVE MONEY TO COMPLETE TREATMENT THEN. NOW SHE WANTS TO COMPLETE IT. 47 MESIALLY TILTED. PATIENT COMPLAINS OF PAIN ON BITING ON UPPER LEFT REGION AND MOBILITY SINCE THE LAST FEW DAYS. OVERALL HISTORY OF GENERALISED PERIODONTITIS? SMOKING? MEDICAL HISTORY OF OSTEOPOROSIS & TAKING ORAL BISPHOSPHONATES.

I. You examine 25 probing depth on mid buccal-8mm, you find mobility slightly greater than physiological mobility. What is the probable diagnosis?

- A. Irreversible pulpitis
- B. Acute apical periodontitis
- C. Vertical root fracture
- D. Periodontal abscess

II. The patient decided she wants to go with extraction since the tooth is very heavily restored. What will be the most common (High risk) complication which you should inform the patient about? Tooth was heavily restored and the mesial part was completely decayed, even below CEJ)

- A. Infection
- B. Maxillary sinus
- C. Root fracture
- D. Tuberosity fracture

III. She wants to get an implant in its place. What would complicate implant?

- A. Infection
- B. History of past & current periodontitis
- C. Smoking
- D. Osteoporosis
- E. Occlusal trauma

IV. You examine it and it shows slight redness and swelling around the implant and maybe some bleeding on palpation. Probing 6mm distally and 4mm mesially? Looking at the OPG there did not seem any much bone loss, no mobility mentioned in the question.

What is the probable diagnosis for the implant?

- A. Periimplantitis
- B. Peri Implant gingivitis
- C. Peri implant periodontitis
- D. Peri implant mucositis

DISCLAIMER

THIS IS COPYRIGHTED CONTENT. Unauthorized use, including screenshots, copying, misuse, reuse, or resale of any content from this app, is strictly prohibited. Our app monitors and records all screenshots and recordings. Violators will face strict legal action.

DISCLAIMER

THIS IS COPYRIGHTED CONTENT. Unauthorized use, including screenshots, copying, misuse, reuse, or resale of any content from this app, is strictly prohibited. Our app monitors and records all screenshots and recordings. Violators will face strict legal action.

THIS IS COPYRIGHTED CONTENT. Unauthorized use, including screenshots, copying, misuse, reuse, or resale of any content from this app, is strictly prohibited. Our app monitors and records all screenshots and recordings. Violators will face strict legal action.

DISCLAIMER

PERIODONTICS

SBQ 4

V. She wants to get her implant prosthesis. What will you tell regarding implant prosthesis?

- A. Can't restore implant
- B. Take out old and put new implant
- C. Ortho uprighting may be required.
- D. Implants are contraindication to osteoporosis.
- E. Implant can be given but a complex treatment might be required.

VI. How much space required for two implants of 3.5 mm?

- A. 14mm
- B. 17mm
- C. 9mm
- D. 13mm

THIS IS COPYRIGHTED CONTENT. Unauthorized use, including screenshots, copying, misuse, reuse, or resale of any content from this app, is strictly prohibited. Our app monitors and records all screenshots and recordings. Violators will face strict legal action.

DISCLAIMER
THIS IS COPYRIGHTED CONTENT. Unauthorized use, including screenshots, copying, misuse, reuse, or resale of any content from this app, is strictly prohibited. Our app monitors and records all screenshots and recordings. Violators will face strict legal action.

THIS IS COPYRIGHTED CONTENT. Unauthorized use, including screenshots, copying, misuse, reuse, or resale of any content from this app, is strictly prohibited. Our app monitors and records all screenshots and recordings. Violators will face strict legal action.

THIS IS COPYRIGHTED CONTENT. Unauthorized use, including screenshots, copying, misuse, reuse, or resale of any content from this app, is strictly prohibited. Our app monitors and records all screenshots and recordings. Violators will face strict legal action.

THIS IS COPYRIGHTED CONTENT. Unauthorized use, including screenshots, copying, misuse, reuse, or resale of any content from this app, is strictly prohibited. Our app monitors and records all screenshots and recordings. Violators will face strict legal action.

DISCLAIMER

THIS IS COPYRIGHTED CONTENT. Unauthorized use, including screenshots, copying, misuse, reuse, or resale of any content from this app, is strictly prohibited. Our app monitors and records all screenshots and recordings. Violators will face strict legal action.

PERIODONTICS

P.O.W.E.R NOTES SBQ 4

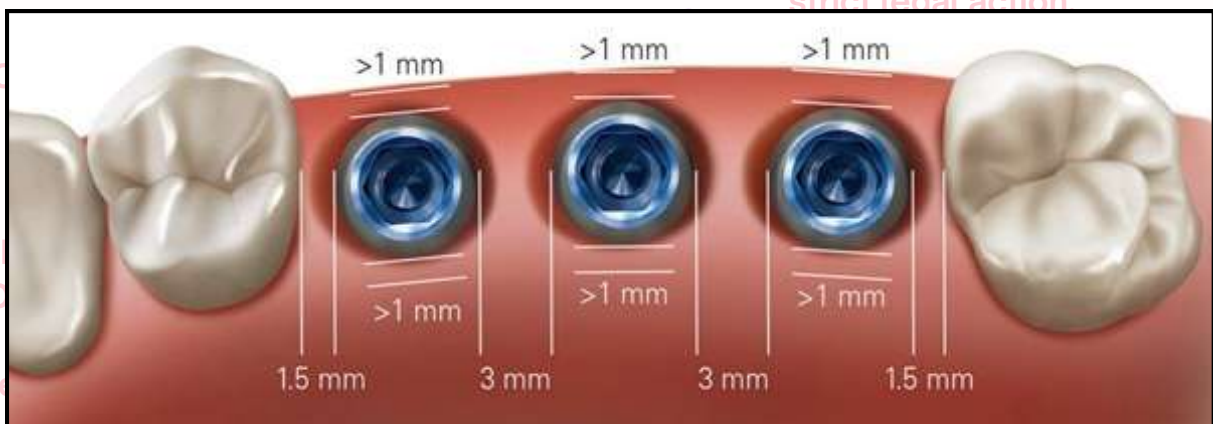
- I. A narrow, vertical deep mid buccal probing depth confined to the one surface of the tooth with mobility and slight pain on biting in a post treated tooth gives the diagnosis of VRF.
- II. It's a heavily restored, post core treated tooth with a VRF and has a high risk of root fracture. Bone preservation during exodontia is the most important factor. Infection is less likely due to aseptic techniques. Maxillary sinus communication is not a risk or complication that we need to inform the patient about. Premolar is not associated with the tuberosity fracture.
- III. Once the causative factor for the infection is removed, there won't be infection afterwards. Smoking and osteoporosis are not absolute complications. Traumatic occlusion from the opposing tooth can be corrected. Past history of periodontitis would not be a complication as the now the disease is under control. But the current periodontitis will hamper the implant osseointegration. Plaque retention and poor OH is the greatest risk factor for implants. With the drug planning, implants can be given for patients with osteoporosis and who are on bisphosphonates. Even for smokers' implants can be given with controlling smoking.

ABSOLUTE CONTRAINDICATION FOR IMPLANTS:

- Plaque and poor OH
- Terminally ill patients

- IV. Even though it's mentioned about 6mm of probing depth, there's no bone loss and no mobility. Only soft tissue involvement. There's no baseline record of more than 0.2mm of bone loss annually. Up to 0.2mm of bone loss is normal. Therefore, the diagnosis is peri implant mucositis. Option (B) and (C) are incorrect terms.
- V. There's no space for crown placement as the adjacent tooth is mesially tilted. Therefore, orthodontic up righting is required before crown placement. If option (C) is not given, next best option is (E).

VI.



DISCLAIMER

THIS IS COPYRIGHTED CONTENT. Unauthorized use, including screenshots, copying, misuse, reuse, or resale of any content from this app, is strictly prohibited. Our app monitors and records all screenshots and recordings. Violators will face strict legal action.

DISCLAIMER
THIS IS COPYRIGHTED CONTENT. Unauthorized use, including screenshots, copying, misuse, reuse, or resale of any content from this app, is strictly prohibited. Our app monitors and records all screenshots and recordings. Violators will face strict legal action.

DISCLAIMER
THIS IS COPYRIGHTED CONTENT. Unauthorized use, including screenshots, copying, misuse, reuse, or resale of any content from this app, is strictly prohibited. Our app monitors and records all screenshots and recordings. Violators will face strict legal action.

PERIODONTICS

SBQ 5

PATIENT HAD POOR ORAL HYGIENE AND POOR PERIODONTAL HEALTH.37 (MOST DISTAL TOOTH) (IT WAS MESIALLY TILTED WITH AN APPARENT UNDERCUT LOCATED MESIALLY AND FLAT SURFACE DISTALLY) AFTER EXTRACTION OF 34, 35 AND 38 (36 ALREADY MISSING) ON OPG?

I. Which clasp would be given on 37 (most distal tooth) (it was mesially tilted with an apparent undercut located mesially and flat surface distally) after extraction of 34, 35 and 38 (36 already missing) on opg?

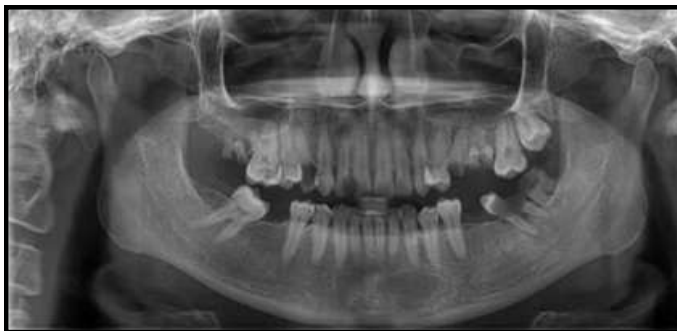- A. Ring clasp
- B. Roach clasp
- C. C clasp
- D. I Bar
- E. Infrabulge clasp

II. In the OPG Findings:

25 was root stumps which were rct treated (in some centres 26 also as root stumps), you decide to extract 38 now.

What would you explain the patient about future extractions, what would be the risk (not complication) of the future extractions?

(Almost similar OPG except 37 was tilted but no caries)



- A. Root Fracture
- B. Oroantral communication
- C. Bleeding
- D. Fracture of zygomatic buttress
- E. It's lying in close proximity to the distal tooth.

III. There is an associated pimple with 25, its asymptomatic & no tenderness on percussion, what would be the diagnosis with 25, the pimple would come and go. What would be the diagnosis?

- A. Chronic periapical abscess
- B. Acute periapical abscess
- C. Acute periapical periodontitis
- D. Chronic periapical periodontitis

DISCLAIMER

THIS IS COPYRIGHTED CONTENT. Unauthorized use, including screenshots, copying, misuse, reuse, or resale of any content from this app, is strictly prohibited. Our app monitors and records all screenshots and recordings. Violators will face strict legal action.

DISCLAIMER

THIS IS COPYRIGHTED CONTENT. Unauthorized use, including screenshots, copying, misuse, reuse, or resale of any content from this app, is strictly prohibited. Our app monitors and records all screenshots and recordings. Violators will face strict legal action.

THIS IS COPYRIGHTED CONTENT. Unauthorized use, including screenshots, copying, misuse, reuse, or resale of any content from this app, is strictly prohibited. Our app monitors and records all screenshots and recordings. Violators will face strict legal action.

PERIODONTICS

SBQ 5

IV. What could be the possible reason for this condition?

- A. Attachment loss predominantly
- B. Due to root stumps
- C. RCT failure

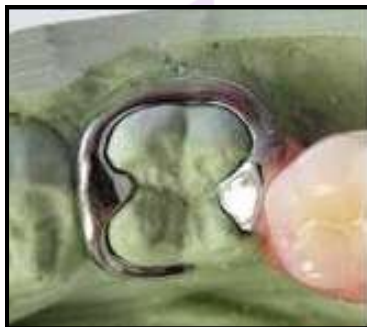P.O.W.E.R NOTES SBQ 5

I. There's a mesial edentulous space for 37 and it's mesially tilted. Undercut of 37 lies mesially adjacent to the edentulous space.

Options (B), (D) and (E) are similar types and these are not indicated for a tilted tooth. C-clasp is also not indicated for a tilted tooth. Ring clasp is suitable for a tilted tooth.

RING CLASP:

- Encircles nearly the abutment tooth
- Usually used with mesially and lingually tilted mandibular molars (with a ML undercut) or mesially and buccally tilted maxillary molars (with a MB undercut).
- The undercut is on the same side as the rest seat. (i.e adjacent to the edentulous span)



II. Root stumps should be removed in the next appointment. Root fracture is the complication associated with it, which you must explain the patient.

III. Associated pimple with 25 denotes a soft tissue involvement, therefore, it's an abscess. It's asymptomatic and non-tender. So, it's a chronic condition. Diagnosis is chronic periapical abscess.

IV. It's an RCT tooth associated with a periapical abscess. It happens due to RCT failure.

DISCLAIMER

THIS IS COPYRIGHTED CONTENT. Unauthorized use, including screenshots, copying, misuse, reuse, or resale of any content from this app, is strictly prohibited. Our app monitors and records all screenshots and recordings. Violators will face strict legal action.

PERIODONTICS

SBQ 6

IN A PATIENT WITH SEVERE PERIODONTITIS AND HbA1C 7 PERCENT. WHAT DOES DIABETES HAVE ON PERIODONTAL DISEASE?

- A. Minimal as long as diabetes is well controlled
- B. Minimal with periodontal care.
- C. Significant as periodontal condition will decline
- D. Significant coz of diabetes medications in long

P.O.W.E.R NOTES SBQ 6

- I. HbA1c is 7, which means grade C. so, the periodontal condition is significant. Medication doesn't have an effect on periodontitis, but the blood glucose level has. So, option (C) is correct.

this app, is strictly prohibited. Our app monitors and records all screenshots and recordings. Violators will face strict legal action.

THIS IS COPYRIGHTED CONTENT. Unauthorized use, including screenshots, copying, misuse, reuse, or resale of any content from this app, is strictly prohibited. Our app monitors and records all screenshots and recordings. Violators will face strict legal action.

THIS IS COPYRIGHTED CONTENT. Unauthorized use, including screenshots, copying, misuse, reuse, or resale of any content from this app, is strictly prohibited. Our app monitors and records all screenshots and recordings. Violators will face strict legal action.

DISCLAIMER

THIS IS COPYRIGHTED CONTENT. Unauthorized use, including screenshots, copying, misuse, reuse, or resale of any content from this app, is strictly prohibited. Our app monitors and records all screenshots and recordings. Violators will face strict legal action.

DISCLAIMER
THIS IS COPYRIGHTED CONTENT. Unauthorized use, including screenshots, copying, misuse, reuse, or resale of any content from this app, is strictly prohibited. Our app monitors and records all screenshots and recordings. Violators will face strict legal action.

PERIODONTICS

SBQ 7

THE DENTIST DECIDES TO DIVIDE TREATMENT WITH ORAL HYGIENIST/THERAPIST WORKING IN YOUR CLINIC, HOW TREATMENT CAN BE DIVIDED?

- A. Dentist retains full responsibility of overall treatment
- B. Oht take full responsibility of treatment
- C. Dentist only put oral hygiene responsibility on oht
- D. Dentist take full responsibility of counselling or instruction or rx done by oht
- E. Dentist shares the work responsibility for that specific period and is not responsible for the decisions made by hygienist
- F. Dentist takes full responsibility and instruct to the oral hygienist for the management

P.O.W.E.R NOTES SBQ 7

I. DELEGATION

Delegation involves one practitioner asking another person or member or staff to provide care on behalf of the delegating practitioner while the practitioner retains overall responsibility for the care of the patient or client.

GOOD PRACTICE INVOLVES:

- Taking reasonable steps to ensure that any person to whom a practitioner delegates, refers or handover has the qualifications and/ or experience and/ or knowledge and/ or skills to provide the care required.
- The delegating practitioner remains responsible for the overall management of the patient or client and for the decision to delegate.

THIS IS COPYRIGHTED CONTENT. Unauthorized use, including screenshots, copying, misuse, reuse, or resale of any content from this app, is strictly prohibited. Our app monitors and records all screenshots and recordings. Violators will face strict legal action.

DISCLAIMER

THIS IS COPYRIGHTED CONTENT. Unauthorized use, including screenshots, copying, misuse, reuse, or resale of any content from this app, is strictly prohibited. Our app monitors and records all screenshots and recordings. Violators will face strict legal action.

DISCLAIMER
THIS IS COPYRIGHTED CONTENT. Unauthorized use, including screenshots, copying, misuse, reuse, or resale of any content from this app, is strictly prohibited. Our app monitors and records all screenshots and recordings. Violators will face strict legal action.

THIS IS COPYRIGHTED CONTENT. Unauthorized use, including screenshots, copying, misuse, reuse, or resale of any content from this app, is strictly prohibited. Our app monitors and records all screenshots and recordings. Violators will face strict legal action.

DISCLAIMER

PERIODONTICS

SBQ 8

OPG GIVEN

36 BONE LOSS ALL AROUND ROOTS INVOLVING FURCATION AREA (IT WAS MOBILE) 36 AND 37 HAS MILD POCKET 46 BONE LOSS AROUND ONE ROOT AND FURCATION. DISTAL ROOT FINE, 47, 35 MISSING.

I. How to identify the tooth with questionable to hopeless prognosis

- A. Grade 3 mobility
- B. Furcation grade 3
- C. Furcation grade 3 and vertical bone Loss 3mm
- D. Pocket depth 7 mm

II. You would like to assess the stage of progression of disease for this patient. How to assess, without previous record or x-ray.

- A. Check the clinical attachment loss
- B. Bleeding on probing
- C. Plaque index
- D. Radiographic bone loss

III. BPE scoring was given

4* 3* 3*
4* 3* 4*
(*furcation involvement)

- A. Localized periodontitis
- B. Generalized perio
- C. 6 point probing of all the teeth in all quadrant
- D. Mobility

IV. Clinical attachment lost- gingival recession- 3 and pocket 4

- A. 4
- B. 3
- C. 7

THIS IS COPYRIGHTED CONTENT. Unauthorized use, including screenshots, copying, misuse, reuse, or resale of any content from this app, is strictly prohibited. Our app monitors and records all screenshots and recordings. Violators will face strict legal action.

DISCLAIMER

THIS IS COPYRIGHTED CONTENT. Unauthorized use, including screenshots, copying, misuse, reuse, or resale of any content from this app, is strictly prohibited. Our app monitors and records all screenshots and recordings. Violators will face strict legal action.

DISCLAIMER
THIS IS COPYRIGHTED CONTENT. Unauthorized use, including screenshots, copying, misuse, reuse, or resale of any content from this app, is strictly prohibited. Our app monitors and records all screenshots and recordings. Violators will face strict legal action.

THIS IS COPYRIGHTED CONTENT. Unauthorized use, including screenshots, copying, misuse, reuse, or resale of any content from this app, is strictly prohibited. Our app monitors and records all screenshots and recordings. Violators will face strict legal action.

DISCLAIMER

PERIODONTICS

P.O.W.E.R NOTES SBQ 8

- I. Hopeless prognosis: something that goes for extraction immediately.
 Good prognosis: you can save the tooth.
 Questionable prognosis: you can treat the tooth but you are not sure whether it's saveable or not.
 Questionable to hopeless prognosis: you can do the treatment and may be able to save the tooth but at the same time there's a risk that the tooth may require extraction.
 Grade 3 mobility – hopeless prognosis
 Pocket depth 7mm- fair prognosis (re attachment can be achieved with graft techniques)
 Furcation grade 3- questionable prognosis
 Furcation grade 3 and vertical one loss 3mm- questionable prognosis but going towards hopeless.
- II. Either you need the bone loss or the attachment loss to get to know the staging.
- III. BPE score 0-2: periodontal chart is not required.
 BPE score 3-4: periodontal chart is required.
 In periodontal chart 6-point probing depth of all teeth, bleeding, furcation involvement, recession and mobility is recorded.
- IV. CAL= probing dept + gingival recession

THIS IS COPYRIGHTED CONTENT. Unauthorized use, including screenshots, copying, misuse, reuse, or resale of any content from this app, is strictly prohibited. Our app monitors and records all screenshots and recordings. Violators will face strict legal action.

DISCLAIMER

THIS IS COPYRIGHTED CONTENT. Unauthorized use, including screenshots, copying, misuse, reuse, or resale of any content from this app, is strictly prohibited. Our app monitors and records all screenshots and recordings. Violators will face strict legal action.

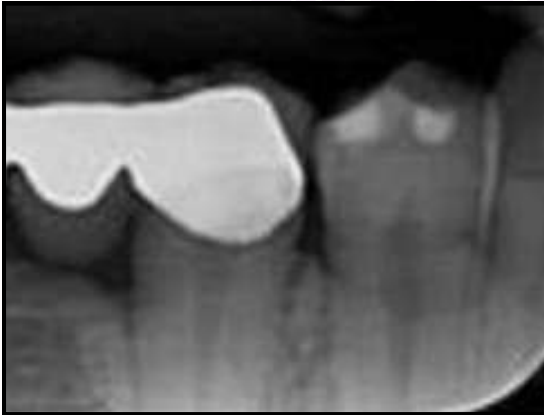THIS IS COPYRIGHTED CONTENT. Unauthorized use, including screenshots, copying, misuse, reuse, or resale of any content from this app, is strictly prohibited. Our app monitors and records all screenshots and recordings. Violators will face strict legal action.

DISCLAIMER
 THIS IS COPYRIGHTED CONTENT. Unauthorized use, including screenshots, copying, misuse, reuse, or resale of any content from this app, is strictly prohibited. Our app monitors and records all screenshots and recordings. Violators will face strict legal action.

PERIODONTICS

SBQ 9

LADY WITH UNSUPPORTED PFM BRIDGE. TREATMENT WAS SIMILAR TO THAT ONE, NOT THE SAME. ALSO SHE SAID THAT THE PROBE WAS NOT DEEPER THAN A SHADED PART. IT HAS A CANTILEVERS BRIDGE IRT 43 44 45 (RADIOPAQUE AREA OF BONE IT WAS DENSE IN CERVICAL 1/3 AREA) (VISIBLE IN THE IOPA AROUND 43, 44).



I. What is the reason for the radiopaque dense area of bone ?

- A. Calculus
- B. Paget's disease
- C. Condensing osteitis

II. Best fulcrum line to probe disto labial of tooth 21 (which fulcrum is to probe the area of disto labial wrt 11)

- A. Chin
- B. Upper arch
- C. Lower arch
- D. Finger on finger
- E. Zygoma

III. What would you ask the patient to know more about the case?

- A. Last visit to the dentist for scaling

IV. Clinical attachment loss asked?

- A. Gingival recession 3mm
- B. Pocket depth 4mm
- C. 7mm

THIS IS COPYRIGHTED CONTENT. Unauthorized use, including screenshots, copying, misuse, reuse, or resale of any content from this app, is strictly prohibited. Our app monitors and records all screenshots and recordings. Violators will face strict legal action.

DISCLAIMER
THIS IS COPYRIGHTED CONTENT. Unauthorized use, including screenshots, copying, misuse, reuse, or resale of any content from this app, is strictly prohibited. Our app monitors and records all screenshots and recordings. Violators will face strict legal action.

DISCLAIMER

THIS IS COPYRIGHTED CONTENT. Unauthorized use, including screenshots, copying, misuse, reuse, or resale of any content from this app, is strictly prohibited. Our app monitors and records all screenshots and recordings. Violators will face strict legal action.

THIS IS COPYRIGHTED CONTENT. Unauthorized use, including screenshots, copying, misuse, reuse, or resale of any content from this app, is strictly prohibited. Our app monitors and records all screenshots and recordings. Violators will face strict legal action.

DISCLAIMER

PERIODONTICS

P.O.W.E.R NOTES SBQ 9

- I. Condensing osteitis is seen in the apical level. Can't be Paget's bone disease.
- II. DESCRIPTION OF THE VARIOUS INTRA ORAL FINGER RESTS:
 Conventional rest: here, finger rest is established on the tooth surface immediately adjacent to the working area.
 Cross arch rest: in this case finger rest is established on the tooth surface on the other side of the same arch.
 Opposite arch: finger rest is established on the tooth surface of the opposite arch, for an example while working on the maxillary arch, finger rest is established on the mandibular arch.
 Finger on finger rest: it's established on the thumb or index finger of the non-operating hand.
- III. Since the patient has a cantilever bridge and calculus deposits it's good to know when was the last FMS was done.
- IV. CAL= probing dept + gingival recession

THIS IS COPYRIGHTED CONTENT. Unauthorized use, including screenshots, copying, misuse, reuse, or resale of any content from this app, is strictly prohibited. Our app monitors and records all screenshots and recordings. Violators will face strict legal action.

DISCLAIMER

THIS IS COPYRIGHTED CONTENT. Unauthorized use, including screenshots, copying, misuse, reuse, or resale of any content from this app, is strictly prohibited. Our app monitors and records all screenshots and recordings. Violators will face strict legal action.

THIS IS COPYRIGHTED CONTENT. Unauthorized use, including screenshots, copying, misuse, reuse, or resale of any content from this app, is strictly prohibited. Our app monitors and records all screenshots and recordings. Violators will face strict legal action.

DISCLAIMER
THIS IS COPYRIGHTED CONTENT. Unauthorized use, including screenshots, copying, misuse, reuse, or resale of any content from this app, is strictly prohibited. Our app monitors and records all screenshots and recordings. Violators will face strict legal action.

PERIODONTICS

SBQ 10

PATIENT COMPLAINS OF BAD TASTE IN THE LOWER LEFT AREA? WHICH TEST WILL HELP YOU TO DIAGNOSE HER CONDITION?

- A. Bite wing and IOPA
 - B. Sensibility test
 - C. Percussion
- Ps: *Probing wasn't an option.

P.O.W.E.R NOTES SBQ 10

- I. If probing was given as an option that would be the best answer as it helps to determine the presence of the periodontal pockets. Periodontal pockets lead to food impaction and bad breath/ bad taste.
Bitewing and IOPA will be helpful to see the bone loss.

THIS IS COPYRIGHTED CONTENT. Unauthorized use, including screenshots, copying, misuse, reuse, or resale of any content from this app, is strictly prohibited. Our app monitors and records all screenshots and recordings. Violators will face strict legal action.

THIS IS COPYRIGHTED CONTENT. Unauthorized use, including screenshots, copying, misuse, reuse, or resale of any content from this app, is strictly prohibited. Our app monitors and records all screenshots and recordings. Violators will face strict legal action.

THIS IS COPYRIGHTED CONTENT. Unauthorized use, including screenshots, copying, misuse, reuse, or resale of any content from this app, is strictly prohibited. Our app monitors and records all screenshots and recordings. Violators will face strict legal action.

DISCLAIMER

THIS IS COPYRIGHTED CONTENT. Unauthorized use, including screenshots, copying, misuse, reuse, or resale of any content from this app, is strictly prohibited. Our app monitors and records all screenshots and recordings. Violators will face strict legal action.

DISCLAIMER
THIS IS COPYRIGHTED CONTENT. Unauthorized use, including screenshots, copying, misuse, reuse, or resale of any content from this app, is strictly prohibited. Our app monitors and records all screenshots and recordings. Violators will face strict legal action.

PERIODONTICS

SBQ 11

PATIENT WITH PERIODONTITIS THAT USES WHICH OTHER HYGIENE TOOL HE WAS MISSING TO USE? OPEN SPACES BETWEEN TEETH.

- A. Water Floss
- B. Pikster
- C. Electric toothbrush
- D. Mouthwash AND interdental toothbrushes
- E. Interdental toothpicks

P.O.W.E.R NOTES SBQ 11

- I. For interdental cleaning interdental brushes and dental floss are used. Interdental brush is used for the open spaces between the teeth whereas dental floss is used for the tight contacts.
Regular dental floss is superior to the water floss.
According to TG mouth wash is not recommended on daily basis.
“**Pickster**” is a brand name for interdental brushes which can be used in the open space between the teeth.

THIS IS COPYRIGHTED CONTENT. Unauthorized use, including screenshots, copying, misuse, reuse, or resale of any content from this app, is strictly prohibited. Our app monitors and records all screenshots and recordings. Violators will face strict legal action.

THIS IS COPYRIGHTED CONTENT. Unauthorized use, including screenshots, copying, misuse, reuse, or resale of any content from this app, is strictly prohibited. Our app monitors and records all screenshots and recordings. Violators will face strict legal action.

THIS IS COPYRIGHTED CONTENT. Unauthorized use, including screenshots, copying, misuse, reuse, or resale of any content from this app, is strictly prohibited. Our app monitors and records all screenshots and recordings. Violators will face strict legal action.

DISCLAIMER

THIS IS COPYRIGHTED CONTENT. Unauthorized use, including screenshots, copying, misuse, reuse, or resale of any content from this app, is strictly prohibited. Our app monitors and records all screenshots and recordings. Violators will face strict legal action.

DISCLAIMER
THIS IS COPYRIGHTED CONTENT. Unauthorized use, including screenshots, copying, misuse, reuse, or resale of any content from this app, is strictly prohibited. Our app monitors and records all screenshots and recordings. Violators will face strict legal action.

PERIODONTICS

SBQ 12

WHILE PROBING THE BLACK BAND IS TOTALLY VISIBLE, AND PATIENT HAS OVERHANGING FILLINGS, BOP, WHICH BPE SCORE WOULD INDICATE THIS?

- A. 1
- B. 2
- C. 3
- D. *

P.O.W.E.R NOTES SBQ 12

I. Black band is completely visible in 0,1,2 BPE scores. Calculus and over hanging restorations are present in BPE score 2.

resale of any content from this app, is strictly prohibited. Our app monitors and records all screenshots and recordings. Violators will face strict legal action.

THIS IS COPYRIGHTED CONTENT. Unauthorized use, including screenshots, copying, misuse, reuse, or resale of any content from this app, is strictly prohibited. Our app monitors and records all screenshots and recordings. Violators will face strict legal action.

THIS IS COPYRIGHTED CONTENT. Unauthorized use, including screenshots, copying, misuse, reuse, or resale of any content from this app, is strictly prohibited. Our app monitors and records all screenshots and recordings. Violators will face strict legal action.

DISCLAIMER

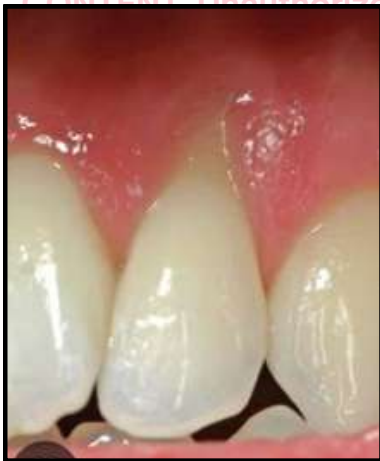THIS IS COPYRIGHTED CONTENT. Unauthorized use, including screenshots, copying, misuse, reuse, or resale of any content from this app, is strictly prohibited. Our app monitors and records all screenshots and recordings. Violators will face strict legal action.

DISCLAIMER
THIS IS COPYRIGHTED CONTENT. Unauthorized use, including screenshots, copying, misuse, reuse, or resale of any content from this app, is strictly prohibited. Our app monitors and records all screenshots and recordings. Violators will face strict legal action.

PERIODONTICS

SBQ 13

LADY WHO COMPLAINTS OF PRESSURE IN HER TEETH AROUND 23 (SHE FEELS HER TEETH 'JAMMED') IT IS SO INTENSE THAT SHE USES RUBBER AND TOOTHPICK OR ANYTHING AVAILABLE TO REMOVE THE FOOD STUCK TO RELIEVE THE PRESSURE SHE BRUSHES TWICE DAILY SHE ALSO FLOSSES INTERDENTAL BRUSHES ALSO SHE USES. SHE SAID EVEN WHEN SHE WAS TALKING TO SOMEONE, SHE WILL LEAVE AND FIND ANYTHING SHE CAN FIND, EVEN A TWIG FROM THE STREET TO CLEAN HER TEETH. (EVEN A TWIG TO PUT INTERDENTALLY SO SHE CAN RELIEVE THE PRESSURE) SHE IS REALLY STRESSED BECAUSE HER BUSINESS GOT AFFECTED BY COVID, SAID SHE HAS HAD TO FIRE 10 OF HER EMPLOYEES DUE TO HER COMPANY BEING IN A FINANCIAL CRISIS. SHE IS ON BANKRUPTCY.



I. On examination YOU found trauma for gingiva around 23 picture was given.

What is the diagnosis

- A. Necrotizing gingivitis
- B. Traumatic injury
- C. Stillman's cleft
- D. Dehiscence

II. What is the reason

- A. Stillman cleft
- B. Trauma
- C. Stress
- D. Poor oral hygiene
- E. Inflammation

III. The lady also had generalized mild gingivitis with shiny attached gingiva.

Reason for gingivitis May be

- A. Mechanical injury caused gingivitis
- B. Plaque induced gingivitis
- C. Generalized Perio
- D. Gingivitis due to bacterial condition
- E. Viral infection

DISCLAIMER

THIS IS COPYRIGHTED CONTENT. Unauthorized use, including screenshots, copying, misuse, reuse, or resale of any content from this app, is strictly prohibited. Our app monitors and records all screenshots and recordings. Violators will face strict legal action.

DISCLAIMER

THIS IS COPYRIGHTED CONTENT. Unauthorized use, including screenshots, copying, misuse, reuse, or resale of any content from this app, is strictly prohibited. Our app monitors and records all screenshots and recordings. Violators will face strict legal action.

THIS IS COPYRIGHTED CONTENT. Unauthorized use, including screenshots, copying, misuse, reuse, or resale of any content from this app, is strictly prohibited. Our app monitors and records all screenshots and recordings. Violators will face strict legal action.

DISCLAIMER

PERIODONTICS

SBQ 13

IV. WHAT IS THE CAUSE OF PRESSURE” (exact wording)

- A. Dissection
- B. Trauma
- C. Recession

V. What mouthwash would you prescribe to her to help her while she is waiting for a specialist appointment.

- A. Antibacterial gel
- B. Analgesic
- C. Topical anesthetic mouthwash
- D. Moisturizing gel
- E. Anti inflammatory mouthwash
- F. Essential oil

THIS IS COPYRIGHTED CONTENT. Unauthorized use, including screenshots, copying, misuse, reuse, or resale of any content from this app, is strictly prohibited. Our app monitors and records all screenshots and recordings. Violators will face strict legal action.

DISCLAIMER
THIS IS COPYRIGHTED CONTENT. Unauthorized use, including screenshots, copying, misuse, reuse, or resale of any content from this app, is strictly prohibited. Our app monitors and records all screenshots and recordings. Violators will face strict legal action.

THIS IS COPYRIGHTED CONTENT. Unauthorized use, including screenshots, copying, misuse, reuse, or resale of any content from this app, is strictly prohibited. Our app monitors and records all screenshots and recordings. Violators will face strict legal action.

DISCLAIMER

THIS IS COPYRIGHTED CONTENT. Unauthorized use, including screenshots, copying, misuse, reuse, or resale of any content from this app, is strictly prohibited. Our app monitors and records all screenshots and recordings. Violators will face strict legal action.

THIS IS COPYRIGHTED CONTENT. Unauthorized use, including screenshots, copying, misuse, reuse, or resale of any content from this app, is strictly prohibited. Our app monitors and records all screenshots and recordings. Violators will face strict legal action.

PERIODONTICS

P.O.W.E.R NOTES SBQ 13

- I. Tooth pick can lead to gingival trauma, recession and bone loss. So, we don't recommend to use it.

STILLMAN'S CLEFT: It's a mucogingival triangular shape defect. Predominantly seen on the buccal surface of the root. It can be related to occlusal trauma which is associated either with marginal gingivitis or periodontitis. It can be found as depression or a define fissure extending up to 5-6mm of length. Other cause can be traumatic toot brushing, incorrect use of interdental floss.

Patient has been using flossing and interdental cleaning agent excessively. So, there's a relationship between the traumatic tooth brushing and gingival recession.

FENESTRATION AND DEHISCENCE: A fenestration is an isolated area in which the root of a tooth has bone resorption and it is only covered by periosteum and gingival tissues, but maintains an intact marginal ridge. But when the bone resorption involves the marginal ridge, it is called a dehiscence.

- II. Aetiology for stillman's cleft is trauma. Poor OH will lead to dehiscence. Dehiscence is a "U" shaped depression, staring from the marginal bone.
- III. When there's mild gingivitis in the absence of plaque and calculus, with the presence of shiny attached gingiva. This is due to excessive abrasion of gingiva as a result of mechanical injury.
- IV. Patient feels pressure on her teeth and this pressure is due to the trauma because she continuously traumatises the gingiva by vigorously using interdental cleaning. Recession is the outcome of it.
- V. Question specifically ask for a mouth wash. So, option (A), (D) get ruled out. She doesn't have pain. She has pressure on the gums. Therefore, analgesics and anaesthetics are not required. Option (B) and (C) get ruled out. There's an inflammation of the area due to the mild gingivitis. So, anti-inflammatory mouth wash is suitable.

THIS IS COPYRIGHTED
CONTENT. Unauthorized use,
including screenshots,
copying, misuse, reuse, or
resale of any content from
this app, is strictly prohibited.
Our app monitors and records
all screenshots and
recordings. Violators will face
strict legal action.

DISCLAIMER

THIS IS COPYRIGHTED CONTENT. Unauthorized use, including screenshots, copying, misuse, reuse, or resale of any content from this app, is strictly prohibited. Our app monitors and records all screenshots and recordings. Violators will face strict legal action.

DISCLAIMER
THIS IS COPYRIGHTED CONTENT. Unauthorized use, including screenshots, copying, misuse, reuse, or resale of any content from this app, is strictly prohibited. Our app monitors and records all screenshots and recordings. Violators will face strict legal action.

DISCLAIMER
THIS IS COPYRIGHTED CONTENT. Unauthorized use, including screenshots, copying, misuse, reuse, or resale of any content from this app, is strictly prohibited. Our app monitors and records all screenshots and recordings. Violators will face strict legal action.

PERIODONTICS

SBQ 14

LADY, CAME FOR NORMAL PERIODONTAL EXAMINATION - FIND OUT UPPER TOOTH (28) - GRADE 2 MOBILITY - NO PAIN, BUT SUPPURATION ON PROBING - COMES TO YOU SAYING, RECENTLY TOOK HOME PREGNANCY TEST, BEFORE WEEK AND POSITIVE.

I. How to manage?

- A. Take radiograph and extract now
- B. Extract without taking radiograph
- C. Defer radiograph and extraction till 2nd trimester
- D. Defer radiograph and extraction till 3rd trimester

II. There was a question from some other scenario saying what is the earliest time for LA injection in pregnant female?

- A. 1st trimester
- B. 2nd trimester
- C. 3rd trimester
- D. 4th trimester

III. Following question - she comes back to you - 14 weeks pregnant - for tooth cleaning - but sensitivity present - so what LA will you give

- A. Lignocaine 2% with adrenaline
- B. Articaine with adrenaline
- C. 3% Prilocaine with felypressin

IV. She asks about the baby's oral health, when to bring the baby to the dentist - you say, bring on his first birthday! What will you check up on that stage

- A. Oral brushing habits
- B. Fluoride varnish
- C. Solid food
- D. Epstein pearl
- E. Oral hygiene

V. If she comes with a baby who is 10 months old and he has his two lower incisors what would you recommend...she said the child does lots of breastfeeding at night, breastfeeding and what is the best preventative measure for the child?

- A. Brush teeth with low fluoride toothpaste
- B. Use wipe to clean teeth after breastfeeding
- C. Use fluoridated water

DISCLAIMER

THIS IS COPYRIGHTED CONTENT. Unauthorized use, including screenshots, copying, misuse, reuse, or resale of any content from this app, is strictly prohibited. Our app monitors and records all screenshots and recordings. Violators will face strict legal action.

DISCLAIMER
THIS IS COPYRIGHTED CONTENT. Unauthorized use, including screenshots, copying, misuse, reuse, or resale of any content from this app, is strictly prohibited. Our app monitors and records all screenshots and recordings. Violators will face strict legal action.

DISCLAIMER
THIS IS COPYRIGHTED CONTENT. Unauthorized use, including screenshots, copying, misuse, reuse, or resale of any content from this app, is strictly prohibited. Our app monitors and records all screenshots and recordings. Violators will face strict legal action.

PERIODONTICS

P.O.W.E.R NOTES SBQ 14

- I. In the 1st trimester of pregnancy elective dental treatments are not done. And the patient doesn't have any pain. But can perform scaling as there's suppuration present on probing.
- II. For LA, there's no contraindication. You can give LA in 1st trimester as well. So, if you are planning to perform FMS in this case you can give LA if required.
- III. There's no contraindication for lignocaine with adrenaline in pregnancy.
- IV. At the age of 1yr we check for the OH and the eruption status of teeth.
- V. According to TG, fluoridated toothpaste is recommended at the age of 18months. According to WHO recommendation fluoridated water is not given up to the age of 10months.

THIS IS COPYRIGHTED CONTENT. Unauthorized use, including screenshots, copying, misuse, reuse, or resale of any content from this app, is strictly prohibited. Our app monitors and records all screenshots and recordings. Violators will face strict legal action.

THIS IS COPYRIGHTED CONTENT. Unauthorized use, including screenshots, copying, misuse, reuse, or resale of any content from this app, is strictly prohibited. Our app monitors and records all screenshots and recordings. Violators will face strict legal action.

THIS IS COPYRIGHTED CONTENT. Unauthorized use, including screenshots, copying, misuse, reuse, or resale of any content from this app, is strictly prohibited. Our app monitors and records all screenshots and recordings. Violators will face strict legal action.

DISCLAIMER

THIS IS COPYRIGHTED CONTENT. Unauthorized use, including screenshots, copying, misuse, reuse, or resale of any content from this app, is strictly prohibited. Our app monitors and records all screenshots and recordings. Violators will face strict legal action.

DISCLAIMER
THIS IS COPYRIGHTED CONTENT. Unauthorized use, including screenshots, copying, misuse, reuse, or resale of any content from this app, is strictly prohibited. Our app monitors and records all screenshots and recordings. Violators will face strict legal action.

DISCLAIMER

THIS IS COPYRIGHTED CONTENT. Unauthorized use, including screenshots, copying, misuse, reuse, or resale of any content from this app, is strictly prohibited. Our app monitors and records all screenshots and recordings. Violators will face strict legal action.

PERIODONTICS

SBQ 15

OLD MAN WITH EXPOSED ROOTS, JUST WANT TO CLEAN HIS TEETH, COMPLAINING SENSITIVITY WHAT DO U PRESCRIBE TO HIM IN CONJUNCTION WITH INTERDENTAL BRUSHES.

- A. Fluoride varnish monthly
- B. Toothpaste with potassium nitrate
- C. Fluoride mouthwash

P.O.W.E.R NOTES SBQ 15

- I. Amongst the given potassium nitrate is the desensitising agent. Fluoride varnish is recommended to use in 6 months intervals.

resale of any content from this app, is strictly prohibited. Our app monitors and records all screenshots and recordings. Violators will face strict legal action.

THIS IS COPYRIGHTED CONTENT. Unauthorized use, including screenshots, copying, misuse, reuse, or resale of any content from this app, is strictly prohibited. Our app monitors and records all screenshots and recordings. Violators will face strict legal action.

THIS IS COPYRIGHTED CONTENT. Unauthorized use, including screenshots, copying, misuse, reuse, or resale of any content from this app, is strictly prohibited. Our app monitors and records all screenshots and recordings. Violators will face strict legal action.

DISCLAIMER

THIS IS COPYRIGHTED CONTENT. Unauthorized use, including screenshots, copying, misuse, reuse, or resale of any content from this app, is strictly prohibited. Our app monitors and records all screenshots and recordings. Violators will face strict legal action.

DISCLAIMER
THIS IS COPYRIGHTED CONTENT. Unauthorized use, including screenshots, copying, misuse, reuse, or resale of any content from this app, is strictly prohibited. Our app monitors and records all screenshots and recordings. Violators will face strict legal action.

PERIODONTICS

SBQ 16

YOU WANT TO DO THE SCALING OF THE LOWER ANTERIORS. PATIENT IS FEELING PAIN WHILE DOING THE SCALING. WHAT WOULD YOU GIVE ? (SUBGINGIVAL SCALING)

- A. Lignocaine gel
- B. Lignocaine block
- C. Lignocaine infiltration

P.O.W.E.R NOTES SBQ 16

I. No need to give a block for scaling. Anaesthetic gel is given prior to injecting.

copying, misuse, reuse, or resale of any content from this app, is strictly prohibited. Our app monitors and records all screenshots and recordings. Violators will face strict legal action.

THIS IS COPYRIGHTED CONTENT. Unauthorized use, including screenshots, copying, misuse, reuse, or resale of any content from this app, is strictly prohibited. Our app monitors and records all screenshots and recordings. Violators will face strict legal action.

THIS IS COPYRIGHTED CONTENT. Unauthorized use, including screenshots, copying, misuse, reuse, or resale of any content from this app, is strictly prohibited. Our app monitors and records all screenshots and recordings. Violators will face strict legal action.

THIS IS COPYRIGHTED CONTENT. Unauthorized use, including screenshots, copying, misuse, reuse, or resale of any content from this app, is strictly prohibited. Our app monitors and records all screenshots and recordings. Violators will face strict legal action.

DISCLAIMER

THIS IS COPYRIGHTED CONTENT. Unauthorized use, including screenshots, copying, misuse, reuse, or resale of any content from this app, is strictly prohibited. Our app monitors and records all screenshots and recordings. Violators will face strict legal action.

DISCLAIMER
THIS IS COPYRIGHTED CONTENT. Unauthorized use, including screenshots, copying, misuse, reuse, or resale of any content from this app, is strictly prohibited. Our app monitors and records all screenshots and recordings. Violators will face strict legal action.

PERIODONTICS

SBQ 17

MRS HONG WORKS IN A RESTAURANT AND WORKS TILL NIGHT. MRS AND MR HONG RECENTLY RETURNED FROM TRIP TO VIETNAM TO VISIT HER FATHER-IN-LAW. THEY HAD FINANCIAL PROBLEM SAVING FOR NEW HOUSE. WORKS HEAVILY SHE DISCONTINUED HER EDUCATION ON 6TH STANDARD. SHE FEELS ABOUT HER DENTAL HYGIENE STATUS.

I. What factors would have led to high caries risk in the patient?

- A. Socio economic, educational, professional
- B. Educational, marital status, professional
- C. Socio economic, marital status, professional
- D. Socio economic, educational, marital status , cultural linguistic background

II. Mrs. Hong has 2 front crowns, missing teeth, and the crowns are loose. what investigation to do with Based on given conditions and from photo of Mrs. Hong anterior gum with crowns of 11 21, She wants to replace her crowns.

- A. Probing, bone sounding, smile analysis
- B. Probing, iopa, remove crown
- C. Probing, vitality test
- D. Vitality test, bone sounding, smile analysis

III. Continued from the previous question. What advice you should give her if she is diagnosed with xerostomia?

- A. Xylitol gum, frequent drinking of water, oral hygiene instruction
- B. Diet analysis, frequent drinking of water, ohi
- C. Salivary substitute, ohi

THIS IS COPYRIGHTED
CONTENT. Unauthorized use,
including screenshots,
copying, misuse, reuse, or
resale of any content from
this app, is strictly prohibited.
Our app monitors and records
all screenshots and
recordings. Violators will face
strict legal action.

DISCLAIMER

THIS IS COPYRIGHTED CONTENT. Unauthorized use, including screenshots, copying, misuse, reuse, or resale of any content from this app, is strictly prohibited. Our app monitors and records all screenshots and recordings. Violators will face strict legal action.

DISCLAIMER
THIS IS COPYRIGHTED CONTENT. Unauthorized use, including screenshots, copying, misuse, reuse, or resale of any content from this app, is strictly prohibited. Our app monitors and records all screenshots and recordings. Violators will face strict legal action.

DISCLAIMER
THIS IS COPYRIGHTED CONTENT. Unauthorized use, including screenshots, copying, misuse, reuse, or resale of any content from this app, is strictly prohibited. Our app monitors and records all screenshots and recordings. Violators will face strict legal action.

PERIODONTICS

P.O.W.E.R NOTES SBQ 17

- I. Marital status has no effect on high caries risk. So, options (B), (C), (D) get ruled out.
- II. **Bone sounding** is done to address the crest of the level of the bone which would dictate whether there is violation of BW or not. That's important to know when you are giving a new crown to re-establish the margins.

Smile analysis is also needed when you are giving new crown and in the presence of missing teeth.

Probing is done to check for the attachment loss and VRF.

Vitality test may be required when you are giving crowns again.

Most importantly **probing**, **IOPA**, **crown removal** will show the remaining attachment, crown: root ratio, remaining tooth structure, whether there is fracture or not

- III. Dry mouth management according to TG; frequent drinking of water and xylitol gum come first.

THIS IS COPYRIGHTED CONTENT. Unauthorized use, including screenshots, copying, misuse, reuse, or resale of any content from this app, is strictly prohibited. Our app monitors and records all screenshots and recordings. Violators will face strict legal action.

DISCLAIMER

THIS IS COPYRIGHTED CONTENT. Unauthorized use, including screenshots, copying, misuse, reuse, or resale of any content from this app, is strictly prohibited. Our app monitors and records all screenshots and recordings. Violators will face strict legal action.

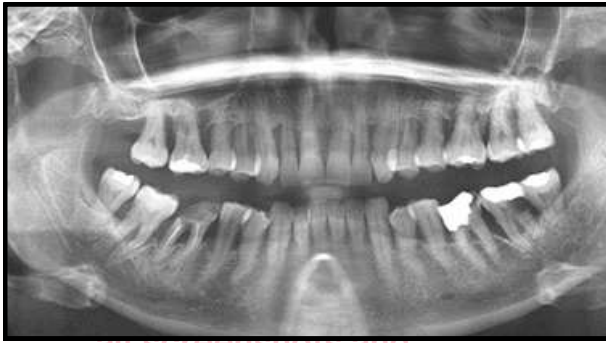THIS IS COPYRIGHTED CONTENT. Unauthorized use, including screenshots, copying, misuse, reuse, or resale of any content from this app, is strictly prohibited. Our app monitors and records all screenshots and recordings. Violators will face strict legal action.

DISCLAIMER
THIS IS COPYRIGHTED CONTENT. Unauthorized use, including screenshots, copying, misuse, reuse, or resale of any content from this app, is strictly prohibited. Our app monitors and records all screenshots and recordings. Violators will face strict legal action.

PERIODONTICS

SBQ 18

A 64 YR OLD LADY. SHE IS SOCIAL IN CULTURAL GATHERINGS AND IS CONSIDERED A SAMOAN ELDER. SHE IS DIABETIC BUT SAYS HER DIABETES IS WELL UNDER CONTROL AS SHE IS ON A CONTROLLED DIET. PLAQUE DEPOSITS, GENERALISED PERIODONTITIS. USED TO SMOKE 10 CIGARETTES BUT QUIT NOW, CLINICAL ATTACHMENT LOSS MORE THAN 6MM. HASN'T BEEN TO THE PHYSICIAN AND DENTIST, BONE LOSS TILL APICAL THIRD IN FEW MOLARS. OPG - ALL FIRST MOLARS HAD BONE LOSS WITH FURCATION INVOLVEMENT. PREMOLARS HAS 50 PERCENT BONE LOSS UPPER AND LOWER, SUBGINGIVAL CALCULUS PRESENT



I. You believe that her diabetes is not as controlled as she thinks it is. What is the best test to check for diabetes?

- A. Haemoglobin a1c
- B. Glucose tolerance test
- C. Fasting glucose
- D. Random glucose
- E. Glucose Screening

II. Perio classification asked after describing her Periodontitis staging and grading features in question.

- A. Stage 3 grade C unstable
- B. Stage 4 grade B unstable
- C. Stage 3 grade B stable
- D. Stage 4 grade C stable
- E. Stage 4 grade C unstable

III. Which indicates rate of progression?

- A. %bone loss by age
- B. Clinical attachment loss analysis
- C. Plaque index

IV. Which clinical finding describes stage of periodontitis?

- A. Radiographic attachment loss
- B. Bleeding on probing
- C. Overhanging restoration
- D. Deep bite forces
- E. Smoking

DISCLAIMER

THIS IS COPYRIGHTED CONTENT. Unauthorized use, including screenshots, copying, misuse, reuse, or resale of any content from this app, is strictly prohibited. Our app monitors and records all screenshots and recordings. Violators will face strict legal action.

DISCLAIMER

THIS IS COPYRIGHTED CONTENT. Unauthorized use, including screenshots, copying, misuse, reuse, or resale of any content from this app, is strictly prohibited. Our app monitors and records all screenshots and recordings. Violators will face strict legal action.

THIS IS COPYRIGHTED CONTENT. Unauthorized use, including screenshots, copying, misuse, reuse, or resale of any content from this app, is strictly prohibited. Our app monitors and records all screenshots and recordings. Violators will face strict legal action.

DISCLAIMER

PERIODONTICS

SBQ 18

V. Bpe 112/212 indicates?

- A. Bleeding on probing and calculus
- B. Gingival inflammation
- C. Pockets in all quadrants

IV. 1/1/1

1/2/1 CPITN index scores what it indicates on intraoral findings?

- A. Gingival bleeding in all sextant
- B. Gingival bleeding and calculus detected in one sextant
- C. Gingival bleeding and calculus in all sextant
- D. Gingival bleeding and calculus detected

VI. The best antibiotic combination with Metronidazole for prescribing after Scaling and root planing, which is scientifically proven to reduce pocket depths?

- A. Amoxicillin
- B. Clindamycin
- C. Azithromycin
- D. Doxycycline

P.O.W.E.R NOTES SBQ 18

- I. The best way to estimate and evaluate her DM condition is hba1c. nothing else will tell the chronic overall management and the blood sugar level of the last 3months.
- II. Bone loss is seen up to the middle and apical 3rd. but there's no flaring, no drifting of teeth, no ridge defects because teeth have not been lost yet. Therefore, this is stage 3 situation.

In this case hba1c level and smoking hx is not given. So, to know about the grading u must use the formula = % bone loss/ age

More than 65%= which means patient falls in grade C. (only in the area of premolar region it shows 50% bone loss.)

There are plaque deposits and patient hasn't got any treatment yet. Before the treatment when the disease in the active state, it is unstable. After getting treatment if still bleeding on probing present, if still plaque and calculi present, then it will be unstable. After getting the treatment if there's no BOP and reduced PD, then it will be stable.

DISCLAIMER

THIS IS COPYRIGHTED CONTENT. Unauthorized use, including screenshots, copying, misuse, reuse, or resale of any content from this app, is strictly prohibited. Our app monitors and records all screenshots and recordings. Violators will face strict legal action.

DISCLAIMER
THIS IS COPYRIGHTED CONTENT. Unauthorized use, including screenshots, copying, misuse, reuse, or resale of any content from this app, is strictly prohibited. Our app monitors and records all screenshots and recordings. Violators will face strict legal action.

THIS IS COPYRIGHTED CONTENT. Unauthorized use, including screenshots, copying, misuse, reuse, or resale of any content from this app, is strictly prohibited. Our app monitors and records all screenshots and recordings. Violators will face strict legal action.

DISCLAIMER

PERIODONTICS

P.O.W.E.R NOTES SBQ 18

Staging and Grading Periodontitis

The 2017 World Workshop on the Classification of Periodontal and Peri-Implant Diseases and Conditions resulted in a new classification of periodontitis characterized by a multidimensional staging and grading system. The charts below provide an overview. Please visit perio.org/2017wwdc for the complete suite of reviews, case definition papers, and consensus reports.



PERIODONTITIS: STAGING

Staging intends to classify the severity and extent of a patient's disease based on the measurable amount of destroyed and/or damaged tissue as a result of periodontitis and to assess the specific factors that may attribute to the complexity of long-term case management.

Initial stage should be determined using clinical attachment loss (CAL). If CAL is not available, radiographic bone loss (RBL) should be used. Tooth loss due to periodontitis may modify stage definition. One or more complexity factors may shift the stage to a higher level. See perio.org/2017wwdc for additional information.

	Periodontitis	Stage I	Stage II	Stage III	Stage IV
Severity	Interdental CAL (at site of greatest loss)	1 – 2 mm	3 – 4 mm	≥5 mm	≥5 mm
	RBL	Coronal third (<15%)	Coronal third (15% - 33%)	Extending to middle third of root and beyond	Extending to middle third of root and beyond
	Tooth loss (due to periodontitis)	No tooth loss		≤4 teeth	≥5 teeth
Complexity	Local	<ul style="list-style-type: none"> Max. probing depth ≤4 mm Mostly horizontal bone loss 	<ul style="list-style-type: none"> Max. probing depth ≤5 mm Mostly horizontal bone loss 	In addition to Stage II complexity: <ul style="list-style-type: none"> Probing depths ≥6 mm Vertical bone loss ≥3 mm Furcation involvement Class II or III Moderate ridge defects 	In addition to Stage III complexity: <ul style="list-style-type: none"> Need for complex rehabilitation due to: <ul style="list-style-type: none"> Masticatory dysfunction Secondary occlusal trauma (tooth mobility degree ≥2) Severe ridge defects Bite collapse, drifting, flaring < 20 remaining teeth (10 opposing pairs)
	Extent and distribution	Add to stage as descriptor	For each stage, describe extent as: <ul style="list-style-type: none"> Localized (<30% of teeth involved); Generalized; or Molar/incisor pattern 		

PERIODONTITIS: GRADING

Adapted from: see perio.org/2017wwdc for additional information

Grading aims to indicate the rate of periodontitis progression, responsiveness to standard therapy, and potential impact on systemic health. Clinicians should initially assume grade B disease and seek specific evidence to shift to grade A or C.

	Progression		Grade A: Slow Rate	Grade B: Moderate Rate	Grade C: Rapid Rate
Primary criteria Whenever available, direct evidence should be used	Direct evidence of progression	Radiographic bone loss or CAL	No loss over 5 years	<2mm over 5 years	≥2mm over 5 years
	Indirect evidence of progression	% bone loss ÷ age	≤.24	.25-1.0	≥ 1.1
		Case phenotype	Heavy biofilm deposits with low levels of destruction	Destruction commensurate with biofilm deposits	Destruction exceeds expectations given biofilm deposits; specific clinical patterns suggestive of periods of rapid progression and/or early onset disease
Grade modifiers	Risk factors	Smoking	Non-smoker	≤9 cigarettes/day	10+ cigarettes/day
		Diabetes	Normal glycemic/no diagnosis of diabetes	HbA1c ≤6.99% in patients with diabetes	HbA1c ≥7.0 in patients with diabetes

recordings. Violators will face strict legal action.

DISCLAIMER

THIS IS COPYRIGHTED CONTENT. Unauthorized use, including screenshots, copying, misuse, reuse, or resale of any content from this app, is strictly prohibited. Our app monitors and records all screenshots and recordings. Violators will face strict legal action.

DISCLAIMER
THIS IS COPYRIGHTED CONTENT. Unauthorized use, including screenshots, copying, misuse, reuse, or resale of any content from this app, is strictly prohibited. Our app monitors and records all screenshots and recordings. Violators will face strict legal action.

THIS IS COPYRIGHTED CONTENT. Unauthorized use, including screenshots, copying, misuse, reuse, or resale of any content from this app, is strictly prohibited. Our app monitors and records all screenshots and recordings. Violators will face strict legal action.

DISCLAIMER

PERIODONTICS

P.O.W.E.R NOTES SBQ 18

III. Rate is the speed. It denotes whether is it rapid or slow. Speed of progression is the grade. Grade indicators are smoking, DM and %bone loss as per the age. Clinical attachment loss is the severity, that would be the staging criteria.

IV. **BOP** and **PD** can determine the stability. Presence of BOP and increased PD determines the presence of active/ unstable disease.

Smoking is a grade factor.

Deep bite forces are neither the grading nor staging factors.

Overhanging restoration describes the BPE score.

Attachment loss criteria is for staging.

V.

Probing depth	Observation	BPE Score
Black band completely visible	No probing depths >3.5 mm, no calculus/overhangs, no bleeding after probing	0
Black band completely visible	No probing depths >3.5 mm, no calculus/overhangs, but bleeding after probing	1
Black band completely visible	No probing depths >3.5 mm, but supra- or sub-gingival calculus/overhangs present	2
Black band partially visible	Probing depth(s) of 3.5 – 5.5 mm present	3
Black band entirely within the pocket	Probing depth(s) of 6 mm or more present	4
N/A	Furcation involvement	*

VI.1 denotes bleeding and 2 denotes the presence of calculus. So, calculus is detected only in one sextant.

VII. Metronidazole acts on the gram negative. Usually amoxicillin is given in combination with metronidazole. Clindamycin is broad spectrum and given as a single drug. Azithromycin acts on the gram negative. Doxycycline is used in periodontitis but not in combination with metronidazole. It's given as a single drug.

DISCLAIMER

THIS IS COPYRIGHTED CONTENT. Unauthorized use, including screenshots, copying, misuse, reuse, or resale of any content from this app, is strictly prohibited. Our app monitors and records all screenshots and recordings. Violators will face strict legal action.

DISCLAIMER
THIS IS COPYRIGHTED CONTENT. Unauthorized use, including screenshots, copying, misuse, reuse, or resale of any content from this app, is strictly prohibited. Our app monitors and records all screenshots and recordings. Violators will face strict legal action.

THIS IS COPYRIGHTED CONTENT. Unauthorized use, including screenshots, copying, misuse, reuse, or resale of any content from this app, is strictly prohibited. Our app monitors and records all screenshots and recordings. Violators will face strict legal action.

DISCLAIMER

PERIODONTICS

SBQ 19

IMPLANT

I. You decided to extract a first molar for a patient and now plan to replace it with an implant. While placing the implant, you should be careful regarding which nerve?

- A. Mylohyoid nerve
- B. IAN
- C. Mental
- D. Long buccal
- E. Lingual nerve

II. Why are you considering CBCT

- A. Lingual bone contour/concavity
- B. Bone width

P.O.W.E.R NOTES SBQ 19

I. IAN is most commonly injured nerve (64.4%), followed by the lingual nerve (28.8%) during mandibular implant placement in the molar region. If it was a premolar situation mental nerve would be the answer.

II. Bone width can be measured by the bone sounding.

CBCT scans help in the planning of oral implants, they enable measurement of the distance between the alveolar crest and mandibular canal to avoid impingement of inferior alveolar nerve, avoid perforation of mandibular posterior lingual undercut, and assess the density and quality of bone.

THIS IS COPYRIGHTED CONTENT. Unauthorized use, including screenshots, copying, misuse, reuse, or resale of any content from this app, is strictly prohibited. Our app monitors and records all screenshots and recordings. Violators will face strict legal action.

DISCLAIMER

THIS IS COPYRIGHTED CONTENT. Unauthorized use, including screenshots, copying, misuse, reuse, or resale of any content from this app, is strictly prohibited. Our app monitors and records all screenshots and recordings. Violators will face strict legal action.

THIS IS COPYRIGHTED CONTENT. Unauthorized use, including screenshots, copying, misuse, reuse, or resale of any content from this app, is strictly prohibited. Our app monitors and records all screenshots and recordings. Violators will face strict legal action.

DISCLAIMER
THIS IS COPYRIGHTED CONTENT. Unauthorized use, including screenshots, copying, misuse, reuse, or resale of any content from this app, is strictly prohibited. Our app monitors and records all screenshots and recordings. Violators will face strict legal action.

PERIODONTICS

SBQ 20

WHICH LOCAL CRITERIA WILL HELP WITH THE STABILITY OF THE IMPLANT AND WILL FURTHER HELP IN THE TREATMENT PLANNING FOR THIS PATIENT? OR WHICH LOCAL CRITERIA WILL YOU CHECK BEFORE PLACING AN IMPLANT IN THE PATIENT?

- A. Plaque index
- B. Bleeding on probing
- C. Take study model cast
- D. Cbct
- E. Opg

P.O.W.E.R NOTES SBQ 20

- I. Suppose that patient didn't brush one day before the dental appointment, then the plaque index will be high. But there won't be established gingivitis.

In the presence of BOP in the area where you are planning to place implants, it's an immediate sign that you need to postpone the surgery until the tissues healed and arrest BOP. BOP indicate active gingivitis.

(C), (D), (E) are not local factors.

THIS IS COPYRIGHTED CONTENT. Unauthorized use, including screenshots, copying, misuse, reuse, or resale of any content from this app, is strictly prohibited. Our app monitors and records all screenshots and recordings. Violators will face strict legal action.

DISCLAIMER

THIS IS COPYRIGHTED CONTENT. Unauthorized use, including screenshots, copying, misuse, reuse, or resale of any content from this app, is strictly prohibited. Our app monitors and records all screenshots and recordings. Violators will face strict legal action.

THIS IS COPYRIGHTED CONTENT. Unauthorized use, including screenshots, copying, misuse, reuse, or resale of any content from this app, is strictly prohibited. Our app monitors and records all screenshots and recordings. Violators will face strict legal action.

THIS IS COPYRIGHTED CONTENT. Unauthorized use, including screenshots, copying, misuse, reuse, or resale of any content from this app, is strictly prohibited. Our app monitors and records all screenshots and recordings. Violators will face strict legal action.

WINSPERT
P.O.W.E.R
NOTES

DISCLAIMER
THIS IS COPYRIGHTED CONTENT. Unauthorized use, including screenshots, copying, misuse, reuse, or resale of any content from this app, is strictly prohibited. Our app monitors and records all screenshots and recordings. Violators will face strict legal action.