



# UAF VOL 2

ULTIMATE ADVANCE FILE

P.O.W.E.R

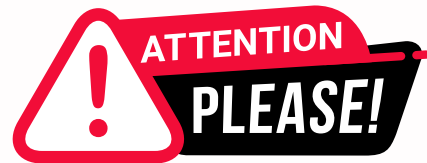PREPARATION OF ADC WITH WINSPERT EXPERT REVIEW

NOTES



By Dr. Jigyasa Sharma

PEDO  
+  
ORTHO



Dear Students,

We'd like to remind you about the importance of respecting the integrity of the resources provided in our app.

Please be aware that **WINSPERT POWERNOTES ARE COPYRIGHTED CONTENT. Unauthorized use, including screenshots, copying, misuse, reuse, or resale of any content from this app, is strictly prohibited.**

**Our app monitors and records all screenshots and recordings. Violators will face strict legal action.**

We're committed to providing you with the best tools for your success, and we appreciate your cooperation in maintaining a fair and secure learning environment.

Thank you for your understanding and continued dedication.

Best regards,  
WINSPERT TEAM



# R.A.S.H TECHNIQUE

R- **RULE** OUT

A- DOES IT **ANSWER** OUR QUESTION

S- **SEQUENCE** WISE WHAT COMES 1<sup>ST</sup>

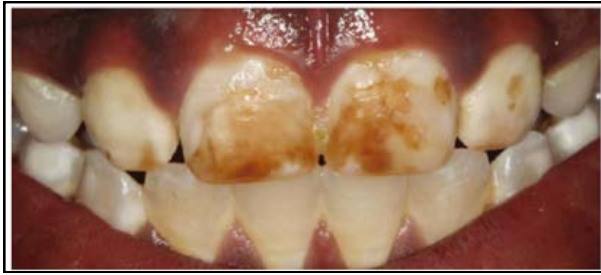H- WHAT IS GIVEN IN THE **HISTORY**

SOLVE ADC QUESTIONS AT  
*lightning speed!*

# PEDO+ORTHO

## SBQ 1

MOTHER BROUGHT HER CHILD, SHE IS HAVING DISCOLORED ANTERIOR. YOU SUSPECT FLUOROSIS AND ASK HER HISTORY . SHE WAS BORN IN THE AFRICAN GREAT RIFT VALLEY AND AT THE AGE OF 3 YEARS SHIFTED TO ERITREA, AFRICA AND AT AGE OF 4 SHE IMMIGRATED TO AUSTRALIA AND NOW SHE IS 11 YEARS. NOTE THAT THE DARK BROWN STAINS ARE LIMITED TO UPPER INCISORS. THE LOWER INCISORS WERE THE LEAST AFFECTED TEETH



I. Which place would have caused her fluorosis?

- A. African Ethiopian great rift valley
- B. Eritrea
- C. Australia

II. You decide to do bleaching and at the end you applied CPP ACP .Why did you decide to do that?

- A. To reduce post treatment sensitivity.
- B. To enhance whitening.
- C. To prevent caries.
- D. To remineralize the enamel

III. It gave good results, but still the patient's mother is not happy with her appearance. You decided to give home bleaching. What will you use?

- A. Carbamide peroxide 10 percent
- B. Sodium Perborate
- C. H<sub>2</sub>O<sub>2</sub> 30 percent

IV. While reviewing the patient after home bleach and ccp, still discoloration is persistent, how will you manage?

- A. Crown
- B. Porcelain veneer
- C. Resin bonded porcelain veneer
- D. Restoration of resin composite

## DISCLAIMER

THIS IS COPYRIGHTED CONTENT. Unauthorized use, including screenshots, copying, misuse, reuse, or resale of any content from this app, is strictly prohibited. Our app monitors and records all screenshots and recordings. Violators will face strict legal action.

## DISCLAIMER

THIS IS COPYRIGHTED CONTENT. Unauthorized use, including screenshots, copying, misuse, reuse, or resale of any content from this app, is strictly prohibited. Our app monitors and records all screenshots and recordings. Violators will face strict legal action.

THIS IS COPYRIGHTED CONTENT. Unauthorized use, including screenshots, copying, misuse, reuse, or resale of any content from this app, is strictly prohibited. Our app monitors and records all screenshots and recordings. Violators will face strict legal action.

## DISCLAIMER



# PEDO+ORTHO

## P.O.W.E.R NOTES SBQ 1

- I.
  - According to the given history the provisional diagnosis is **FLUOROSIS**.
  - Fluorosis is mostly confined to upper anterior predominantly, which means it's chronological (age related).
  - In the incisors from incisal edge to the cervical portion if affected with fluorosis which means the child might have exposed to excessive amounts of the fluorides during 1<sup>st</sup> 3 year of life.
  - She was in Africa up to 3 years old. So, option (A) is the best among the given.
  - In Australia they maintain optimal level of fluoride in tap water.
- II.
  - Usually in Australia bleaching is done after 16yrs old. In the scenario the child is 11yrs old.
  - But the child is having a pathological condition which has an impact on the aesthetics. So, in such situations bleaching can be done.
  - Bleaching alone will have mild demineralising effect.
  - During etching, fluorosis teeth will take longer time to create surface roughness compared to a normal tooth. this is because teeth with fluorosis have lack of enamel so, less mineral content and existing demineralisation. (during etching process enamel tags are formed on the tooth surface so the resin material can infiltrate thoroughly.

Thus, phosphoric acid etching for the severe fluorosis group is questionable. Moderate and severe fluorosis of enamel exhibited decreased surface roughness and depth profiles after etching, probably because of demineralization of enamel structure, and loss of enamel. The findings from the present study differ from other studies which suggest that the greater the degree of dental fluorosis, the greater the etching time is

- Teeth with fluorosis are more prone to get caries as there are pitting surfaces and demineralised enamel.
- There will be post treatment sensitivity after bleaching but it doesn't happen always.
- CPP-ACP will not enhance the whitening. Option (B) is ruled out.
- Teeth with fluorosis are already demineralised, so, CPP-ACP will be helpful to re-mineralize the tooth structure. When the tooth structure is re-mineralised, it helps to prevent caries and reduce post-operative sensitivity.
- Among the given the best option is (D).

### DISCLAIMER

THIS IS COPYRIGHTED CONTENT. Unauthorized use, including screenshots, copying, misuse, reuse, or resale of any content from this app, is strictly prohibited. Our app monitors and records all screenshots and recordings. Violators will face strict legal action.

### DISCLAIMER

THIS IS COPYRIGHTED CONTENT. Unauthorized use, including screenshots, copying, misuse, reuse, or resale of any content from this app, is strictly prohibited. Our app monitors and records all screenshots and recordings. Violators will face strict legal action.

THIS IS COPYRIGHTED CONTENT. Unauthorized use, including screenshots, copying, misuse, reuse, or resale of any content from this app, is strictly prohibited. Our app monitors and records all screenshots and recordings. Violators will face strict legal action.

### DISCLAIMER

# PEDO+ORTHO

## P.O.W.E.R NOTES SBQ 1

### III. INTERNAL BLEACHING - (walking bleaching technique) – Sodium perborate

**OFFICE BLEACHING**- 30% H<sub>2</sub>O<sub>2</sub>

**HOME BLEACHING** – 10% Carbamide peroxide

- IV. • Patient is still 11yrs and we cannot give anything with definite margins. So, options (A), (B), (C) get ruled out.
- Reversible restoration with minimal or no preparation is needed. Option (D) is the best answer.
  - If no prep composite veneers are given as an option, that would become the best answer.

THIS IS COPYRIGHTED CONTENT. Unauthorized use, including screenshots, copying, misuse, reuse, or resale of any content from this app, is strictly prohibited. Our app monitors and records all screenshots and recordings. Violators will face strict legal action.

THIS IS COPYRIGHTED CONTENT. Unauthorized use, including screenshots, copying, misuse, reuse, or resale of any content from this app, is strictly prohibited. Our app monitors and records all screenshots and recordings. Violators will face strict legal action.

THIS IS COPYRIGHTED CONTENT. Unauthorized use, including screenshots, copying, misuse, reuse, or resale of any content from this app, is strictly prohibited. Our app monitors and records all screenshots and recordings. Violators will face strict legal action.

#### DISCLAIMER

THIS IS COPYRIGHTED CONTENT. Unauthorized use, including screenshots, copying, misuse, reuse, or resale of any content from this app, is strictly prohibited. Our app monitors and records all screenshots and recordings. Violators will face strict legal action.

**DISCLAIMER**  
THIS IS COPYRIGHTED CONTENT. Unauthorized use, including screenshots, copying, misuse, reuse, or resale of any content from this app, is strictly prohibited. Our app monitors and records all screenshots and recordings. Violators will face strict legal action.

# PEDO+ORTHO

## SBQ 2

A 8 YEAR OLD PATIENT WAS BROUGHT TO THE CLINIC BY THE PARENTS WITH THE CHIEF COMPLAINT OF 2 MISSING TEETH (ONE PRIMARY AND ONE PERMANENT TEETH). HISTORY OF TRAUMA WHILE PLAYING FOOTBALL. THE KID WAS BROUGHT 15-30 MINUTES AFTER THE TRAUMA AND THE PARENTS TELL YOU THAT THE COACH IS STILL LOOKING FOR THE TEETH.

### I. What is the most significant question you would ask the parents?

- A. When did the injury occur?
- B. Did the child lose any consciousness?
- C. How did the injury occur?

### II. The coach brings back the teeth after 30 minutes. What will preclude the reimplantation?

- A. If its the deciduous tooth
- B. Extra oral dry time
- C. If It is rinsed
- D. If it has been held with yellow part

### III. What suggests better prognosis of the teeth?

- A. Permanent tooth open apex
- B. Permanent tooth close apex
- C. The 60 minute time since injury

### IV. You reimplanted the tooth and what determines the success of treatment?

- A. Viability of periodontal ligament
- B. Open apex of tooth
- C. How you reimplanted in socket
- D. Flexibility of composite and nylon splint

### V. What is the home care you will mention to the parents?

- A. Not to eat solid food
- B. CHX mouth rinse for 2 weeks
- C. Not to brush in the area

### VI. In the followup appointment after 4 weeks. What will you check in the IOPA?

- A. Inflammatory root resorption
- B. Ankylosis
- C. Pulp obliteration

### VII. What is the preferred medium for placing an avulsed tooth?

- A. HBSS (osmolality balanced solution)
- B. Water
- C. Plastic wrap

#### DISCLAIMER

THIS IS COPYRIGHTED CONTENT. Unauthorized use, including screenshots, copying, misuse, reuse, or resale of any content from this app, is strictly prohibited. Our app monitors and records all screenshots and recordings. Violators will face strict legal action.

#### DISCLAIMER

THIS IS COPYRIGHTED CONTENT. Unauthorized use, including screenshots, copying, misuse, reuse, or resale of any content from this app, is strictly prohibited. Our app monitors and records all screenshots and recordings. Violators will face strict legal action.

THIS IS COPYRIGHTED CONTENT. Unauthorized use, including screenshots, copying, misuse, reuse, or resale of any content from this app, is strictly prohibited. Our app monitors and records all screenshots and recordings. Violators will face strict legal action.

#### DISCLAIMER

# PEDO+ORTHO

## P.O.W.E.R NOTES SBQ 2

- I.
  - In an injury the most important thing to check is “whether the child lost consciousness”.
  - Avulsion injuries can have neck impact, brain impact and head impact.
  - Head injuries should be ruled out as they have more complications than tooth getting avulsed.
  - Medical history is more important than the dental history.
- II.
  - Re-implantation can even take place after 60min even though the prognosis is less.
  - It's not recommended to touch the root of the tooth as it reduces the prognosis. But in case if we touch the root, that won't be a contraindication for the re-implantation.
  - It's not recommended to rinse the tooth with water, but still if it has happened, we don't stay without re-implanting the tooth.
  - Options (B), (C), (D) are prognostic indicators but not the absolute contraindications of re-implantation.
  - Primary teeth are not re-implanted as they can permanently damage the permanent tooth.
- III.
  - Prognosis is best within 15min and prognosis reduces after 60 min of extraoral time.
  - There is a high chance of re-vascularisation with the “open apex” compare to the “close apex”.
- IV. Success of the re-implantation depends on:
  - Time outside the socket
  - storage media
  - manipulation/handling of the tooth

All these factors are important to maintain the viability of the periodontal ligament.
- V. Instructions to be followed after re-implantation.
  1. Avoid participation in contact sport.
  2. Patient needs to be on a soft diet for 2weeks. It's not about the solids or liquids.
  3. Brush their teeth with a soft brush after each meal.
  4. Use chlorhexidine mouthwash twice a day for 2 weeks.

### DISCLAIMER

THIS IS COPYRIGHTED CONTENT. Unauthorized use, including screenshots, copying, misuse, reuse, or resale of any content from this app, is strictly prohibited. Our app monitors and records all screenshots and recordings. Violators will face strict legal action.

### DISCLAIMER

THIS IS COPYRIGHTED CONTENT. Unauthorized use, including screenshots, copying, misuse, reuse, or resale of any content from this app, is strictly prohibited. Our app monitors and records all screenshots and recordings. Violators will face strict legal action.

THIS IS COPYRIGHTED CONTENT. Unauthorized use, including screenshots, copying, misuse, reuse, or resale of any content from this app, is strictly prohibited. Our app monitors and records all screenshots and recordings. Violators will face strict legal action.

### DISCLAIMER



# PEDO+ORTHO

## P.O.W.E.R NOTES SBQ 2

VI. Most common **delayed outcome after re-implantation** is; replacement resorption/ ankylosis.

**In case of open apex situations:**

- For open apex teeth where spontaneous pulp space revascularisation is possible, clinical and radiographic reviews should be more frequent owing to the risk of infection related (inflammatory) resorption and rapid loss of the tooth and supporting bone. Evidence of root and/ or bone resorption anywhere around the circumference of the root should be interpreted as **infection related “inflammatory resorption”**.
- **Ankylosis related (replacement resorption):** Radiographic absence of the periodontal ligament space, the replacement of the root structure by bone, together with metallic sound to percussion should be interpreted as “Ankylosis related (replacement resorption)”.
- The 2 types of resorption may occur concurrently.
- For these reasons replanted teeth with an open apex should be monitored clinically and radiographically at 2 weeks (when the splint is removed), 1-2-3-6 months, 1 year, yearly thereafter for 5 years.
- Poorest prognosis / unfavourable outcomes are expected in Ankylosis related (replacement resorption).
- Delayed re-implantation is mostly associated with Ankylosis related (replacement resorption). In such cases tooth will be infra-occluded.
- **In case of inflammatory resorption, immediate tooth extraction is needed. Whereas in replacement resorption, immediate tooth extraction is not needed.**

V. Best solutions to store the tooth:

- Milk
- HBSS
- Saliva
- Saline

THIS IS COPYRIGHTED CONTENT. Unauthorized use, including screenshots, copying, misuse, reuse, or resale of any content from this app, is strictly prohibited. Our app monitors and records all screenshots and recordings. Violators will face strict legal action.

### DISCLAIMER

THIS IS COPYRIGHTED CONTENT. Unauthorized use, including screenshots, copying, misuse, reuse, or resale of any content from this app, is strictly prohibited. Our app monitors and records all screenshots and recordings. Violators will face strict legal action.

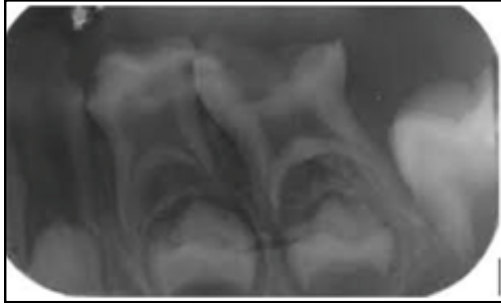
DISCLAIMER  
THIS IS COPYRIGHTED CONTENT. Unauthorized use, including screenshots, copying, misuse, reuse, or resale of any content from this app, is strictly prohibited. Our app monitors and records all screenshots and recordings. Violators will face strict legal action.

DISCLAIMER  
THIS IS COPYRIGHTED CONTENT. Unauthorized use, including screenshots, copying, misuse, reuse, or resale of any content from this app, is strictly prohibited. Our app monitors and records all screenshots and recordings. Violators will face strict legal action.

# PEDO+ORTHO

## SBQ 3

4 YR OLD BOY, WHO HAS DONE TREATMENT FOR 84 AND 85 IN VIETNAM (SSC CROWNS), THEY COULDN'T COMPLETE TREATMENT FOR 74, 75 DUE TO LACK OF TIME. 75 IS GROSSLY DECAYED. FATHER BRINGS HIM TO YOU AND ASKS TO DO THE SAME TREATMENT FOR THE OTHER SIDE TOO. WHEN ASKED TO SIT, THE CHILD QUIETLY CAME AND SAT ON THE DENTAL CHAIR.



I. What is the main factor you will consider whether to treat this patient?

- A. Delivery of pain control
- B. Previous pulp treatment done in Vietnam)
- C. Post operative complications
- D. Pre operative symptoms

II. What will contraindicate pulpectomy on 75?

- A. Furcation involvement
- B. Absence of permanent successor
- C. Periapical radiolucency
- D. Presence of big cavity

III. You plan to extract 75, what you should consider?

- A. Damage to permanent successor
- B. Psychological trauma of tooth removal.
- C. Fracture of the root
- D. Fracture of the crown

IV. You planned for space maintenance. What is the best Cement for space maintainer cementation?

- A. gic
- B. polycarboxylate,
- C. Zn phosphate
- D. zoe
- E. composite resin

## DISCLAIMER

THIS IS COPYRIGHTED CONTENT. Unauthorized use, including screenshots, copying, misuse, reuse, or resale of any content from this app, is strictly prohibited. Our app monitors and records all screenshots and recordings. Violators will face strict legal action.

## DISCLAIMER

THIS IS COPYRIGHTED CONTENT. Unauthorized use, including screenshots, copying, misuse, reuse, or resale of any content from this app, is strictly prohibited. Our app monitors and records all screenshots and recordings. Violators will face strict legal action.

THIS IS COPYRIGHTED CONTENT. Unauthorized use, including screenshots, copying, misuse, reuse, or resale of any content from this app, is strictly prohibited. Our app monitors and records all screenshots and recordings. Violators will face strict legal action.

DISCLAIMER

# PEDO+ORTHO

## P.O.W.E.R NOTES SBQ 3

- I. • Previous pulp treatment was performed in 84, 85 and now patient c/o 74, 75. So, there's no impact of the Vietnam treatment for the present chief complaint. option (B) is ruled out.
- Post op complications don't have a direct impact on the present treatment. option (C) is ruled out.
- Both options (A) and (D) are correct. But the treatment is purely dependant on the chief complaint and investigations. So, the best answer is option (D).
- II. • Size of the cavity doesn't decide the type of the pulp therapy. option (D) is ruled out.
- Periapical radiolucency is an indication to RCT whereas root resorption in a deciduous tooth is a contraindication to RCT. Option (C) is ruled out.
- In case of absence of permanent successor, the deciduous requires RCT as it requires to be in the mouth longer. So, need to preserve it. Option (B) gets ruled out.
- RCT is contraindicated in case of furcation involvement and root resorption in deciduous teeth. option (A) is the best among the given.
- III. • (A) these can  
haj will refrain  
• An the patient to use dental treatment in the future for the maintenance of their permanent dentition.

It is important to not proceed with extraction of a primary tooth unless it is absolutely necessary as this is often the child's first exposure to a dental procedure. For them to have to sit through local anaesthetic and a tooth extraction as their first ever dental experience may lead to a negative experience and may induce dental anxiety. Lower anterior crowding indicates a developing malocclusion and is better managed orthodontically, typically in the mid to late mixed dentition.

**Table II. Sources of dental anxiety created in a dental practice setting**

Dental and Dental Hygiene Procedures	Provider Actions
<b>Every Single Procedure</b> <ul style="list-style-type: none"> <li>Restorations</li> <li>Extractions</li> <li>Scaling</li> <li>Local Anesthesia               <ul style="list-style-type: none"> <li>Injections</li> <li>Fear of needles</li> </ul> </li> <li>X-rays</li> <li>Flossing</li> </ul>	<b>Inconsistency</b> <b>Personal Space</b> <ul style="list-style-type: none"> <li>Having hands in mouth</li> </ul> <b>Lack of information</b> <ul style="list-style-type: none"> <li>Poor communication</li> <li>Not being able to vocalize during procedure</li> </ul>
<b>Waiting Room</b> <ul style="list-style-type: none"> <li>Waiting too long</li> <li>Hearing others</li> </ul>	<b>Not recognizing signs of anxiety</b> <b>Rushing procedures or patients when they are not ready</b>
<b>Sensory</b> <b>Smell</b> <ul style="list-style-type: none"> <li>Too Sterile</li> <li>Drilling of bone</li> </ul> <b>Sights</b> <ul style="list-style-type: none"> <li>Operatory looks like a medieval torture chamber</li> <li>The instruments</li> <li>Lighting is strong on the eyes</li> </ul> <b>Noise</b> <ul style="list-style-type: none"> <li>High-pitched whine from drilling</li> <li>Scaling</li> <li>Suction</li> </ul> <b>Sensation</b> <ul style="list-style-type: none"> <li>Scaling/scraping on bone</li> <li>Sharp instruments are uncomfortable in gums</li> <li>Metal against teeth</li> <li>Feeling the pressure during scaling</li> <li>Chair feels claustrophobic</li> <li>If something falls onto tongue</li> <li>The grit</li> <li>Vibration of polisher</li> </ul>	<b>Speaking in dental terms</b> <b>Telling patients not to think about it, relax, or to take calming breaths</b> <b>Fear that Provider will break a tooth</b> <b>Anticipation that provider will find a cavity</b>

### DISCLAIMER

THIS IS COPYRIGHTED CONTENT. Unauthorized use, including screenshots, copying, misuse, reuse, or resale of any content from this app, is strictly prohibited. Our app monitors and records all screenshots and recordings. Violators will face strict legal action.

### DISCLAIMER

THIS IS COPYRIGHTED CONTENT. Unauthorized use, including screenshots, copying, misuse, reuse, or resale of any content from this app, is strictly prohibited. Our app monitors and records all screenshots and recordings. Violators will face strict legal action.

THIS IS COPYRIGHTED CONTENT. Unauthorized use, including screenshots, copying, misuse, reuse, or resale of any content from this app, is strictly prohibited. Our app monitors and records all screenshots and recordings. Violators will face strict legal action.

### DISCLAIMER



# PEDO+ORTHO

## P.O.W.E.R NOTES SBQ 3

III.

It is important to not proceed with extraction of a primary tooth unless it is absolutely necessary as this is often the child's first exposure to a dental procedure. For them to have to sit through local anaesthetic and a tooth extraction as their first ever dental experience may lead to a negative experience and may induce dental anxiety. Lower anterior crowding indicates a developing malocclusion and is better managed orthodontically, typically in the mid to late mixed dentition.

- IV. • Most common cements used for the cementation of the space maintainers are options GIC and Zn phosphate.
- All (A), (B), (C), (D) are temporary cements. (B) and (D) have poor physical qualities and they cannot survive in the oral environment.
  - GIC has chemical addition and Zn phosphate has physical addition. Zn phosphate is more technique sensitive compared to GIC. GIC is the best among the given options.
  - RMGIC can also be used for cementation when more forces are applied in that are and it needs to be there for a longer duration. RMGIC can be used as a luting cement in PFM crowns, SS bands, temporary crowns. But RMGIC is contraindicated in all ceramic crowns and zirconia crowns because on expansion all ceramic/ zirconia cannot take that pressure and can lead to fracture. (ceramic has internal stresses).

### REFERENCE:

Retention of the band depends on its close adaptation to the tooth by cement lute. Numerous studies done antecedently have shown advances in the area of dental cements with the event of the latest varieties.<sup>6</sup> Many studies within the past have investigated the chemical composition of varied cements, their physical and chemical properties, and their application as well as use in restorative dentistry. Earlier, zinc phosphate cements were widely used for luting bands but have limitations of high solubility and relying entirely on mechanical adhesion for their retention. Other dental cements have been developed to overcome these shortcomings. Polycarboxylate cements react chemically with enamel and stainless steel. Its disadvantages like high viscosity, short setting time, and high intraoral solubility decreased its use as luting cement.<sup>7</sup>

Glass ionomer cements have been very popular for the cementation of fixed space maintainers.<sup>8</sup> Relative to zinc phosphate it has lower solubility in saliva, higher tensile and compressive strengths, and also form ionic bonds with stainless steel.<sup>7</sup> The key disadvantage of this cement is its sensitivity to moisture during its setting, and maximum bond strength being reached after 24 hours.<sup>5,8</sup>

New advancement in GIC technology occurred with the use of glass ionomer hybrid materials, resin-modified glass ionomers (RMGI), their favorable properties like low solubility, ability to chelate via acid-base reaction to enamel and metal, moisture tolerance, good tensile, and compressive strength confers it superior to the GICs. The only limitation of this cement is its questionable fluoride release.<sup>5,9</sup> The most recent resin cements, self-adhesive resin cements were introduced in 2002. These cements mix the advantages of adhesive and conventional luting agents and were designed to overcome the drawbacks of both traditional and resin cements. Adhesion occurs by micromechanical retention and chemical retention between monomer acidic groups and hydroxyapatite.<sup>10</sup>

### DISCLAIMER

THIS IS COPYRIGHTED CONTENT. Unauthorized use, including screenshots, copying, misuse, reuse, or resale of any content from this app, is strictly prohibited. Our app monitors and records all screenshots and recordings. Violators will face strict legal action.

THIS IS COPYRIGHTED CONTENT. Unauthorized use, including screenshots, copying, misuse, reuse, or resale of any content from this app, is strictly prohibited. Our app monitors and records all screenshots and recordings. Violators will face strict legal action.

DISCLAIMER  
THIS IS COPYRIGHTED CONTENT. Unauthorized use, including screenshots, copying, misuse, reuse, or resale of any content from this app, is strictly prohibited. Our app monitors and records all screenshots and recordings. Violators will face strict legal action.



# PEDO+ORTHO

## SBQ 4

MOTHER SAYS THE CHILD IS KNOWN EPILEPTIC. SHE SAYS HE HAS AN ABSENCE SEIZURE EVEN THOUGH HE TAKES MEDICATION. IT HAS REDUCED BUT NOT FULLY GONE.

### I. What precaution will you take?

- A. Using a mouth prop
- B. Avoiding dental light overhead
- C. Send urgently to GP

### II. What else must you inform parents in relation to her medication? (this time they didn't mention name of drug)

- A. Gingival enlargement
- B. Bleeding
- C. Excessive calculus formation
- D. Dry mouth
- E. Dental caries

## P.O.W.E.R NOTES SBQ 4

- I.
  - Option (C) is rules out. In the question it's mentioned that there's absence of seizures, but the patient takes medication.
  - No need to avoid dental light instead you can dim them because bright flashlight can be triggers. Or you can ask the patient to wear the eye wear.
  - It's recommended to use a mouth prop in TG as in case if episode happens while working, it would be helpful for the patient to avoid tongue biting and would be helpful for the clinician to avoid any hand biting injury.
- II.
  - Oral manifestation of antiepileptic drugs: gingival enlargement
  - Bleeding would be a secondary concern.

REFERENCE: TG

Some antiepileptic drugs (phenytoin, sodium valproate, carbamazepine and barbiturates) can cause gingival enlargement (gingival hyperplasia). Gingival enlargement can be minimised with good oral hygiene; however, extensive gingival enlargement requires specialist management.

copying, misuse, reuse, or resale of any content from this app, is strictly prohibited. Our app monitors and records all screenshots and recordings. Violators will face strict legal action.

## DISCLAIMER

THIS IS COPYRIGHTED CONTENT. Unauthorized use, including screenshots, copying, misuse, reuse, or resale of any content from this app, is strictly prohibited. Our app monitors and records all screenshots and recordings. Violators will face strict legal action.

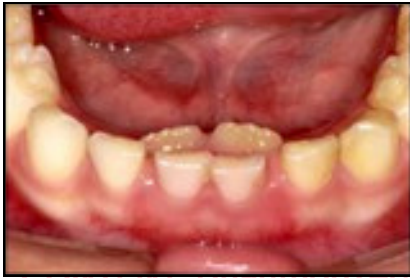DISCLAIMER  
THIS IS COPYRIGHTED CONTENT. Unauthorized use, including screenshots, copying, misuse, reuse, or resale of any content from this app, is strictly prohibited. Our app monitors and records all screenshots and recordings. Violators will face strict legal action.

DISCLAIMER  
THIS IS COPYRIGHTED CONTENT. Unauthorized use, including screenshots, copying, misuse, reuse, or resale of any content from this app, is strictly prohibited. Our app monitors and records all screenshots and recordings. Violators will face strict legal action.

# PEDO+ORTHO

## SBQ 5

6 YEARS OLD GIRL PATIENT WITH HER MOTHER VISITS YOU. MOTHER IS CONCERNED ABOUT HER DAUGHTERS TEETH.(EXACT PHOTO) IT WAS VISIBLE ON THE PICTURE, THE PATIENT HAS 50% ERUPTED 31,41(LINGUALLY) BUT 81,71 ARE RETAINED AND IMMOBILE.



### I. What will you do?

- A. Ask patient to wiggle it ,encourage the mobility
- B. Extract labially erupted teeth
- C. Extract lingually erupted teeth
- D. Leave it as it naturally fall off

### P.O.W.E.R NOTES SBQ 5

- I.
  - The over retained deciduous teeth are immobile and require extraction. Mobility of the tooth is encouraged when the deciduous teeth are quite mobile in nature can be removed by increasing mobility to avoid any kind psychological trauma. So, option (A) is ruled out.
  - According to the picture the permanent mandibular incisors are partially erupted. Unless the permanent teeth erupt till the occlusal level extraction is not required. You can leave it and wait until it exfoliates on its own.

REFERENCE attached on next page.

THIS IS COPYRIGHTED CONTENT. Unauthorized use, including screenshots, copying, misuse, reuse, or resale of any content from this app, is strictly prohibited. Our app monitors and records all screenshots and recordings. Violators will face strict legal action.

#### DISCLAIMER

THIS IS COPYRIGHTED CONTENT. Unauthorized use, including screenshots, copying, misuse, reuse, or resale of any content from this app, is strictly prohibited. Our app monitors and records all screenshots and recordings. Violators will face strict legal action.

THIS IS COPYRIGHTED CONTENT. Unauthorized use, including screenshots, copying, misuse, reuse, or resale of any content from this app, is strictly prohibited. Our app monitors and records all screenshots and recordings. Violators will face strict legal action.

**DISCLAIMER**  
THIS IS COPYRIGHTED CONTENT. Unauthorized use, including screenshots, copying, misuse, reuse, or resale of any content from this app, is strictly prohibited. Our app monitors and records all screenshots and recordings. Violators will face strict legal action.

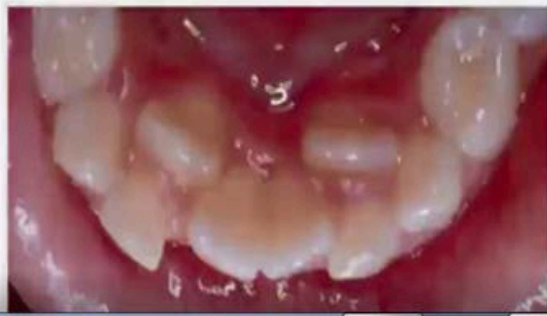# PEDO+ORTHO

## P.O.W.E.R NOTES SBQ 5

Otherwise commonly referred to as 'shark teeth', lower anterior crowding is a very common issue seen in the early mixed dentition. Often parents attend a dental practice worried that a primary tooth has not exfoliated despite its permanent successor erupting lingually to it. Even though this may appear abnormal, this situation very rarely needs any intervention from a dental practitioner. In more than 90% of cases, the primary tooth will eventually exfoliate, and the permanent tooth still erupt fully into the arch and migrate forward with tongue pressure (3). Removing the primary tooth is only of benefit if:

- the tooth is not mobile at all despite the permanent successor being fully erupted;
- enough time (usually six to 12 months) has been given beyond the normal stage of development the tooth is expected to exfoliate by;
- there is evidence the permanent successor will not erupt and become impacted or erupt severely ectopically without this extraction; and/or
- the primary tooth is significantly impacting normal hygiene and dietary practices.

It is important to not proceed with extraction of a primary tooth unless it is absolutely necessary as this is often the child's first exposure to a dental procedure. For them to have to sit through local anaesthetic and a tooth extraction as their first ever dental experience may lead to a negative experience and may induce dental anxiety. Lower anterior crowding indicates a developing malocclusion and is better managed orthodontically, typically in the mid to late mixed dentition.



# NOTES

CONTENT. Unauthorized use, including screenshots, copying, misuse, reuse, or resale of any content from this app, is strictly prohibited. Our app monitors and records all screenshots and recordings. Violators will face strict legal action.

THIS IS COPYRIGHTED CONTENT. Unauthorized use, including screenshots, copying, misuse, reuse, or resale of any content from this app, is strictly prohibited. Our app monitors and records all screenshots and recordings. Violators will face strict legal action.

### DISCLAIMER

THIS IS COPYRIGHTED CONTENT. Unauthorized use, including screenshots, copying, misuse, reuse, or resale of any content from this app, is strictly prohibited. Our app monitors and records all screenshots and recordings. Violators will face strict legal action.

### DISCLAIMER

THIS IS COPYRIGHTED CONTENT. Unauthorized use, including screenshots, copying, misuse, reuse, or resale of any content from this app, is strictly prohibited. Our app monitors and records all screenshots and recordings. Violators will face strict legal action.

THIS IS COPYRIGHTED CONTENT. Unauthorized use, including screenshots, copying, misuse, reuse, or resale of any content from this app, is strictly prohibited. Our app monitors and records all screenshots and recordings. Violators will face strict legal action.

### DISCLAIMER



# PEDO+ORTHO

## SBQ 6

A 16 YEAR FOOTBALL PLAYER COMES TO YOU FOR A MOUTHGUARD. YOU DECIDED TO DO SCALING BEFORE DELIVERY OF THE MOUTHGUARD. SHE SAYS THAT HER TEETH ARE SENSITIVE WHILE PERFORMING THE PROCEDURE (SUBGINGIVAL SCALING) AND DOES NOT WANT TO PROCEED FURTHER.

### I. What would you do?

- A. hand scaling with a curette
- B. Lignocaine infiltration in all 4 quadrants
- C. Apply Lignocaine Topical gel over the gums
- D. Ask the patient to wiggle his toes
- E. Reduce the water flow of the scaler

### II. She had mild crowding and wanted the treatment for that. Now, keeping in mind about the girl's oral hygiene/ complaint during the procedure. What will you emphasize to tell her regarding the risks of treatment ?

- A. Pain and discomfort.
- B. White Spot Lesion (WSL)
- C. Difficult to maintain oral hygiene after braces.
- D. Relapse.
- E. Root resorption.

### III. You took opg (opg was not given) . Which information is significant from opg ?

- A. Crowding in Permanent teeth
- B. Presence of third molars
- C. Pathology

### IV. What advice would you give about using diet cola?

- A. Restrict it to meal times
- B. Reduce the amount of diet cola intake.

### V. Diet soft drinks is not good for oral and general health because

- A. Have low ph
- B. Have sugars
- C. Have caffeine

### VI. What can be the side effect of sweeteners in coca cola?

- A. Diarrhoea
- B. Headache
- C. Excessive urination
- D. Dry mouth

#### DISCLAIMER

THIS IS COPYRIGHTED CONTENT. Unauthorized use, including screenshots, copying, misuse, reuse, or resale of any content from this app, is strictly prohibited. Our app monitors and records all screenshots and recordings. Violators will face strict legal action.

#### DISCLAIMER

THIS IS COPYRIGHTED CONTENT. Unauthorized use, including screenshots, copying, misuse, reuse, or resale of any content from this app, is strictly prohibited. Our app monitors and records all screenshots and recordings. Violators will face strict legal action.

THIS IS COPYRIGHTED CONTENT. Unauthorized use, including screenshots, copying, misuse, reuse, or resale of any content from this app, is strictly prohibited. Our app monitors and records all screenshots and recordings. Violators will face strict legal action.

#### DISCLAIMER



# PEDO+ORTHO

## SBQ 6

VII. Patient was diagnosed as prediabetic and was advised diet plan and exercise by gp. She had also heard about sugar substitutes that are good for oral health. Which is the sugar substitute ( word was sweetener) you would choose for both her oral and general health?

- A. Sorbitol
- B. Xylitol (not in some centers))
- C. Saccharine
- D. Erythritol
- E. Aspartame
- F. Sucralose
- G. Stevia

DISCLAIMER

THIS IS COPYRIGHTED CONTENT. Unauthorized use, including screenshots, copying, misuse, reuse, or resale of any content from this app, is strictly prohibited. Our app monitors and records all screenshots and recordings. Violators will face strict legal action.

THIS IS COPYRIGHTED CONTENT. Unauthorized use, including screenshots, copying, misuse, reuse, or resale of any content from this app, is strictly prohibited. Our app monitors and records all screenshots and recordings. Violators will face strict legal action.

DISCLAIMER

THIS IS COPYRIGHTED CONTENT. Unauthorized use, including screenshots, copying, misuse, reuse, or resale of any content from this app, is strictly prohibited. Our app monitors and records all screenshots and recordings. Violators will face strict legal action.

THIS IS COPYRIGHTED CONTENT. Unauthorized use, including screenshots, copying, misuse, reuse, or resale of any content from this app, is strictly prohibited. Our app monitors and records all screenshots and recordings. Violators will face strict legal action.

THIS IS COPYRIGHTED CONTENT. Unauthorized use, including screenshots, copying, misuse, reuse, or resale of any content from this app, is strictly prohibited. Our app monitors and records all screenshots and recordings. Violators will face strict legal action.

DISCLAIMER

THIS IS COPYRIGHTED CONTENT. Unauthorized use, including screenshots, copying, misuse, reuse, or resale of any content from this app, is strictly prohibited. Our app monitors and records all screenshots and recordings. Violators will face strict legal action.

# PEDO+ORTHO

## P.O.W.E.R NOTES SBQ 6

- I.
  - Ultrasonic scalers can induce discomfort, pain and dentinal hypersensitivity.
  - Hand scaling will also cause discomfort. Option (A) is ruled out.
  - If you reduce the water in the scaler, more heat will be generated, and it will be more harmful for the teeth. option (E) is ruled out.
  - Oxalate acid is a desensitising agent, before the scaling and root planing, if you apply it on the tooth surface it seals the tubules. Oxalate acid works within minutes. Oxalate is the 1<sup>st</sup> preference.
  - After oxalate acid, the second-best option is lignocaine infiltration.
  - Sensitivity is coming from the dentin so, application of lignocaine gel on the gum will not work. Option (C) is ruled out.

According to the new research, scaling and root planing under LA can reduce the probing depths rather than doing without LA. Therefore, LA has a positive effect on scaling and root planing.

### REFERENCE:

The results of the present study show that LA improved NSPT outcomes (reduced PD and BI) at the patient level. However, the results should be interpreted with caution owing to the uneven distribution of age, sex, and smoking status in the sample and the mismatch between baseline PD and BI. Multivariate analyses were used to adjust for other factors that affect NSPT. The multilevel analyses confirmed the benefit of LA for treatment outcomes after NSPT when other factors that might have affected NSPT outcomes were adjusted. A previous study demonstrated that more than 60% of patients might suffer from some degree of pain during periodontal scaling.<sup>[12]</sup> Perceived pain can hinder the use of ultrasonic or hand instruments in the bottoms of periodontal pockets where dental plaque and calculus collects. Several studies have compared the effects of different pain control regimens during NSPT on treatment outcomes.<sup>[4-8,10-12]</sup> However, data on whether LA affects NSPT outcomes are still limited. The results of this study demonstrate that LA improves treatment outcomes.

PD and BI are indices of periodontal inflammation. Improving PD and BI depends on removing initiating factors (ie, dental plaque); local stimulating factors, such as calculus and pigment; and systemic promoting factors, such as systemic diseases and hormones. LA effectively eliminates or reduces the pain of patients, which reduces anxiety during treatment and improves cooperation with doctors. Better cooperation is also conducive to a more thorough debridement of the deeper periodontal pockets, the root bifurcated area, and other areas that are difficult to operate on without LA. In addition, epinephrine (bluish blue) is added to local anesthetics used for oral treatment to increase their effects and duration. Epinephrine also has hemostatic effects in local anesthetics, which can help periodontists obtain a better operative field of vision.

recordings. Violators will face strict legal action.

### DISCLAIMER

THIS IS COPYRIGHTED CONTENT. Unauthorized use, including screenshots, copying, misuse, reuse, or resale of any content from this app, is strictly prohibited. Our app monitors and records all screenshots and recordings. Violators will face strict legal action.

DISCLAIMER  
THIS IS COPYRIGHTED CONTENT. Unauthorized use, including screenshots, copying, misuse, reuse, or resale of any content from this app, is strictly prohibited. Our app monitors and records all screenshots and recordings. Violators will face strict legal action.

# PEDO+ORTHO

## P.O.W.E.R NOTES SBQ 6

- II. • If the patient starts ortho treatment and not willing to maintain the OH, the periodontal condition can get worse.
- Braces will compromise the oral hygiene practices.
- Both options (A) and (B) are correct but they don't answer the question.
- III. • Crowding can be appreciated clinically and in OPG crowding is not appreciated well as it can be obliterated. Option (A) is ruled out.
- Patient doesn't give any history to suspect any pathology. So, option (C) is ruled out.
- Impacted molars may not be seen clinically. Therefore, OPG will be helpful in that case.
- IV. Frequency of sugar intake has more impact on developing caries rather the amount / quantity of sugar intake.
- Option (A) is the best.
- V. • "Diet soft drinks" doesn't have sugars. It has artificial sweeteners. Option (B) is ruled out.
- All the soft drinks don't have caffeine. Option (C) is ruled out.
- Lower pH has an impact on both oral health and gut health.
- VI. • Diet Coke contains the artificial sweeteners **aspartame** and **acesulfame potassium**. These sweeteners are used to provide sweetness without the calories of sugar.
- Diarrhoea is a side effect of **xylitol**.
- Aspartame is carcinogenic. It has side effects of headache, depression and mood swings. It can also lead to mental health issues.
- VII. • Stevia is plant derived. Completely sugar free sugar substitute.
- Stevia is the safest among all given. It contains no calory.
- Sucralose, aspartame, saccharine are artificial sugars.
- Xylitol and sorbitol are natural sugars. They are not zero caloric. They are alcohol-based sugars.
- Patient is prediabetic. So, it's good to avoid calories. So, Xylitol and sorbitol are ruled out even though they are natural sugars.

### REFERENCE:

#### Natural intense sweeteners

More recently 'natural' sweeteners have appeared on the market such as Stevia (Food additive code number 960) and Monk Fruit extract (nd code number associated). Natural sweeteners are typically derived from plants. Stevia is between 200 - 300 times sweeter than regular sugar and contains no energy (kilojoules or calories). Monk fruit extract is between 250 and 400 times sweeter than regular sugar and also contains no energy. Stevia and monk fruit extract have a history of safe consumption and are all approved for use in Australia. Natural sweeteners are used in many food and drinks but are commonly used to sweeten flavoured waters and soft drinks.

### DISCLAIMER

THIS IS COPYRIGHTED CONTENT. Unauthorized use, including screenshots, copying, misuse, reuse, or resale of any content from this app, is strictly prohibited. Our app monitors and records all screenshots and recordings. Violators will face strict legal action.

### DISCLAIMER

THIS IS COPYRIGHTED CONTENT. Unauthorized use, including screenshots, copying, misuse, reuse, or resale of any content from this app, is strictly prohibited. Our app monitors and records all screenshots and recordings. Violators will face strict legal action.

### DISCLAIMER

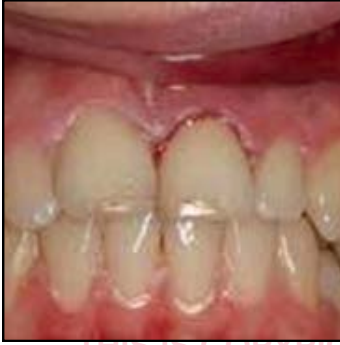THIS IS COPYRIGHTED CONTENT. Unauthorized use, including screenshots, copying, misuse, reuse, or resale of any content from this app, is strictly prohibited. Our app monitors and records all screenshots and recordings. Violators will face strict legal action.



# PEDO+ORTHO

## SBQ 7

### SUBLUXATION CASE



**I. In the follow-up review appointment after 4 weeks, which sign indicates that the tooth is failing ?**

- A. Increasing discolouration
- B. Reduced mobility
- C. Pulp canal obliteration

### P.O.W.E.R NOTES SBQ 7

**I. Reduced mobility and pulp canal obliteration are the positive signs. Pulp canal obliteration can be seen more commonly in immature teeth than mature teeth. and it's considered as a neutral sign rather than an unfavourable outcome.**

#### Unfavourable outcomes

- Pain and discomfort
- Pulp necrosis
- Discolouration
- Root resorption
- Abscess formation

THIS IS COPYRIGHTED CONTENT. Unauthorized use, including screenshots, copying, misuse, reuse, or resale of any content from this app, is strictly prohibited. Our app monitors and records all screenshots and recordings. Violators will face strict legal action.

**DISCLAIMER**  
THIS IS COPYRIGHTED CONTENT. Unauthorized use, including screenshots, copying, misuse, reuse, or resale of any content from this app, is strictly prohibited. Our app monitors and records all screenshots and recordings. Violators will face strict legal action.

THIS IS COPYRIGHTED CONTENT. Unauthorized use, including screenshots, copying, misuse, reuse, or resale of any content from this app, is strictly prohibited. Our app monitors and records all screenshots and recordings. Violators will face strict legal action.

#### DISCLAIMER

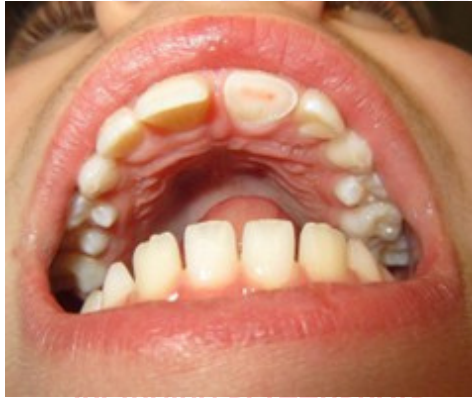THIS IS COPYRIGHTED CONTENT. Unauthorized use, including screenshots, copying, misuse, reuse, or resale of any content from this app, is strictly prohibited. Our app monitors and records all screenshots and recordings. Violators will face strict legal action.



# PEDO+ORTHO

## SBQ 8

**A 12 YR OLD PATIENT PRESENTED TO YOU AFTER A TRAUMA.( ENAMEL AND DENTINE FRACTURE WITH PINK SPOT)**



### I. What is your provisional diagnosis?

- A. Uncomplicated crown fracture with Uninjured PDL
- B. Complicated crown fracture with normal PDL
- C. Complicated crown fracture with luxation
- D. Uncomplicated crown fracture with luxation.

### II. What is the immediate treatment you will provide this patient ?

- A. Direct resin restoration
- B. Pulpotomy with non staining silicate (mta)
- C. Pulpectomy with non setting calcium
- D. Restore fast setting calcium and GIC

### III. When to review ?

- A. 6-8 week, 3 months, 6 months ,1 year
- B. 2 weeks, 4 weeks, 6 weeks
- C. 2-3 weeks and so on till 5 years
- D. 6-8 weeks, 6m, 1y, 5y
- E. 4-6w, 3m, 6m, 1y

### IV. How will you create awareness of wearing mouth guards among players? (no club meetings)

- A. Engage with coaches and explain to them the benefits of using mouth guard.
- B. Warn the players about what happens if they do not use a mouth guard.
- C. Telling the parents about the benefits of wearing mouthguards

THIS IS COPYRIGHTED CONTENT. Unauthorized use, including screenshots, copying, misuse, reuse, or resale of any content from this app, is strictly prohibited. Our app monitors and records all screenshots and recordings. Violators will face strict legal action.

**DISCLAIMER**  
THIS IS COPYRIGHTED CONTENT. Unauthorized use, including screenshots, copying, misuse, reuse, or resale of any content from this app, is strictly prohibited. Our app monitors and records all screenshots and recordings. Violators will face strict legal action.

## DISCLAIMER

THIS IS COPYRIGHTED CONTENT. Unauthorized use, including screenshots, copying, misuse, reuse, or resale of any content from this app, is strictly prohibited. Our app monitors and records all screenshots and recordings. Violators will face strict legal action.

# PEDO+ORTHO

## P.O.W.E.R NOTES SBQ 8

I. Enamel and dentin fracture with a pink spot mean the pulp is not yet exposed, but the dentine thickness above the overlying pulp is below 0.5mm. Dentin is so thin, and the pulp is reflected through the dentine. In this case it will not be bleeding. If the pulp is really exposed the blood would be oozing out due to high vascularity. Options (B) and (C) are ruled out as this is a uncomplicated #. (# of enamel and dentine)

There's no PDL or gingival injury. So, the best answer is option (A).

II. It's an uncomplicated crown #. No pulp therapy is required. Option (B) and (C) are ruled out.

There's a pink spot. So, direct resin restoration may not be enough.

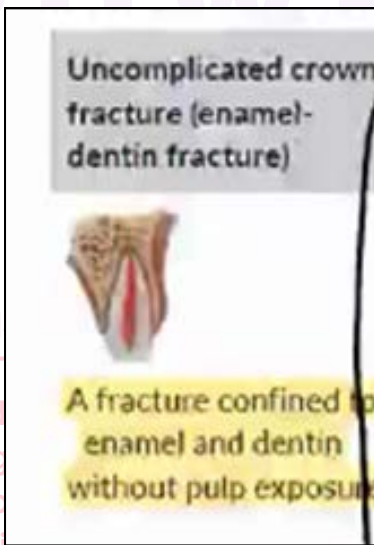
In this case we need to do indirect pulp capping. (IPC). We need to apply an agent which stimulates secondary/ tertiary dentine formation.  $\text{Ca}(\text{OH})_2 + \text{GIC}$  is used in IPC.

III. Uncomplicated crown # doesn't require the 3month and 6month follow up.

But need to do the 1<sup>st</sup> review at 6-8 weeks. And last review at 1yr. So, among the given options (A) is the best.

It also doesn't require follow up after 1yr. Options (C) and (D) get ruled out.

### REFERENCE:

TYPE OF #	FOLLOW UP
 <p>Uncomplicated crown fracture (enamel-dentin fracture)</p> <p>A fracture confined to enamel and dentin without pulp exposure</p>	<p>Follow up</p> <p>Clinical and radiographic evaluations are necessary:</p> <ul style="list-style-type: none"> <li>after 6-8 wk</li> <li>after 1 y</li> <li>If there is an associated luxation, root fracture or the suspicion of an associated luxation injury, the luxation follow-up regimen prevails and should be used. Longer follow ups will be needed</li> </ul>

### DISCLAIMER

THIS IS COPYRIGHTED CONTENT. Unauthorized use, including screenshots, copying, misuse, reuse, or resale of any content from this app, is strictly prohibited. Our app monitors and records all screenshots and recordings. Violators will face strict legal action.

### DISCLAIMER

THIS IS COPYRIGHTED CONTENT. Unauthorized use, including screenshots, copying, misuse, reuse, or resale of any content from this app, is strictly prohibited. Our app monitors and records all screenshots and recordings. Violators will face strict legal action.


### DISCLAIMER

THIS IS COPYRIGHTED CONTENT. Unauthorized use, including screenshots, copying, misuse, reuse, or resale of any content from this app, is strictly prohibited. Our app monitors and records all screenshots and recordings. Violators will face strict legal action.

# PEDO+ORTHO

## P.O.W.E.R NOTES SBQ 8

### III. REFERENCE:

TYPE OF #	FOLLOW UP
<p>Complicated crown fracture (enamel-dentin fracture with pulp exposure)</p>  <p>A fracture confined to enamel and dentin with pulp exposure</p>	<p>Follow up</p> <p>Clinical and radiographic evaluations are necessary:</p> <ul style="list-style-type: none"> <li>• after 6-8 wk</li> <li>• after 3 mo</li> <li>• after 6 mo</li> <li>• after 1 y</li> <li>• If there is an associated luxation, root fracture or the suspicion of an associated luxation injury, the luxation follow-up regimen prevails and should be used. Longer follow ups will be needed</li> </ul>

- IV. This is a child patient so both education and supervision is needed. They need somebody to reinforce it.  
Among the given option (A) is the best.

### REFERENCE:

2.7.	There should be targeted training in assessment and provision of oral protection in schools, sporting clubs, and workplaces.
2.8.	Protective equipment such as helmets and mouthguards should be used during training as well as competition.
2.9.	There should be community action in sports clubs, schools, and workplaces to reduce risk and encourage mouthguard use. Where a risk of oral injury exists, sporting bodies should adopt a mandatory mouthguard policy such as that outlined in Appendix 1.
2.10.	The need to wear a mouthguard should be assessed by a dentist based on risk factors, including an individual's sporting or occupational activities and dental anatomy.

### DISCLAIMER

THIS IS COPYRIGHTED CONTENT. Unauthorized use, including screenshots, copying, misuse, reuse, or resale of any content from this app, is strictly prohibited. Our app monitors and records all screenshots and recordings. Violators will face strict legal action.

### DISCLAIMER

THIS IS COPYRIGHTED CONTENT. Unauthorized use, including screenshots, copying, misuse, reuse, or resale of any content from this app, is strictly prohibited. Our app monitors and records all screenshots and recordings. Violators will face strict legal action.

THIS IS COPYRIGHTED CONTENT. Unauthorized use, including screenshots, copying, misuse, reuse, or resale of any content from this app, is strictly prohibited. Our app monitors and records all screenshots and recordings. Violators will face strict legal action.

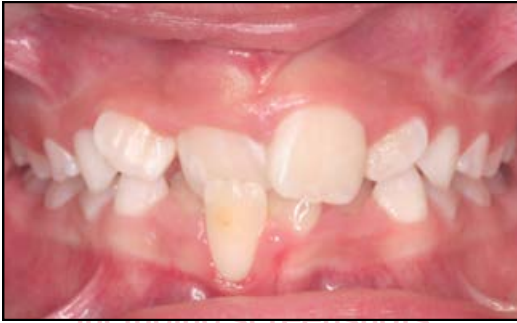### DISCLAIMER



# PEDO+ORTHO

## SBQ 9

9 YEAR OLD PATIENT WITH MOTHER. 11 41 CROSSBITE, 41 GINGIVAL RECESSON. YOU ARE A DENTIST WORKING IN A REGIONAL AREA. AN ORTHODONTIST VISITS YOU EVERY WEEK AND HE TOLD YOU HE WOULD HELP YOU IN TREATING MILD MALOCCLUSIONS.



### I. Mother was worried. How will you proceed with the treatment?

- A. Delay the treatment
- B. Immediately because of trauma and gingival recession irt 41
- C. Immediately because canine eruption would cause crowding

### II. Mother had heard about the white spot lesions following orthodontic treatment. What will be your best advice?

- A. Interactive videos to show about oral hygiene practices
- B. Clear aligners will be the best option
- C. Patients are not at High risk of developing WSLs because of good oral hygiene. So no treatment is required.
- D. Assure that it is reversible

### III. Even after educating the mother, she was worried. Now what will you do?

- A. 5000 ppm fluoride dentifrice
- B. Apply Fluoride varnish 3 monthly
- C. Gel form fluoride application
- D. Fluoride mouthwash

### IV. What will be the result if you delay or don't treat this condition in addition to 41 pushing outwards?

- A. Development of skeletal malocclusion
- B. Maxillary anterior crowding
- C. Mandibular crowding and growth cessation

THIS IS COPYRIGHTED CONTENT. Unauthorized use, including screenshots, copying, misuse, reuse, or resale of any content from this app, is strictly prohibited. Our app monitors and records all screenshots and recordings. Violators will face strict legal action.

**DISCLAIMER**  
THIS IS COPYRIGHTED CONTENT. Unauthorized use, including screenshots, copying, misuse, reuse, or resale of any content from this app, is strictly prohibited. Our app monitors and records all screenshots and recordings. Violators will face strict legal action.

## DISCLAIMER

THIS IS COPYRIGHTED CONTENT. Unauthorized use, including screenshots, copying, misuse, reuse, or resale of any content from this app, is strictly prohibited. Our app monitors and records all screenshots and recordings. Violators will face strict legal action.



# PEDO+ORTHO

## SBQ 9

**V. For confirming the malocclusion what are you going to do?**

- A. Lateral Cephalogram
- B. Measurement of overjet
- C. Check centric occlusion
- D. Take more photos

**VI. What can you infer from the lateral ceph?**

- A. Dental crowding
- B. Arch malalignment
- C. Skeletal malocclusion

THIS IS COPYRIGHTED CONTENT. Unauthorized use, including screenshots, copying, misuse, reuse, or resale of any content from this app, is strictly prohibited. Our app monitors and records all screenshots and recordings. Violators will face strict legal action.

THIS IS COPYRIGHTED CONTENT. Unauthorized use, including screenshots, copying, misuse, reuse, or resale of any content from this app, is strictly prohibited. Our app monitors and records all screenshots and recordings. Violators will face strict legal action.

THIS IS COPYRIGHTED CONTENT. Unauthorized use, including screenshots, copying, misuse, reuse, or resale of any content from this app, is strictly prohibited. Our app monitors and records all screenshots and recordings. Violators will face strict legal action.

THIS IS COPYRIGHTED CONTENT. Unauthorized use, including screenshots, copying, misuse, reuse, or resale of any content from this app, is strictly prohibited. Our app monitors and records all screenshots and recordings. Violators will face strict legal action.

### DISCLAIMER

THIS IS COPYRIGHTED CONTENT. Unauthorized use, including screenshots, copying, misuse, reuse, or resale of any content from this app, is strictly prohibited. Our app monitors and records all screenshots and recordings. Violators will face strict legal action.

### DISCLAIMER

THIS IS COPYRIGHTED CONTENT. Unauthorized use, including screenshots, copying, misuse, reuse, or resale of any content from this app, is strictly prohibited. Our app monitors and records all screenshots and recordings. Violators will face strict legal action.

# PEDO+ORTHO

## P.O.W.E.R NOTES SBQ 8

- I. If there was no trauma and no recession, single tooth cross bite would not have been treated. Delaying the treatment is not an option in this case. So, option (A) gets ruled out.  
Both (B) and (C) statements are correct. But crowding is a consequence. Crowding can be treated later.  
But if trauma and recession is not treated immediately, the child can lose the permanent tooth. option (B) is the best among given.

### Crossbites

Anterior and posterior crossbites are caused by dental or skeletal discrepancies, or a combination of the two. A dental crossbite usually involves one or two teeth whereas a skeletal crossbite generally involves multiple teeth. Other factors such as a high palatal vault, mouth breathing, cleft palate and skeletal malocclusions (class II or class III) more commonly have skeletal crossbites (4).

Crossbites in the primary dentition usually do not need early correction unless the crossbite is causing a functional shift or it has been indicated by a medical specialist, usually an ENT specialist or sleep physician, for obstructive sleep apnoea. In the early mixed dentition, correction of any crossbite is typically done once the first permanent molars and permanent incisors have erupted so that it is easier to maintain the correction and any incisor irregularities can be corrected at the same time. In general, single tooth crossbites do not need early correction unless there is evidence of trauma to teeth or gingival recession occurring.

Posterior crossbites are generally corrected with the use of a maxillary expander. In the early mixed dentition either a removable appliance with an expansion screw or a fixed maxillary expander can be used with a similar level of efficacy as the palatal suture has not yet started to interdigitate. Anterior crossbites are generally corrected at this stage using a removable appliance with a Z-spring or partial fixed appliances.

- II. Severe crowding can be treated better with fixed orthodontic treatment rather than the clear aligners. If oral hygiene practices are not done well, even the clear aligners can cause demineralisation spots. Option (B) is ruled out. White spot lesions are not always reversible. If they have noticed in the very initial stage then it could be reversible. Otherwise it's not. option (D) is ruled out. Not only the oral hygiene but also the diet has an impact on developing caries. Even though the patient brushes well and maintain OH, if the patient is having a sugary diet, then the patient is at a risk of getting cavities. Option (C) is ruled out. Option (A) is the best answer.

THIS IS COPYRIGHTED CONTENT. Unauthorized use, including screenshots, copying, misuse, reuse, or resale of any content from this app, is strictly prohibited. Our app monitors and records all screenshots and recordings. Violators will face strict legal action.

### DISCLAIMER

THIS IS COPYRIGHTED CONTENT. Unauthorized use, including screenshots, copying, misuse, reuse, or resale of any content from this app, is strictly prohibited. Our app monitors and records all screenshots and recordings. Violators will face strict legal action.

### DISCLAIMER

THIS IS COPYRIGHTED CONTENT. Unauthorized use, including screenshots, copying, misuse, reuse, or resale of any content from this app, is strictly prohibited. Our app monitors and records all screenshots and recordings. Violators will face strict legal action.

THIS IS COPYRIGHTED CONTENT. Unauthorized use, including screenshots, copying, misuse, reuse, or resale of any content from this app, is strictly prohibited. Our app monitors and records all screenshots and recordings. Violators will face strict legal action.

### DISCLAIMER

# PEDO+ORTHO

## P.O.W.E.R NOTES SBQ 8

III. Even after explaining about OH practices the mother is worried. So, the mother is worried beyond oral hygiene practices.

Daily high strength toothpaste is more important than varnish application in the clinic. But mother is worried that the child might not be able maintain the OH with brushing. In that case varnish application is more important than brushing regularly with a fluoride toothpaste.

In case of poor patient compliance with using preventive protocols at home, it would be advantageous to apply fluoride varnish 2 times a year, perhaps at all orthodontic visits.

Fluoride varnish vs fluoride gel: varnish has more longevity on the surface.

Toothpaste and gels for home use and varnishes are for the chair side use.

Fluoride mouthwashes are not that helpful when comparing with varnish. So, among the give option (B) is the best.

### Do fluoride mouth rinses help?

In general, fluoride mouth rinses can add an extra exposure of fluoride and might be beneficial to some patients, but there is no strong evidence that fluoride mouth rinses can effectively prevent or reduce the severity of white spot lesions during orthodontic treatment.

There is some evidence that a daily sodium fluoride mouthwash is effective in reducing the severity of white spots in people undergoing orthodontic treatment, but it is not strong. Little has been published concerning its use in orthodontic patients or how successfully it minimizes the development of white spot lesions.<sup>20</sup> The method of fluoride delivery is important: a fluoride mouth rinse will work best if it is used regularly by the patient. Geiger et al<sup>9</sup> reported that only 42% of patients rinsed with sodium fluoride mouth rinse at least every other day, but patients who were more compliant had fewer white spot lesions.

### What fluoride treatment is recommended?

The use of higher-concentration fluoride toothpastes and gels (1500-5000 ppm) twice a day during orthodontic treatment has demonstrated a demineralization-inhibiting tendency.<sup>15</sup>

For many years, fluoride toothpaste has been considered the most effective and widely used method of applying fluoride, in addition to fluoridated water. The efficacy of conventional fluoride toothpaste (1000 ppm) has been documented in many studies; evidence suggests that toothpaste containing 5000 ppm fluoride can further reduce demineralization and enhance remineralization.<sup>16,17</sup> Recently, it was suggested that patients undergoing orthodontic treatment should brush twice a day with 5000-ppm fluoride toothpaste or gel.<sup>16</sup> This regimen was reported to provide greater prevention than the daily use of 500-ppm sodium fluoride rinse.<sup>18</sup>

As part of the recommended fluoride regimen, patients with orthodontic fixed bonded appliances should have an in-office fluoride varnish application at least twice a year; this provides a high concentration of fluoride to the teeth (5% sodium fluoride in an alcohol suspension of natural resins, approximately 22,000 ppm). The American Dental Association's Council on Scientific Affairs recommends that "moderate-risk and high-risk patients should receive in-office fluoride varnish at six-month intervals. A fluoride varnish application at three-month intervals may provide an additional caries prevention benefit."<sup>19</sup> In case of poor patient compliance with using preventive protocols at home, it would be advantageous to apply fluoride varnish more than 2 times a year, perhaps at all orthodontic visits.

THIS IS COPYRIGHTED  
CONTENT. Unauthorized use,  
including screenshots,  
copying, misuse, reuse, or  
resale of any content from  
this app, is strictly prohibited.  
Our app monitors and records  
all screenshots and  
recordings. Violators will face  
strict legal action.

### DISCLAIMER

THIS IS COPYRIGHTED CONTENT. Unauthorized use, including screenshots, copying, misuse, reuse, or resale of any content from this app, is strictly prohibited. Our app monitors and records all screenshots and recordings. Violators will face strict legal action.

DISCLAIMER  
THIS IS COPYRIGHTED CONTENT. Unauthorized use, including screenshots, copying, misuse, reuse, or resale of any content from this app, is strictly prohibited. Our app monitors and records all screenshots and recordings. Violators will face strict legal action.



# PEDO+ORTHO

## P.O.W.E.R NOTES SBQ 8

- IV. In cross bite the maxilla growth is affected. It hinders the maxillary growth. Mandibular growth will not stop. So, option (C) is incorrect. Both (A) and (B) are correct. Skeletal malocclusion has larger impact on patient's overall jaw and facial growth and aesthetics. More important to address the present situation otherwise will end up in skeletal class III malocclusion which requires complex treatment. Option (A) is the best answer.
- V. Lateral cephalogram will be helpful to rule out skeletal malocclusion.
- VI. Lateral cephalogram will be helpful to rule out skeletal malocclusion not the crowding or arch alignment.