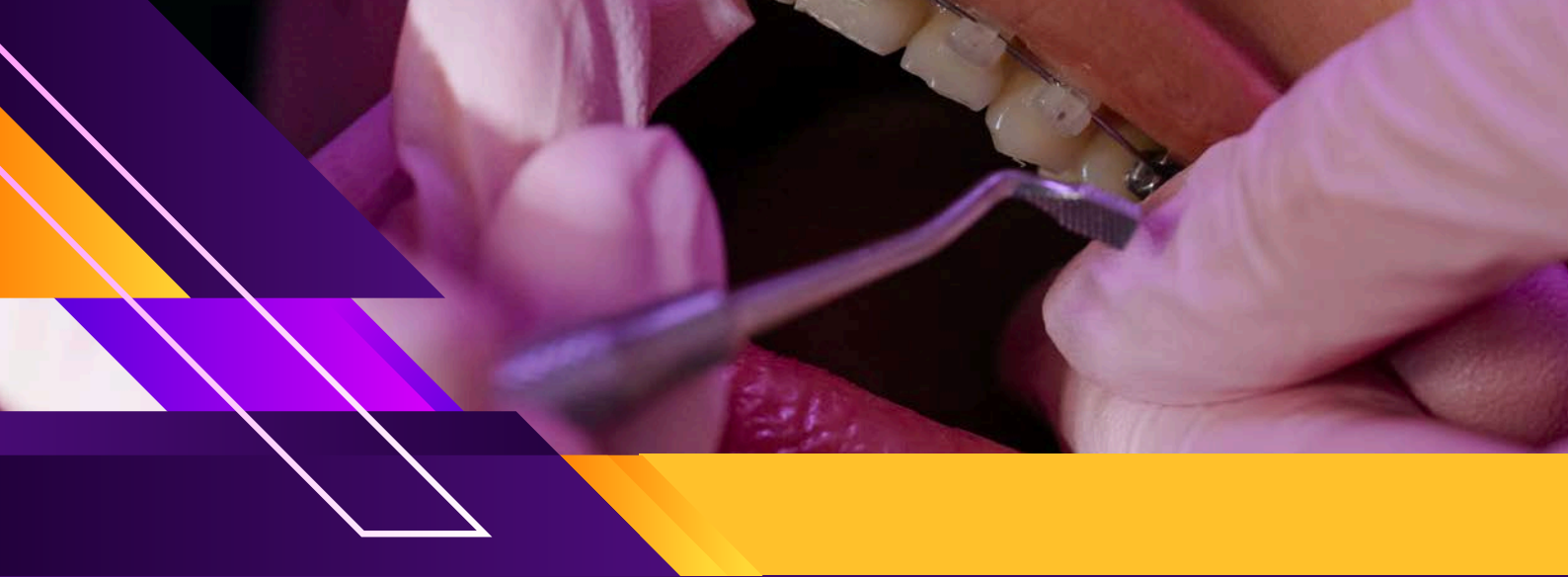



WINSPERT

WINSPERT

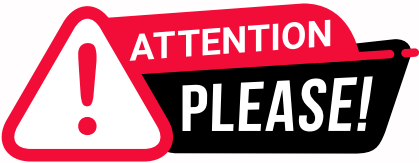# P.O.W.E.R

PREPARATION OF ADC WITH WINSPERT EXPERT REVIEW

# NOTES

By Dr. Jigyasa Sharma





# ORAL SURGERY

## SBQ 1

75 YEARS OLD, HAD HEPATITIS-B HISTORY AS A CHILD. HE HAD A STROKE 2 YEARS BACK AND WAS TAKING WARFARIN FOR IT BUT THE GP CHANGED IT TO DABIGATRAN RECENTLY. HAS HYPERTENSION, TAKING MEDICATION FOR IT, HAS ATRIAL FIBRILLATION.

### I. What is the best test to check warfarin?

- A. INR
- B. Prothrombin test
- C. Ptt
- D. Bt

### II. If you have to do extraction. What will you consider?

- A. Give ab prophylaxis
- B. Speak to GP and ask about liver function test (it mentioned for drug clearance)
- C. Reduce the dose of dabigatran
- D. Assume dabigatran will cause minimal bleeding and go ahead with local hemostatic measures

### III. When will you check inr?

- A. On the day of the procedure
- B. 36 hours before the procedure
- C. 48 hours before the procedure
- D. 72 hours before the procedure

### IV. Opg given 27 no 26 25. Isolated molar.

What will be the major risk in extracting 27 (complication for extraction)?

- A. Oaf (x-ray showed communication with the antrum)
- B. Tuberosity fracture
- C. Fracture of roots

### V. A patient on renal dialysis has end stage kidney disease. Goes for dialysis 3 times a week. You have to do an extraction. What is the best way to manage him? (asa)

- A. Treat on the day of dialysis
- B. Refer to a specialist for the dental treatment
- C. Treat her on non dialysis days
- D. Give painkillers

## DISCLAIMER

THIS IS COPYRIGHTED CONTENT. Unauthorized use, including screenshots, copying, misuse, reuse, or resale of any content from this app, is strictly prohibited. Our app monitors and records all screenshots and recordings. Violators will face strict legal action.

DISCLAIMER  
THIS IS COPYRIGHTED CONTENT. Unauthorized use, including screenshots, copying, misuse, reuse, or resale of any content from this app, is strictly prohibited. Our app monitors and records all screenshots and recordings. Violators will face strict legal action.

THIS IS COPYRIGHTED CONTENT. Unauthorized use, including screenshots, copying, misuse, reuse, or resale of any content from this app, is strictly prohibited. Our app monitors and records all screenshots and recordings. Violators will face strict legal action.

DISCLAIMER

# ORAL SURGERY

## SBQ 1

75 YEARS OLD, HAD HEPATITIS-B HISTORY AS A CHILD. HE HAD A STROKE 2 YEARS BACK AND WAS TAKING WARFARIN FOR IT BUT THE GP CHANGED IT TO DABIGATRAN RECENTLY. HAS HYPERTENSION, TAKING MEDICATION FOR IT, HAS ATRIAL FIBRILLATION.

### I. What is the best test to check warfarin?

- A. INR
- B. Prothrombin test
- C. Ptt
- D. Bt

### II. If you have to do extraction. What will you consider?

- A. Give ab prophylaxis
- B. Speak to GP and ask about liver function test (it mentioned for drug clearance)
- C. Reduce the dose of dabigatran
- D. Assume dabigatran will cause minimal bleeding and go ahead with local hemostatic measures

### III. When will you check inr?

- A. On the day of the procedure
- B. 36 hours before the procedure
- C. 48 hours before the procedure
- D. 72 hours before the procedure

### IV. Opg given 27 no 26 25. Isolated molar.

What will be the major risk in extracting 27 (complication for extraction)?

- A. Oaf (x-ray showed communication with the antrum)
- B. Tuberosity fracture
- C. Fracture of roots

### V. A patient on renal dialysis has end stage kidney disease. Goes for dialysis 3 times a week. You have to do an extraction. What is the best way to manage him? (asa)

- A. Treat on the day of dialysis
- B. Refer to a specialist for the dental treatment
- C. Treat her on non dialysis days
- D. Give painkillers

## DISCLAIMER

THIS IS COPYRIGHTED CONTENT. Unauthorized use, including screenshots, copying, misuse, reuse, or resale of any content from this app, is strictly prohibited. Our app monitors and records all screenshots and recordings. Violators will face strict legal action.

DISCLAIMER  
THIS IS COPYRIGHTED CONTENT. Unauthorized use, including screenshots, copying, misuse, reuse, or resale of any content from this app, is strictly prohibited. Our app monitors and records all screenshots and recordings. Violators will face strict legal action.

THIS IS COPYRIGHTED CONTENT. Unauthorized use, including screenshots, copying, misuse, reuse, or resale of any content from this app, is strictly prohibited. Our app monitors and records all screenshots and recordings. Violators will face strict legal action.

DISCLAIMER

# ORAL SURGERY

## P.O.W.E.R NOTES SBQ 1

- I. The international normalised ratio (INR) blood test tells you how long it takes for your blood to clot. It is used to test clotting times in people taking warfarin.
- II. Patient is on one anticoagulant. So, we can proceed ahead with extraction in the absence of patient related factors. But in this there's a patient related factor (hx of hepatitis is present. This can prolong bleeding)
- III. We check INR within 24hrs. among the given (A) is the best.
- IV. 27 is an isolated, standalone maxillary molar which is more prone to get ankylosed. Therefore, there's a high risk of tuberosity fracture.
- V. According to TG, end stage kidney disease is a severe immune compromised situation. These patients are handled by the specialist and multidisciplinary team.

THIS IS COPYRIGHTED CONTENT. Unauthorized use, including screenshots, copying, misuse, reuse, or resale of any content from this app, is strictly prohibited. Our app monitors and records all screenshots and recordings. Violators will face strict legal action.

### DISCLAIMER

THIS IS COPYRIGHTED CONTENT. Unauthorized use, including screenshots, copying, misuse, reuse, or resale of any content from this app, is strictly prohibited. Our app monitors and records all screenshots and recordings. Violators will face strict legal action.

THIS IS COPYRIGHTED CONTENT. Unauthorized use, including screenshots, copying, misuse, reuse, or resale of any content from this app, is strictly prohibited. Our app monitors and records all screenshots and recordings. Violators will face strict legal action.

THIS IS COPYRIGHTED CONTENT. Unauthorized use, including screenshots, copying, misuse, reuse, or resale of any content from this app, is strictly prohibited. Our app monitors and records all screenshots and recordings. Violators will face strict legal action.

THIS IS COPYRIGHTED CONTENT. Unauthorized use, including screenshots, copying, misuse, reuse, or resale of any content from this app, is strictly prohibited. Our app monitors and records all screenshots and recordings. Violators will face strict legal action.

DISCLAIMER

THIS IS COPYRIGHTED CONTENT. Unauthorized use, including screenshots, copying, misuse, reuse, or resale of any content from this app, is strictly prohibited. Our app monitors and records all screenshots and recordings. Violators will face strict legal action.

DISCLAIMER

THIS IS COPYRIGHTED CONTENT. Unauthorized use, including screenshots, copying, misuse, reuse, or resale of any content from this app, is strictly prohibited. Our app monitors and records all screenshots and recordings. Violators will face strict legal action.



# ORAL SURGERY

## SBQ 2

A 65 YEARS OLD PATIENT HAS A PROBLEM AT 15 AND WANTS AN EXTRACTION. THE LADY HAD HYPERTENSION 155/95 BP, A STROKE 9 YEARS BACK, SMOKED 10 CIGARETTES IN A DAY, HAS EMPHYSEMA, PACEMAKER PRESENT. PATIENT TOLD THE DOCTOR THAT SHE NEEDS ANTIBIOTIC PROPHYLAXIS. THE PATIENT WAS VERY ANXIOUS.

### I. In which case surgical antibiotic prophylaxis is required?

- A. Hip replacement
- B. Mitral valve prolapse
- C. Ventricular septal defect
- D. Patent ductus arteriosus
- E. Mitral valve prolapse

### II. In which classification does this patient fall?

- A. ASA2
- B. ASA1
- C. ASA3
- D. ASA4
- E. ASA5

### III. IOPA/OPG given what will be the most likely complication with the extraction in this case?

- A. Dry socket
- B. Root fracture
- C. Sinus perforation
- D. Spread of infection
- E. Adjacent filling may fall out

### IV. By mistake during extraction, you displaced the opposing amalgam restoration as your forceps slipped. What will you do?

- A. Inform the patient, replace the restoration and ask him to pay
- B. Inform the patient, replace the restoration and you do it for free
- C. You don't tell the patient now to prevent additional stress and tell him in next appointment
- D. Inform the patient in that appointment and restore and ask him to pay
- E. Replace the restoration and do not tell the patient

### V. Patient requested for sedation as she is scared of needles and we have planned the nitrous oxide sedation. The patient came the next morning and had already taken diazepam 10gm. What will you do now?

- A. Lower the dose of nitrous oxide
- B. Do not administer nitrous
- C. Lower the dose of I<sub>a</sub> and normal nitrous oxide sedation
- D. Go ahead with planned treatment and give her nitrous oxide
- E. Go ahead with treatment but give nitrous only till the injection of I<sub>a</sub>

## DISCLAIMER

THIS IS COPYRIGHTED CONTENT. Unauthorized use, including screenshots, copying, misuse, reuse, or resale of any content from this app, is strictly prohibited. Our app monitors and records all screenshots and recordings. Violators will face strict legal action.

## DISCLAIMER

THIS IS COPYRIGHTED CONTENT. Unauthorized use, including screenshots, copying, misuse, reuse, or resale of any content from this app, is strictly prohibited. Our app monitors and records all screenshots and recordings. Violators will face strict legal action.

THIS IS COPYRIGHTED CONTENT. Unauthorized use, including screenshots, copying, misuse, reuse, or resale of any content from this app, is strictly prohibited. Our app monitors and records all screenshots and recordings. Violators will face strict legal action.

## DISCLAIMER

# ORAL SURGERY

## P.O.W.E.R NOTES SBQ 2

- I. None of the given options require ABP. Cyanotic heart defects require ABP. Valvular conditions don't require ABP. Patent ductus arteriosus is an acyanoitic condition, but it also gives some cyanosis.
- II. Due to uncontrolled HTN and smoking, this patient is falling under ASA class III.
  - ASA I- healthy
  - ASA II- mild and controlled
  - ASA III- uncontrolled and may require specialist referral
  - ASA IV- referral to hospital
  - ASA V- requires operation
- III.
  - Need the x-ray for marking the answer.
  - If it's a grossly broken max. molar, there's a risk of root #.
  - If there's an adjacent filling in relation to the extracting tooth, then option (E).
  - Sinus perforation can't be seen with the 2-dimentional. Radiograph doesn't review. We don't inform about sinus perforation before the treatment. When you identify a communication has occurred, you must correct it immediately and inform the patient. It's not the clinician's fault as the sinus line can't be seen with the 2-dimentional as it's a soft tissue lining and sometimes the root can overlap.
  - Spread of infection is not a complication with the aseptic techniques.
  - Dry socket is seen commonly in the mandible.
- IV. Must inform the patient what has happened and shouldn't charge from the patient as it's a mistake happened by the dentist.
- V. Both N2O and diazepam can't be given at the same time.

THIS IS COPYRIGHTED CONTENT. Unauthorized use, including screenshots, copying, misuse, reuse, or resale of any content from this app, is strictly prohibited. Our app monitors and records all screenshots and recordings. Violators will face strict legal action.

### DISCLAIMER

THIS IS COPYRIGHTED CONTENT. Unauthorized use, including screenshots, copying, misuse, reuse, or resale of any content from this app, is strictly prohibited. Our app monitors and records all screenshots and recordings. Violators will face strict legal action.

DISCLAIMER  
THIS IS COPYRIGHTED CONTENT. Unauthorized use, including screenshots, copying, misuse, reuse, or resale of any content from this app, is strictly prohibited. Our app monitors and records all screenshots and recordings. Violators will face strict legal action.

DISCLAIMER

THIS IS COPYRIGHTED CONTENT. Unauthorized use, including screenshots, copying, misuse, reuse, or resale of any content from this app, is strictly prohibited. Our app monitors and records all screenshots and recordings. Violators will face strict legal action.

# ORAL SURGERY

## SBQ 3

### INFRAORBITAL SPACE INFECTION

PT HAD FEVER 39.5, INFRAORBITAL SWELLING, OEDEMA AND TOOTH INVOLVED WAS MOBILE

#### I. Which tooth is likely to cause this infection?

- A. Canine
- B. Lateral incisor
- C. Central incisor
- D. First premolar
- E. Second molar

#### II. How to diagnose?

- A. Ept
- B. Cold test
- C. Heat test
- D. Percussion

#### III. The infection has spread to which facial space?

- A. Canine space
- B. Maxillary space
- C. Buccal space
- D. Labial space
- E. Palatal space

#### IV. What treatment can be done?

- A. Refer to hospital
- B. Extraction and drainage
- C. Extraction and antibiotics
- D. Rct and antibiotics
- E. Drainage through intraoral incision

#### V. Patient has a headache, can't open his eyes, nausea and drooping of eye.

What is happening?

- A. Maxillary sinusitis
- B. Cavernous sinus thrombosis
- C. Migraine

THIS IS COPYRIGHTED CONTENT. Unauthorized use, including screenshots, copying, misuse, reuse, or resale of any content from this app, is strictly prohibited. Our app monitors and records all screenshots and recordings. Violators will face strict legal action.

**DISCLAIMER**  
THIS IS COPYRIGHTED CONTENT. Unauthorized use, including screenshots, copying, misuse, reuse, or resale of any content from this app, is strictly prohibited. Our app monitors and records all screenshots and recordings. Violators will face strict legal action.

#### DISCLAIMER

THIS IS COPYRIGHTED CONTENT. Unauthorized use, including screenshots, copying, misuse, reuse, or resale of any content from this app, is strictly prohibited. Our app monitors and records all screenshots and recordings. Violators will face strict legal action.



# ORAL SURGERY

## P.O.W.E.R NOTES SBQ 3

- I. Canine has got the longest root, so, canine is mostly involved with infraorbital space infections. Also know as canine space infection.
- II. Cold test is the best vitality test. Infection comes from the necrosed pupal tissue. Percussion is an indicator of the inflammation within the periapical PDL. When there's a space infection, you need to identify the infected pulp. Percussion can become positive even with the traumatic occlusion. Percussion may become negative in this case as it's not a localised infection and it's a spreading infection and pus accumulation is beyond the PDL now. Percussion test reveals PLD inflammation due to traumatic bite, high point, food impaction.
- III. Involvement of the maxillary incisors and canines may result in a **canine space** infection, which manifests as dramatic swelling of the upper lip, canine fossa, and, frequently, the periorbital tissues.
- IV. Patient has high grade fever. It's a spreading infection with sever systemic features. Therefore, need to refer to the hospital as IV AB and extraction is immediately needed.
- V. Cavernous sinus thrombosis is the most common complication of infraorbital space infection.  
Cellulitis and respiratory space involvement are the most common complications of submandibular space infection.

THIS IS COPYRIGHTED CONTENT. Unauthorized use, including screenshots, copying, misuse, reuse, or resale of any content from this app, is strictly prohibited. Our app monitors and records all screenshots and recordings. Violators will face strict legal action.

### DISCLAIMER

THIS IS COPYRIGHTED CONTENT. Unauthorized use, including screenshots, copying, misuse, reuse, or resale of any content from this app, is strictly prohibited. Our app monitors and records all screenshots and recordings. Violators will face strict legal action.

THIS IS COPYRIGHTED CONTENT. Unauthorized use, including screenshots, copying, misuse, reuse, or resale of any content from this app, is strictly prohibited. Our app monitors and records all screenshots and recordings. Violators will face strict legal action.

THIS IS COPYRIGHTED CONTENT. Unauthorized use, including screenshots, copying, misuse, reuse, or resale of any content from this app, is strictly prohibited. Our app monitors and records all screenshots and recordings. Violators will face strict legal action.

WINSPERT  
P.O.W.E.R  
NOTES

DISCLAIMER  
THIS IS COPYRIGHTED CONTENT. Unauthorized use, including screenshots, copying, misuse, reuse, or resale of any content from this app, is strictly prohibited. Our app monitors and records all screenshots and recordings. Violators will face strict legal action.

# ORAL SURGERY

## SBQ 4

**A MALE PT IN HIS 30'S REPORTED TO YOU REGARDING A COMPLAINT OF CLICKING OF HIS TMJ. CEREBRAL PALSY CASE.**

**I. What is the best investigation to examine and diagnose his joint problem?**

- A. Ultrasound
- B. Cbct
- C. Opg, Lat oblique.
- D. MRI

**II. While examining, you notice a trismus. What is the minimum requirement for mouth opening in order to diagnose that it's not trismus? (Measuring mouth opening (trismus) mentioned limited mouth opening)**

- A. Fits 2 fingers of the practitioner
- B. Fits 3 fingers of the practitioners Fits 2
- C. Fingers of the patient
- D. Fits 3 fingers of the patent
- E. The mandible something

**III. 3rd molar needs extraction which xray modality would be the best for treatment planning?**

- A. Cbct
- B. Mri
- C. Ct scan
- D. Oral pantomogram

**IV. Which splint?**

- A. Mandibular repositioning splint
- B. Michigan splint (for TMD, MPDS & bruxism)
- C. Michigan and mandibular advancement splint
- D. Morning repositioning splint (Anterior repositioning splint) (Joint & disc problems)
- E. Mandibular advancement splint (Sleep apnoea)

**V. He has an injury on his forehead in which a part of skin peeled off and the blood was oozing. What kind of injury is it?**

- A. Abrasion
- B. Bruising
- C. Laceration
- D. Puncture

## DISCLAIMER

THIS IS COPYRIGHTED CONTENT. Unauthorized use, including screenshots, copying, misuse, reuse, or resale of any content from this app, is strictly prohibited. Our app monitors and records all screenshots and recordings. Violators will face strict legal action.

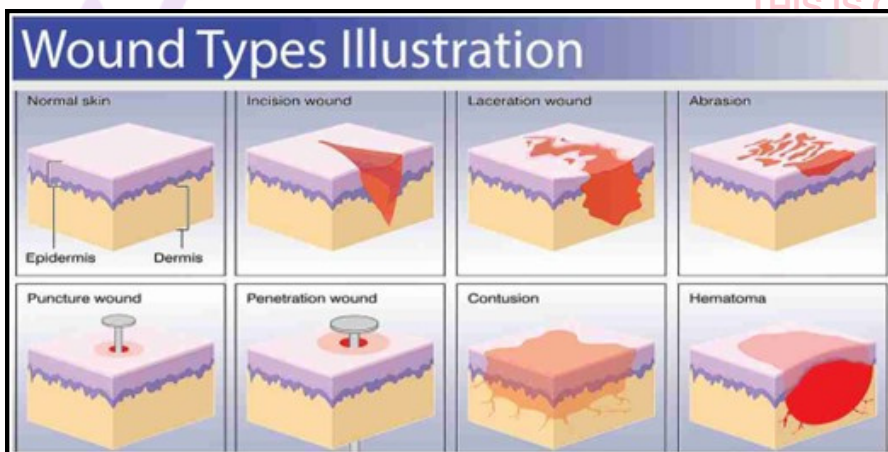
THIS IS COPYRIGHTED CONTENT. Unauthorized use, including screenshots, copying, misuse, reuse, or resale of any content from this app, is strictly prohibited. Our app monitors and records all screenshots and recordings. Violators will face strict legal action.

DISCLAIMER  
THIS IS COPYRIGHTED CONTENT. Unauthorized use, including screenshots, copying, misuse, reuse, or resale of any content from this app, is strictly prohibited. Our app monitors and records all screenshots and recordings. Violators will face strict legal action.

# ORAL SURGERY

## P.O.W.E.R NOTES SBQ 4

- I. Patient has clicking which means the disk is involved. We do soft tissue examination when the disk gets involved. MRI is the best to investigate this.
- II. **"Three Finger test"**: ask the patient to insert three fingers into the mouth. If all three fingers fit between the central incisors, mouth opening is considered functional. If less than three fingers can be inserted, restriction is likely.
- III. Nerve involvement is needed to study in 3RD molar extraction. Therefore, CBCT is the best for the treatment planning.
- IV.
  - Joint problems involve disc and condyle. So, you need to reposition them. You need to create more space between the joint capsule then the symptoms will be relieved. **Morning reposition splint** is used to treat these problems. **Morning reposition splint** is another variant of anterior reposition splint.
  - **Michigan splint** is used in MPDS/ bruxism.
  - **Mandibular advancement split** is used in sleep apnoea.
  - **Mandibular reposition splint** should be avoided as it causes open bite posteriorly.
- V. **Abrasion**- oozing of blood due to capillary bleeding.  
**Bruising** – discoloration of skin but there's no bleeding.  
**Laceration and puncture** - profuse bleeding



THIS IS COPYRIGHTED CONTENT. Unauthorized use, including screenshots, copying, misuse, reuse, or resale of any content from this app, is strictly prohibited. Our app monitors and records all screenshots and recordings. Violators will face strict legal action.

### DISCLAIMER

THIS IS COPYRIGHTED CONTENT. Unauthorized use, including screenshots, copying, misuse, reuse, or resale of any content from this app, is strictly prohibited. Our app monitors and records all screenshots and recordings. Violators will face strict legal action.

THIS IS COPYRIGHTED CONTENT. Unauthorized use, including screenshots, copying, misuse, reuse, or resale of any content from this app, is strictly prohibited. Our app monitors and records all screenshots and recordings. Violators will face strict legal action.



# ORAL SURGERY

## SBQ 5

### ICG NEW CASE

YOU BOUGHT AN OLD PRACTICE FROM A SENIOR DENTIST, YOU HAD TO CHANGE ONE ROOM (THE ROOM WAS REPROCESSING OR STERILISATION RELATED) COMPLETELY. STAFF IS VERY EXPERIENCED BUT YOU NEED TO UPDATE THEM WITH NEW INFECTION CONTROL PROTOCOLS). YOUR NEWLY APPOINTED DA IS TRAINED AND SAYS SHE'S AWARE OF ALL THE INFECTION CONTROL PROTOCOLS

- I. Your DA says, it is easier for her to soak the contaminated instruments in the hand wash basin in your surgery so that she can collect all the instruments. The materials on the instruments will not dry. What is the basic rule of infection control your DA is unaware of here?
  - A. Keep the instruments covered in a wet paper towel so that the debris shouldn't dry..
  - B. You cannot wash your hands and instruments in the same basin
  - C. Chair side wiping of the instruments after the procedure.
  - D. We need to use a container with a lid to transport the instruments to the processing room.
- II. The mouth mirror & college tweezers being Semi critical instruments needed a full cycle of sterilisation?
  - A. Chemical disinfection
  - B. Thermal disinfection
  - C. Chemical and thermal
  - D. Sterilisation but does not require BCI
  - E. Sterilisation but requires BCI
- III. Your DA was suggesting you skip the ultrasonic cleaning step as she was sure the other steralisation procedures were done optimally. What is the one best explanation you can give to your DA which would make a complete sense in the favour of using ultrasonic cleaning?
  - A. Washing instruments by hands can cause injury
  - B. Ultrasonic cleaners remove organic masses which get stuck to instruments which prevents steam penetration.
  - C. Ultrasonic is more efficient than manual cleaning.
  - D. The data can be stored & monitored efficiently by use of ultrasonics.
- IV. After you open the instruments what would you tell your DA to do with the empty pouches with BCI?
  - A. You throw them.
  - B. You note it down in the patients hard copy under the date & throw the pouches.
  - C. Entering in the steri-manual(something similar)

### DISCLAIMER

THIS IS COPYRIGHTED CONTENT. Unauthorized use, including screenshots, copying, misuse, reuse, or resale of any content from this app, is strictly prohibited. Our app monitors and records all screenshots and recordings. Violators will face strict legal action.

DISCLAIMER  
THIS IS COPYRIGHTED CONTENT. Unauthorized use, including screenshots, copying, misuse, reuse, or resale of any content from this app, is strictly prohibited. Our app monitors and records all screenshots and recordings. Violators will face strict legal action.

THIS IS COPYRIGHTED CONTENT. Unauthorized use, including screenshots, copying, misuse, reuse, or resale of any content from this app, is strictly prohibited. Our app monitors and records all screenshots and recordings. Violators will face strict legal action.

DISCLAIMER

# ORAL SURGERY

## SBQ 5

V. He bought a new autoclave & DA has a question, the printers was printing all the parameters. Is it necessary to do any other performance tests, isn't it enough that the data print coming from the data recorder enough?

- A. Leak rate test weekly and helix test daily
- B. Leak rate test daily bowie dick test weekly
- C. Do spore test weekly & put routine chemical indicators.
- D. Spore test daily & some thing related to indicators.

## P.O.W.E.R NOTES SBQ 5

### I. According to ICG:

Ideally there should be several sinks, one separate basin for hand washing that is fitted with elbow operated or sensor operated taps, and at least one sink for rinsing or manually cleaning contaminated instruments, that has hot and cold-water taps. Hand washing must only occur in the dedicated separated basin for hand washing, and not in the sinks used for instrument reprocessing.

### II. Semi critical instruments require sterilisation but don't require BCI.

III. Manual or mechanical cleaning should be done before sterilisation. There are 2 types of mechanical cleaning. They are instrument washer and ultrasonic cleaning. Ultrasonic cleaners are the best as they remove organic masses, with manual cleaning it's not done.

IV. BCI should be noted in the patient's records. Once it's done the packages can be discarded. Clinician is responsible for this.

V. Test with **chemical indicator** is done with each load.

**Helix test**- is optional now and is renamed to **PCD (Process Challenge Device)**

**Steam penetration test- Bowie Dick test**- is done daily

**Air leak test** – daily for machines without automatic air leak detection, weekly for machines with automatic air leak detection

**Spore test**- is done annually

## DISCLAIMER

THIS IS COPYRIGHTED CONTENT. Unauthorized use, including screenshots, copying, misuse, reuse, or resale of any content from this app, is strictly prohibited. Our app monitors and records all screenshots and recordings. Violators will face strict legal action.

DISCLAIMER  
THIS IS COPYRIGHTED CONTENT. Unauthorized use, including screenshots, copying, misuse, reuse, or resale of any content from this app, is strictly prohibited. Our app monitors and records all screenshots and recordings. Violators will face strict legal action.

THIS IS COPYRIGHTED CONTENT. Unauthorized use, including screenshots, copying, misuse, reuse, or resale of any content from this app, is strictly prohibited. Our app monitors and records all screenshots and recordings. Violators will face strict legal action.

DISCLAIMER



# ORAL SURGERY

## SBQ 6

A PATIENT COMES TO YOU AFTER A BASKETBALL ACCIDENT. A PLAYER KNOCKED ON ANOTHER PLAYERS ARM(SOMETHING SIMILAR).THIS PATIENT HAS SUFFERED DENTAL INJURY WHERE IN HIS ANTERIOR TOOTH WAS INVOLVED. HE WENT TO HOSPITAL ER & COMES BACK TO YOU FOR DENTAL VISIT. PICTURE GIVEN WITH UPPER ANTERIORS. WE COULD SEE THE SULCULAR BLEEDING IN RELATION TO THE CENTRAL INCISOR. THE TOOTH WAS SHOWING MORE THAN NORMAL MOBILITY. THE TOOTH WASN'T DISLOCATED.

### I. What type of injury is it?

- A. Subluxation
- B. Alveolar fracture
- C. Concussion
- D. Root Fracture.
- E. Extrusion

### II. You did the sensibility test but after 4 weeks and it is still negative. What would be the explanation for this?

- A. Start RCT if the signs arise
- B. The status of the pulp cannot be determined by pulp sensibility testing alone
- C. Pulp necrosis

### III. How does chlorhexidine work?

- A. It is bacteriocidal & also acts in established plaque
- B. Its adsorbs onto the surfaces and works for longer time.

### IV. How do you create awareness in athletes wearing mouth guards. The patient tells that all the players in the club wear mouthguards only during competition and not during practice matches.

- A. Engage with he coaches & educate them about benefits of using mouth guard.s
- B. Participate in the official club meeting and create awareness about cost versus benefits of mouth guards.
- C. Give discount on mouth guards.
- D. Issue free mouth guards for all the players

### V. When pt comes for review at 4 weeks after subluxation injury of mature lateral incisor, what signs of tooth tells u that it is going to be necrotic?

- A. Pulp sensibility negative still at 4 weeks
- B. On xray it shows canal obliteration
- C. Tooth discoloration improves
- D. NO periapical sign
- E. Still mobile

#### DISCLAIMER

THIS IS COPYRIGHTED CONTENT. Unauthorized use, including screenshots, copying, misuse, reuse, or resale of any content from this app, is strictly prohibited. Our app monitors and records all screenshots and recordings. Violators will face strict legal action.

DISCLAIMER  
THIS IS COPYRIGHTED CONTENT. Unauthorized use, including screenshots, copying, misuse, reuse, or resale of any content from this app, is strictly prohibited. Our app monitors and records all screenshots and recordings. Violators will face strict legal action.

THIS IS COPYRIGHTED CONTENT. Unauthorized use, including screenshots, copying, misuse, reuse, or resale of any content from this app, is strictly prohibited. Our app monitors and records all screenshots and recordings. Violators will face strict legal action.

DISCLAIMER

# ORAL SURGERY

## P.O.W.E.R NOTES SBQ 6

- I. Dental subluxation is a traumatic injury to the periodontal tissue in which the tooth has increased mobility (i.e., is loosened) but has not been displaced.
- II. It's normal to have negative sensibility test after trauma. Sensibility test is not indicating the exact status of pulp after a trauma.
- III. CHX works on the new forming plaque. It can adsorb on to the surfaces and has a substantivity effect.
- IV. Players need to wear mouth guards during practice matches. Dentist's advise has more legit effect.
- V.
  - Pulp test is not a reliable factor at 4 weeks' time.
  - On x-ray canal obliteration is a good sign of healing because dentin gets deposited.
  - Improvement in the tooth discoloration is a good sign.
  - No periapical sign is a good sign.
  - Mobility and non-healing PDL are a bad sign. It can be a sign of external inflammatory resorption.

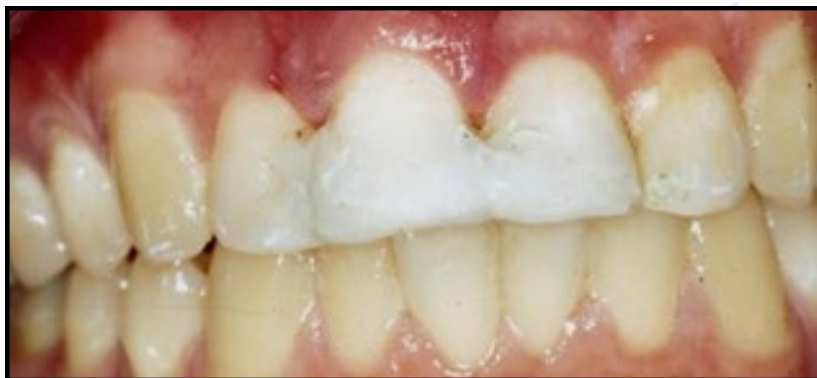# ORAL SURGERY

## SBQ 7

A 12YRS OLD BOY HAD AN ACCIDENT OF 21. HE WAS TREATED IN THE ORAL AND EMERGENCY DEPARTMENT. THEY HAVE DONE THE REIMPLANTATION & STABILISED IT WITH A RIGID SPLINT ON 11,21. MOTHER BROUGHT HIM FOR A DENTAL VISIT AFTER COMING FROM ER.

(IT WAS AFTER 24 HOURS)

MOTHER NOTICED THAT THE 21 WAS PLACED A LITTLE BIT LONGER THAT 11. (PA IS GIVEN WITH 21 STILL A LITTLE BIT EXTRUDED) MOTHER WASHED IT WITH WATER FOR 15 MINUTES AND THEN PLACED IT IN MILK.



### I. What would you do?

- A. Immediate surgical repositioning of the 21 and change the splint to flexible
- B. Digitally apply pressure to repositioned the 21 and replace it with the flexible splint
- C. Wait until it repositions by itself & observe
- D. Reposition 21 and maintain the rigid splint

### II. What will you tell the mother regarding the home care of this child?

- A. Chlorhexidine 0.2% mouthwash for 2weeks
- B. Hypochloride mouthwash
- C. Sodium bicarbonate mouthwash
- D. Hydrogen peroxide mouthwash.

### III. What would be the management of this case?

- A. Commence RCT within 10days. (In one centre within 2weeks)
- B. Wait until there is a signs of discolouration.
- C. Observe until the child complains of any symptoms
- D. Change to flexible and commence RCT within 2 weeks.

### IV. What would be the factor which would interfere with the prognosis of the tooth?

- A. As the tooth was washed in the water for 15 minutes before placing it in milk.
- B. As it was placed in the milk
- C. Type of Injury
- D. Time lapse between the accident and the tooth placement in the socket

#### DISCLAIMER

THIS IS COPYRIGHTED CONTENT. Unauthorized use, including screenshots, copying, misuse, reuse, or resale of any content from this app, is strictly prohibited. Our app monitors and records all screenshots and recordings. Violators will face strict legal action.

**DISCLAIMER**  
THIS IS COPYRIGHTED CONTENT. Unauthorized use, including screenshots, copying, misuse, reuse, or resale of any content from this app, is strictly prohibited. Our app monitors and records all screenshots and recordings. Violators will face strict legal action.

THIS IS COPYRIGHTED CONTENT. Unauthorized use, including screenshots, copying, misuse, reuse, or resale of any content from this app, is strictly prohibited. Our app monitors and records all screenshots and recordings. Violators will face strict legal action.

DISCLAIMER

# ORAL SURGERY

## SBQ 7

**V. The doctor had prescribed him doxycycline. What was the reason for him to choose this antibiotic?**

- A. It can be given to children of all ages and has no side effects.
- B. It has anti inflammatory, antibacterial & antiresorptive properties.
- C. It is usually well tolerated with all the children.
- D. Because of its potent antibacterial properties
- E. Because it is good for prevention of Tetanus.

## P.O.W.E.R NOTES SBQ 7

- I. The tooth was already positioned in the socket, if there's any mal positioning you can correct it by using slight digital pressure. Should not take the tooth out and reposition. Avulsion needs passive flexible splint.
- II. CHX is best for the gingival sulcular healing.
- III. For mature apex RCT is done within 2weeks time in avulsed teeth.  
In immature teeth, RCT is indicated in the presence of change in any signs/symptoms.
- IV. Immediate reimplantation should have been done within 15 mins. PDL could have been viable if it was reimplanted within 15mins. Mother did 2 mistakes in this case. She used water to wash the tooth and extra oral time was more than 15mins. Even though she placed the tooth in milk afterwards, the viability of the tooth was compromised due to osmolality.
- V. Doxycycline has anti-inflammatory, anti-bacterial, anti-resorptive activity. It's not given for children younger than 8yrs old.

THIS IS COPYRIGHTED CONTENT. Unauthorized use, including screenshots, copying, misuse, reuse, or resale of any content from this app, is strictly prohibited. Our app monitors and records all screenshots and recordings. Violators will face strict legal action.

### DISCLAIMER

THIS IS COPYRIGHTED CONTENT. Unauthorized use, including screenshots, copying, misuse, reuse, or resale of any content from this app, is strictly prohibited. Our app monitors and records all screenshots and recordings. Violators will face strict legal action.

DISCLAIMER  
THIS IS COPYRIGHTED CONTENT. Unauthorized use, including screenshots, copying, misuse, reuse, or resale of any content from this app, is strictly prohibited. Our app monitors and records all screenshots and recordings. Violators will face strict legal action.

DISCLAIMER

THIS IS COPYRIGHTED CONTENT. Unauthorized use, including screenshots, copying, misuse, reuse, or resale of any content from this app, is strictly prohibited. Our app monitors and records all screenshots and recordings. Violators will face strict legal action.



# ORAL SURGERY

## SBQ 8

**TMJ RHEUMATOID ARTHRITIS CASE: PATIENT IS 33 YEARS OLD. HAD SUFFERED A BLOW TO LEFT JAW DURING HER CHILDHOOD WHILE PLAYING SPORTS. WHEN OPENING HER MOUTH SHE HAD PAIN & DEVIATION ON THE LEFT SIDE OF HER TMJ. PAIN WAS RADIATING TO EAR. SHE WAS HAVING DIFFICULTY CHEWING ON LEFT SIDE & HENCE GOT ACCUSTOMED TO EATING ON THE RIGHT SIDE. RECENTLY SHE HAS NOTED THAT HER JAW GETS MOMENTARILY LOCKED FOR WHILE YAWNING FOR 30 SECOND. (TMJ CLOSED MOMENTARILY) ..SIGNS OF BRUXISM & ATTRITION IN THE LOWER.**

### I. What question from her history is most relevant to lead you to potential diagnosis?

- A. History of Autoimmune/degenerative disorders in the family.
- B. Anxiety/depression
- C. Post traumatic Stress disorder(PTSD)
- D. Osteoporosis
- E. Stress

### II. They gave 4 Radiographic views of the TMJ

- A. One was normal tmj view
- B. One with rheumatoid arthritis wear condyle
- C. One with disc
- D. One looks normal as well.

### III. Which splint to give?

- A. Michigan splint
- B. Mand advancement splint
- D. No splint
- F. Morning repositioning splint

### IV. What is the condition the patient is suffering?

- A. Disc derangement with delayed reduction
- B. Disc derangement without reduction
- C. Disc derangement with immediate reduction
- D. Disc derangement with open/close reduction

### V. Best investigation for TMJ?

- A. MRI
- B. CBCT
- C. OPG
- D. CT Scan

#### DISCLAIMER

THIS IS COPYRIGHTED CONTENT. Unauthorized use, including screenshots, copying, misuse, reuse, or resale of any content from this app, is strictly prohibited. Our app monitors and records all screenshots and recordings. Violators will face strict legal action.

#### DISCLAIMER

THIS IS COPYRIGHTED CONTENT. Unauthorized use, including screenshots, copying, misuse, reuse, or resale of any content from this app, is strictly prohibited. Our app monitors and records all screenshots and recordings. Violators will face strict legal action.

THIS IS COPYRIGHTED CONTENT. Unauthorized use, including screenshots, copying, misuse, reuse, or resale of any content from this app, is strictly prohibited. Our app monitors and records all screenshots and recordings. Violators will face strict legal action.

#### DISCLAIMER



# ORAL SURGERY

## P.O.W.E.R NOTES SBQ 8

- I. Patient has a hx of trauma in the childhood and at the present she suffers from TMD. Childhood injury is linked with the TMD.

**Association between the PTSD and TMD.**

Stress is believed to be coming from various kinds of triggers. Childhood sports injury can be a serious type of injury that can have an impact even in growing years and can develop PTSD. It can develop though out the life and can develop TMD. Stress leads to parafunction habits and bruxism.

- II. Patient is suffering from a disc disorder. There's internal disc displacement with delayed reduction.

So, the radiograph will give the image of the disc which is ahead of condyle.

- III. **Anterior reposition splint** is used to treat disc problems.

**Michigan splint** is used in MPDS/ bruxism.

**Mandibular advancement** split is used in sleep apnoea.

- IV. **Wilkes Classification of Internal Derangement**

<b>Stage I</b>	Early reducing disk displacement No pain or limitation, early opening click
<b>Stage II</b>	Late reducing disk displacement One or more episodes of pain, mid to late opening click, transient catch & lock
<b>Stage III</b>	Nonreducing disk displacement: acute/subacute Multiple painful episodes, locking, restricted mobility
<b>Stage IV</b>	Nonreducing disk displacement: chronic Increasing functional disturbance
<b>Stage V</b>	Nonreducing disk displacement: chronic with osteoarthritis, crepitus, scraping, grating, grinding symptoms; pain, restricted motion, difficult function

### DISCLAIMER

THIS IS COPYRIGHTED CONTENT. Unauthorized use, including screenshots, copying, misuse, reuse, or resale of any content from this app, is strictly prohibited. Our app monitors and records all screenshots and recordings. Violators will face strict legal action.

DISCLAIMER  
THIS IS COPYRIGHTED CONTENT. Unauthorized use, including screenshots, copying, misuse, reuse, or resale of any content from this app, is strictly prohibited. Our app monitors and records all screenshots and recordings. Violators will face strict legal action.

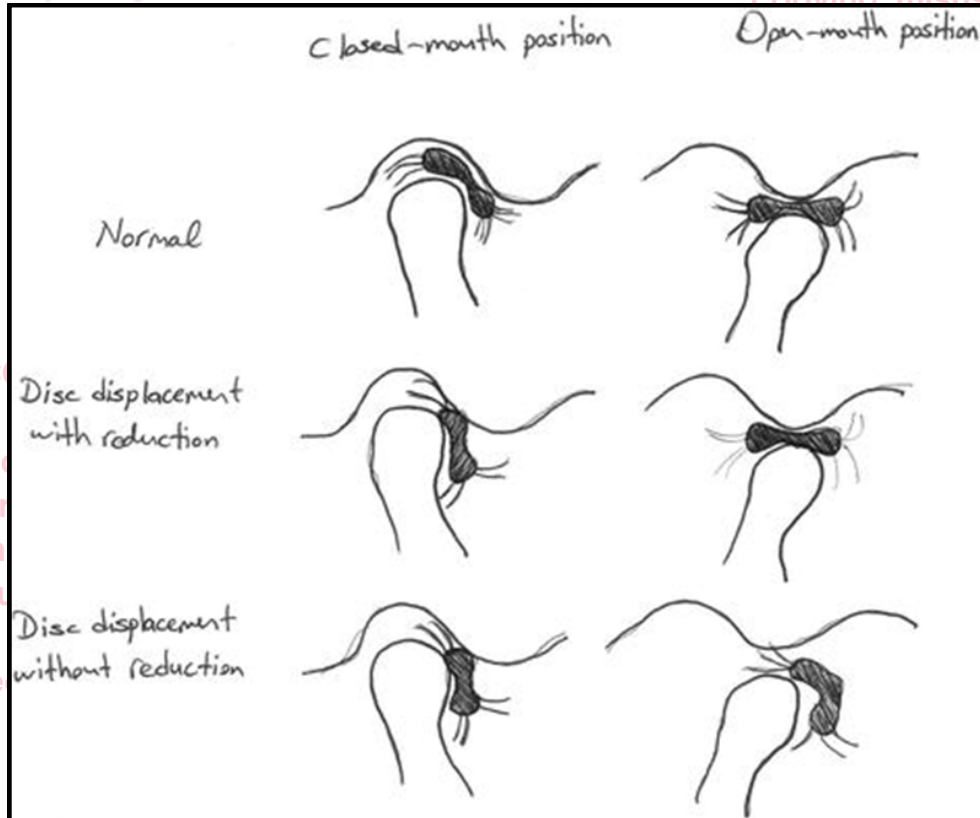
DISCLAIMER

THIS IS COPYRIGHTED CONTENT. Unauthorized use, including screenshots, copying, misuse, reuse, or resale of any content from this app, is strictly prohibited. Our app monitors and records all screenshots and recordings. Violators will face strict legal action.

# ORAL SURGERY

## P.O.W.E.R NOTES SBQ 8

IV.



V. When we want to see the disc derangement, the soft tissue analysis MRI is the best as it shows the articular eminence, disc and the condyle.

THIS IS COPYRIGHTED CONTENT. Unauthorized use, including screenshots, copying, misuse, reuse, or resale of any content from this app, is strictly prohibited. Our app monitors and records all screenshots and recordings. Violators will face strict legal action.

**DISCLAIMER**

THIS IS COPYRIGHTED CONTENT. Unauthorized use, including screenshots, copying, misuse, reuse, or resale of any content from this app, is strictly prohibited. Our app monitors and records all screenshots and recordings. Violators will face strict legal action.

**DISCLAIMER**  
THIS IS COPYRIGHTED CONTENT. Unauthorized use, including screenshots, copying, misuse, reuse, or resale of any content from this app, is strictly prohibited. Our app monitors and records all screenshots and recordings. Violators will face strict legal action.

THIS IS COPYRIGHTED CONTENT. Unauthorized use, including screenshots, copying, misuse, reuse, or resale of any content from this app, is strictly prohibited. Our app monitors and records all screenshots and recordings. Violators will face strict legal action.

WINSPERT  
P.O.W.E.R  
NOTES

# ORAL SURGERY

## SBQ 9

64 YEAR OLD PATIENT CAME WITH PAIN ON BITING AND HAS A PERIAPICAL ABSCESS. SHE COMES TO YOUR CLINIC FOR AN EXTRACTION. PATIENT IS IN PAIN. YOU PLANNED A RCT TREATMENT, SHE HAD POSTPONED HER APPOINTMENT. NOW SHE GIVES YOU A CALL SAYING SHE IS HAVING SEVERE PAIN, BUT YOUR AREA IS IN LEVEL 3 RESTRICTIONS.

- I. You extract her tooth but she is able to pay only 50 percent right now and couldn't pay the full amount. She calls you from home saying she is in pain after 24 hours. What will you do?
  - A. Don't treat till she pays the full amount
  - B. Give her an appointment to come and see you in the clinic on emergency basis
  - C. Ask her to pay the full amount first before doing any treatment
  - D. Refer her to community clinic
- II. After a few months she comes to you wanting an extraction for another tooth, complains of some pain. She has paid full amount by now. But your area is now under ADA level-3 restrictions. And it is in the hot spot zone. How will you proceed?
  - A. Use N95 mask and extract instead of surgical mask
  - B. Do emergency access opening and expatriate the pulp to relieve pain use rubber dam and give temp restoration
  - C. Refer to the hospital emergency dept.
  - D. Refer to oral surgeon
  - E. Prescribe Painkillers and antibiotics
- III. What will be the complication of extraction?
  - A. Infection
  - B. Root fracture
- IV. The patient did not want a rubber dam .What will we advise her?
  - A. Respect her feelings and do not apply Rubber Dam
  - B. Tell her we can't continue treatment without Rubber Dam and offer alternative such as extraction
  - C. Refer to endodontist
  - D. Refuse treatment
- V. What would you do to her. She says she wants extraction.
  - A. Refer to hospital
  - B. Extirpate the pulp under dental dam to relieve her pain
  - C. Do extraction

## DISCLAIMER

THIS IS COPYRIGHTED CONTENT. Unauthorized use, including screenshots, copying, misuse, reuse, or resale of any content from this app, is strictly prohibited. Our app monitors and records all screenshots and recordings. Violators will face strict legal action.

DISCLAIMER  
THIS IS COPYRIGHTED CONTENT. Unauthorized use, including screenshots, copying, misuse, reuse, or resale of any content from this app, is strictly prohibited. Our app monitors and records all screenshots and recordings. Violators will face strict legal action.

# ORAL SURGERY

## P.O.W.E.R NOTES SBQ 9

Let's treat this patient as a normal patient and not as a covid positive patient.

- I. According to TG, after an extraction any complication should be treated by the treating dental surgeon. Cost is not coming as a 1st factor in the emergency management.
- II. Infection is not a common complication if you are following the aseptic techniques. Root fracture is a common complication in a grossly destructed tooth.
- III. Should explain the patient that treatment can't be done without the rubber dam and the only option which is left is extraction without using the rubber dam. After saying this if the patient disagrees to extract the tooth, patient should be referred to the specialist.
- IV. Patient agreed to the alternative treatment plan we mentioned. So, you can proceed with extraction.

THIS IS COPYRIGHTED CONTENT. Unauthorized use, including screenshots, copying, misuse, reuse, or resale of any content from this app, is strictly prohibited. Our app monitors and records all screenshots and recordings. Violators will face strict legal action.

### DISCLAIMER

THIS IS COPYRIGHTED CONTENT. Unauthorized use, including screenshots, copying, misuse, reuse, or resale of any content from this app, is strictly prohibited. Our app monitors and records all screenshots and recordings. Violators will face strict legal action.

THIS IS COPYRIGHTED CONTENT. Unauthorized use, including screenshots, copying, misuse, reuse, or resale of any content from this app, is strictly prohibited. Our app monitors and records all screenshots and recordings. Violators will face strict legal action.

THIS IS COPYRIGHTED CONTENT. Unauthorized use, including screenshots, copying, misuse, reuse, or resale of any content from this app, is strictly prohibited. Our app monitors and records all screenshots and recordings. Violators will face strict legal action.

THIS IS COPYRIGHTED CONTENT. Unauthorized use, including screenshots, copying, misuse, reuse, or resale of any content from this app, is strictly prohibited. Our app monitors and records all screenshots and recordings. Violators will face strict legal action.

DISCLAIMER

THIS IS COPYRIGHTED CONTENT. Unauthorized use, including screenshots, copying, misuse, reuse, or resale of any content from this app, is strictly prohibited. Our app monitors and records all screenshots and recordings. Violators will face strict legal action.

DISCLAIMER

THIS IS COPYRIGHTED CONTENT. Unauthorized use, including screenshots, copying, misuse, reuse, or resale of any content from this app, is strictly prohibited. Our app monitors and records all screenshots and recordings. Violators will face strict legal action.



# ORAL SURGERY

## SBQ 10

62 YEARS OLD LADY. SHE HAS A COMPLEX MEDICAL HISTORY & TAKING LOTS OF MEDICATIONS HAS A HIP JOINT REPLACEMENT. COMES TO YOUR PRACTICE FOR EXTRACTION. SHE SAYS SHE HAS ALWAYS BEEN GIVEN ANTIBIOTIC COVERAGE & HENCE MARKED THE NEED FOR ANTIBIOTIC COVERAGE.

### I. In which case antibiotic prophylaxis is required?

- A. Ventricular septal defect
- B. Mitral valve prolapse
- C. Hip replacement
- D. Patent ductus arteriosus
- E. Mitral valve prolapse

### II. For which procedures do you need antibiotic prophylaxis?

- A. Procedures that might cause infection
- B. Deep invasive procedures
- C. Severe infected (didn't have this option)
- D. All dental procedures.
- E. Procedures causing inflammation

### III. Patient complains of pain on biting, which investigation would be most helpful?

- A. Percussion test
- B. Probing test
- C. Radiographs
- D. Vitality test
- E. Selective cuspal loading

### IV. Antibiotic regime for Infective endocarditis.

- A. Clindamycin 600mg Oral one hour before the procedure
- B. Amoxicillin for 5days
- C. Tetracycline for 5days
- D. Amoxicillin but regime wasn't correct.

#### DISCLAIMER

THIS IS COPYRIGHTED CONTENT. Unauthorized use, including screenshots, copying, misuse, reuse, or resale of any content from this app, is strictly prohibited. Our app monitors and records all screenshots and recordings. Violators will face strict legal action.

#### DISCLAIMER

THIS IS COPYRIGHTED CONTENT. Unauthorized use, including screenshots, copying, misuse, reuse, or resale of any content from this app, is strictly prohibited. Our app monitors and records all screenshots and recordings. Violators will face strict legal action.

THIS IS COPYRIGHTED CONTENT. Unauthorized use, including screenshots, copying, misuse, reuse, or resale of any content from this app, is strictly prohibited. Our app monitors and records all screenshots and recordings. Violators will face strict legal action.

#### DISCLAIMER



# ORAL SURGERY

## P.O.W.E.R NOTES SBQ 10

- I. According to TG, AB prophylaxis is not indicated in the hx of hip replacement. None of the given options require AB prophylaxis.
- II. Deep invasive procedures, where there's a chance of contamination involving the deeper circulation require ABP.
- III. No pain on hot and cold, no spontaneous pain indicated that there's no pulpal involvement. When only pain on biting present, percussion test is helpful to localise the pain and identify the tooth.
- IV. Options (B) and (C) are therapeutic doses. Clindamycin 600mg or amoxicillin 2g given 1hr before as ABP.

THIS IS COPYRIGHTED CONTENT. Unauthorized use, including screenshots, copying, misuse, reuse, or resale of any content from this app, is strictly prohibited. Our app monitors and records all screenshots and recordings. Violators will face strict legal action.

### DISCLAIMER

THIS IS COPYRIGHTED CONTENT. Unauthorized use, including screenshots, copying, misuse, reuse, or resale of any content from this app, is strictly prohibited. Our app monitors and records all screenshots and recordings. Violators will face strict legal action.

DISCLAIMER  
THIS IS COPYRIGHTED CONTENT. Unauthorized use, including screenshots, copying, misuse, reuse, or resale of any content from this app, is strictly prohibited. Our app monitors and records all screenshots and recordings. Violators will face strict legal action.

DISCLAIMER

THIS IS COPYRIGHTED CONTENT. Unauthorized use, including screenshots, copying, misuse, reuse, or resale of any content from this app, is strictly prohibited. Our app monitors and records all screenshots and recordings. Violators will face strict legal action.

# ORAL SURGERY

## SBQ 11

YOU ARE SEEING A PATIENT WITH SCHIZOPHRENIA, EPILEPSY AND NEEDLE PHOBIA. PATIENT SEEMS AGITATED. HE HAS MENTAL INCAPABILITY (INTELLECTUAL INSTABILITY). IT IS DIFFICULT TO OBTAIN ANY INFORMATION FROM THE PATIENT REGARDING THEIR HISTORY AND MEDICATION. SO YOU ASK HELP FOR HIS CARER DURING THE APPOINTMENT TO GET THE PATIENT'S MEDICATION LIST IN THE NEXT APPOINTMENT. PATIENT IS TAKING ANTIDEPRESSANTS, ANTIPSYCHOTICS.

**I. You judge the patient is not capable of giving consent for the treatment . Who should provide consent?**

- A. Carer
- B. Legal guardian
- C. Family member
- D. Next to kin

**II. Patient is needle phobic and asks for nitrous oxide minimal sedation. What would you say?**

- A. N2O is best indicated under these circumstances
- B. You can use n2o but inform the patient that you still need the needle for the LA
- C. Prefer to perform the treatment under GA

**III. You have to extract 11 and 27 (or 26) the patient presents all the rest of his dentition. What would be the best treatment to manage the edentulous space?**

- A. Implant
- B. Acrylic rpd
- C. Croco rpd
- D. No replacement.

**IV. The daughter called afterwards and advised that due to financial issues. What will you do?**

- A. Explain Daughter the health impact of not continuing with Planned Rx Plan
- B. Report Abuse
- C. Suggest Payment plan
- D. Refer the patient to the community dental clinic.

## DISCLAIMER

THIS IS COPYRIGHTED CONTENT. Unauthorized use, including screenshots, copying, misuse, reuse, or resale of any content from this app, is strictly prohibited. Our app monitors and records all screenshots and recordings. Violators will face strict legal action.

DISCLAIMER  
THIS IS COPYRIGHTED CONTENT. Unauthorized use, including screenshots, copying, misuse, reuse, or resale of any content from this app, is strictly prohibited. Our app monitors and records all screenshots and recordings. Violators will face strict legal action.

THIS IS COPYRIGHTED CONTENT. Unauthorized use, including screenshots, copying, misuse, reuse, or resale of any content from this app, is strictly prohibited. Our app monitors and records all screenshots and recordings. Violators will face strict legal action.

DISCLAIMER

# ORAL SURGERY

## P.O.W.E.R NOTES SBQ 11

- I. Schizophrenia patient has incapacity to give medical consent. Legal guardian comes first in giving consent.

### SUBSTITUTION DECISION MAKERS:

- Spouse
- Son or daughter
- Father or mother
- Brother or sister
- Grandfather or grandmother
- Grandson or granddaughter
- Uncle or aunt
- Nephew or niece

- II. N20 can't eliminate the need of local anaesthesia. Patients with mental incapacities and psychotic disorders best to get the treatment done by a specialist.
- III. This question is also the part of ADC release sample questions and the answer given is cobalt-chrome denture. It can be also explained by the fact that the tooth loss is bilateral and that's why the metal based RPD will be the best option for this patient.
- IV. You can make the treatment plan easy by introducing them a payment plan.

THIS IS COPYRIGHTED CONTENT. Unauthorized use, including screenshots, copying, misuse, reuse, or resale of any content from this app, is strictly prohibited. Our app monitors and records all screenshots and recordings. Violators will face strict legal action.

**DISCLAIMER**  
THIS IS COPYRIGHTED CONTENT. Unauthorized use, including screenshots, copying, misuse, reuse, or resale of any content from this app, is strictly prohibited. Our app monitors and records all screenshots and recordings. Violators will face strict legal action.

THIS IS COPYRIGHTED CONTENT. Unauthorized use, including screenshots, copying, misuse, reuse, or resale of any content from this app, is strictly prohibited. Our app monitors and records all screenshots and recordings. Violators will face strict legal action.

### DISCLAIMER

THIS IS COPYRIGHTED CONTENT. Unauthorized use, including screenshots, copying, misuse, reuse, or resale of any content from this app, is strictly prohibited. Our app monitors and records all screenshots and recordings. Violators will face strict legal action.

# ORAL SURGERY

## SBQ 12

IT WAS A WHOLE CASE ABOUT ICG. THE MANAGER WANTS TO UNDERTAKE A VERIFICATION OF THE INFECTION CONTROL OF THE CLINIC AND VALIDATION PROCESSES.

I. What is the ideal temperature and time to validation of cycle B of the autoclave?

- A. 121C for 3 minutes
- B. 121C for 5 minutes
- C. 121C for 2 minutes
- D. 134C for 3 minutes
- E. 6134C for 5 minutes

II. One staff member got the full vaccines and immunisation for HBV. What will prove that she is immune? (There were crazy values.)

- A. 0.1 - 0.5
- B. 50-150
- C. 5-15
- D. 500 - 1500
- E. 1500 to 5000
- F. 5000-15000

III. What process do you need to do to check if there is steam penetration through a big porous load?

- A. Vacuum test
- B. Helix test
- C. Bowie Dick test
- D. Leakage test
- E. Cycle B

IV. How do you validate ultrasonic cleaners?

- A. Pencil test
- B. Leak rate test
- C. Degassing test
- D. Foil test
- E. Strip test

V. Dentist has slight irritation from hand washing.

How will you help your DA take out the instrument?

- A. Remove gloves, do abhr, take instrument, do abhr, done new gloves (all other options were clearly wrong)

## DISCLAIMER

THIS IS COPYRIGHTED CONTENT. Unauthorized use, including screenshots, copying, misuse, reuse, or resale of any content from this app, is strictly prohibited. Our app monitors and records all screenshots and recordings. Violators will face strict legal action.

DISCLAIMER  
THIS IS COPYRIGHTED CONTENT. Unauthorized use, including screenshots, copying, misuse, reuse, or resale of any content from this app, is strictly prohibited. Our app monitors and records all screenshots and recordings. Violators will face strict legal action.

THIS IS COPYRIGHTED CONTENT. Unauthorized use, including screenshots, copying, misuse, reuse, or resale of any content from this app, is strictly prohibited. Our app monitors and records all screenshots and recordings. Violators will face strict legal action.

DISCLAIMER

# ORAL SURGERY

## P.O.W.E.R NOTES SBQ 12

- I. According to ICG it's, **134-137 C for 3min.**
- II. Anything less than 10 is not immune. Anything above 10 is immune. Best answer is Option (B).
- III. **HELIX test**- for hollow load  
**BOWIE DICK** – for porous load.
- IV. Foil test and pencil test are indicated for ultrasonic cleaners. Foil test is the universal test.

V. **REMOVE GLOVES**



**ABHR**



**TAKE INSTRUMENT**



**ABHR**



**WEAR NEW GLOVES**

**DISCLAIMER**  
THIS IS COPYRIGHTED CONTENT. Unauthorized use, including screenshots, copying, misuse, reuse, or resale of any content from this app, is strictly prohibited. Our app monitors and records all screenshots and recordings. Violators will face strict legal action.

THIS IS COPYRIGHTED CONTENT. Unauthorized use, including screenshots, copying, misuse, reuse, or resale of any content from this app, is strictly prohibited. Our app monitors and records all screenshots and recordings. Violators will face strict legal action.

### DISCLAIMER

THIS IS COPYRIGHTED CONTENT. Unauthorized use, including screenshots, copying, misuse, reuse, or resale of any content from this app, is strictly prohibited. Our app monitors and records all screenshots and recordings. Violators will face strict legal action.



# ORAL SURGERY

## SBQ 13

**INCIDENCE OF SHARP INJURY. WHAT WOULD BE OF LEAST CONCERN WHEN WRITING THE INJURY REPORT IN RECORDS?**

- A. Another person was there as a witness
- B. Sharps injury was through clothing or glove
- C. Depth of penetrating injury
- D. Whether the instrument was solid or hollow object
- E. If the object had blood or saliva on it

## P.O.W.E.R NOTES SBQ 13

- I. All the given options are relevant except for the witness.  
*Ref: blood and body fluid exposure protocol*

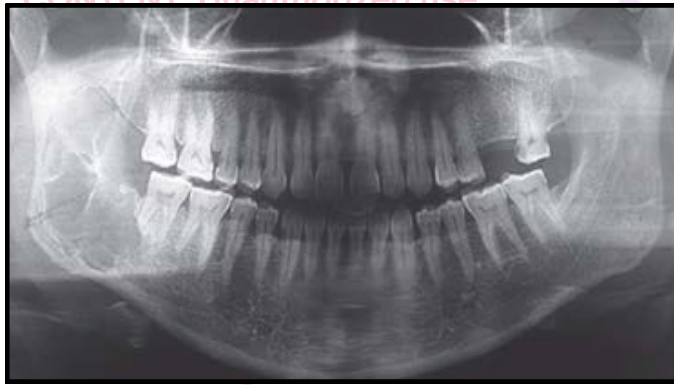## DISCLAIMER

THIS IS COPYRIGHTED CONTENT. Unauthorized use, including screenshots, copying, misuse, reuse, or resale of any content from this app, is strictly prohibited. Our app monitors and records all screenshots and recordings. Violators will face strict legal action.

# ORAL SURGERY

## SBQ 14

BRIAN 30YR OLD MAN, HAS HAD DISCOMFORT IN HIS LOWER RIGHT BACK REGION FOR 3 MONTHS. THE DISCOMFORT INCREASED IN THE PAST 1 WEEK. OPG GIVEN WITH RADIO LUCENCY IN MANDIBULAR ANGLE ALL THE WAY UP TO CORONOID PROCESS. IT IS A MULTILOCULAR RADIO LUCENCY (48 IS DISPLACED THE RADIO LUCENCY STARTS WHERE THE TOOTH IS. (CAN ONLY SEE THE CROWN OF 48, 47 ROOT RESORPTION ON DISTAL ROOT, 48 IS PUSHED DOWN TO MANDIBLE EDGE). THERE WAS ANOTHER SMALL RADIO LUCENCY ATTACHED TO THE ROOT OF FULLY ERUPTED 38 IN THE SAME OPG. CORTICAL EXPANSION WAS SEEN AT THE LOWER CORTEX OF THE MANDIBLE.



### I. What is this lesion most likely?

- A. OKC
- B. Ameloblastoma
- C. Dentigerous cyst

### II. Which further investigation will you require to help diagnosing this lesion?

- A. Lateral oblique
- B. CBCT
- C. CT SCAN
- D. MRI

### III. What could be the further complication if the lesion persists in relation to 47?

- A. Displacement of 47
- B. External resorption of 47 roots (was visible on the opg)
- C. Pocket formation with 47,
- D. Occlusal plane displacement

### IV. What is the most conservative treatment for this lesion?

- A. Enucleation and resection
- B. Enucleation with extraction
- C. Cryosurgery
- D. Resection
- E. Enucleation and curettage

#### DISCLAIMER

THIS IS COPYRIGHTED CONTENT. Unauthorized use, including screenshots, copying, misuse, reuse, or resale of any content from this app, is strictly prohibited. Our app monitors and records all screenshots and recordings. Violators will face strict legal action.

**DISCLAIMER**  
THIS IS COPYRIGHTED CONTENT. Unauthorized use, including screenshots, copying, misuse, reuse, or resale of any content from this app, is strictly prohibited. Our app monitors and records all screenshots and recordings. Violators will face strict legal action.

THIS IS COPYRIGHTED CONTENT. Unauthorized use, including screenshots, copying, misuse, reuse, or resale of any content from this app, is strictly prohibited. Our app monitors and records all screenshots and recordings. Violators will face strict legal action.

DISCLAIMER

# ORAL SURGERY

## SBQ 14

V. There was another small radiolucency attached to the root of fully erupted 38 in the same case OPG and it was asked, what is the appropriate investigation for that?

- A. Perform pulp sensibility test
- B. Do Rct
- C. Extract
- D. Observe
- E. Biopsy

## P.O.W.E.R NOTES SBQ 14

- I. **Ameloblastoma**- cortical expansion and extending towards ramus.  
**OKC**- extending towards anteriorly and no cortical expansion  
**Dentigerous cyst**- not multilocular. Is associated with a crown of an impacted tooth, not the apex of the tooth.
- II. OPG is already taken. CBCT is the next best investigation in ameloblastoma. Since it's a soft tissue tumour MRI can give overexaggerated extent of the tumour. So, can end up doing more surgical removal than required.
- III. Resorption has already occurred. Displacement of 47 can happen after resorption.
- IV. • In this question it's mentioned "conservative treatment" therefore it's enucleation and curettage. In patients younger than 18yrs, we do conservative treatment.
  - Ideal treatment for ameloblastoma is surgical resection.
  - Enucleation and curettage will show 60% of recurrence.
  - Surgical resection will show 10% of recurrence

This is also an ADC released sample paper question and answer given is Enucleation and extraction, which is the most conservative treatment plan for ameloblastoma and OKC.

- V. • Need to do the pulp sensibility test 1st, whether it's vital or non-vital. If It's non vital, then it would be coming from the infected pulp. If it's vital, then you would have to extract the tooth and send for the biopsy. Because radiolucency in the mandibular posterior region associated with a vital tooth could be a malignancy, a metastatic presentation.
  - If it was a diffuse radiolucency attached with the tooth in the mandible and not attached to the root, you can suspect of a malignancy. Then a biopsy would be required. Here it's a radiolucency which is attached to the root may be due to the non-vital tooth.

## DISCLAIMER

THIS IS COPYRIGHTED CONTENT. Unauthorized use, including screenshots, copying, misuse, reuse, or resale of any content from this app, is strictly prohibited. Our app monitors and records all screenshots and recordings. Violators will face strict legal action.

DISCLAIMER  
THIS IS COPYRIGHTED CONTENT. Unauthorized use, including screenshots, copying, misuse, reuse, or resale of any content from this app, is strictly prohibited. Our app monitors and records all screenshots and recordings. Violators will face strict legal action.

THIS IS COPYRIGHTED CONTENT. Unauthorized use, including screenshots, copying, misuse, reuse, or resale of any content from this app, is strictly prohibited. Our app monitors and records all screenshots and recordings. Violators will face strict legal action.

DISCLAIMER

# ORAL SURGERY

## SBQ 15

A MALE PT 38YR OLD WHO HAS WORKED IN THE MILITARY (OR, STILL WORKING MAYBE) COMES TO YOU FOR CONSULTATION REGARDING HIS 3RD MOLARS. HE IS ASYMPTOMATIC. YOU TOOK AN OPG TO FIND A RADIOLOUCENT AREA EXTENDING FROM 34 TO 36.

**I. What is the most likely diagnosis? (It was a R/L that could have been confused with submandibular fossa if the option was given)**

- A. Traumatic cyst
- B. Dentigerous cyst
- C. Odontogenic keratocyst
- D. 1 more option no stafne no submand fossa given

**II. What is the structure arrows are pointing to? Lamina dure**

- A. External oblique ridge
- B. Internal oblique ridge
- C. Mylohyoid ridge

**III. What is the arrow indicating? Dark rim between enamel and dentine**

- A. Difference in the thickness of substances
- B. Artifact
- C. Error
- D. Contrast

**IV. What is the lucency under the cej indicating?**

- A. Cervical burnout
- B. Root caries
- C. Resorptiom

**V. What is the error in bitewing?**

- A. Conecut
- B. Incorrect placement
- C. Incorrect angulation
- D. Patient not biting properly

**VI. Bitewing given. Multiple caries present. In the main sbq history mentioned that 36 has caries. Apart from caries in 37, which other tooth is carious?**

- A. Mesial of 14
- B. Distal of 15

## DISCLAIMER

THIS IS COPYRIGHTED CONTENT. Unauthorized use, including screenshots, copying, misuse, reuse, or resale of any content from this app, is strictly prohibited. Our app monitors and records all screenshots and recordings. Violators will face strict legal action.

DISCLAIMER  
THIS IS COPYRIGHTED CONTENT. Unauthorized use, including screenshots, copying, misuse, reuse, or resale of any content from this app, is strictly prohibited. Our app monitors and records all screenshots and recordings. Violators will face strict legal action.

THIS IS COPYRIGHTED CONTENT. Unauthorized use, including screenshots, copying, misuse, reuse, or resale of any content from this app, is strictly prohibited. Our app monitors and records all screenshots and recordings. Violators will face strict legal action.

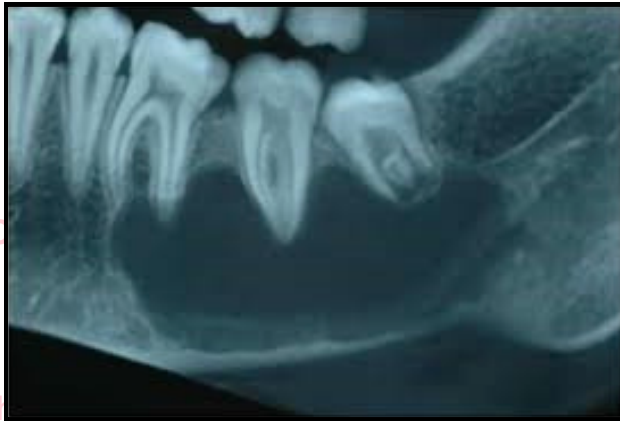
DISCLAIMER



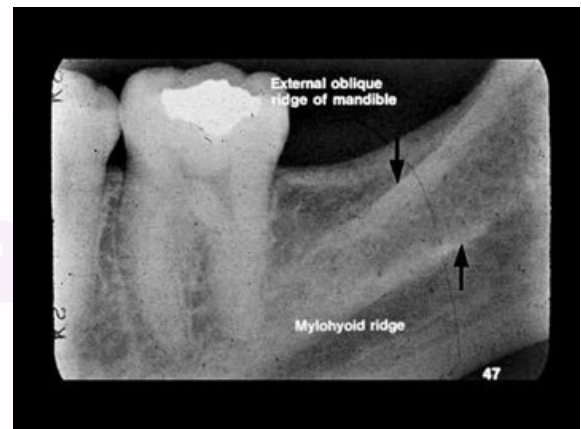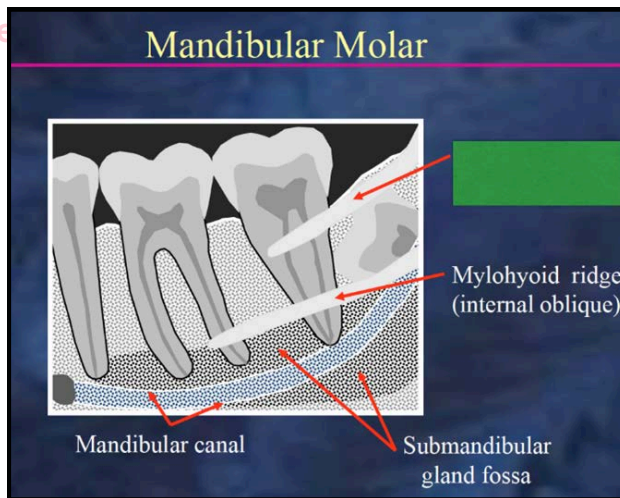
# ORAL SURGERY

## P.O.W.E.R NOTES SBQ 15

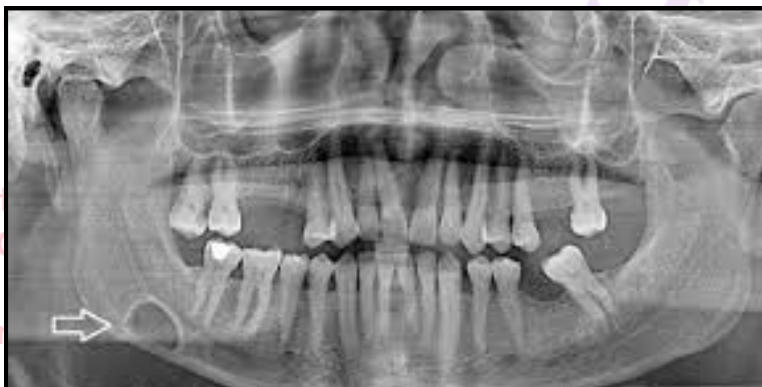- I. Radiolucency is seen in a scalloping fashion among the roots. Patient has worked in the army. So probably traumatic injury might have happened. So the diagnosis is traumatic cyst.



- II. Internal ridge is also known as mylohyoid ridge.



## STAFINE BONE CAVITY



### DISCLAIMER

THIS IS COPYRIGHTED CONTENT. Unauthorized use, including screenshots, copying, misuse, reuse, or resale of any content from this app, is strictly prohibited. Our app monitors and records all screenshots and recordings. Violators will face strict legal action.

THIS IS COPYRIGHTED CONTENT. Unauthorized use, including screenshots, copying, misuse, reuse, or resale of any content from this app, is strictly prohibited. Our app monitors and records all screenshots and recordings. Violators will face strict legal action.

**DISCLAIMER**  
THIS IS COPYRIGHTED CONTENT. Unauthorized use, including screenshots, copying, misuse, reuse, or resale of any content from this app, is strictly prohibited. Our app monitors and records all screenshots and recordings. Violators will face strict legal action.

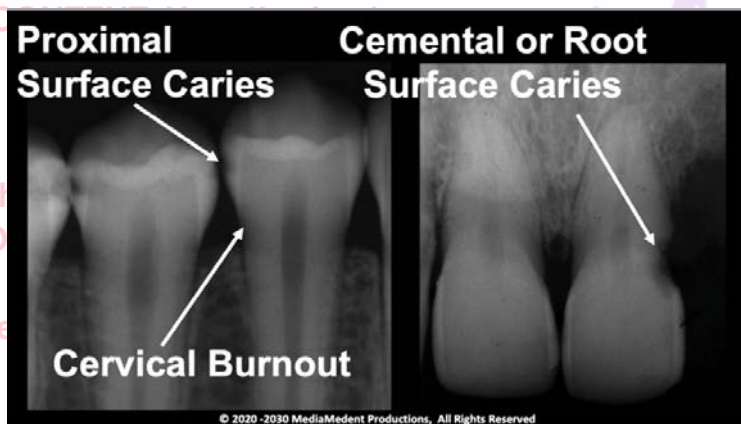
recordings. Violators will face strict legal action.

# ORAL SURGERY

## P.O.W.E.R NOTES SBQ 15

III. In a radiograph, the dark rim between the enamel and dentin is typically the result of the differing radiopacity of these two tissues. Enamel is more radiopaque (appears lighter) than dentin because it is denser and contains more mineral content.

IV. If the radiolucency is under the crest or parallel to the crest of the bone is a "cervical burn out". Can be seen on all the teeth. It appears as a black shadow. If the radiolucency is above the crest of the bone indicate attachment loss and exposed bone. It appears circular in shape. Proximal caries is triangular in shape.



V. Answering this question requires a bitewing radiograph.

THIS IS COPYRIGHTED CONTENT. Unauthorized use, including screenshots, copying, misuse, reuse, or resale of any content from this app, is strictly prohibited. Our app monitors and records all screenshots and recordings. Violators will face strict legal action.

### DISCLAIMER

THIS IS COPYRIGHTED CONTENT. Unauthorized use, including screenshots, copying, misuse, reuse, or resale of any content from this app, is strictly prohibited. Our app monitors and records all screenshots and recordings. Violators will face strict legal action.

DISCLAIMER  
THIS IS COPYRIGHTED CONTENT. Unauthorized use, including screenshots, copying, misuse, reuse, or resale of any content from this app, is strictly prohibited. Our app monitors and records all screenshots and recordings. Violators will face strict legal action.

DISCLAIMER

THIS IS COPYRIGHTED CONTENT. Unauthorized use, including screenshots, copying, misuse, reuse, or resale of any content from this app, is strictly prohibited. Our app monitors and records all screenshots and recordings. Violators will face strict legal action.

THIS IS COPYRIGHTED CONTENT. Unauthorized use, including screenshots, copying, misuse, reuse, or resale of any content from this app, is strictly prohibited. Our app monitors and records all screenshots and recordings. Violators will face strict legal action.

THIS IS COPYRIGHTED CONTENT. Unauthorized use, including screenshots, copying, misuse, reuse, or resale of any content from this app, is strictly prohibited. Our app monitors and records all screenshots and recordings. Violators will face strict legal action.

# ORAL SURGERY

## SBQ 16

**SCENARIO OF DENS INVAGINATUS. 8-9 YEARS OLD MAYBE PATIENT HAD FEVER AND INFRAORBITAL SWELLING. TEMP 38. X-RAY GIVEN**

### I. You took an iopa. What is the diagnosis for 12?

- A. Dens invaginatus
- B. Open apex
- C. Internal resorption
- D. Vertical root fracture

### II. What should be the immediate treatment?

- A. Extraction and drainage
- B. Drainage through intraoral incision and antibiotics
- C. Drainage through skin
- D. Antibiotics and recall
- E. Extraction And Antibiotics
- F. Refer to hospital emergency

### III. Mother is concerned. What will replace the tooth if it goes for extraction?

- A. Make a temporary rpd for 12 Cantilever
- B. Resin bonded bridge with 11 Implant
- C. Fixed bridge with 11,13
- D. Tell her 13 will come in its place Refer to orthodontist
- E. Leave it as it is

### IV. Mother is asking what will happen if we go for rct? What will you advise her regarding the outcome of rct on 12?

- A. Will need multiple dressings for root closure before final restoration
- B. Rct can be done but such tooth has poor prognosis
- C. Rct is not possible

### V. You see the opposite 22 has similar clinical appearance but no radiolucency seen with it. What will you do?

- A. Pit and fissures sealant
- B. Rct
- C. Explore and filling Pulpotomy

THIS IS COPYRIGHTED CONTENT. Unauthorized use, including screenshots, copying, misuse, reuse, or resale of any content from this app, is strictly prohibited. Our app monitors and records all screenshots and recordings. Violators will face strict legal action.

**DISCLAIMER**  
THIS IS COPYRIGHTED CONTENT. Unauthorized use, including screenshots, copying, misuse, reuse, or resale of any content from this app, is strictly prohibited. Our app monitors and records all screenshots and recordings. Violators will face strict legal action.

## DISCLAIMER

THIS IS COPYRIGHTED CONTENT. Unauthorized use, including screenshots, copying, misuse, reuse, or resale of any content from this app, is strictly prohibited. Our app monitors and records all screenshots and recordings. Violators will face strict legal action.



# ORAL SURGERY

## P.O.W.E.R NOTES SBQ 16

- I. Dens invaginatus, also known as dens in dente, is a dental anomaly resulting from an invagination (infolding) of the enamel organ into the dental papilla during tooth development. This condition leads to the formation of a tooth within a tooth  
Location: This anomaly most commonly affects the maxillary lateral incisors but can occur in any tooth.

Location: This anomaly most commonly affects the maxillary lateral incisors but can occur in any tooth.

### Clinical Implications:

- Teeth with dens invaginatus are more susceptible to dental caries and pulp infections because the invaginated area can create an entry point for bacteria.
- The condition can lead to pulpitis or periapical periodontitis if not treated appropriately.

**Treatment:** The treatment depends on the type and severity of the invagination and may include:

- Preventive measures such as sealing the invagination to prevent bacterial entry.
- Endodontic treatment (root canal therapy) if the pulp is involved.
- In severe cases, extraction might be necessary if the tooth is not restorable.
- Early diagnosis and appropriate management are crucial to prevent complications associated with dens invaginatus.

- II. Hospital referral is done in case of spreading infection with sever and systemic features.

- III. To decide whether we need to maintain this space, to decide whether we need to move canine or not, we need to refer the patient to the orthodontist.

- IV. If RCT is needed to attempt in dens invaginatus tooth, it should be done by a specialist. But these teeth have poor prognosis.

- V. In these teeth prophylactic RCT is not done as they have complicated pulp anatomy. Instead, preventive measures such as sealing the invagination to prevent bacterial entry is the best thing to do.

### DISCLAIMER

THIS IS COPYRIGHTED CONTENT. Unauthorized use, including screenshots, copying, misuse, reuse, or resale of any content from this app, is strictly prohibited. Our app monitors and records all screenshots and recordings. Violators will face strict legal action.

DISCLAIMER

THIS IS COPYRIGHTED CONTENT. Unauthorized use, including screenshots, copying, misuse, reuse, or resale of any content from this app, is strictly prohibited. Our app monitors and records all screenshots and recordings. Violators will face strict legal action.

DISCLAIMER

THIS IS COPYRIGHTED CONTENT. Unauthorized use, including screenshots, copying, misuse, reuse, or resale of any content from this app, is strictly prohibited. Our app monitors and records all screenshots and recordings. Violators will face strict legal action.



# ORAL SURGERY

## SBQ 17

### COVID RESTRICTIONS LEVEL 1 QUESTION

**DEFER NON-URGENT TREATMENT FOR PEOPLE WHO DO MEET EPIDEMIOLOGICAL OR CLINICAL SYMPTOM CRITERIA FOR COVID-19 RISK. URGENT DENTAL TREATMENT FOR PEOPLE WHO DO MEET EPIDEMIOLOGICAL OR CLINICAL SYMPTOM CRITERIA FOR COVID-19 RISK OR CONFIRMED AS A COVID-19 CASE, PROVIDED AS PER ADA MANAGING COVID-19 GUIDELINES**

#### I. Which is the recommended mouthwash

- A. 1% hydrogen peroxide
- B. Chlorhexidine 0.2%
- C. 0.2% povidone iodine
- D. Essential oil

#### II. Who should use the mouthwash

- A. Pre & post procedural mouth rinse by Staff & Patient
- B. Pre-operative mouth rinse by patient and staff
- C. Pre-operative mouth rinse by patient and postoperative rinse by Staff
- D. Pre procedural Patient only

#### III. Patient has swelling but and has been exposed to covid and waiting for test results, she insist you to do check up on her, What would be the management?

- A. Give her appt ("at the end of the day" not given in our center) and clean everything using standard precaution.
- B. Refer her to the local community hospital (emergency department?)
- C. Telephone appt
- D. Defer until test result arrive

#### IV. The patient had to take analgesics. Which one to give? No medical history/ condition, has mild toothache.

- A. PCM and Ibuprofen separately
- B. PCM and Ibuprofen together
- C. PCM and celecoxib combination together
- D. PCM and celecoxib separately

#### V. Other pt has to get treatment generating aerosol, which can't be deferred, what else would you do in addition to the covid precautions?

- A. Use p2 or n95 masks for the dentist and staff
- B. 15 min fallow time after pt completes
- C. Clean everything after pt finishes treatment with Tga approved disinfectant active against covid-19 only once.
- D. Use disposable instruments and double sterilization of the other instruments.
- E. Use level 3 SURGICAL mask FOR aerosol generating procedure

#### DISCLAIMER

THIS IS COPYRIGHTED CONTENT. Unauthorized use, including screenshots, copying, misuse, reuse, or resale of any content from this app, is strictly prohibited. Our app monitors and records all screenshots and recordings. Violators will face strict legal action.

#### DISCLAIMER

THIS IS COPYRIGHTED CONTENT. Unauthorized use, including screenshots, copying, misuse, reuse, or resale of any content from this app, is strictly prohibited. Our app monitors and records all screenshots and recordings. Violators will face strict legal action.

THIS IS COPYRIGHTED CONTENT. Unauthorized use, including screenshots, copying, misuse, reuse, or resale of any content from this app, is strictly prohibited. Our app monitors and records all screenshots and recordings. Violators will face strict legal action.

#### DISCLAIMER

# ORAL SURGERY

## P.O.W.E.R NOTES SBQ 17

- I. As per the latest university of Adelaide article and guidelines floor, chlorhexidine is the most preferred agent for mouth rinsing for pre-procedural mouth rinsing in case of Covid precautions

Sequentially after chlorhexidine, you will choose hydrogen peroxide, 1% and then essential oils.

**NOTE: ONLY SBQ 17 - QUESTION I IS STILL PART OF SYLLABUS THE REST ARE OUT OF SYLLABUS**

THIS IS COPYRIGHTED CONTENT. Unauthorized use, including screenshots, copying, misuse, reuse, or resale of any content from this app, is strictly prohibited. Our app monitors and records all screenshots and recordings. Violators will face strict legal action.

THIS IS COPYRIGHTED CONTENT. Unauthorized use, including screenshots, copying, misuse, reuse, or resale of any content from this app, is strictly prohibited. Our app monitors and records all screenshots and recordings. Violators will face strict legal action.

THIS IS COPYRIGHTED CONTENT. Unauthorized use, including screenshots, copying, misuse, reuse, or resale of any content from this app, is strictly prohibited. Our app monitors and records all screenshots and recordings. Violators will face strict legal action.

### DISCLAIMER

THIS IS COPYRIGHTED CONTENT. Unauthorized use, including screenshots, copying, misuse, reuse, or resale of any content from this app, is strictly prohibited. Our app monitors and records all screenshots and recordings. Violators will face strict legal action.

DISCLAIMER  
THIS IS COPYRIGHTED CONTENT. Unauthorized use, including screenshots, copying, misuse, reuse, or resale of any content from this app, is strictly prohibited. Our app monitors and records all screenshots and recordings. Violators will face strict legal action.

# ORAL SURGERY

## SBQ 18

### IMPLANT

**I. Which local criteria will help with stability of the implant with further help in Treatment planning for this patient. Would you check before giving the implant to the patient?**

- A. Plaque index
- B. Take study model cast
- C. CBCT
- D. OPG

**II. You palpate the alveolar ridge area wrt14 and buccal cortical plate was the cortical plate collapsed so what will do?**

- A. Bone graft before placing implant
- B. Bone graft does not require before placing implant
- C. We can't place implant because the poor bone quality
- D. Place implant with lingual tilt with angulated abutment
- E. Place an implant with angled abutment
- F. Bone graft after implant placement

**III. Which further radiographic investigation u will go ahead / What have you gone to the Pt about the maxillary 14 region to place an implant?**

- A. Large intertrabecular space
- B. Improper bone quality
- C. Maxillary sinus nearby
- D. Pneumatization of sinus
- E. Porous bone something

**IV. What is the important history we have to consider in this patient?**

- A. Previous History of Bone graft rejection
- B. History of bone disease
- C. Smoking
- D. History of metabolic disease

**V. What feature is most desirable in the investigation you would like to order further?**

- A. Ability to measure linear measurements accurately
- B. High resolution
- C. Superimposition of anatomical structures
- D. Level of sinus
- E. 2d image
- F. Breadth image

**VI. Best exam to do a implant**

- A. Opg
- B. Cbct
- C. Periapical

### DISCLAIMER

THIS IS COPYRIGHTED CONTENT. Unauthorized use, including screenshots, copying, misuse, reuse, or resale of any content from this app, is strictly prohibited. Our app monitors and records all screenshots and recordings. Violators will face strict legal action.

### DISCLAIMER

THIS IS COPYRIGHTED CONTENT. Unauthorized use, including screenshots, copying, misuse, reuse, or resale of any content from this app, is strictly prohibited. Our app monitors and records all screenshots and recordings. Violators will face strict legal action.

THIS IS COPYRIGHTED CONTENT. Unauthorized use, including screenshots, copying, misuse, reuse, or resale of any content from this app, is strictly prohibited. Our app monitors and records all screenshots and recordings. Violators will face strict legal action.

### DISCLAIMER

# ORAL SURGERY

## P.O.W.E.R NOTES SBQ 18

- I. The implant disease risk assessment was introduced as a guide to identify the risk of developing implant disease. 8 parameters were suggested to be included in assessing the risk of peri-implant disease in a patient.

They include:

- History of periodontitis
- Bleeding on probing
- Number of teeth/implants with probing depth of 5mm or more
- Bone loss/ age of the patient
- Periodontitis susceptibility
- Compliance with supportive care
- Distance of the restorative margin to the bone crest
- Prosthesis related factor

If both plaque index and BOP are given as options, BOP comes 1st.

- II. Buccal cortical plate was collapsed, so, there's an anatomical restriction for engaging both the anatomical plates with implants. Solution for that would be either adding a bone graft or changing the direction of the implant placement towards where there is more bone present to engage the cortical plates. So, among these 2 options placing bone graft before implants placement is the best. If option (A) is not given (D) is the 2nd best option.

The use of angled abutments facilitates paralleling, nonaligned implants, thereby making prosthesis fabrication easier. The abutments can also aid the clinician in avoiding anatomical structures when placing implants. In addition, use of angled abutments can reduce treatment time, fees and the need to perform guided tissue regeneration procedures.

- III. There's poor bone quality in the maxillary premolar region.

Reference:

*The bone height between the floor of the maxillary sinus and the alveolar crest is routinely analysed in oral implantology when posterior maxillary implants are contemplated. An increase of sinus volume or sinus pneumatization after a loss of a posterior tooth/ teeth often necessitates vertical bone augmentation with a sinus lift procedure if implants are considered in this area. The bone of this region is also known to have compromised bone quality (type 3 and 4) that can increase an implant failure rate.*

- IV. We are planning to place a graft in this patient, so, previous hx of bone graft rejection is important to ask. In the presence of positive hx there's a high chance of failure in this procedure.

Smoking is not an absolute contraindication for implants.

### DISCLAIMER

THIS IS COPYRIGHTED CONTENT. Unauthorized use, including screenshots, copying, misuse, reuse, or resale of any content from this app, is strictly prohibited. Our app monitors and records all screenshots and recordings. Violators will face strict legal action.

DISCLAIMER  
THIS IS COPYRIGHTED CONTENT. Unauthorized use, including screenshots, copying, misuse, reuse, or resale of any content from this app, is strictly prohibited. Our app monitors and records all screenshots and recordings. Violators will face strict legal action.



# ORAL SURGERY

## P.O.W.E.R NOTES SBQ 18

V. CBCT provides accurate linear measurements, which are essential for diagnosing and planning treatments, especially in orthodontics, implantology, and reconstructive surgery. The precision depends on the voxel size, image resolution, and the quality of the CBCT machine.

VI. **Comparison with Other Imaging Techniques:** CBCT provides more accurate 3D measurements compared to traditional 2D imaging techniques like panoramic radiographs or cephalograms.

THIS IS COPYRIGHTED  
CONTENT. Unauthorized use,  
including screenshots,  
copying, misuse, reuse, or  
resale of any content from  
this app, is strictly prohibited.  
Our app monitors and records  
all screenshots and  
recordings. Violators will face  
strict legal action.

THIS IS COPYRIGHTED  
CONTENT. Unauthorized use,  
including screenshots,  
copying, misuse, reuse, or  
resale of any content from  
this app, is strictly prohibited.  
Our app monitors and records  
all screenshots and  
recordings. Violators will face  
strict legal action.

THIS IS COPYRIGHTED  
CONTENT. Unauthorized use,  
including screenshots,  
copying, misuse, reuse, or  
resale of any content from  
this app, is strictly prohibited.  
Our app monitors and records  
all screenshots and  
recordings. Violators will face  
strict legal action.

### DISCLAIMER

THIS IS COPYRIGHTED CONTENT. Unauthorized use, including screenshots, copying, misuse, reuse, or resale of any content from this app, is strictly prohibited. Our app monitors and records all screenshots and recordings. Violators will face strict legal action.

DISCLAIMER  
THIS IS COPYRIGHTED CONTENT. Unauthorized use, including screenshots, copying, misuse, reuse, or resale of any content from this app, is strictly prohibited. Our app monitors and records all screenshots and recordings. Violators will face strict legal action.

# ORAL SURGERY

## SBQ 19

WHILE PLACING AN IMPLANT WRT 36 WHICH ANATOMICAL STRUCTURE (THICK RADIOPAQUE LINE RUNNING ALONG D ROOTS OTHER THAN SUB MANDIBULAR FOSSA RELEVANT DURING THE INVESTIGATION)

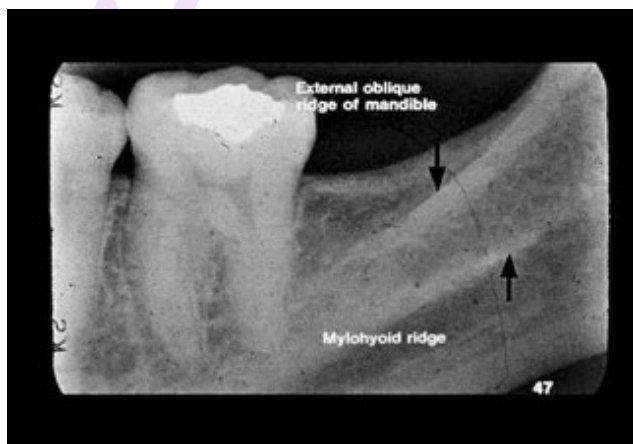- A. Mylohyoid ridge
- B. Inferior alveolar canal
- C. Lingual nerve
- D. External oblique ridge

## P.O.W.E.R NOTES SBQ 19

- I. Among the given inferior alveolar canal and lingual nerve are radiolucent structures.

In the question it's asking for the radiopaque structures. External oblique ridge is a radiopaque structure that runs over the CEJ. Mylohyoid ridge is a radiopaque structure that runs over the roots.

Submandibular fossa is a radiolucency diffusely present near the inferior alveolar canal.



CONTENT. Unauthorized use, including screenshots, copying, misuse, reuse, or resale of any content from this app, is strictly prohibited. Our app monitors and records all screenshots and recordings. Violators will face strict legal action.

## DISCLAIMER

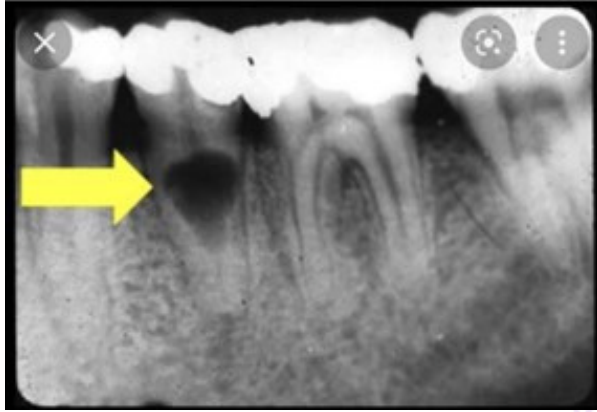
THIS IS COPYRIGHTED CONTENT. Unauthorized use, including screenshots, copying, misuse, reuse, or resale of any content from this app, is strictly prohibited. Our app monitors and records all screenshots and recordings. Violators will face strict legal action.

THIS IS COPYRIGHTED CONTENT. Unauthorized use, including screenshots, copying, misuse, reuse, or resale of any content from this app, is strictly prohibited. Our app monitors and records all screenshots and recordings. Violators will face strict legal action.

THIS IS COPYRIGHTED CONTENT. Unauthorized use, including screenshots, copying, misuse, reuse, or resale of any content from this app, is strictly prohibited. Our app monitors and records all screenshots and recordings. Violators will face strict legal action.

DISCLAIMER  
THIS IS COPYRIGHTED CONTENT. Unauthorized use, including screenshots, copying, misuse, reuse, or resale of any content from this app, is strictly prohibited. Our app monitors and records all screenshots and recordings. Violators will face strict legal action.

# ORAL SURGERY

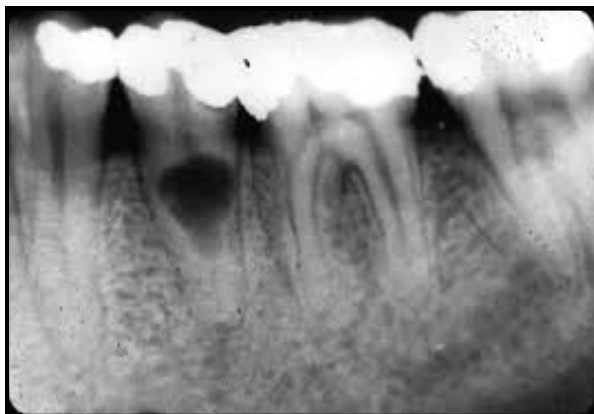
**SBQ 20**
**INDIGENOUS MAN**


I. What is the lesion you see above?

- A. Internal root resorption
- B. External inflammatory root resorption
- C. Cervical root resorption

**P.O.W.E.R NOTES SBQ 20**

- **Radiolucent Area:** A distinct, well-defined radiolucent (dark) area within the root canal space, often round or oval in shape.
- **Uniform Enlargement:** The radiolucent area typically shows a uniform enlargement, indicating the resorptive process within the canal.
- **Root Canal Continuity:** The outer surface of the root appears intact, distinguishing internal resorption from external root resorption where the outer surface is involved.



THIS IS COPYRIGHTED CONTENT. Unauthorized use, including screenshots, copying, misuse, reuse, or resale of any content from this app, is strictly prohibited. Our app monitors and records all screenshots and recordings. Violators will face strict legal action.

**DISCLAIMER**  
THIS IS COPYRIGHTED CONTENT. Unauthorized use, including screenshots, copying, misuse, reuse, or resale of any content from this app, is strictly prohibited. Our app monitors and records all screenshots and recordings. Violators will face strict legal action.

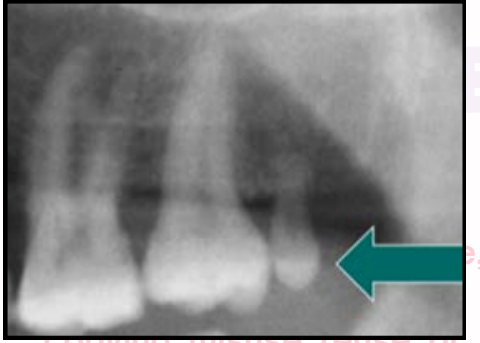
**DISCLAIMER**

THIS IS COPYRIGHTED CONTENT. Unauthorized use, including screenshots, copying, misuse, reuse, or resale of any content from this app, is strictly prohibited. Our app monitors and records all screenshots and recordings. Violators will face strict legal action.

# ORAL SURGERY

## SBQ 21

OPG OF 26 27 AND 28 (SMALL MICRODONT) GIVEN. THE PATIENT WANTS TO UNDERGO EXTRACTION OF THE TOOTH, PT HAD A HISTORY THAT LA NEVER WORK PROPERLY ON HIM.



- I. You want to give palatal and buccal infiltrations to anesthetize tooth 28, Where would you give the palatal infiltration? What is the best direction (or location) how you infiltrate palatally?
  - A. Parallel to long axis of 27
  - B. Parallel to long axis of 28
  - C. Distal to 27
  - D. Distal to 28
  - E. In between of 27 & 28
- II. After infiltration while you attempt to extract the teeth, the patient complains of pain. How further will you anesthetize?
  - A. Intraligamentary injection mesial to 28
  - B. Intraligamentary injection distal to 28
  - C. Intrapulpal injection to 28
  - D. Intra osseous injection

THIS IS COPYRIGHTED CONTENT. Unauthorized use, including screenshots, copying, misuse, reuse, or resale of any content from this app, is strictly prohibited. Our app monitors and records all screenshots and recordings. Violators will face strict legal action.

**DISCLAIMER**  
THIS IS COPYRIGHTED CONTENT. Unauthorized use, including screenshots, copying, misuse, reuse, or resale of any content from this app, is strictly prohibited. Our app monitors and records all screenshots and recordings. Violators will face strict legal action.

THIS IS COPYRIGHTED CONTENT. Unauthorized use, including screenshots, copying, misuse, reuse, or resale of any content from this app, is strictly prohibited. Our app monitors and records all screenshots and recordings. Violators will face strict legal action.

### DISCLAIMER

THIS IS COPYRIGHTED CONTENT. Unauthorized use, including screenshots, copying, misuse, reuse, or resale of any content from this app, is strictly prohibited. Our app monitors and records all screenshots and recordings. Violators will face strict legal action.



# ORAL SURGERY

## P.O.W.E.R NOTES SBQ 21

### I. Reference:

#### INFILTRATION ANAESTHETIC TECHNIQUES

##### Buccal anaesthesia

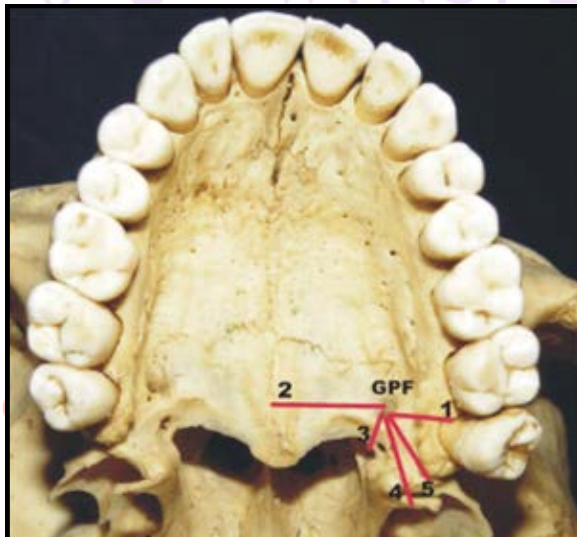
- **Injection for the maxillary 3rd molars**  
Made opposite to the maxillary 2nd molar tooth to avoid injury to the pterygoid plexus of veins.
- **Upper centrals**  
Inject a few drops to the apical area of the central incisor

##### Palatal anaesthesia

- **Injection for the maxillary 3rd molar**  
Should be at the palatal root of the maxillary second molar to avoid anaesthesia of the lesser palatine nerves which supply the soft palate and may lead to gag reflection.

##### Greater palatine nerve

It's located on either side of the roof of the mouth between the 2nd and 3rd maxillary molars, approximately 1cm medial to the palatogingival margin.



- II. It's safer to inject mesial to 28 than distal. Intraligamentary is the most effective supplemental anaesthesia.

### DISCLAIMER

THIS IS COPYRIGHTED CONTENT. Unauthorized use, including screenshots, copying, misuse, reuse, or resale of any content from this app, is strictly prohibited. Our app monitors and records all screenshots and recordings. Violators will face strict legal action.

THIS IS COPYRIGHTED CONTENT. Unauthorized use, including screenshots, copying, misuse, reuse, or resale of any content from this app, is strictly prohibited. Our app monitors and records all screenshots and recordings. Violators will face strict legal action.

DISCLAIMER  
THIS IS COPYRIGHTED CONTENT. Unauthorized use, including screenshots, copying, misuse, reuse, or resale of any content from this app, is strictly prohibited. Our app monitors and records all screenshots and recordings. Violators will face strict legal action.

# ORAL SURGERY

## SBQ 22

**PATIENT WITH UPPER DENTURE AND EPULIS FISSURATUM CASE. REPEATED QUESTION SAME AS IN THE MEGA MASTER FILE, STEPS TO TREAT IT AND MANAGEMENT.**

- A. Refer to oral surgeon and excision with laser, remake the cd
- B. Excision, biopsy and shorten the borders
- C. Excision, shorten the border and reline
- D. New cd

## P.O.W.E.R NOTES SBQ 22

Epulis fissuratum is caused by the over extended borders of the denture. So, we must shorten the borders. Even though it's a non-malignant condition we send for the biopsy for the confirmation.

this app, is strictly prohibited. Our app monitors and records all screenshots and recordings. Violators will face strict legal action.

THIS IS COPYRIGHTED CONTENT. Unauthorized use, including screenshots, copying, misuse, reuse, or resale of any content from this app, is strictly prohibited. Our app monitors and records all screenshots and recordings. Violators will face strict legal action.

THIS IS COPYRIGHTED CONTENT. Unauthorized use, including screenshots, copying, misuse, reuse, or resale of any content from this app, is strictly prohibited. Our app monitors and records all screenshots and recordings. Violators will face strict legal action.

## DISCLAIMER

THIS IS COPYRIGHTED CONTENT. Unauthorized use, including screenshots, copying, misuse, reuse, or resale of any content from this app, is strictly prohibited. Our app monitors and records all screenshots and recordings. Violators will face strict legal action.

DISCLAIMER  
THIS IS COPYRIGHTED CONTENT. Unauthorized use, including screenshots, copying, misuse, reuse, or resale of any content from this app, is strictly prohibited. Our app monitors and records all screenshots and recordings. Violators will face strict legal action.

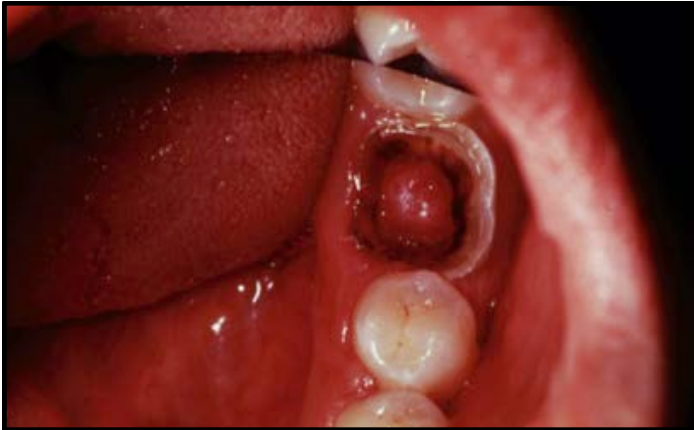
DISCLAIMER

THIS IS COPYRIGHTED CONTENT. Unauthorized use, including screenshots, copying, misuse, reuse, or resale of any content from this app, is strictly prohibited. Our app monitors and records all screenshots and recordings. Violators will face strict legal action.

# ORAL SURGERY

## SBQ 23

ABORIGINAL PT WITH RHEUMATIC HEART DISEASE, 35 YEARS OLD LIVES IN A REMOTE COMMUNITY, COMES WITH HIS SON WHO IS 14YO. PT IS IN PAIN. PT SPEAKS LITTLE ENGLISH AND SON IS TRANSLATING AND REPORTS HIS DAD IS FIT AND WELL APART FROM THE TOOTHACHE AND THAT HE HAS NEVER BEEN TO THE DENTIST.



SIMILAR BUT IN 2ND MOLAR

I. 37 with pulp polyp with picture. You made a provisional diagnosis of pulp polyp. How would you proceed to confirm the nature of the tissue?

- A. Extract the tooth then send it to the pathology lab
- B. Remove the tissue growth and then send to the pathology and start Root canal treatment
- C. Do nothing
- D. Refer him to the public system and wait for an oral surgeon to see him

II. What to take in consideration when using the son as a translator? Or its like Why do you consider his son can't be considered as a translator for him?

- A. Organising a translator will require booking and delay treatment
- B. It is difficult to arrange translator for an aboriginal remote area
- C. The son is 14 yrs old and considered a minor mature
- D. Family members do not always explain the treatment properly
- E. The situation is an emergency

### DISCLAIMER

THIS IS COPYRIGHTED CONTENT. Unauthorized use, including screenshots, copying, misuse, reuse, or resale of any content from this app, is strictly prohibited. Our app monitors and records all screenshots and recordings. Violators will face strict legal action.

### DISCLAIMER

THIS IS COPYRIGHTED CONTENT. Unauthorized use, including screenshots, copying, misuse, reuse, or resale of any content from this app, is strictly prohibited. Our app monitors and records all screenshots and recordings. Violators will face strict legal action.

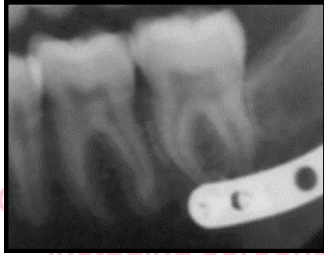THIS IS COPYRIGHTED CONTENT. Unauthorized use, including screenshots, copying, misuse, reuse, or resale of any content from this app, is strictly prohibited. Our app monitors and records all screenshots and recordings. Violators will face strict legal action.

### DISCLAIMER

# ORAL SURGERY

## SBQ 23

III. IOPA X-ray given of the patient's lower posterior molar region asked what is the radiopacity in exam caused by (tricky question as hx mention pt has never been to the dentist). Aboriginal man (looked like titanium plate over the region of the 3rd lower molar and the pulp polyp was in the 2nd molar)



X-ray similar to this

- A. Artifact
- B. Titanium plate
- C. Patient movement
- D. Jewellery
- E. X-ray holder

IV. You decided on the extraction of this tooth. What other investigation do you have?

- A. X ray
- B. Pulp sensibility
- C. Opg
- D. Cbct

V. The patient was concerned about antibiotics that he took previously with other procedure and this appointment he did not take it. What will u do?

- A. Clindamycin 2g iv 60min before
- B. Amox 2g iv 60 min before
- C. Amox 3g
- D. Amox 500 mg oral one hour before the procedure

THIS IS COPYRIGHTED CONTENT. Unauthorized use, including screenshots, copying, misuse, reuse, or resale of any content from this app, is strictly prohibited. Our app monitors and records all screenshots and recordings. Violators will face strict legal action.

### DISCLAIMER

THIS IS COPYRIGHTED CONTENT. Unauthorized use, including screenshots, copying, misuse, reuse, or resale of any content from this app, is strictly prohibited. Our app monitors and records all screenshots and recordings. Violators will face strict legal action.

THIS IS COPYRIGHTED CONTENT. Unauthorized use, including screenshots, copying, misuse, reuse, or resale of any content from this app, is strictly prohibited. Our app monitors and records all screenshots and recordings. Violators will face strict legal action.

THIS IS COPYRIGHTED CONTENT. Unauthorized use, including screenshots, copying, misuse, reuse, or resale of any content from this app, is strictly prohibited. Our app monitors and records all screenshots and recordings. Violators will face strict legal action.

**DISCLAIMER**  
THIS IS COPYRIGHTED CONTENT. Unauthorized use, including screenshots, copying, misuse, reuse, or resale of any content from this app, is strictly prohibited. Our app monitors and records all screenshots and recordings. Violators will face strict legal action.

THIS IS COPYRIGHTED CONTENT. Unauthorized use, including screenshots, copying, misuse, reuse, or resale of any content from this app, is strictly prohibited. Our app monitors and records all screenshots and recordings. Violators will face strict legal action.

**DISCLAIMER**



# ORAL SURGERY

## P.O.W.E.R NOTES SBQ 23

Any patient with rheumatic heart disease requires ABP.

- I. Any abnormal growth in the mouth / body should be removed and sent for the pathological examination. If the tooth is non restorable or if the patient cannot afford the treatment cost, extraction is indicated. That's why the answer is Option (A).
- II. According to the COC guidelines, a family member is not considered as a translator, as they don't explain the treatment properly. You should arrange another translator.
- III. Radiopaque metallic plate which is used in fracture reduction is given in the IOPA. Patient says that he has never been to the dentist, but the fracture could have been managed in a hospital set up and he may have forgotten about it.
- IV. The degree of fracture displacement and the relationship of the fracture line to the periodontium are evaluated using OPG. Pulp sensibility test won't be helpful as it's a case of chronic irreversible pulpitis. As the base line investigation CBCT is not required initially.
- V. Amoxicillin when given as a prophylactic AB, it's given 2g, 60min before. Clindamycin when given as a prophylactic AB, it's given 600mg, 60min before.

THIS IS COPYRIGHTED CONTENT. Unauthorized use, including screenshots, copying, misuse, reuse, or resale of any content from this app, is strictly prohibited. Our app monitors and records all screenshots and recordings. Violators will face strict legal action.

### DISCLAIMER

THIS IS COPYRIGHTED CONTENT. Unauthorized use, including screenshots, copying, misuse, reuse, or resale of any content from this app, is strictly prohibited. Our app monitors and records all screenshots and recordings. Violators will face strict legal action.

THIS IS COPYRIGHTED CONTENT. Unauthorized use, including screenshots, copying, misuse, reuse, or resale of any content from this app, is strictly prohibited. Our app monitors and records all screenshots and recordings. Violators will face strict legal action.

THIS IS COPYRIGHTED CONTENT. Unauthorized use, including screenshots, copying, misuse, reuse, or resale of any content from this app, is strictly prohibited. Our app monitors and records all screenshots and recordings. Violators will face strict legal action.

DISCLAIMER  
THIS IS COPYRIGHTED CONTENT. Unauthorized use, including screenshots, copying, misuse, reuse, or resale of any content from this app, is strictly prohibited. Our app monitors and records all screenshots and recordings. Violators will face strict legal action.

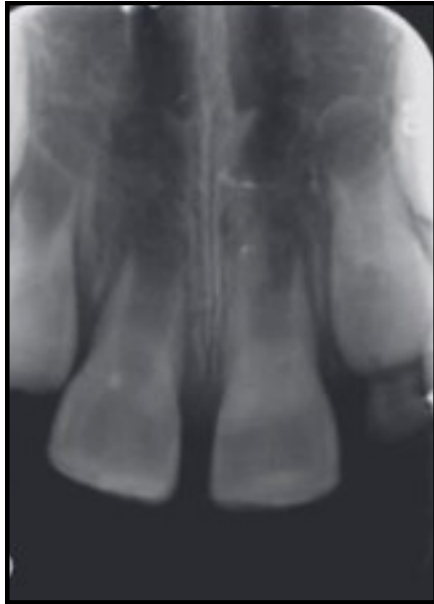DISCLAIMER

THIS IS COPYRIGHTED CONTENT. Unauthorized use, including screenshots, copying, misuse, reuse, or resale of any content from this app, is strictly prohibited. Our app monitors and records all screenshots and recordings. Violators will face strict legal action.

# ORAL SURGERY

## SBQ 24

EXACTLY SAME PICTURE IN EXAM WHAT'S THE RADIO LUCENCY, ALONG THE APEX IN THE PERIAPICAL BELOW:



- A. Normal apex for patient age
- B. External root resorption
- C. Nasal cavities
- D. Open apex

### P.O.W.E.R NOTES SBQ 24

According to the IOPA there's an extending radiolucency from the apices of the roots suggestive of nasal cavity.

THIS IS COPYRIGHTED CONTENT. Unauthorized use, including screenshots, copying, misuse, reuse, or resale of any content from this app, is strictly prohibited. Our app monitors and records all screenshots and recordings. Violators will face strict legal action.

THIS IS COPYRIGHTED CONTENT. Unauthorized use, including screenshots, copying, misuse, reuse, or resale of any content from this app, is strictly prohibited. Our app monitors and records all screenshots and recordings. Violators will face strict legal action.

THIS IS COPYRIGHTED CONTENT. Unauthorized use, including screenshots, copying, misuse, reuse, or resale of any content from this app, is strictly prohibited. Our app monitors and records all screenshots and recordings. Violators will face strict legal action.

#### DISCLAIMER

THIS IS COPYRIGHTED CONTENT. Unauthorized use, including screenshots, copying, misuse, reuse, or resale of any content from this app, is strictly prohibited. Our app monitors and records all screenshots and recordings. Violators will face strict legal action.

DISCLAIMER  
THIS IS COPYRIGHTED CONTENT. Unauthorized use, including screenshots, copying, misuse, reuse, or resale of any content from this app, is strictly prohibited. Our app monitors and records all screenshots and recordings. Violators will face strict legal action.

THIS IS COPYRIGHTED CONTENT. Unauthorized use, including screenshots, copying, misuse, reuse, or resale of any content from this app, is strictly prohibited. Our app monitors and records all screenshots and recordings. Violators will face strict legal action.

DISCLAIMER

# ORAL SURGERY

## SBQ 25

### SURVEY X-RAY AFTER ALL 3RD MOLARS HAVE ERUPTED

- A. Bitewing
- B. Periapical
- C. Opg

## P.O.W.E.R NOTES SBQ 26

OPG is the survey x-ray that shows all the 3rd molars.

THIS IS COPYRIGHTED CONTENT. Unauthorized use, including screenshots, copying, misuse, reuse, or resale of any content from this app, is strictly prohibited. Our app monitors and records all screenshots and recordings. Violators will face strict legal action.

THIS IS COPYRIGHTED CONTENT. Unauthorized use, including screenshots, copying, misuse, reuse, or resale of any content from this app, is strictly prohibited. Our app monitors and records all screenshots and recordings. Violators will face strict legal action.

THIS IS COPYRIGHTED CONTENT. Unauthorized use, including screenshots, copying, misuse, reuse, or resale of any content from this app, is strictly prohibited. Our app monitors and records all screenshots and recordings. Violators will face strict legal action.

THIS IS COPYRIGHTED CONTENT. Unauthorized use, including screenshots, copying, misuse, reuse, or resale of any content from this app, is strictly prohibited. Our app monitors and records all screenshots and recordings. Violators will face strict legal action.

## DISCLAIMER

THIS IS COPYRIGHTED CONTENT. Unauthorized use, including screenshots, copying, misuse, reuse, or resale of any content from this app, is strictly prohibited. Our app monitors and records all screenshots and recordings. Violators will face strict legal action.

DISCLAIMER  
THIS IS COPYRIGHTED CONTENT. Unauthorized use, including screenshots, copying, misuse, reuse, or resale of any content from this app, is strictly prohibited. Our app monitors and records all screenshots and recordings. Violators will face strict legal action.

# ORAL SURGERY

## SBQ 26

### PREGNANT LADY

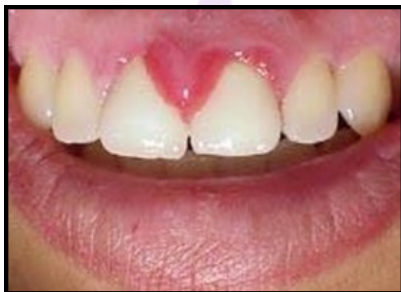PATIENT SEES THE DENTIST THAT SHE GOT HOME PREGNANCY TEST WHICH SHOWED POSITIVE, THEN COMPLAINS MOBILE TEETH IN THE LOWER JAW

- I. Dentist wants to extract her tooth what precautions will u take during radiograph
- Take the x-ray and continue with treatment plan
  - Recall her second trimester and take the x-ray

- II. A lady came to see you for a clean, 20 weeks pregnant she complains of sore gums, while doing the cleaning, she complains that it is uncomfortable and you decide to give her an anaesthesia to help with the pain. Which anaesthesia will you choose/What is the most appropriate LA to use?

- Lignocaine 10% GEL
- Prilocaine 3% with felypressin
- Lignocaine 2% with adrenaline 1:80000
- Articaine 4% with adrenaline
- Lidocaine plain

- III. Few weeks later she comes back to see you 30 weeks pregnant, she wants you to check her gums. What is your management for this presentation?



- Clean and biopsy pathology ( not there in my station)
- Tell her don't need to do anything
- Only clean( in my station this was not there)
- Do nothing and asked her to cm bck after delivery
- Local debridement and ohi
- 0.12% chx mouthwash

### DISCLAIMER

THIS IS COPYRIGHTED CONTENT. Unauthorized use, including screenshots, copying, misuse, reuse, or resale of any content from this app, is strictly prohibited. Our app monitors and records all screenshots and recordings. Violators will face strict legal action.

### DISCLAIMER

THIS IS COPYRIGHTED CONTENT. Unauthorized use, including screenshots, copying, misuse, reuse, or resale of any content from this app, is strictly prohibited. Our app monitors and records all screenshots and recordings. Violators will face strict legal action.

THIS IS COPYRIGHTED CONTENT. Unauthorized use, including screenshots, copying, misuse, reuse, or resale of any content from this app, is strictly prohibited. Our app monitors and records all screenshots and recordings. Violators will face strict legal action.

### DISCLAIMER



# ORAL SURGERY

## P.O.W.E.R NOTES SBQ 26

- I. However, most procedures to be performed in dentistry are important in the 1st trimester and the 3rd trimester, in terms of the stresses to which the mother and the baby will be exposed. Effective dental treatment in the 1st trimester should be avoided. This period is a very sensitive period because it's the stage of organogenesis. Unnecessary interventions can lead to abortions. However, in case where there is pain or if no intervention will cause more harm, the teeth must be urgently treated. Under these circumstances, tooth extraction and canal treatment can be performed.  
x-rays are not contraindicated in pregnancy.  
As per the latest guidelines for the management of any infection in pregnant patients, it is the latest recommendation to remove the source of infection as early as possible in pregnancy. So taking radiograph and extraction or doing RCT for removal of source of infection is not contraindicated anymore, follow the latest pregnancy guideline article for more details. So best answer will be option A.
- II. Lignocaine with adrenaline is not contraindicated during pregnancy. Lignocaine gel is the best and painless method to achieve anesthesia in gums while scaling.
- III. In case of pregnancy epulis we will not excise it, instead we will perform FMS and give OHI.

THIS IS COPYRIGHTED CONTENT. Unauthorized use, including screenshots, copying, misuse, reuse, or resale of any content from this app, is strictly prohibited. Our app monitors and records all screenshots and recordings. Violators will face strict legal action.

### DISCLAIMER

THIS IS COPYRIGHTED CONTENT. Unauthorized use, including screenshots, copying, misuse, reuse, or resale of any content from this app, is strictly prohibited. Our app monitors and records all screenshots and recordings. Violators will face strict legal action.

THIS IS COPYRIGHTED CONTENT. Unauthorized use, including screenshots, copying, misuse, reuse, or resale of any content from this app, is strictly prohibited. Our app monitors and records all screenshots and recordings. Violators will face strict legal action.

DISCLAIMER  
THIS IS COPYRIGHTED CONTENT. Unauthorized use, including screenshots, copying, misuse, reuse, or resale of any content from this app, is strictly prohibited. Our app monitors and records all screenshots and recordings. Violators will face strict legal action.

DISCLAIMER

THIS IS COPYRIGHTED CONTENT. Unauthorized use, including screenshots, copying, misuse, reuse, or resale of any content from this app, is strictly prohibited. Our app monitors and records all screenshots and recordings. Violators will face strict legal action.

# ORAL SURGERY

## SBQ 27

PATIENT WEIGHS 80 KGS. TOOTH #36 WITH PERIODONTAL INVOLVEMENT AND RADIOLUCENCY ALL AROUND THE ROOTS. YOU INJECT 1.8ML OF LIGNOCAINE USING THE CORRECT TECHNIQUE FOR THE IAN BLOCK. WAIT FOR 5 MINUTES BUT THE PATIENT STILL FEELS PAIN. YOU ATTEMPT TO INJECT A SECOND CARTRIDGE AND IT WORKS. WHAT IS THE MOST LIKELY REASON FOR THE FAIL OF THE FIRST INJECTION?

I. One question ask about block fail reason and the other for infiltration fail reason (Totally 6.3 ml of LA was injected) Not enough anaesthesia. Picture shows there was an gingival swelling in the buccal vestibule wrt 36\37

- A. Anatomical variation of the mandibular canal
- B. Not enough wait time i.e 5 mins
- C. Incorrect operator technique

II. Now you gave buccal infiltration twice and the patient still feels pain. What is the reason for failure?

- A. Low pH of the area
- B. Anatomy
- C. Not enough amount of LA given

## P.O.W.E.R NOTES SBQ 27

- I. The technique was good enough and the waiting time after LA was good enough. According to the Walton it's given that the failure rate of the mandibular nerve block is due to anatomical variation in the mandibular canal.
- II. Buccal infiltration would fail due to the ph of the tissue/ excessive inflammation. Same happens with the maxillary infiltrations and blocks.

THIS IS COPYRIGHTED CONTENT. Unauthorized use, including screenshots, copying, misuse, reuse, or resale of any content from this app, is strictly prohibited. Our app monitors and records all screenshots and recordings. Violators will face strict legal action.

### DISCLAIMER

THIS IS COPYRIGHTED CONTENT. Unauthorized use, including screenshots, copying, misuse, reuse, or resale of any content from this app, is strictly prohibited. Our app monitors and records all screenshots and recordings. Violators will face strict legal action.

DISCLAIMER  
THIS IS COPYRIGHTED CONTENT. Unauthorized use, including screenshots, copying, misuse, reuse, or resale of any content from this app, is strictly prohibited. Our app monitors and records all screenshots and recordings. Violators will face strict legal action.

THIS IS COPYRIGHTED CONTENT. Unauthorized use, including screenshots, copying, misuse, reuse, or resale of any content from this app, is strictly prohibited. Our app monitors and records all screenshots and recordings. Violators will face strict legal action.

DISCLAIMER

# ORAL SURGERY

## SBQ 28

ADULT PATIENT. WITH UNCOMPLICATED CROWN FRACTURE PALATALLY JUST BELOW THE GINGIVA CASE, APEX COMPLETE. PATIENT WITH INCISAL MESIAL AND SUBGINGIVAL FRACTURE, NORMAL PULP SENSIBILITY TEST, NO PULP EXPOSURE BUT THE PINK COLOR OF THE PULP CAN BE SEEN THROUGH DENTINE( VERY CLOSE TO PULP). PT COMPLAINS OF SLIGHT SENSITIVITY. ALMOST HALF OF THE TOOTH WAS LOST. ALSO THIS TOOTH SHOWS MOBILITY BUT NO DISPLACEMENT. (PICTURE WAS GIVEN FROM BUCCAL VIEW WRT I1 WHERE THE FRACTURED 2/3RD CLINICAL CROWN)

### I. What is going to be your immediate management today:

- A. Complete root canal treatment with restoration
- B. CaOH and gic restoration
- C. Pulpotomy with calcium hydroxide with restoration
- D. GIC restoration

### II. What is the most appropriate treatment for this tooth? Asked about the long term treatment.

- A. Post and core, crown by rct
- B. Core and crown
- C. Give Veneers

## P.O.W.E.R NOTES SBQ 28

- I. Uncomplicated crown fracture in a permanent mature tooth: indirect pulp capping with Ca(OH)<sub>2</sub> and GIC is indicated. Pulp capping is done because pink colour of the pulp is seen through the dentine.
- II. Half of the tooth structure is lost so veneers are not indicated. RCT or post is not required as the pulp is vital. And also prophylactic RCT is not needed as there's enough tooth structure to withstand core and crown.

### DISCLAIMER

THIS IS COPYRIGHTED CONTENT. Unauthorized use, including screenshots, copying, misuse, reuse, or resale of any content from this app, is strictly prohibited. Our app monitors and records all screenshots and recordings. Violators will face strict legal action.

DISCLAIMER

THIS IS COPYRIGHTED CONTENT. Unauthorized use, including screenshots, copying, misuse, reuse, or resale of any content from this app, is strictly prohibited. Our app monitors and records all screenshots and recordings. Violators will face strict legal action.

THIS IS COPYRIGHTED CONTENT. Unauthorized use, including screenshots, copying, misuse, reuse, or resale of any content from this app, is strictly prohibited. Our app monitors and records all screenshots and recordings. Violators will face strict legal action.

DISCLAIMER

# ORAL SURGERY

## SBQ 29

PATIENT HAS ALVEOLAR OSTEITIS, SOCKET WAS IRRIGATED WITH CHLORHEXIDINE AND ALVOGYL WAS PLACED. WHAT ALLERGY WOULD MOST LIKELY OCCUR? OR WHAT ALLERGY WOULD YOU CHECK.

- A. Allergy to milk proteins
- B. Allergy to egg proteins
- C. Allergy to iodine
- D. Allergy to chlorhexidine

## P.O.W.E.R NOTES SBQ 29

CHX can cause anaphylaxis when used in open wounds. It is not a commonly reported allergy though as its one of the rare allergies

Alvogyl is contraindicated in those who are allergic to iodine.

Alvogyl is not to be used on the patients having a hx of allergic reactions to procaine type anaesthetics or sensitivity to iodine or iodine compounds.

THIS IS COPYRIGHTED  
CONTENT. Unauthorized use,  
including screenshots,  
copying, misuse, reuse, or  
resale of any content from  
this app, is strictly prohibited.  
Our app monitors and records  
all screenshots and  
recordings. Violators will face  
strict legal action.

### DISCLAIMER

THIS IS COPYRIGHTED CONTENT. Unauthorized use, including screenshots, copying, misuse, reuse, or resale of any content from this app, is strictly prohibited. Our app monitors and records all screenshots and recordings. Violators will face strict legal action.

THIS IS COPYRIGHTED  
CONTENT. Unauthorized use,  
including screenshots,  
copying, misuse, reuse, or  
resale of any content from  
this app, is strictly prohibited.  
Our app monitors and records  
all screenshots and  
recordings. Violators will face  
strict legal action.

THIS IS COPYRIGHTED  
CONTENT. Unauthorized use,  
including screenshots,  
copying, misuse, reuse, or  
resale of any content from  
this app, is strictly prohibited.  
Our app monitors and records  
all screenshots and  
recordings. Violators will face  
strict legal action.

WINSPERT  
P.O.W.E.R  
NOTES

DISCLAIMER  
THIS IS COPYRIGHTED CONTENT. Unauthorized use, including screenshots, copying, misuse, reuse, or resale of any content from this app, is strictly prohibited. Our app monitors and records all screenshots and recordings. Violators will face strict legal action.



# ORAL SURGERY

## SBQ 30

OPG GIVEN AND POINTED ARROWS TOWARDS 1ST QUADRANT. (TWO VARIATIONS ON OPG- COMPOUND ODONTOMA / RETAINED ROOTS)

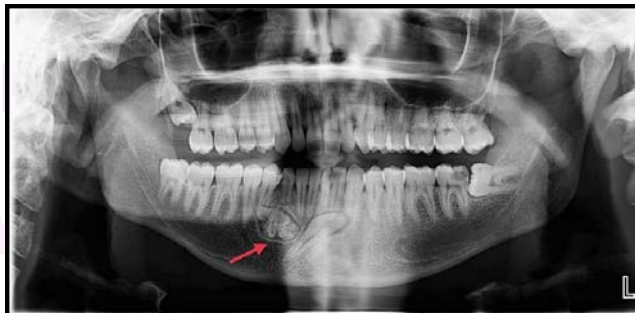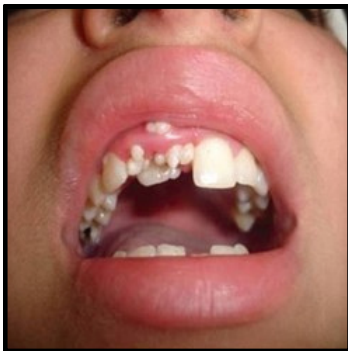- A. Cementoma
- B. Compound odontoma
- C. Ghost image
- D. Supernumerario
- E. Retained roots

## P.O.W.E.R NOTES SBQ 30

### Compound odontoma:

it consists of well-organized, tooth-like structures that resemble small, abnormal teeth or denticles. Compound odontomas typically contain enamel, dentin, cementum, and sometimes pulp, arranged in an orderly pattern.

**Radiographic Appearance:** On X-rays, they appear as a collection of tooth-like structures within a radiolucent (dark) area, surrounded by a well-defined radiopaque (light) border.



THIS IS COPYRIGHTED CONTENT. Unauthorized use, including screenshots, copying, misuse, reuse, or resale of any content from this app, is strictly prohibited. Our app monitors and records all screenshots and recordings. Violators will face strict legal action.

### DISCLAIMER

THIS IS COPYRIGHTED CONTENT. Unauthorized use, including screenshots, copying, misuse, reuse, or resale of any content from this app, is strictly prohibited. Our app monitors and records all screenshots and recordings. Violators will face strict legal action.

THIS IS COPYRIGHTED CONTENT. Unauthorized use, including screenshots, copying, misuse, reuse, or resale of any content from this app, is strictly prohibited. Our app monitors and records all screenshots and recordings. Violators will face strict legal action.

DISCLAIMER  
THIS IS COPYRIGHTED CONTENT. Unauthorized use, including screenshots, copying, misuse, reuse, or resale of any content from this app, is strictly prohibited. Our app monitors and records all screenshots and recordings. Violators will face strict legal action.

THIS IS COPYRIGHTED CONTENT. Unauthorized use, including screenshots, copying, misuse, reuse, or resale of any content from this app, is strictly prohibited. Our app monitors and records all screenshots and recordings. Violators will face strict legal action.

WINSPERT  
P.O.W.E.R  
NOTES

# ORAL SURGERY

## SBQ 31

CHILD WITH TYPE-1 DIABETES AND CRIES NO PAIN AND, NEEDS LA. PREVIOUS DENTISTS SAID THAT THE ANAESTHESIA WAS NOT WORKING AT ALL. "INADEQUATE ANAESTHESIA/ DIFFICULT ANAESTHESIA. WHAT IS THE BEST LA?

- A. 2% lignocaine with 1:80000 adrenaline
- B. Prilocaine with felypressin
- C. Articaine without adrenaline
- D. Mepivacaine 3%

## P.O.W.E.R NOTES SBQ 31

Lignocaine with adrenalin is not contraindicated in diabetic patients.

### DISCLAIMER

THIS IS COPYRIGHTED CONTENT. Unauthorized use, including screenshots, copying, misuse, reuse, or resale of any content from this app, is strictly prohibited. Our app monitors and records all screenshots and recordings. Violators will face strict legal action.

### DISCLAIMER

THIS IS COPYRIGHTED CONTENT. Unauthorized use, including screenshots, copying, misuse, reuse, or resale of any content from this app, is strictly prohibited. Our app monitors and records all screenshots and recordings. Violators will face strict legal action.

# ORAL SURGERY

## SBQ 32

### ICG

#### I. Min requirement for checking steam sterilization by which indicator -

- A. Class 1
- B. Class 2
- C. Class 3
- D. Class 4
- E. Class 5 and 6

#### II. Why do we need to bag / pouch extraction forceps prior to sterilization?

- A. To avoid perforation injuries (In the staff)
- B. To keep it sterile at the time of procedure
- C. To prolong life of instrument
- D. To check the sterilization status by changing color on pouch
- E. To check if the bag changed color

#### III. You were about to start a procedure on a patient, and waiting for an instrument, your DA who was discarding old instruments and suddenly the DA injured. You record the sharp injury, send both patient and the DA for blood test. So you go to the Sterilization chamber to unload, but you see all the pouches are still damp/wet Why the instrument are still wet after sterilization?

- A. Overload chamber?
- B. Paper faced down
- C. Water reservoir full
- D. Door seal not good

#### IV. And you find your instrument - Class 1 indicator not changed color. In which condition does Class 1 indicator change color? OTHER VARIATION What does the class 1 indicator tell

- A. Pouch put in heat or steam
- B. Pouch put in 134 degrees
- C. Pouch put in 137 degrees
- D. Pouch steamed for 3 mins
- E. Pouch put in dry heat

#### V. Precautions taken to restrict legionella (asked in 3 out of 4 papers)

- A. Retraction cord
- B. Silver ion in water lines
- C. 30 sec flushing
- D. H<sub>2</sub>O<sub>2</sub> in water line
- E. Check biofilm concentration in units

### DISCLAIMER

THIS IS COPYRIGHTED CONTENT. Unauthorized use, including screenshots, copying, misuse, reuse, or resale of any content from this app, is strictly prohibited. Our app monitors and records all screenshots and recordings. Violators will face strict legal action.

DISCLAIMER  
THIS IS COPYRIGHTED CONTENT. Unauthorized use, including screenshots, copying, misuse, reuse, or resale of any content from this app, is strictly prohibited. Our app monitors and records all screenshots and recordings. Violators will face strict legal action.

THIS IS COPYRIGHTED CONTENT. Unauthorized use, including screenshots, copying, misuse, reuse, or resale of any content from this app, is strictly prohibited. Our app monitors and records all screenshots and recordings. Violators will face strict legal action.

DISCLAIMER

# ORAL SURGERY

## SBQ 32

**VI. Pt said he read that there was a lady who got pre term labour after getting treated by dentist due to legionella infections How will you reassure the patient?**

- A. By showing him your staffs Attendance
- B. By showing your clinics annual health report
- C. By telling we put silver ions tab in bottle everyday
- D. Tell patient that you disinfect the waterline daily
- E. By showing him your monthly Dental unit water line (DUWL) check report

**VII. When would you open the pouch?**

- A. Just before the procedure
- B. When patient reports to your desk
- C. Two hours after sterilization procedure
- D. When you are setting up the instruments for the procedure.

**VIII. What is the first advice you provide**

- A. Wash with soap and water
- B. Squeeze and allow bleeding for 2 to 3 minutes
- C. Apply pressure
- D. Use alcohol gel hand rub

**IX. Why should extraction forceps be packaged individually?**

- A. Sterile till point of use
- B. So the steam can penetrate inside the bag sterilize
- C. We protect the sharp part and injuries sharp?
- D. To keep it clean while it is kept in storage
- E. So that the sharp beaks of forcep doesn't cause any injury

THIS IS COPYRIGHTED  
CONTENT. Unauthorized use,  
including screenshots,  
copying, misuse, reuse, or  
resale of any content from  
this app, is strictly prohibited.  
Our app monitors and records  
all screenshots and  
recordings. Violators will face  
strict legal action.

### DISCLAIMER

THIS IS COPYRIGHTED CONTENT. Unauthorized use, including screenshots, copying, misuse, reuse, or resale of any content from this app, is strictly prohibited. Our app monitors and records all screenshots and recordings. Violators will face strict legal action.

**DISCLAIMER**  
THIS IS COPYRIGHTED CONTENT. Unauthorized use, including screenshots, copying, misuse, reuse, or resale of any content from this app, is strictly prohibited. Our app monitors and records all screenshots and recordings. Violators will face strict legal action.



# ORAL SURGERY

## P.O.W.E.R NOTES SBQ 32

- I. Class 4 chemical indicator is the minimum that must be included inside every package of a wrapped load when the reprocessing conditions have not (or not yet) been verified by a full qualification process. Class 5 and 6 indicates high accuracy.
- II. Extraction forceps is a critical instrument. Critical instruments are put in pouches to keep it sterile at the time of the procedure.
- III. When the pouches are overloaded and kept over the other, the steam gets trapped between each other.  
If the door seal is not good the colour indicator would not change.
- IV. Class 1 indicator will change colours only to heat/ high temperature and it will not change the colour for steam.
- V. Biofilm levels in the dental equipment can be minimised by using a range of measures, including ozonation, electrochemical activation, and chemical dosing of water (e.g. with hydrogen peroxide, oxygen compounds, hypochlorites, chloramines, iodine, silver ions, or nanoparticle silver).  
**According to the Australian Drinking Water Guidelines:**  
The number of bacteria in water used as a coolant/ irrigant for non-surgical dental procedures should be less than 200 CFU/ml since this is a widely used international limit for safe water for medical application.  
All the given options are correct by option (E) is the most important among them.
- VI. Evidence is most important in reassuring a patient. So, the monthly DUWL check report should be offered to the patient.
- VII. Critical instrument pouches are opened just before the procedure.
- VIII. In case of sharp injury, let the blood flow and wash the area with soap.  
Don't squeeze, don't apply pressure, don't use alcohol in that area.
- IX. Extraction forceps are critical instruments which should be packed individually and should be sterile at the point of use.

### DISCLAIMER

THIS IS COPYRIGHTED CONTENT. Unauthorized use, including screenshots, copying, misuse, reuse, or resale of any content from this app, is strictly prohibited. Our app monitors and records all screenshots and recordings. Violators will face strict legal action.

DISCLAIMER  
THIS IS COPYRIGHTED CONTENT. Unauthorized use, including screenshots, copying, misuse, reuse, or resale of any content from this app, is strictly prohibited. Our app monitors and records all screenshots and recordings. Violators will face strict legal action.

DISCLAIMER

THIS IS COPYRIGHTED CONTENT. Unauthorized use, including screenshots, copying, misuse, reuse, or resale of any content from this app, is strictly prohibited. Our app monitors and records all screenshots and recordings. Violators will face strict legal action.

# ORAL SURGERY

## SBQ 33

### QUESTION ABOUT LA

IT WAS EXTRACTION OF FIRST MOLAR WITH DIVERGENT ROOTS. THE DENTIST WAS GOING TO SECTION THE TOOTH AND KNEW IT WAS GOING TO BE COMPLICATED. YOU WANT TO ACHIEVE A LONGER AND DEEPER ANAESTHESIA.

#### I. Which LA would you prefer

- A. Articaine with adrenaline
- B. Mepivacaine with adrenaline
- C. Lignocaine
- D. Mepivacaine

#### II. X Ray given with radiopacity around the coronal thirds of the molar and premolar. Mentioned that we diagnosed it as Exostoses. What could be the likely cause for this radiopacity in the coronal third of 43,44 (instead of cause, the exact word was REASON)

- A. Bruxism (exact wording - Heavy Bruxer)
- B. History of bone disease
- C. Localized pocket
- D. Calculus
- E. Lack of interdental cleaning

### P.O.W.E.R NOTES SBQ 33

#### I. When adrenaline or felypressin is not added to LA, it will be short acting. Therefore, options (C) and (D) are ruled out.

When adrenaline or felypressin is added to LA, it will be intermediate acting.

Bupivacaine, ropivacaine are long acting. But articaine has a risk of prolonged or permanent anaesthesia. So, it's used only for infiltration and it's not used for regional blocks. Bupivacaine is not used in children younger than 12yrs old.

In the question it's mentioned only 1st molar and not mentioned whether it's lower or upper. So, we believe in this case a block anaesthesia is required. So, among the given options, (B) is the best.

#### II. Hyper deposition of the cortical bone is known as exostosis. It's not a pathological condition. In case if a patient with exostosis requires a denture, we may need to remove the excess bone as it has an impact on the denture retention.

The likely cause of radiopacity in this area / exostosis is due to the bruxism.

**Reference:**

*Aetiology is not established, but it has been suggested that the bony overgrowth can be because of abnormally increased masticatory forces to the teeth.*

### DISCLAIMER

THIS IS COPYRIGHTED CONTENT. Unauthorized use, including screenshots, copying, misuse, reuse, or resale of any content from this app, is strictly prohibited. Our app monitors and records all screenshots and recordings. Violators will face strict legal action.

DISCLAIMER  
THIS IS COPYRIGHTED CONTENT. Unauthorized use, including screenshots, copying, misuse, reuse, or resale of any content from this app, is strictly prohibited. Our app monitors and records all screenshots and recordings. Violators will face strict legal action.

THIS IS COPYRIGHTED CONTENT. Unauthorized use, including screenshots, copying, misuse, reuse, or resale of any content from this app, is strictly prohibited. Our app monitors and records all screenshots and recordings. Violators will face strict legal action.

DISCLAIMER

# ORAL SURGERY

## SBQ 34

**DIFFERENT CASES - YOU PLAN EXTRACTION - LOOKS SIMPLE - SO YOU PUT UP A FINANCIAL PLAN FOR A NORMAL FORCEPS EXTRACTION AND START THE PROCEDURE. MID WAY BETWEEN THE PROCEDURE - COMPLICATION OCCURS - ROOT FRACTURE - SO YOU HAD TO RAISE FLAP AND SURGICAL EXTRACTION DONE.**

### I. How would you manage the patient

- A. Stop extraction midway, explain the patient - about increase cost for surgical extraction and then proceed
- B. Finish the extraction surgically, after the procedure - explain the patient
- C. Its your mistake, so reduce the charges for patient
- D. Get only the planned finance, nothing extra as its a complication during extraction

### II. For this procedure you require anaesthesia. Which anaesthetic agent will you choose?

- A. Mepivacaine with adrenaline
- B. Articaine with adrenaline
- C. Lignocaine with adrenaline

### III. While u reflect the flap how the flap should be, "Based on the flap techniques":

- A. With a wider base
- B. With a narrow base
- C. Reflecting upto the attached gingiva
- D. Partial thickness flap

### IV. In what situation will you leave the root stump:

- A. Deep and vital
- B. Deep and non vital
- C. Superficial
- D. Less than 5 mm size of root stump
- E. Bleeding is uncontrollable

THIS IS COPYRIGHTED CONTENT. Unauthorized use, including screenshots, copying, misuse, reuse, or resale of any content from this app, is strictly prohibited. Our app monitors and records all screenshots and recordings. Violators will face strict legal action.

#### DISCLAIMER

THIS IS COPYRIGHTED CONTENT. Unauthorized use, including screenshots, copying, misuse, reuse, or resale of any content from this app, is strictly prohibited. Our app monitors and records all screenshots and recordings. Violators will face strict legal action.

DISCLAIMER  
THIS IS COPYRIGHTED CONTENT. Unauthorized use, including screenshots, copying, misuse, reuse, or resale of any content from this app, is strictly prohibited. Our app monitors and records all screenshots and recordings. Violators will face strict legal action.

THIS IS COPYRIGHTED CONTENT. Unauthorized use, including screenshots, copying, misuse, reuse, or resale of any content from this app, is strictly prohibited. Our app monitors and records all screenshots and recordings. Violators will face strict legal action.

DISCLAIMER

# ORAL SURGERY

## P.O.W.E.R NOTES SBQ 34

### I. Reference:

*Dental fees may be based on either an itemised schedule of treatment or on the time taken to complete the dental procedure. Accordingly, the dentist may only be able to estimate a range of fees based on the expected time to undertake the procedure and the anticipated complexity of the procedure. Similarly, if the planned procedure is changed during the procedure due to for unseen circumstances, this may also result in a change to the final fee charged by the dentist. Any such change should be advised at an appropriate time.*

### II. It's good to use an intermediate acting LA. Both (A) and (C) are intermediate acting. Lignocaine with adrenaline is the gold standard.

### III. The flap should be wider on the base and narrow on the top up to the mucogingival junction. It should be full thickness as you want the bone to be exposed. The blood circulation will be maintained.

### IV. Reference:

*What happens if a root tip fracture?*

*1st consider leaving it there if it is vital, less than 5mm and in proximity to a vital structure such as nerve. If you can remove it through a small bony window thus maintaining alveolar bone height.*

THIS IS COPYRIGHTED CONTENT. Unauthorized use, including screenshots, copying, misuse, reuse, or resale of any content from this app, is strictly prohibited. Our app monitors and records all screenshots and recordings. Violators will face strict legal action.

#### DISCLAIMER

THIS IS COPYRIGHTED CONTENT. Unauthorized use, including screenshots, copying, misuse, reuse, or resale of any content from this app, is strictly prohibited. Our app monitors and records all screenshots and recordings. Violators will face strict legal action.

THIS IS COPYRIGHTED CONTENT. Unauthorized use, including screenshots, copying, misuse, reuse, or resale of any content from this app, is strictly prohibited. Our app monitors and records all screenshots and recordings. Violators will face strict legal action.

DISCLAIMER  
THIS IS COPYRIGHTED CONTENT. Unauthorized use, including screenshots, copying, misuse, reuse, or resale of any content from this app, is strictly prohibited. Our app monitors and records all screenshots and recordings. Violators will face strict legal action.



# ORAL SURGERY

## SBQ 35

PATIENT - 48 EXTRACTION DONE - PAIN, FOUL TASTE/SMELL YOU GIVE LA - PATIENT SETTLES DOWN - RELIEVED - AFTER 5 MINS. YOU IRRIGATE WITH SALINE, REMOVE SOME SMALL NECROTIC BONE FRAGMENTS - PLACE ALVOGYL SUDDENLY THE PATIENT GETS AGITATED, FLUSHING ON FACE, CHEEKS AND FOREARMS. AMBULANCE ALREADY CALLED APART FROM ANAPHYLAXIS.

### I. Which of the below could have a similar clinical presentation?

- A. Panic attack
- B. Shingles
- C. Impetigo
- D. Increase of core body temperature
- E. Cellulitis

### II. Oral mucosa starts to get swollen suddenly. What's your first management

- A. Tell nurse to call 000 ambulance
- B. Remove alvogyl
- C. Place patient in supine position
- D. Assist to make him stand
- E. Put pressure and ice packs

### III. You administer adrenaline from an auto-injector in his antero lateral thigh (which was available in your clinic) Why was the antero lateral thigh chosen?

- A. Rapid plasma concentration increases
- B. Not invading privacy
- C. Less painful site
- D. Not any major blood vessels in that area
- E. Best site for subcutaneous injections

### IV. Now the patient develops stridor, what is your management?

- A. Administer another adrenaline injection
- B. Administer steroids
- C. Administer oxygen
- D. Administer oral anti histamines

### V. Finally, its anaphylaxis, probably due to?

- A. Lidocaine
- B. Adrenaline
- C. Lodoform
- D. Saline
- E. Nitrile gloves

#### DISCLAIMER

THIS IS COPYRIGHTED CONTENT. Unauthorized use, including screenshots, copying, misuse, reuse, or resale of any content from this app, is strictly prohibited. Our app monitors and records all screenshots and recordings. Violators will face strict legal action.

**DISCLAIMER**  
THIS IS COPYRIGHTED CONTENT. Unauthorized use, including screenshots, copying, misuse, reuse, or resale of any content from this app, is strictly prohibited. Our app monitors and records all screenshots and recordings. Violators will face strict legal action.

THIS IS COPYRIGHTED CONTENT. Unauthorized use, including screenshots, copying, misuse, reuse, or resale of any content from this app, is strictly prohibited. Our app monitors and records all screenshots and recordings. Violators will face strict legal action.

DISCLAIMER

# ORAL SURGERY

## P.O.W.E.R NOTES SBQ 35

I. **Shingles** is a viral disease. **Impetigo** is a bacterial disease. **Hyperthermia** is not associated with anaphylaxis. **Cellulitis** is the facial swelling due to spreading infection. **Panic attack** is an autonomic nervous situation that mimic anaphylaxis.

II. Management of anaphylaxis:

- Stop the treatment
- Remove or stop administration of the allergen
- Lie the patient flat
- Give IM injection of adrenalin
- Call 000
- Start supplemental O2 and airway support if needed
- Be prepared to start CPR
- Repeat adrenalin every 5mins until the patient responds or assistance arrives

III. There's no major nerves or blood vessels running in anterolateral thigh region. So, it's safe to give IM injection in this area.

IV. Stridor is the noisy breathing. Which indicates that the patient is struggling to breathe. O2 should be administered. Adrenaline is already given and repeated in every 5mins time.

V. Patient developed anaphylaxis immediately after administering alvogyl. Iodine present in alvogyl is the causative agent.

THIS IS COPYRIGHTED CONTENT. Unauthorized use, including screenshots, copying, misuse, reuse, or resale of any content from this app, is strictly prohibited. Our app monitors and records all screenshots and recordings. Violators will face strict legal action.

### DISCLAIMER

THIS IS COPYRIGHTED CONTENT. Unauthorized use, including screenshots, copying, misuse, reuse, or resale of any content from this app, is strictly prohibited. Our app monitors and records all screenshots and recordings. Violators will face strict legal action.

DISCLAIMER  
THIS IS COPYRIGHTED CONTENT. Unauthorized use, including screenshots, copying, misuse, reuse, or resale of any content from this app, is strictly prohibited. Our app monitors and records all screenshots and recordings. Violators will face strict legal action.

DISCLAIMER  
THIS IS COPYRIGHTED CONTENT. Unauthorized use, including screenshots, copying, misuse, reuse, or resale of any content from this app, is strictly prohibited. Our app monitors and records all screenshots and recordings. Violators will face strict legal action.

# ORAL SURGERY

## SBQ 36

A PT WHO IS MISSING UPPER 5 WANTS TO DO REPLACE IT WITH IMPLANT. HE HAS HYPERTENSION. (130/80 ; 140/90) AND HE IS TAKING ANGIOTENSIN CONVERTING ENZYME INHIBITOR.. ALSO TAKING CLOPIDOGREL. PREVIOUSLY GOT HIS TOOTH EXTRACTED AND HE HAD HX OF BLEEDING.

I. When assessing his risk of bleeding what in the medical hx may increase the risk of bleeding other than clopidogrel:

- A. Concomitant use of ACEI
- B. Hx of bleeding
- C. (his diabetes?)
- D. His blood pressure

II. Which of the below is "THE BEST" artificial sugar substitute?

- A. Sorbitol
- B. Xylitol
- C. Stevia
- D. Sucralose

III. What is the reason that xylitol is not being used widespread

- A. Too expensive
- B. Stomach flatulence
- C. Is contraindicated in Crohn's disease
- D. Inflammatory bowel disease
- E. Gastric ulcer
- F. It has half the calories than sugar

THIS IS COPYRIGHTED CONTENT. Unauthorized use, including screenshots, copying, misuse, reuse, or resale of any content from this app, is strictly prohibited. Our app monitors and records all screenshots and recordings. Violators will face strict legal action.

### DISCLAIMER

THIS IS COPYRIGHTED CONTENT. Unauthorized use, including screenshots, copying, misuse, reuse, or resale of any content from this app, is strictly prohibited. Our app monitors and records all screenshots and recordings. Violators will face strict legal action.

DISCLAIMER  
THIS IS COPYRIGHTED CONTENT. Unauthorized use, including screenshots, copying, misuse, reuse, or resale of any content from this app, is strictly prohibited. Our app monitors and records all screenshots and recordings. Violators will face strict legal action.

# ORAL SURGERY

## P.O.W.E.R NOTES SBQ 36

### I. Patient related factors for increased bleeding: “BOILDSHKAB”

- B- bleeding disorders
- O- old age and frailty
- I- INR unstable
- L- liver disease and unstable INR
- D- drugs that predispose to bleeding including NSAIDs
- S- prior stroke
- H- hypertension
- K- kidney dysfunction
- A- alcohol consumption
- B- hx of bleeding

According to the question, patient's BP is under control. Patient has a hx of bleeding other than clopidogrel.

### II. Stevia, xylitol, sorbitol are natural sugar substitutes. Only sucralose is the artificial sugar substitute among the given.

### III. Xylitol has laxative effect which causes diarrhea. It's not using widespread due to stomach flatulence. It's too expensive too.

THIS IS COPYRIGHTED CONTENT. Unauthorized use, including screenshots, copying, misuse, reuse, or resale of any content from this app, is strictly prohibited. Our app monitors and records all screenshots and recordings. Violators will face strict legal action.

THIS IS COPYRIGHTED CONTENT. Unauthorized use, including screenshots, copying, misuse, reuse, or resale of any content from this app, is strictly prohibited. Our app monitors and records all screenshots and recordings. Violators will face strict legal action.

THIS IS COPYRIGHTED CONTENT. Unauthorized use, including screenshots, copying, misuse, reuse, or resale of any content from this app, is strictly prohibited. Our app monitors and records all screenshots and recordings. Violators will face strict legal action.

#### DISCLAIMER

THIS IS COPYRIGHTED CONTENT. Unauthorized use, including screenshots, copying, misuse, reuse, or resale of any content from this app, is strictly prohibited. Our app monitors and records all screenshots and recordings. Violators will face strict legal action.

DISCLAIMER  
THIS IS COPYRIGHTED CONTENT. Unauthorized use, including screenshots, copying, misuse, reuse, or resale of any content from this app, is strictly prohibited. Our app monitors and records all screenshots and recordings. Violators will face strict legal action.



# ORAL SURGERY

## SBQ 37

MALE PATIENT AROUND 70YRS OLD. PATIENT WAS BREATHING HEAVILY, TELLING HIS CHEST WAS ACHING. PATIENT IN THE DENTAL CHAIR AND STILL WISHES TO GET EXTRACTION DONE BY MENTIONING HE IS FINE.

I. What can be the reason for his recent condition?

- A. Angina
- B. Allergic reaction

II. There was a case on diabetic pt taking sglt-2. Also pt who is taking medication for DM. His doctor recently changed his medication from metformin to sglt 2. What can be the risk factors that u must consider managing this patient.

- A. Diabetic nephropathy
- B. Hypoglycemia

## P.O.W.E.R NOTES SBQ 36

I. Chest pain in an old patient with difficulty in breathing suggestive of a cardiac condition.

II. Patient's taking SGLT2 are at a higher risk of developing diabetic ketoacidosis. Presenting signs would be nausea, stomach pain, abdominal toxicity.

Reference: *TG page 179*

SGLT2 inhibitors have been associated with the development of DKA in patients with type 1 and type 2 diabetes. The risk of DKA is increased in patients taking SGLT2 inhibitors who:

- Have been fasting or having a very restricted dietary intake
- Have undergone a surgical procedure
- Are dehydrated
- Have an active infection

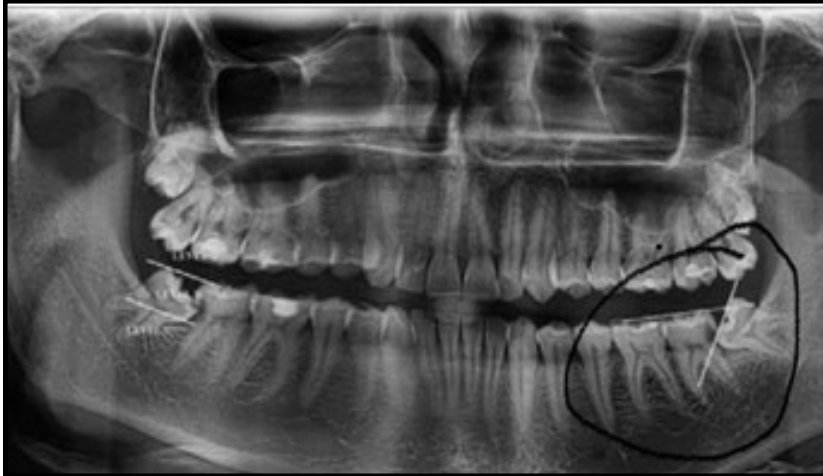SGLT2 inhibitors may need to be stopped before a dental procedure, consult the medical practitioner.

## DISCLAIMER

THIS IS COPYRIGHTED CONTENT. Unauthorized use, including screenshots, copying, misuse, reuse, or resale of any content from this app, is strictly prohibited. Our app monitors and records all screenshots and recordings. Violators will face strict legal action.

DISCLAIMER  
THIS IS COPYRIGHTED CONTENT. Unauthorized use, including screenshots, copying, misuse, reuse, or resale of any content from this app, is strictly prohibited. Our app monitors and records all screenshots and recordings. Violators will face strict legal action.

# ORAL SURGERY

**SBQ 38**
**SIMILAR OPG**


this app, is strictly prohibited.

- I. There OPG gave questions relating to the lower nerve (inferior alveolar nerve) 38 near the IAN and also 48 . The opg both sides u could also see proximity/interruptions nerve canal of the 48 and 38. What factor will determine that you will need to refer this patient to the specialist?
  - A. Proximity of inferior alveolar nerve to 38
  - B. On the right mandibular radiolucency across the mandible
  - C. The position of 38 will complicate the extraction of 37
  - D. The proximity of IAN to the root end of 37
- II. What can you see from the x rays that can determine that patient has bruxism,
  - A. Thin enamel of lower posteriors when compared to other teeth
  - B. Pulp stones
  - C. Lower 3rd molar enamel is normal(no opposing 3rd molar maxilla)

THIS IS COPYRIGHTED CONTENT. Unauthorized use, including screenshots, copying, misuse, reuse, or resale of any content from this app, is strictly prohibited. Our app monitors and records all screenshots and recordings. Violators will face strict legal action.

**DISCLAIMER**

THIS IS COPYRIGHTED CONTENT. Unauthorized use, including screenshots, copying, misuse, reuse, or resale of any content from this app, is strictly prohibited. Our app monitors and records all screenshots and recordings. Violators will face strict legal action.

THIS IS COPYRIGHTED CONTENT. Unauthorized use, including screenshots, copying, misuse, reuse, or resale of any content from this app, is strictly prohibited. Our app monitors and records all screenshots and recordings. Violators will face strict legal action.

**DISCLAIMER**  
THIS IS COPYRIGHTED CONTENT. Unauthorized use, including screenshots, copying, misuse, reuse, or resale of any content from this app, is strictly prohibited. Our app monitors and records all screenshots and recordings. Violators will face strict legal action.

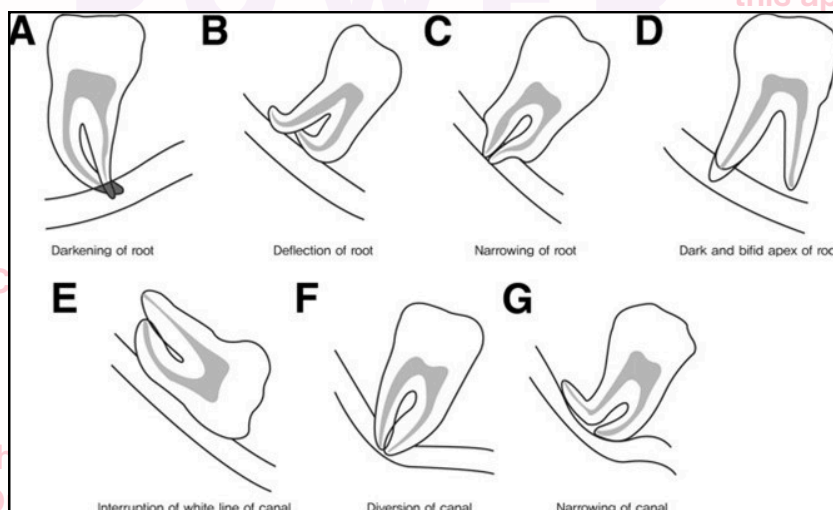
**DISCLAIMER**

THIS IS COPYRIGHTED CONTENT. Unauthorized use, including screenshots, copying, misuse, reuse, or resale of any content from this app, is strictly prohibited. Our app monitors and records all screenshots and recordings. Violators will face strict legal action.

# ORAL SURGERY

## P.O.W.E.R NOTES SBQ 38

- I. According to the OPG the IAN runs closer to the 3rd molar, there's an interruption of the canal.



Radiographic sign	Criteria for positive sign
Diversion of the canal	Change in direction of inferior alveolar canal when it comes on contact with root of third molar
Interruption of white line of canal	Disappearance of one or both cortical white line of inferior alveolar canal
Narrowing of the canal	Reduction in diameter of the inferior alveolar canal when it meets roots of third molar
Darkening of root	Increased radiolucency because of overlapping of the canal and roots of third molar
Deflection of root	Abrupt deviation of third molar roots when it reaches the canal
Narrowing of the root	Abrupt narrowing of the third molar root when it overlaps with the inferior alveolar canal
Dark and bifid apex of the root	Double shadow of periodontal membrane when roots cross the inferior alveolar canal

- II. Masseter hypertrophy can't be seen in x-rays. Attrition is a clinical feature that can be seen due to bruxism. Attrition can be identified in a x-ray due to the presence of the thin enamel.

### DISCLAIMER

THIS IS COPYRIGHTED CONTENT. Unauthorized use, including screenshots, copying, misuse, reuse, or resale of any content from this app, is strictly prohibited. Our app monitors and records all screenshots and recordings. Violators will face strict legal action.

**DISCLAIMER**  
THIS IS COPYRIGHTED CONTENT. Unauthorized use, including screenshots, copying, misuse, reuse, or resale of any content from this app, is strictly prohibited. Our app monitors and records all screenshots and recordings. Violators will face strict legal action.

**DISCLAIMER**

THIS IS COPYRIGHTED CONTENT. Unauthorized use, including screenshots, copying, misuse, reuse, or resale of any content from this app, is strictly prohibited. Our app monitors and records all screenshots and recordings. Violators will face strict legal action.

THIS IS COPYRIGHTED CONTENT. Unauthorized use, including screenshots, copying, misuse, reuse, or resale of any content from this app, is strictly prohibited. Our app monitors and records all screenshots and recordings. Violators will face strict legal action.

THIS IS COPYRIGHTED CONTENT. Unauthorized use, including screenshots, copying, misuse, reuse, or resale of any content from this app, is strictly prohibited. Our app monitors and records all screenshots and recordings. Violators will face strict legal action.

# ORAL SURGERY

## SBQ 39

68 YEAR OLD PATIENT, HAS COME FOR EXTRACTION 26,17 AND 13 GRADE 3 MOBILE .RADIO FINDINGS OF 26 LIKE CURVED ROOT OR HYPERCEMENTOSIS. PATIENT HAS THREE TEETH LEFT IN THE UPPER JAW 26 ,17,13 AND WANTED TO GET THEM EXTRACTED. ALL THESE TEETH WERE GRADE 3 MOBILE ON EXAMINATION. YOU DECIDE TO REMOVE IT BY SURGICAL EXTRACTION. WHILE REMOVING A TOOTH U FRACTURE THE ROOT TIP, PT GETS ANGRY.

I. Question on denosumab. He was about to start denosumab next week. What should you ask before extraction (safest time zone)

- A. When did the dose started
- B. When is the next dose

II. On providing denture for denosumab patient what should you inform the patient to report immediately?

- A. Calculus deposits on dentist
- B. Soreness under denture
- C. Stains in denture

THIS IS COPYRIGHTED CONTENT. Unauthorized use, including screenshots, copying, misuse, reuse, or resale of any content from this app, is strictly prohibited. Our app monitors and records all screenshots and recordings. Violators will face strict legal action.

### DISCLAIMER

THIS IS COPYRIGHTED CONTENT. Unauthorized use, including screenshots, copying, misuse, reuse, or resale of any content from this app, is strictly prohibited. Our app monitors and records all screenshots and recordings. Violators will face strict legal action.

DISCLAIMER  
THIS IS COPYRIGHTED CONTENT. Unauthorized use, including screenshots, copying, misuse, reuse, or resale of any content from this app, is strictly prohibited. Our app monitors and records all screenshots and recordings. Violators will face strict legal action.



# ORAL SURGERY

## P.O.W.E.R NOTES SBQ 39

### I. Reference : TG PG 170

Patient who is on denosumab is associated with any of the risk factors mentioned below is at a high risk of developing MRONJ.

- Immune compromised
- Diabetes
- Anaemia
- Hyperthyroidism
- Renal dialysis
- Glucocorticoid therapy
- Tobacco use
- Periodontal disease
- Denture use
- Local suppuration

Patient is about to start the denosumab in the next week.

Denosumab is a reversible antiresorptive administered every 6 months for osteoporosis. If it's possible to delay a bone invasive dental procedure in a patient taking denosumab for osteoporosis, ideally scheduled the procedure just before the next dose of denosumab. It's never appropriate to interrupt or delay the dose of denosumab. Withdrawal of denosumab has been associated with an increased risk of spontaneous vertebral fractures.

II. Poorly fitting dentures, inflammation/ soreness under the denture puts the patient at a higher risk to develop MRONJ.

THIS IS COPYRIGHTED CONTENT. Unauthorized use, including screenshots, copying, misuse, reuse, or resale of any content from this app, is strictly prohibited. Our app monitors and records all screenshots and recordings. Violators will face strict legal action.

#### DISCLAIMER

THIS IS COPYRIGHTED CONTENT. Unauthorized use, including screenshots, copying, misuse, reuse, or resale of any content from this app, is strictly prohibited. Our app monitors and records all screenshots and recordings. Violators will face strict legal action.

THIS IS COPYRIGHTED CONTENT. Unauthorized use, including screenshots, copying, misuse, reuse, or resale of any content from this app, is strictly prohibited. Our app monitors and records all screenshots and recordings. Violators will face strict legal action.

DISCLAIMER  
THIS IS COPYRIGHTED CONTENT. Unauthorized use, including screenshots, copying, misuse, reuse, or resale of any content from this app, is strictly prohibited. Our app monitors and records all screenshots and recordings. Violators will face strict legal action.

DISCLAIMER

THIS IS COPYRIGHTED CONTENT. Unauthorized use, including screenshots, copying, misuse, reuse, or resale of any content from this app, is strictly prohibited. Our app monitors and records all screenshots and recordings. Violators will face strict legal action.

# ORAL SURGERY

## SBQ 40

**ON PERFORMING EXTRACTION OF THE MAXILLARY FIRST MOLAR YOU FIND BLUE LINING WHICH BLOWS ON EXPIRATION.**

**I. What is the factor which decides which surgeon to refer the patient to an oral surgeon?**

- A. Size of the opening
- B. Ask patient to blow nose with closed nostrils.
- C. Air passes through communication while he breathes.
- D. Surrounding soft tissue available for its closure.

**II. What do you advice the patient for healing?**

- A. Antibiotics
- B. Do not blow the nose
- C. Sneeze with mouth closed
- D. Saltwater rinse after 24 hours

**III. You conclude on doing surgical extraction (buccal bone removal).**

**What is the important aspect of flap design?**

- A. Base wide and narrow apex.
- B. Within the attached gingiva.
- C. Bevelled margins
- D. Use a split thickness flap design.

**IV. Patient was worried about post op complications. What will you advise the patient that is crucial to an uneventful healing?**

- A. Resorbable suture
- B. Blood Clot retention
- C. Warm saline rinses
- D. Antihistamines
- E. Antibiotics

**V. Patient comes with trismus after few days of extraction, what is the cause of this?**

- A. Internal derangement of jaw.
- B. Traumatic extraction

## DISCLAIMER

THIS IS COPYRIGHTED CONTENT. Unauthorized use, including screenshots, copying, misuse, reuse, or resale of any content from this app, is strictly prohibited. Our app monitors and records all screenshots and recordings. Violators will face strict legal action.

**DISCLAIMER**  
THIS IS COPYRIGHTED CONTENT. Unauthorized use, including screenshots, copying, misuse, reuse, or resale of any content from this app, is strictly prohibited. Our app monitors and records all screenshots and recordings. Violators will face strict legal action.

THIS IS COPYRIGHTED CONTENT. Unauthorized use, including screenshots, copying, misuse, reuse, or resale of any content from this app, is strictly prohibited. Our app monitors and records all screenshots and recordings. Violators will face strict legal action.

**DISCLAIMER**

# ORAL SURGERY

## P.O.W.E.R NOTES SBQ 40

- I. Blue lining which blows on expiration is the sinus lining. There's an oroantral communication.

**Oroantral communication (OAC)** is an opening between the oral cavity and the maxillary sinus, often occurring after the extraction of upper posterior teeth. If this communication does not heal properly, it can develop into an **oroantral fistula (OAF)**, a persistent pathological connection.

Epithelial lining is formed in this communication and form the oroantral fistula.

Check for the presence of oroantral communication by holding the patient's nose and getting them to blow, listen for any passage of air or bubbles. If the tooth is intact and the **communication is small** compress the socket and suture closed. Tell the patient to not to blow their nose or create a negative pressure.

**If the communication is large, more than 4mm** or a piece of tooth is missing, promptly refer to an oral and maxillofacial surgeon. A two-layer mucoperiosteal flap with a buccal fat pad graft is useful for large communications.

Size of the opening will decide that it can be done by general dentist or an oral and maxillofacial surgeon.

- II. To keep the integrity of suture and the flap is most important.

**Advice the patient to:**

Don't blow the nose, otherwise the pressure can break the sutures and integrity of the communication. It's the most important thing to do.

Sneeze while the mouth is open, so, the negative pressure will not be created.

Saltwater gargle

Use of antibiotics and anti-inflammatory in case of persistent infection and sinusitis, oroantral fistula formation.

- III. Incision should be made beyond the mucogingival junction to make it movable. Base should be wider, and the apex should be narrower.

- IV. Compression is done to preserve the blood clot. Clot formation is the 1st step of healing.

- V. IM injection during LA can lead to trauma to the muscle which lead to internal bleeding and hematoma formation. This results in trismus. LA should be given within the tissue space, not in the muscle or vessel.

Specialist referral is needed in the presence of trismus after extraction.

### DISCLAIMER

THIS IS COPYRIGHTED CONTENT. Unauthorized use, including screenshots, copying, misuse, reuse, or resale of any content from this app, is strictly prohibited. Our app monitors and records all screenshots and recordings. Violators will face strict legal action.

DISCLAIMER

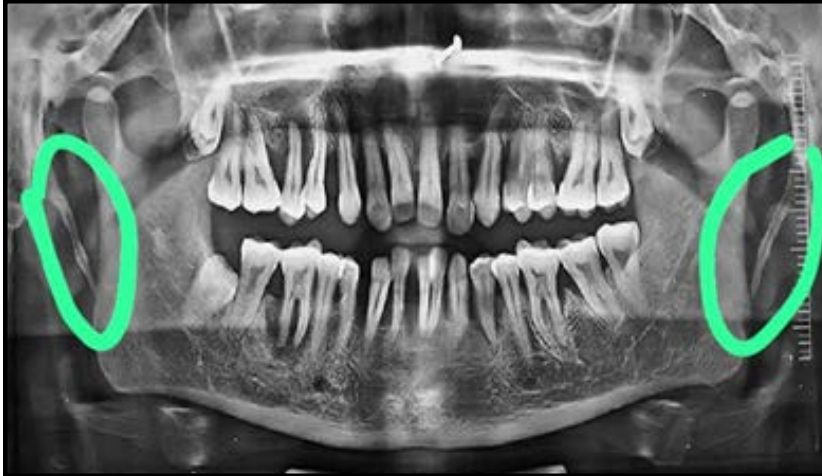THIS IS COPYRIGHTED CONTENT. Unauthorized use, including screenshots, copying, misuse, reuse, or resale of any content from this app, is strictly prohibited. Our app monitors and records all screenshots and recordings. Violators will face strict legal action.

THIS IS COPYRIGHTED CONTENT. Unauthorized use, including screenshots, copying, misuse, reuse, or resale of any content from this app, is strictly prohibited. Our app monitors and records all screenshots and recordings. Violators will face strict legal action.

DISCLAIMER



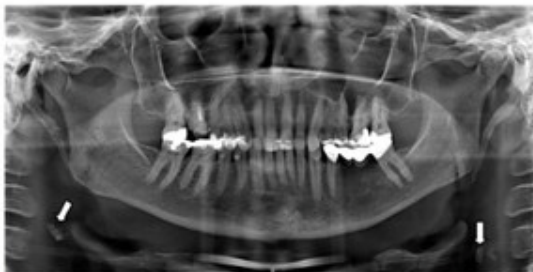# ORAL SURGERY

**SBQ 41**
**SAME OPG**


I. Asked about this calcified ligament which cause her difficult during swallowing

- A. Stylo Cricoid
- B. Stylomandibular
- C. Stylohyoid
- D. 4 stylopharyngeus

II. OPG - you are very concerned about white structure in the opg and you decided to send it to her GP. What condition in the below makes the patient worse if confirmed? There were radiopaque dots near the angle of mandible on both sides and they had encircled that. pt is taking clopidogrel. Calcification on both sides of OPG. Phlebolith, but not in the cervical spine. In relation to her medical condition what makes the condition worst if confirmed.



**Figure 5.**

Digital panoramic radiography with images suggesting the presence of atheroma on both sides.

- A. Stroke
- B. Thyroid goitre
- C. Hypercalcemia
- D. Renal stones

THIS IS COPYRIGHTED CONTENT. Unauthorized use, including screenshots, copying, misuse, reuse, or resale of any content from this app, is strictly prohibited. Our app monitors and records all screenshots and recordings. Violators will face strict legal action.

**DISCLAIMER**  
THIS IS COPYRIGHTED CONTENT. Unauthorized use, including screenshots, copying, misuse, reuse, or resale of any content from this app, is strictly prohibited. Our app monitors and records all screenshots and recordings. Violators will face strict legal action.

**DISCLAIMER**

THIS IS COPYRIGHTED CONTENT. Unauthorized use, including screenshots, copying, misuse, reuse, or resale of any content from this app, is strictly prohibited. Our app monitors and records all screenshots and recordings. Violators will face strict legal action.

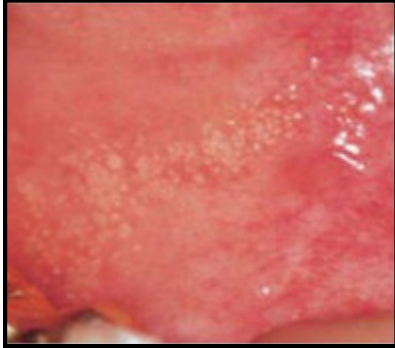
THIS IS COPYRIGHTED CONTENT. Unauthorized use, including screenshots, copying, misuse, reuse, or resale of any content from this app, is strictly prohibited. Our app monitors and records all screenshots and recordings. Violators will face strict legal action.

**DISCLAIMER**



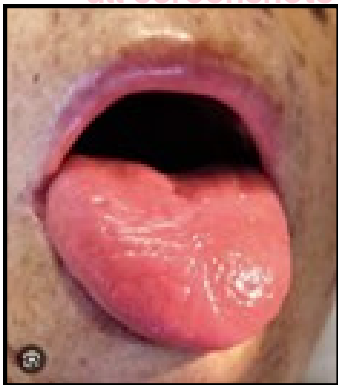
# ORAL SURGERY

## SBQ 41



**III. SAME PHOTO - Question - you have diagnosed this as Fordyce spots. What is management?**

- A. Biopsy
- B. Corticosteroid
- C. NSAID
- D. No treatment



**IV. Patient has burning sensation in the tongue, has been to the doctor and iron levels are normal, beefy tongue appearance. Due to lack of which vitamin tongue becomes atrophic.**

- A. Vit A
- B. Vit K
- C. Vit C
- D. Vit B12

THIS IS COPYRIGHTED CONTENT. Unauthorized use, including screenshots, copying, misuse, reuse, or resale of any content from this app, is strictly prohibited. Our app monitors and records all screenshots and recordings. Violators will face strict legal action.

THIS IS COPYRIGHTED CONTENT. Unauthorized use, including screenshots, copying, misuse, reuse, or resale of any content from this app, is strictly prohibited. Our app monitors and records all screenshots and recordings. Violators will face strict legal action.

**DISCLAIMER**  
THIS IS COPYRIGHTED CONTENT. Unauthorized use, including screenshots, copying, misuse, reuse, or resale of any content from this app, is strictly prohibited. Our app monitors and records all screenshots and recordings. Violators will face strict legal action.

### DISCLAIMER

THIS IS COPYRIGHTED CONTENT. Unauthorized use, including screenshots, copying, misuse, reuse, or resale of any content from this app, is strictly prohibited. Our app monitors and records all screenshots and recordings. Violators will face strict legal action.

# ORAL SURGERY

## P.O.W.E.R NOTES SBQ 41

- I. Bilateral radiopacities behind the ramus are the calcified ligaments. They are stylohyoid ligaments. They run from styloid process to the hyoid bone. Facial pain when turning the head, dysphagia, foreign body sensation, pain on extending tongue, change in voice, sensation of hypersalivation, tinnitus or otalgia can be present and in these cases the term "Eagle syndrome" is used.
- II. There's a calcification close to the vertebra. These are atheroma in the carotid artery. It's a high-risk condition. It can dislodge and can reach the cranial blood vessels and can lead to ischemic stroke.
- III. Fordyce's granules/spots are the ectopic sebaceous glands and they don't require any treatment.
- IV. Beefy red enlarged tongue is associated with vitamin deficiency. Iron and vitamin B12 deficiency are associated with glossitis. In the question it's mentioned that the iron levels are normal.

**Pernicious anaemia, one of the causes of vitamin B12 deficiency, is an autoimmune condition that prevents your body from absorbing vitamin B12. Left untreated, pernicious anaemia can cause serious medical issues, including irreversible damage to your nervous system.**

Pernicious anaemia related enlarged tongue and glossitis is associated with vitamin B12 deficiency.

THIS IS COPYRIGHTED CONTENT. Unauthorized use, including screenshots, copying, misuse, reuse, or resale of any content from this app, is strictly prohibited. Our app monitors and records all screenshots and recordings. Violators will face strict legal action.

### DISCLAIMER

THIS IS COPYRIGHTED CONTENT. Unauthorized use, including screenshots, copying, misuse, reuse, or resale of any content from this app, is strictly prohibited. Our app monitors and records all screenshots and recordings. Violators will face strict legal action.

DISCLAIMER  
THIS IS COPYRIGHTED CONTENT. Unauthorized use, including screenshots, copying, misuse, reuse, or resale of any content from this app, is strictly prohibited. Our app monitors and records all screenshots and recordings. Violators will face strict legal action.

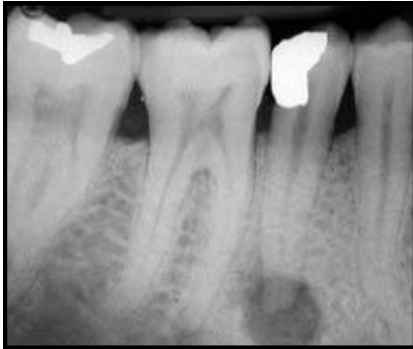DISCLAIMER

THIS IS COPYRIGHTED CONTENT. Unauthorized use, including screenshots, copying, misuse, reuse, or resale of any content from this app, is strictly prohibited. Our app monitors and records all screenshots and recordings. Violators will face strict legal action.

# ORAL SURGERY

## SBQ 42

PATIENT COMES TO YOUR PRACTICE WITH DIFFUSE SWELLING, AND PAIN IN MANDIBULAR POSTERIOR REGION SINCE 3 DAYS. ON RADIOGRAPH YOU FIND SWELLING EXTENDS FROM PREMOLAR REGION TO RAMUS. HE WAS HAVING SPACE INFECTION IRT 38 AND YOU ARE SUSPECTING IT TO BE LUDWIG'S ANGINA.



### I. What is the radiological diagnosis?

- A. Acute periapical rarefying osteitis
- B. Fibrous Healing
- C. Chronic apical periodontitis
- D. Overactive granuloma
- E. Advanced stage of Radicular cyst

### II. How will you confirm its Ludwig's?

- A. Raised temperature
- B. Raised floor of mouth
- C. Tender lymph nodes

### III. What is the antibiotic regime following extraction?

- A. No antibiotics as source of infection removed
- B. Amoxicillin 500mg for 5 days
- C. Amox+clav 875+125 mg for 5 days

THIS IS COPYRIGHTED CONTENT. Unauthorized use, including screenshots, copying, misuse, reuse, or resale of any content from this app, is strictly prohibited. Our app monitors and records all screenshots and recordings. Violators will face strict legal action.

#### DISCLAIMER

THIS IS COPYRIGHTED CONTENT. Unauthorized use, including screenshots, copying, misuse, reuse, or resale of any content from this app, is strictly prohibited. Our app monitors and records all screenshots and recordings. Violators will face strict legal action.

THIS IS COPYRIGHTED CONTENT. Unauthorized use, including screenshots, copying, misuse, reuse, or resale of any content from this app, is strictly prohibited. Our app monitors and records all screenshots and recordings. Violators will face strict legal action.

THIS IS COPYRIGHTED CONTENT. Unauthorized use, including screenshots, copying, misuse, reuse, or resale of any content from this app, is strictly prohibited. Our app monitors and records all screenshots and recordings. Violators will face strict legal action.

**DISCLAIMER**  
THIS IS COPYRIGHTED CONTENT. Unauthorized use, including screenshots, copying, misuse, reuse, or resale of any content from this app, is strictly prohibited. Our app monitors and records all screenshots and recordings. Violators will face strict legal action.

THIS IS COPYRIGHTED CONTENT. Unauthorized use, including screenshots, copying, misuse, reuse, or resale of any content from this app, is strictly prohibited. Our app monitors and records all screenshots and recordings. Violators will face strict legal action.

**DISCLAIMER**

# ORAL SURGERY

## P.O.W.E.R NOTES SBQ 42

I. Granuloma/ abscess/ radicular cyst are **histological diagnosis** which require biopsy.

Among the given acute rarefying osteitis is the **radiological diagnosis**.

There's no draining sinus and it's painful so, option (C) is ruled out.

Space infection is not a radiographic finding and it's a clinical finding.

II. Any infection can cause raised temperature and tender lymph nodes. Raised floor of the mouth will determine that it's Ludwig's angina.

III. Patient requires therapeutic IV dose of AB. Once the patient can swallow you can switch to oral AB.

including screenshots, copying, misuse, reuse, or resale of any content from this app, is strictly prohibited. Our app monitors and records all screenshots and recordings. Violators will face strict legal action.

THIS IS COPYRIGHTED CONTENT. Unauthorized use, including screenshots, copying, misuse, reuse, or resale of any content from this app, is strictly prohibited. Our app monitors and records all screenshots and recordings. Violators will face strict legal action.

THIS IS COPYRIGHTED CONTENT. Unauthorized use, including screenshots, copying, misuse, reuse, or resale of any content from this app, is strictly prohibited. Our app monitors and records all screenshots and recordings. Violators will face strict legal action.

### DISCLAIMER

THIS IS COPYRIGHTED CONTENT. Unauthorized use, including screenshots, copying, misuse, reuse, or resale of any content from this app, is strictly prohibited. Our app monitors and records all screenshots and recordings. Violators will face strict legal action.

DISCLAIMER  
THIS IS COPYRIGHTED CONTENT. Unauthorized use, including screenshots, copying, misuse, reuse, or resale of any content from this app, is strictly prohibited. Our app monitors and records all screenshots and recordings. Violators will face strict legal action.



# ORAL SURGERY

## SBQ 43

**ABORIGINAL PERSON AGE 17, WITH SEVERE PAIN IN HIS BACK TOOTH VISITS UR CLINIC. TOOTH DOESN'T REMEMBER. HE LIVES IN NON-FLUORIDATED AREAS AND REMOTE AREAS AND HAS POOR EATING HABITS. OPG GIVEN AND 38 WAS MESIOANGULAR IMPACTED, ROOTS NOT COMPLETED.**

### **I. Why 3rd molar has to be removed in his case as preventive measure to prevent in opg.crowding was seen?**

- A. 3rd molar can cause crowding in anterior teeth
- B. Position of 38 molar can cause caries on 37 (could see that the 38 was mesioangular and was pressing on the 37 tooth)

### **II. Removal of 3rd molars decision in 17 yr old person? (All for third molars impacted with no root formation. Lower left molar seems to be buccally placed and she has a fixed lingual retainer in lower anterior and all premolars present)**

- A. Monitor until age of 20, as bone grows it'll gain space for eruption
- B. Advise her to extract her 3rd molar as it will impact her ortho treatment.
- C. Wait until adult and extract
- D. Less complicated to extract third molars early
- E. Provide coronectomy

### **III. You see that you can't extract the teeth and you refer to specialist but pt has financial constraints and he wants you to take all the third molars out**

- A. You take out the upper ones and send to specialist for the lower ones
- B. You say that you can't do the extraction
- C. Send to the local hospital so that the patient can get into the waiting list.

THIS IS COPYRIGHTED CONTENT. Unauthorized use, including screenshots, copying, misuse, reuse, or resale of any content from this app, is strictly prohibited. Our app monitors and records all screenshots and recordings. Violators will face strict legal action.

#### DISCLAIMER

THIS IS COPYRIGHTED CONTENT. Unauthorized use, including screenshots, copying, misuse, reuse, or resale of any content from this app, is strictly prohibited. Our app monitors and records all screenshots and recordings. Violators will face strict legal action.

DISCLAIMER  
THIS IS COPYRIGHTED CONTENT. Unauthorized use, including screenshots, copying, misuse, reuse, or resale of any content from this app, is strictly prohibited. Our app monitors and records all screenshots and recordings. Violators will face strict legal action.

DISCLAIMER  
THIS IS COPYRIGHTED CONTENT. Unauthorized use, including screenshots, copying, misuse, reuse, or resale of any content from this app, is strictly prohibited. Our app monitors and records all screenshots and recordings. Violators will face strict legal action.

# ORAL SURGERY

## P.O.W.E.R NOTES SBQ 43

- I.
  - The present study does not provide enough evidence to incriminate 3rd molars as being the only or even major etiological factor in the late lower dental arch crowding.
  - At the same time a cost/benefit analysis should be carried out to justify the prophylactic removal of 3rd molars, which should only be indicated with the purpose of preventing case that involve pathological processes, such as root resorption or caries in second molars, cysts and pericoronitis.
  - Dentists and patients must take into account that surgical complications after 3rd molar removal are common. Severe pain, swelling, bleeding, alveolar osteitis, abscesses, dehiscence, sequestra paraesthesia, hematoma and trismus are the complications that can take place.

Therefore option (B) is better compared to option (A).

- II. As a general rule ages 18-24 is considered ideal for 3rd molar extraction.

### Why age is a consideration in wisdom tooth extraction?

Oral surgeons usually prefer to perform the procedure when about 2/3 of the 3rd molar roots have developed. Most patients reach this stage by age 18yrs, and delaying tooth extraction until then can make for an easy experience. When the tooth roots are fully erupted, 3rd molar removal is more difficult, and patients may have a great risk of complications.

According to new researches as mentioned above, all the 3rd molars don't need to undergo extraction unless they are associated with a pathology. 3rd molar eruption will not impact the ortho treatment. Bone will grow and there may be space for 3rd molars to erupt, therefore, better to monitor. Answer is Option (D).

- III. If all the 3rd molars are erupted, then the answer would be (A). If all the 3rd molars are impacted then the answer would be (C). OPG is required to decide this.

THIS IS COPYRIGHTED CONTENT. Unauthorized use, including screenshots, copying, misuse, reuse, or resale of any content from this app, is strictly prohibited. Our app monitors and records all screenshots and recordings. Violators will face strict legal action.

### DISCLAIMER

THIS IS COPYRIGHTED CONTENT. Unauthorized use, including screenshots, copying, misuse, reuse, or resale of any content from this app, is strictly prohibited. Our app monitors and records all screenshots and recordings. Violators will face strict legal action.

# ORAL SURGERY

## SBQ 44

### ORAL SURGERY

#### I. Patient with liver cirrhosis which L.a can be given?

- A. Mepivacaine
- B. Articaine
- C. Lignocaine
- D. Citanest

#### II. You are injecting block but you're unable to achieve successful anaesthesia.

You also had two positive aspirations and you're worried that the patient has received toxic levels of L.A. The patient feels unwell. how to know systemic toxic dose of anaesthesia what will be early sign of LA toxicity

- A. Excitability
- B. Hyperventilation
- C. Hypotension
- D. Palpitation
- E. 5, wheezing

#### III. What is the best anaesthetic for a "long procedure" to extract 16 with a flap? I don't remember but I think the patient didn't have any systemic problems or allergies.

- A. Articaine with adrenaline
- B. Lidocaine with adrenaline
- C. Prilocaine with felypressin
- D. Mepi with adrenaline

#### IV. First immediate sign of heart attack?

- A. Noisy breathing
- B. Skin pallor
- C. Tingling in tips and lips
- D. Slurred speech

THIS IS COPYRIGHTED CONTENT. Unauthorized use, including screenshots, copying, misuse, reuse, or resale of any content from this app, is strictly prohibited. Our app monitors and records all screenshots and recordings. Violators will face strict legal action.

THIS IS COPYRIGHTED CONTENT. Unauthorized use, including screenshots, copying, misuse, reuse, or resale of any content from this app, is strictly prohibited. Our app monitors and records all screenshots and recordings. Violators will face strict legal action.

THIS IS COPYRIGHTED CONTENT. Unauthorized use, including screenshots, copying, misuse, reuse, or resale of any content from this app, is strictly prohibited. Our app monitors and records all screenshots and recordings. Violators will face strict legal action.

#### DISCLAIMER

THIS IS COPYRIGHTED CONTENT. Unauthorized use, including screenshots, copying, misuse, reuse, or resale of any content from this app, is strictly prohibited. Our app monitors and records all screenshots and recordings. Violators will face strict legal action.

DISCLAIMER  
THIS IS COPYRIGHTED CONTENT. Unauthorized use, including screenshots, copying, misuse, reuse, or resale of any content from this app, is strictly prohibited. Our app monitors and records all screenshots and recordings. Violators will face strict legal action.

# ORAL SURGERY

## P.O.W.E.R NOTES SBQ 44

I. Articaine is the safest LA for patients with liver and kidney disease. Plain mepivacaine, prilocaine with felypressin or maximum of 2 cartridges of lidocaine with adrenaline are the best indications for cardiovascular patients.

II. CNS signs appear 1st before the CVS signs. 1st the excitability (restlessness and anxiety) take place.

**Reference: TG**

the clinical presentation of systemic toxicity is variable and can include neurological, psychiatric, cardiovascular and respiratory effects, allergic reactions and rarely methemoglobinemia. Minor CNS effects (e.g. restlessness, anxiety, tinnitus, dizziness, blurred vision, tremors, CNS depression, drowsiness are early indications of systemic toxicity. However, CVS effects may occur before CNS effects if a long acting LA is used (particularly bupivacaine). Serious systemic effects include seizures and CV toxicity.

Hyperventilation, hypotension, palpitation, wheezing are CVS and respiratory signs.

III. It's a long procedure which requires a flap; therefore, block anaesthesia is required. Articaine is given only as infiltration. So, option (A) is ruled out. Patient doesn't have any allergy or contraindication to lignocaine. So, option (C) is ruled out. Both options (B) and (D) are intermediate LA. Lidocaine is widely used. So, option (B) is selected.

IV. CARDINAL SYMPTOMS OF HEART ATTACK ARE:

- Chest pain
- Pain in the shoulder or back
- Radiating pain or numbness in the arm
- Dyspnea
- Fatigue

THIS IS COPYRIGHTED CONTENT. Unauthorized use, including screenshots, copying, misuse, reuse, or resale of any content from this app, is strictly prohibited. Our app monitors and records all screenshots and recordings. Violators will face strict legal action.

### DISCLAIMER

THIS IS COPYRIGHTED CONTENT. Unauthorized use, including screenshots, copying, misuse, reuse, or resale of any content from this app, is strictly prohibited. Our app monitors and records all screenshots and recordings. Violators will face strict legal action.

THIS IS COPYRIGHTED CONTENT. Unauthorized use, including screenshots, copying, misuse, reuse, or resale of any content from this app, is strictly prohibited. Our app monitors and records all screenshots and recordings. Violators will face strict legal action.

THIS IS COPYRIGHTED CONTENT. Unauthorized use, including screenshots, copying, misuse, reuse, or resale of any content from this app, is strictly prohibited. Our app monitors and records all screenshots and recordings. Violators will face strict legal action.

DISCLAIMER  
THIS IS COPYRIGHTED CONTENT. Unauthorized use, including screenshots, copying, misuse, reuse, or resale of any content from this app, is strictly prohibited. Our app monitors and records all screenshots and recordings. Violators will face strict legal action.



# ORAL SURGERY

## SBQ 45

### FROM INFECTION CONTROL

- I. Hep b. In this scenario pt clearly said to the dentist that he is infected with hep.B 10 months ago and he is homosexual before starting the procedure. So, the DA asks the dentist what preventive measures should we take for handling this pt. So what might have the dentist said to the DA.**
- Use disposable gloves
  - See him as first patient of the day
  - Use 2 cycles for sterilisation
  - Use N95 mask
  - Don't treat the patient and delay the appointment
  - Treat patient with regular sterilisation
- II. Dentist met with an penetrating injury from the forceps with the above mentioned Hep. b pt. After an injury while cleaning immunity level 98mIU/ml. What should the dentist do now?**
- Get a booster dose
  - Immunization again
  - Get the medical advice asap
  - Within 48-72 hrs single human immunoglobulin dose
  - No precaution you are already immunised
- III. Dentist is worried and emotional while explaining this scenario to the patient about a sharp injury and you're uncomfortable regarding blood borne infections. You are contemplating of the recent incident What Should be his next step to manage the patient/ or to avoid this situation in future (two versions)**
- Avoid infected hep B patients in future
  - Refer infected patients to a colleague
  - Undergo a sharps injury refresher training before your next appointment
  - Do palliative care today and ask him to come back for the rest of the treatment later
- IV. How to tell if a person is not immunised, I think the question was more. How to check that the HBv is still and active infection**
- HBS ag
  - Hbs antibody(Hb S)
  - HBC antigen
  - HBC antibody
  - IgM

#### DISCLAIMER

THIS IS COPYRIGHTED CONTENT. Unauthorized use, including screenshots, copying, misuse, reuse, or resale of any content from this app, is strictly prohibited. Our app monitors and records all screenshots and recordings. Violators will face strict legal action.

DISCLAIMER  
THIS IS COPYRIGHTED CONTENT. Unauthorized use, including screenshots, copying, misuse, reuse, or resale of any content from this app, is strictly prohibited. Our app monitors and records all screenshots and recordings. Violators will face strict legal action.

DISCLAIMER  
THIS IS COPYRIGHTED CONTENT. Unauthorized use, including screenshots, copying, misuse, reuse, or resale of any content from this app, is strictly prohibited. Our app monitors and records all screenshots and recordings. Violators will face strict legal action.

# ORAL SURGERY

## P.O.W.E.R NOTES SBQ 45

- I. In case of hepatitis B, standard precautions are taken. Therefore, patients are treated with disposable gloves that's why answer is (A).
- II. Patients antibody levels are sufficient so he doesn't need any booster or immunoglobulins  
But to assess the risk of HIV and hepatitis C, he needs an urgent medical assessment that's why the answer will be (C)
- III. Dentist is worried about the needle injury. So, it's good to proceed ahead with the treatment in the next appointment and do the palliative care today.  
You can avoid this situation by undergoing a training related to sharps before the next appointment.
- IV. Indicator for hepatitis B immunity= hepatitis B antibody  
Indicator for patient is actively infected= hepatitis b antigen (HBe and HBs); when both HBe and HBs are given, HBe is chosen as it is transmissible and actively replicating.

THIS IS COPYRIGHTED CONTENT. Unauthorized use, including screenshots, copying, misuse, reuse, or resale of any content from this app, is strictly prohibited. Our app monitors and records all screenshots and recordings. Violators will face strict legal action.

### DISCLAIMER

THIS IS COPYRIGHTED CONTENT. Unauthorized use, including screenshots, copying, misuse, reuse, or resale of any content from this app, is strictly prohibited. Our app monitors and records all screenshots and recordings. Violators will face strict legal action.

THIS IS COPYRIGHTED CONTENT. Unauthorized use, including screenshots, copying, misuse, reuse, or resale of any content from this app, is strictly prohibited. Our app monitors and records all screenshots and recordings. Violators will face strict legal action.

THIS IS COPYRIGHTED CONTENT. Unauthorized use, including screenshots, copying, misuse, reuse, or resale of any content from this app, is strictly prohibited. Our app monitors and records all screenshots and recordings. Violators will face strict legal action.

THIS IS COPYRIGHTED CONTENT. Unauthorized use, including screenshots, copying, misuse, reuse, or resale of any content from this app, is strictly prohibited. Our app monitors and records all screenshots and recordings. Violators will face strict legal action.

**DISCLAIMER**  
THIS IS COPYRIGHTED CONTENT. Unauthorized use, including screenshots, copying, misuse, reuse, or resale of any content from this app, is strictly prohibited. Our app monitors and records all screenshots and recordings. Violators will face strict legal action.

**DISCLAIMER**

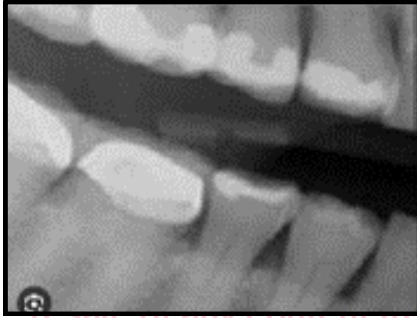
THIS IS COPYRIGHTED CONTENT. Unauthorized use, including screenshots, copying, misuse, reuse, or resale of any content from this app, is strictly prohibited. Our app monitors and records all screenshots and recordings. Violators will face strict legal action.

# ORAL SURGERY

## SBQ 46

### BITEWING ERROR

- I. It showed lower molar mid root on distal side and upper occlusal 1/3rd on mesial side two edges with black area lower root not visible x ray looked angled (a bit vertically sloping downwards distally)



- A. Sensor displaced vertically by tongue
- B. Sensor pushed palatally
- C. Patient gagged while taking
- D. Sensor contacted patient's palate on biting
- E. Patient did not bite the bite block correctly

- II. Patient with gagging, pic of occlusion given roots stumps in front lower enough teeth present upper only three in occlusion need to take posterior and anterior teeth how to take a radiograph

- A. Use extraoral radiograph
- B. Slide the sensor along the palate
- C. Take canine first and molars later
- D. Give him antiemetic and then take radiograph

- III. You manage to take the radiograph of that patient, and then 2 radiographs were given.

THIS IS COPYRIGHTED CONTENT. Unauthorized use, including screenshots, copying, misuse, reuse, or resale of any content from this app, is strictly prohibited. Our app monitors and records all screenshots and recordings. Violators will face strict legal action.

#### DISCLAIMER

THIS IS COPYRIGHTED CONTENT. Unauthorized use, including screenshots, copying, misuse, reuse, or resale of any content from this app, is strictly prohibited. Our app monitors and records all screenshots and recordings. Violators will face strict legal action.

THIS IS COPYRIGHTED CONTENT. Unauthorized use, including screenshots, copying, misuse, reuse, or resale of any content from this app, is strictly prohibited. Our app monitors and records all screenshots and recordings. Violators will face strict legal action.

**DISCLAIMER**  
THIS IS COPYRIGHTED CONTENT. Unauthorized use, including screenshots, copying, misuse, reuse, or resale of any content from this app, is strictly prohibited. Our app monitors and records all screenshots and recordings. Violators will face strict legal action.

THIS IS COPYRIGHTED CONTENT. Unauthorized use, including screenshots, copying, misuse, reuse, or resale of any content from this app, is strictly prohibited. Our app monitors and records all screenshots and recordings. Violators will face strict legal action.

# ORAL SURGERY

## P.O.W.E.R NOTES SBQ 46

- I. Patient has not been bitten on the bite block completely, so, there's a gap between the upper and the lower teeth and the upper teeth are not visible completely.
- II. When the patient has gag reflex you should not start with the pharmacological management 1st.  
Gag reflex can be controlled by smaller exposures such as managing the anterior 1st and posteriors later.  
Extra oral radiographs are not clear enough and there's too much of exposure to radiation.

THIS IS COPYRIGHTED CONTENT. Unauthorized use, including screenshots, copying, misuse, reuse, or resale of any content from this app, is strictly prohibited. Our app monitors and records all screenshots and recordings. Violators will face strict legal action.

THIS IS COPYRIGHTED CONTENT. Unauthorized use, including screenshots, copying, misuse, reuse, or resale of any content from this app, is strictly prohibited. Our app monitors and records all screenshots and recordings. Violators will face strict legal action.

THIS IS COPYRIGHTED CONTENT. Unauthorized use, including screenshots, copying, misuse, reuse, or resale of any content from this app, is strictly prohibited. Our app monitors and records all screenshots and recordings. Violators will face strict legal action.

### DISCLAIMER

THIS IS COPYRIGHTED CONTENT. Unauthorized use, including screenshots, copying, misuse, reuse, or resale of any content from this app, is strictly prohibited. Our app monitors and records all screenshots and recordings. Violators will face strict legal action.

DISCLAIMER  
THIS IS COPYRIGHTED CONTENT. Unauthorized use, including screenshots, copying, misuse, reuse, or resale of any content from this app, is strictly prohibited. Our app monitors and records all screenshots and recordings. Violators will face strict legal action.

DISCLAIMER

THIS IS COPYRIGHTED CONTENT. Unauthorized use, including screenshots, copying, misuse, reuse, or resale of any content from this app, is strictly prohibited. Our app monitors and records all screenshots and recordings. Violators will face strict legal action.



# ORAL SURGERY

## SBQ 47

CHILD WITH UNERUPTED PREMOLAR AND FACIAL SWELLING CASE. NO OBVIOUS CARIES OR TRAUMA HAS FACIAL SWELLING AND BUCCAL SINUS AND THEY ARE GOING OVERSEAS IN ONE WEEK, X-RAY GIVEN 12YR OLD OPEN APEX. THERE WAS NO PAIN IN PAST AND NOT NOW. MOTHER WAS WORRIED WHY THIS IS HAPPENING. SWELLING WAS HARD AND FIRM.

### I. What will you tell her that is likely diagnosis?

- A. Systemic condition
- B. Cellulitis
- C. Abscess
- D. Induration
- E. It's unusual to have a radiolucency for a vital tooth.

### II. What will be the immediate management?

- A. Extraction
- B. Pulp debridement
- C. Analgesics only
- D. Drainage and antibiotic

### III. What will be the final management?

- A. Extraction
- B. Refer to endo
- C. Refer to oral surgeon
- D. Close the apex with mta and do the rct
- E. Close the apex with caoh and do the rct

THIS IS COPYRIGHTED CONTENT. Unauthorized use, including screenshots, copying, misuse, reuse, or resale of any content from this app, is strictly prohibited. Our app monitors and records all screenshots and recordings. Violators will face strict legal action.

#### DISCLAIMER

THIS IS COPYRIGHTED CONTENT. Unauthorized use, including screenshots, copying, misuse, reuse, or resale of any content from this app, is strictly prohibited. Our app monitors and records all screenshots and recordings. Violators will face strict legal action.

DISCLAIMER  
THIS IS COPYRIGHTED CONTENT. Unauthorized use, including screenshots, copying, misuse, reuse, or resale of any content from this app, is strictly prohibited. Our app monitors and records all screenshots and recordings. Violators will face strict legal action.

THIS IS COPYRIGHTED CONTENT. Unauthorized use, including screenshots, copying, misuse, reuse, or resale of any content from this app, is strictly prohibited. Our app monitors and records all screenshots and recordings. Violators will face strict legal action.

# ORAL SURGERY

## P.O.W.E.R NOTES SBQ 47

In the main question it's given as "It's an **unerupted** premolar associated with radiolucency". But we are answering the below questions by thinking it's an **erupted tooth**. Because the given answers are not matching if the tooth is unerupted.

If it's an **unerupted premolar associated with radiolucency, it can't be associated with systemic disease. The likely diagnosis can be dentigerous cyst.**

If it's an **erupted premolar associated with radiolucency, then it can be associated with Langerhans cell histiocytosis.**

- I. Usually swelling associated with an odontogenic infection and draining sinus will not be hard and firm. The likely diagnosis is; It's unusual to have a radiolucency in a vital tooth. (no caries / no trauma)
- II. There's big radiolucency associated with the premolar. Sometimes may not be able to save the tooth. But it may require pulp debridement and take some of the exudate out. Since it has open apex, apexification may require.
- III. We are referring the patient to the oral surgeon as there's no odontogenic cause associated with the swelling, whether the tooth is erupted or un erupted.

# ORAL SURGERY

## SBQ 48

LADY IN HER 50S CAME TO YOUR CLINIC AND REPORTED THAT SHE HAD INJURED HER UPPER FRONT TWO TEETH. (11,21) 3 DAYS AGO WHILE SHE WAS CLEANING HER HOME. ON EXAMINATION YOU FOUND THAT HER TOOTH 21 IS GRADE 1 MOBILE AND HAD 1 MM GINGIVAL RECESSION ON CERVICAL REGION OF THE TOOTH AND YOU ASK HER WHETHER SHE KNEW ABOUT IT, PATIENT SAYS SHE KNEW ABOUT GUM LOOKING LIKE THIS SINCE 1 YEAR BUT SHE'S NOT BOTHERED ABOUT IT

I. You did a vitality test of the teeth and found no response. What is the reason for no response?

- A. Recent trauma renders temporary loss of sensations
- B. You decide to do splinting
- C. Nylon splint for 2 weeks

II. One case with an X-ray after trauma but you are not satisfied with the X-ray. Pt came after trauma happened 2 days ago while cleaning the house. Just a little loose.

III. What X-ray will give you the most info lopa given very light, 11 was crown fracture, 21 was fractured on root horizontal fracture?

- A. lopa in different angulation
- B. Occlusal
- C. Cbct
- D. Mri

IV. What is the most appropriate specialist to refer?

- A. Endo
- B. Perio
- C. Oral surgeon
- D. Orthodontist

V. The patient has come after 2 weeks for splint removal. What will you check in the X-ray on that appointment?

- A. Vitality of tooth
- B. Signs of inflammatory root resorption
- C. Ankylosis
- D. Revascularisation

VI. What is the diagnosis of 11?

- A. Complicated Crown fracture on 11
- B. Luxation on 11
- C. Uncomplicated crown fracture
- D. Crown and root fracture irt 11

VII. What is the diagnosis of 21?

- A. Horizontal root fracture.

## DISCLAIMER

THIS IS COPYRIGHTED CONTENT. Unauthorized use, including screenshots, copying, misuse, reuse, or resale of any content from this app, is strictly prohibited. Our app monitors and records all screenshots and recordings. Violators will face strict legal action.

DISCLAIMER

THIS IS COPYRIGHTED CONTENT. Unauthorized use, including screenshots, copying, misuse, reuse, or resale of any content from this app, is strictly prohibited. Our app monitors and records all screenshots and recordings. Violators will face strict legal action.

THIS IS COPYRIGHTED CONTENT. Unauthorized use, including screenshots, copying, misuse, reuse, or resale of any content from this app, is strictly prohibited. Our app monitors and records all screenshots and recordings. Violators will face strict legal action.

DISCLAIMER

# ORAL SURGERY

## P.O.W.E.R NOTES SBQ 48

- I. There's a temporary loss of sensation. The main factors that interfere with the effectiveness of sensibility tests in newly traumatized teeth are subjectivity of the patient's response, alteration of the pain threshold, changes in the supporting dental tissues, and especially transient paraesthesia, which may persist up to 6 months after the traumatic injury.
- II. IOPA in different angle would be helpful to identify root fracture.
- III. There's a horizontal root fracture. So, need to check whether both fragments have vitality or not. Sometimes you might have to do the RCT till the fracture line. Therefore, need to refer to the endodontist.
- IV. All the clinical and radiographical evaluation is done in each appointment according to the trauma guideline. Vitality can't be checked with the help of the x-ray. Option (A) is ruled out. In 2 weeks', time ankylosis will not take place. Option (C) is ruled out. Revascularisation will not show with a x-ray. Signs of root resorption may appear in 2 weeks' time.
- V. Given history is not enough to mark whether it's complicated/ uncomplicated crown #. Therefore, answer can be (A) or (C).
- VI. In the question it's clearly given that there's a horizontal root # involving 21.

THIS IS COPYRIGHTED CONTENT. Unauthorized use, including screenshots, copying, misuse, reuse, or resale of any content from this app, is strictly prohibited. Our app monitors and records all screenshots and recordings. Violators will face strict legal action.

### DISCLAIMER

THIS IS COPYRIGHTED CONTENT. Unauthorized use, including screenshots, copying, misuse, reuse, or resale of any content from this app, is strictly prohibited. Our app monitors and records all screenshots and recordings. Violators will face strict legal action.

THIS IS COPYRIGHTED CONTENT. Unauthorized use, including screenshots, copying, misuse, reuse, or resale of any content from this app, is strictly prohibited. Our app monitors and records all screenshots and recordings. Violators will face strict legal action.

DISCLAIMER  
THIS IS COPYRIGHTED CONTENT. Unauthorized use, including screenshots, copying, misuse, reuse, or resale of any content from this app, is strictly prohibited. Our app monitors and records all screenshots and recordings. Violators will face strict legal action.

DISCLAIMER

THIS IS COPYRIGHTED CONTENT. Unauthorized use, including screenshots, copying, misuse, reuse, or resale of any content from this app, is strictly prohibited. Our app monitors and records all screenshots and recordings. Violators will face strict legal action.



# ORAL SURGERY

## SBQ 49

### AIRWAY OBSTRUCTION

**I. You were doing prophylaxis and the prophy cup came off and fell (across the back of the patient's tongue) What is the next step to take?**

- A. Call an ambulance
- B. Give abdominal thrust
- C. Put into recovery position
- D. Give up to 5 back blows
- E. Cricothyrotomy

**II. Emergency number in Australia?**

- A. 000, 999
- B. 000, 112
- C. 000, 911
- D. 911, 112

THIS IS COPYRIGHTED CONTENT. Unauthorized use, including screenshots, copying, misuse, reuse, or resale of any content from this app, is strictly prohibited. Our app monitors and records all screenshots and recordings. Violators will face strict legal action.

**DISCLAIMER**  
THIS IS COPYRIGHTED CONTENT. Unauthorized use, including screenshots, copying, misuse, reuse, or resale of any content from this app, is strictly prohibited. Our app monitors and records all screenshots and recordings. Violators will face strict legal action.

THIS IS COPYRIGHTED CONTENT. Unauthorized use, including screenshots, copying, misuse, reuse, or resale of any content from this app, is strictly prohibited. Our app monitors and records all screenshots and recordings. Violators will face strict legal action.

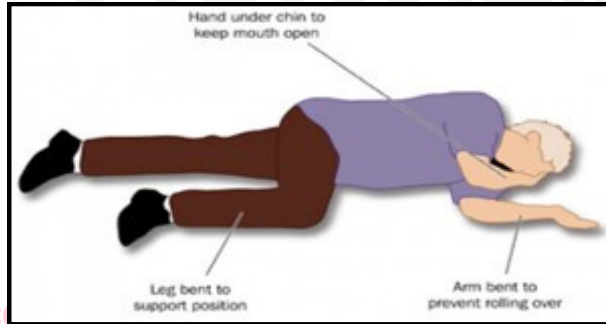
#### DISCLAIMER

THIS IS COPYRIGHTED CONTENT. Unauthorized use, including screenshots, copying, misuse, reuse, or resale of any content from this app, is strictly prohibited. Our app monitors and records all screenshots and recordings. Violators will face strict legal action.

# ORAL SURGERY

## P.O.W.E.R NOTES SBQ 48

I. According to TG, it's not the recovery position, it should be upright position. So, option (C) is ruled out. Below image demonstrates the recovery position.



### Box 48. Management of an inhaled or swallowed object [NB1]

In the event that an object appears to have fallen down the oropharynx:

- Stop dental treatment.
- Check whether the object is present in the patient's mouth or clothes and, if so, remove it.
- If the object is not found, put the patient into an upright position.
- Although the majority of ingested foreign bodies will pass through the gastrointestinal tract without incident, refer the patient for further medical assessment and management. If the patient is stable and asymptomatic, it may be appropriate to complete dental treatment before doing so.

If the patient is conscious with signs of airway obstruction (see Table 26; p.257):

- Call 000.
- Reassure the patient and encourage them to relax, breathe deeply and try to dislodge the object by coughing.
- If coughing is ineffective, give up to 5 back blows between the shoulder blades using the heel of the hand (checking for effectiveness between each blow).
- If back blows are unsuccessful, give up to 5 chest thrusts delivered at the same compression point as for CPR (checking for effectiveness between each chest thrust).
- Continue to alternate between back blows and chest thrusts until the obstruction is relieved or assistance arrives.

If the patient with airway obstruction becomes unconscious:

- Call 000.
- Inspect the back of the throat for the foreign object and remove it if possible.
- Start CPR (for 'Basic life support flow chart', see Figure 8; p.235).
- Clinicians with appropriate expertise and equipment should consider performing cricothyroidotomy.
- Abdominal thrusts, such as those described in the Heimlich manoeuvre, can cause internal organ damage so are not recommended.

CPR = cardiopulmonary resuscitation

NB1: A flow chart for the management of choking can be downloaded from the Australian Resuscitation Council website <[resus.org.au/guidelines/flowcharts-3/](http://resus.org.au/guidelines/flowcharts-3/)>.

emergencies in dental

Back blows, chest thrusts and cricothyroidotomy are done after calling 000.

II. 000 is Australia's main emergency service number. You should call 000 if you need urgent help from police, fire or ambulance services. Telstra answers calls to the emergency service numbers 000 and 112 and transfers the call, and information about your location, to the emergency service you request.

### DISCLAIMER

THIS IS COPYRIGHTED CONTENT. Unauthorized use, including screenshots, copying, misuse, reuse, or resale of any content from this app, is strictly prohibited. Our app monitors and records all screenshots and recordings. Violators will face strict legal action.

THIS IS COPYRIGHTED CONTENT. Unauthorized use, including screenshots, copying, misuse, reuse, or resale of any content from this app, is strictly prohibited. Our app monitors and records all screenshots and recordings. Violators will face strict legal action.

DISCLAIMER  
THIS IS COPYRIGHTED CONTENT. Unauthorized use, including screenshots, copying, misuse, reuse, or resale of any content from this app, is strictly prohibited. Our app monitors and records all screenshots and recordings. Violators will face strict legal action.

THIS IS COPYRIGHTED CONTENT. Unauthorized use, including screenshots, copying, misuse, reuse, or resale of any content from this app, is strictly prohibited. Our app monitors and records all screenshots and recordings. Violators will face strict legal action.

THIS IS COPYRIGHTED CONTENT. Unauthorized use, including screenshots, copying, misuse, reuse, or resale of any content from this app, is strictly prohibited. Our app monitors and records all screenshots and recordings. Violators will face strict legal action.

# ORAL SURGERY

## SBQ 50

### ICG NEW QUESTIONS

**I. How much time does ADA guidelines recommend that you should have your blood tested after a sharp incident with a needle?**

- A. Within 24 hours
- B. One week
- C. Two weeks
- D. 4-6 weeks

**II. Where should the sharps bin be located?**

- A. In the sterilization room
- B. Near to the point of use
- C. Above/near the hand washing sink
- D. In overhead cupboard
- E. Above/near the dustbin

**III. How will you discard needle and syringe after use to avoid sharp injury**

- A. Hold the syringe assembly with one hand and close the syringe with the other hand
- B. Hold the syringe assembly with a hand and close the syringe cap with same hand
- C. Leave the syringe assembly on the bracket table and cover the needle with a gauze
- D. Hold the syringe in one hand and Remove with a needle holder with other hand
- E. Keep the syringe with a needle in a contaminated area on the bench top

**IV. According to spaulding classification ,which is the semi critical item**

- A. Mouth Mirror
- B. Stainless steel matrix band
- C. Shade guide
- D. Extraction forceps
- E. Eye wear

THIS IS COPYRIGHTED CONTENT. Unauthorized use, including screenshots, copying, misuse, reuse, or resale of any content from this app, is strictly prohibited. Our app monitors and records all screenshots and recordings. Violators will face strict legal action.

**DISCLAIMER**  
THIS IS COPYRIGHTED CONTENT. Unauthorized use, including screenshots, copying, misuse, reuse, or resale of any content from this app, is strictly prohibited. Our app monitors and records all screenshots and recordings. Violators will face strict legal action.

THIS IS COPYRIGHTED CONTENT. Unauthorized use, including screenshots, copying, misuse, reuse, or resale of any content from this app, is strictly prohibited. Our app monitors and records all screenshots and recordings. Violators will face strict legal action.

#### DISCLAIMER

THIS IS COPYRIGHTED CONTENT. Unauthorized use, including screenshots, copying, misuse, reuse, or resale of any content from this app, is strictly prohibited. Our app monitors and records all screenshots and recordings. Violators will face strict legal action.



# ORAL SURGERY

## P.O.W.E.R NOTES SBQ 50

- I. The test should be completed as soon as possible after the injury (ideally same day and definitely within 24hrs) bearing in mind the window period of the tests.
- II. Sharp bin should be wall mounted. It should never be in overhead cupboard. It should never be near the hand washing sink.

Reference: ICG

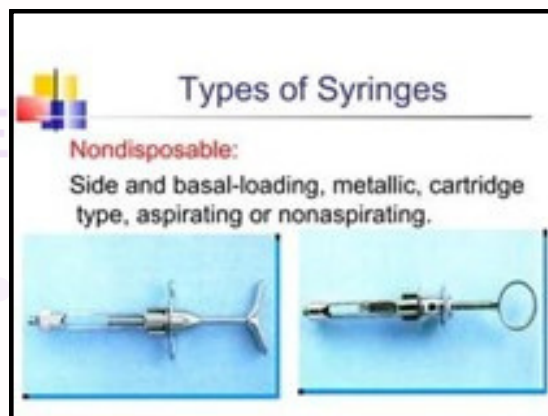
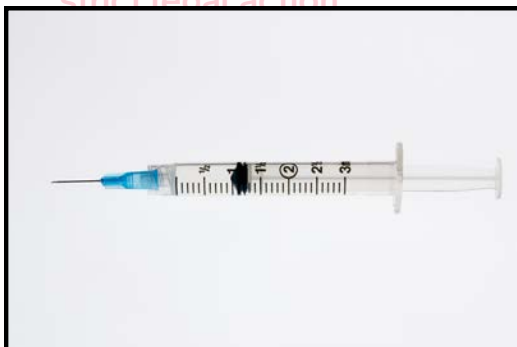Disposal of sharps is always best done at the point of use (i.e. into a sharp bin located in the operatory or treatment room).

It should be wall mounted at the height of 1100-1300mm from the floor to enable access from the sitting position, or a minimum of 1300mm if access is required from the standing position, so as to allow staff to be able to see into the opening of the container.

III. Reference: ICG

Needles must not be re-sheathed unless using an approved recapping device or single-handed technique. Contaminated needles must never be bent or broken by hand or removed from disposable syringe.

In the question if it's asked how to discard "needle" so, the answer would be (D).



IV. Stainless steel matrix band is a single use item which is discarded after use.

Shade guide and eye wear are non-critical instruments.

Extraction forceps is a critical instrument.

Mouth mirror is a semi critical instrument.

## DISCLAIMER

THIS IS COPYRIGHTED CONTENT. Unauthorized use, including screenshots, copying, misuse, reuse, or resale of any content from this app, is strictly prohibited. Our app monitors and records all screenshots and recordings. Violators will face strict legal action.

DISCLAIMER

THIS IS COPYRIGHTED CONTENT. Unauthorized use, including screenshots, copying, misuse, reuse, or resale of any content from this app, is strictly prohibited. Our app monitors and records all screenshots and recordings. Violators will face strict legal action.

THIS IS COPYRIGHTED CONTENT. Unauthorized use, including screenshots, copying, misuse, reuse, or resale of any content from this app, is strictly prohibited. Our app monitors and records all screenshots and recordings. Violators will face strict legal action.

DISCLAIMER

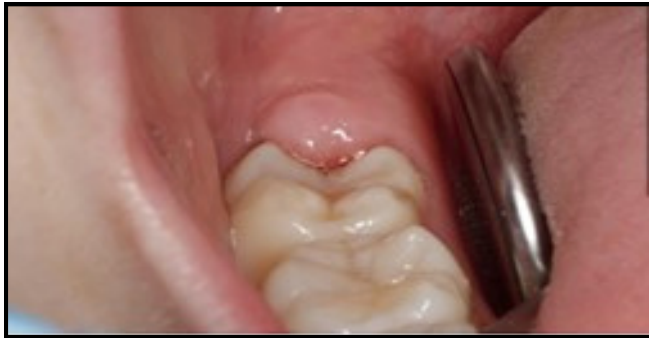

# ORAL SURGERY

## SBQ 51

### PERICORONITIS

A TEENAGE GIRL COMES TO YOU WITH A COMPLAINT OF A REPEAT EPISODE OF PERICORONITIS. IOPA WAS GIVEN ,A QUESTION WAS ASKED REGARDING THE 3RD MOLAR (CLINICAL PICTURE WAS GIVEN IN SOME CENTERS) . IT WAS IMPACTED AGAINST THE SECOND MOLAR WITH SWOLLEN OPERCULUM IN RESPECT TO 48 AND THE SAME APPEARANCE ON THE 3RD QUADRANT AS WELL.



I. Which investigation will you perform 1st?

- A. Bitewing
- B. IOPA
- C. Opg
- D. Cbct
- E. MRI

II. It will be 2 weeks till you extract so What will you do for her interim pain relief? ( in the main question it was mentioned something she is having bad/severe pain)The patient is not going to be able to come for the extractions until 2 weeks

- A. Salt water gargle
- B. Chlorhexidine mouthwash
- C. Ibuprofen
- D. Operculectomy
- E. Debridement and irritation with 1% peroxide
- F. Povidone iodine

III. What will be the most difficult factor faced during the extraction of the third molar?

- A. IAN is just touching the roots of tooth
- B. There is interruption in the continuity of the lamina dura of the IAN
- C. There is darkening of roots of tooth
- D. There is narrowing of the bony wall of the canal

### DISCLAIMER

THIS IS COPYRIGHTED CONTENT. Unauthorized use, including screenshots, copying, misuse, reuse, or resale of any content from this app, is strictly prohibited. Our app monitors and records all screenshots and recordings. Violators will face strict legal action.

### DISCLAIMER

THIS IS COPYRIGHTED CONTENT. Unauthorized use, including screenshots, copying, misuse, reuse, or resale of any content from this app, is strictly prohibited. Our app monitors and records all screenshots and recordings. Violators will face strict legal action.

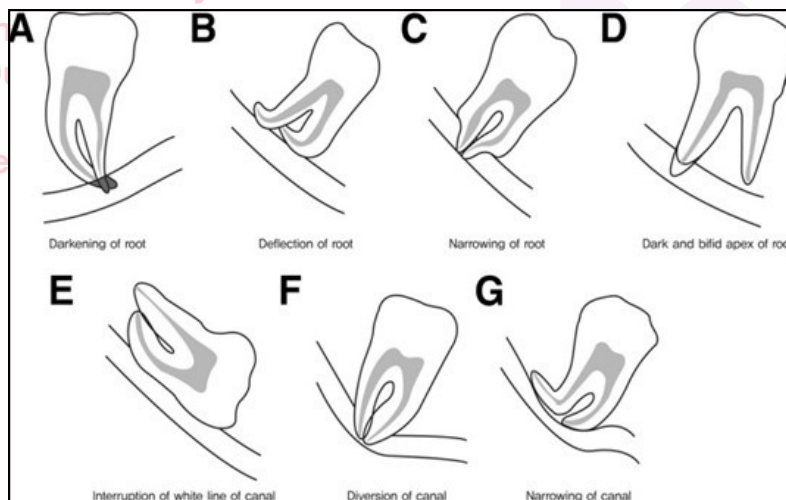
THIS IS COPYRIGHTED CONTENT. Unauthorized use, including screenshots, copying, misuse, reuse, or resale of any content from this app, is strictly prohibited. Our app monitors and records all screenshots and recordings. Violators will face strict legal action.

### DISCLAIMER

# ORAL SURGERY

## P.O.W.E.R NOTES SBQ 51

- I. Repeated episodes of pericoronitis in related to 3rd molar requires extraction. OPG is the gold standard investigation which is required in surgical removal of 3rd molar tooth. CBCT is only require din complicated extractions and that would be recommended by the oral and maxillofacial surgeon and not by the general dentist. The most common sign of a close relationship between 3d molar and mandibular canal have been consistently reported as the interruption of the white line followed by darkening of the roots.
- II. Hydrogen peroxide is the best management for pericoronitis in this situation as per ADC Sample Paper File answers.
- III. The most difficult factor will be narrowing of the canal followed by interruption and darkening of the roots.



THIS IS COPYRIGHTED CONTENT. Unauthorized use, including screenshots, copying, misuse, reuse, or resale of any content from this app, is strictly prohibited. Our app monitors and records all screenshots and recordings. Violators will face strict legal action.

### DISCLAIMER

THIS IS COPYRIGHTED CONTENT. Unauthorized use, including screenshots, copying, misuse, reuse, or resale of any content from this app, is strictly prohibited. Our app monitors and records all screenshots and recordings. Violators will face strict legal action.

DISCLAIMER  
THIS IS COPYRIGHTED CONTENT. Unauthorized use, including screenshots, copying, misuse, reuse, or resale of any content from this app, is strictly prohibited. Our app monitors and records all screenshots and recordings. Violators will face strict legal action.

DISCLAIMER

THIS IS COPYRIGHTED CONTENT. Unauthorized use, including screenshots, copying, misuse, reuse, or resale of any content from this app, is strictly prohibited. Our app monitors and records all screenshots and recordings. Violators will face strict legal action.

# ORAL SURGERY

## SBQ 52

### ON IV BISPHOSPHONATES

MISS RUTHERFORD CAME TO YOUR CLINIC, HER GENERAL PHYSICIAN IS SOON GOING TO START IV BISPHOSPHONATES ON COMING FRIDAY. ON OPG, 36 IS RCT TREATED WHICH IS INCOMPLETE, MESIAL ROOT APPEARED BULBOUS, INFECTION IS PRESENT AT PERIAPICAL AREA. OTHER TEETH SEEMS TO HAVE NO PROBLEMS SHE CAME TO YOU FOR AN OVERALL DENTAL CHECK UP BEFORE SHE STARTS HER IV BISPHOSPHONATE THERAPY.

**I. What is the best advice you would include in the management before she goes for her next dose?**

- A. Switch to oral from IV bisphosphonates
- B. Stop the iv bisphosphonates
- C. Drug holiday
- D. Continue taking the same regime.
- E. Do only restorative work, tell GP to continue with treatment.
- F. Delay the bisphosphonate therapy for one week.

**II. From the x-ray, what local factor is going to make the extraction most difficult for you? (all this factors are seen in X-ray)**

- A. Hypercementosis of ML root of 36
- B. Brittleness of RCT treated 36
- C. Close proximity of ML root of 35
- D. Change in the density of the bone.

**III. Regarding the consent of extraction of 36. What is the most important factor to be considered for extraction?**

- A. Make sure patients understands the whole procedure
- B. Give patient the brochure to read
- C. Important to sign the written consent
- D. It's legal procedure
- E. You explain details of steps of the procedure to the patient.

THIS IS COPYRIGHTED CONTENT. Unauthorized use, including screenshots, copying, misuse, reuse, or resale of any content from this app, is strictly prohibited. Our app monitors and records all screenshots and recordings. Violators will face strict legal action.

#### DISCLAIMER

THIS IS COPYRIGHTED CONTENT. Unauthorized use, including screenshots, copying, misuse, reuse, or resale of any content from this app, is strictly prohibited. Our app monitors and records all screenshots and recordings. Violators will face strict legal action.

**DISCLAIMER**  
THIS IS COPYRIGHTED CONTENT. Unauthorized use, including screenshots, copying, misuse, reuse, or resale of any content from this app, is strictly prohibited. Our app monitors and records all screenshots and recordings. Violators will face strict legal action.

THIS IS COPYRIGHTED CONTENT. Unauthorized use, including screenshots, copying, misuse, reuse, or resale of any content from this app, is strictly prohibited. Our app monitors and records all screenshots and recordings. Violators will face strict legal action.

**DISCLAIMER**

# ORAL SURGERY

## P.O.W.E.R NOTES SBQ 52

- I. There's an underlying infection in relation to 36 which requires extraction. Patient is going to receive IV bisphosphonates.

According to the flow chart given in TG, this patient is at a lower risk. If the tooth has an abscess, then the patient is at a higher risk.

According to TG it's advised to extract just before starting bisphosphonate treatment or immediately after bisphosphonate treatment.

As per ADC release sample papers, ADC has advised to delay the biphosphate therapy. In case you are performing extractions or a questionable tooth is being treated where extraction is likely that is why in this case also as an extraction may be required to delay, the biphosphate therapy for a week would be the best advice. Of course it would be given by the physician, but recommending it and talking to GP about it can make sense and can prevent the risk of MRONJ

### Reference: TG

- If possible, any necessary dental treatment should be completed before or shortly after starting antiresorptive therapy for osteoporosis (e.g. within 6 months) the risk of MRONJ of the jaw in patients with osteoporosis remain low in the early stage of the treatment.
- It's never appropriate to interrupt or delay the dose of denosumab; withdrawal of denosumab has been associated with an increased risk of spontaneous vertebral fractures.
- There is no evidence that drug holidays reduce the risk of MRONJ.

- II. In case of brittleness of RCT, we can split the tooth and manage.  
In case of hypercementosis, lot of bone must be sacrificed. More complicated procedure.

- III. You can explain all the steps to the patient, but the informed consent can be taken only if the patient understands the procedure well. If the patient doesn't have the mental capacity to understand there's no point in explaining all the steps to that patient.

THIS IS COPYRIGHTED CONTENT. Unauthorized use, including screenshots, copying, misuse, reuse, or resale of any content from this app, is strictly prohibited. Our app monitors and records all screenshots and recordings. Violators will face strict legal action.

### DISCLAIMER

THIS IS COPYRIGHTED CONTENT. Unauthorized use, including screenshots, copying, misuse, reuse, or resale of any content from this app, is strictly prohibited. Our app monitors and records all screenshots and recordings. Violators will face strict legal action.

DISCLAIMER  
THIS IS COPYRIGHTED CONTENT. Unauthorized use, including screenshots, copying, misuse, reuse, or resale of any content from this app, is strictly prohibited. Our app monitors and records all screenshots and recordings. Violators will face strict legal action.

DISCLAIMER  
THIS IS COPYRIGHTED CONTENT. Unauthorized use, including screenshots, copying, misuse, reuse, or resale of any content from this app, is strictly prohibited. Our app monitors and records all screenshots and recordings. Violators will face strict legal action.



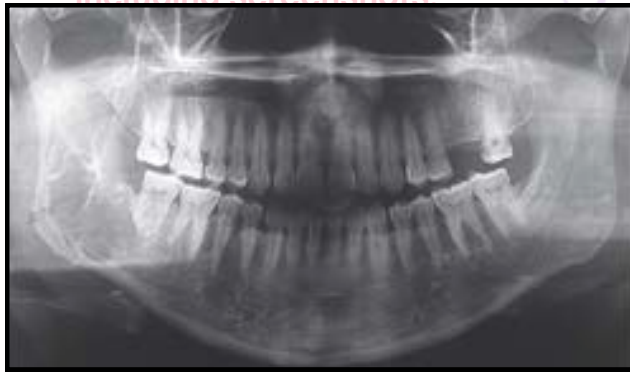# ORAL SURGERY

## SBQ 53

### JAW LESION

OPG GIVEN. MULTIOCLULAR RADIOCUCENCY EXTENDING TO THE RAMUS AND 48 WAS CLOSE TO THE LESION BUT NOT FROM THE CEJ OF THE 48. (48 - ROOTS WERE NOT FORMED AND WERE LYING CLOSE TO THE LOWER BORDER OF MANDIBLE 47 SHOWING SOME ROOT RESORPTION. THE PATIENT FELT DISCOMFORT BEFORE BUT NOW IT HAS BEEN ACHING FOR A FEW DAYS. (PIC 1 - LOOK AT POSITION OF 47 - IN EXAM 47 WAS DISPLACED OCCLUSALLY SLIGHT AS COMPARED TO PLANE OF 46 AND ALSO ROOT RESORPTION WAS SEEN WITH BOTH 47 AND 46)

RADIOCUCENT LESION WAS LIKE ONE SHOWN IN THIS PIC AND 3RD MOLAR WAS PLACED MORE TOWARDS LOWER BORDER OF MANDIBLE)



I. What is the lesion on the right side which has 3rd molar impacted, multilocular radiolucency?

- A. Metastatic tumor
- B. Radicular cyst
- C. Odontogenic keratocystic tumor
- D. Hemangioma
- E. Myxoma

II. What is the complication caused by the lesion with respect to 47?

OR

(What could be complicating adjacent teeth due to radiolucency)

- A. Root resorption on 47
- B. Distal pocket formation with 47
- C. Displacement of 47

III. What is the most conservative treatment for this lesion?

- A. Extraction of 48 and enucleation
- B. Resection
- C. Cryosurgery
- D. Enucleation

### DISCLAIMER

THIS IS COPYRIGHTED CONTENT. Unauthorized use, including screenshots, copying, misuse, reuse, or resale of any content from this app, is strictly prohibited. Our app monitors and records all screenshots and recordings. Violators will face strict legal action.

DISCLAIMER

THIS IS COPYRIGHTED CONTENT. Unauthorized use, including screenshots, copying, misuse, reuse, or resale of any content from this app, is strictly prohibited. Our app monitors and records all screenshots and recordings. Violators will face strict legal action.

THIS IS COPYRIGHTED CONTENT. Unauthorized use, including screenshots, copying, misuse, reuse, or resale of any content from this app, is strictly prohibited. Our app monitors and records all screenshots and recordings. Violators will face strict legal action.

DISCLAIMER

# ORAL SURGERY

## P.O.W.E.R NOTES SBQ 53

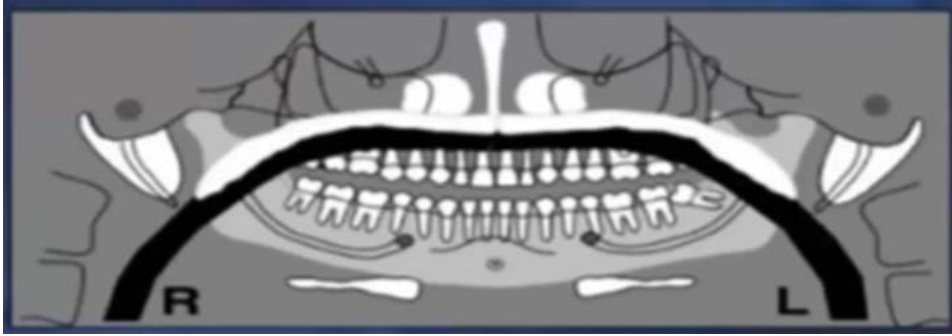- I.
  - **Metastatic lesions** don't have multilocular radiolucency. They are presented with diffuse radiolucency in the mandible. But not associated with impacted teeth.
  - **Radicular cyst** is associated in the periapical area of the infected root.
  - **OKC** is seen as a multilocular radiolucency associated with impacted teeth.
  - **Hemangioma** is not associated with impacted teeth.
  - **Myxoma** is not associated with impacted teeth.
- II. There are 2 variants of this question.  
 If it's asked what the complication is caused by the lesion; then the answer would be **root resorption**.  
 If it's asked what could be the complicating the adjacent teeth; then the answer would be **displacement of 47**, as root resorption is already mentioned in the question.
- III. Cystic lesion doesn't require resection. Resection is a tumour related procedure. Resection is done in ameloblastoma.  
 For OKC extraction along with enucleation is required. Enucleation alone is not adequate. OKC has the highest recurrence rate among all the cysts.

# ORAL SURGERY

## SBQ 54

### OPG ERROR

OPG GIVEN IN WHICH THERE WAS A RADIOLOUCENT BAND OVER THE APICAL PART OF THE ROOTS OF UPPER ANTERIOR TEETH. WHAT WILL YOU TELL THE PATIENT TO PREVENT THIS?



resale of any content from this app, is strictly prohibited.

- A. Ask the patient to keep the tongue still
- B. Ask the patient to keep the tongue in contact with the palate
- C. Place the chin downwards

### P.O.W.E.R NOTES SBQ 54

Palatoglossal space is appearing as the radiolucent band in this OPG. It's a radiographic error. We can prevent it by asking the patient to keep the tongue in contact with the palate.

THIS IS COPYRIGHTED CONTENT. Unauthorized use, including screenshots, copying, misuse, reuse, or resale of any content from this app, is strictly prohibited. Our app monitors and records all screenshots and recordings. Violators will face strict legal action.

### DISCLAIMER

THIS IS COPYRIGHTED CONTENT. Unauthorized use, including screenshots, copying, misuse, reuse, or resale of any content from this app, is strictly prohibited. Our app monitors and records all screenshots and recordings. Violators will face strict legal action.

THIS IS COPYRIGHTED CONTENT. Unauthorized use, including screenshots, copying, misuse, reuse, or resale of any content from this app, is strictly prohibited. Our app monitors and records all screenshots and recordings. Violators will face strict legal action.

**DISCLAIMER**  
THIS IS COPYRIGHTED CONTENT. Unauthorized use, including screenshots, copying, misuse, reuse, or resale of any content from this app, is strictly prohibited. Our app monitors and records all screenshots and recordings. Violators will face strict legal action.

including screenshots, copying, misuse, reuse, or resale of any content from this app, is strictly prohibited. Our app monitors and records all screenshots and recordings. Violators will face strict legal action.

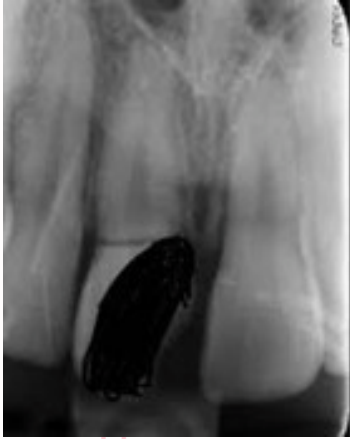# ORAL SURGERY

## SBQ 55

### DISABILITY/ SCHIZOPHRENIA SBQ

A SCHIZOPHRENIC PATIENT STAYING AT A DISABILITY CARE HOME, VISITS YOUR DENTAL OFFICE WITH HIS WIFE. WIFE SAYS SHE IS ALSO GETTING OLD AND NOT ABLE TO VISIT HIM EVERYDAY.

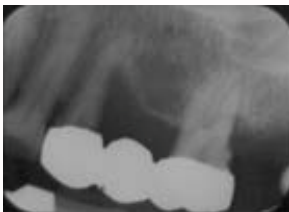PHOTO SHOWING BROKEN INCISORS (ONLY MESIO- LABIAL PORTION REMAINS). OTHER OPTION: ONLY THE ROOT WAS VISIBLE IN THE IOPA.



**I. What is your immediate concern as a dentist? It was asking about restorability of the tooth?**

- A. Tooth mobility
- B. Pulp status
- C. Patient preference
- D. Restorability of the tooth

**II. Same patient came to his dentist with discomfort in the posterior back region./ IOPA showing tooth supported 5 unit bridge 26 with root canal treatment and bone loss around 26, upon examination you felt the issue is with the bridge. 25 is missing, 26 is tilted and bone loss, gap between 25 (pontic) and underlying ridge (more 3-4 mm bone loss, with 6 bone loss was almost close to apex). What investigation will you do to address the issue?**



- A. Mobility test
- B. Perio probing
- C. Pulp sensitivity
- D. Percussion
- E. Probe margins of the crown

**III. Cantilever bridge in mandibular teeth, 34 35 (abutments) 33 was cantilever pontic. IOPA showing a diffuse radiopaque band along the coronal third of abutment teeth. What is the most likely reason for this?**

- A. Bad oral hygiene
- B. History of Bone disease
- C. Heavy bruxer

### DISCLAIMER

THIS IS COPYRIGHTED CONTENT. Unauthorized use, including screenshots, copying, misuse, reuse, or resale of any content from this app, is strictly prohibited. Our app monitors and records all screenshots and recordings. Violators will face strict legal action.

### DISCLAIMER

THIS IS COPYRIGHTED CONTENT. Unauthorized use, including screenshots, copying, misuse, reuse, or resale of any content from this app, is strictly prohibited. Our app monitors and records all screenshots and recordings. Violators will face strict legal action.

THIS IS COPYRIGHTED CONTENT. Unauthorized use, including screenshots, copying, misuse, reuse, or resale of any content from this app, is strictly prohibited. Our app monitors and records all screenshots and recordings. Violators will face strict legal action.



# ORAL SURGERY

## P.O.W.E.R NOTES SBQ 55

- I. The main concern is the restorability. Whether there's enough tooth structure is left for restoring. Doesn't matter whether the tooth is vital or non-vital as if it's non vital we can perform RCT and preserve the tooth. But if there's not enough tooth structure then tooth may require extraction.
- II. RCT teeth with extreme bone loss and discomfort indicates of a failure of the bridge.

**Pulp sensibility tests** are not useful in RCT teeth.

**Periodontal probing** Will be most helpful test right now. To assess surrounding bone and attachment loss around abutment teeth for possible cause of discomfort

Bridge is a unit which is connected and splinted. So, the mobility test won't be helpful to identify whether the abutment tooth is mobile or connector/ pontic is mobile.

- III. Radiopaque band along the coronal 3rd of the abutment teeth may be due to exostosis. Heavy bruxism can be the aetiology for it. It requires only cosmetic management.

THIS IS COPYRIGHTED  
CONTENT. Unauthorized use,  
including screenshots,  
copying, misuse, reuse, or  
resale of any content from  
this app, is strictly prohibited.  
Our app monitors and records  
all screenshots and  
recordings. Violators will face  
strict legal action.

### DISCLAIMER

THIS IS COPYRIGHTED CONTENT. Unauthorized use, including screenshots, copying, misuse, reuse, or resale of any content from this app, is strictly prohibited. Our app monitors and records all screenshots and recordings. Violators will face strict legal action.

THIS IS COPYRIGHTED  
CONTENT. Unauthorized use,  
including screenshots,  
copying, misuse, reuse, or  
resale of any content from  
this app, is strictly prohibited.  
Our app monitors and records  
all screenshots and  
recordings. Violators will face  
strict legal action.

DISCLAIMER  
THIS IS COPYRIGHTED CONTENT. Unauthorized use, including screenshots, copying, misuse, reuse, or resale of any content from this app, is strictly prohibited. Our app monitors and records all screenshots and recordings. Violators will face strict legal action.

# ORAL SURGERY

## SBQ 56

### NEW ICG - BBV - HEP B

**YOU ARE TREATING A PATIENT WHO RECENTLY GOT HEPATITIS B INFECTION 9 MONTHS BACK AND IS STILL ACTIVE**

**I. Which other vaccination should all your dental staff be up to date with, along with Hep B**

- A. Viral influenza
- B. Tetanus
- C. Hepatitis A
- D. Tuberculosis

**II. Extraction was required. How will you proceed to treat the patient, while protecting your staff and other patients from getting infected?**

- A. N 95 mask
- B. Wear disposable gloves
- C. Last patient of day
- D. Double clean the surfaces of the operatory

**III. The treating dentist has an antibody (HbSAb) level of 98 IU/ml. What does the injured dentist do next?**

- A. Get medical assessment from infectious disease physician
- B. Get a booster vaccine.
- C. Give a single dose of immunoglobulin.
- D. Start new course of vaccination within 7 days

THIS IS COPYRIGHTED  
CONTENT. Unauthorized use,  
including screenshots,  
copying, misuse, reuse, or  
resale of any content from  
this app, is strictly prohibited.  
Our app monitors and records  
all screenshots and  
recordings. Violators will face  
strict legal action.

#### DISCLAIMER

THIS IS COPYRIGHTED CONTENT. Unauthorized use, including screenshots, copying, misuse, reuse, or resale of any content from this app, is strictly prohibited. Our app monitors and records all screenshots and recordings. Violators will face strict legal action.

THIS IS COPYRIGHTED  
CONTENT. Unauthorized use,  
including screenshots,  
copying, misuse, reuse, or  
resale of any content from  
this app, is strictly prohibited.  
Our app monitors and records  
all screenshots and  
recordings. Violators will face  
strict legal action.

**DISCLAIMER**  
THIS IS COPYRIGHTED CONTENT. Unauthorized use, including screenshots, copying, misuse, reuse, or resale of any content from this app, is strictly prohibited. Our app monitors and records all screenshots and recordings. Violators will face strict legal action.

THIS IS COPYRIGHTED  
CONTENT. Unauthorized use,  
including screenshots,  
copying, misuse, reuse, or  
resale of any content from  
this app, is strictly prohibited.  
Our app monitors and records  
all screenshots and  
recordings. Violators will face  
strict legal action.

# ORAL SURGERY

## P.O.W.E.R NOTES SBQ 56

- I. Hep A and tuberculosis are optional and they are for the doctors who work in high risk areas / indigenous communities. Staff need to be up to date with viral influenza every year.

Reference: ICG

All dental practitioners and clinical support staff are to be advised to the need to have particular immunisations. The list of immunisations required for HCWs is provided in the current edition of the Australian Immunisation Handbook and is summarised below.

- A history of successful immunisation against HBV. This is shown by having developed antibodies to Hep B surface antigen in a blood test taken after a initial course of 3 injections.
- Varicella (if seronegative)
- Measles, mumps and rubella (MMR) (if non immune)
- Pertussis (whooping cough)
- Viral influenza (required every year to cover new circulating strains of these viruses).

Those work with the remote indigenous communities are advised to also undergo vaccination for Hep A, while those at a high risk of exposure to drug resistant cases of tuberculosis should also undergo vaccination with bacilli Calmette Guerin (BCG) after being tested for their immune response to tuberculosis using an appropriate challenge test.

- II. The answer is Option (B)

Wear disposable gloves, because, hepatitis B patients require only standard precautions and no special or transmission based precautions

- III. The answer is Option (A) because his antibody levels are 98, which are more than 10 so he is immune, so he does not require any booster dose or any immunoglobulins but he does require medical assessment from infectious disease physician to get the risk assessed for HIV and Hepatitis C.

### DISCLAIMER

THIS IS COPYRIGHTED CONTENT. Unauthorized use, including screenshots, copying, misuse, reuse, or resale of any content from this app, is strictly prohibited. Our app monitors and records all screenshots and recordings. Violators will face strict legal action.

# ORAL SURGERY

## SBQ 57

**MRS. MARY IS A 50-YEAR-OLD WOMAN WHO OWNS A FLOWER BUSINESS.**

MRS. MARY HAS BEEN ON SYSTEMIC CORTICOSTEROIDS IN THE LAST 6 MONTHS FOR HER MEDICAL CONDITIONS OF HAY FEVER AND ASTHMA RELATED TO HER PROFESSION. SHE PRESENTED TO YOUR PRACTICE WITH A FRACTURED TOOTH 37, WHICH WAS PREVIOUSLY RESTORED MANY TIMES WITH COMPOSITE. AS THE PATIENT WANTED THE TOOTH TO GO, HER TREATING DOCTOR ADVISED THE NECESSITY TO INCREASE THE CURRENT DOSE OF CORTICOSTEROID MEDICATION.

I. As per the guidelines, when is the recommended time to increase the dose?

- A. The night before the treatment
- B. The night before and the morning of the treatment
- C. Only on the morning of the treatment
- D. Usually on the morning of the treatment

### P.O.W.E.R NOTES SBQ 57

I. **Reference: TG page 164**

The increased dose is usually started on the morning of the procedure.



# ORAL SURGERY

## SBQ 58

WHILE TREATING A PATIENT, IAN BLOCK IS GIVEN FOR ENDO ACCESS OPENING. THE TECHNIQUE USED FOR LA WAS CORRECT AND SOFT TISSUE IS ALREADY NUMB, YET THE PATIENT HAS PAIN FROM THE TOOTH WHILE PREPARING THE ACCESS CAVITY. HOW WILL YOU RE-INFORCE/ COMPLIMENT THE BLOCK ALREADY GIVEN?

- A. Give buccal infiltration at apex of 46 and distal to 46
- B. Give intraligamental
- C. Repeat IAN at higher level
- D. Give la at distal part and at the level of root (same as option A)

## P.O.W.E.R NOTES SBQ 58

- I. The technique was good enough. According to the Walton it's given that the failure rate of the mandibular nerve block is due to the anatomical variation in the mandibular canal. Buccal infiltration would fail due to the pH of the tissue/inflammation. Best supplemental anaesthesia is the intraligamental.

# ORAL SURGERY

## SBQ 59

**IN A DENTAL CLINIC, WHAT CAN MOST LIKELY CAUSE A PATIENT TO LOSE CONSCIOUSNESS SUDDENLY?**

- A. Vasovagal response
- B. Angina
- C. Cardiac arrest
- D. Anaphylactic shock

## P.O.W.E.R NOTES SBQ 59

- I. **Syncope/ vasovagal response** is the most likely cause a patient loses consciousness. In the dental office, **fear and anxiety** are common causes of syncope. **Neurally mediated syncope (NMS)** is the most common form of fainting and a frequent reason for emergency department visits.

resale of any content from this app, is strictly prohibited. Our app monitors and records all screenshots and recordings. Violators will face strict legal action.

THIS IS COPYRIGHTED CONTENT. Unauthorized use, including screenshots, copying, misuse, reuse, or resale of any content from this app, is strictly prohibited. Our app monitors and records all screenshots and recordings. Violators will face strict legal action.

THIS IS COPYRIGHTED CONTENT. Unauthorized use, including screenshots, copying, misuse, reuse, or resale of any content from this app, is strictly prohibited. Our app monitors and records all screenshots and recordings. Violators will face strict legal action.

## DISCLAIMER

THIS IS COPYRIGHTED CONTENT. Unauthorized use, including screenshots, copying, misuse, reuse, or resale of any content from this app, is strictly prohibited. Our app monitors and records all screenshots and recordings. Violators will face strict legal action.

THIS IS COPYRIGHTED CONTENT. Unauthorized use, including screenshots, copying, misuse, reuse, or resale of any content from this app, is strictly prohibited. Our app monitors and records all screenshots and recordings. Violators will face strict legal action.

DISCLAIMER

DISCLAIMER

THIS IS COPYRIGHTED CONTENT. Unauthorized use, including screenshots, copying, misuse, reuse, or resale of any content from this app, is strictly prohibited. Our app monitors and records all screenshots and recordings. Violators will face strict legal action.

# ORAL SURGERY

## SBQ 60

PATIENT CAME FOR EXTRACTION. HE HAS A HISTORY OF CEREBRAL PALSY. HE IS TAKING CLOPIDOGREL AND A FEW OTHER MEDICINES. HOW WILL YOU MANAGE THIS PATIENT (NO OPTION OF REFERRAL)

- A. Stop medication 2 days before the treatment
- B. No change
- C. Double the dose
- D. Proceed with the treatment

## P.O.W.E.R NOTES SBQ 60

- I. There's no patient related factors and no procedure related risk factors. And patient is not taking anticoagulant. Patient takes only one antiplatelet (clopidogrel). So, we can proceed with the treatment without altering the drug. We don't usually alter or stop the drug and it's done by the medical officer.

Patient related factors for increased bleeding: "BOLD SHKAB"

- B- bleeding disorders
- O- old age and frailty
- L- liver disease and unstable INR
- D- drugs that predispose to bleeding including NSAIDs
- S- prior stroke
- H- hypertension
- K- kidney dysfunction
- A- alcohol consumption
- B- hx of bleeding

Cerebral palsy is a group of conditions that affect movement and posture. It's caused by damage that occurs to the developing brain, most often before birth. Symptoms appear during infancy or preschool years and vary from very mild to serious. Children with cerebral palsy may have exaggerated reflexes.

THIS IS COPYRIGHTED CONTENT. Unauthorized use, including screenshots, copying, misuse, reuse, or resale of any content from this app, is strictly prohibited. Our app monitors and records all screenshots and recordings. Violators will face strict legal action.

## DISCLAIMER

THIS IS COPYRIGHTED CONTENT. Unauthorized use, including screenshots, copying, misuse, reuse, or resale of any content from this app, is strictly prohibited. Our app monitors and records all screenshots and recordings. Violators will face strict legal action.

DISCLAIMER

THIS IS COPYRIGHTED CONTENT. Unauthorized use, including screenshots, copying, misuse, reuse, or resale of any content from this app, is strictly prohibited. Our app monitors and records all screenshots and recordings. Violators will face strict legal action.

THIS IS COPYRIGHTED CONTENT. Unauthorized use, including screenshots, copying, misuse, reuse, or resale of any content from this app, is strictly prohibited. Our app monitors and records all screenshots and recordings. Violators will face strict legal action.

DISCLAIMER

# ORAL SURGERY

## SBQ 61

### QUESTIONS ABOUT TOOTH MOVEMENT

#### I. The movement of extraction for 16

- A. Buccal palatal movement towards buccal
- B. Buccal palatal movement towards palatal
- C. Figure of 8 and pulling out
- D. Rotational

#### II. The movement of extraction for 47

- A. movement towards buccal (bucco-lingual towards buccal)
- B. movement towards lingual (bucco-lingual towards lingual)
- C. figure of 8 and pulling out
- D. rotational

#### III. The position for extraction of 16 for a right handed operator

- A. in front of the patient, on the right side
- B. in front of the patient, on the left side
- C. behind the patient on right side
- D. behind the patient on left side

#### IV. The position of extraction of 47, (if you are left handed)

- A. in front of the patient, on the right side
- B. in front of the patient, on the left side
- C. behind the patient on right side
- D. behind the patient on left side

#### V. If you are left hand operator where will you stand to extract 37

- A. in front of the patient, on the right side
- B. in front of the patient, on the left side
- C. behind the patient on right side
- D. behind the patient on left side

#### VI. Movement of forceps for 35 extraction

- A. Rotational
- B. Buccal
- C. Lingual
- D. Apical

#### VI. For a left handed operator you have to left max molar 27 on standing not remember which tooth

- A. in front of the pt on left side
- B. in front of the pt on right side
- C. behind the pt on right side
- D. behind the pt on right side

THIS IS COPYRIGHTED CONTENT. Unauthorized use, including screenshots, copying, misuse, reuse, or resale of any content from this app, is strictly prohibited. Our app monitors and records all screenshots and recordings. Violators will face strict legal action.

**DISCLAIMER**  
THIS IS COPYRIGHTED CONTENT. Unauthorized use, including screenshots, copying, misuse, reuse, or resale of any content from this app, is strictly prohibited. Our app monitors and records all screenshots and recordings. Violators will face strict legal action.

## DISCLAIMER

THIS IS COPYRIGHTED CONTENT. Unauthorized use, including screenshots, copying, misuse, reuse, or resale of any content from this app, is strictly prohibited. Our app monitors and records all screenshots and recordings. Violators will face strict legal action.



# ORAL SURGERY

## P.O.W.E.R NOTES SBQ 61

### Chair – Dentist Position During Extraction

#### B- Dentist position:

##### 1 For maxillary teeth:

For all maxillary teeth (left & right) the dentist should stand in front of the patient and to the right side during the extraction.

##### 2 For mandibular teeth:

For left quadrant, the dentist should stand in front of the patient to the right side.

For right quadrant, the dentist should stand behind the patient in the right side.

#### Note:

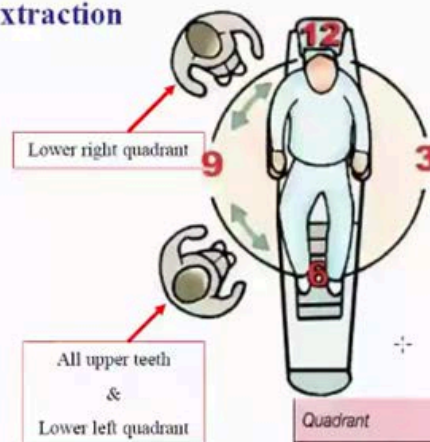
1 These positions are for a standing, right handed dentist, while for seated position or left handed dentist modifications required.

2 During extraction the left hand plays an important role in

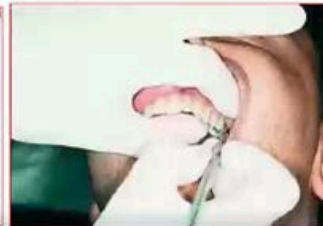
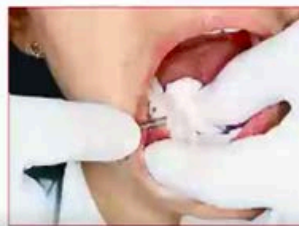A- Providing support and stability for the alveolar process and the jaw.

B- Provide tactile information to the surgeon regarding the progress of extraction.

C- Reflection of the soft tissues like lip, cheek, or tongue.



Quadrant	Operator
Upper right and upper left	In front
Lower left	In front
Lower right	Behind



Role of the left hand during the extraction

### Specific Technique For Removal of Each Tooth

#### Extraction of Maxillary Central Incisors

##### Instruments:

Extraction forceps for six anterior maxillary teeth.

##### Position:

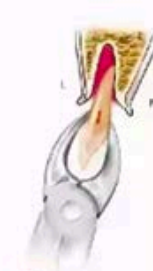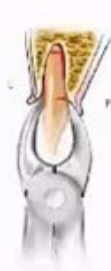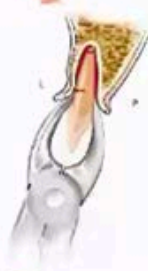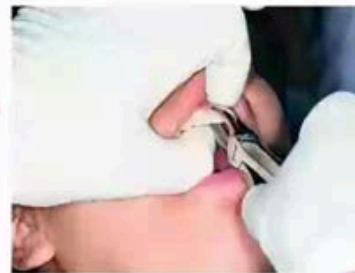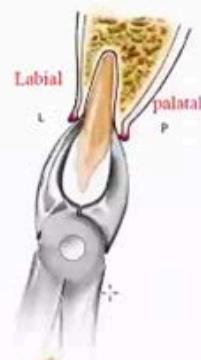The dentist should stand in front of and to the right of the patient (right handed).

##### Support:

By the index and the thumb finger.

##### Technique:

The initial movements are in a labial direction, and then palatal. Since the root is conical in shape, rotational forces are applied and the final extraction force is applied labially.



5

Buccal force

Palatal force

Tractional force

strict legal action.

#### DISCLAIMER

THIS IS COPYRIGHTED CONTENT. Unauthorized use, including screenshots, copying, misuse, reuse, or resale of any content from this app, is strictly prohibited. Our app monitors and records all screenshots and recordings. Violators will face strict legal action.

DISCLAIMER  
THIS IS COPYRIGHTED CONTENT. Unauthorized use, including screenshots, copying, misuse, reuse, or resale of any content from this app, is strictly prohibited. Our app monitors and records all screenshots and recordings. Violators will face strict legal action.

THIS IS COPYRIGHTED CONTENT. Unauthorized use, including screenshots, copying, misuse, reuse, or resale of any content from this app, is strictly prohibited. Our app monitors and records all screenshots and recordings. Violators will face strict legal action.

# ORAL SURGERY

## P.O.W.E.R NOTES SBQ 61

### Specific Technique For Removal of Each Tooth

#### Extraction of Maxillary Central Incisors

##### Instruments:

Extraction forceps for six anterior maxillary teeth.

##### Position:

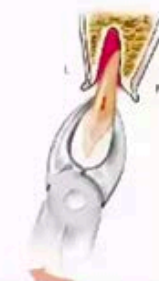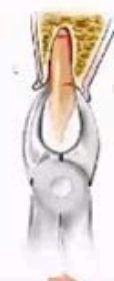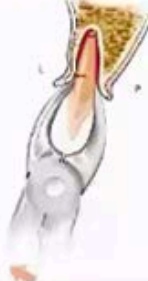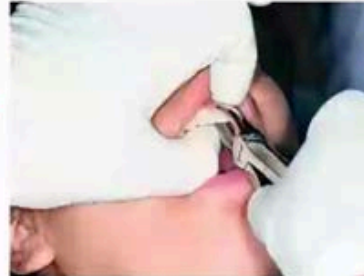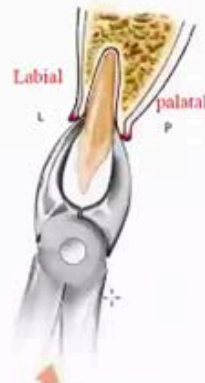The dentist should stand in front of and to the right of the patient (right handed).

##### Support:

By the index and the thumb finger.

##### Technique:

The initial movements are in a labial direction, and then palatal. Since the root is conical in shape, rotational forces are applied and the final extraction force is applied labially.



5

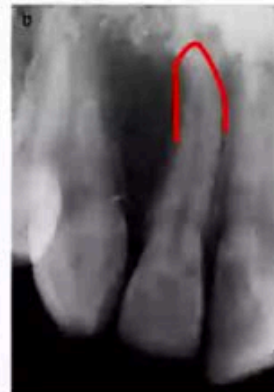Buccal force

Palatal force

Tractional force

#### Extraction of Maxillary Lateral Incisors

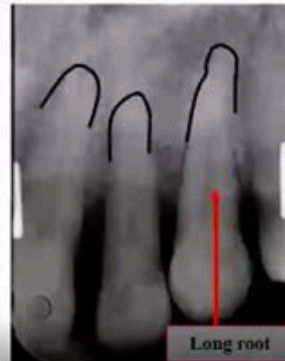The same technique as for central incisors, the difference is that the extraction movements are labial and palatal only **without rotational force** because it has curvature of the root tip palato-distally.



#### Extraction of Maxillary Canines

The extraction technique is the same for lateral incisors with some degree of difficulty due to:

- 1 Their firm anchorage in alveolar bone.
- 2 The roots are long with frequent curvature of the root tip.
- 3- The labial surface of the root is covered by thin alveolar bone, so there is a risk of fracturing the alveolar process.



6

Long root

strict legal action.

#### DISCLAIMER

THIS IS COPYRIGHTED CONTENT. Unauthorized use, including screenshots, copying, misuse, reuse, or resale of any content from this app, is strictly prohibited. Our app monitors and records all screenshots and recordings. Violators will face strict legal action.

**DISCLAIMER**  
THIS IS COPYRIGHTED CONTENT. Unauthorized use, including screenshots, copying, misuse, reuse, or resale of any content from this app, is strictly prohibited. Our app monitors and records all screenshots and recordings. Violators will face strict legal action.

THIS IS COPYRIGHTED CONTENT. Unauthorized use, including screenshots, copying, misuse, reuse, or resale of any content from this app, is strictly prohibited. Our app monitors and records all screenshots and recordings. Violators will face strict legal action.

DISCLAIMER



# ORAL SURGERY

## P.O.W.E.R NOTES SBQ 61

### Extraction of Maxillary Premolars

#### Instruments:

Maxillary premolar forceps.

#### Position:

The dentist should stand in front of and to the right of the patient (right handed).

#### Support:

By the index and the thumb finger.

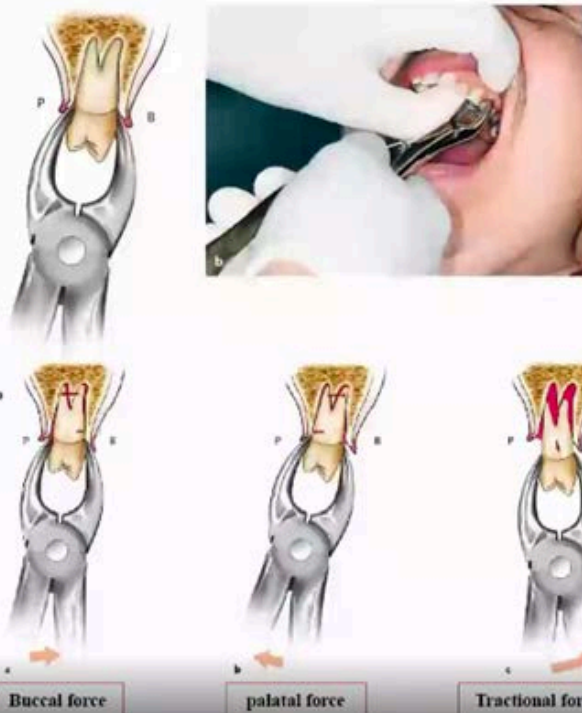#### Technique:

1 For the first premolar, because it usually has two roots, buccal and palatal pressure should be gentle and slight. If movements are vigorous and abrupt, there is a risk of fracturing the root tips. **Rotational motions are not allowed due to the tooth's anatomy.**

2 For the second premolar the extraction is easier, because the tooth mostly has one root.

3- The final movement for both teeth is buccal.

7



### Extraction of Maxillary First Molars

#### Instruments:

Maxillary right & left molar forceps.

#### Position:

The dentist should stand in front of and to the right of the patient (right handed).

#### Support:

By the index and the thumb finger.

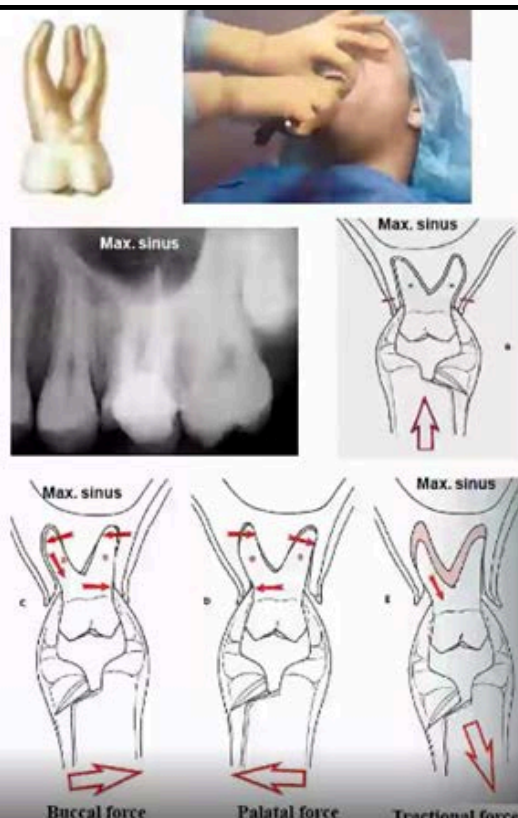
#### Note:

The maxillary first molar has three diverging roots, and the tooth is firmly anchored in the alveolar bone, therefore this tooth requires the application of strong force during its extraction, which may cause fracture of the crown or root tips.

#### Technique:

To avoid tooth fracture, initial movements must be gentle, with buccopalatal pressure and an increasing range of motion, especially buccally, where resistance is less. The final extraction movement is a buccal curved motion.

8



recordings. Violators will face strict legal action.

#### DISCLAIMER

THIS IS COPYRIGHTED CONTENT. Unauthorized use, including screenshots, copying, misuse, reuse, or resale of any content from this app, is strictly prohibited. Our app monitors and records all screenshots and recordings. Violators will face strict legal action.

DISCLAIMER  
THIS IS COPYRIGHTED CONTENT. Unauthorized use, including screenshots, copying, misuse, reuse, or resale of any content from this app, is strictly prohibited. Our app monitors and records all screenshots and recordings. Violators will face strict legal action.

THIS IS COPYRIGHTED CONTENT. Unauthorized use, including screenshots, copying, misuse, reuse, or resale of any content from this app, is strictly prohibited. Our app monitors and records all screenshots and recordings. Violators will face strict legal action.

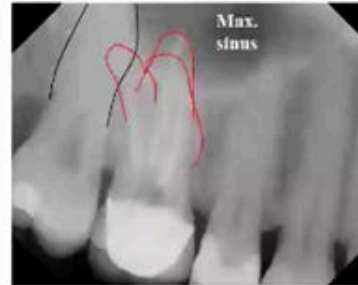DISCLAIMER

# ORAL SURGERY

## P.O.W.E.R NOTES SBQ 61

### Extraction of Maxillary Second Molars

**Instruments, Position, Support & technique:** The same as for maxillary first molars because the teeth have similar anatomy, however, it is easier because of little divergence of the roots and quite often are fused together in a conical shape.



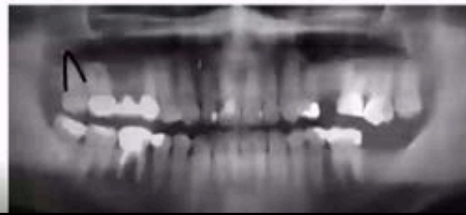
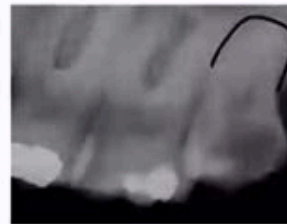
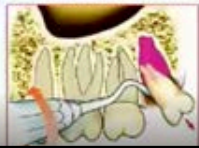### Extraction of Maxillary Third Molar

**Instrument:** maxillary third molar forceps.

**Position and Support:** same as for upper molars.

**Note:** The maxillary third molar is the smallest of all molars and varies greatly in size, number of roots, and root morphology. The tooth is usually easily removed because the buccal bone is thin and the roots are usually conical and fused.

**Technique:** If the third molar has erupted completely its extraction is accomplished by applying buccal pressure and very gentle palatal pressure. Root anatomy of the third molar may permit extraction using elevator only. The elevator is positioned in the mesio-buccal corner.



### Extraction of Mandibular Molars (first & second molars)

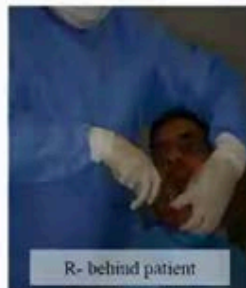
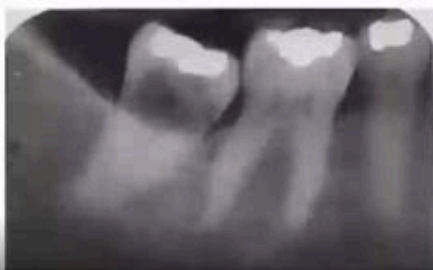**Instruments:** Mandibular molar forceps.

**Position and Support:** Same for lower anterior and premolars.

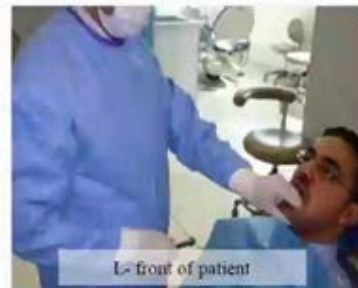**Note:**

The mandibular second molar has a morphology similar to that of the first molar, but its removal is more easily than the first molar, because its roots are smaller and less divergent.

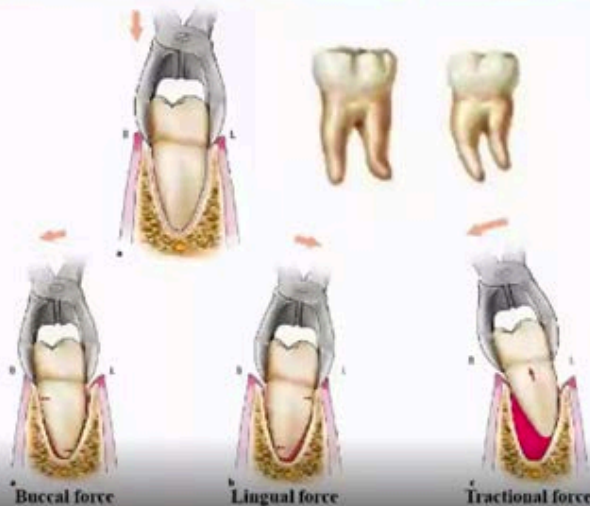
**Technique:** The extraction technique is the same for both molars. Initially the movements are gentle with buccal and lingual pressure. After the tooth is slightly mobilized, force is gradually increased and the final extraction movement is buccal (outward & downward).



R- behind patient



L- front of patient



Buccal force

Lingual force

Tractional force

strict legal action.

### DISCLAIMER

THIS IS COPYRIGHTED CONTENT. Unauthorized use, including screenshots, copying, misuse, reuse, or resale of any content from this app, is strictly prohibited. Our app monitors and records all screenshots and recordings. Violators will face strict legal action.

### DISCLAIMER

THIS IS COPYRIGHTED CONTENT. Unauthorized use, including screenshots, copying, misuse, reuse, or resale of any content from this app, is strictly prohibited. Our app monitors and records all screenshots and recordings. Violators will face strict legal action.

THIS IS COPYRIGHTED CONTENT. Unauthorized use, including screenshots, copying, misuse, reuse, or resale of any content from this app, is strictly prohibited. Our app monitors and records all screenshots and recordings. Violators will face strict legal action.

### DISCLAIMER



# ORAL SURGERY

## P.O.W.E.R NOTES SBQ 61

### Extraction of Mandibular Premolars

#### Instruments:

Mandibular premolar forceps.

#### Position and Support:

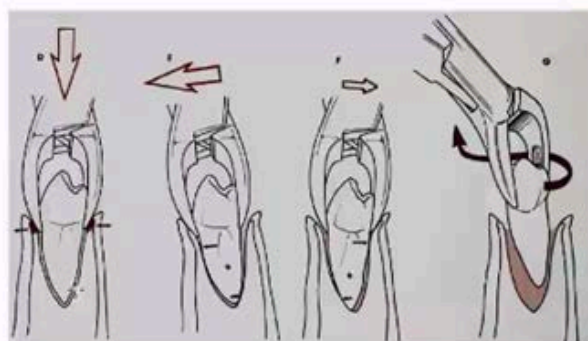
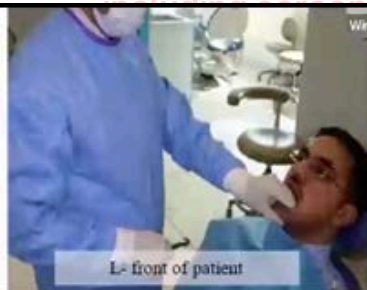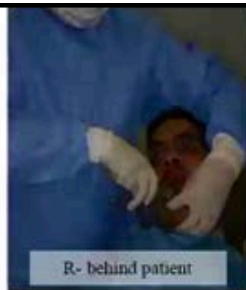
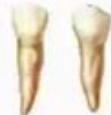Same for anterior teeth.

#### Note:

Premolar extraction is considered quite easy because their roots are straight and conical.

#### Technique:

Buccolingual force is applied for extraction of these teeth. Gentle rotational force may also be applied. The final extraction movement is outwards and downwards.



Buccal force

Lingual force

Tractional force

### Extraction of Mandibular Molars ( first & second molars)

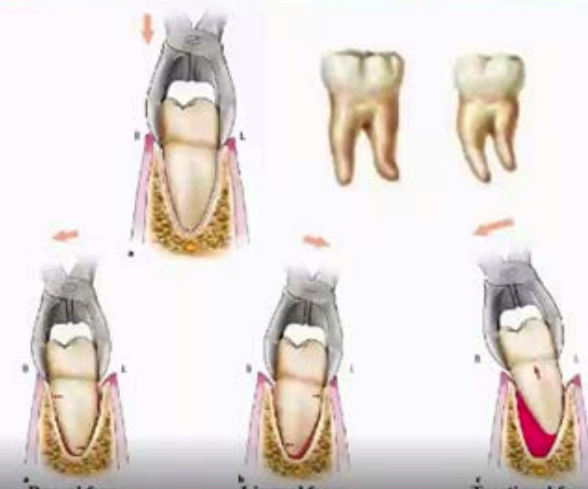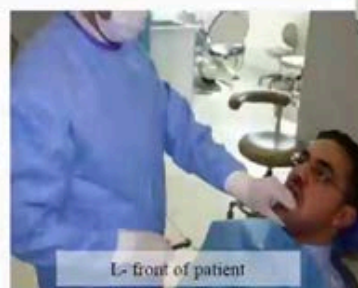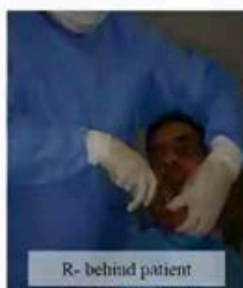
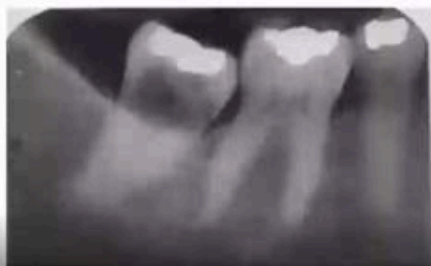
**Instruments:** Mandibular molar forceps.

**Position and Support:** Same for lower anterior and premolars.

#### Note:

The mandibular second molar has a morphology similar to that of the first molar, but its removal is more easily than the first molar, because its roots are smaller and less divergent.

**Technique:** The extraction technique is the same for both molars. Initially the movements are gentle with buccal and lingual pressure. After the tooth is slightly mobilized, force is gradually increased and the final extraction movement is buccal ( outward & downward).



Buccal force

Lingual force

Tractional force

recordings. Violators will face strict legal action.

#### DISCLAIMER

THIS IS COPYRIGHTED CONTENT. Unauthorized use, including screenshots, copying, misuse, reuse, or resale of any content from this app, is strictly prohibited. Our app monitors and records all screenshots and recordings. Violators will face strict legal action.

THIS IS COPYRIGHTED CONTENT. Unauthorized use, including screenshots, copying, misuse, reuse, or resale of any content from this app, is strictly prohibited. Our app monitors and records all screenshots and recordings. Violators will face strict legal action.

THIS IS COPYRIGHTED CONTENT. Unauthorized use, including screenshots, copying, misuse, reuse, or resale of any content from this app, is strictly prohibited. Our app monitors and records all screenshots and recordings. Violators will face strict legal action.

DISCLAIMER

# ORAL SURGERY

## P.O.W.E.R NOTES SBQ 61

**Instruments:**  
Mandibular molar forceps

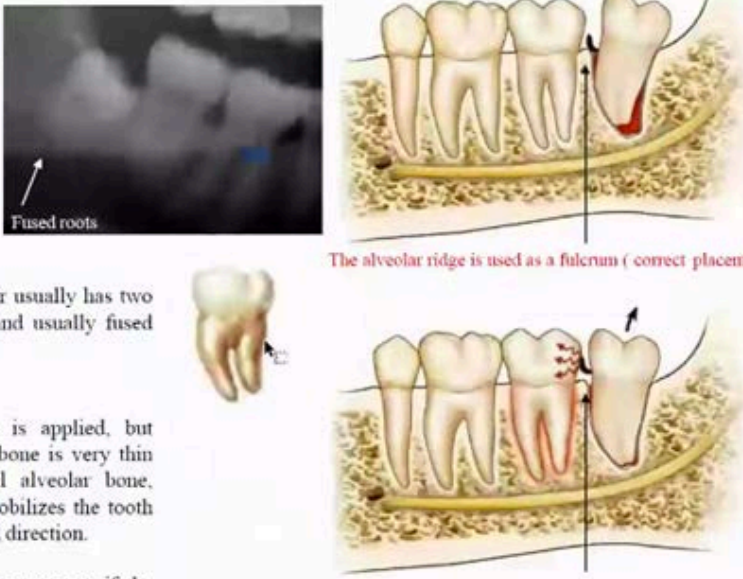
**Position and Support:**  
Same for molars.

**Note:**  
The mandibular third molar usually has two roots, which are smaller and usually fused in a conical shape.

**Technique:**

- 1- Buccolingual pressure is applied, but since the lingual alveolar bone is very thin compared to the buccal alveolar bone, therefore, the force that mobilizes the tooth must be more in the lingual direction.
- 2- If the third molar has one root or if the roots converge, the extraction may be accomplished using the straight elevator alone.

**Extraction of the mandibular third molar using a straight elevator**



The alveolar ridge is used as a fulcrum ( correct placement)

Using the adjacent tooth (second molar) as a fulcrum (incorrect placement) creates great tension around the tooth, with a risk of injury to tissues surrounding the root.

13

THIS IS COPYRIGHTED CONTENT. Unauthorized use, including screenshots, copying, misuse, reuse, or resale of any content from this app, is strictly prohibited. Our app monitors and records all screenshots and recordings. Violators will face strict legal action.

### DISCLAIMER

THIS IS COPYRIGHTED CONTENT. Unauthorized use, including screenshots, copying, misuse, reuse, or resale of any content from this app, is strictly prohibited. Our app monitors and records all screenshots and recordings. Violators will face strict legal action.

THIS IS COPYRIGHTED CONTENT. Unauthorized use, including screenshots, copying, misuse, reuse, or resale of any content from this app, is strictly prohibited. Our app monitors and records all screenshots and recordings. Violators will face strict legal action.

**DISCLAIMER**  
THIS IS COPYRIGHTED CONTENT. Unauthorized use, including screenshots, copying, misuse, reuse, or resale of any content from this app, is strictly prohibited. Our app monitors and records all screenshots and recordings. Violators will face strict legal action.

THIS IS COPYRIGHTED CONTENT. Unauthorized use, including screenshots, copying, misuse, reuse, or resale of any content from this app, is strictly prohibited. Our app monitors and records all screenshots and recordings. Violators will face strict legal action.

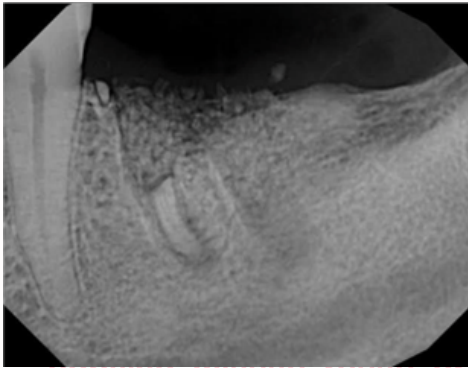
**DISCLAIMER**

# ORAL SURGERY

## SBQ 62

### REMAINING ROOT TIP

PATIENT HAD PRESENTED TO YOUR DENTAL PRACTICE . HE IS NEW TO YOUR PRACTICE. COMPLAINTS OF PAIN IN THE LOWER LEFT REGION OF THE MOUTH. IOPA WAS PRESENT . PATIENT HAD GOT EXTRACTION DONE OVERSEAS



I. Which flap is required to remove this root tip?

- A. triangular flap
- B. Envelope flap
- C. semilunar flap
- D. sulcular Flap
- E. Apical positioned flap.

II. What question will you ask her?

- A. Was the extraction difficult
- B. Was the tooth infected
- C. How much time it took for the extraction
- D. Is she aware of the remaining root
- E. Are the retained root pieces causing her discomfort.

III. How will you do treatment planning for this patient (the extraction was originally done overseas)

- A. Tell him that you will take the case but might require specialist referral
- B. Contact your professional indemnity insurer to ask if you should take the case
- C. Contact your professional group and ask how to do the case
- D. Refuse to take here case
- E. Ask him to see the overseas dentist.

IV. How will you conservatively extract this root ?

- A. using Cryers elevator from distal socket
- B. Root tip elevator
- C. Surgical exo
- D. Refer to the oral surgeon

### DISCLAIMER

THIS IS COPYRIGHTED CONTENT. Unauthorized use, including screenshots, copying, misuse, reuse, or resale of any content from this app, is strictly prohibited. Our app monitors and records all screenshots and recordings. Violators will face strict legal action.

### DISCLAIMER

THIS IS COPYRIGHTED CONTENT. Unauthorized use, including screenshots, copying, misuse, reuse, or resale of any content from this app, is strictly prohibited. Our app monitors and records all screenshots and recordings. Violators will face strict legal action.

THIS IS COPYRIGHTED CONTENT. Unauthorized use, including screenshots, copying, misuse, reuse, or resale of any content from this app, is strictly prohibited. Our app monitors and records all screenshots and recordings. Violators will face strict legal action.



# ORAL SURGERY

## P.O.W.E.R NOTES SBQ 62

- I. Triangular flap may be superior to the enveloped flap in terms of pain, trismus and wound dehiscence in the first 3 days after impacted 3rd molar surgery and may have better impact on quality of life during this process.
- II. Patient can not tell whether the extraction is difficult or not. Option (A) is ruled out. Patient can tell whether the tooth is painful or not. But patient can not say whether the tooth is infected or not. Option (B) is ruled out. Patient may not really remember how much time it took for extraction. Option (C) is ruled out. Patient would be known whether there's a remaining root piece is left behind in the socket if the dentist would have mentioned about it. So, you need to know whether the patient is aware about it. Discomfort from that area comes next. 1st you need to know whether the patient is aware about it. Option (E) is ruled out. For medicolegal purpose it's extremely important the patient is aware or not.
- III. Primary treatment was done in overseas. So, in this case, before you start doing any procedure it's always better to contact the indemnity insurer. Every practitioner should need to have an indemnity insurer in Australia. It's mandatory.

### Reference:

- Travellers should ensure that they do not depart from Australia with a pre-existing dental problem
- They should have a dental examination at least 3 months before departure to allow time for completion of any necessary dental treatment before they leave Australia
- Travellers especially young adults should know the status of their wisdom teeth and have any associated problems treated prior to departure
- Travelers should ensure that they have adequate insurance to cover the cost of emergency dental treatment overseas.
- Travellers should be advised that if they experience a dental emergency whilst overseas, information on availability of treatment can be obtained from the consular services provided through Australian Embassies, High Commissions and Consulates. Where there is no Australian overseas post, Canadian Embassies, High Commissions and Consulates provide this advice to Australian citizens.
- Governments and organisations providing advice to travellers should include information on the prevention and treatment of dental emergencies.
- Travellers should request a written report including radiographs on any emergency dental treatment received overseas to be passed on to their regular dentist on return from abroad.

### DISCLAIMER

THIS IS COPYRIGHTED CONTENT. Unauthorized use, including screenshots, copying, misuse, reuse, or resale of any content from this app, is strictly prohibited. Our app monitors and records all screenshots and recordings. Violators will face strict legal action.

### DISCLAIMER

THIS IS COPYRIGHTED CONTENT. Unauthorized use, including screenshots, copying, misuse, reuse, or resale of any content from this app, is strictly prohibited. Our app monitors and records all screenshots and recordings. Violators will face strict legal action.

### DISCLAIMER

THIS IS COPYRIGHTED CONTENT. Unauthorized use, including screenshots, copying, misuse, reuse, or resale of any content from this app, is strictly prohibited. Our app monitors and records all screenshots and recordings. Violators will face strict legal action.



# ORAL SURGERY

## P.O.W.E.R NOTES SBQ 62

### III. Reference:

- The diagnosis, treatment and maintenance of dental conditions is a complex process and the oral environment changes throughout life. This can be made even more complex due to language and cultural differences and time limits. Optimal ongoing oral health cannot be achieved in a single episode or short course of treatment and requires regular maintenance.
- Ongoing and corrective treatment may be compromised, as the records and complete details of treatment obtained overseas are unlikely to be available to those providing subsequent treatment in Australia.
- Complications to health from elective dental treatments obtained while overseas are not always covered by travel insurance and the treatments may not be covered by Australian health funds.
- Infection prevention and control standards in overseas dental clinics may not meet Australian standards leading to increased risk of disease transmission to the individual and community.

### IV. Root tip pick- used for the empty sockets where a very tiny part of a root is left behind. (e.g. 1/3rd of root)

Cryres - used when there's a quit large amount of root part is left behind in the socket and when the adjacent root socket is empty.

In the given x-ray, cryers can be applied from the distal socket and can break the septal bone. This will help to engage with the root portion and provide access to remove it.

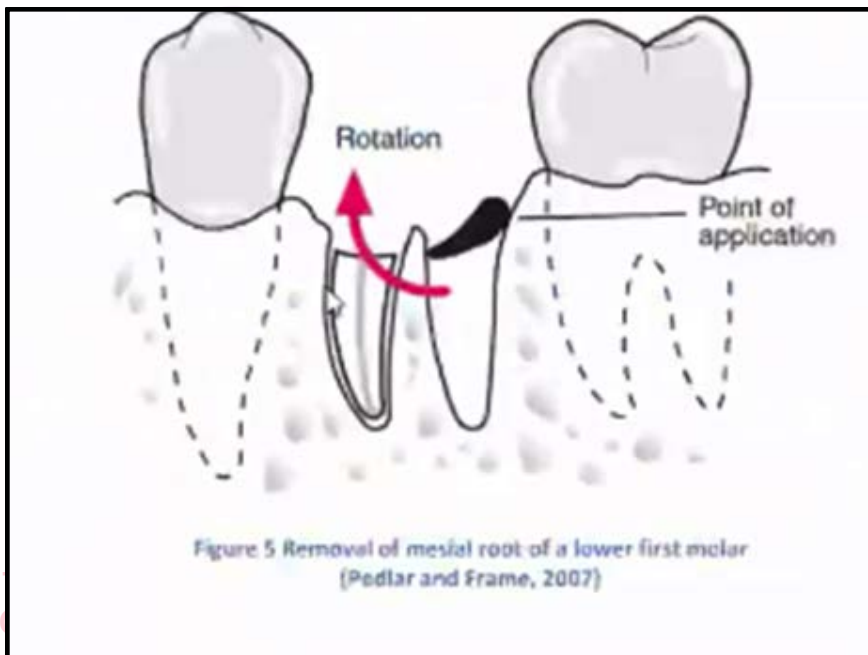


Figure 5 Removal of mesial root of a lower first molar  
(Pedlar and Frame, 2007)

### DISCLAIMER

THIS IS COPYRIGHTED CONTENT. Unauthorized use, including screenshots, copying, misuse, reuse, or resale of any content from this app, is strictly prohibited. Our app monitors and records all screenshots and recordings. Violators will face strict legal action.

DISCLAIMER

THIS IS COPYRIGHTED CONTENT. Unauthorized use, including screenshots, copying, misuse, reuse, or resale of any content from this app, is strictly prohibited. Our app monitors and records all screenshots and recordings. Violators will face strict legal action.

THIS IS COPYRIGHTED CONTENT. Unauthorized use, including screenshots, copying, misuse, reuse, or resale of any content from this app, is strictly prohibited. Our app monitors and records all screenshots and recordings. Violators will face strict legal action.

DISCLAIMER

# ORAL SURGERY

## P.O.W.E.R NOTES SBQ 62

These are the second most common type. These elevators usually come in right and left pairs with different angulations, all having a triangular working end, with the most commonly used are Cryer's elevators (East-west elevators)(Fig.4). The triangular elevators can be used to remove fractured roots when there is an adjacent empty socket. For example, when a distal root of a mandibular molar is removed while the mesial is still in place, the Cryer can be inserted in the distal socket and then slightly rotated (by wheel and axis action). The tip of the elevator will remove some inter-septal bone and then engages the cementum of the mesial root. By this movement the root can be delivered (Hupp et al., 2014) (Fig.5).



Figure 4 Triangular elevators, a pair of Cryer's elevators (Hupp et al., 2014)

### 3- Pick-Type Elevators:

This is uncommon type of elevators. It has two versions. A heavy version known as Crane Pick (Fig.6) and a smaller version known as root-tip pick (Fig.7).

Crane pick can remove roots from the socket, after a purchase point is prepared by drilling a hole into the root (Fig.8). The root-tip pick is a delicate instrument used to displace small root tips from the socket (Hupp et al., 2014).

THIS IS COPYRIGHTED CONTENT. Unauthorized use, including screenshots, copying, misuse, reuse, or resale of any content from this app, is strictly prohibited. Our app monitors and records all screenshots and recordings. Violators will face strict legal action.

### DISCLAIMER

THIS IS COPYRIGHTED CONTENT. Unauthorized use, including screenshots, copying, misuse, reuse, or resale of any content from this app, is strictly prohibited. Our app monitors and records all screenshots and recordings. Violators will face strict legal action.

THIS IS COPYRIGHTED CONTENT. Unauthorized use, including screenshots, copying, misuse, reuse, or resale of any content from this app, is strictly prohibited. Our app monitors and records all screenshots and recordings. Violators will face strict legal action.

WINSPERT  
P.O.W.E.R  
NOTES

THIS IS COPYRIGHTED CONTENT. Unauthorized use, including screenshots, copying, misuse, reuse, or resale of any content from this app, is strictly prohibited. Our app monitors and records all screenshots and recordings. Violators will face strict legal action.

WINSPERT  
P.O.W.E.R  
NOTES

**DISCLAIMER**  
THIS IS COPYRIGHTED CONTENT. Unauthorized use, including screenshots, copying, misuse, reuse, or resale of any content from this app, is strictly prohibited. Our app monitors and records all screenshots and recordings. Violators will face strict legal action.

**DISCLAIMER**

THIS IS COPYRIGHTED CONTENT. Unauthorized use, including screenshots, copying, misuse, reuse, or resale of any content from this app, is strictly prohibited. Our app monitors and records all screenshots and recordings. Violators will face strict legal action.

# ORAL SURGERY

## P.O.W.E.R NOTES SBQ 62



Figure 6 The heavy version of the Pick-type elevators, The Crane Pick (Hupp et al., 2014)




Figure 7 The small version of the Pick-type elevators, The Root-tip Pick (Hupp et al., 2014)

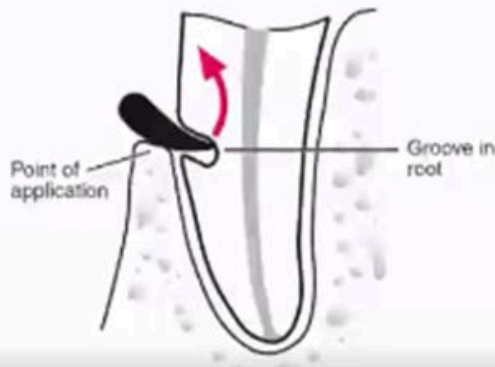


Figure 8 Removal of a lower retained root after drilling a hole for placement of the elevator (Pedlar and Frame, 2007)

THIS IS COPYRIGHTED CONTENT. Unauthorized use, including screenshots, copying, misuse, reuse, or resale of any content from this app, is strictly prohibited. Our app monitors and records all screenshots and recordings. Violators will face strict legal action.

### DISCLAIMER

THIS IS COPYRIGHTED CONTENT. Unauthorized use, including screenshots, copying, misuse, reuse, or resale of any content from this app, is strictly prohibited. Our app monitors and records all screenshots and recordings. Violators will face strict legal action.

THIS IS COPYRIGHTED CONTENT. Unauthorized use, including screenshots, copying, misuse, reuse, or resale of any content from this app, is strictly prohibited. Our app monitors and records all screenshots and recordings. Violators will face strict legal action.

**DISCLAIMER**  
THIS IS COPYRIGHTED CONTENT. Unauthorized use, including screenshots, copying, misuse, reuse, or resale of any content from this app, is strictly prohibited. Our app monitors and records all screenshots and recordings. Violators will face strict legal action.

COPYRIGHTED  
Unauthorized use, including screenshots, copying, misuse, reuse, or resale of any content from this app, is strictly prohibited. Our app monitors and records all screenshots and recordings. Violators will face strict legal action.

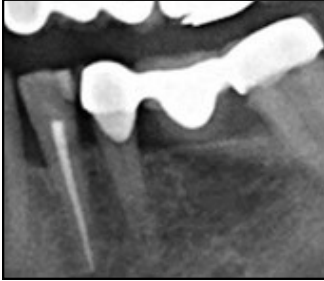
WINSPERT  
P.O.W.E.R  
NOTES



# ORAL SURGERY

## SBQ 63

IAN BLOCK



**A MALE PATIENT COMPLAINS OF PAIN IN THE LEFT LOWER REGION OF THE MOUTH. PATIENT ALREADY HAS 3 UNIT BRIDGE IN THE UPPER AND LOWER LEFT SIDE. YOU DECIDE TO DO XRAY. AFTER EXAMINING IOPA YOU SEE CARIES UNDER FPD ABUTMENT AND TENDER TO PERCUSSION IS ALSO POSITIVE. BONE LEVELS WERE NORMAL UNDER THE BRIDGE.**

**I. What additional tests will you do to diagnose in this case?**

- A. Remove the crowns and direct vision
- B. Periodontal probing
- C. Opg
- D. Pulp sensibility

**II. You gave an IANB injection a swelling developed in the cheek region. What is the cause for this**

- A. Hematoma
- B. Subcutaneous emphysema
- C. Injection to the lateral pterygoid muscle
- D. Allergic to adrenaline

**III. How to avoid this consequence to happen in future?**

- A. aseptic technique
- B. good injection technique

THIS IS COPYRIGHTED CONTENT. Unauthorized use, including screenshots, copying, misuse, reuse, or resale of any content from this app, is strictly prohibited. Our app monitors and records all screenshots and recordings. Violators will face strict legal action.

**DISCLAIMER**  
THIS IS COPYRIGHTED CONTENT. Unauthorized use, including screenshots, copying, misuse, reuse, or resale of any content from this app, is strictly prohibited. Our app monitors and records all screenshots and recordings. Violators will face strict legal action.

THIS IS COPYRIGHTED CONTENT. Unauthorized use, including screenshots, copying, misuse, reuse, or resale of any content from this app, is strictly prohibited. Our app monitors and records all screenshots and recordings. Violators will face strict legal action.

**DISCLAIMER**

THIS IS COPYRIGHTED CONTENT. Unauthorized use, including screenshots, copying, misuse, reuse, or resale of any content from this app, is strictly prohibited. Our app monitors and records all screenshots and recordings. Violators will face strict legal action.



# ORAL SURGERY

## P.O.W.E.R NOTES SBQ 63

I. Removal of the crown and direction vision is required to: check for the;

- Secondary caries
- Remaining tooth structure
- Pulp sensibility test – more accuracy after removal of bridge
- Initial margin probing can be done with the prosthesis

II. Subcutaneous emphysema (SE)

Subcutaneous emphysema is a rare but serious complication that can occur after some dental procedures. It happens when air is forced into the soft tissues beneath the skin.

**Causes:**

- Air-driven handpieces: High-speed drills that use compressed air to section teeth during extractions, restorations, and endodontic procedures
- Air syringes: Used during dental procedures
- Repeated Valsalva manoeuvres: Blowing out forcefully after a dental procedure

**Symptoms:**

- Swelling in the face and neck
- Crepitus, or crackling sensation, when the area is palpated

**Treatment:**

- Antibiotics
- Pain medication
- Avoiding activities that increase air pressure in the mouth, like blowing balloons or drinking through straws

**Prognosis:**

- In most cases, subcutaneous emphysema is self-limiting and resolves on its own within 7–10 days
- If left untreated, it can spread and lead to life-threatening complications

Injection in the lateral pterygoid muscle

This leads to trismus and causing any swelling

Allergic to adrenalin

Adrenalin is an indigenous chemical present within the patient's body. Allergic can be due to the metabisulfite or lignocaine, and not for the adrenalin.

DISCLAIMER

THIS IS COPYRIGHTED CONTENT. Unauthorized use, including screenshots, copying, misuse, reuse, or resale of any content from this app, is strictly prohibited. Our app monitors and records all screenshots and recordings. Violators will face strict legal action.

DISCLAIMER

THIS IS COPYRIGHTED CONTENT. Unauthorized use, including screenshots, copying, misuse, reuse, or resale of any content from this app, is strictly prohibited. Our app monitors and records all screenshots and recordings. Violators will face strict legal action.

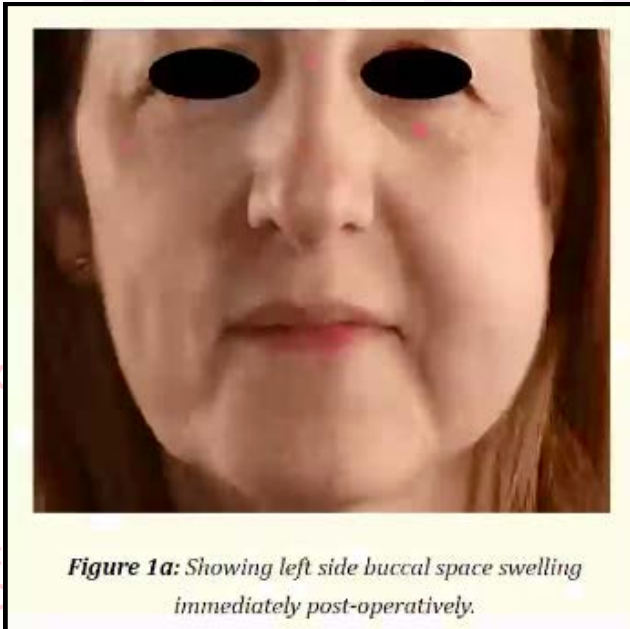DISCLAIMER

THIS IS COPYRIGHTED CONTENT. Unauthorized use, including screenshots, copying, misuse, reuse, or resale of any content from this app, is strictly prohibited. Our app monitors and records all screenshots and recordings. Violators will face strict legal action.

# ORAL SURGERY

## P.O.W.E.R NOTES SBQ 63

### II. Hematoma



Hematoma is caused by penetration of blood vessel by needle resulting in damage to the vessel wall and subsequent bleeding into the surrounding tissues. Hematoma resulting from attempts at intraoral anaesthesia are most commonly caused by rupture of the posterior superior alveolar and infraorbital vessels. However, we believe that this hematoma resulted in damage to the inferior alveolar artery which lies in close proximity to the inferior alveolar nerve.

When faced with an unexpected complication following an IANB, the clinician should immediately stop administration of the local anaesthetic and withdraw the needle. It's important to recognise the signs and symptoms of each potential complication and manage appropriately. Short term management would include assurance and explanation of the situation. For specific complications such as a buccal hematoma formation, medical photographs may be useful. Longer term management would include regular follow ups as no surgical intervention is usually required. Should a persistent swelling remain or if there are signs of infection then advice and referral to an oral and maxillofacial department would be advisable.

III. To avoid such complications, it is important to have a clear understanding of anatomy and techniques required for effective anaesthesia. This can include knowledge of anatomical landmarks, achieving negative aspirate to avoid the needle while in the vicinity of the inferior alveolar bundle.

THIS IS COPYRIGHTED CONTENT. Unauthorized use, including screenshots, copying, misuse, reuse, or resale of any content from this app, is strictly prohibited. Our app monitors and records all screenshots and recordings. Violators will face strict legal action.

#### DISCLAIMER

THIS IS COPYRIGHTED CONTENT. Unauthorized use, including screenshots, copying, misuse, reuse, or resale of any content from this app, is strictly prohibited. Our app monitors and records all screenshots and recordings. Violators will face strict legal action.

DISCLAIMER  
THIS IS COPYRIGHTED CONTENT. Unauthorized use, including screenshots, copying, misuse, reuse, or resale of any content from this app, is strictly prohibited. Our app monitors and records all screenshots and recordings. Violators will face strict legal action.

THIS IS COPYRIGHTED CONTENT. Unauthorized use, including screenshots, copying, misuse, reuse, or resale of any content from this app, is strictly prohibited. Our app monitors and records all screenshots and recordings. Violators will face strict legal action.

DISCLAIMER

# ORAL SURGERY

**SBQ 64****BOTULINUM TOXIN**

**Question about botulinum toxin for tmj dysfunction, What should be told to patient about it to make an informed consent.**

- A. this is a normal routine procedure any dentist can do the procedure
- B. patient must consult oral surgeon before procedure
- C. you guarantee the long term success of the treatment to the patient
- D. Botulinum toxin is an experimental procedure.
- E. only a dentist can do this procedure.
- F. Trismus is a common side effect

THIS IS COPYRIGHTED CONTENT. Unauthorized use, including screenshots, copying, misuse, reuse, or resale of any content from this app, is strictly prohibited. Our app monitors and records all screenshots and recordings. Violators will face strict legal action.

THIS IS COPYRIGHTED CONTENT. Unauthorized use, including screenshots, copying, misuse, reuse, or resale of any content from this app, is strictly prohibited. Our app monitors and records all screenshots and recordings. Violators will face strict legal action.

THIS IS COPYRIGHTED CONTENT. Unauthorized use, including screenshots, copying, misuse, reuse, or resale of any content from this app, is strictly prohibited. Our app monitors and records all screenshots and recordings. Violators will face strict legal action.

**DISCLAIMER**

THIS IS COPYRIGHTED CONTENT. Unauthorized use, including screenshots, copying, misuse, reuse, or resale of any content from this app, is strictly prohibited. Our app monitors and records all screenshots and recordings. Violators will face strict legal action.

**DISCLAIMER**  
THIS IS COPYRIGHTED CONTENT. Unauthorized use, including screenshots, copying, misuse, reuse, or resale of any content from this app, is strictly prohibited. Our app monitors and records all screenshots and recordings. Violators will face strict legal action.

**DISCLAIMER**

THIS IS COPYRIGHTED CONTENT. Unauthorized use, including screenshots, copying, misuse, reuse, or resale of any content from this app, is strictly prohibited. Our app monitors and records all screenshots and recordings. Violators will face strict legal action.



# ORAL SURGERY

## P.O.W.E.R NOTES SBQ 64

- 2.1. The use of neurotoxins and dermal fillers has become part of the practice of dentistry over the past decade.
- 2.2. Dentists through their oral and maxillofacial anatomy education are the only appropriately qualified dental practitioner to administer neurotoxins and dermal fillers
- 2.3. The Board has released communiques on the use of neurotoxins and dermal fillers in dentistry and had released an Interim Policy which has been subsequently withdrawn from its website.
- 2.4. The Therapeutic Goods Administration (TGA) regulates the use of neurotoxins and dermal fillers.
- 2.5. Some applications of neurotoxins and dermal fillers are classified as Off-Label Use. The TGA does not assess off-label use.
- 2.6. Off-Label use of scheduled medication requires clinical judgement of the practitioner and consent of the patient.
- 2.7. The use of neurotoxins and dermal fillers may be limited by state and territory drugs and poisons legislation.
- 2.8. There are restrictions on the advertising of neurotoxins and dermal fillers.
- 3.1. Dentists should be the only dental practitioner able to administer neurotoxins and dermal fillers.
- 3.2. Dentists must comply with any requirements of the Board and their state and territory drugs and poison legislation, including appropriate legal consent requirement. Dentists who use neurotoxins and dermal fillers as part of their practice of dentistry or adjunctive to dentistry will be expected to have completed appropriate education to ensure the safety of the public.
- 3.3. Before administering neurotoxins and dermal fillers dentists must have knowledge of and skills in:
  - patient assessment and consultation for neurotoxins and dermal fillers;
  - indications and contraindications for their use;
  - safety and risk issues for neurotoxins and dermal filler injectable therapy;
  - appropriate preparation and delivery techniques for desired outcomes;
  - enhancing and finishing treatments with dermal fillers;
  - the pharmacology of neurotoxins and dermal fillers;
  - adverse reactions and management of possible complications; and
  - the appropriate treatment of temporomandibular disorders with neurotoxins.
- 3.4. If a dentist does decide to use neurotoxins and dermal fillers off-label then this is a clinical judgement that should be made in consultation with and consent of their patient.
- 3.5. Before using neurotoxins and dermal fillers dentists must confirm that their professional indemnity policy provides appropriate cover for the treatment.
- 3.6. Dentists must not delegate treatment involving neurotoxins and dermal fillers.

resale of any content from this app, is strictly prohibited. Our app monitors and records all screenshots and recordings. Violators will face strict legal action.

### DISCLAIMER

THIS IS COPYRIGHTED CONTENT. Unauthorized use, including screenshots, copying, misuse, reuse, or resale of any content from this app, is strictly prohibited. Our app monitors and records all screenshots and recordings. Violators will face strict legal action.

**DISCLAIMER**  
THIS IS COPYRIGHTED CONTENT. Unauthorized use, including screenshots, copying, misuse, reuse, or resale of any content from this app, is strictly prohibited. Our app monitors and records all screenshots and recordings. Violators will face strict legal action.

**DISCLAIMER**

THIS IS COPYRIGHTED CONTENT. Unauthorized use, including screenshots, copying, misuse, reuse, or resale of any content from this app, is strictly prohibited. Our app monitors and records all screenshots and recordings. Violators will face strict legal action.

NOTES



# ORAL SURGERY

## P.O.W.E.R NOTES SBQ 64

### Reference: TG

There is some evidence for the use of botulinum toxin to manage the symptoms of temporomandibular disorders when conservative measures are inadequate. Ensure patients understand that botulinum toxin is not a cure for temporomandibular disorders but may be used as part of the overall management strategy. The use of botulinum toxin for temporomandibular disorders is off label. Dentists require additional training to administer botulinum toxin. If the recommended doses and protocols are adhered to, the incidence of adverse effects is low. Local complications include stinging during injections, bruising at the site of injection and excessive muscle weakness. Adverse effects associated with inadvertent injection of botulinum toxin into nontarget tissues are rare but can include alteration in smile and temporary dry mouth. Systemic adverse effects include an influenza-like syndrome that is transient and hypersensitivity reactions.

THIS IS COPYRIGHTED CONTENT. Unauthorized use, including screenshots, copying, misuse, reuse, or resale of any content from this app, is strictly prohibited. Our app monitors and records all screenshots and recordings. Violators will face strict legal action.

THIS IS COPYRIGHTED CONTENT. Unauthorized use, including screenshots, copying, misuse, reuse, or resale of any content from this app, is strictly prohibited. Our app monitors and records all screenshots and recordings. Violators will face strict legal action.

THIS IS COPYRIGHTED CONTENT. Unauthorized use, including screenshots, copying, misuse, reuse, or resale of any content from this app, is strictly prohibited. Our app monitors and records all screenshots and recordings. Violators will face strict legal action.

### DISCLAIMER

THIS IS COPYRIGHTED CONTENT. Unauthorized use, including screenshots, copying, misuse, reuse, or resale of any content from this app, is strictly prohibited. Our app monitors and records all screenshots and recordings. Violators will face strict legal action.

### DISCLAIMER

THIS IS COPYRIGHTED CONTENT. Unauthorized use, including screenshots, copying, misuse, reuse, or resale of any content from this app, is strictly prohibited. Our app monitors and records all screenshots and recordings. Violators will face strict legal action.

### DISCLAIMER

THIS IS COPYRIGHTED CONTENT. Unauthorized use, including screenshots, copying, misuse, reuse, or resale of any content from this app, is strictly prohibited. Our app monitors and records all screenshots and recordings. Violators will face strict legal action.