



OSCE Lens Card

YELLOW SET: TEENAGE PATIENT WITH PERIODONTITIS CASE

Cluster 1: Clinical Information Gathering

Key Words

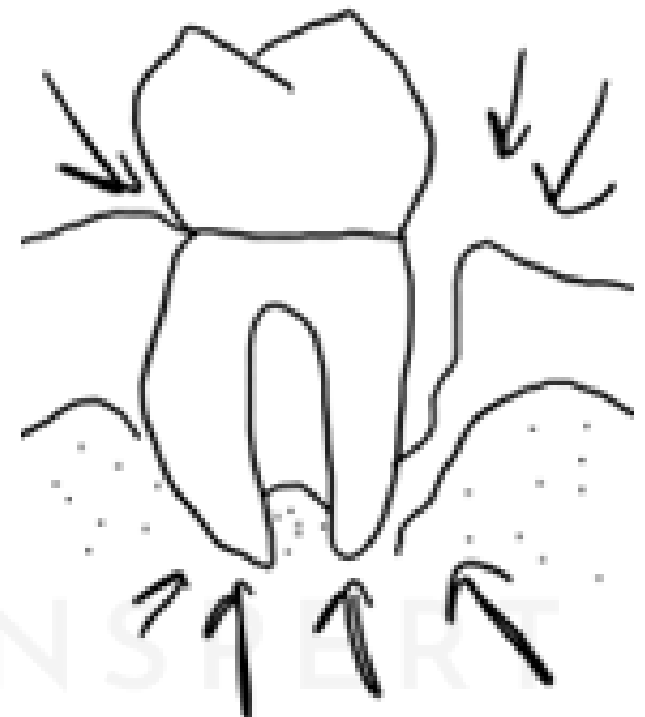- 1 HISTORY:**
 - HOPC: Discharge/ Bleeding gums? Wobbly teeth? Sensitivity?
 - Medical history - Medical conditions, medications and allergies.
 - Dental history - Regular visits?
 - Oral hygiene history - Toothbrushing, flossing.
 - Social history - (Underage patient for smoking and alcohol, but in confidence ask about this).

- 2 Explain the findings and risk factors (Genetic periodontal conditions).**

- 3 INVESTIGATIONS:**
 - E/O - Swelling over the face or grinding.
 - I/O - Detailed examine all teeth and count.

X-rays: OPG.
Detailed gum examination.

Diagram





OSCE Lens Card

YELLOW SET: MULTIPLE CARIES IN A CHILD CASE

Cluster 1: Clinical Information Gathering

Key Words

1

HISTORY:

- HOPC: Pain? Swelling over the gums/ face?
- Medical history - Medical conditions, medications and allergies.
- Dental history - Regular visits?
- Oral hygiene history - Toothbrushing, flossing, supervision and toothpaste.
- Social history - Diet and water.

2

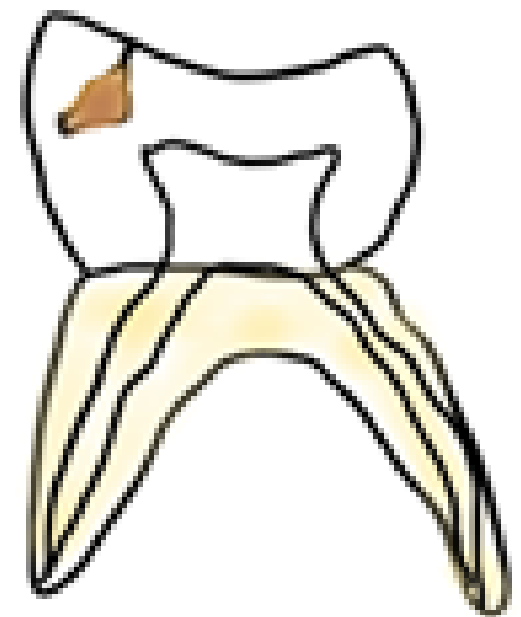
Explain the findings on x-rays and risk factors.

3

INVESTIGATIONS:

- E/O - Swelling over the face.
 - I/O - Detailed examination of all the teeth.
- X-rays: OPG.
Detailed gum examination.
Diet chart.

Diagram





OSCE Lens Card

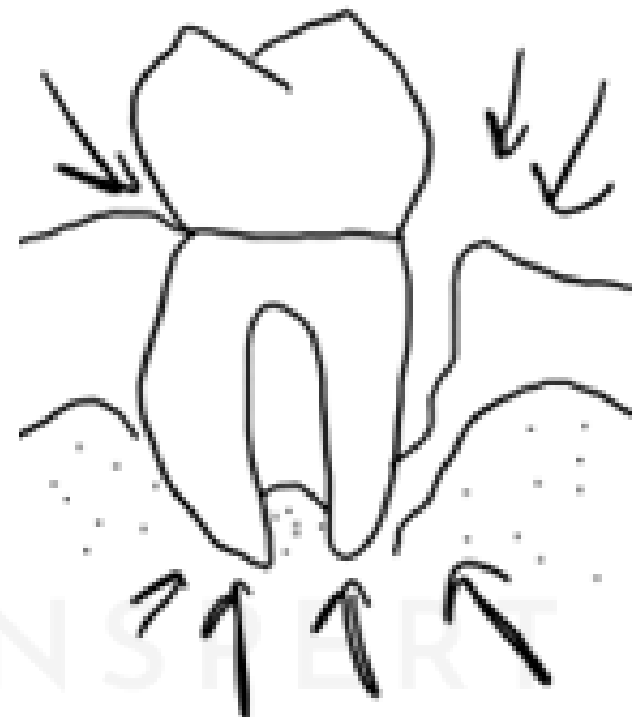YELLOW SET: PERIODONTAL ABSCESS CASE.

Cluster 2: Diagnosis and Management

Key Words

- 1** HOPC: Wobbly teeth? Discharge? Bleeding? Sensitivity?
- 2** EXPLANATION OF FINDINGS AND DIAGNOSIS: Acute/ chronic periodontal abscess.
- 3** RELEVANT HISTORY: Medical history (MRONJ risk), regular dental visits and oral hygiene, smoking.
- 4** MANAGEMENT:
 - No treatment.
 - Referral to an oral surgeon - MRONJ risk.
 - Temporary/ emergency treatment - Superficial clean to drain pus along with splinting.
 - Recall: Review and regular dental visits.
- 5** HEALTH PROMOTION ASPECTS:
 - Regular dental visits.
 - Oral hygiene routine (Brushing twice daily and flossing).
 - Medical history (regular blood tests and checks).

Diagram





OSCE Lens Card

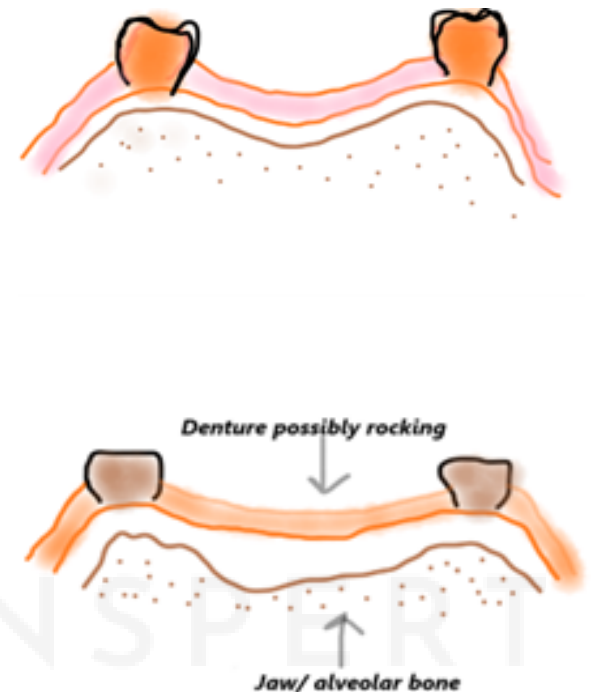
YELLOW SET: DENTURE STOMATITIS CASE

Cluster 2: Diagnosis and Management

Key Words

- 1 HOPC: Denture age? Denture hygiene?
Any symptoms in and around the mouth?
- 2 EXPLANATION OF FINDINGS AND DIAGNOSIS:
Denture stomatitis and angular cheilitis.
- 3 RELEVANT HISTORY:
Medical history (blood test), regular dental visits and oral hygiene, smoking.
- 4 MANAGEMENT:
 - No treatment.
 - Temporary management - Relining of the denture.
 - Clotrimazole 1% cream topically to the angles of the mouth, twice daily for at least 14 days; continue treatment for 14 days after symptoms resolve.
 - Long term management - Assess for combination syndrome and then refer to dental prosthetist or prosthodontist.
- 5 HEALTH PROMOTION ASPECTS:
 - Regular dental visits.
 - Oral hygiene routine (Brushing twice daily and flossing).
 - Medical history (regular blood tests and checks).

Diagram





OSCE Lens Card

YELLOW SET: REPLACEMENT OPTIONS CASE.

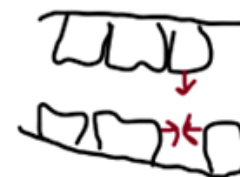
Cluster 3: Clinical Treatment and Evaluation

Key Words

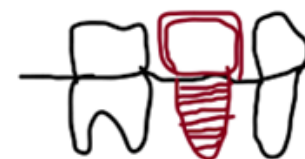- 1 HOPC: Any symptoms? Any hopes or expectations?
- 2 Explanation of findings and x-ray.
- 3 Relevant history and correlate with replacement options: OH, D/H, M/H, S/H.
- 4 **TREATMENT AND EVALUATION:**
 - No treatment.
 - Removable options - chrome cobalt denture.
 - Fixed options - Conventional bridge, cantilever bridge, implant.
 - Written brochures about detailed options.
- 5 **HEALTH PROMOTION ASPECTS:**
 - Regular dental visits.
 - Optimum oral hygiene.
 - Regular GP visits (blood tests and checks).

Diagram

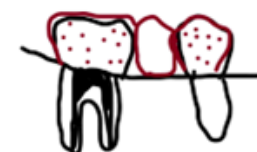No treatment



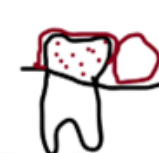Implant



Fixed bridges



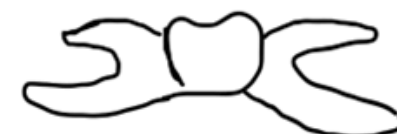
traditional



cantilever bridge



Removable options





OSCE Lens Card

**YELLOW SET: CROWN BROKE DURING
EXTRACTION CASE**

Cluster 3: Clinical Treatment and Evaluation

Key Words

- 1** HOPC: Swelling extent? Severe features of odontogenic infection?
- 2** Explanation of the situation over x-ray. And the risk of complications is more. (OAC and root slipping into sinus).
- 3** **RELEVANT HISTORY:**
M/H - allergies. S/H.
- 4** **TREATMENT AND EVALUATION:**
 - Extraction by us but risk is present.
 - Option of referral to an oral surgeon.
 - VPTAS.
 - Post-extraction instructions.
- 5** **HEALTH PROMOTION ASPECTS:**
 - Regular dental visits - brochures on dental camps in remote areas.
 - Optimum oral hygiene.

Diagram

Explain with x-ray given.