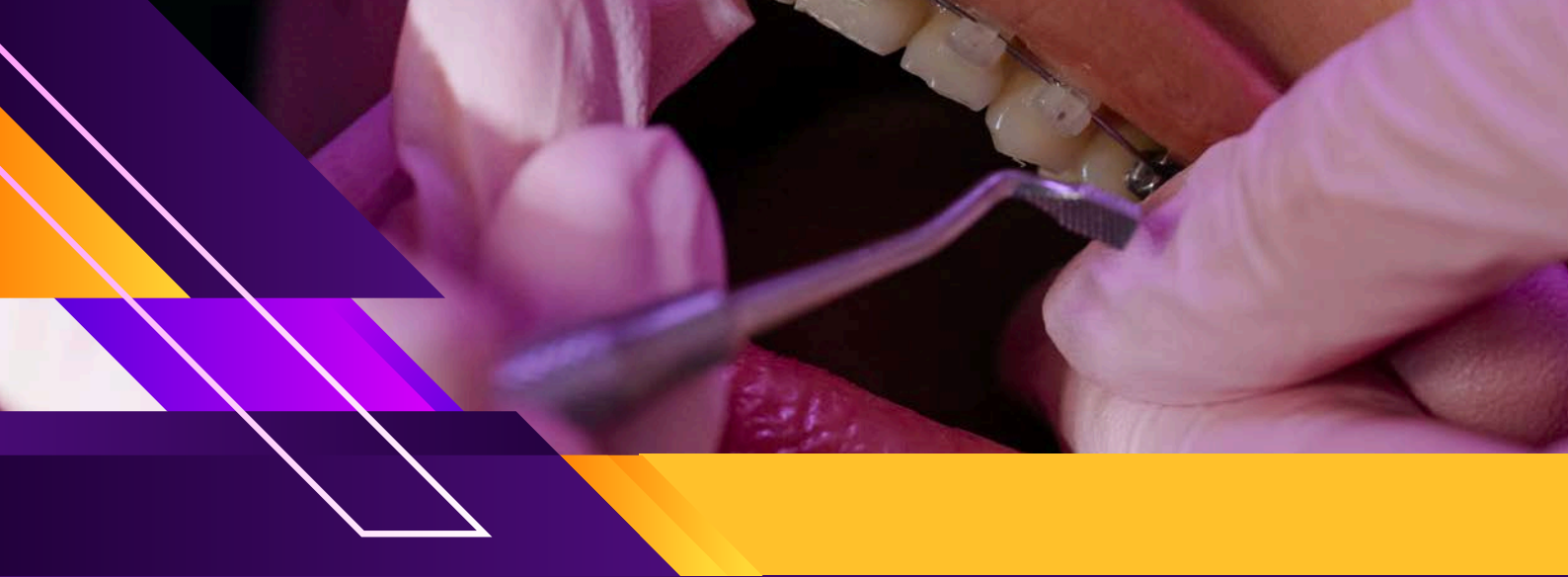



WINSPERT

WINSPERT

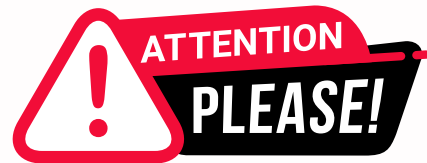P.O.W.E.R

PREPARATION OF ADC WITH WINSPERT EXPERT REVIEW

NOTES

By Dr. Jigyasa Sharma





Dear Students,

We'd like to remind you about the importance of respecting the integrity of the resources provided in our app.

Please be aware that **WINSPERT POWERNOTES ARE COPYRIGHTED CONTENT. Unauthorized use, including screenshots, copying, misuse, reuse, or resale of any content from this app, is strictly prohibited.**

Our app monitors and records all screenshots and recordings. Violators will face strict legal action.

We're committed to providing you with the best tools for your success, and we appreciate your cooperation in maintaining a fair and secure learning environment.

Thank you for your understanding and continued dedication.

Best regards,
WINSPERT TEAM

ENDODONTICS

SBQ 1

ONE X-RAY WAS GIVEN WHERE ON PREMOLAR RESTORATION WITH PINS WERE PRESENT. THERE WAS SOME HORIZONTAL FRACTURE NEAR THE MESIAL AREA ON THE X-RAY.(X-RAY WAS GIVEN AND COULD SEE THE HORIZONTAL FRACTURE AND ALSO IT HAD PINS AND LARGE RESTORATION) PATIENT COMPLAINS OF PAIN IN UPPER RIGHT AREA. PATIENT HAD SENSITIVITY, SINCE A LONG TIME BUT RECENTLY HAS PAIN WITH HOT FOODS. SHE SAYS A LARGE RESTORATION WAS DONE 10YRS AGO BY ANOTHER DENTIST AND NOW IT IS SO SORE THAT SHE CANNOT BITE ON IT.

I. What test will you do to check pulp sensibility?

- A. Heat test
- B. Cold test with CO2 snow
- C. Cold test with ice stick
- D. Ethyl chloride spray
- E. Tooth sleuth (not the exactly this name)

II. You performed pulp testing and the pain lasted more than 10 mins. What is the pulpal riapical diagnosis?

- A. Acute apical periodontitis
- B. Acute apical abscess
- C. Chronic apical abscess
- D. Chronic apical periodontitis

III. What is the cause of patient's complaint?

- A. Fracture along the mesio-distal
- B. Loss of marginal integrity/seal of the restoration
- C. Caries
- D. Tooth in traumatic bite
- E. Pin entered the pulp chamber

IV. What decides the prognosis for this tooth?

- A. Amount of tooth structure left
- B. Possibility to put a post in one of the canals
- C. Restorability of the tooth
- D. Financial capacity of the patient

DISCLAIMER

THIS IS COPYRIGHTED CONTENT. Unauthorized use, including screenshots, copying, misuse, reuse, or resale of any content from this app, is strictly prohibited. Our app monitors and records all screenshots and recordings. Violators will face strict legal action.

DISCLAIMER
THIS IS COPYRIGHTED CONTENT. Unauthorized use, including screenshots, copying, misuse, reuse, or resale of any content from this app, is strictly prohibited. Our app monitors and records all screenshots and recordings. Violators will face strict legal action.

THIS IS COPYRIGHTED CONTENT. Unauthorized use, including screenshots, copying, misuse, reuse, or resale of any content from this app, is strictly prohibited. Our app monitors and records all screenshots and recordings. Violators will face strict legal action.

DISCLAIMER

ENDODONTICS

P.O.W.E.R NOTES SBQ 1

I. Sensibility Tests: Cold test, Heat test, EPT

Among these, cold test is the best.

Option (A):

Patient has pain with hot food therefore, this test should be done to confirm it.

Option (B), (C), (D):

All these 3 options are cold tests. Among these CO2 snow/dry ice is the best.

OPTION (E):

Tooth sloth is not a sensibility test.

II. Sensitivity for hot/cold indicates pulpitis. Pain which last for more than 10mins is associated with irreversible pulpitis. The patient has pain on biting which means the inflammation has involved the PDL space. Therefore, the periapical condition is **acute apical periodontitis**.

If there's soft tissue involvement, then the answer would be **acute apical abscess**.

If there's a fistula with soft tissue involvement, then the answer would be **chronic apical abscess**.

When there's no abscess/no fistula but there's a periapical radiolucency, no pain then the answer would be chronic apical periodontitis.

For a diagnosis to be a abscess there should be soft tissue involvement or presence of fistula.

In the presence of soft tissue involvement

Acute periapical abscess
(abscess+ pain+)

Chronic periapical abscess
(fistula+ no/mild pain)

In the absence of soft tissue involvement

Acute apical periodontitis
(pain+/no apical radiolucency)

Chronic apical periodontitis
(pain may or may not/apical radiolucency)

DISCLAIMER

THIS IS COPYRIGHTED CONTENT. Unauthorized use, including screenshots, copying, misuse, reuse, or resale of any content from this app, is strictly prohibited. Our app monitors and records all screenshots and recordings. Violators will face strict legal action.

THIS IS COPYRIGHTED CONTENT. Unauthorized use, including screenshots, copying, misuse, reuse, or resale of any content from this app, is strictly prohibited. Our app monitors and records all screenshots and recordings. Violators will face strict legal action.

DISCLAIMER

THIS IS COPYRIGHTED CONTENT. Unauthorized use, including screenshots, copying, misuse, reuse, or resale of any content from this app, is strictly prohibited. Our app monitors and records all screenshots and recordings. Violators will face strict legal action.

ENDODONTICS

P.O.W.E.R NOTES SBQ 1

III.

RESTORATION WITH PINS



HORIZONTAL FRACTURE



FRACTURE LEAD TO ENTRANCE OF BACTERIA TO THE TOOTH



PULPITIS

IV. In case of RCT- the amount of the tooth structure left will decide the prognosis.

In case of fracture- the restorability matters, if the crack is propagating below the CEJ or up to the furcation extraction may require. Therefore, the direction/orientation of the crack matters.

DISCLAIMER

THIS IS COPYRIGHTED CONTENT. Unauthorized use, including screenshots, copying, misuse, reuse, or resale of any content from this app, is strictly prohibited. Our app monitors and records all screenshots and recordings. Violators will face strict legal action.

DISCLAIMER
THIS IS COPYRIGHTED CONTENT. Unauthorized use, including screenshots, copying, misuse, reuse, or resale of any content from this app, is strictly prohibited. Our app monitors and records all screenshots and recordings. Violators will face strict legal action.

DISCLAIMER

THIS IS COPYRIGHTED CONTENT. Unauthorized use, including screenshots, copying, misuse, reuse, or resale of any content from this app, is strictly prohibited. Our app monitors and records all screenshots and recordings. Violators will face strict legal action.

ENDODONTICS

SBQ 2

A PATIENT HAD SEVERE PAIN 1-2 WEEKS AFTER THE RCT THAT SOME OTHER DENTIST DID. IOPA GIVEN. SHORT OBTURATION ON DISTAL CANAL OF LOWER MOLAR.

I. What is the reason for pain?

- A. Bacteria left in the canal
- B. Short GP point
- C. Trauma from occlusion
- D. Leakage of irrigating material

II. You are retreatting the tooth. What irrigation technique will you choose to safely irrigate?

- A. Irrigate upto the apex to remove debris
- B. Static irrigation in apical region
- C. Positive pressure with plunger
- D. Bind the needle in apical one third (0.5 mm from apex)
- E. Side vented needle
- F. Irrigation via open ended needle at the apical third

III. How will you obturate to prevent root fracture/ cracks in the root?

- A. Lateral oblique movement of the spreader
- B. Pushing the spreader in apical direction away from walls of the roots
- C. Pre curve the spreader according to canal (Xray didn't show any curvature of roots or canals)
- D. Push the spreader against the walls
- E. Put the spreader 0.5 mm away from the anatomic apex

IV. What will you check before final restoration?

- A. Amount of remaining tooth structure
- B. Radiographic healing
- C. Biological width

THIS IS COPYRIGHTED CONTENT. Unauthorized use, including screenshots, copying, misuse, reuse, or resale of any content from this app, is strictly prohibited. Our app monitors and records all screenshots and recordings. Violators will face strict legal action.

DISCLAIMER
THIS IS COPYRIGHTED CONTENT. Unauthorized use, including screenshots, copying, misuse, reuse, or resale of any content from this app, is strictly prohibited. Our app monitors and records all screenshots and recordings. Violators will face strict legal action.

THIS IS COPYRIGHTED CONTENT. Unauthorized use, including screenshots, copying, misuse, reuse, or resale of any content from this app, is strictly prohibited. Our app monitors and records all screenshots and recordings. Violators will face strict legal action.

DISCLAIMER

THIS IS COPYRIGHTED CONTENT. Unauthorized use, including screenshots, copying, misuse, reuse, or resale of any content from this app, is strictly prohibited. Our app monitors and records all screenshots and recordings. Violators will face strict legal action.

ENDODONTICS

P.O.W.E.R NOTES SBQ 2

I. Failure of RCT is see.

Short obturation alone will not give pain if the canal was cleaned thoroughly. Short obturation can give an idea that the BMP is not done well. And there is left remnant. Therefore, the bacteria left in the apical 1/3rd causing the pain.

II. Side vented needle may offer safer irrigation than open ended needles in positive irrigation.

Negative pressure irrigation is superior to positive irrigation because it prevents the possibility of irrigant extrusion.

Endovac system uses the negative pressure to achieve safe irrigation of the apical canal.

Endovac is not given in the option, no negative pressure is given so answer is (E).

III. Technique of obturation to prevent the root #/cracks in the root.

Pushing the spreader in apical direction away from the walls of the root.

Reference:

Spreader is placed alongside the GP point and pushed apically with controlled force until it reaches the appropriate depth.

1mm from the end point of preparation.

The direction of force would be apically with no lateral rocking of the spreader to prevent root #.

In straight canals the spreader can be rotated at the same time as being pushed apically, this is contraindicated in curved canals.

IV. If these answers would have been there, then it's the best:

- Restorability of the tooth
- Extension of the #/crack line

Biological width is always consistent even in a healthy or in a tooth with periodontitis. So, no need to check BW. In case there's no proper ferrule crown lengthening should be done prior to placing a crown to avoid violence of BW.

THIS IS COPYRIGHTED CONTENT. Unauthorized use, including screenshots, copying, misuse, reuse, or resale of any content from this app, is strictly prohibited. Our app monitors and records all screenshots and recordings. Violators will face strict legal action.

DISCLAIMER

THIS IS COPYRIGHTED CONTENT. Unauthorized use, including screenshots, copying, misuse, reuse, or resale of any content from this app, is strictly prohibited. Our app monitors and records all screenshots and recordings. Violators will face strict legal action.

DISCLAIMER
THIS IS COPYRIGHTED CONTENT. Unauthorized use, including screenshots, copying, misuse, reuse, or resale of any content from this app, is strictly prohibited. Our app monitors and records all screenshots and recordings. Violators will face strict legal action.

DISCLAIMER
THIS IS COPYRIGHTED CONTENT. Unauthorized use, including screenshots, copying, misuse, reuse, or resale of any content from this app, is strictly prohibited. Our app monitors and records all screenshots and recordings. Violators will face strict legal action.

ENDODONTICS

SBQ 3

51 YEARS OLD COMPLAINS OF PAIN IN LOWER LEFT AREA, CAN'T BITE ON THE TOOTH 36 37, NO SENSITIVITY TO HOT LIQUIDS, MESIAL ROOT OF FIRST MOLAR LOOKS FUSED AND HAVE FILLINGS.

I. How will you investigate?

- A. Percussion
- B. Palpation
- C. Cold test
- D. Ept
- E. Hot test

II. Complication in doing RCT?

- A. First molar
- B. Root resorption
- C. Tooth inclination
- D. Curved roots

III. You took an iopa, and see 36 has a deep caries almost reaching the pulpal floor and a lot of secondary dentine is formed reducing the level of pulp chamber floor. Which anatomic structure will help you determine the floor level so that you don't perforate it?

- A. Cej
- B. Inclination of the tooth
- C. Mesiodistal width of tooth
- D. Buccolingual width of tooth

THIS IS COPYRIGHTED CONTENT. Unauthorized use, including screenshots, copying, misuse, reuse, or resale of any content from this app, is strictly prohibited. Our app monitors and records all screenshots and recordings. Violators will face strict legal action.

DISCLAIMER
THIS IS COPYRIGHTED CONTENT. Unauthorized use, including screenshots, copying, misuse, reuse, or resale of any content from this app, is strictly prohibited. Our app monitors and records all screenshots and recordings. Violators will face strict legal action.

THIS IS COPYRIGHTED CONTENT. Unauthorized use, including screenshots, copying, misuse, reuse, or resale of any content from this app, is strictly prohibited. Our app monitors and records all screenshots and recordings. Violators will face strict legal action.

DISCLAIMER

THIS IS COPYRIGHTED CONTENT. Unauthorized use, including screenshots, copying, misuse, reuse, or resale of any content from this app, is strictly prohibited. Our app monitors and records all screenshots and recordings. Violators will face strict legal action.

THIS IS COPYRIGHTED CONTENT. Unauthorized use, including screenshots, copying, misuse, reuse, or resale of any content from this app, is strictly prohibited. Our app monitors and records all screenshots and recordings. Violators will face strict legal action.

WINSPERT
P.O.W.E.R
NOTES

ENDODONTICS

P.O.W.E.R NOTES SBQ 3

- I. When a patient presents with pain and can't identify which tooth it is usually gives a provisional diagnosis of pulpitis as it's poorly localised. 2 teeth shows pain on biting reveals a early stage of PDL involvement.
Patient doesn't have sensitivity to hot liquids therefore, cold test should be done as the sensibility test to identify the tooth.
- II. 1st check with the x-rays and pictures that are provided to you.
Suppose you have all the findings,
Root resorption is the biggest complication as it hampers the prognosis because apical seal is the predominant factor for success. If all were present, then the biggest challenge would be root resorption.
2nd most difficult thing to handle is the curved roots as it's technique sensitive.
3rd most difficult thing to handle is the tooth inclination as perforation can take place.
- III. CEJ is the most important anatomic land mark for determining the location of pulp chambers and the root canal orifices.

ENDODONTICS

SBQ 4

A PATIENT HAS PAIN ON BITING IN THE UPPER RIGHT AREA WHICH COMES ONLY SOMETIMES ON BITING ON SOME THINGS, NO OTHER COMPLAINT. RESTORATION WAS PLACED FEW WEEKS BACK. WANTS TO CHECK WHY IS IT HAPPENING. ACCESS OPENING PIC GIVEN LATER IN ONE OF THE QUESTIONS.

I. How will you investigate?

- A. Percussion
- B. Palpation
- C. Sensibility
- D. CO2 test
- E. Ept
- F. Probing

II. Clinical picture given of access opening. We can see multiple small cracks in the coronal portion not involving the pulp chamber (also it was mentioned in the question), sufficient tooth structure remaining. Question mentions no crack is going to the pulp chamber. What do you think will be the prognosis?

- A. Fair
- B. Excellent
- C. Poor
- D. Hopeless
- E. Good

III. What is the complication in treating this tooth? (3 versions of iopa given). lopa upper first molar normal roots normal inclination adjacent teeth present/ lopa upper first molar severe inclination of the tooth /lopa upper first molar resorption of half of root in one root

- A. Extreme inclination
- B. Rubber dam
- C. Open apex/ apical seal
- D. Root resorption
- E. The fact that it's a first molar

IV. Which local anesthesia will you use for this tooth 16?

- A. Middle superior alveolar
- B. Infiltration buccally and palatally
- C. Greater palatine block
- D. Nasopalatine block

DISCLAIMER

THIS IS COPYRIGHTED CONTENT. Unauthorized use, including screenshots, copying, misuse, reuse, or resale of any content from this app, is strictly prohibited. Our app monitors and records all screenshots and recordings. Violators will face strict legal action.

DISCLAIMER
THIS IS COPYRIGHTED CONTENT. Unauthorized use, including screenshots, copying, misuse, reuse, or resale of any content from this app, is strictly prohibited. Our app monitors and records all screenshots and recordings. Violators will face strict legal action.

THIS IS COPYRIGHTED CONTENT. Unauthorized use, including screenshots, copying, misuse, reuse, or resale of any content from this app, is strictly prohibited. Our app monitors and records all screenshots and recordings. Violators will face strict legal action.

DISCLAIMER

ENDODONTICS

P.O.W.E.R NOTES SBQ 4

- I. It's not the pain in the area but it's the pain on biting. Restoration was placed few weeks back so; the pain may be due to a high point. Percussion test should be done as pain on biting is present.
- II. Multiple cracks are seen so it can't be excellent. Sufficient tooth structure is remaining so it can be fair. Guarded prognosis. Poor and hopeless teeth need extraction.
- III. Answer get changed depending on the version.
Version (A) - answer (E)
Version (B) - answer (A) because extreme inclination will lead to perforation if not following the long axis of the tooth during access cavity preparation.
Version (C) - answer (D) Root resorption is the biggest complication as it hampers the prognosis because apical seal is the predominant factor for success.
- IV. MSA is given to anesthetise the mesiobuccal root.
Greater palatine alone will not work.
Nasopalatine is not useful for 16.
Infiltration both buccally and palatally will work.

ENDODONTICS

SBQ 5

PATIENT HAD A CAVITY WHERE HE HAD SLIGHT PAIN A FEW WEEKS BEFORE BUT NOW IS OKAY, TOOTH IS TENDER TO PERCUSSION

I. What investigation will you do to diagnose?

- A. Cold test with CO2 snow
- B. Percussion
- C. Palpation
- D. Ept

II. What is pulp status?

- A. Reversible pulpitis,
- B. Symptomatic irreversible pulpitis,
- C. Asymptomatic irreversible pulpitis
- D. Necrosis

III. What is periapical status?

- A. Symptomatic apical periodontitis,
- B. Asymptomatic periapical periodontitis
- C. Acute periodontitis
- D. Chronic abscess

IV. What will be the treatment for the tooth?

- A. RCT
- B. Filling
- C. Pulpotomy

V. What is the diagnosis?

- A. Necrosis with acute apical periodontitis
- B. Necrosis with normal periapical tissue
- C. Necrosis with acute apical abscess
- D. Necrosis with chronic apical
- E. Periodontitis Necrosis with acute periodontitis

THIS IS COPYRIGHTED CONTENT. Unauthorized use, including screenshots, copying, misuse, reuse, or resale of any content from this app, is strictly prohibited. Our app monitors and records all screenshots and recordings. Violators will face strict legal action.

DISCLAIMER
THIS IS COPYRIGHTED CONTENT. Unauthorized use, including screenshots, copying, misuse, reuse, or resale of any content from this app, is strictly prohibited. Our app monitors and records all screenshots and recordings. Violators will face strict legal action.

THIS IS COPYRIGHTED CONTENT. Unauthorized use, including screenshots, copying, misuse, reuse, or resale of any content from this app, is strictly prohibited. Our app monitors and records all screenshots and recordings. Violators will face strict legal action.

DISCLAIMER

THIS IS COPYRIGHTED CONTENT. Unauthorized use, including screenshots, copying, misuse, reuse, or resale of any content from this app, is strictly prohibited. Our app monitors and records all screenshots and recordings. Violators will face strict legal action.

ENDODONTICS

P.O.W.E.R NOTES SBQ 5

- I. Patient had pain before but now there's no pain and but there's tenderness to percussion. Which means earlier there was a pulpal involvement but now it has progressed peri apically. Provisional diagnosis can be necrosis.
As investigation percussion will not be helpful because it's already done according to the information give. Therefore, cold test can be done to check the vitality of the tooth.
- II. There's no pain involvement so it can't be pulpitis. So pulpal status would be necrosis.
Symptomatic irreversible pulpitis will never turn into asymptomatic irreversible pulpitis. It can only involve the peri apically and cause necrosis.
Asymptomatic irreversible pulpitis is pulp polyp.
- III. Pulpal condition has progressed peri apically. There's tenderness to percussion. So periapical condition is symptomatic apical periodontitis.
- IV. When both pulp chamber and radicular pulp are inflamed, RCT is the only treatment that can save the tooth. Restoration or pulpotomy won't be sufficient.
- V. According to the above explanations, the diagnosis is necrosis with acute apical periodontitis. It's combination of pulpal and periapical diagnosis.

ENDODONTICS

SBQ 6

PAIN ON BITING & ABSCESS CASE

PATIENT CAME WITH PAIN ON BITING. THERE WAS A PATIENT WITH ABSCESS. A 64-YEAR-OLD COMES TO YOUR CLINIC FOR AN EXTRACTION.

- I. Which test would you perform to make a provisional diagnosis?
 - A. Cold test
 - B. EPT
 - C. Percussion test
 - D. Probing
- II. You extracted her tooth but she is able to pay only 50 percent right now and couldn't pay the full amount. She calls you from home saying she is in pain after 24 hours. What will you do?
 - A. Don't treat till she pays the full amount
 - B. Give her an appointment to come and see you in the clinic on emergency basis
 - C. Ask her to pay the full amount first before doing any treatment
 - D. Refer her to community clinic
- III. If you did not do the extraction for this patient the first time (as she cant pay the full fee) what could have been the complication then?
 - A. Spreading infection (it was given like ascending infection involving deep spaces)
 - B. Abscess
 - C. Tooth will continue to be carious.
- IV. After a few months she comes to you wanting an extraction of another tooth (infected tooth +no pain & wanting extraction). She has paid the full amount by now. But your area is now under ADA level-3 restrictions & is under the Hot Spot zone. How will you proceed? In the question it was mentioned that her X-ray was given (but there was no IOPA Attached) only the x-ray findings were written. Grossly carious lower first molar, caries extending to pulp with divergent roots and radiolucency around roots.
 - A. Use N95 mask and extract instead of surgical mask
 - B. Do emergency access opening and expatriate the pulp to relieve her pain under a dental rubber dam and give temporary restoration.
 - C. Refer to the hospital emergency dept.
 - D. Refer to oral surgeon
 - E. Prescribe Antibiotics.

DISCLAIMER

THIS IS COPYRIGHTED CONTENT. Unauthorized use, including screenshots, copying, misuse, reuse, or resale of any content from this app, is strictly prohibited. Our app monitors and records all screenshots and recordings. Violators will face strict legal action.

DISCLAIMER
THIS IS COPYRIGHTED CONTENT. Unauthorized use, including screenshots, copying, misuse, reuse, or resale of any content from this app, is strictly prohibited. Our app monitors and records all screenshots and recordings. Violators will face strict legal action.

ENDODONTICS

P.O.W.E.R NOTES SBQ 6

- I. In this case the patient has both pain on biting and abscess. Which means the pulpal condition has progressed peri apically and also, it's involving the soft tissue due to underlying infection. In the presence of the abscess sensibility test should be done to rule out necrosed pulp.

If it's given only pain on biting, then you would have selected percussion test. Because only pain on biting can be due to restoration, high point, TFO, fracture/crack or food impaction.

Both periodontal and periapical abscess have same clinical and radiographic features. Sensibility tests will be helpful to differentiate them. Periodontal abscess will give positive response to sensibility tests whereas periapical abscess will give negative response.

- II. According to TG any complication after extraction should be managed by the treating dentist.

According to the professionalism cluster you can't deny taking care of her even though she paid half. So, the answer is B.

- III. Patient came with acute apical abscess with grossly decayed necrosed pulp on the 1st day.

If the extraction is not performed on that day (A) could have happened. (B) and (C) are were already present at the time of arrival.

- IV. Use N95 mask and extract instead of surgical mask - Since the patient wants an extraction and the tooth is non-vital and carious till the pulp level, extraction is valid. Due to COVID ADA Level 3 restrictions, only urgent/emergency care is allowed, and proper PPE (like N95) is mandated.

RULE OUT -

Option B. Do emergency access opening and extirpate the pulp to relieve her pain under a dental rubber dam and give temporary restoration is not suitable here. She does not have pain. So, extirpation is not necessary.

Option C. Refer to the hospital emergency dept. is Not needed. This is not a life-threatening emergency that needs hospital care. Can be managed in dental setup as well.

Option D - Refer D. Refer to oral surgeon is not indication. General dentist can handle this extraction unless surgical or complicated extraction.

Option E - Prescribe antibiotics is ruled out. There're no active infection here and also, antibiotics are not a substitute for dental treatment. Hence, alone antibiotics without treatment is never indicated.

DISCLAIMER

THIS IS COPYRIGHTED CONTENT. Unauthorized use, including screenshots, copying, misuse, reuse, or resale of any content from this app, is strictly prohibited. Our app monitors and records all screenshots and recordings. Violators will face strict legal action.

ENDODONTICS

SBQ 7

SCENARIO WHERE BOTH MOLARS 36 AND 37 WERE RCT TREATED, HAD RADIOLUCENCY NEAR THE BIFURCATION AND (TOOTH WASN'T BROKEN TILL GUM LEVEL. IT WAS GROSSLY CARIOUS BUT IN A RESTORABLE CONDITION). PREVIOUS DENTIST HAD DONE THE RCT AND THE PATIENT COMES TO YOU AFTER 1 YEAR. YOU TOOK AN IOPA. IN THE IOPA YOU CAN SEE SECONDARY CARIES WHICH HAVE REACHED THE BIFURCATION AND THE ROOTS ARE SHORT.

I. How will you further investigate these teeth?

- A. Probing
- B. Sensibility
- C. Vitality test
- D. Percussion
- E. Mobility
- F. Use air from triplex syringe

II. In the iopa you can see secondary caries which have reached the bifurcation or maybe it said roots and the roots are short. How will you manage?

- A. Extract
- B. Refer to endo for retreatment
- C. Crown lengthening
- D. Refer to prosthodontics
- E. Restoration with Resin Modified GIC

III. Patient agrees to the treatment you suggested but he wants some time to think about the treatment options. So, for the meantime, how will you restore these temporarily? (i didn't have this question)

- A. Sealing with gic fuji vii
- B. Flowable composite
- C. Use preformed temp crowns as template
- D. Make him a temp crown with pro temp

IV. You inform the patient that this would have not happened if they timely got their final restorations done and that final restorations are very important. The patient said he was never told by the previous dentist about the crown and was upset that he was not informed. What would you advise?

- A. Offer to ask for his records from previous dentist after he signs record release form
- B. Ask him to talk to previous dentist and ask for the explanation
- C. Ask patient to complain about dentist
- D. Ask patient to take advice from Ahpra/ ADA
- E. Ask him to take to take legal advice

DISCLAIMER

THIS IS COPYRIGHTED CONTENT. Unauthorized use, including screenshots, copying, misuse, reuse, or resale of any content from this app, is strictly prohibited. Our app monitors and records all screenshots and recordings. Violators will face strict legal action.

DISCLAIMER
THIS IS COPYRIGHTED CONTENT. Unauthorized use, including screenshots, copying, misuse, reuse, or resale of any content from this app, is strictly prohibited. Our app monitors and records all screenshots and recordings. Violators will face strict legal action.

THIS IS COPYRIGHTED CONTENT. Unauthorized use, including screenshots, copying, misuse, reuse, or resale of any content from this app, is strictly prohibited. Our app monitors and records all screenshots and recordings. Violators will face strict legal action.

DISCLAIMER

ENDODONTICS

SBQ 7

v. What will you ask the patient while taking history to know about the problem?

- A. Pain
- B. Swelling
- C. Since the time it broke
- D. How it broke

P.O.W.E.R NOTES SBQ 7

- I. It's a RCT tooth so no need of doing the vitality/sensibility tests. There's no pain on biting to do the percussion test. Triplex syringe is not a test. Both probing and mobility are important, but clinical attachment loss is checked 1st and then mobility is checked. Probing is important to check the pockets, BOP, VRF. Can even do the cuspal loading to check the presence of any crack.
- II. It's a restorable tooth. Tooth doesn't have a crown so microleakage lead to secondary caries in bifurcation. Bicuspidation can be done and tooth can be treated as 2 separated teeth with 2 separate crowns. It's always good to refer if the tooth can be saved. If the treatment is beyond your expertise to handle then it's always good to refer. There's no emergency such as spread infection to address immediately.
- III. GIC fuji VII is flowable and can't use in this situation as it will not restore and protect the tooth from occlusal forces. Flowable composite will not save and protect the tooth from occlusal loads. Preformed temp crowns vs pro temp strip crown, pro temp strip crowns are the simplest and matching for tooth colour and used for permanent posterior. Preformed temp crowns will take more time to do adjustments as need to modify more for adaptation. Patient will get better marginal adaptation and operator chair side ease with pro temp strip crowns.
- IV. Don't get in between the situations where any complaints about the colleges and other dentists are present. Ethical management and the professionalism should be followed up. Since you don't have any access to the previous records and since you didn't go through their verbal discussion, tell the patient to ask from the previous dentist and clarify it with him/her. If still they are not happy then they by themselves can complain. Don't get involved in that. Don't advice the patient to take legal advice or follow AHPRA/ADA as the initial step.
- V. Pain is the greatest indicator of the RCT failure.

DISCLAIMER

THIS IS COPYRIGHTED CONTENT. Unauthorized use, including screenshots, copying, misuse, reuse, or resale of any content from this app, is strictly prohibited. Our app monitors and records all screenshots and recordings. Violators will face strict legal action.

THIS IS COPYRIGHTED CONTENT. Unauthorized use, including screenshots, copying, misuse, reuse, or resale of any content from this app, is strictly prohibited. Our app monitors and records all screenshots and recordings. Violators will face strict legal action.

DISCLAIMER
THIS IS COPYRIGHTED CONTENT. Unauthorized use, including screenshots, copying, misuse, reuse, or resale of any content from this app, is strictly prohibited. Our app monitors and records all screenshots and recordings. Violators will face strict legal action.

ENDODONTICS

SBQ 8

PULPITIS CASE

- I. While removing the caries of a reversible pulpitis you realise that if you continue you could expose the pulp? What do you do?
 - A. Remove infected dentin and leave affected dentin and restore with a definitive restoration.
 - B. Similar option with temporary restoration
 - C. Restoration after complete removal of infected dentine and CAOHP plus Temporary Filling
 - D. Restoration after partial removal of infected dentine with CAOHP plus Temporary Filling
- II. While removing the caries, there was an exposure of the pulp. What would you do?
 - A. Partial Pulpotomy with Tricalcium silicate base
 - B. Pulpotomy with Tricalcium silicate.
 - C. Calcium Hydroxide
- III. How does composite restoration gets the resistance & retention to the tooth?
 - A. Preparing cavity walls with undercuts.
 - B. Slots & grooves
 - C. Enamel & Dentine bonding
 - D. Cavity preparation in relation to providing retentive features.
- IV. He has an injury on his forehead in which a part of skin peeled off and the blood was oozing. What kind of injury is it?
 - A. Abrasion
 - B. Bruising
 - C. Laceration
 - D. Puncture

THIS IS COPYRIGHTED CONTENT. Unauthorized use, including screenshots, copying, misuse, reuse, or resale of any content from this app, is strictly prohibited. Our app monitors and records all screenshots and recordings. Violators will face strict legal action.

DISCLAIMER

THIS IS COPYRIGHTED CONTENT. Unauthorized use, including screenshots, copying, misuse, reuse, or resale of any content from this app, is strictly prohibited. Our app monitors and records all screenshots and recordings. Violators will face strict legal action.

THIS IS COPYRIGHTED CONTENT. Unauthorized use, including screenshots, copying, misuse, reuse, or resale of any content from this app, is strictly prohibited. Our app monitors and records all screenshots and recordings. Violators will face strict legal action.

THIS IS COPYRIGHTED CONTENT. Unauthorized use, including screenshots, copying, misuse, reuse, or resale of any content from this app, is strictly prohibited. Our app monitors and records all screenshots and recordings. Violators will face strict legal action.

DISCLAIMER
THIS IS COPYRIGHTED CONTENT. Unauthorized use, including screenshots, copying, misuse, reuse, or resale of any content from this app, is strictly prohibited. Our app monitors and records all screenshots and recordings. Violators will face strict legal action.

ENDODONTICS

P.O.W.E.R NOTES SBQ 8

- I. Block off/cut off the bacteria from all the nutritional supply so the remaining bacteria will die. Seal is the deal. Pulp will heal. Keep observing.
According to MID approach you can leave little amount of infected dentin.
TF is now not recommended for IPC therefore, (C) and (D) are ruled out.

- II. Only partial pulpotomy is sufficient as it is a mild exposure and no further bleeding after the exposure.

MTA= calcium silicate

- III. Composite restorations achieve resistance and retention through a combination of mechanical and chemical factors. Composites rely on bonding.

CHEMICAL FACTORS

Bonding Agents:

- **Adhesive Systems:** Modern dental adhesives create a chemical bond between the tooth structure and the composite material. These systems involve a primer that penetrates into the etched surface and a bonding agent that chemically bonds to both the primer and the composite.

Hybrid Layer Formation:

- **Dentin Bonding:** The adhesive penetrates the demineralized dentin, forming a hybrid layer that consists of resin tags interlocked with the dentin matrix. This hybrid layer provides significant chemical and micro-mechanical retention.

- IV. Peeling and oozing of blood is associated with abrasion.
A skin abrasion is a superficial injury to the skin, usually caused by friction or scraping against a rough surface. Abrasions are often referred to as "scrapes" or "grazes" and typically do not penetrate deeper than the epidermis, the outermost layer of the skin.

THIS IS COPYRIGHTED
CONTENT. Unauthorized use,
including screenshots,
copying, misuse, reuse, or
resale of any content from
this app, is strictly prohibited.
Our app monitors and records
all screenshots and
recordings. Violators will face
strict legal action.

DISCLAIMER

THIS IS COPYRIGHTED CONTENT. Unauthorized use, including screenshots, copying, misuse, reuse, or resale of any content from this app, is strictly prohibited. Our app monitors and records all screenshots and recordings. Violators will face strict legal action.

THIS IS COPYRIGHTED
CONTENT. Unauthorized use,
including screenshots,
copying, misuse, reuse, or
resale of any content from
this app, is strictly prohibited.
Our app monitors and records
all screenshots and
recordings. Violators will face
strict legal action.

DISCLAIMER

THIS IS COPYRIGHTED CONTENT. Unauthorized use, including screenshots, copying, misuse, reuse, or resale of any content from this app, is strictly prohibited. Our app monitors and records all screenshots and recordings. Violators will face strict legal action.

THIS IS COPYRIGHTED
CONTENT. Unauthorized use,
including screenshots,
copying, misuse, reuse, or
resale of any content from
this app, is strictly prohibited.
Our app monitors and records
all screenshots and
recordings. Violators will face
strict legal action.

WINSPERT
P.O.W.E.R
NOTES

DISCLAIMER

THIS IS COPYRIGHTED CONTENT. Unauthorized use, including screenshots, copying, misuse, reuse, or resale of any content from this app, is strictly prohibited. Our app monitors and records all screenshots and recordings. Violators will face strict legal action.

ENDODONTICS

SBQ 9

CASE OF RCT TREATED 46.IT WAS TREATED 2-3DAYS BACK & THE SEALER WAS INADEQUATELY PLACED. PATIENT HAD SEVERE PAIN. IOPA WAS ALSO GIVEN, IT WAS UNDERFILLED.

I. Which are the diagnostic tests for this case?

- A. Sensibility, palpation, percussion
- B. Selective cuspal loading test, Percussion, palpation, probing test
- C. Cuspal loading test
- D. Cuspal loading test, probing test, sensibility test.

II. What is the reason for the pain?

- A. Sealer material diffusing in to the bone
- B. Bacterial in periapical tissues
- C. Sealer binding insufficiently with dentine
- D. Underfilling of the canal

III. Why amalgam is better than composite?

- A. Its marginal integration is much more reliable.
- B. Aesthetic reasons
- C. Retention form is better

IV. If there was a fracture in this RCT treated tooth, which diagnostic test would be most reliable?

- A. Probing
- B. IOPA
- C. Sensibility testing
- D. Palpation

V. As the filling is short in apical third, What would be your next step in management?

- A. Do immediate refilling
- B. Retrograde Sealer to be filled in this appointment
- C. To wait and observe until the signs arise.

THIS IS COPYRIGHTED CONTENT. Unauthorized use, including screenshots, copying, misuse, reuse, or resale of any content from this app, is strictly prohibited. Our app monitors and records all screenshots and recordings. Violators will face strict legal action.

DISCLAIMER

THIS IS COPYRIGHTED CONTENT. Unauthorized use, including screenshots, copying, misuse, reuse, or resale of any content from this app, is strictly prohibited. Our app monitors and records all screenshots and recordings. Violators will face strict legal action.

THIS IS COPYRIGHTED CONTENT. Unauthorized use, including screenshots, copying, misuse, reuse, or resale of any content from this app, is strictly prohibited. Our app monitors and records all screenshots and recordings. Violators will face strict legal action.

DISCLAIMER
THIS IS COPYRIGHTED CONTENT. Unauthorized use, including screenshots, copying, misuse, reuse, or resale of any content from this app, is strictly prohibited. Our app monitors and records all screenshots and recordings. Violators will face strict legal action.

THIS IS COPYRIGHTED CONTENT. Unauthorized use, including screenshots, copying, misuse, reuse, or resale of any content from this app, is strictly prohibited. Our app monitors and records all screenshots and recordings. Violators will face strict legal action.

WINSPERT
P.O.W.E.R
NOTES

ENDODONTICS

P.O.W.E.R NOTES SBQ 9

- I. Presence of pain after 2-3 days of a RCT is not normal. May indicate a flare up. Bacteria must have reached the periapical area and inflammation must be present.
No point in doing sensibility tests in RCT teeth. So (A) and (D) are ruled out.
To check for VRF/periapical infection probing, percussion, palpation and cuspal loading should be done.
- II. There may be underfilled canals with no pain. Because shaping and cleaning of canals have been done adequately up to the working length.
If there is bacteria left over in the canal due to improper cleaning, that lead to pain.
- III. Amalgam has its corrosive property. Corrosive products will seal the margins. Therefore, its marginal integration is much more reliable.
In composite there's polymerisation shrinkage and this will lead to micro leakage.
- IV. In case of VRF, IOPA will be helpful as there will be "J-shaped" radiolucency, but this may not always be recognised in the radiograph due to overlapping. So (B) is not always reliable.
Probing with a narrow deep pocket is the most reliable technique for the VRF. Sensibility test is not helpful in RCT teeth.
- V. Retrograde is the periapical surgery. It's only done in the presence of a post. Because it's difficult to remove the post.
There's pain and underlying infection going on, so wait and observe is not a good thing to do.
Orthograde Rx/ immediate re-RCT is needed.

THIS IS COPYRIGHTED CONTENT. Unauthorized use, including screenshots, copying, misuse, reuse, or resale of any content from this app, is strictly prohibited. Our app monitors and records all screenshots and recordings. Violators will face strict legal action.

DISCLAIMER

THIS IS COPYRIGHTED CONTENT. Unauthorized use, including screenshots, copying, misuse, reuse, or resale of any content from this app, is strictly prohibited. Our app monitors and records all screenshots and recordings. Violators will face strict legal action.

DISCLAIMER
THIS IS COPYRIGHTED CONTENT. Unauthorized use, including screenshots, copying, misuse, reuse, or resale of any content from this app, is strictly prohibited. Our app monitors and records all screenshots and recordings. Violators will face strict legal action.

ENDODONTICS

SBQ 10

PATIENT COMPLAINS OF SENSITIVITY ON COLD DRINKS, IT OCCURS ONLY WHEN HE DRINKS COLD DRINKS, YOU TAKE AN IOPA AND SEE DEEP CARIES.

I. What is the diagnosis based on the symptoms?

- A. Reversible pulpitis
- B. Irreversible pulpitis
- C. Necrosis

II. How will you remove the caries?

- A. From outside to inside incrementally
- B. Remove all at once

III. (IOPA given) Lining present small amount of filling dislodged. What will the patient feel?

- A. Sensitivity on cold
- B. Sensitivity on sweet
- C. No sensitivity
- D. Sens on hot
- E. Pain

IV. While removing caries you realise that if you remove any further soft dentine, pulp will be exposed. What should be the management? (still caries is remaining, incomplete excavation then what will be the management?)

- A. DPC
- B. Pulpotomy
- C. RCT
- D. IPC and direct restoration extraction

THIS IS COPYRIGHTED CONTENT. Unauthorized use, including screenshots, copying, misuse, reuse, or resale of any content from this app, is strictly prohibited. Our app monitors and records all screenshots and recordings. Violators will face strict legal action.

THIS IS COPYRIGHTED CONTENT. Unauthorized use, including screenshots, copying, misuse, reuse, or resale of any content from this app, is strictly prohibited. Our app monitors and records all screenshots and recordings. Violators will face strict legal action.

THIS IS COPYRIGHTED CONTENT. Unauthorized use, including screenshots, copying, misuse, reuse, or resale of any content from this app, is strictly prohibited. Our app monitors and records all screenshots and recordings. Violators will face strict legal action.

THIS IS COPYRIGHTED CONTENT. Unauthorized use, including screenshots, copying, misuse, reuse, or resale of any content from this app, is strictly prohibited. Our app monitors and records all screenshots and recordings. Violators will face strict legal action.

DISCLAIMER

THIS IS COPYRIGHTED CONTENT. Unauthorized use, including screenshots, copying, misuse, reuse, or resale of any content from this app, is strictly prohibited. Our app monitors and records all screenshots and recordings. Violators will face strict legal action.

DISCLAIMER
THIS IS COPYRIGHTED CONTENT. Unauthorized use, including screenshots, copying, misuse, reuse, or resale of any content from this app, is strictly prohibited. Our app monitors and records all screenshots and recordings. Violators will face strict legal action.

ENDODONTICS

P.O.W.E.R NOTES SBQ 10

- I. Because it's not spontaneous pain and comes only for cold drinks. And it's not mentioned how long it lasts. So, It's reversible pulpitis.
- II. Removing the infected dentin 1st and then removing the affected dentin, can leave the affected dentin behind. So should remove outside to inside incrementally.
- III. Liner is only present on the floor of the cavity. So dentinal tubules are protected on the floor of the cavity. So, the patient will not feel sensitivity.
(Same Question given in ADC Sample Question file - Same Answer No Sensitivity)
- IV. Still caries is remaining, incomplete excavation. Always best to do conservative Rx. You can leave the little amount of infected and proceed ahead with IPC and you can review the tooth. Tooth should be symptom free to leave infected pulp behind.

ENDODONTICS

SBQ 11

A 10 WEEKS PREGNANT WOMAN CAME WITH DEEP CARIES AND SOME SYMPTOMS, CARIES ALMOST REACHING THE PULP, WILL NEED RCT. RCT WAS DONE AND PULP EXTIRPATED, TEMPORARY DRESSING GIVEN.

I. Which pregnancy period is safe for elective dental treatment?

- A. Between 14 to 28 weeks
- B. Between 32 onwards
- C. Between 24 weeks to 9 weeks
- D. Between 10 weeks to 30 weeks

II. Same patient didn't complete the treatment and came at 32 weeks in pain. Patient is 32 weeks pregnant. Which medication is safe to give?

- A. Naproxen
- B. Celecoxib
- C. Paracetamol
- D. Ibuprofen

III. Now she (32 weeks) comes for her regular scaling appointment. On the dental chair in a reclined position she started feeling dizziness, sweating, nausea. What is the most likely cause?

- A. Vaso-vagal Syncope
- B. Supine hypotensive syndrome
- C. Pre-eclampsia

IV. She came after giving birth and is breastfeeding. Which painkiller will you prescribe her?

- A. Paracetamol
- B. Naproxen
- C. Celecoxib
- D. Oxycontin

V. She asked about the future child and how to clean the child's teeth?

- A. Brush with 500-550 ppm tooth paste pea sized at 18 months
- B. At 24 months brush with 1000 ppm smear of it
- C. Clean with 500-550 ppm FL toothpaste at 6 months of age

DISCLAIMER

THIS IS COPYRIGHTED CONTENT. Unauthorized use, including screenshots, copying, misuse, reuse, or resale of any content from this app, is strictly prohibited. Our app monitors and records all screenshots and recordings. Violators will face strict legal action.

DISCLAIMER
THIS IS COPYRIGHTED CONTENT. Unauthorized use, including screenshots, copying, misuse, reuse, or resale of any content from this app, is strictly prohibited. Our app monitors and records all screenshots and recordings. Violators will face strict legal action.

THIS IS COPYRIGHTED CONTENT. Unauthorized use, including screenshots, copying, misuse, reuse, or resale of any content from this app, is strictly prohibited. Our app monitors and records all screenshots and recordings. Violators will face strict legal action.

DISCLAIMER

ENDODONTICS

P.O.W.E.R NOTES SBQ 11

- I. For elective dental treatment best is → 2nd trimester
Emergency Rx can be done → 1st and 2nd trimester
High chance of preterm labour → 3rd trimester
- II. Up to 32 weeks it's safe to give NSAIDS. Ibuprofen is the safest among NSAIDS. But after 32 weeks you can't give NSAIDS, only PCM is recommended.
- III. Supine hypotensive syndrome (SHS) is a condition that can occur when a pregnant woman lies flat on her back, particularly in the later stages of pregnancy. The weight of the uterus compresses the inferior vena cava, a large vein that carries blood from the lower part of the body to the heart. This compression can reduce blood flow to the heart, resulting in decreased cardiac output and a drop in blood pressure.

This can cause symptoms such as:

- Dizziness or lightheadedness
- Nausea
- Sweating
- Pallor (paleness)
- Rapid heartbeat (tachycardia)

In severe cases, it can lead to fainting (syncope). To prevent SHS, it is generally recommended that pregnant women, especially in the second and third trimesters, avoid lying flat on their backs and instead sleep or rest on their side, preferably the left side. This position helps to improve blood flow and reduce the risk of symptoms associated with SHS.

Pre-eclampsia is a pregnancy complication characterized by high blood pressure and signs of damage to other organs, most often the liver and kidneys. It typically occurs after 20 weeks of pregnancy in women whose blood pressure had previously been normal. If untreated, pre-eclampsia can lead to serious, even fatal, complications for both the mother and the baby.

- IV. If NSAID is required in breast feeding patient diclofenac or ibuprofen is preferred. In breast feeding only ibuprofen and PCM is preferred.
(reference TG page no. 286 table 28)
- IV. Fluoride toothpaste is recommended after 18 months of age. From 18 months to 6 yrs of age, it's preferred to use 500-550ppm fluoridated toothpaste.
(reference TG page no. 67 table 7)

DISCLAIMER

THIS IS COPYRIGHTED CONTENT. Unauthorized use, including screenshots, copying, misuse, reuse, or resale of any content from this app, is strictly prohibited. Our app monitors and records all screenshots and recordings. Violators will face strict legal action.

DISCLAIMER

THIS IS COPYRIGHTED CONTENT. Unauthorized use, including screenshots, copying, misuse, reuse, or resale of any content from this app, is strictly prohibited. Our app monitors and records all screenshots and recordings. Violators will face strict legal action.

THIS IS COPYRIGHTED CONTENT. Unauthorized use, including screenshots, copying, misuse, reuse, or resale of any content from this app, is strictly prohibited. Our app monitors and records all screenshots and recordings. Violators will face strict legal action.

DISCLAIMER

ENDODONTICS

SBQ 12

MR. GOYAL 30 YEARS OLD, CAME FOR TREATMENT. WANTS BLEACHING FOR HIS TEETH. ALSO HAS PAIN WITH 36, ALSO HAS RESTORATION, WANTS TO GET 36 TREATED AND HAS EROSION, DRINKS A LOT OF COCA COLA, NEVER VISITED A DENTIST IN 3-5 YEARS, POOR ORAL HYGIENE.

I. What will be the etiology of the lesions?

- A. Coca cola
- B. Poor oral hygiene

II. Iopa given and you diagnose that it is irreversible pulpitis. You want to do RCT. But the patient refuses Rubber Dam. What will you do? (Iopa given)

- A. Refer to endo
- B. Give alternate options like extraction
- C. Respect his decision make him sign a waiver
- D. Refuse to treat

III. Wants to get bleaching done regardless. What will you tell him?

- A. Need to stabilize his condition first
- B. Do tooth whitening, and make her sign waiver

THIS IS COPYRIGHTED CONTENT. Unauthorized use, including screenshots, copying, misuse, reuse, or resale of any content from this app, is strictly prohibited. Our app monitors and records all screenshots and recordings. Violators will face strict legal action.

THIS IS COPYRIGHTED CONTENT. Unauthorized use, including screenshots, copying, misuse, reuse, or resale of any content from this app, is strictly prohibited. Our app monitors and records all screenshots and recordings. Violators will face strict legal action.

THIS IS COPYRIGHTED CONTENT. Unauthorized use, including screenshots, copying, misuse, reuse, or resale of any content from this app, is strictly prohibited. Our app monitors and records all screenshots and recordings. Violators will face strict legal action.

DISCLAIMER

THIS IS COPYRIGHTED CONTENT. Unauthorized use, including screenshots, copying, misuse, reuse, or resale of any content from this app, is strictly prohibited. Our app monitors and records all screenshots and recordings. Violators will face strict legal action.

DISCLAIMER
THIS IS COPYRIGHTED CONTENT. Unauthorized use, including screenshots, copying, misuse, reuse, or resale of any content from this app, is strictly prohibited. Our app monitors and records all screenshots and recordings. Violators will face strict legal action.

ENDODONTICS

P.O.W.E.R NOTES SBQ 12

- I. In the question it's mentioned about erosive lesions. The history denotes that the patient drinks a lot of acidic drinks (coca cola). Acidic drinks lead to erosion.
- II. RCT must not be performed without a rubber dam.
 - Because there's a high risk that the patient may aspirate files without a rubber dam.
 - It helps to maintain a sterile area without saliva and blood contamination.
 - It helps to prevent sodium hypochlorite accidents.

**If a patient refuses rubber dam you can offer these options:*

- Refer to an endodontist if the tooth is restorable.
- Give alternate options like extraction if the tooth is not restorable.

**You must see the picture and the IOPA to decide the restorability of the tooth.*

- III. Before performing a bleaching treatment, you must stabilize his conditions.

If erosions are present you need to control it with habit intervention and then temporisation.

If caries is detected, you must temporise them.

Because bleaching may lead to further damage if the dentine is exposed to the oral cavity and lead to more sensitivity and teeth may undergo with pulpitis.

After 2 weeks time of bleaching we can proceed ahead with the permanent restorations. This waiting time period is to stabilize the colour after a bleaching treatment.

THIS IS COPYRIGHTED CONTENT. Unauthorized use, including screenshots, copying, misuse, reuse, or resale of any content from this app, is strictly prohibited. Our app monitors and records all screenshots and recordings. Violators will face strict legal action.

DISCLAIMER

THIS IS COPYRIGHTED CONTENT. Unauthorized use, including screenshots, copying, misuse, reuse, or resale of any content from this app, is strictly prohibited. Our app monitors and records all screenshots and recordings. Violators will face strict legal action.

DISCLAIMER
THIS IS COPYRIGHTED CONTENT. Unauthorized use, including screenshots, copying, misuse, reuse, or resale of any content from this app, is strictly prohibited. Our app monitors and records all screenshots and recordings. Violators will face strict legal action.

DISCLAIMER
THIS IS COPYRIGHTED CONTENT. Unauthorized use, including screenshots, copying, misuse, reuse, or resale of any content from this app, is strictly prohibited. Our app monitors and records all screenshots and recordings. Violators will face strict legal action.

ENDODONTICS

SBQ 13

PHOTOS OF 25,26,27 GIVEN. THE PATIENT HAD RCT TREATED DONE ONE YEAR AGO. AND 26, 27 WERE BROKEN DOWN, NOW THE PATIENT WANTED TO RESTORE THEM. 26 MESIAL SUBGINGIVAL CAVITY EXTENSION, 27 MESIAL, PALATAL AND DISTAL SUBGINGIVAL CAVITY.

I. What will you ask the patient while taking history to know about the problem?

- A. Whether patient have pain
- B. How the teeth were broken
- C. Time since teeth broke
- D. Swelling

II. Which of the following investigations will help with a diagnosis?

- A. Probing
- B. Percussion
- C. Cold test
- D. X-RAY

III. How do you restore 26 and 27 (the difficulty in this question for me is whether 26 needed crown lengthening, as only half of mesial side for 26 cavity is subgingival)

- A. Core and crown for 26, Crown lengthening for 27
- B. Crown lengthening for 26 and 27
- C. Crown lengthening and post and core wrt 26,27 (i think this was the answer the tooth was having insufficient ferrule)
- D. Extraction

IV. Previous dentist did not say about crown to patient after RCT

- A. Advise patient to talk to previous dentist
- B. You request the previous dentist to transfer records of the patient
- C. You ask the patient to report the previous dentist to AHPRA

V. Patient wants to think about the proposed treatment plan and come back, how would you temporize them?

- A. Do a temporary crown with a prefabricated crown temp.
- B. GIC
- C. Flowable composite
- D. Do temporary with luxatemp

DISCLAIMER

THIS IS COPYRIGHTED CONTENT. Unauthorized use, including screenshots, copying, misuse, reuse, or resale of any content from this app, is strictly prohibited. Our app monitors and records all screenshots and recordings. Violators will face strict legal action.

DISCLAIMER
THIS IS COPYRIGHTED CONTENT. Unauthorized use, including screenshots, copying, misuse, reuse, or resale of any content from this app, is strictly prohibited. Our app monitors and records all screenshots and recordings. Violators will face strict legal action.

THIS IS COPYRIGHTED CONTENT. Unauthorized use, including screenshots, copying, misuse, reuse, or resale of any content from this app, is strictly prohibited. Our app monitors and records all screenshots and recordings. Violators will face strict legal action.

DISCLAIMER

ENDODONTICS

P.O.W.E.R NOTES SBQ 13

- I. Presence of pain and swelling are signs of RCT failure. So among the given pain is the most important symptom to ask about.
- II. It's an RCT tooth so no need of doing the vitality/sensibility tests.
Both probing and percussion are important, but XRAY is the most important investigation among all. Because with the help of the XRAY you would be able to see the extending of the obturation whether it's short or over obturated, is there any peri apical radiolucency or root resorption, is there any missed canal. So, with the help of the XRAY we can get a clear idea about RCT tooth.
- III. In this case,
26-mesial wall has sub gingival cavity
27-mesial, distal, palatal have subgingival cavity
When to give an onlay?
When the tooth structure/the walls are all in contact in 360 degree up to the middle 3rd or occlusally.
When to give core build up + crown?
When 1 or more walls are broken below the middle 3rd and proper ferrule is available.
When to do crown lengthening+ core build up+ crown?
When 1 or more walls are broken up to the CEJ or below CEJ crown lengthening is done to create a ferrule to retain the crown.
Both 26 and 27 has subgingival cavities so need crown lengthening + post and core.
- IV. Don't get in between the situations where any complaints about the colleges and other dentists are present. Ethical management and the professionalism should be followed up. Since you don't have any access to the previous records and since you didn't go through their verbal discussion, tell the patient to ask from the previous dentist and clarify it with him/her. If still they are not happy then they by themselves can complain. Don't get involved in that. Don't advice the patient to take legal advice or follow AHPRA/ADA as the initial step.
- V. When comparing pre-fabricated temporary crowns and Luxatemp, there are several factors to consider, including material, application, durability, aesthetics, and cost.

PRE-FABRICATED TEMPORARY CROWNS

Material:

- Typically made from materials like polycarbonate, composite resin, or acrylic.

DISCLAIMER

THIS IS COPYRIGHTED CONTENT. Unauthorized use, including screenshots, copying, misuse, reuse, or resale of any content from this app, is strictly prohibited. Our app monitors and records all screenshots and recordings. Violators will face strict legal action.

DISCLAIMER

THIS IS COPYRIGHTED CONTENT. Unauthorized use, including screenshots, copying, misuse, reuse, or resale of any content from this app, is strictly prohibited. Our app monitors and records all screenshots and recordings. Violators will face strict legal action.

DISCLAIMER

THIS IS COPYRIGHTED CONTENT. Unauthorized use, including screenshots, copying, misuse, reuse, or resale of any content from this app, is strictly prohibited. Our app monitors and records all screenshots and recordings. Violators will face strict legal action.

ENDODONTICS

P.O.W.E.R NOTES SBQ 13

Application:

- These crowns are pre-made in various sizes and shapes to fit different teeth.
- They can be adjusted and trimmed chairside to fit the patient's tooth.
- They are cemented onto the prepared tooth using temporary cement.

Durability:

- Generally strong enough to last several weeks to a few months, depending on the material and patient's oral habits.

Aesthetics:

- Pre-fabricated crowns might not perfectly match the patient's natural teeth in terms of color and shape.
- They are often less aesthetic compared to custom-made options.

Cost:

- Usually less expensive than custom-made temporary crowns, including those made from Luxatemp.

LUXATEMP

Material:

- Luxatemp is a bisacrylic composite resin specifically designed for temporary crowns and bridges.

Application:

- It is custom-made directly in the dental office. The dentist creates a mold or uses a matrix to shape the Luxatemp material around the prepared tooth.
- This allows for a more precise fit and better aesthetics.

Durability:

- Luxatemp is known for its strength and durability, providing a reliable temporary solution.
- It can withstand normal biting and chewing forces.

Aesthetics:

- Luxatemp provides a more natural-looking appearance compared to pre-fabricated crowns.
- It can be color-matched to the patient's natural teeth, offering better aesthetics.

Cost:

- Typically more expensive than pre-fabricated crowns due to the custom fabrication process and higher material cost.

DISCLAIMER

THIS IS COPYRIGHTED CONTENT. Unauthorized use, including screenshots, copying, misuse, reuse, or resale of any content from this app, is strictly prohibited. Our app monitors and records all screenshots and recordings. Violators will face strict legal action.

DISCLAIMER

THIS IS COPYRIGHTED CONTENT. Unauthorized use, including screenshots, copying, misuse, reuse, or resale of any content from this app, is strictly prohibited. Our app monitors and records all screenshots and recordings. Violators will face strict legal action.

THIS IS COPYRIGHTED CONTENT. Unauthorized use, including screenshots, copying, misuse, reuse, or resale of any content from this app, is strictly prohibited. Our app monitors and records all screenshots and recordings. Violators will face strict legal action.

DISCLAIMER

ENDODONTICS

P.O.W.E.R NOTES SBQ 13

SUMMARY

Pre-Fabricated Temporary Crowns:

- Pros: *Quick application, lower cost.*
- Cons: *May not fit as well, less aesthetic.*

Luxatemp:

- Pros: *Custom fit, better aesthetics, durable.*
- Cons: *Higher cost, more time-consuming application.*

The choice between the two often depends on the specific needs of the patient, the dentist's preference, and budget considerations.

THIS IS COPYRIGHTED CONTENT. Unauthorized use, including screenshots, copying, misuse, reuse, or resale of any content from this app, is strictly prohibited. Our app monitors and records all screenshots and recordings. Violators will face strict legal action.

THIS IS COPYRIGHTED CONTENT. Unauthorized use, including screenshots, copying, misuse, reuse, or resale of any content from this app, is strictly prohibited. Our app monitors and records all screenshots and recordings. Violators will face strict legal action.

THIS IS COPYRIGHTED CONTENT. Unauthorized use, including screenshots, copying, misuse, reuse, or resale of any content from this app, is strictly prohibited. Our app monitors and records all screenshots and recordings. Violators will face strict legal action.

DISCLAIMER

THIS IS COPYRIGHTED CONTENT. Unauthorized use, including screenshots, copying, misuse, reuse, or resale of any content from this app, is strictly prohibited. Our app monitors and records all screenshots and recordings. Violators will face strict legal action.

DISCLAIMER
THIS IS COPYRIGHTED CONTENT. Unauthorized use, including screenshots, copying, misuse, reuse, or resale of any content from this app, is strictly prohibited. Our app monitors and records all screenshots and recordings. Violators will face strict legal action.

ENDODONTICS

SBQ 14

QUESTION ON REVERSIBLE PULPITIS. FURTHER REMOVAL OF CARIES WILL CAUSE PULPAL EXPOSURE. WHAT WILL YOU DO? (MATURE TEETH)

- A. Remove all from the margins, keep infected in the center and place GIC.
- B. REMOVE ALL infected dentin and give permanent restoration.
- C. Remove step wise, put temporary, recall in 3-6 months
- D. Remove infected, if exposed, do partial pulpotomy, fast setting caoh, GIC and composite.
- E. Remove infected, if exposed, do partial pulpotomy, calcium silicate and composite

P.O.W.E.R NOTES SBQ 14

According to MID article;

GIC achieves chemical adhesion to tooth structure via an ion exchange mechanism, creating a stable acid resistance ion exchange layer interface, preventing micro leakage and bacterial contamination of pulp.

Leaving small amount of infected dentin in a cavity does not seem to result in caries progression, pulpitis or pulp death, provided the overlying restoration has a perfect seal.

Need to remove caries from the margins and can leave in the centre.
Now TF is not used in IPC. So, option (C) is ruled out.

Removing "all infected" dentin can lead to pulpal exposure. So option (B) is ruled out.

Both option (D) AND (E) are correct. In (D) sandwich technique is used. In (E) MTA is used, which is superior to Ca(OH)₂. So option (E) is better.

But among all option (E) is the best according to MID guidelines.

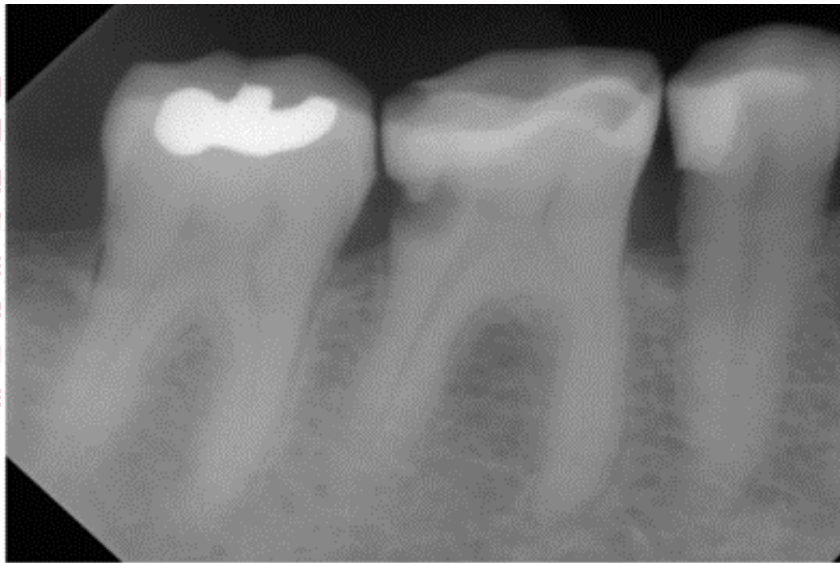DISCLAIMER

THIS IS COPYRIGHTED CONTENT. Unauthorized use, including screenshots, copying, misuse, reuse, or resale of any content from this app, is strictly prohibited. Our app monitors and records all screenshots and recordings. Violators will face strict legal action.

ENDODONTICS

SBQ 15

A YOUNG ADULT FEMALE, IOPA GIVEN (EXACT SAME PICTURE OF XRAY AS IN THE ADC SAMPLE QUESTION IN WEBSITE, LESION GIVEN ON DISTAL SIDE). PATIENT HAD PAIN ON HER LOWER LEFT HAND SIDE WHILE EATING COLD AND SWEET FOODS AND LITTLE DISCOMFORT IN THAT AREA, SPECIALLY PATIENT COMPLAINS ABOUT BAD TASTE COMING FROM LEFT POSTERIOR LOWER SITE. MEDICALLY FIT AND WELL.



- I. Other than proximal cavitation seen in iopa, what else do you find significant connected to the chief complaint in x-ray?
 - A. Periapical radiolucency on mesial root
 - B. Mesial canal of 36 obliterated
 - C. Root fracture
 - D. Open contacts on mesial and distal of 36
- II. What is the most appropriate material to fill this tooth?
 - A. Resin composite
 - B. Gic
 - C. Amalgam because it has more marginal integrity
 - D. Rmgic
- III. What is the most appropriate test to confirm the diagnosis for this case?
 - A. Percussion
 - B. Hot GP point
 - C. Co2 spray
 - D. Probing test

DISCLAIMER

THIS IS COPYRIGHTED CONTENT. Unauthorized use, including screenshots, copying, misuse, reuse, or resale of any content from this app, is strictly prohibited. Our app monitors and records all screenshots and recordings. Violators will face strict legal action.

DISCLAIMER
THIS IS COPYRIGHTED CONTENT. Unauthorized use, including screenshots, copying, misuse, reuse, or resale of any content from this app, is strictly prohibited. Our app monitors and records all screenshots and recordings. Violators will face strict legal action.

THIS IS COPYRIGHTED CONTENT. Unauthorized use, including screenshots, copying, misuse, reuse, or resale of any content from this app, is strictly prohibited. Our app monitors and records all screenshots and recordings. Violators will face strict legal action.

DISCLAIMER

ENDODONTICS

P.O.W.E.R NOTES SBQ 15

- I. Chief complaints are associated with the food impaction and pulpitis. Option (A), (B), (C) are not related. But option (D), open contacts lead to food impaction.
- II. Resin composites are best in class 2 restorations.
GIC is not a permanent restoration.
RMGIC is best in root caries. Root caries needs more chemical bonding than physical bonding.
Amalgam is not preferred nowadays as it's aesthetically inferior though it has more marginal integrity. Composites binds well with enamel and dentin; good retention is seen with composites.
- III. It's a pulpitis case, so sensibility test will be helpful. Among sensibility test cold test is the best.

DISCLAIMER

THIS IS COPYRIGHTED CONTENT. Unauthorized use, including screenshots, copying, misuse, reuse, or resale of any content from this app, is strictly prohibited. Our app monitors and records all screenshots and recordings. Violators will face strict legal action.

DISCLAIMER
THIS IS COPYRIGHTED CONTENT. Unauthorized use, including screenshots, copying, misuse, reuse, or resale of any content from this app, is strictly prohibited. Our app monitors and records all screenshots and recordings. Violators will face strict legal action.

DISCLAIMER

THIS IS COPYRIGHTED CONTENT. Unauthorized use, including screenshots, copying, misuse, reuse, or resale of any content from this app, is strictly prohibited. Our app monitors and records all screenshots and recordings. Violators will face strict legal action.

ENDODONTICS

SBQ 16

MAN WITH RCT TREATED TEETH A FEW MONTHS AGO WITH BARELY ANY CROWN STRUCTURE REMAINING (36 AND 36) WITH THE CORONAL PART SEALED WITH A PERMANENT FILLING MATERIAL. PATIENT HAS RETURNED AFTER SOME TIME TO HAVE CROWNS PUT. NO PAIN IN THE LAST FEW WEEKS.

I. What will you ask the patient regarding these teeth?

- A. History of pain
- B. Medical history
- C. Dental history

II. What investigation will you perform to confirm?

- A. Pulp sensibility
- B. IOPA
- C. OPG
- D. Percussion
- E. Probing

III. What is the best way to restore these two teeth (not enough coronal structure at all)?

- A. Crown lengthening, Post and core build up and PFM
- B. Post and core and crown
- C. Pins and restoration

THIS IS COPYRIGHTED CONTENT. Unauthorized use, including screenshots, copying, misuse, reuse, or resale of any content from this app, is strictly prohibited. Our app monitors and records all screenshots and recordings. Violators will face strict legal action.

DISCLAIMER

THIS IS COPYRIGHTED CONTENT. Unauthorized use, including screenshots, copying, misuse, reuse, or resale of any content from this app, is strictly prohibited. Our app monitors and records all screenshots and recordings. Violators will face strict legal action.

DISCLAIMER
THIS IS COPYRIGHTED CONTENT. Unauthorized use, including screenshots, copying, misuse, reuse, or resale of any content from this app, is strictly prohibited. Our app monitors and records all screenshots and recordings. Violators will face strict legal action.

ENDODONTICS

P.O.W.E.R NOTES SBQ 16

- I. Because if there was pain few months back and then subsided eventually, that means it require re-RCT. So, history of pain is more important.
- II. In a RCT tooth IOPA is the best investigation as it gives the status of RCT. Percussion and probing comes next. Pulp sensibility test is not useful in RCT tooth. OPG will not give a clear image compared to IOPA.
- III. If there's not enough coronal structure but if you still want to save the tooth, then must perform crown lengthening with post and core. Post will replace only the missing wall. Inadequate ferrule will be gained with crown lengthening. 1.5-2mm ferrule is needed in 360degree to prevent the dislodgment of the crown.

THIS IS COPYRIGHTED CONTENT. Unauthorized use, including screenshots, copying, misuse, reuse, or resale of any content from this app, is strictly prohibited. Our app monitors and records all screenshots and recordings. Violators will face strict legal action.

THIS IS COPYRIGHTED CONTENT. Unauthorized use, including screenshots, copying, misuse, reuse, or resale of any content from this app, is strictly prohibited. Our app monitors and records all screenshots and recordings. Violators will face strict legal action.

THIS IS COPYRIGHTED CONTENT. Unauthorized use, including screenshots, copying, misuse, reuse, or resale of any content from this app, is strictly prohibited. Our app monitors and records all screenshots and recordings. Violators will face strict legal action.

DISCLAIMER

THIS IS COPYRIGHTED CONTENT. Unauthorized use, including screenshots, copying, misuse, reuse, or resale of any content from this app, is strictly prohibited. Our app monitors and records all screenshots and recordings. Violators will face strict legal action.

DISCLAIMER
THIS IS COPYRIGHTED CONTENT. Unauthorized use, including screenshots, copying, misuse, reuse, or resale of any content from this app, is strictly prohibited. Our app monitors and records all screenshots and recordings. Violators will face strict legal action.

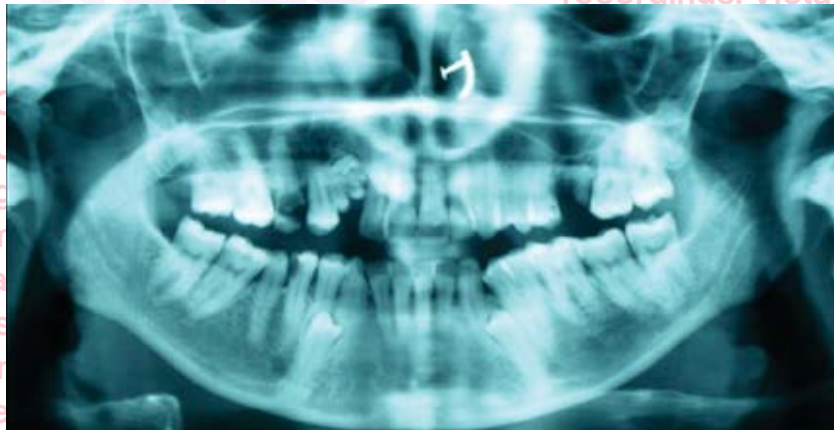
DISCLAIMER

THIS IS COPYRIGHTED CONTENT. Unauthorized use, including screenshots, copying, misuse, reuse, or resale of any content from this app, is strictly prohibited. Our app monitors and records all screenshots and recordings. Violators will face strict legal action.

ENDODONTICS

SBQ 17

PATIENT NEEDED RCT ON AN UPPER 1ST MOLAR, (IOPA GIVEN, PATIENT'S MOLAR HAD ROOTS THAT WERE BENT IN THE MIDDLE THIRD PORTION, MIDDLE THIRD OF ROOTS WERE ALSO IMPOSED ON THE MAXILLARY SINUS) WHAT COMPLICATION WOULD MOST LIKELY TO OCCUR DURING RCT? (CALCIFIED CHAMBER AND THIN CANALS IOPA GIVEN)



- A. Pneumatization of sinus
- B. Difficulty in negotiating the canal
- C. Difficult to put rubber dam

P.O.W.E.R NOTES SBQ 17

- I. In the presence of calcified chambers and thin canals in a maxillary molar tooth it's difficult to negotiate the canals. Maxillary molar tooth has difficult canal anatomy.

With the help of temporary endo build-up, it's not difficult to put a rubber dam.

THIS IS COPYRIGHTED CONTENT. Unauthorized use, including screenshots, copying, misuse, reuse, or resale of any content from this app, is strictly prohibited. Our app monitors and records all screenshots and recordings. Violators will face strict legal action.

DISCLAIMER

THIS IS COPYRIGHTED CONTENT. Unauthorized use, including screenshots, copying, misuse, reuse, or resale of any content from this app, is strictly prohibited. Our app monitors and records all screenshots and recordings. Violators will face strict legal action.

DISCLAIMER
THIS IS COPYRIGHTED CONTENT. Unauthorized use, including screenshots, copying, misuse, reuse, or resale of any content from this app, is strictly prohibited. Our app monitors and records all screenshots and recordings. Violators will face strict legal action.

THIS IS COPYRIGHTED CONTENT. Unauthorized use, including screenshots, copying, misuse, reuse, or resale of any content from this app, is strictly prohibited. Our app monitors and records all screenshots and recordings. Violators will face strict legal action.

DISCLAIMER

ENDODONTICS

SBQ 18

14 YEAR OLD COMES WITH MOTHER WITH HISTORY OF PULPITIS AND SYMPTOMS WERE OF IRREVERSIBLE PULPITIS AND SHE IS AGAINST X-RAY RADIATIONS WHAT WILL YOU SAY TO MOTHER.

- A. Defer the treatment as we can't do treatment without x ray
- B. Give alternate options like extraction
- C. Do rct without x ray
- D. Educate patient on radiation

P.O.W.E.R NOTES SBQ 18

- I. This is a professionalism question. For both extraction and RCT, IOPA is needed. And can't differ the treatment as the patient is in pain. So, you must educate the patient about the radiation.

THIS IS COPYRIGHTED CONTENT. Unauthorized use, including screenshots, copying, misuse, reuse, or resale of any content from this app, is strictly prohibited. Our app monitors and records all screenshots and recordings. Violators will face strict legal action.

DISCLAIMER

THIS IS COPYRIGHTED CONTENT. Unauthorized use, including screenshots, copying, misuse, reuse, or resale of any content from this app, is strictly prohibited. Our app monitors and records all screenshots and recordings. Violators will face strict legal action.

THIS IS COPYRIGHTED CONTENT. Unauthorized use, including screenshots, copying, misuse, reuse, or resale of any content from this app, is strictly prohibited. Our app monitors and records all screenshots and recordings. Violators will face strict legal action.

THIS IS COPYRIGHTED CONTENT. Unauthorized use, including screenshots, copying, misuse, reuse, or resale of any content from this app, is strictly prohibited. Our app monitors and records all screenshots and recordings. Violators will face strict legal action.

DISCLAIMER
THIS IS COPYRIGHTED CONTENT. Unauthorized use, including screenshots, copying, misuse, reuse, or resale of any content from this app, is strictly prohibited. Our app monitors and records all screenshots and recordings. Violators will face strict legal action.

ENDODONTICS

SBQ 19

DANNY IS A LABOURER, HE IS 30 YEARS OLD, WORKING ON A CONSTRUCTION SITE NEAR YOUR CLINIC, HE HAS PAIN IN TOOTH 11, HE SMOKES 5-10 CIGARETTES WHAT SYMPTOMS INDICATE HE HAS REVERSIBLE PULPITIS A MAN TOOTH PAIN EVERY NOW AND THEN WHEN DRINKING COLD WATER. HE LOVES DRINKING COLA AND HE CONSUMES LOT OF COKE ON HIS WORK

- I. You made the diagnosis of reversible pulpitis, how did you decide to make this as a diagnosis?
 - A. Initial onset of pain
 - B. Transient nature of pain
 - C. Sensitivity to cold
- II. You did the cold test n found that pulp is vital. How will u restore this tooth?
 - A. Give GIC lining and composite
 - B. Calcium hydroxide lining and composite
- III. You found that patient had one more carious lesion on the distal of 45. How will u restore it?
 - A. Using sectional wedge system n incremental packing of composite

THIS IS COPYRIGHTED CONTENT. Unauthorized use, including screenshots, copying, misuse, reuse, or resale of any content from this app, is strictly prohibited. Our app monitors and records all screenshots and recordings. Violators will face strict legal action.

DISCLAIMER

THIS IS COPYRIGHTED CONTENT. Unauthorized use, including screenshots, copying, misuse, reuse, or resale of any content from this app, is strictly prohibited. Our app monitors and records all screenshots and recordings. Violators will face strict legal action.

DISCLAIMER
THIS IS COPYRIGHTED CONTENT. Unauthorized use, including screenshots, copying, misuse, reuse, or resale of any content from this app, is strictly prohibited. Our app monitors and records all screenshots and recordings. Violators will face strict legal action.

THIS IS COPYRIGHTED CONTENT. Unauthorized use, including screenshots, copying, misuse, reuse, or resale of any content from this app, is strictly prohibited. Our app monitors and records all screenshots and recordings. Violators will face strict legal action.

THIS IS COPYRIGHTED CONTENT. Unauthorized use, including screenshots, copying, misuse, reuse, or resale of any content from this app, is strictly prohibited. Our app monitors and records all screenshots and recordings. Violators will face strict legal action.

ENDODONTICS

P.O.W.E.R NOTES SBQ 19

- I. The transient nature of pain is only present in reversible pulpitis. Onset of pain on hot and cold is present in both reversible and irreversible pulpitis.
- II. In case of leaving infected dentin and restoring then we prefer sandwich technique (Ca(OH)_2 + GIC + composite) or GIC + composite. Because GIC can be used to line the infected dentin. But when Ca(OH)_2 and MTA are given these calcifying agents are also preferred choices.

Reference:

GIC achieves chemically adhesion to tooth structure via an ion exchange mechanism, creating a stable acid resistant "ion exchange layer" interface, preventing microleakage and bacterial contamination of pulp. Fluoride, calcium, phosphate, strontium ions are released from GIC and taken up by adjacent enamel and dentin, resulting in hyper mineralisation of sound and demineralised enamel and inhibition of caries progression.

But according to the MID article Ca(OH)_2 and MTA best in pulp therapy. Which means in reversible pulpitis these materials work best. Even among them MTA is superior.

This is a case of reversible pulpitis so need to do IPC as there is no exposure yet. If both (A) and (B) options are given, we will be choosing option (B) as the pulp is still vital and you want to create reparative dentin as well. If all the 3 options are given; Ca(OH)_2 , MTA and GIC. MTA is the best, Ca(OH)_2 is the 2nd best and last will be GIC. Setting Ca(OH)_2 will not interfere with the composite bonding.

III. IN CLASS II RESTORATIONS:

Successful contacts are achieved with the "**sectional matrix system**" with small increments.

When the word "**system**" is given it denotes the combination of tofflemire, band and wedge. All the 3 items should be present.

Reference:

It is widely accepted that proximal contacts are very important features in healthy teeth. A lack of proximal contacts contributes to food impaction, secondary caries, tooth movement and periodontal complications. These studies supported use of the sectional matrix with separating ring in order to achieve tight contacts. the sectional matrix with separation ring seems to be the most reliable device for restoring proximal contacts in posterior teeth.

DISCLAIMER

THIS IS COPYRIGHTED CONTENT. Unauthorized use, including screenshots, copying, misuse, reuse, or resale of any content from this app, is strictly prohibited. Our app monitors and records all screenshots and recordings. Violators will face strict legal action.

ENDODONTICS

SBQ 20

POST AND CORE CASE:

PICTURE WAS GIVEN. PT COMPLAINS OF PAIN IRT 11/21. WHILE ON EXAMINATION CROWS IRT 11/21 FELL OFF. MES LOT OF COKE ON HIS WORK

- I. There were retraction cords around 11/21. There was pus draining sinus above 11. What will be the best investigation to do? (At this point they didn't give the radiograph.) Radiograph was given in the second question.
 - A. GP inserting to the sinus and taking a radiograph
 - B. Percussion
 - C. Palpation
 - D. Probing
- II. After taking the radiograph you notice that it was rc treated. What can be the reason for the failed rct before 10 years, photo give 2 showing 11 post incomplete obturation, 21 Short rct in 11 was in x-ray
 - A. Horizontal root fracture
 - B. Failure on RCT
 - C. Post too long
 - D. Post too angulated
 - E. Short obturation
- III. What will be essential for the success of the endodontic retreatment?
 - A. Length of Post
 - B. Type of filing
 - C. Obturation method
 - D. Coronal seal

THIS IS COPYRIGHTED CONTENT. Unauthorized use, including screenshots, copying, misuse, reuse, or resale of any content from this app, is strictly prohibited. Our app monitors and records all screenshots and recordings. Violators will face strict legal action.

DISCLAIMER

THIS IS COPYRIGHTED CONTENT. Unauthorized use, including screenshots, copying, misuse, reuse, or resale of any content from this app, is strictly prohibited. Our app monitors and records all screenshots and recordings. Violators will face strict legal action.

DISCLAIMER
THIS IS COPYRIGHTED CONTENT. Unauthorized use, including screenshots, copying, misuse, reuse, or resale of any content from this app, is strictly prohibited. Our app monitors and records all screenshots and recordings. Violators will face strict legal action.

DISCLAIMER

THIS IS COPYRIGHTED CONTENT. Unauthorized use, including screenshots, copying, misuse, reuse, or resale of any content from this app, is strictly prohibited. Our app monitors and records all screenshots and recordings. Violators will face strict legal action.

ENDODONTICS

P.O.W.E.R NOTES SBQ 20

- I. You can insert the GP to identify the source of infection specially when the pus draining sinus is lying between the 2 central incisors. So, you can find out from the where the infection is coming from. It's draining sinus so there's no pain, so percussion is not helpful. You will perform palpation and probing as well but option (A) comes first.
- II. There is short incomplete obturation so there's lack of periapical seal. If that was given as choice that would be the best answer. Lack of apical seal or left-over bacteria in the apical 3rd these two would be the best answers. Therefore option (E) is the best answer among the given.
- III. Length of the post will determine whether the tooth will sustain the restoration or not or whether it will fracture or not. Obturation method doesn't matter but the quality of the obturation matters. Coronal seal; as per the sequence of Walton picture the most important factor for the success is coronal seal. That's why immediately after a RCT permanent restoration is provided.

recordings. Violators will face strict legal action.

THIS IS COPYRIGHTED CONTENT. Unauthorized use, including screenshots, copying, misuse, reuse, or resale of any content from this app, is strictly prohibited. Our app monitors and records all screenshots and recordings. Violators will face strict legal action.

THIS IS COPYRIGHTED CONTENT. Unauthorized use, including screenshots, copying, misuse, reuse, or resale of any content from this app, is strictly prohibited. Our app monitors and records all screenshots and recordings. Violators will face strict legal action.

DISCLAIMER

THIS IS COPYRIGHTED CONTENT. Unauthorized use, including screenshots, copying, misuse, reuse, or resale of any content from this app, is strictly prohibited. Our app monitors and records all screenshots and recordings. Violators will face strict legal action.

DISCLAIMER
THIS IS COPYRIGHTED CONTENT. Unauthorized use, including screenshots, copying, misuse, reuse, or resale of any content from this app, is strictly prohibited. Our app monitors and records all screenshots and recordings. Violators will face strict legal action.

ENDODONTICS

SBQ 21

BEFORE AND AFTER IOPA WITH RESPECT TO LOWER MOLAR:

A PATIENT CAME WITH PAIN ON THE LOWER LEFT HAND SIDE AND COMPLAINED OF A "FOUL SMELL" FROM THE LOWER LEFT PART OF THE MOUTH. 12 MONTHS AGO YOU HAD PLACED GIC CALCIUM HYDROXIDE WITH TEMPORARY FILLING, WHICH IS DISLODGED PARTLY NOW. RCT ATTEMPTED PULP, WAS DEBRIDED, AND HAD ASKED THE PATIENT TO COME BACK, BUT SHE DIDN'T DO IT BECAUSE SHE SAID SHE WAS TRAVELING. CHRONIC PERIAPICAL ABSCESS WAS PRESENT.

(OBSERVATIONS) TWO IOPA RADIOGRAPHS WERE GIVEN SIDE BY SIDE (PREVIOUS NO RADIO LUCENCY IN FURCATION, CAO H FILLING WAS VISIBLE AND NEW X - RAY HAD RADIO LUCENCY IN FURCATION)

OLD: RL IMAGE ON CORONAL ASPECT. COULD SEE HORIZONTAL BONE LOSS 1-2 MM INTERDENTALLY BETWEEN PREMOLAR AND MOLAR ALTHOUGH WAS VERY LESS

NEW: FURCATION INVOLVEMENT.

DIFFERENT IMAGE ON OCCLUSAL, AS IF THE RESTORATION HAD BEEN CHANGED AND THERE WAS A SLIGHT GAP WITH THE 37.

I. Upon examination, you can see that some caries has developed on the tooth. What is the reason for the change with respect to bone density that you can see in the radiograph?

- A. Aggressive periodontists
- B. Poor oral hygiene
- C. Chronic pulpitis
- D. Localized chronic infection
- E. Food impaction

II. Apart from x-ray, which step will you do next to arrive at the diagnosis?

- A. Periodontal probing
- B. Bite and release test
- C. Pulp sensibility test
- D. Palpation
- E. Transillumination

THIS IS COPYRIGHTED CONTENT. Unauthorized use, including screenshots, copying, misuse, reuse, or resale of any content from this app, is strictly prohibited. Our app monitors and records all screenshots and recordings. Violators will face strict legal action.

DISCLAIMER

THIS IS COPYRIGHTED CONTENT. Unauthorized use, including screenshots, copying, misuse, reuse, or resale of any content from this app, is strictly prohibited. Our app monitors and records all screenshots and recordings. Violators will face strict legal action.

THIS IS COPYRIGHTED CONTENT. Unauthorized use, including screenshots, copying, misuse, reuse, or resale of any content from this app, is strictly prohibited. Our app monitors and records all screenshots and recordings. Violators will face strict legal action.

THIS IS COPYRIGHTED CONTENT. Unauthorized use, including screenshots, copying, misuse, reuse, or resale of any content from this app, is strictly prohibited. Our app monitors and records all screenshots and recordings. Violators will face strict legal action.

WINSPERT
P.O.W.E.R
NOTES

ENDODONTICS

P.O.W.E.R NOTES SBQ 21

- I. It's acute periapical re infection. Acute periodontal infection coming from an endodontic cause. Endo-perio lesion. In endodontics acute and chronic is symptomatic depiction. Patient comes with pain so the presentation can't be chronic and it's an acute condition.

In the localised area long standing chronic infection is established. That is the reasons behind the pain present right now.

Change in the bone is seen the area of furcation. Food impaction can lead to vertical bone loss/infrabony pockets, not the furcation involvement, option (E) is ruled out.

Aggressive periodontitis is a destructive disease characterized by the following: the involvement of multiple teeth with a distinctive pattern of periodontal tissue loss; a high rate of disease progression; an early age of onset; and the absence of systemic diseases. So, option (A) is ruled out.

Pulp is already debrided so it can't be pulpitis. So, option (C) is ruled out.

- II. Pain in RCT treated tooth may be due to flare-up or VRF.

In VRF pain is coming from the PDL. When pain on biting is present in RCT treated tooth mostly it can be due to VRF. That is why probing will help you with investigating the VRF. If the case was of cracked tooth in another variation than both B and E options are suitable for cracked tooth. B option is best for cracked tooth as u can immediately identity with a tooth sloth due to the wedging effect and separation of the fragments. If B is not given E is the 2nd best, as the transillumination can reveal the cracks.

Sensibility tests are not useful in RCT treated teeth.

The answer is option (A).

THIS IS COPYRIGHTED CONTENT. Unauthorized use, including screenshots, copying, misuse, reuse, or resale of any content from this app, is strictly prohibited. Our app monitors and records all screenshots and recordings. Violators will face strict legal action.

DISCLAIMER

THIS IS COPYRIGHTED CONTENT. Unauthorized use, including screenshots, copying, misuse, reuse, or resale of any content from this app, is strictly prohibited. Our app monitors and records all screenshots and recordings. Violators will face strict legal action.

DISCLAIMER

THIS IS COPYRIGHTED CONTENT. Unauthorized use, including screenshots, copying, misuse, reuse, or resale of any content from this app, is strictly prohibited. Our app monitors and records all screenshots and recordings. Violators will face strict legal action.

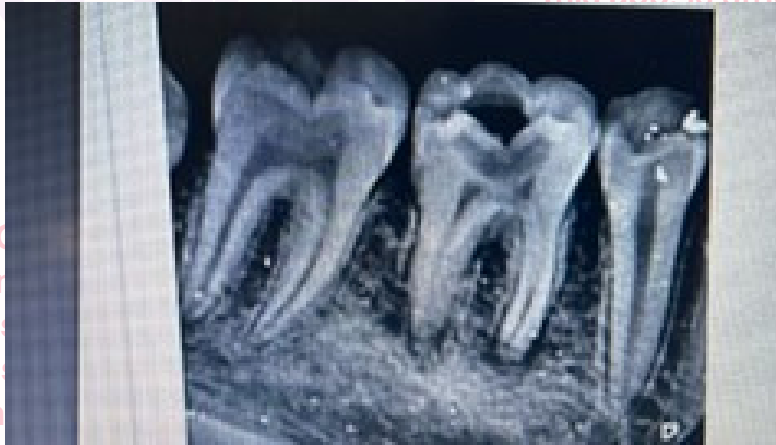DISCLAIMER

THIS IS COPYRIGHTED CONTENT. Unauthorized use, including screenshots, copying, misuse, reuse, or resale of any content from this app, is strictly prohibited. Our app monitors and records all screenshots and recordings. Violators will face strict legal action.

ENDODONTICS

SBQ 22

JAMES MISSED AN APPOINTMENT AND PRESENTED TO YOU AFTER A FEW WEEKS WITH IRREVERSIBLE PULPITIS; SPONTANEOUS AND SEVERE PAIN.



- I. What is the best treatment you can do for James on this day?
 - A. Pulp extirpation
 - B. Emergency pulpotomy
 - C. Partial pulpotomy
 - D. Leader mix dressing after removal of 2 mm of pulp tissues
 - E. Zinc oxide dressing directly on pulp to relieve pain
- II. In a case where deep caries are present, if you remove the caries further then it would lead to pulp exposure. What will be the appropriate management for this case?
 - A. Spot application of caoh2 and composite restoration
 - B. Spot application of corticosteroid and antibiotic application
 - C. Caoh2 layer and composite restoration
 - D. Direct pulp capping and spot application of corticosteroid and antibiotic layer

THIS IS COPYRIGHTED CONTENT. Unauthorized use, including screenshots, copying, misuse, reuse, or resale of any content from this app, is strictly prohibited. Our app monitors and records all screenshots and recordings. Violators will face strict legal action.

DISCLAIMER

THIS IS COPYRIGHTED CONTENT. Unauthorized use, including screenshots, copying, misuse, reuse, or resale of any content from this app, is strictly prohibited. Our app monitors and records all screenshots and recordings. Violators will face strict legal action.

DISCLAIMER
THIS IS COPYRIGHTED CONTENT. Unauthorized use, including screenshots, copying, misuse, reuse, or resale of any content from this app, is strictly prohibited. Our app monitors and records all screenshots and recordings. Violators will face strict legal action.

THIS IS COPYRIGHTED CONTENT. Unauthorized use, including screenshots, copying, misuse, reuse, or resale of any content from this app, is strictly prohibited. Our app monitors and records all screenshots and recordings. Violators will face strict legal action.

DISCLAIMER

ENDODONTICS

P.O.W.E.R NOTES SBQ 22

- I. Minimal emergency Rx for irreversible pulpitis → emergency pulpotomy
Best Rx for irreversible pulpitis → pulp extirpation
- II. Corticosteroids are not used in IPC. So, options (B) and (D) are ruled out.
Spot application is not adequate. So, option (A) is ruled out.
Ca(OH)₂ and MTA are used as pulp capping agents.

THIS IS COPYRIGHTED CONTENT. Unauthorized use, including screenshots, copying, misuse, reuse, or resale of any content from this app, is strictly prohibited. Our app monitors and records all screenshots and recordings. Violators will face strict legal action.

THIS IS COPYRIGHTED CONTENT. Unauthorized use, including screenshots, copying, misuse, reuse, or resale of any content from this app, is strictly prohibited. Our app monitors and records all screenshots and recordings. Violators will face strict legal action.

THIS IS COPYRIGHTED CONTENT. Unauthorized use, including screenshots, copying, misuse, reuse, or resale of any content from this app, is strictly prohibited. Our app monitors and records all screenshots and recordings. Violators will face strict legal action.

DISCLAIMER

THIS IS COPYRIGHTED CONTENT. Unauthorized use, including screenshots, copying, misuse, reuse, or resale of any content from this app, is strictly prohibited. Our app monitors and records all screenshots and recordings. Violators will face strict legal action.

DISCLAIMER
THIS IS COPYRIGHTED CONTENT. Unauthorized use, including screenshots, copying, misuse, reuse, or resale of any content from this app, is strictly prohibited. Our app monitors and records all screenshots and recordings. Violators will face strict legal action.

DISCLAIMER

THIS IS COPYRIGHTED CONTENT. Unauthorized use, including screenshots, copying, misuse, reuse, or resale of any content from this app, is strictly prohibited. Our app monitors and records all screenshots and recordings. Violators will face strict legal action.

ENDODONTICS

SBQ 23

PULPITIS

PATIENT COMPLAINS OF ON AND OFF PAIN, COMPLAINING OF PAIN TO COLD FOR A FEW SECONDS. ON EXAMINATION SHE HAS A DECAY IN 46. YOU PERFORM COLD ICE STICK TEST FOR HER.

- I. Which test are you going to perform next to confirm your diagnosis? (no x-ray option was given)
 - A. Hot water test
 - B. Percussion
 - C. Probing
 - D. Palpation
- II. Patients complain of pain upon having anything cold, but subsides within a few seconds. Upon discussion with the patient you diagnose this as reversible pulpitis. How will you confirm your diagnosis of reversible pulpitis?
 - A. Transient of pain
 - B. X-ray
 - C. Cold stimulus

THIS IS COPYRIGHTED CONTENT. Unauthorized use, including screenshots, copying, misuse, reuse, or resale of any content from this app, is strictly prohibited. Our app monitors and records all screenshots and recordings. Violators will face strict legal action.

DISCLAIMER

THIS IS COPYRIGHTED CONTENT. Unauthorized use, including screenshots, copying, misuse, reuse, or resale of any content from this app, is strictly prohibited. Our app monitors and records all screenshots and recordings. Violators will face strict legal action.

THIS IS COPYRIGHTED CONTENT. Unauthorized use, including screenshots, copying, misuse, reuse, or resale of any content from this app, is strictly prohibited. Our app monitors and records all screenshots and recordings. Violators will face strict legal action.

THIS IS COPYRIGHTED CONTENT. Unauthorized use, including screenshots, copying, misuse, reuse, or resale of any content from this app, is strictly prohibited. Our app monitors and records all screenshots and recordings. Violators will face strict legal action.

THIS IS COPYRIGHTED CONTENT. Unauthorized use, including screenshots, copying, misuse, reuse, or resale of any content from this app, is strictly prohibited. Our app monitors and records all screenshots and recordings. Violators will face strict legal action.

DISCLAIMER
THIS IS COPYRIGHTED CONTENT. Unauthorized use, including screenshots, copying, misuse, reuse, or resale of any content from this app, is strictly prohibited. Our app monitors and records all screenshots and recordings. Violators will face strict legal action.

ENDODONTICS

P.O.W.E.R NOTES SBQ 23

- I. Heat test is done in the presence of pain to hot. So, option (A) is ruled out. Cold ice stick test is already performed for this patient. So, percussion test is done to see the periapical involvement. By percussion you can confirm whether there is a periapical involvement or not. If it's a sharp severe sort of pain, then the patient may not allow to do the percussion test. Probing will be helpful in RCT tooth to check the VRF.
- II. The transient nature of pain is only present in reversible pulpitis. Onset of pain on hot and cold is present in both reversible and irreversible pulpitis.
X-RAY changes won't be seen in both reversible/irreversible pulpitis.

including screenshots, copying, misuse, reuse, or resale of any content from this app, is strictly prohibited. Our app monitors and records all screenshots and recordings. Violators will face strict legal action.

THIS IS COPYRIGHTED CONTENT. Unauthorized use, including screenshots, copying, misuse, reuse, or resale of any content from this app, is strictly prohibited. Our app monitors and records all screenshots and recordings. Violators will face strict legal action.

THIS IS COPYRIGHTED CONTENT. Unauthorized use, including screenshots, copying, misuse, reuse, or resale of any content from this app, is strictly prohibited. Our app monitors and records all screenshots and recordings. Violators will face strict legal action.

DISCLAIMER

THIS IS COPYRIGHTED CONTENT. Unauthorized use, including screenshots, copying, misuse, reuse, or resale of any content from this app, is strictly prohibited. Our app monitors and records all screenshots and recordings. Violators will face strict legal action.

DISCLAIMER
THIS IS COPYRIGHTED CONTENT. Unauthorized use, including screenshots, copying, misuse, reuse, or resale of any content from this app, is strictly prohibited. Our app monitors and records all screenshots and recordings. Violators will face strict legal action.

ENDODONTICS

SBQ 24

A HOLISTIC PATIENT COMES TO YOUR CLINIC WITH A CHIEF COMPLAINT OF PAIN. SHE DID NOT BELIEVE IN MAINSTREAM DENTISTRY. YOU CONDUCT THE EXAMINATION AND AFTER CONFIRMING DIAGNOSIS OF IRREVERSIBLE PULPITIS, YOU INFORM HER THAT RCT COULD BE REQUIRED SO YOU NEED TO TAKE A SMALL DOSE RADIOGRAPH BUT THE PATIENT REFUSES RADIOGRAPH.

I. What will you do in this situation?

- A. Continue treatment without x-ray
- B. Extract without x-ray
- C. Use apex locator to do rct
- D. Explain patient that we can't continue treatment without x-ray

II. You need to apply fluoride as a preventive regime but she refuses because she believes fluoride is toxic to health. How will you manage this patient?

- A. Respect patient's belief
- B. Explain evidence based positive aspects of fluoride
- C. Advice essential oil
- D. Discuss with her holistic doctor

THIS IS COPYRIGHTED CONTENT. Unauthorized use, including screenshots, copying, misuse, reuse, or resale of any content from this app, is strictly prohibited. Our app monitors and records all screenshots and recordings. Violators will face strict legal action.

DISCLAIMER

THIS IS COPYRIGHTED CONTENT. Unauthorized use, including screenshots, copying, misuse, reuse, or resale of any content from this app, is strictly prohibited. Our app monitors and records all screenshots and recordings. Violators will face strict legal action.

THIS IS COPYRIGHTED CONTENT. Unauthorized use, including screenshots, copying, misuse, reuse, or resale of any content from this app, is strictly prohibited. Our app monitors and records all screenshots and recordings. Violators will face strict legal action.

DISCLAIMER
THIS IS COPYRIGHTED CONTENT. Unauthorized use, including screenshots, copying, misuse, reuse, or resale of any content from this app, is strictly prohibited. Our app monitors and records all screenshots and recordings. Violators will face strict legal action.

ENDODONTICS

P.O.W.E.R NOTES SBQ 24

- I. Without an X-RAY it's difficult to perform RCT or extraction. So, you need to explain the patient about the importance of X-RAY.
- II. As a healthcare provider you must educate the patient about the importance of fluoride. Show evidenced based factors in related to fluoride.

THIS IS COPYRIGHTED CONTENT. Unauthorized use, including screenshots, copying, misuse, reuse, or resale of any content from this app, is strictly prohibited. Our app monitors and records all screenshots and recordings. Violators will face strict legal action.

THIS IS COPYRIGHTED CONTENT. Unauthorized use, including screenshots, copying, misuse, reuse, or resale of any content from this app, is strictly prohibited. Our app monitors and records all screenshots and recordings. Violators will face strict legal action.

THIS IS COPYRIGHTED CONTENT. Unauthorized use, including screenshots, copying, misuse, reuse, or resale of any content from this app, is strictly prohibited. Our app monitors and records all screenshots and recordings. Violators will face strict legal action.

DISCLAIMER

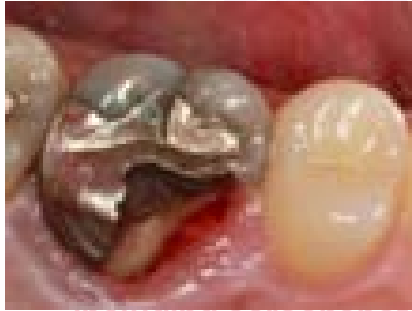THIS IS COPYRIGHTED CONTENT. Unauthorized use, including screenshots, copying, misuse, reuse, or resale of any content from this app, is strictly prohibited. Our app monitors and records all screenshots and recordings. Violators will face strict legal action.

DISCLAIMER
THIS IS COPYRIGHTED CONTENT. Unauthorized use, including screenshots, copying, misuse, reuse, or resale of any content from this app, is strictly prohibited. Our app monitors and records all screenshots and recordings. Violators will face strict legal action.

ENDODONTICS

SBQ 25

A PATIENT GOT ROOT CANAL TREATMENT DONE WITH TOOTH 36. HE GOT THE TREATMENT DONE OVERSEAS BUT DIDN'T GET A CROWN FOR THE SAME.



I. Now the patient has come to you, root canal treatment is satisfactory. By looking at the clinical picture, What defines the treatment plan.

- A. Fracture line depth
- B. 360 degree ferrule
- C. Restorability

II. What investigation will you perform?

- A. Probing
- B. X-ray
- C. Sensitivity

III. What can be long term treatment in this case?

- A. PFM
- B. Crown lengthening, post & core and crown
- C. Post and core
- D. Extraction

THIS IS COPYRIGHTED CONTENT. Unauthorized use, including screenshots, copying, misuse, reuse, or resale of any content from this app, is strictly prohibited. Our app monitors and records all screenshots and recordings. Violators will face strict legal action.

DISCLAIMER
THIS IS COPYRIGHTED CONTENT. Unauthorized use, including screenshots, copying, misuse, reuse, or resale of any content from this app, is strictly prohibited. Our app monitors and records all screenshots and recordings. Violators will face strict legal action.

THIS IS COPYRIGHTED CONTENT. Unauthorized use, including screenshots, copying, misuse, reuse, or resale of any content from this app, is strictly prohibited. Our app monitors and records all screenshots and recordings. Violators will face strict legal action.

DISCLAIMER

THIS IS COPYRIGHTED CONTENT. Unauthorized use, including screenshots, copying, misuse, reuse, or resale of any content from this app, is strictly prohibited. Our app monitors and records all screenshots and recordings. Violators will face strict legal action.

ENDODONTICS

P.O.W.E.R NOTES SBQ 25

- I. Tooth seem to be restorable. Even though the tooth has 360degree ferrule but if the tooth has a fracture, then it can progress to root, then extraction is indicated. Therefore the direction of the crack/fracture matters when it's present. The direction/orientation of the crack/fracture determines the prognosis of the tooth.
- II. Here rct is done by other dentist.
So taking xray will reveal fracture extend and root canal filling status as well.
So IOPA will be best choice here.
- III. Suppose that the fracture is only up to the CEJ and not progressed up to the root, then you can still save this tooth. Even the fracture has progressed sub gingivally (fracture remains within the confines), still you can save the tooth by doing crown lengthening + post and core+ crown. But even crown lengthening has its limits, only up 1-2mm bone can be removed in crown lengthening, if the fracture is progressing more deeper than that then extraction is indicated. There's also a limit in sacrificing the supporting bone. You should not disrupt the crown: root ratio and the supporting bone.
Based on the picture/X-RAY the answer may get changed. It can be either B or D.

DISCLAIMER

THIS IS COPYRIGHTED CONTENT. Unauthorized use, including screenshots, copying, misuse, reuse, or resale of any content from this app, is strictly prohibited. Our app monitors and records all screenshots and recordings. Violators will face strict legal action.

DISCLAIMER
THIS IS COPYRIGHTED CONTENT. Unauthorized use, including screenshots, copying, misuse, reuse, or resale of any content from this app, is strictly prohibited. Our app monitors and records all screenshots and recordings. Violators will face strict legal action.

THIS IS COPYRIGHTED CONTENT. Unauthorized use, including screenshots, copying, misuse, reuse, or resale of any content from this app, is strictly prohibited. Our app monitors and records all screenshots and recordings. Violators will face strict legal action.

DISCLAIMER

THIS IS COPYRIGHTED CONTENT. Unauthorized use, including screenshots, copying, misuse, reuse, or resale of any content from this app, is strictly prohibited. Our app monitors and records all screenshots and recordings. Violators will face strict legal action.

THIS IS COPYRIGHTED CONTENT. Unauthorized use, including screenshots, copying, misuse, reuse, or resale of any content from this app, is strictly prohibited. Our app monitors and records all screenshots and recordings. Violators will face strict legal action.

ENDODONTICS

SBQ 26

A 20 YEAR OLD BOY GOT RCT DONE OVERSEAS A FEW MONTHS BACK. NOW, THE PATIENT HAS COME TO YOU TO GET A CROWN FOR THE SAME TOOTH AND HAS NO SYMPTOMS, YOU JUST FIGURED OUT ON X-RAY RADIOLUCENCY AT APEX OF TOOTH 27. WHAT CAN YOU DO IN THE PATIENT'S BEST INTEREST?

- A. Retreat
- B. Extraction
- C. Ask when the treatment was done
- D. Talk to the previous dentist

THIS IS COPYRIGHTED CONTENT. Unauthorized use, including screenshots, copying, misuse, reuse, or resale of any content from this app, is strictly prohibited. Our app monitors and records all screenshots and recordings. Violators will face strict legal action.

THIS IS COPYRIGHTED CONTENT. Unauthorized use, including screenshots, copying, misuse, reuse, or resale of any content from this app, is strictly prohibited. Our app monitors and records all screenshots and recordings. Violators will face strict legal action.

THIS IS COPYRIGHTED CONTENT. Unauthorized use, including screenshots, copying, misuse, reuse, or resale of any content from this app, is strictly prohibited. Our app monitors and records all screenshots and recordings. Violators will face strict legal action.

DISCLAIMER

THIS IS COPYRIGHTED CONTENT. Unauthorized use, including screenshots, copying, misuse, reuse, or resale of any content from this app, is strictly prohibited. Our app monitors and records all screenshots and recordings. Violators will face strict legal action.

DISCLAIMER
THIS IS COPYRIGHTED CONTENT. Unauthorized use, including screenshots, copying, misuse, reuse, or resale of any content from this app, is strictly prohibited. Our app monitors and records all screenshots and recordings. Violators will face strict legal action.

ENDODONTICS

P.O.W.E.R NOTES SBQ 26

You can't start doing re treatment or extraction when there's absence of signs and symptoms. Instead you must ask the patient when the treatment was done. As it will give you the estimate of whether this a long-standing radiolucency or not. As we usually wait for 1 year for a long-standing radiolucency to get it healed and resolved. The radiolucency must have been present even before the tooth was RC treated.

You can't talk to the previous dentist. So (D) is not the option as there can be language problems, time zone problems. According to ADA guideline you should not call doctors to confirm it. Best thing to do is to get the previous records. Then you can get to know on the day of the RCT whether the radiolucency was present or not. Because this could have also been a new radiolucency as well.

Ref: EMERGENCY OVERSEAS DENTAL TREATMENT article, travelers should request a written report including radiographs on any emergency dental treatment received overseas to be passed on to their dentist on return from abroad. (so, the traveler requests not the dentist, then you must manage based on your capacity)

Persistent radiographical changes present in the absence of signs and symptoms may require re treatment. If it's only few months, you can wait and observe. If the radiolucency still presents even after 1 yr from RCT then re treatment is required. If there's an option where asking the patient to request for the previous records and X-RAY, this would be best as you can get a clear idea about the tooth.

THIS IS COPYRIGHTED CONTENT. Unauthorized use, including screenshots, copying, misuse, reuse, or resale of any content from this app, is strictly prohibited. Our app monitors and records all screenshots and recordings. Violators will face strict legal action.

DISCLAIMER

THIS IS COPYRIGHTED CONTENT. Unauthorized use, including screenshots, copying, misuse, reuse, or resale of any content from this app, is strictly prohibited. Our app monitors and records all screenshots and recordings. Violators will face strict legal action.

DISCLAIMER
THIS IS COPYRIGHTED CONTENT. Unauthorized use, including screenshots, copying, misuse, reuse, or resale of any content from this app, is strictly prohibited. Our app monitors and records all screenshots and recordings. Violators will face strict legal action.

DISCLAIMER

THIS IS COPYRIGHTED CONTENT. Unauthorized use, including screenshots, copying, misuse, reuse, or resale of any content from this app, is strictly prohibited. Our app monitors and records all screenshots and recordings. Violators will face strict legal action.

ENDODONTICS

SBQ 27

ENDO PERIO LESION

THE PATIENT HAD OCCLUSAL CARIES ON EXCAVATING THE CARIES; IT WAS CLOSE TO PULP SO A BARRIER OF CALCIUM HYDROXIDE WAS GIVEN AND RESTORATION WAS PLACED, AT THAT TIME HER PERIODONTITIS WAS DIAGNOSED TO BE STAGE 2 GRADE C (PATIENT HAD PRIOR 7 MM POCKET TOOTH ON 27 OCCLUSAL RESTORATION). AFTER INITIAL APPOINTMENT PATIENT WAS PUT ON RECALL AFTER 6 MONTHS, AND IN THAT APPOINTMENT SHE CAME BACK WITH PAIN AND TOOTH HAD PROGRESSED TO IRREVERSIBLE PULPITIS. SHE ALSO HAS DIABETES

I. Asking about the lesion, what is the diagnosis

- A. True combined lesion
- B. Primary perio secondary endo
- C. Primary endo
- D. Primary endo secondary perio
- E. Primary perio

II. What treatment will u do now?

- A. Access opening debride the pulp
- B. Scaling and review after 3 months

DISCLAIMER

THIS IS COPYRIGHTED CONTENT. Unauthorized use, including screenshots, copying, misuse, reuse, or resale of any content from this app, is strictly prohibited. Our app monitors and records all screenshots and recordings. Violators will face strict legal action.

THIS IS COPYRIGHTED CONTENT. Unauthorized use, including screenshots, copying, misuse, reuse, or resale of any content from this app, is strictly prohibited. Our app monitors and records all screenshots and recordings. Violators will face strict legal action.

THIS IS COPYRIGHTED CONTENT. Unauthorized use, including screenshots, copying, misuse, reuse, or resale of any content from this app, is strictly prohibited. Our app monitors and records all screenshots and recordings. Violators will face strict legal action.

DISCLAIMER

THIS IS COPYRIGHTED CONTENT. Unauthorized use, including screenshots, copying, misuse, reuse, or resale of any content from this app, is strictly prohibited. Our app monitors and records all screenshots and recordings. Violators will face strict legal action.

DISCLAIMER

THIS IS COPYRIGHTED CONTENT. Unauthorized use, including screenshots, copying, misuse, reuse, or resale of any content from this app, is strictly prohibited. Our app monitors and records all screenshots and recordings. Violators will face strict legal action.

ENDODONTICS

P.O.W.E.R NOTES SBQ 27

I. TYPES OF ENDO-PERIO LESIONS

PRIMARY PERIODONTAL

Lesions of periodontal origin usually, but not always, involve multiple teeth. Plaque and calculus deposits induce an inflammatory response, resulting in loss of alveolar bone. Clinically, the bone loss can usually be probed as a broad-based pocket. There may be gingival recession at the sites and as the disease progress, teeth may become mobile.

Generally, Pulp sensibility testing is normal assuming there are no confounding factors such as pulp canal calcification due to other cause, such as previous trauma. Pulp sensibility testing is therefore an important too when diagnosing primary periodontal disease.

PRIMARY PERIODONTAL WITH SECONDARY ENDODONTIC

If marginal periodontitis progress, attachment loss may expose lateral and accessory canals or even the apical foramen. This can allow bacteria to enter the pulp, resulting in pulp necrosis. Such cases appear clinically and radiographically very similar to primary endodontic-secondary periodontal and true combined lesions. There may be no other obvious cause for the endodontic infection, such as caries or deep restorations.

Treatment involves addressing both disease entities via periodontal treatment and root canal treatment; however, the prognosis is generally directed by the severity of the periodontal disease and the patient's response to treatment.

PRIMARY ENDODONTIC

Endodontic infections generally cause an inflammatory response in the periapical tissues adjacent to the apical foramen, thus causing apical periodontitis.

If a periapical or peri-radicular radiolucency is present, an endodontic cause can be expected if the tooth is negative to pulp sensibility testing and periodontal attachment levels are normal.

In some cases, especially if a chronic apical abscess forms, there can be localised periodontal attachment loss in the form of a narrow pocket if the infection drains coronally. This is essentially a draining sinus within the periodontal ligament space, rather than through the bone and overlying soft tissues.

These situations can be misdiagnosed as a periodontal abscess or assumed to be a primary endodontic- secondary periodontal condition.

If the attachment loss or draining sinus is confined to a single tooth, and is not interproximal, one may suspect a primary endodontic condition, especially if the tooth is tender to percussion.

DISCLAIMER

THIS IS COPYRIGHTED CONTENT. Unauthorized use, including screenshots, copying, misuse, reuse, or resale of any content from this app, is strictly prohibited. Our app monitors and records all screenshots and recordings. Violators will face strict legal action.

THIS IS COPYRIGHTED CONTENT. Unauthorized use, including screenshots, copying, misuse, reuse, or resale of any content from this app, is strictly prohibited. Our app monitors and records all screenshots and recordings. Violators will face strict legal action.

THIS IS COPYRIGHTED CONTENT. Unauthorized use, including screenshots, copying, misuse, reuse, or resale of any content from this app, is strictly prohibited.

Our app monitors and records all screenshots and recordings. Violators will face strict legal action.

DISCLAIMER
THIS IS COPYRIGHTED CONTENT. Unauthorized use, including screenshots, copying, misuse, reuse, or resale of any content from this app, is strictly prohibited. Our app monitors and records all screenshots and recordings. Violators will face strict legal action.

ENDODONTICS

P.O.W.E.R NOTES SBQ 27

I. PRIMARY ENDODONTIC WITH SECONDARY PERIODONTAL

If a primary endodontic infection is left untreated, continued suppuration can sometimes lead to the supporting periodontal tissues becoming secondarily involved, eventually results in a periodontal defect which become involved with plaque and possibly calculus. Once the periodontal tissues have become secondarily involved, both periodontal and endodontic treatments are required. Root canal treatment removes the endodontic infection, but the periodontal bioburden remains. Prognosis now depends on appropriate periodontal intervention, patient compliance with the oral hygiene measures and a favourable patient response to treatment.

TRUE COMBINED LESIONS

Probably the least common type of the endodontic-periodontal lesions, true combined lesions really are where two worlds meet.

They are formed when endodontic disease travelling coronally meets a concurrent, but otherwise unrelated infected periodontal pocket as it deepens apically along the root.

True combined lesions may be clinically and radiographically indistinguishable from primary endodontic-secondary periodontal and primary periodontal-secondary endodontic conditions. Because true combined lesions are essentially two separate conditions, management must involve both endodontic and periodontal treatment.

In multirooted teeth where the condition is localised to one particular root, hemi-sectioning of the tooth or re-section of the affected root may be considered if the tooth is amenable and the patient motivated. Extraction is often the end result in single rooted teeth.

I. NON-SURGICAL TREATMENT OF ENDODONTIC-PERIODONTAL DISEASE

Generally, treatment involves initiating endodontic treatment followed by a period of monitoring, thus allowing the endodontic component of the disease to settle. it's often after the monitoring phase that the extent of the endodontic contribution can be fully assessed.

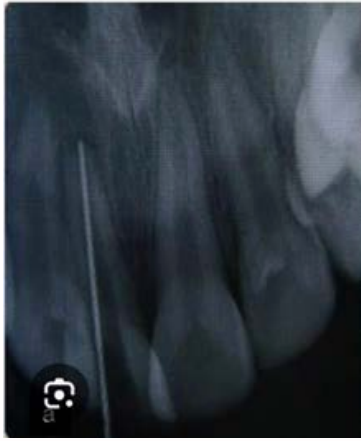This in turn, allows a more accurate assessment of the periodontal condition and periodontal treatment needs.

In combined lesions, the prognosis is heavily influenced by the extent of the periodontal attachment loss, and significant attachment loss has negative effect on prognosis and tooth survival.

DISCLAIMER

THIS IS COPYRIGHTED CONTENT. Unauthorized use, including screenshots, copying, misuse, reuse, or resale of any content from this app, is strictly prohibited. Our app monitors and records all screenshots and recordings. Violators will face strict legal action.

ENDODONTICS

SBQ 28
ENDO CASE


I. IOPA given with file going beyond apex, Asked based on the radiograph what will you do

- A. Increase the working length 1mm
- B. Decrease working length 1mm
- C. Increase working length 2mm
- D. Decrease working length 2mm
- E. Working length is adequate

II. What is the most appropriate confirming way to know the correct working length?

- A. Take iopa in a different angulation
- B. Take iopa with a larger file
- C. Take iopa with a master gp cone
- D. Use apex locator

P.O.W.E.R NOTES SBQ 28

- I. Based on the studies of apical anatomy, the ideal apical point of termination of root canal preparation, also known as working length, has been established empirically to be 0.5 to 1mm from the radiographic apex.
- II. Historically working lengths have been determined with apical radiographs, however it's recommended that an electronic apex locator is used in conjunction with verifying radiographs to determine the working length.

DISCLAIMER

THIS IS COPYRIGHTED CONTENT. Unauthorized use, including screenshots, copying, misuse, reuse, or resale of any content from this app, is strictly prohibited. Our app monitors and records all screenshots and recordings. Violators will face strict legal action.

THIS IS COPYRIGHTED CONTENT. Unauthorized use, including screenshots, copying, misuse, reuse, or resale of any content from this app, is strictly prohibited. Our app monitors and records all screenshots and recordings. Violators will face strict legal action.

DISCLAIMER
THIS IS COPYRIGHTED CONTENT. Unauthorized use, including screenshots, copying, misuse, reuse, or resale of any content from this app, is strictly prohibited. Our app monitors and records all screenshots and recordings. Violators will face strict legal action.

THIS IS COPYRIGHTED CONTENT. Unauthorized use, including screenshots, copying, misuse, reuse, or resale of any content from this app, is strictly prohibited. Our app monitors and records all screenshots and recordings. Violators will face strict legal action.

DISCLAIMER

ENDODONTICS

SBQ 29

EROSION

AN IMMIGRANT PATIENT VISITS YOUR DENTAL CLINIC. PATIENT COMPLAINS OF SENSITIVITY REGARDING HIS TEETH. PATIENT IS DRINKING LEMON WATER FOR WEIGHT LOSS EVERY DAY IN THE MORNING.

I. What has caused her hypersensitivity?

- A. Softened enamel
- B. Exposed dentinoenamel junction
- C. Dissolution of dentinal plugs
- D. Cumulative effect of electronic brushing

II. What is the lesion?

- A. Erosion
- B. Attrition
- C. Abfraction
- D. Abrasion

III. Which surface is least affected?

- A. Palatal surface of upper anteriors
- B. Lingual surface of lower posteriors
- C. Occlusal surface of lower posterior
- D. Labial surface of upper anteriors
- E. Buccal surface of upper posteriors

THIS IS COPYRIGHTED CONTENT. Unauthorized use, including screenshots, copying, misuse, reuse, or resale of any content from this app, is strictly prohibited. Our app monitors and records all screenshots and recordings. Violators will face strict legal action.

DISCLAIMER

THIS IS COPYRIGHTED CONTENT. Unauthorized use, including screenshots, copying, misuse, reuse, or resale of any content from this app, is strictly prohibited. Our app monitors and records all screenshots and recordings. Violators will face strict legal action.

THIS IS COPYRIGHTED CONTENT. Unauthorized use, including screenshots, copying, misuse, reuse, or resale of any content from this app, is strictly prohibited. Our app monitors and records all screenshots and recordings. Violators will face strict legal action.

DISCLAIMER
THIS IS COPYRIGHTED CONTENT. Unauthorized use, including screenshots, copying, misuse, reuse, or resale of any content from this app, is strictly prohibited. Our app monitors and records all screenshots and recordings. Violators will face strict legal action.

THIS IS COPYRIGHTED CONTENT. Unauthorized use, including screenshots, copying, misuse, reuse, or resale of any content from this app, is strictly prohibited. Our app monitors and records all screenshots and recordings. Violators will face strict legal action.

ENDODONTICS

P.O.W.E.R NOTES SBQ 29

- I. Soften enamel/ demineralisation will not cause “sensitivity”. Enamel and cementum naturally help in sealing the dentinal tubules. Dentinal tubules are never sealed on their own. Once the cementum and enamel are lost, dentinal tubules become open and cause “sensitivity”. Desensitising agents are used in such situations to create “dental plugs”.

REFERENCE:

Dentinal tubules potentially form a communication between the pulp and periodontal tissue. However, they are normally protected externally by enamel in the coronal part of the tooth and by cementum in the radicular part of the tooth.

Under normal circumstances, the presence of these layers has the effect of limiting the permeability of the dentinal tubules at the outer extent of the tooth.

One of the roles of the cementum is to prevent communication between the root canal system and the periodontium via the otherwise open dentinal tubules.

- II. Patient has the habit of drinking lemon water which is acidic in nature. This is a contributing factor for “erosion”.

- III. Intrinsic erosion: palatal surfaces of upper anterior > occlusal surfaces of lower posterior > lingual surfaces of lower posterior

Extrinsic erosion: buccal surface of upper posteriors and labial surfaces of upper anterior are more involved.

In the question it asked about the least affected surface in “EXTRINSIC EROSION”. So, the options (D) and (E) get ruled out.

Option (B) is the least affected among the options (A), (B) and (C).

THIS IS COPYRIGHTED CONTENT. Unauthorized use, including screenshots, copying, misuse, reuse, or resale of any content from this app, is strictly prohibited. Our app monitors and records all screenshots and recordings. Violators will face strict legal action.

DISCLAIMER

THIS IS COPYRIGHTED CONTENT. Unauthorized use, including screenshots, copying, misuse, reuse, or resale of any content from this app, is strictly prohibited. Our app monitors and records all screenshots and recordings. Violators will face strict legal action.

THIS IS COPYRIGHTED CONTENT. Unauthorized use, including screenshots, copying, misuse, reuse, or resale of any content from this app, is strictly prohibited. Our app monitors and records all screenshots and recordings. Violators will face strict legal action.

DISCLAIMER
THIS IS COPYRIGHTED CONTENT. Unauthorized use, including screenshots, copying, misuse, reuse, or resale of any content from this app, is strictly prohibited. Our app monitors and records all screenshots and recordings. Violators will face strict legal action.

THIS IS COPYRIGHTED CONTENT. Unauthorized use, including screenshots, copying, misuse, reuse, or resale of any content from this app, is strictly prohibited. Our app monitors and records all screenshots and recordings. Violators will face strict legal action.

WINSPERT
P.O.W.E.R
NOTES

ENDODONTICS

SBQ 30

BLEACHING

PATIENT HAD COME TO THE CLINIC WITH THE CHIEF COMPLAINT OF ANTERIOR DISCOLORED TOOTH 11. HISTORY OF TRAUMA 15 YEARS BACK. IT WAS ROOT CANAL TREATED. HE DOESN'T LIKE APPEARANCE. TOOTH HAD CRAZE LINE AND COMPOSITE RESTORATION

I. Reason for the discoloration?

- A. Intracanal medicaments
- B. Necrosed pulp

II. You decide to do internal bleaching. Which is the best material

- A. Hydrogen peroxide
- B. Carbamide peroxide
- C. Sodium perborate
- D. Calcium perborate

III. In between appointments of change of the bleaching solution how long should the bleaching solution stay in the canal?

OR

How long should the bleaching solution be kept in the canal?

- A. 2 to 3 weeks
- B. 30 days
- C. 7-10 days
- D. 14-21 days

THIS IS COPYRIGHTED CONTENT. Unauthorized use, including screenshots, copying, misuse, reuse, or resale of any content from this app, is strictly prohibited. Our app monitors and records all screenshots and recordings. Violators will face strict legal action.

DISCLAIMER

THIS IS COPYRIGHTED CONTENT. Unauthorized use, including screenshots, copying, misuse, reuse, or resale of any content from this app, is strictly prohibited. Our app monitors and records all screenshots and recordings. Violators will face strict legal action.

THIS IS COPYRIGHTED CONTENT. Unauthorized use, including screenshots, copying, misuse, reuse, or resale of any content from this app, is strictly prohibited. Our app monitors and records all screenshots and recordings. Violators will face strict legal action.

THIS IS COPYRIGHTED CONTENT. Unauthorized use, including screenshots, copying, misuse, reuse, or resale of any content from this app, is strictly prohibited. Our app monitors and records all screenshots and recordings. Violators will face strict legal action.

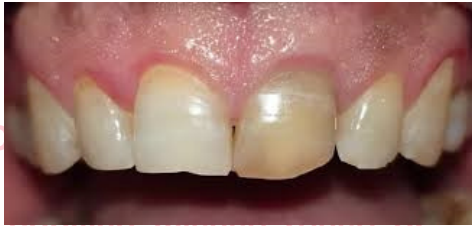DISCLAIMER
THIS IS COPYRIGHTED CONTENT. Unauthorized use, including screenshots, copying, misuse, reuse, or resale of any content from this app, is strictly prohibited. Our app monitors and records all screenshots and recordings. Violators will face strict legal action.

ENDODONTICS

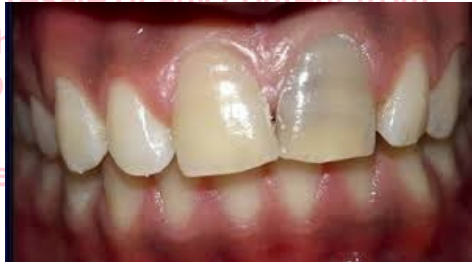P.O.W.E.R NOTES SBQ 30

- I. Blackish discoloration is associated with **INTERCANAL MEDICAMENTS** and **SEALERS** in the pulp chamber. Yellowish-brown-maroon discoloration is associated with **TRAUMA AND NECROSED PULP**. Therefore, both the given options are contributing factors for tooth discolouration. Picture is required to choose the best out of it.

DISCOLOURATION DUE TO NECROSED PULP:



DISCOLOURATION DUE TO INTERCANAL MEDICAMENTS:



- II. The shade stability of teeth treated by a mixture of sodium perborate and H₂O is as high as shade stability of teeth in which a mixture of sodium perborate with 3% or 30% H₂O₂ was used.

The safest bleaching agent for internal bleaching is sodium perborate and H₂O.

- III. In the "WALKING BLEACHING" technique the root filling should be completed first and a cervical seal must be established. The bleaching agent can be kept for up to 28-30 days as per the latest Australian guidelines. The bleaching agent is left in the tooth so that it can function as a walking bleaching until the next visit.

External bleaching of endodontically treated teeth with an in-office technique requires a high concentration gel. It might be a supplement to walking bleaching technique, if the results are not satisfactory after 3-4 visits. These treatments require a bonded temporary filling or a bonded resin composite to seal the access cavity.

There's a deficiency of evidence-based science in the literature that addresses the prognosis of bleached non vital teeth. Therefore, it's important to always be aware of the possible complications and risks that are associated with the different bleaching techniques.

DISCLAIMER

THIS IS COPYRIGHTED CONTENT. Unauthorized use, including screenshots, copying, misuse, reuse, or resale of any content from this app, is strictly prohibited. Our app monitors and records all screenshots and recordings. Violators will face strict legal action.

DISCLAIMER

THIS IS COPYRIGHTED CONTENT. Unauthorized use, including screenshots, copying, misuse, reuse, or resale of any content from this app, is strictly prohibited. Our app monitors and records all screenshots and recordings. Violators will face strict legal action.

THIS IS COPYRIGHTED CONTENT. Unauthorized use, including screenshots, copying, misuse, reuse, or resale of any content from this app, is strictly prohibited. Our app monitors and records all screenshots and recordings. Violators will face strict legal action.

DISCLAIMER