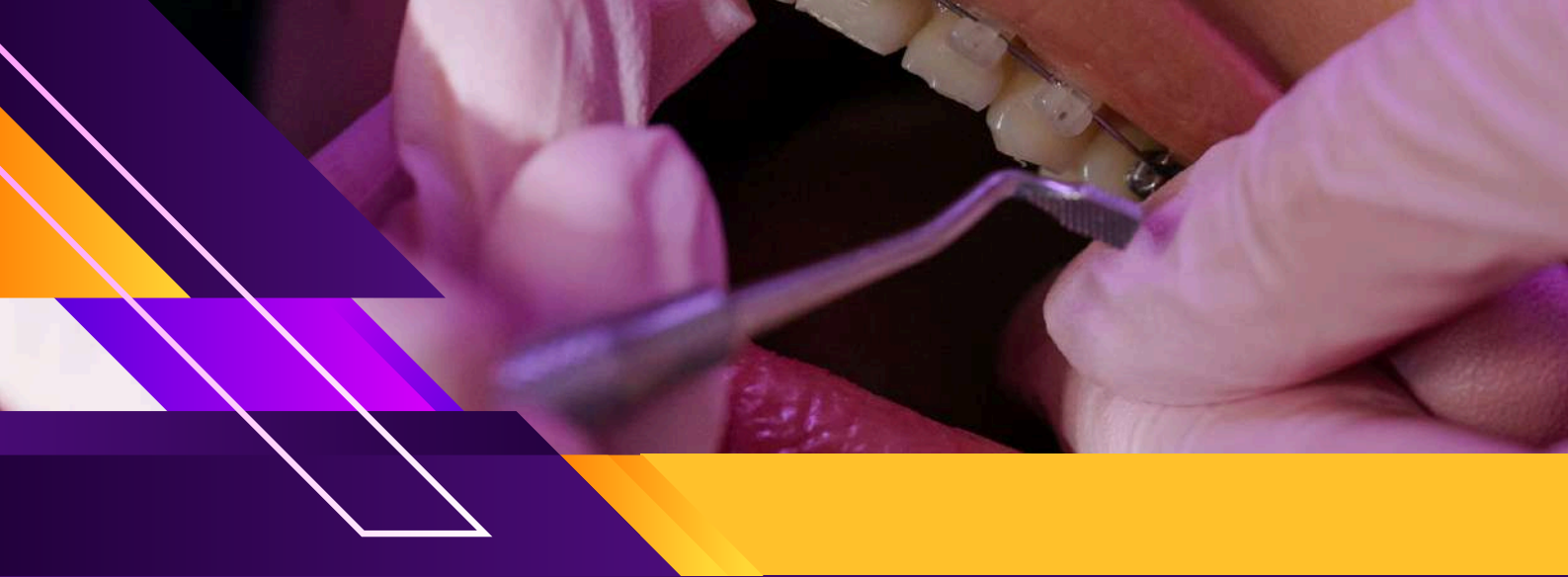



WINSPERT

WINSPERT

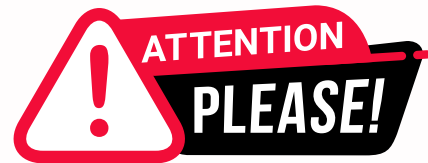P.O.W.E.R

PREPARATION OF ADC WITH WINSPERT EXPERT REVIEW

NOTES

By Dr. Jigyasa Sharma





Dear Students,

We'd like to remind you about the importance of respecting the integrity of the resources provided in our app.

Please be aware that **WINSPERT POWERNOTES ARE COPYRIGHTED CONTENT. Unauthorized use, including screenshots, copying, misuse, reuse, or resale of any content from this app, is strictly prohibited.**

Our app monitors and records all screenshots and recordings. Violators will face strict legal action.

We're committed to providing you with the best tools for your success, and we appreciate your cooperation in maintaining a fair and secure learning environment.

Thank you for your understanding and continued dedication.

Best regards,
WINSPERT TEAM

PEDO+ORTHO

SBQ 1

ADULT CERVICAL RESORPTION WITH CHILDHOOD ORTHODONTIC TREATMENT:
 LADY 61 HAD ORTHO TREATMENT AS A CHILD. SHE HAS A RETAINER FIXED IN 11 21 TO MAINTAIN DIASTEMA CLOSURE DUE TO ANODONTIA. SHE HAS BEEN EXPERIENCING WEIRD FEELINGS SINCE A FEW DAYS IN THE FRONT TEETH, A VERY REGULAR ATTENDEE OF YOURS. IOPA GIVEN SOME SORT OF RESORPTION WITH 21 LOOKS LIKE AN EXTERNAL CERVICAL BUT NOT CLEAR. YOU DID THE EXAM, ALL LOOKS GOOD. NO SENSIBILITY TEST PROBLEM, NO PROBING PROBLEM. IOPA SHOWED DIFFERENT APEX LEVELS FOR BOTH INCISORS BUT ALSO THERE WAS A RADIOLUCENCY CLOSELY ASSOCIATED WITH PULP OF 21 INTERNALLY (IT WAS CONFUSING). THE TOOTH WAS VITAL ON SENSIBILITY TESTING.

I. What is the defect in her teeth?

- A. Apical root resorption
- B. Internal resorption
- C. External invasive cervical resorption
- D. External replacement resorption
- E. Orthodontic root resorption

II. What is the cause for her problem?

- A. Past Orthodontic treatment
- B. Past trauma
- C. Perio disease
- D. External bleaching
- E. Plague/bad oral hygiene

III. Patient said her Florine, daughter who is 14 now got the same thing when she got her tooth avulsed at age of 7-8 years old and then it was replaced and then she got this resorption. She had researched a lot about it and is convinced that its same with her. The patient was concerned if it was due to same reason as her daughter. How will you explain her how her resorption is different from her daughters?

- A. Its progression need presence of orthodontic forces/treatment /it resolves as soon as forces stop
- B. It starts at the beginning of orthodontic treatment and resolves in later stages of treatment
- C. It starts at the beginning of orthodontic treatment and Repairs in later stages of treatment
- D. The resorption is related to the amount of force applied
- E. The resorption is related to the amount of time for the orthodontic treatment

DISCLAIMER

THIS IS COPYRIGHTED CONTENT. Unauthorized use, including screenshots, copying, misuse, reuse, or resale of any content from this app, is strictly prohibited. Our app monitors and records all screenshots and recordings. Violators will face strict legal action.

DISCLAIMER

THIS IS COPYRIGHTED CONTENT. Unauthorized use, including screenshots, copying, misuse, reuse, or resale of any content from this app, is strictly prohibited. Our app monitors and records all screenshots and recordings. Violators will face strict legal action.

DISCLAIMER

THIS IS COPYRIGHTED CONTENT. Unauthorized use, including screenshots, copying, misuse, reuse, or resale of any content from this app, is strictly prohibited. Our app monitors and records all screenshots and recordings. Violators will face strict legal action.

PEDO+ORTHO

SBQ 1

- IV. You are treating this same patient and in your treatment, you used trichloroacetic acid (tca). When you remove the rubber dam you see it has caused a burn on palate. What will be your immediate step to treat/do?**
- Distilled Water
 - Vaseline
 - Saline
 - Corticosteroid cream
 - Sodium bicarbonate solution
- V. What could have been done for the daughter at that time?**
- Use of flexible nylon splint and starting rct within 7 days
 - Use rigid splint and do recall within 3-4 days
 - Use flexible splint for two weeks and start the root canal within 10 days(mature)
 - Use flexible splint for two weeks and start the root canal treatment once the signs start to appear.(Immature)
 - Use rigid splint for 4 weeks

Our app monitors and records all screenshots and recordings. Violators will face strict legal action.

THIS IS COPYRIGHTED CONTENT. Unauthorized use, including screenshots, copying, misuse, reuse, or resale of any content from this app, is strictly prohibited. Our app monitors and records all screenshots and recordings. Violators will face strict legal action.

THIS IS COPYRIGHTED CONTENT. Unauthorized use, including screenshots, copying, misuse, reuse, or resale of any content from this app, is strictly prohibited. Our app monitors and records all screenshots and recordings. Violators will face strict legal action.

DISCLAIMER

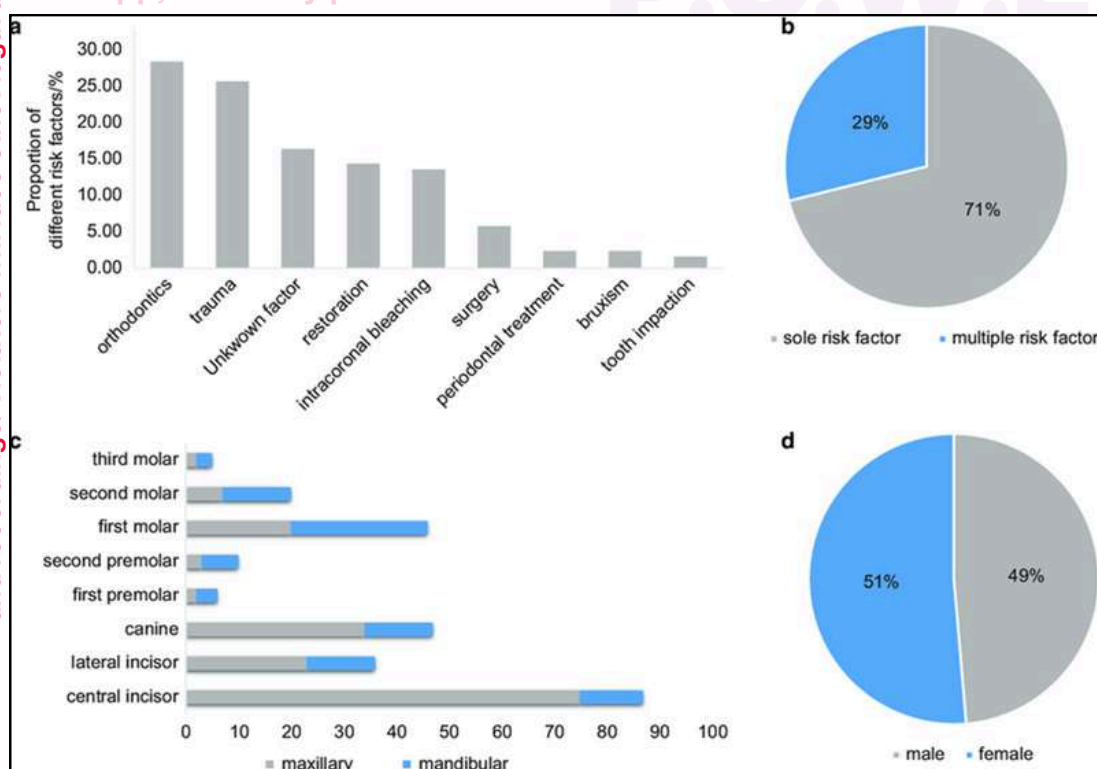
THIS IS COPYRIGHTED CONTENT. Unauthorized use, including screenshots, copying, misuse, reuse, or resale of any content from this app, is strictly prohibited. Our app monitors and records all screenshots and recordings. Violators will face strict legal action.

DISCLAIMER
THIS IS COPYRIGHTED CONTENT. Unauthorized use, including screenshots, copying, misuse, reuse, or resale of any content from this app, is strictly prohibited. Our app monitors and records all screenshots and recordings. Violators will face strict legal action.

PEDO+ORTHO

P.O.W.E.R NOTES SBQ 1

External cervical resorption is a type of pathological root resorption that is often asymptomatic. It leads to progressive loss of dental hard tissues while the pulp usually remains vital. External cervical resorption (ECR) refers to a pathological state in which resorption tissues penetrate into the dentin at the cervical aspect of the root. Inflammatory apical resorption happens during the orthodontic treatment and it will not take place after the treatment. Once the braces are off the apical resorption stops. Even in the optimal orthodontic force apical resorption can happen. In excessive orthodontic force, apical resorption is excessive which leads to tooth mobility. ECR doesn't happen immediately after ortho treatment. Systematic reviews pointed to a positive correlation between the amount of the force exerted on the teeth. Besides, extending the time of acting force also increased the severity of root resorption. Mostly excessive force will induce ECR.



- I. Retainer fixed in 11, 21 mild orthodontic force is applied on the teeth for a long time period. This can lead to ECR. So, answer is (C)

Different apex levels for incisors- it's normal to have apical root resorption in a ortho patient. Orthodontic root resorption is nothing but apical root resorption. So, option (A) and (E) are ruled out.

There's no ankylosis happening due to external trauma. So, option (D) is ruled out.

DISCLAIMER

THIS IS COPYRIGHTED CONTENT. Unauthorized use, including screenshots, copying, misuse, reuse, or resale of any content from this app, is strictly prohibited. Our app monitors and records all screenshots and recordings. Violators will face strict legal action.

DISCLAIMER

THIS IS COPYRIGHTED CONTENT. Unauthorized use, including screenshots, copying, misuse, reuse, or resale of any content from this app, is strictly prohibited. Our app monitors and records all screenshots and recordings. Violators will face strict legal action.

DISCLAIMER

THIS IS COPYRIGHTED CONTENT. Unauthorized use, including screenshots, copying, misuse, reuse, or resale of any content from this app, is strictly prohibited. Our app monitors and records all screenshots and recordings. Violators will face strict legal action.

PEDO+ORTHO

P.O.W.E.R NOTES SBQ 1

- II. Ortho treatment is given as the past dental history. So, the predominant cause is (A) only.
- III. ECR doesn't require presence of ortho forces. So, option (A) is incorrect. Options (B) and (C) are related to apical root resorption. Option (D) is true for both apical root resorption and ECR. So, option (D) is selected.
Time factor is not related to ECR. It's related to apical root resorption. So, option (E) is ruled out.
- IV. TCA is an acid. so to neutralise it you need to have a base. NaHCO_3 is the base. When you use TCA in the clinic you must have NaHCO_3 solution.
- IV. • Daughter is 7-8yrs of age. Rigid and nylon splints are not used in immature teeth/mixed dentition because during the eruption of teeth forces can act and dislodge the splint.
- Nylon (fishing line) splints are not recommended for children when there are only a few permanent teeth for stabilization of the traumatised tooth.
 - Flexible splint can be used in immature. RCT is done within 10 days in case of mature teeth. In case of immature teeth RCT is done once signs starts to appear. Otherwise you wait for apexogenesis to take place.

THIS IS COPYRIGHTED CONTENT. Unauthorized use, including screenshots, copying, misuse, reuse, or resale of any content from this app, is strictly prohibited. Our app monitors and records all screenshots and recordings. Violators will face strict legal action.

DISCLAIMER

THIS IS COPYRIGHTED CONTENT. Unauthorized use, including screenshots, copying, misuse, reuse, or resale of any content from this app, is strictly prohibited. Our app monitors and records all screenshots and recordings. Violators will face strict legal action.

THIS IS COPYRIGHTED CONTENT. Unauthorized use, including screenshots, copying, misuse, reuse, or resale of any content from this app, is strictly prohibited. Our app monitors and records all screenshots and recordings. Violators will face strict legal action.

THIS IS COPYRIGHTED CONTENT. Unauthorized use, including screenshots, copying, misuse, reuse, or resale of any content from this app, is strictly prohibited. Our app monitors and records all screenshots and recordings. Violators will face strict legal action.

WINSPERT
P.O.W.E.R
NOTES

DISCLAIMER

THIS IS COPYRIGHTED CONTENT. Unauthorized use, including screenshots, copying, misuse, reuse, or resale of any content from this app, is strictly prohibited. Our app monitors and records all screenshots and recordings. Violators will face strict legal action.

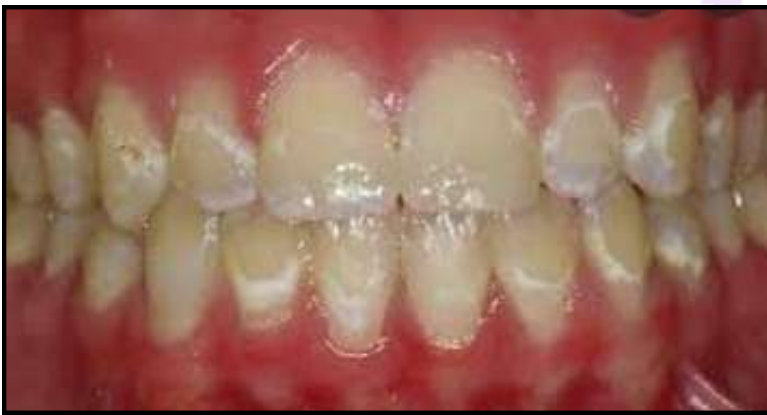DISCLAIMER

THIS IS COPYRIGHTED CONTENT. Unauthorized use, including screenshots, copying, misuse, reuse, or resale of any content from this app, is strictly prohibited. Our app monitors and records all screenshots and recordings. Violators will face strict legal action.

PEDO+ORTHO

SBQ 2

PATIENT COMES WITH COMPLAINTS OF WHITE STAINS ON TEETH WHICH HE DISLIKES A LOT. PHOTO GIVEN WITH INCIPIENT LESIONS IN THE CERVICAL AREA. ORTHO TREATMENT BUT THE ORTHODONTIST TOOK OFF THE BRACES BECAUSE HE THOUGHT THE PATIENT IS NOT KEEPING UP THE GOOD ORAL HYGIENE. NOW HE DOES A LOT OF TOOTH BRUSHING BUT THESE WHITE STAINS ARE NOT GOING AWAY. HE DRINKS 2L COLA DAILY. ORTHODONTIST ALSO GIVE HIM REMOVABLE RETAINERS WHICH HE'S NOT WEARING. HE IS ALLERGIC TO PENICILLIN AND DAIRY PRODUCTS LIKE CHEESE, MILK, AND BANANAS.



I. What is the cause of white lesions?

- A. Plaque deposits (retained plaque deposits)
- B. Acidic drinks
- C. Excessive tooth brushing
- D. Ortho treatment

II. When prescribing preventative treatment for this patient, what should be kept in mind?

- A. Allergy to dairy
- B. Allergy to penicillin
- C. Frequency of brushing
- D. Frequency of sugary drinks

III. What treatment will you give for this patient?

- A. 5000 ppm toothpaste twice daily
- B. 10 % Cpp acp and 900 ppm fl gel
- C. 900ppm Fluoride mouthwash weekly
- D. 22600 ppm varnish every month

III. What treatment will you give for this patient?

- A. 5000 ppm toothpaste twice daily
- B. 10 % Cpp acp and 900 ppm fl gel
- C. 900ppm Fluoride mouthwash weekly
- D. 22600 ppm varnish every month

DISCLAIMER

THIS IS COPYRIGHTED CONTENT. Unauthorized use, including screenshots, copying, misuse, reuse, or resale of any content from this app, is strictly prohibited. Our app monitors and records all screenshots and recordings. Violators will face strict legal action.

DISCLAIMER

THIS IS COPYRIGHTED CONTENT. Unauthorized use, including screenshots, copying, misuse, reuse, or resale of any content from this app, is strictly prohibited. Our app monitors and records all screenshots and recordings. Violators will face strict legal action.

THIS IS COPYRIGHTED CONTENT. Unauthorized use, including screenshots, copying, misuse, reuse, or resale of any content from this app, is strictly prohibited. Our app monitors and records all screenshots and recordings. Violators will face strict legal action.

DISCLAIMER

PEDO+ORTHO

SBQ 2

- IV. Considering this patient not wearing the removable retainer for bite correction. What is the major drawback of a removable retainer? (Question says retainers not aligners)
- Patients compliance issue.
 - Plaque control
 - Movements in different planes
 - Tipping forces (this option was not there in my station n it mentioned removable appliance)

- V. What are the white lesions on the cervical area?

- Incipient caries
- Demineralisation
- Hypoplasia
- Hypomineralisation

P.O.W.E.R NOTES SBQ 2

- The diagnosis is orthodontic demineralisation. The aetiology/ cause for both incipient caries and orthodontic demineralisation spots is plaque. Patient is not keeping good oral hygiene.
- The treatment for orthodontic demineralisation spots is CPP-ACP+ fluoride combination.
A recent systemic review showed that CPP-ACP with fluoride incorporate in to it was superior to fluoride alone for arresting and reversing early occlusal carious lesions. CPP-ACP will increase the Ca uptake.
In the patients who are allergic to dairy products, CPP-ACP can't be given. Therefore, fluoride alone is recommended in these patients. So, his allergic condition to CPP-ACP should be kept in mind.
- CPP-ACP can't be given due to his allergic condition. So, Option (B) is ruled out. 22600ppm varnish is used 4-5 times annually. So, option (D) is ruled out. 900ppm fluoride mouth wash weekly will not give required remineralisation. So, option (C) is ruled out.
- Plaque control is better with removable compared to fixed. So, option (B) is ruled out.
There are no movement desired or tipping forces desired from a removable retainer. So, option (C) and (D) are ruled out.
Patient is not wearing the removable retainer, so patient compliance is the drawback.
- According to the given history patient had underwent ortho treatment. Therefore, these lesions are orthodontic demineralisation spots.

DISCLAIMER

THIS IS COPYRIGHTED CONTENT. Unauthorized use, including screenshots, copying, misuse, reuse, or resale of any content from this app, is strictly prohibited. Our app monitors and records all screenshots and recordings. Violators will face strict legal action.

THIS IS COPYRIGHTED CONTENT. Unauthorized use, including screenshots, copying, misuse, reuse, or resale of any content from this app, is strictly prohibited. Our app monitors and records all screenshots and recordings. Violators will face strict legal action.

DISCLAIMER
THIS IS COPYRIGHTED CONTENT. Unauthorized use, including screenshots, copying, misuse, reuse, or resale of any content from this app, is strictly prohibited. Our app monitors and records all screenshots and recordings. Violators will face strict legal action.

PEDO+ORTHO

SBQ 3

6-7 YEARS OLD GIRL COMES WITH FATHER. CLINICAL PICTURE OF PAINLESS PEDUNCULATED MASS ON PALATAL SURFACE ADJACENT TO 21. PARENTS ARE CONCERNED ABOUT IT INTERFERING WITH THE OCCLUSION OF THEIR CHILD. PIC GIVEN: GINGIVAL OVERGROWTH LINGUAL TO 21 WHICH HAS PUSHED 21 OUT LABIALLY DUE TO OVERGROWTH, NO HISTORY OF TRAUMA OR NO PULPAL ABNORMALITIES. LOWER CENTRAL INCISOR IS INDENTED INTO THE GROWTH. THERE WAS A PICTURE OF A SMALL LIGHT PINK COLOURED LOBULATED GROWTH WITHOUT ANY INFLAMMATION AND BLEEDING. ON THE PALATAL SIDE OF 21, 21 WAS LABIALLY DISPLACED (IT MENTIONED THAT IT IS A PEDUNCULATED MASS WHICH HAD INDENTATION FROM LL1) (IT DIDN'T LOOK LIKE A PYOGENIC GRANULOMA BUT A FIBROUS EPULIS).

- I. You did a biopsy while waiting for the result. you have provisional diagnosis of pyogenic granuloma. On what basis do you diagnose as pyogenic granuloma?
 - A. Familial and hereditary condition
 - B. As it is pedunculated and painless growth
 - C. Form of actinomyces infection
 - D. Pus coming out of the lesion
- II. You want to take an IOPA of 21 to check the status inside. but the child is having a hard time or biting the film. What will you do?
 - A. Postponed the x-ray till you have the biopsy result
 - B. Ask the parents to put a lead apron on them & hold the film
 - C. Ask the DA to hold the film with the lead apron wearing
 - D. You hold the film with lead apron wearing
- III. PA is given with immature roots of 11, 21. (looks normal without any pathology) what is significant can you see from the PA?
 - A. Root of 21 is dilacerated
 - B. Radiolucent areas near the apices of the permanent incisors are the nasal cavity (looks like this is the best answer)
 - C. Roots do not correspond to the patient's age
 - D. Open apices compatible with the age
 - E. Infection
 - F. Dentigerous cyst
- IV. You come up with a diagnosis of pyogenic granuloma as it is confirmed with biopsy results. What is the cause of it?
 - A. Chronic trauma
 - B. Bacteria
 - C. Virus
 - D. Genetic or hereditary

DISCLAIMER

THIS IS COPYRIGHTED CONTENT. Unauthorized use, including screenshots, copying, misuse, reuse, or resale of any content from this app, is strictly prohibited. Our app monitors and records all screenshots and recordings. Violators will face strict legal action.

DISCLAIMER

THIS IS COPYRIGHTED CONTENT. Unauthorized use, including screenshots, copying, misuse, reuse, or resale of any content from this app, is strictly prohibited. Our app monitors and records all screenshots and recordings. Violators will face strict legal action.

THIS IS COPYRIGHTED CONTENT. Unauthorized use, including screenshots, copying, misuse, reuse, or resale of any content from this app, is strictly prohibited. Our app monitors and records all screenshots and recordings. Violators will face strict legal action.

DISCLAIMER

PEDO+ORTHO

SBQ 3

V. You did a biopsy while waiting for the result. you have provisional diagnosis of pyogenic granuloma. On what basis do you diagnose is as pyogenic granuloma?

- A. Pulpitis
- B. Familial adenomatoid polyposis
- C. Some infection by lactobacillus
- D. Infection by actinomyces/ staph or strep
- E. Chronic minor trauma

P.O.W.E.R NOTES SBQ 3

I. Fibrous epulis is a histological variant of pyogenic granuloma. There's no fibrous tissue other than an inflammatory component. Pyogenic granuloma is not associated with a familial history. It's not an infection or not associated with pus drainage. But it's a pedunculated and a painless overgrowth.

II. If the child is having a hard time on biting the film, somebody should help him. You will not postpone the x-ray as the next time the child will do the same. X-ray is needed to confirm the diagnosis and plan the treatment. The legal guardian/parent should help the child to hold the film. You don't expose your self or staff for excessive radiation. Because if you were to hold the film for every patient then the exposure for you is increased. For the parent it's just a one time exposure.

III. There were nasal cavities seen along with the apices. If the film was placed deeper, you would be able to appreciate the nasal cavities. So, the answer could be (B)

It can also be the open apices compatible with the age. So, the answer could be (D).

(B) or (D) are more likely findings. Two different radiographs were given is different stations.

IV. Chronic minor trauma either due to plaque, restoration, chronic irritation is associated with pyogenic granuloma.

V. Same as above. Pyogenic granuloma is not associated with infection, familial history. So, the answer is (E).

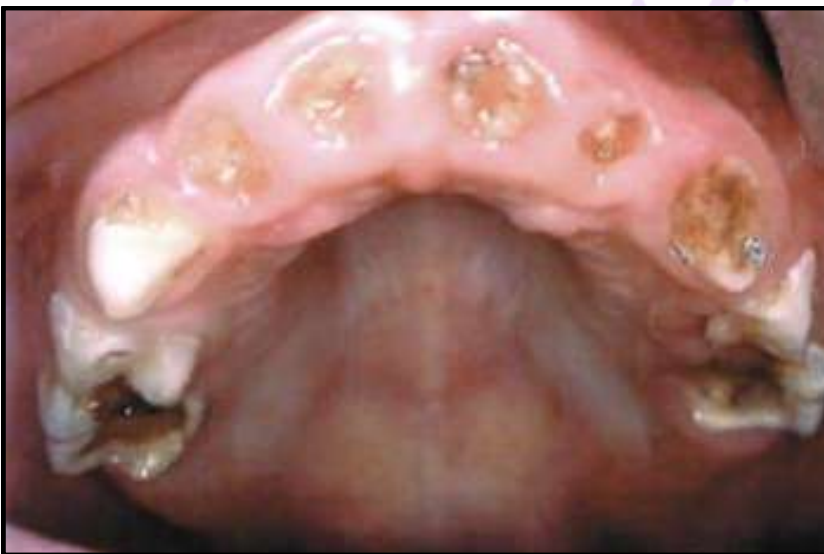DISCLAIMER

THIS IS COPYRIGHTED CONTENT. Unauthorized use, including screenshots, copying, misuse, reuse, or resale of any content from this app, is strictly prohibited. Our app monitors and records all screenshots and recordings. Violators will face strict legal action.

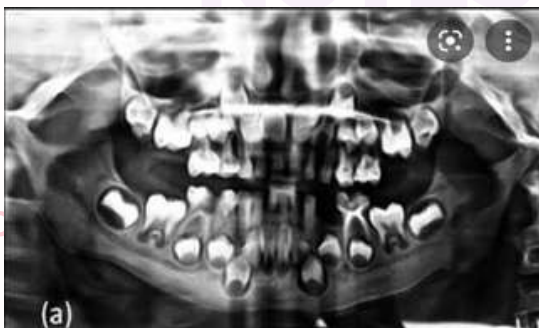
PEDO+ORTHO

SBQ 4

PRESCHOOL GIRL COMES WITH FATHER & FATHER IS COMPLAINING THAT SHE HAS NO TEETH AT THE FRONT. HAS PAIN WHILE EATING. INTRAORAL PICTURES GIVEN FOR BOTH THE ARCHES & OPG ALSO GIVEN, ALL INCISORS GROSSLY DECAYED AND XRAY GIVEN WITH SOME MOLARS DECAYED AS WELL. (PERMANENT MOLARS WERE OUT OF BONE BUT WITHIN THE MUCOSA IN XRAY. CLINICALLY NO BULGE IN SOFT TISSUE) CLINICAL PICTURE: SHOWED CARIOUS TEETH IN ANTERIORS & HAD SINUS TRACT OPENINGS IN THE ANTERIORS IN BETWEEN 21 & 23 & SOME REMEMBERED IT WAS EVEN IN THE POSTERIORS)



- I. As per clinical pictures & the radiographic given what is the expected age of this patient?
(OPG findings: First molars not erupted but reached alveolar bone already.)**



- A. 3-4 y
- B. 4-5 y
- C. 5-6 y
- D. 1-2 y
- E. 6-7 y
- F. 2-3 y

DISCLAIMER

THIS IS COPYRIGHTED CONTENT. Unauthorized use, including screenshots, copying, misuse, reuse, or resale of any content from this app, is strictly prohibited. Our app monitors and records all screenshots and recordings. Violators will face strict legal action.

DISCLAIMER
THIS IS COPYRIGHTED CONTENT. Unauthorized use, including screenshots, copying, misuse, reuse, or resale of any content from this app, is strictly prohibited. Our app monitors and records all screenshots and recordings. Violators will face strict legal action.

THIS IS COPYRIGHTED CONTENT. Unauthorized use, including screenshots, copying, misuse, reuse, or resale of any content from this app, is strictly prohibited. Our app monitors and records all screenshots and recordings. Violators will face strict legal action.

DISCLAIMER

PEDO+ORTHO

SBQ 4

II. The previous dentist had given fissure sealants & he was asked to come back in 6months. What could have been a most essential step which was missing to be done at that stage along with the sealant placement?

- A. Fluoride toothpaste
- B. Categorising child to be in high caries risk & doing early intervention.
- C. Fluoride varnish application more than twice that year.

III. While taking the radiograph the patient seems to be cooperative. But while being accompanied by the parent for being seated on the dental chair, the girl seems uncomfortable and wasn't willing to. She was also wearing a long sleeved dress on a hot sunny day. What does this presentation immediately suggests you?

- A. Suspicion of child abuse
- B. Girl is very shy
- C. She was cold on sunny day
- D. Nothing noticeable as for this age, the behaviour is very common.
- E. Child neglect suspicion
- F. She had recent injury

IV. What treatment would you do first in this case?

- A. Restoration of lower primary molar first.
- B. Extract all non savable poorly prognostic teeth first.
- C. Managing diet.

V. How do you restore 75/85 donot remember which one exactly.(badly broken down carious molar)

- A. Calcium hydroxide with stainless steel crown
- B. GIC
- C. Composite build up

THIS IS COPYRIGHTED
CONTENT. Unauthorized use,
including screenshots,
copying, misuse, reuse, or
resale of any content from
this app, is strictly prohibited.
Our app monitors and records
all screenshots and
recordings. Violators will face
strict legal action.

DISCLAIMER

THIS IS COPYRIGHTED CONTENT. Unauthorized use, including screenshots, copying, misuse, reuse, or resale of any content from this app, is strictly prohibited. Our app monitors and records all screenshots and recordings. Violators will face strict legal action.

DISCLAIMER
THIS IS COPYRIGHTED CONTENT. Unauthorized use, including screenshots, copying, misuse, reuse, or resale of any content from this app, is strictly prohibited. Our app monitors and records all screenshots and recordings. Violators will face strict legal action.

PEDO+ORTHO

P.O.W.E.R NOTES SBQ 4

- I. Molars are still within the soft tissues but out of the bone. So, it's about to erupt. It erupts at the age of 6yrs. Since it's not erupted yet the age is 5-6yrs.
- II. Anterior teeth can not be protected with sealants.
When you do sealants in a high caries risk patient, fluoride varnish application is an adjunct to it. Smooth surfaces are protected by the application of fluoride varnish.
Dentist categorised the patient as a high caries risk patient and did the early intervention by application of sealers, but he missed applying fluoride varnish.
- III. According to the history given it denotes that it's a child abuse scenario rather than child neglect. The child was uncomfortable when she was accompanied by the parent. She must be wearing along sleeve dress on a hot sunny day to cover up her body marks.

IV. CARIES MANAGEMENT

1. EMERGENCY PHASE

(EXTRACT ALL THE NON-SAVABLE POORLY PROGNOSSED TEETH)



2. MANAGE DIET



3. STABILIZE THE SAVABLE TEETH WITH TFF



4. EDUCATE THE PATIENT/PARENT



5. RESTORE WITH PERMANENT RESTORATIONS

- V. SS crowns are the best for the badly broken-down primary molars.

DISCLAIMER

THIS IS COPYRIGHTED CONTENT. Unauthorized use, including screenshots, copying, misuse, reuse, or resale of any content from this app, is strictly prohibited. Our app monitors and records all screenshots and recordings. Violators will face strict legal action.

DISCLAIMER

THIS IS COPYRIGHTED CONTENT. Unauthorized use, including screenshots, copying, misuse, reuse, or resale of any content from this app, is strictly prohibited. Our app monitors and records all screenshots and recordings. Violators will face strict legal action.

DISCLAIMER

THIS IS COPYRIGHTED CONTENT. Unauthorized use, including screenshots, copying, misuse, reuse, or resale of any content from this app, is strictly prohibited. Our app monitors and records all screenshots and recordings. Violators will face strict legal action.

PEDO+ORTHO

SBQ 5

QUESTION ABOUT SPACE MAINTAINER

43,44,45 HAS NOT YET ERUPTED, NO ENOUGH SPACE FOR 43 44 AND 45. 46 IS PRESENT IN ORAL CAVITY. OPG SHOWED 43,44,45 WERE PRESENT. YOU HAVE PLANNED TO EXTRACT 85. SHE HAD PREMATURE LOSS OF 83.THERE WAS A MIDLINE SHIFT (TOWARDS RIGHT TO LEFT)

I. What is the malocclusion as per the intraoral picture?

- A. Class II div 2
- B. Class II div 1
- C. Class I
- D. Class III

II. Previous Dentist has extracted a tooth.What would have been done at that time when she had lost the canine?(Whether the treatment is for midline shift or the arch perimeter? (Only 83 was lost)

- A. Molar distalization space maintainer from 42
- B. Band and loop space maintainer
- C. Extract 73
- D. Lingual arch from 32 to 42

III. In which direction was the midline shift?

- A. Towards right with space loss of 43 44 45
- B. Towards left with space loss of 83 84 85
- C. Towards right with space loss on 33 34 35
- D. Towards left space loss of 73 74 75

P.O.W.E.R NOTES SBQ 5

I. Pictures/ radiograph is needed to answer this question.

- II. • Lingual arch is preferred in a bilateral canine loss. So, option is (D) is ruled out. (D) is done to prevent the collapse of permanent incisors lingually. If the chief complaint says that her permanent incisors are lingually collapsed, then lingual arch could have been give. It's mostly used in case of bilateral molar loss.
 - To prevent midline shift contra lateral extraction is performed.
 - Band and loop are for the molar situations.
 - Molar distalisation is not done for the incisors.

III. Midline shift happens towards the same side in which the canine is lost.

DISCLAIMER

THIS IS COPYRIGHTED CONTENT. Unauthorized use, including screenshots, copying, misuse, reuse, or resale of any content from this app, is strictly prohibited. Our app monitors and records all screenshots and recordings. Violators will face strict legal action.

DISCLAIMER
THIS IS COPYRIGHTED CONTENT. Unauthorized use, including screenshots, copying, misuse, reuse, or resale of any content from this app, is strictly prohibited. Our app monitors and records all screenshots and recordings. Violators will face strict legal action.

THIS IS COPYRIGHTED CONTENT. Unauthorized use, including screenshots, copying, misuse, reuse, or resale of any content from this app, is strictly prohibited. Our app monitors and records all screenshots and recordings. Violators will face strict legal action.

PEDO+ORTHO

SBQ 6

CHILD COMES WITH THE MOTHER. ONE OF THE FRONT TEETH IS MISSING. 12 HAD DILACERATION.

I. What is the deciding factor to manage it?

- A. To extract impacted 12 or surgically expose to fix it with ortho
- B. The space or lack of in the mouth
- C. The dilaceration
- D. Position of impacted

II. You suspect child abuse what would you do next?

- A. Send the parent outside and ask the child
- B. Take the history of the injuries from the parent
- C. Call the authority

P.O.W.E.R NOTES SBQ 6

- I.
 - To extract or to surgically expose are the management option but they are not the deciding factors.
 - The lack of space is one of the factors but it's not the predominant factor.
 - Dilaceration is a finding and not a deciding factor. Dilaceration is a course of impaction. It can be treated by surgically or ortho traction or by extraction.
 - Position of impaction will decide whether you can surgically expose it and orthodontically bring it to its normal position or not. If it's too far palatally placed, you can't orthodontically correct it. Therefore, position of impaction is the deciding factor.

II. Assess the child (history/ examination/ talk to the child)

You must see whether the history matches with the injuries or not. Because children do get injured in childhood more often. First you must take the history from the parent as children are poor historians. If the history doesn't match with the injuries, then you can take the history from the child.

If the injuries are seen within the safety triangle and the history doesn't correlate with the injuries, it will be a suspicious case. Then you may call the authorities or colleague.

(Reference: Odel case 36- skateboard accident flow chart)

DISCLAIMER

THIS IS COPYRIGHTED CONTENT. Unauthorized use, including screenshots, copying, misuse, reuse, or resale of any content from this app, is strictly prohibited. Our app monitors and records all screenshots and recordings. Violators will face strict legal action.

DISCLAIMER
THIS IS COPYRIGHTED CONTENT. Unauthorized use, including screenshots, copying, misuse, reuse, or resale of any content from this app, is strictly prohibited. Our app monitors and records all screenshots and recordings. Violators will face strict legal action.

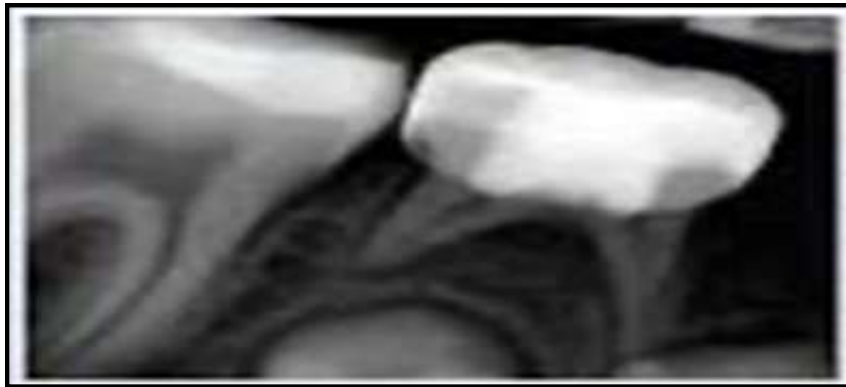
THIS IS COPYRIGHTED CONTENT. Unauthorized use, including screenshots, copying, misuse, reuse, or resale of any content from this app, is strictly prohibited. Our app monitors and records all screenshots and recordings. Violators will face strict legal action.

DISCLAIMER

PEDO+ORTHO

SBQ 7

9 YEARS OLD ALI CAME WITH FATHER FOR A ROUTINE DENTAL CHECK UP. HIS FATHER SAID SOME TREATMENT WAS DONE BY THE PREVIOUS DENTIST BUT THEY DON'T REMEMBER AND DON'T HAVE ANY RECORDS ON HAND OR CONTACT OF THE PREVIOUS DENTIST. HE COMPLAINS OF NO PAIN NO DISCOMFORT. (MORE RESORPTION OF ROOTS / FURCATION INVOLVEMENT THAN THIS IMAGE, THERE WERE TWO BITEWINGS PROVIDED. RIGHT AND LEFT SIDE)



I. What is TX done for 85?

- A. Pulpotomy with ss crown
- B. Only ss crown
- C. Pulpotomy with preformed resin crown SS D) crown with Hall technique

II. Current TX for 4 (pulpotomy and crown) and 85 (caries close to pulp)

- A. Do nothing for 84 and gic for 85
- B. Do nothing for 84 and Pulpectomy for 85 C) Extract 84 and ssc for 85
- D. Extract 84 and pulpotomy and ssc for 85 E) Do nothing for 84 and ssc for 85
- F. Extraction of 84 and steel crown on 85
- G. Pulpectomy of 84 and steel crown on 85

III. Child 9 years old child does not like to use adult toothpaste, doesn't like its taste, so using children's toothpaste, is at high caries risk. Brushes only when he likes. What should he be advised?

- A. Use children toothpaste twice in a day and 900 ppm mouthwash in daily routine
- B. Use 1500 ppm toothpaste twice plus 200 ppm mouthwash 5000 fluoride toothpaste
- C. Use adult toothpaste twice daily and
- D. Use children's toothpaste thrice in a day.

DISCLAIMER

THIS IS COPYRIGHTED CONTENT. Unauthorized use, including screenshots, copying, misuse, reuse, or resale of any content from this app, is strictly prohibited. Our app monitors and records all screenshots and recordings. Violators will face strict legal action.

DISCLAIMER
THIS IS COPYRIGHTED CONTENT. Unauthorized use, including screenshots, copying, misuse, reuse, or resale of any content from this app, is strictly prohibited. Our app monitors and records all screenshots and recordings. Violators will face strict legal action.

THIS IS COPYRIGHTED CONTENT. Unauthorized use, including screenshots, copying, misuse, reuse, or resale of any content from this app, is strictly prohibited. Our app monitors and records all screenshots and recordings. Violators will face strict legal action.

DISCLAIMER

PEDO+ORTHO

SBQ 7

IV. 54/55 caries involving enamel and dentine on proximal wall involving the cusp (c4). What will be the treatment?

- A. Restore with gic
- B. Use ssc
- C. No treatment

V. Similar picture provided: lowest premolar. Father says he has seen this empty space since almost an year. (Empty space is there for a long time) Nothing is clearly visible below the cej (Very slight tip of erupting tooth visible just below bone on x ray) (no tip visible). What will you do immediately

- A. Radiograph to see location of premolar B) Refer to ortho.
- C. Do nothing
- D. Save space with space maintainer

P.O.W.E.R NOTES SBQ 7

Resorption along with the furcation represents the physiological resorption. As there's no signs and symptoms or no exudate or no soft tissue involvement. physiological bone turnover is undergoing for eruption.

- I.
 - Restorative material is extending up to the pulpal floor. Therefore, pulp therapy is performed in this tooth and a crown was given. So, option (B) is ruled out.
 - Hall technique is done for the uncooperative patients without doing a restoration. So, option (D) is ruled out.
 - Resin crown is radiolucent. So, option (C) is ruled out.
- II. 84 is already treated. No signs and symptoms in relation to 84. So, options (C),(D), (F),(G) are ruled out.
GIC is not permanent restorative material. It's either SS crown, RMGIC, composite is used for primary teeth as a permanent restorative material. Among them the most preferred is the SS crown. Option (A) is ruled out.
In 85 the caries is closer to pulp but there's irreversible pulpitis associated with it. So, option (B) is ruled out.
- III. After 6yrs of age child can use a tooth paste with 1000-1500ppm according to TG. Adults tooth paste is not matching for her. There are children's tooth paste with 1500ppm. 900ppm mouth wash is for weekly use. 200ppm mouth wash is for daily use and can be used after 6yrs of age.
- IV. According to ICDAS, c4 requires restoration as it involves enamel and deeper dentin. GIC is not adequate. SSC is the best option.
- V. Tooth has not erupted in 1years time. To confirm the presence of premolar and its location radiograph is needed. For now, only the clinical picture is available. Depending of the radiograph you can refer the patient or can advice a space maintainer or do nothing if the tooth is almost erupting.

DISCLAIMER

THIS IS COPYRIGHTED CONTENT. Unauthorized use, including screenshots, copying, misuse, reuse, or resale of any content from this app, is strictly prohibited. Our app monitors and records all screenshots and recordings. Violators will face strict legal action.

DISCLAIMER

THIS IS COPYRIGHTED CONTENT. Unauthorized use, including screenshots, copying, misuse, reuse, or resale of any content from this app, is strictly prohibited. Our app monitors and records all screenshots and recordings. Violators will face strict legal action.

THIS IS COPYRIGHTED CONTENT. Unauthorized use, including screenshots, copying, misuse, reuse, or resale of any content from this app, is strictly prohibited. Our app monitors and records all screenshots and recordings. Violators will face strict legal action.

DISCLAIMER

PEDO+ORTHO

SBQ 8

DWAYNE, A 6 YEAR CHILD PATIENT COMES WITH MOTHER IN SCHOOL HOURS WHO NOTICED A LARGE HOLE IN A TOOTH GROSSLY CARIOUS 85, NO PAIN. CHILD HAS TYPE 1 DIABETES.

I. What investigation will you do?

- A. Iopa
- B. Percussion
- C. Sensibility test

II. On iopa furcation involvement seen. How will you treat 85?

- A. Extraction
- B. Rct
- C. Single sitting RCT
- D. Wait n observe

III. What sequelae will happen if 85 is not treated?

- A. Spread of infection
- B. Ectopic eruption of permanent
- C. Periapical abscess
- D. Necrosis
- E. Ankylosis

IV. Needs exo, he pushes your arm away every time when you attempt to put the forceps on the tooth, how do you handle this? (Version- this was the second time child was behaving like this)

- A. Reassure him and ask mother to hold his hands (exact language) Mother restrains arms of child
- B. Reassure him and ask the nurse to hold his hand /The nurse restrains arms of child
- C. Don't do extraction today and reschedule
- D. Reschedule and do extraction under sedation
- E. Reassure him and continue with the extraction
- F. Refer to specialist

V. Which local anaesthesia will you give for the child?

- A. 2 percent Lignocaine with 1:80000 adrenaline
- B. Prilocaine with felypressin

VI. What will be the complication after extraction considering his diabetes?

- A. Infection
- B. Healing
- C. Bleeding
- D. His age

DISCLAIMER

THIS IS COPYRIGHTED CONTENT. Unauthorized use, including screenshots, copying, misuse, reuse, or resale of any content from this app, is strictly prohibited. Our app monitors and records all screenshots and recordings. Violators will face strict legal action.

DISCLAIMER

THIS IS COPYRIGHTED CONTENT. Unauthorized use, including screenshots, copying, misuse, reuse, or resale of any content from this app, is strictly prohibited. Our app monitors and records all screenshots and recordings. Violators will face strict legal action.

THIS IS COPYRIGHTED CONTENT. Unauthorized use, including screenshots, copying, misuse, reuse, or resale of any content from this app, is strictly prohibited. Our app monitors and records all screenshots and recordings. Violators will face strict legal action.

DISCLAIMER

PEDO+ORTHO

P.O.W.E.R NOTES SBQ 8

- I. Child with DM1 has a grossly decayed tooth and no pain. percussion or pulp sensibility will not give the definitive results. IOPA will be helpful to get a clear idea. And also, 6yrs old child is a poor historian. So, IOPA will be the best.
- II. No point in doing RCT as there's furcation involvement in the primary tooth. There's poor prognosis. In case if the orthodontist wants to save the tooth for another 1yr then we could do RCT though the furcation is involved.
- III. The infection continues to spread if it is not treated. It can either become a periapical abscess or spreading infection. Among (A) and (c), best is (A).
- IV. No physical constraint is indicated as it leads to trauma to the patient. So, (A) and (B) gets ruled out. In an uncooperative child as a dentist you can recommend nitrous oxide sedation. But he's a diabetic patient. When doing under nitrous oxide sedation patient must not eat anything few hours before the surgery as there is a risk of getting hypoglycaemia in a 6yrs old diabetic patient. Slightly more management and more care are needed for this patient. So, specialist referral is required as the child is diabetic.
If this patient is not diabetic, option (D) would have been the answer if the option was corrected as under "conscious sedation". But still conscious sedation is done by specialist. Can't be given by a general dentist. So, this option will be incorrect. For child patients BDZ are given under specialist set up and N2O can be given under general setup.
- V. In diabetes there's no contraindication in giving lignocaine with adrenaline. We use prilocaine with felypressin when lignocaine with adrenaline is contraindicated. In uncontrolled DM adrenaline and elective procedures are contraindicated. Adrenaline increase the sugar levels.
- VI. Infection and poor healing are associated with DM. Infection can be managed with AB. For healing we must rely on body alone. That can be a major challenge that we must observe.

THIS IS COPYRIGHTED CONTENT. Unauthorized use, including screenshots, copying, misuse, reuse, or resale of any content from this app, is strictly prohibited. Our app monitors and records all screenshots and recordings. Violators will face strict legal action.

DISCLAIMER

THIS IS COPYRIGHTED CONTENT. Unauthorized use, including screenshots, copying, misuse, reuse, or resale of any content from this app, is strictly prohibited. Our app monitors and records all screenshots and recordings. Violators will face strict legal action.

DISCLAIMER

THIS IS COPYRIGHTED CONTENT. Unauthorized use, including screenshots, copying, misuse, reuse, or resale of any content from this app, is strictly prohibited. Our app monitors and records all screenshots and recordings. Violators will face strict legal action.

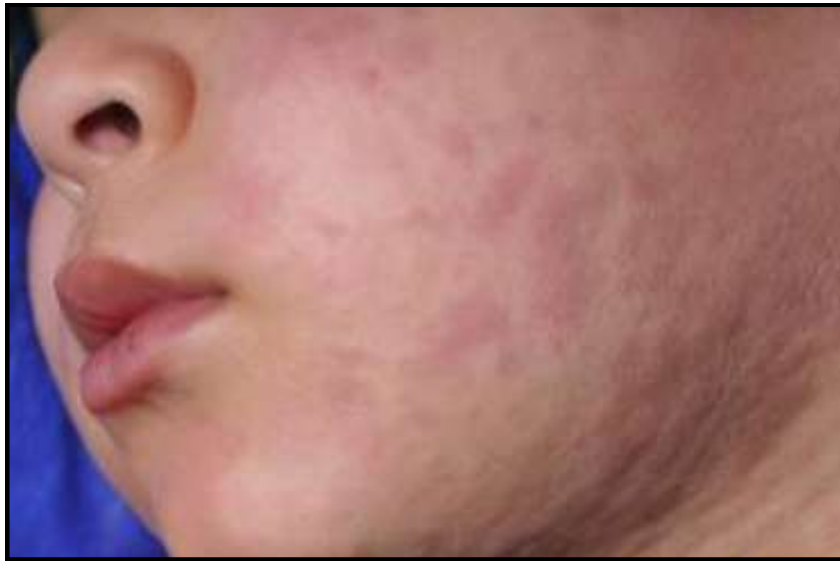DISCLAIMER

THIS IS COPYRIGHTED CONTENT. Unauthorized use, including screenshots, copying, misuse, reuse, or resale of any content from this app, is strictly prohibited. Our app monitors and records all screenshots and recordings. Violators will face strict legal action.

PEDO+ORTHO

SBQ 9

4 YEAR OLD , MOTHER CALLED AT PRACTICE THAT HER SON IS NOT EATING WELL (POSSIBLE TOOTH ISSUE), AS HE IS HAVING MEASLES, (PIC WAS GIVEN WITH TYPICAL RASH ALL OVER THE FACE, SWELLING OVER THE CHEEKS AND RASHES TYPICALLY AROUND LIPS) SHE IS GIVING HIM ICE CREAM BUT THE TOOTH AT THE BACK HURTS ON EATING ICE CREAM. SHE DOESN'T BELIEVE IN VACCINATION AS THINKS IT MAY AFFECT HIS GENERAL HEALTH AND CAUSE AUTISM.



I. What is the most appropriate treatment at this time? You suspect acute pulpitis.

- A. Manage with pain killers until the patient is no longer infectious
- B. Refer to Pediatric specialist
- C. Refer him to emergency department of hospital
- D. Book an appointment for today and see the child.

II. Then he developed swelling 24 hours later, you know it's an abscess and you decided not to delay the treatment, which is the most appropriate method to treat him ?

- A. Using standard precautions
- B. Using disposable instruments, single use items as much as possible
- C. Last patient of day
- D. Using P2/ N95 mask

III. His mum says she did not vaccinate him as she believes the Measles vaccine can cause autism. How can you discuss this matter with her?

- A. Tell her to discuss pros and cons of vaccine with her trusted family doctor
- B. Tell her that evidence based studies have refuted the connection between the measles vaccine and autism
- C. Tell her to discuss with the trusted family members
- D. Tell her that she can get the information from trusted websites.

DISCLAIMER

THIS IS COPYRIGHTED CONTENT. Unauthorized use, including screenshots, copying, misuse, reuse, or resale of any content from this app, is strictly prohibited. Our app monitors and records all screenshots and recordings. Violators will face strict legal action.

THIS IS COPYRIGHTED CONTENT. Unauthorized use, including screenshots, copying, misuse, reuse, or resale of any content from this app, is strictly prohibited. Our app monitors and records all screenshots and recordings. Violators will face strict legal action.

DISCLAIMER
THIS IS COPYRIGHTED CONTENT. Unauthorized use, including screenshots, copying, misuse, reuse, or resale of any content from this app, is strictly prohibited. Our app monitors and records all screenshots and recordings. Violators will face strict legal action.

PEDO+ORTHO

P.O.W.E.R NOTES SBQ 9

- I. Measles is a transmissible infection through the respiratory route. It's a viral infection which can spread through the droplets. According to the ICG, patient should be deferred until they are no longer infectious. Eg: measles, mumps, TB. And should be managed with analgesics. So, option (A) is correct.
- II. But where the treatment cannot be deferred (e.g: facial swelling), transmission-based precaution must be used for the provision of dental treatment. These are described as below;
 - To be seen the last patient of the day
 - Immunise against the current status of influenza
 - Suitable antimicrobial pre- procedure mouth rinse
 - Wear surgical masks that are adapted well to the face. Use of surgical respirators is optional.
 - For restorative dentistry use a dental dam and high velocity evacuation to reduce the formation of aerosols. For other procedures, use techniques that minimise the production of splashes of fluids and generation of aerosols.
 - Undertake the surface cleaning process twice.

Both options (C) and (D) are correct but (D) is optional according to ICG. So answer is (C).
- III. Dentist can give opinion on dental related problems. But when it's related to vaccination you advise them to get the opinion from the family doctor/GP.

THIS IS COPYRIGHTED CONTENT. Unauthorized use, including screenshots, copying, misuse, reuse, or resale of any content from this app, is strictly prohibited. Our app monitors and records all screenshots and recordings. Violators will face strict legal action.

DISCLAIMER

THIS IS COPYRIGHTED CONTENT. Unauthorized use, including screenshots, copying, misuse, reuse, or resale of any content from this app, is strictly prohibited. Our app monitors and records all screenshots and recordings. Violators will face strict legal action.

DISCLAIMER
THIS IS COPYRIGHTED CONTENT. Unauthorized use, including screenshots, copying, misuse, reuse, or resale of any content from this app, is strictly prohibited. Our app monitors and records all screenshots and recordings. Violators will face strict legal action.

DISCLAIMER

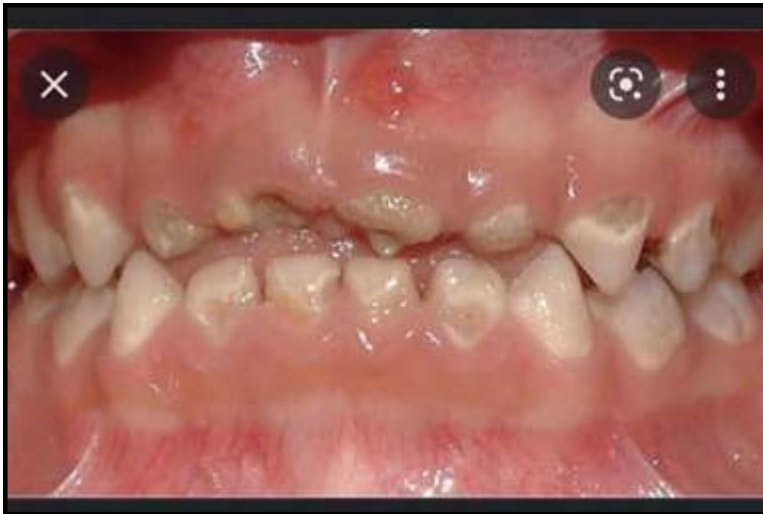THIS IS COPYRIGHTED CONTENT. Unauthorized use, including screenshots, copying, misuse, reuse, or resale of any content from this app, is strictly prohibited. Our app monitors and records all screenshots and recordings. Violators will face strict legal action.

PEDO+ORTHO

SBQ 10

A 4-5 YEAR OLD CHILD WITH RAMPANT CARIES (MULTIPLE INTRAORAL PHOTOS GIVEN SHOWING ALMOST ALL UPPER PRIMARY ANTERIOR RETAINED ROOTS, 54 & 64 GROSSLY CARIOUS, BUCCAL TO 54 AND 61 WITH ABSCESS/SINUS) (74,75 WITH RESTORABLE CARIES). IOPA FOR EACH QUADRANT WERE PROVIDED AS WELL. PATIENT COMPLAINED OF PAIN FROM DRINKING AND EATING ON BOTH SIDES.

WHAT WOULD BE THE DEFINITE TREATMENT? SINUS WAS PRESENT WITH RESPECT TO INCISOR AND MOLAR BOTH.



- A. Extraction of all incisors with hopeless prognosis
- B. Extraction of 54 and 64
- C. Pulpotomy and SCC for 74

THIS IS COPYRIGHTED CONTENT. Unauthorized use, including screenshots, copying, misuse, reuse, or resale of any content from this app, is strictly prohibited. Our app monitors and records all screenshots and recordings. Violators will face strict legal action.

DISCLAIMER

THIS IS COPYRIGHTED CONTENT. Unauthorized use, including screenshots, copying, misuse, reuse, or resale of any content from this app, is strictly prohibited. Our app monitors and records all screenshots and recordings. Violators will face strict legal action.

THIS IS COPYRIGHTED CONTENT. Unauthorized use, including screenshots,

copying, misuse, reuse, or resale of any content from this app, is strictly prohibited. Our app monitors and records all screenshots and recordings. Violators will face strict legal action.

THIS IS COPYRIGHTED CONTENT. Unauthorized use, including screenshots, copying, misuse, reuse, or resale of any content from this app, is strictly prohibited. Our app monitors and records all screenshots and recordings. Violators will face strict legal action.

DISCLAIMER
THIS IS COPYRIGHTED CONTENT. Unauthorized use, including screenshots, copying, misuse, reuse, or resale of any content from this app, is strictly prohibited. Our app monitors and records all screenshots and recordings. Violators will face strict legal action.

PEDO+ORTHO

P.O.W.E.R NOTES SBQ 10

I.

CARIES MANAGEMENT

1. EMERGENCY PHASE

(EXTRACT ALL THE NON-SAVABLE POORLY PROGNOSSED TEETH)



2. MANAGE DIET



3. STABILIZE THE SAVABLE TEETH WITH TF



4. EDUCATE THE PATIENT/PARENT



5. RESTORE WITH PERMANENT RESTORATIONS

Rampant caries starts with max. incisors, then spreading to the max. posteriors. Mandibular anterior are the last to be affected because they have an immune environment due to the presence of salivary glands.

DISCLAIMER

THIS IS COPYRIGHTED CONTENT. Unauthorized use, including screenshots, copying, misuse, reuse, or resale of any content from this app, is strictly prohibited. Our app monitors and records all screenshots and recordings. Violators will face strict legal action.

THIS IS COPYRIGHTED CONTENT. Unauthorized use, including screenshots, copying, misuse, reuse, or resale of any content from this app, is strictly prohibited. Our app monitors and records all screenshots and recordings. Violators will face strict legal action.

DISCLAIMER

THIS IS COPYRIGHTED CONTENT. Unauthorized use, including screenshots, copying, misuse, reuse, or resale of any content from this app, is strictly prohibited. Our app monitors and records all screenshots and recordings. Violators will face strict legal action.

THIS IS COPYRIGHTED CONTENT. Unauthorized use, including screenshots, copying, misuse, reuse, or resale of any content from this app, is strictly prohibited. Our app monitors and records all screenshots and recordings. Violators will face strict legal action.

DISCLAIMER

THIS IS COPYRIGHTED CONTENT. Unauthorized use, including screenshots, copying, misuse, reuse, or resale of any content from this app, is strictly prohibited. Our app monitors and records all screenshots and recordings. Violators will face strict legal action.

PEDO+ORTHO

SBQ 11

PATIENT NEEDED EXTRACTION, PATIENT WAS ALLERGIC TO NICKEL.(43 KG 12 YEAR OLD CHILD).WHAT ANAESTHETIC TO GIVE?

- A. 13.2 ml lignocaine with adrenaline
- B. 13.2 ml lignocaine with epinephrine
- C. 13.2 ml prilocaine with felypressin
- D. 13.2 m articaine

P.O.W.E.R NOTES SBQ 11

- I. All the options have the same value. So, no need to calculate. Patient is allergic to nickel but it's not a contraindication to lignocaine with adrenaline. PFM crowns are contraindicated in Nickle allergy.

THIS IS COPYRIGHTED CONTENT. Unauthorized use, including screenshots, copying, misuse, reuse, or resale of any content from this app, is strictly prohibited. Our app monitors and records all screenshots and recordings. Violators will face strict legal action.

DISCLAIMER

THIS IS COPYRIGHTED CONTENT. Unauthorized use, including screenshots, copying, misuse, reuse, or resale of any content from this app, is strictly prohibited. Our app monitors and records all screenshots and recordings. Violators will face strict legal action.

THIS IS COPYRIGHTED CONTENT. Unauthorized use, including screenshots, copying, misuse, reuse, or resale of any content from this app, is strictly prohibited. Our app monitors and records all screenshots and recordings. Violators will face strict legal action.

THIS IS COPYRIGHTED CONTENT. Unauthorized use, including screenshots, copying, misuse, reuse, or resale of any content from this app, is strictly prohibited. Our app monitors and records all screenshots and recordings. Violators will face strict legal action.

THIS IS COPYRIGHTED CONTENT. Unauthorized use, including screenshots, copying, misuse, reuse, or resale of any content from this app, is strictly prohibited. Our app monitors and records all screenshots and recordings. Violators will face strict legal action.

DISCLAIMER

THIS IS COPYRIGHTED CONTENT. Unauthorized use, including screenshots, copying, misuse, reuse, or resale of any content from this app, is strictly prohibited. Our app monitors and records all screenshots and recordings. Violators will face strict legal action.

DISCLAIMER

THIS IS COPYRIGHTED CONTENT. Unauthorized use, including screenshots, copying, misuse, reuse, or resale of any content from this app, is strictly prohibited. Our app monitors and records all screenshots and recordings. Violators will face strict legal action.

PEDO+ORTHO

SBQ 12

AMARI 12 YEARS OLD (BOY) BASKETBALL TRAUMA, PATIENT WAS AGITATED AND CONFUSE, BOY FELL DOWN WHY, PT LOOKED UNWELL. YOU ASK "WHEN DID YOU GET THE INJURY?" TOOTH WAS MOBILE AND PAINFUL, BLEEDING IN SULCUS.

I. What is the clinical significance of asking when did the injury happen.

- A. Indicate the prognosis of the treatment
- B. Requirement for emergency referral.
- C. Time suggests what treatment to provide
- D. To check if tetanus is up to date.
- E. What environment it happened

II. Patient felt nauseous after the incident. There was dry blood crusting in the nose. What is the first question you ask the parents?

- A. Any loss of consciousness
- B. Is the tooth mobile
- C. How did he fall down
- D. X-ray to see the fracture in the lip and gingiva

III. Mouth guards to prevent sports injury based on the nature of their sports Child plays Rugby. Which mouthguard IS RECOMMENDED FOR 14-15 year old.

- A. Stock
- B. Custom with bilaminar
- C. Custom with tri laminar,
- D. Custom made laminar
- E. Boil and bite

IV. Mouth guard replacement should be done (for 14 and 15-year-old boys)

- A. When discolored
- B. Every year
- C. When they start another contact sport
- D. Only when dental treatment is done.

V. When asked about basket ball player did not wear mouth guard, he says he only wears on competition and not on practice matches. So what do you decide?

- A. Provide mouth guards free of cost to players
- B. Provide mouth guards at cheaper price
- C. Advise coach regarding the benefit of using (arrange meeting with coaches to advise)
- D. Explain the Cost-benefit analysis of using mouth guards to players (by attending official club meetings)

DISCLAIMER

THIS IS COPYRIGHTED CONTENT. Unauthorized use, including screenshots, copying, misuse, reuse, or resale of any content from this app, is strictly prohibited. Our app monitors and records all screenshots and recordings. Violators will face strict legal action.

DISCLAIMER

THIS IS COPYRIGHTED CONTENT. Unauthorized use, including screenshots, copying, misuse, reuse, or resale of any content from this app, is strictly prohibited. Our app monitors and records all screenshots and recordings. Violators will face strict legal action.

THIS IS COPYRIGHTED CONTENT. Unauthorized use, including screenshots, copying, misuse, reuse, or resale of any content from this app, is strictly prohibited. Our app monitors and records all screenshots and recordings. Violators will face strict legal action.

DISCLAIMER

PEDO+ORTHO

P.O.W.E.R NOTES SBQ 12

- I. Importance of asking “when did you get the injury?” for this there is two main reasons. One is dental and the other is the medical. The most important is the medical reason, that is to rule out the brain injury. So, you must refer the patient to the hospital for the neurological assessment.
- II. Concussion can lead to nausea. Dry blood crusting in the nose indicates internal injury. Clinical symptom of brain injury is the loss of consciousness. So, that should be asked first.

BILAMINAR MOUTH GUARD	TRILAMINAR MOUTH GUARD
Age- up to 13yrs for mixed dentition.	Age- 14yrs onwards for permanent teeth
Medium impact sports	High impact sports. E.g. Rugby, hockey, AFL, karate, squash, kickboxing.

- III. Stock mouth guards are not recommended in Australia.
- IV. Examine your mouth guard regularly for signs of deterioration and replace if it is split or if the resilience, fit or bite have changed.
Have your mouth guard check for signs of wear, deterioration or reduction in its fit as part of your routine dental review, or at least annually by your dental practitioner.
- V. Giving the mouth guard at a cheaper price won't motivate them to wear it. Advising and explaining the benefits of the mouth guard should be done by the dentist rather than by the coach.

THIS IS COPYRIGHTED CONTENT. Unauthorized use, including screenshots, copying, misuse, reuse, or resale of any content from this app, is strictly prohibited. Our app monitors and records all screenshots and recordings. Violators will face strict legal action.

DISCLAIMER

THIS IS COPYRIGHTED CONTENT. Unauthorized use, including screenshots, copying, misuse, reuse, or resale of any content from this app, is strictly prohibited. Our app monitors and records all screenshots and recordings. Violators will face strict legal action.

DISCLAIMER
THIS IS COPYRIGHTED CONTENT. Unauthorized use, including screenshots, copying, misuse, reuse, or resale of any content from this app, is strictly prohibited. Our app monitors and records all screenshots and recordings. Violators will face strict legal action.

DISCLAIMER

THIS IS COPYRIGHTED CONTENT. Unauthorized use, including screenshots, copying, misuse, reuse, or resale of any content from this app, is strictly prohibited. Our app monitors and records all screenshots and recordings. Violators will face strict legal action.

PEDO+ORTHO

SBQ 13

I. We notice they are drinking sports drinks before inserting their mouthguards when training, and games to keep their hydration and replace electrolytes. What should your advice them to do:

- A. Drink sport drinks before putting on the mouth guard
- B. When the mouth guard is already on
- C. Substitute sports drinks for water
- D. Sugar free sports drinks

II. It was said the players use mouthguards immediately after having sport drinks and they ask consequences of that on their dentition.

- A. Erosion
- B. Caries
- C. Hypocalcification

III. What would you suggest instead for SNACK for the mid game break

- A. Caramel Muesli Bar
- B. Yogurt Based Smoothie
- C. Orange Wedges
- D. Apple Slices
- E. Dark Chocolate

THIS IS COPYRIGHTED
CONTENT. Unauthorized use,
including screenshots,
copying, misuse, reuse, or
resale of any content from
this app, is strictly prohibited.
Our app monitors and records
all screenshots and
recordings. Violators will face
strict legal action.

THIS IS COPYRIGHTED
CONTENT. Unauthorized use,
including screenshots,
copying, misuse, reuse, or
resale of any content from
this app, is strictly prohibited.
Our app monitors and records
all screenshots and
recordings. Violators will face
strict legal action.

THIS IS COPYRIGHTED
CONTENT. Unauthorized use,
including screenshots,
copying, misuse, reuse, or
resale of any content from
this app, is strictly prohibited.
Our app monitors and records
all screenshots and
recordings. Violators will face
strict legal action.

DISCLAIMER

THIS IS COPYRIGHTED CONTENT. Unauthorized use, including screenshots, copying, misuse, reuse, or resale of any content from this app, is strictly prohibited. Our app monitors and records all screenshots and recordings. Violators will face strict legal action.

DISCLAIMER
THIS IS COPYRIGHTED CONTENT. Unauthorized use, including screenshots, copying, misuse, reuse, or resale of any content from this app, is strictly prohibited. Our app monitors and records all screenshots and recordings. Violators will face strict legal action.

PEDO+ORTHO

P.O.W.E.R NOTES SBQ 13

- I.
 - Sports drinks are needed for hydration, for energy, as nutrition and as electrolytes. So, (C) and (D) are ruled out.
 - It is found that the pH is lower before putting the mouth guard and trap the electrolytes underneath the mouth guard and leads to more damage.
 - When you drink over the mouth guard the tooth surface gets protected and the pH is not reduced. So, it good to drink the energy drinks after wearing the mouth guard.

II. It increases their dental caries risk and erosion risk. Sports drinks have sugar so, the caries risk comes first.

III. Caramel muesli bar is cariogenic because it contains sugar and it is sticky. Yogurt based smoothies have added sugars. Orange wedges are acidic fruits. Apple is a fibrous fruit and has a natural detergent effect on teeth as well. Dark chocolate has less sugar but not as low as apples.

Cariogenic foods include: sweet pastries, chips, cookies, crackers, white bread, sweetened cereals, cakes, confectionary, sweetened muesli bars, dried fruits, ice cream, flavoured milk, sweet yoghurt, beer and any sugary beverages

Low cariogenic foods include: white bread with chocolate and sweet spreads and whole grains, whole wheat bread, tortillas, wholemeal pasta, cooked starchy vegetables (such as corn, potatoes, yams, peas, carrots, beans), acidic fruits (such as mango and berries), soup and meat or cheese sandwiches.

Cario-static foods include: red meat, pork, fish, chicken, eggs, raw high-fibre vegetables (such as celery, broccoli, lettuce, spinach, cucumber and kale), nuts, popcorn and non-acidic artificial sweeteners.

The top anti-cariogenic foods/drinks of this type are plain milk and cheese (such as Swiss and aged Cheddar). Chewing non-citric Xylitol gum

DISCLAIMER

THIS IS COPYRIGHTED CONTENT. Unauthorized use, including screenshots, copying, misuse, reuse, or resale of any content from this app, is strictly prohibited. Our app monitors and records all screenshots and recordings. Violators will face strict legal action.

DISCLAIMER

THIS IS COPYRIGHTED CONTENT. Unauthorized use, including screenshots, copying, misuse, reuse, or resale of any content from this app, is strictly prohibited. Our app monitors and records all screenshots and recordings. Violators will face strict legal action.

THIS IS COPYRIGHTED CONTENT. Unauthorized use, including screenshots, copying, misuse, reuse, or resale of any content from this app, is strictly prohibited. Our app monitors and records all screenshots and recordings. Violators will face strict legal action.

DISCLAIMER

PEDO+ORTHO

SBQ 14

A 4 YEAR OLD CHILD ARRIVES IN MELBOURNE, ANXIOUS BUT COOPERATIVE, HIDING BEHIND HIS MOM, HISTORY OF ASTHMA, OCCASIONAL USE OF SHORT ACTING INHALER, USING DAILY CORTICOSTEROIDS FOR ECZEMA, MOM IS WORRIED ABOUT HIS DIET, LIVING IN A NOT FLUORIDATED WATER AREA, ALLERGY TO NUTS, SESAME AND MILK AND ADHESIVE BANDAGES.

I. Which one is most/least cariogenic? (in my centre it was asked most cariogenic)

- A. Caramel bar something twice a day
- B. Orange juice 4 times a day (fruit juice)
- C. Rice milk 4 times a day
- D. Fresh fruit 2 times
- E. Plain popcorn twice a day

II. Mother asks for happy gas, son 4-year-old with underweight and caries. Every time you ask the boy if he's in pain he hides behind his mum's leg, very apprehensive. Mother discloses she is under anxiety and depression, psychological treatment. What questions would you ask to consider her requests, or what should be considered before giving nitrous oxide to the child?

- A. Any recent severe asthma episodes, as nitrous oxide can exacerbate asthma
- B. Eczema as nitrous oxide can worsen the condition
- C. Putting mask on the child(child willing to wear the mask)
- D. The child is in 15th percentile of weight

III. What is the preventive treatment for this patient?

- A. CPP-ACP
- B. 1400 ppm adult strength toothpaste
- C. 500 ppm child strength toothpaste
- D. 1000 ppm child tooth paste

IV. What would you not recommend for this child (kid allergic to adhesive in rubber band aids)

- A. Avoid Fluoride gel
- B. Avoid fluoride varnish
- C. Avoid CPP-ACP
- D. Avoid Fluoride mouthwash
- E. Avoid High Flouride toothpaste

DISCLAIMER

THIS IS COPYRIGHTED CONTENT. Unauthorized use, including screenshots, copying, misuse, reuse, or resale of any content from this app, is strictly prohibited. Our app monitors and records all screenshots and recordings. Violators will face strict legal action.

DISCLAIMER
THIS IS COPYRIGHTED CONTENT. Unauthorized use, including screenshots, copying, misuse, reuse, or resale of any content from this app, is strictly prohibited. Our app monitors and records all screenshots and recordings. Violators will face strict legal action.

THIS IS COPYRIGHTED CONTENT. Unauthorized use, including screenshots, copying, misuse, reuse, or resale of any content from this app, is strictly prohibited. Our app monitors and records all screenshots and recordings. Violators will face strict legal action.

DISCLAIMER

PEDO+ORTHO

P.O.W.E.R NOTES SBQ 14

- I. Caramel muesli bar is the most cariogenic because it contains sugar and it is sticky. Rice milk still has carbohydrate/sugars. Juices contain sugar. Fresh fruits still have sugars. Plain popcorn is neutral. So, least cariogenic is plain popcorn.
- II. N2O helps in relieving asthma

ABSOLUTE CONTRAINDICATION FOR N2O:

- COPD
- Psychiatric pt
- Not able to wear the mask
- Bleomycin medication used in cancer
- Air cavities in the body
- Previous hx of middle ear surgery
- Pneumothorax
- Bowel obstruction
- Presence of alveolar bullae
- Malnourished pt
- Altered B12 metabolism

RELATIVE CONTRAINDICATION FOR N2O

- Claustrophobia
- Nasal obstruction
- Uncooperative behaviour
- If you are using electro surgery or laser surgery

- III. Child is at a high caries risk. In high caries risk age 18months to 6yrs, 500ppm tooth paste more frequently or 1000ppm tooth paste twice daily is recommended.
- IV. Patient is allergic to adhesives in rubber band aids. so, fluoride varnish should be avoided.

THIS IS COPYRIGHTED CONTENT. Unauthorized use, including screenshots, copying, misuse, reuse, or resale of any content from this app, is strictly prohibited. Our app monitors and records all screenshots and recordings. Violators will face strict legal action.

DISCLAIMER

THIS IS COPYRIGHTED CONTENT. Unauthorized use, including screenshots, copying, misuse, reuse, or resale of any content from this app, is strictly prohibited. Our app monitors and records all screenshots and recordings. Violators will face strict legal action.

THIS IS COPYRIGHTED CONTENT. Unauthorized use, including screenshots, copying, misuse, reuse, or resale of any content from this app, is strictly prohibited. Our app monitors and records all screenshots and recordings. Violators will face strict legal action.

DISCLAIMER
THIS IS COPYRIGHTED CONTENT. Unauthorized use, including screenshots, copying, misuse, reuse, or resale of any content from this app, is strictly prohibited. Our app monitors and records all screenshots and recordings. Violators will face strict legal action.

PEDO+ORTHO

SBQ 15

A 9-YEAR-OLD HAD UNDERGONE TRAUMA AFTER A BASKETBALL GAME. COMPLICATED CROWN # ON 11 PIN POINT EXPOSURE HORIZONTAL ROOT # ON 21 - XRAY GIVEN! AND PICTURE GIVEN

I. What would be the treatment?

- A. Partial pulpotomy on 11 and flexible splint on 21 for 4 weeks
- B. Dpc on 11, flexible splint on 21 for 2 weeks
- C. Pulpectomy on 11 and splinting on 21 for 2 weeks

II. Which has the poorest prognosis in root fracture?

- A. Cervical
- B. Middle
- C. Apical

P.O.W.E.R NOTES SBQ 15

I. In case of pinpoint exposure or in complicated crown # in immature permanent teeth- pulp capping or partial pulpotomy is indicated.

Horizontal root #- flexible splint for 4weeks.

DPC in 11 is ideal but splint for 2weeks is incorrect. So, option (B) is ruled out. And option (A) is correct.

II. Apical root # has the best prognosis and cervical root # has the worst prognosis.

THIS IS COPYRIGHTED CONTENT. Unauthorized use, including screenshots, copying, misuse, reuse, or resale of any content from this app, is strictly prohibited. Our app monitors and records all screenshots and recordings. Violators will face strict legal action.

DISCLAIMER

THIS IS COPYRIGHTED CONTENT. Unauthorized use, including screenshots, copying, misuse, reuse, or resale of any content from this app, is strictly prohibited. Our app monitors and records all screenshots and recordings. Violators will face strict legal action.

DISCLAIMER
THIS IS COPYRIGHTED CONTENT. Unauthorized use, including screenshots, copying, misuse, reuse, or resale of any content from this app, is strictly prohibited. Our app monitors and records all screenshots and recordings. Violators will face strict legal action.

DISCLAIMER
THIS IS COPYRIGHTED CONTENT. Unauthorized use, including screenshots, copying, misuse, reuse, or resale of any content from this app, is strictly prohibited. Our app monitors and records all screenshots and recordings. Violators will face strict legal action.

PEDO+ORTHO

SBQ 16

A LADY BROUGHT HER 4 YR OLD CHILD FOR CARIES TREATMENT WITH PAIN FOR TWO DAYS. HE IS BEHIND HIS AGE GROUP CHILDREN IN DEVELOPMENT U ASK HIM WHAT'S HIS PROBLEM AND HE MOVED HIS HEAD TO DENY ANY PROBLEM . LESS WEIGHT , IN 20 TH PERCENTILE OF WEIGHT AS PER AGE MOTHER HAS A FAMILY HISTORY OF DEPRESSION AND ANXIETY .

I. Child shows Frankel 3 behaviour, nothing to refuse about. Which condition will make it difficult to handle him?

- A. His mental development
- B. Age
- C. Underweight
- D. His mother's psychological situation

II. 85 is carious n painng continuously for 2 days,waking him up at night, what it is?

- A. Reversible pulpitis
- B. Irreversible pulpitis
- C. Hypersensitivity
- D. Degeneration

III. How will you treat him?

- A. Dpc
- B. Ipc
- C. Pulpotomy
- D. Pulpectomy

IV. How will you restore him after treatment?

- A. RMGIC
- B. Composite resin
- C. POLYACID modified resin
- D. Ssc

V. What is the first thing u do while treating this boy

- A. Tell show do
- B. Voice control
- C. All other options were behavior management (option was - Protective stabilization)
- D. Home
- E. Ask tell do

DISCLAIMER

THIS IS COPYRIGHTED CONTENT. Unauthorized use, including screenshots, copying, misuse, reuse, or resale of any content from this app, is strictly prohibited. Our app monitors and records all screenshots and recordings. Violators will face strict legal action.

DISCLAIMER

THIS IS COPYRIGHTED CONTENT. Unauthorized use, including screenshots, copying, misuse, reuse, or resale of any content from this app, is strictly prohibited. Our app monitors and records all screenshots and recordings. Violators will face strict legal action.

THIS IS COPYRIGHTED CONTENT. Unauthorized use, including screenshots, copying, misuse, reuse, or resale of any content from this app, is strictly prohibited. Our app monitors and records all screenshots and recordings. Violators will face strict legal action.

DISCLAIMER

PEDO+ORTHO

P.O.W.E.R NOTES SBQ 16

I.

Table 1. Frankl Scale		
Rating 1	Definitely negative	Refusal of treatment; crying forcefully, fearful, or any other evidence of extreme negativism
Rating 2	Negative	Reluctance to accept treatment; uncooperative; some evidence of negative attitude but not pronounced, i.e., sudden withdrawal
Rating 3	Positive	Acceptance of treatment; at time of cautious; willingness to comply with the dentist, at time with reservation, but patient follows the dentist's directions cooperatively
Rating 4	Definitely positive	Good rapport with dentist; interested in the dental procedures; laughing and enjoying the situation
Survey Instrument		

He's mentally behind his age group. Frankel 3 is positive behaviour.

- II. Continuous, spontaneous pain is associated with irreversible pulpitis.
- III. Irreversible pulpitis is treated with pulpectomy in primary teeth.
- IV. Multiple surfaces are involved with dental caries. SS crown is the best in this situation to give strength to the grossly destructed teeth.
- V. Frankel 3 is not much involved with negative behaviour. So, voice control is not needed. Hand over mouth technique is not used now. No protective stabilizers/no constraints are used. So, tell-show-do is the best.

THIS IS COPYRIGHTED CONTENT. Unauthorized use, including screenshots, copying, misuse, reuse, or resale of any content from this app, is strictly prohibited. Our app monitors and records all screenshots and recordings. Violators will face strict legal action.

DISCLAIMER

THIS IS COPYRIGHTED CONTENT. Unauthorized use, including screenshots, copying, misuse, reuse, or resale of any content from this app, is strictly prohibited. Our app monitors and records all screenshots and recordings. Violators will face strict legal action.

DISCLAIMER
THIS IS COPYRIGHTED CONTENT. Unauthorized use, including screenshots, copying, misuse, reuse, or resale of any content from this app, is strictly prohibited. Our app monitors and records all screenshots and recordings. Violators will face strict legal action.

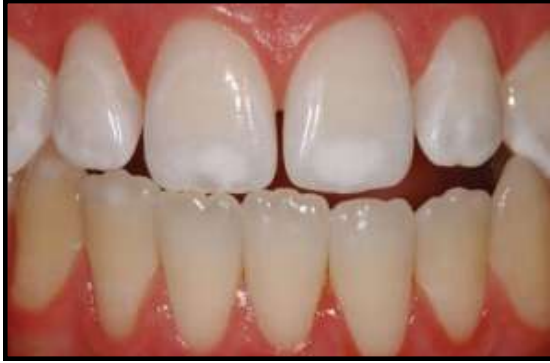THIS IS COPYRIGHTED CONTENT. Unauthorized use, including screenshots, copying, misuse, reuse, or resale of any content from this app, is strictly prohibited. Our app monitors and records all screenshots and recordings. Violators will face strict legal action.

DISCLAIMER

PEDO+ORTHO

SBQ 17

A GIRL 16 YRS OLD CM LIVING IN A NON-FLUORIDATION AREA, HAD ORTHO T/T IN THE PAST. PIC GIVEN YELLOW N WHITE LESIONS. NOT ABLE TO MAINTAIN GOOD ORAL HYGIENE DURING ORTHO T/T.



resale of any content from this app, is strictly prohibited.

I. How will u t/t her most conservatively

- A. Microabrasion w/ 18% hcl n later pumice n something (resin infiltration)
- B. Intra oral sandblasting followed with unfilled resin infiltration and resin composite
- C. Daily home bleaching 10% + cpp acp (it was carbamide 10% + cpp acp)
- D. Composite restoration removing defective enamel first
- E. Covering complete buccal surface with resin composite

II. Action of saliva to help reduce the risk of caries:

- A. Neutralize the acid of the food
- B. Remineralisation of enamel
- C. Attacks bacteria acids
- D. Lubricates mucosa and tongue
- E. Enamel more resistant to acid dissolution

III. You don't think it might be incipient caries. What May be the reason to exclude the caries

- A. Carious lesion in ortho treatment looked like white lesion
- B. She has no pain or sensitivity
- C. The white spot is beneath the location where Ortho brackets were placed

THIS IS COPYRIGHTED CONTENT. Unauthorized use, including screenshots, copying, misuse, reuse, or resale of any content from this app, is strictly prohibited. Our app monitors and records all screenshots and recordings. Violators will face strict legal action.

DISCLAIMER

THIS IS COPYRIGHTED CONTENT. Unauthorized use, including screenshots, copying, misuse, reuse, or resale of any content from this app, is strictly prohibited. Our app monitors and records all screenshots and recordings. Violators will face strict legal action.

THIS IS COPYRIGHTED CONTENT. Unauthorized use, including screenshots, copying, misuse, reuse, or resale of any content from this app, is strictly prohibited. Our app monitors and records all screenshots and recordings. Violators will face strict legal action.

DISCLAIMER
THIS IS COPYRIGHTED CONTENT. Unauthorized use, including screenshots, copying, misuse, reuse, or resale of any content from this app, is strictly prohibited. Our app monitors and records all screenshots and recordings. Violators will face strict legal action.

PEDO+ORTHO

P.O.W.E.R NOTES SBQ 17

- I. Yellowish discolouration can be treated with bleaching technique. White colour spots are orthodontics demineralisation spots and can be treated with CPP-ACP. It's the most conservative method. Sand blasting, micro abrasion and composite restorations are not required.
- II. Saliva helps in remineralization by releasing Ca and other ions. It neutralizes the acid in food will not help in reducing caries. But by neutralizing the acid in the plaque will help in reducing caries. So, option (A) is ruled out.

SALIVA HAS GOT 2 MAIN FUNCTIONS:

1. Neutralise/buffer the acid in the plaque and remineralise the enamel by giving saturating Ca ions. And caries prevention.
2. Increased pH gives Ca^{2+} , phosphate ions. This leads to calculi formation and remineralisation.

It has got antibacterial properties as saliva has got enzymes.

- III. Incipient caries and orthodontic spots appear very similar but can be differentiate with the given history and the location. Incipient caries are usually located at the gingival margin and the orthodontic demineralising spots are located where the brackets used to be.

DISCLAIMER

THIS IS COPYRIGHTED CONTENT. Unauthorized use, including screenshots, copying, misuse, reuse, or resale of any content from this app, is strictly prohibited. Our app monitors and records all screenshots and recordings. Violators will face strict legal action.

THIS IS COPYRIGHTED CONTENT. Unauthorized use, including screenshots, copying, misuse, reuse, or resale of any content from this app, is strictly prohibited. Our app monitors and records all screenshots and recordings. Violators will face strict legal action.

DISCLAIMER

THIS IS COPYRIGHTED CONTENT. Unauthorized use, including screenshots, copying, misuse, reuse, or resale of any content from this app, is strictly prohibited. Our app monitors and records all screenshots and recordings. Violators will face strict legal action.

THIS IS COPYRIGHTED CONTENT. Unauthorized use, including screenshots, copying, misuse, reuse, or resale of any content from this app, is strictly prohibited. Our app monitors and records all screenshots and recordings. Violators will face strict legal action.

DISCLAIMER
THIS IS COPYRIGHTED CONTENT. Unauthorized use, including screenshots, copying, misuse, reuse, or resale of any content from this app, is strictly prohibited. Our app monitors and records all screenshots and recordings. Violators will face strict legal action.

PEDO+ORTHO

SBQ 18

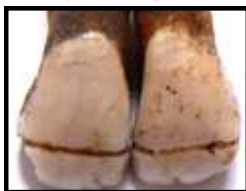BOY WITH RHEUMATIC HEART DISEASES, STAIN IN HIS ANTERIOR UPPER TEETH, BROWN HORIZONTAL LINE CERVICAL THIRD ON 22,21,11,12, SOME ARRESTED CARIES, SOME ACTIVE CARIES ON ANTERIORS. WHAT COULD BE THE REASON(WHITE BROWNISH STAIN) RHEUMATIC FEVER, ABP HE WAS STAYING IN A NON FLUORIDATED AREA HE IS NOW 12 YEARS HE CAME TO LIVE WITH HIS AUNT RECENTLY WHO IS ON PENICILLIN MONTHLY FOR RHEUMATIC FEVER CARIES ON 11,21,12,22.

I. Reason for his black stain?

- A. Arrested caries
- B. Incipient
- C. Rampant and active caries
- D. Arrested and rampant caries
- E. Beginning of arresting of caries (picture had partial brown and white appearance)

II. Possible reason for the horizontal line on the gingival third 12,11,21,22 (There was a horizontal line in cervical third)?

- A. Tetracycline
- B. Lots of sugary drink consumption
- C. Trauma in this early life
- D. Disturbances of enamel development at 1 year old
- E. During the development of permanent teeth defect in amelogenesis
- F. Fluorosis



III. You also think this might be fluorosis. What makes you think that this child might have fluorosis

- A. Ingestion of adult fluoride toothpaste
- B. Fluoride tablet supplementation as a child
- C. Fluoride mouthrinse

IV. You decide to do fillings on 11,12,21,22 (it specified using of cotton rolls).

What is correct about ABP he was 40 kgs

- A. No abp needed
- B. Amox 2 g orally 60 mins before
- C. 50 mg/kg body weight of Amox 60 mins before
- D. Ampicillin 2g iv 60 mins
- E. Ampicillin 2g Im 30 mins

DISCLAIMER

THIS IS COPYRIGHTED CONTENT. Unauthorized use, including screenshots, copying, misuse, reuse, or resale of any content from this app, is strictly prohibited. Our app monitors and records all screenshots and recordings. Violators will face strict legal action.

DISCLAIMER
THIS IS COPYRIGHTED CONTENT. Unauthorized use, including screenshots, copying, misuse, reuse, or resale of any content from this app, is strictly prohibited. Our app monitors and records all screenshots and recordings. Violators will face strict legal action.

THIS IS COPYRIGHTED CONTENT. Unauthorized use, including screenshots, copying, misuse, reuse, or resale of any content from this app, is strictly prohibited. Our app monitors and records all screenshots and recordings. Violators will face strict legal action.

DISCLAIMER

PEDO+ORTHO

P.O.W.E.R NOTES SBQ 18

- I. Rampant and active caries are yellowish in colour. Incipient caries appears white in colour. Arrested caries is black in colour.
- II. Caries can't be a straight line. There's depression along with the line. So, it's hypoplasia. If there's no depression, then it could be hypo mineralisation. Tetracycline stains give a shadow like staining on the teeth. And there should be a history of tetracycline use. Trauma in the childhood will give a localised hypoplastic spot. This incisal area develops at the age of 1yr. and that incisal area is involved in this case. Fluorosis will appear as flecks rather than demarcation seen here. So (D) is the best answer among the given.
- III. Other than the hypo mineralisation due to the developmental disturbance's fluorosis can give brown/white spots. Patient lived in a non-fluoridated area when he was very young. So, he must not have been taken mouth rinses. Fluoride tablet supplementation has banded in Australia since many years now so fluoride tablet consumption incidence is also rare. So possible scenario becomes that child most likely used adult strength flouridated toothpaste and possible ingestion. So (A) is the best answer among the given.
- IV. His medical condition may require AB prophylaxis. But for restorations AB prophylaxis is not required. If it's an extraction AB prophylaxis is needed.

THIS IS COPYRIGHTED CONTENT. Unauthorized use, including screenshots, copying, misuse, reuse, or resale of any content from this app, is strictly prohibited. Our app monitors and records all screenshots and recordings. Violators will face strict legal action.

DISCLAIMER

THIS IS COPYRIGHTED CONTENT. Unauthorized use, including screenshots, copying, misuse, reuse, or resale of any content from this app, is strictly prohibited. Our app monitors and records all screenshots and recordings. Violators will face strict legal action.

THIS IS COPYRIGHTED CONTENT. Unauthorized use, including screenshots, copying, misuse, reuse, or resale of any content from this app, is strictly prohibited. Our app monitors and records all screenshots and recordings. Violators will face strict legal action.

DISCLAIMER
THIS IS COPYRIGHTED CONTENT. Unauthorized use, including screenshots, copying, misuse, reuse, or resale of any content from this app, is strictly prohibited. Our app monitors and records all screenshots and recordings. Violators will face strict legal action.

DISCLAIMER

THIS IS COPYRIGHTED CONTENT. Unauthorized use, including screenshots, copying, misuse, reuse, or resale of any content from this app, is strictly prohibited. Our app monitors and records all screenshots and recordings. Violators will face strict legal action.

PEDO+ORTHO

SBQ 19

PATIENT HAS UNDERGONE ORTHO TREATMENT AS WELL SHE'S 16 YEARS OLD, SHE IS HAPPY WITH ORTHO ALIGNMENT BUT NOT HAPPY WITH THE STAINS, HYPOPLASTIC SPOTS, AS A BABY SHE SUFFERED A CHRONIC EAR INFECTION AND AT 11 YEARS OF AGE SHE SUFFERED CHICKEN POX

I. What is your differential diagnosis

- A. Enamel Hypomineralisation
- B. Enamel hypomineralization
- C. Incipient caries
- D. Tetracycline stains
- E. Chronological hypoplasia

II. You come for a provisional diagnosis of molar incisor Hypoplasia What makes you think that the reason for MIH is?

- A. Her history of chronic ear infection as a baby
- B. Her chickenpox history
- C. Nutritional disturbance during childhood.

III. What treatment would you do she is concerned about her aesthetics

- A. Composite restoration on labial defects
- B. Resin Composite on whole labial surface
- C. Porcelain veneers
- D. All ceramic crowns
- E. RMGIC

THIS IS COPYRIGHTED
CONTENT. Unauthorized use,
including screenshots,
copying, misuse, reuse, or
resale of any content from
this app, is strictly prohibited.
Our app monitors and records
all screenshots and
recordings. Violators will face
strict legal action.

DISCLAIMER

THIS IS COPYRIGHTED CONTENT. Unauthorized use, including screenshots, copying, misuse, reuse, or resale of any content from this app, is strictly prohibited. Our app monitors and records all screenshots and recordings. Violators will face strict legal action.

THIS IS COPYRIGHTED
CONTENT. Unauthorized use,
including screenshots,
copying, misuse, reuse, or
resale of any content from
this app, is strictly prohibited.
Our app monitors and records
all screenshots and
recordings. Violators will face
strict legal action.

THIS IS COPYRIGHTED
CONTENT. Unauthorized use,
including screenshots,
copying, misuse, reuse, or
resale of any content from
this app, is strictly prohibited.
Our app monitors and records
all screenshots and
recordings. Violators will face
strict legal action.

WINSPERT
P.O.W.E.R
NOTES

DISCLAIMER

THIS IS COPYRIGHTED CONTENT. Unauthorized use, including screenshots, copying, misuse, reuse, or resale of any content from this app, is strictly prohibited. Our app monitors and records all screenshots and recordings. Violators will face strict legal action.

DISCLAIMER

THIS IS COPYRIGHTED CONTENT. Unauthorized use, including screenshots, copying, misuse, reuse, or resale of any content from this app, is strictly prohibited. Our app monitors and records all screenshots and recordings. Violators will face strict legal action.

PEDO+ORTHO

P.O.W.E.R NOTES SBQ 19

- I. Orthodontic Rx can give orthodontic demineralisation spots which are white in colour, they are not hypoplastic spots. There will be depressions and enamel protein matrix disturbances in hypoplastic spots, and it will take place during enamel formation. It's a formative and developmental defect. It happens only in certain teeth and not in all teeth. So, the differential diagnosis is chronological hypoplasia.
- II. At the 11yrs of age anterior teeth are already formed. So, chicken pox is not associated with teeth formation. But the patient suffered with an ear infection when she was a baby, front teeth will be developing at that age. So, chronic ear infection is linked with the hypoplastic defects. So, the differential diagnosis is chronological hypoplasia.
- III. Patient is concerned about the aesthetics. She's still 16yrs old. So, porcelain veneers and ceramic crowns are ruled out.

TABLE 56.2 Possible Restorative Options for the Incisors

Technique	Advantages	Disadvantages
Full resin composite veneers	No destruction of tooth tissue, reversible and generally well tolerated even by anxious children. Excellent aesthetic result possible and easy to maintain.	Discolour with time. Tendency to fracture if placed at/over the incisal edge.
Enamel microabrasion	Minimal destruction of enamel, if carefully performed. Technique well tolerated.	Unpredictable. Teeth may rarely suffer postoperative sensitivity. Accidental exposure of dentine is possible where enamel is thin.
Localized resin composite restoration	Enamel destruction limited to defect, and full thickness need not be removed if opaque resin composite shades are used. Good aesthetic result possible.	Irreversible. Weakens tooth structure and large areas of dentine may be uncovered. Colour change and marginal discoloration with time.
Porcelain veneers	Good appearance.	Contraindicated in this age group because gingival contour not mature and stable tooth position not yet established.
Full-crown restoration	Good appearance.	Inappropriate until late second decade because immature pulp horns may be exposed. Gingival contour not mature and stable tooth position not yet established.

FULL RESIN COMPOSITE VENEERS:

- No destruction of the tooth tissue
- Excellent aesthetic results

RESIN COMPOSITE RESTORATIONS:

- Enamel destruction limited to defect
- Good aesthetic results

Therefore, composite veneers are better than composite restorations.

DISCLAIMER

THIS IS COPYRIGHTED CONTENT. Unauthorized use, including screenshots, copying, misuse, reuse, or resale of any content from this app, is strictly prohibited. Our app monitors and records all screenshots and recordings. Violators will face strict legal action.

PEDO+ORTHO

SBQ 20

TRAUMA CASE , LOOKED LIKE A ROOT FRACTURE
IOPA WAS GIVEN, IF U ARE NOT HAPPY WITH THE GIVEN IOPA

I. What is the best radiograph to give the diagnosis

- A. CBCT
- B. Two IOPA in a dif angle
- C. Opg
- D. Occlusal

II. Who is the best to treat this case

- A. Endodontist
- B. Orthodontist
- C. Periodontist
- D. Oral surgeon

III. Question about malocclusion (83 lost and midline shift)

Opg and pictures given. Which class of malocclusion this is

- A. Class 1 with lower midline shift
- B. Class 2 div 1 with lower midline shift
- C. Class 2 div 2 with lower midline shift
- D. Class 3 with lower midline shift

IV. What would be the best treatment that could have be done to avoid the midline shift

- A. Elective Extraction of 73
- B. Band and loop appliance
- C. Lingual arch involving all anterior teeth

THIS IS COPYRIGHTED
 CONTENT. Unauthorized use,
 including screenshots,
 copying, misuse, reuse, or
 resale of any content from
 this app, is strictly prohibited.
 Our app monitors and records
 all screenshots and
 recordings. Violators will face
 strict legal action.

DISCLAIMER
 THIS IS COPYRIGHTED CONTENT. Unauthorized use, including screenshots, copying, misuse, reuse, or resale of any content from this app, is strictly prohibited. Our app monitors and records all screenshots and recordings. Violators will face strict legal action.

THIS IS COPYRIGHTED
 CONTENT. Unauthorized use,
 including screenshots,
 copying, misuse, reuse, or
 resale of any content from
 this app, is strictly prohibited.
 Our app monitors and records
 all screenshots and
 recordings. Violators will face
 strict legal action.

DISCLAIMER

THIS IS COPYRIGHTED CONTENT. Unauthorized use, including screenshots, copying, misuse, reuse, or resale of any content from this app, is strictly prohibited. Our app monitors and records all screenshots and recordings. Violators will face strict legal action.

PEDO+ORTHO

P.O.W.E.R NOTES SBQ 20

I. RECOMMENDED RADIOGRAPHS IN "ROOT FRACTURE"

- One parallel periapical radiograph
- Two additional radiographs of the tooth taken with different / horizontal angulation
- Occlusal radiograph
- Root # may be undetected without additional images

In case where the above radiographs provide insufficient information for the treatment planning CBCT can be considered to determine the location, extent and direction of the #.

II. Endodontist will be the best to treat in the presence of a root #. The coronal portion of the root need treatment.

III. Pictures are required to answer this question.

IV. When there's primary canine is missing in one side it leads midline shift. To avoid this balancing extraction should be done.

DISCLAIMER

THIS IS COPYRIGHTED CONTENT. Unauthorized use, including screenshots, copying, misuse, reuse, or resale of any content from this app, is strictly prohibited. Our app monitors and records all screenshots and recordings. Violators will face strict legal action.

DISCLAIMER
THIS IS COPYRIGHTED CONTENT. Unauthorized use, including screenshots, copying, misuse, reuse, or resale of any content from this app, is strictly prohibited. Our app monitors and records all screenshots and recordings. Violators will face strict legal action.

DISCLAIMER

THIS IS COPYRIGHTED CONTENT. Unauthorized use, including screenshots, copying, misuse, reuse, or resale of any content from this app, is strictly prohibited. Our app monitors and records all screenshots and recordings. Violators will face strict legal action.

PEDO+ORTHO

SBQ 21

BOY 4 YO, MOTHER CAME BECAUSE SHE DOESN'T LIKE THE LOOK OF HIS UPPER FRONT TEETH 52 AND 62 THIRD CERVICAL WITH ACTIVE CARIOUS. HE HAS ASTHMA AND ECZEMA AND IS HAVING DRUGS FOR BOTH. LIVES IN UN FLUORIDATED AREA MOTHER SAID SHE BRUSHES HIM MANUALLY WITH A MANUAL TOOTHBRUSH AND TOOTHPASTE WITH NO FLUORIDE. HAS ASTHMA.

I. What recommendation you give?

- A. Use electric tb with her normal toothpaste
- B. 500 ppm children's toothpaste twice daily
- C. 1000 ppm children's toothpaste twice daily
- D. 1500 ppm adult toothpaste twice daily
- E. 5000 ppm adult toothpaste twice daily

P.O.W.E.R NOTES SBQ 21

- I. Patient lives in a un fluoridated area. Brushes with a toothpaste with no fluoride. Patient is a high caries risk. 500ppm will not work for high caries risk patient. Patient is 4yrs. So, adult toothpaste is not recommended. So, child toothpaste with a high fluoride concentration can be prescribed.

THIS IS COPYRIGHTED CONTENT. Unauthorized use, including screenshots, copying, misuse, reuse, or resale of any content from this app, is strictly prohibited. Our app monitors and records all screenshots and recordings. Violators will face strict legal action.

DISCLAIMER

THIS IS COPYRIGHTED CONTENT. Unauthorized use, including screenshots, copying, misuse, reuse, or resale of any content from this app, is strictly prohibited. Our app monitors and records all screenshots and recordings. Violators will face strict legal action.

THIS IS COPYRIGHTED CONTENT. Unauthorized use, including screenshots, copying, misuse, reuse, or resale of any content from this app, is strictly prohibited. Our app monitors and records all screenshots and recordings. Violators will face strict legal action.

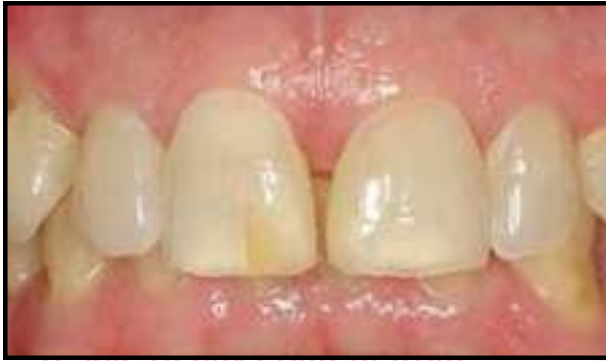THIS IS COPYRIGHTED CONTENT. Unauthorized use, including screenshots, copying, misuse, reuse, or resale of any content from this app, is strictly prohibited. Our app monitors and records all screenshots and recordings. Violators will face strict legal action.

DISCLAIMER
THIS IS COPYRIGHTED CONTENT. Unauthorized use, including screenshots, copying, misuse, reuse, or resale of any content from this app, is strictly prohibited. Our app monitors and records all screenshots and recordings. Violators will face strict legal action.

PEDO+ORTHO

SBQ 22

CHILD 14 YO FROM A REMOTE COMMUNITY, JUST MOVED TO LIVE IN THE CITY. NO CARIES OR GINGIVAL INFLAMMATION. PICTURE OF THE ANTERIOR GIVEN, 12 TO 21 LOOKED FLAT AND SHARP FROM ANTERIOR. (BOTH CENTRALS HAD TRANSLUCENT INCISAL EDGE AND SHARP)



SAID THAT HE TAKES SALBUTAMOL INHALER (OCCASIONALLY) AND A STEROID PREVENTER FOR ASTHMA. HE COMPLAINS OF FEELING THAT HER UPPER FRONT TEETH ARE SHARP. CAN SEE MILD EROSION OF THE LABIAL OF INCISORS. PLAYS SOCCER AND CYCLES. VEGETARIAN. ON EXAMINATION, MINIMAL/NO PLAQUE, NO INFLAMMATION, NO CARIES. HE PLAYS SPORTS AND CYCLING. MENTIONED THAT HE DOESN'T DRINK MUCH WATER. HE FORGETS.

I. Based on the examination and social history, you suspect (provisional diagnosed) erosion What is the likely cause of erosion?

- A. Sports drinks
- B. Sweetened confectionary
- C. Vegetarianism
- D. Reflux
- E. Salbutamol

II. You discuss the cause of erosion with pt and advice management (here dentist made dx of erosion. Then how to manage)

- A. Talk to GP about changing the inhaler meds
- B. Limit sugar intake (no caries mentioned)
- C. Advice to add meat on his diet
- D. Advice pt to not brush after drinking sports drink. (mouthwash 1000 ppm after sports)
- E. See GP for suspect of acid reflux issue (no history and mentioned only front teeth)

DISCLAIMER

THIS IS COPYRIGHTED CONTENT. Unauthorized use, including screenshots, copying, misuse, reuse, or resale of any content from this app, is strictly prohibited. Our app monitors and records all screenshots and recordings. Violators will face strict legal action.

DISCLAIMER

THIS IS COPYRIGHTED CONTENT. Unauthorized use, including screenshots, copying, misuse, reuse, or resale of any content from this app, is strictly prohibited. Our app monitors and records all screenshots and recordings. Violators will face strict legal action.

THIS IS COPYRIGHTED CONTENT. Unauthorized use, including screenshots, copying, misuse, reuse, or resale of any content from this app, is strictly prohibited. Our app monitors and records all screenshots and recordings. Violators will face strict legal action.

DISCLAIMER

PEDO+ORTHO

P.O.W.E.R NOTES SBQ 22

- I. There's erosion on the buccal surface of the teeth. Sharpness and the translucency are due to the erosive wear. He uses salbutamol inhaler and steroid preventor for asthma. In the history it's not given that the patient drinks sports drinks. If it's given in the hx then sports drinks would be the predominant cause for erosion. When he's not drinking sports drinks or not even drinking water, the other acidic exposure that he's going through is salbutamol and asthma related drugs.

Asthmatic medication can place the patient at risk of dental erosion by reducing salivary protection against extrinsic or intrinsic acids. Asthmatic individuals are one of the higher risk groups suffering from dental erosion.

- II. When a sports person drinks sports drinks, we do not ask him to stop using sports drinks. Instead we ask them to alternate or rinse with water to wash it off/neutralise / buffer the acidic environment.

If the patient has a hx of taking sports drinks, then it will be our main concern. Sports drinks have sugar, so it has relatively high risk for both caries and erosion. This child doesn't have caries but has erosion. But sports drinks have a potential to cause both. Because it is not sticky, erosions more likely.

Since the patient uses salbutamol inhaler which causes erosion, always good talk with the GP regarding changing the medication. And advice the patient to use the spacer while using the inhaler.

THIS IS COPYRIGHTED CONTENT. Unauthorized use, including screenshots, copying, misuse, reuse, or resale of any content from this app, is strictly prohibited. Our app monitors and records all screenshots and recordings. Violators will face strict legal action.

DISCLAIMER

THIS IS COPYRIGHTED CONTENT. Unauthorized use, including screenshots, copying, misuse, reuse, or resale of any content from this app, is strictly prohibited. Our app monitors and records all screenshots and recordings. Violators will face strict legal action.

THIS IS COPYRIGHTED CONTENT. Unauthorized use, including screenshots,

copying, misuse, reuse, or resale of any content from this app, is strictly prohibited. Our app monitors and records all screenshots and recordings. Violators will face strict legal action.

THIS IS COPYRIGHTED CONTENT. Unauthorized use, including screenshots, copying, misuse, reuse, or resale of any content from this app, is strictly prohibited. Our app monitors and records all screenshots and recordings. Violators will face strict legal action.

DISCLAIMER
THIS IS COPYRIGHTED CONTENT. Unauthorized use, including screenshots, copying, misuse, reuse, or resale of any content from this app, is strictly prohibited. Our app monitors and records all screenshots and recordings. Violators will face strict legal action.

PEDO+ORTHO

SBQ 23

YOUNG BOY - DOESN'T BRUSH PROPERLY - DOESN'T FLOSS, HYGIENE SATISFACTORY - BEEN APPLYING F VARNISH FOR 6 YEARS NOW, EVERY 6 MONTHS - SPORTS PLAYER, BUT DOESN'T LIKE SPORTS DRINKS - EATS SUGAR IN EVERY MEAL, BUT IN BETWEEN MEAL SNACK IS CHEESE AND FRUIT. NOT MUCH CARIES, JUST ENAMEL DEMINERALIZATION IN ONE TOOTH (16)

I. You do caries risk assessment, what is important in his low caries risk?

- A. The fact that he is a regular Fluoride varnish attendee
- B. He doesn't snack in between on cariogenic foods
- C. He doesn't drink sports drink

II. The best way to improve his oral health?

- A. Decrease sugar DURING meals
- B. Fluoride application
- C. Sport drinks

P.O.W.E.R NOTES SBQ 23

I. Fibrous fruits are non-cariogenic. Acidic fruits are low cariogenic. Fruit is never a highly cariogenic.

Amongst the diet and fluoride application, fluoride application has a caries reducing property.

Amount of free sugars / frequency of free sugars has increased caries risk.

Fluoride exposure, hard cheese, sugar free chewing gum, xylitol, milk, dietary fibre, whole fresh fruit have decreased caries risk.

Eliminating sugar will reduce the caries risk. But when both sugar intake and fluoride are given, fluoride will prevent more than eliminating sugar.

II. He's not taking sports drinks. He's already taking fluoride treatment. So, the best way to improve his oral health is decrease sugar during meals.

THIS IS COPYRIGHTED CONTENT. Unauthorized use, including screenshots, copying, misuse, reuse, or resale of any content from this app, is strictly prohibited. Our app monitors and records all screenshots and recordings. Violators will face strict legal action.

DISCLAIMER

THIS IS COPYRIGHTED CONTENT. Unauthorized use, including screenshots, copying, misuse, reuse, or resale of any content from this app, is strictly prohibited. Our app monitors and records all screenshots and recordings. Violators will face strict legal action.

DISCLAIMER
THIS IS COPYRIGHTED CONTENT. Unauthorized use, including screenshots, copying, misuse, reuse, or resale of any content from this app, is strictly prohibited. Our app monitors and records all screenshots and recordings. Violators will face strict legal action.

THIS IS COPYRIGHTED CONTENT. Unauthorized use, including screenshots, copying, misuse, reuse, or resale of any content from this app, is strictly prohibited. Our app monitors and records all screenshots and recordings. Violators will face strict legal action.

DISCLAIMER

PEDO+ORTHO

SBQ 24

A GIRL - AGE 13 - COMES WITH MOM - WANTS TONGUE PIERCING - DOESN'T BRUSH PROPERLY - HAS SEEN HER SCHOOL ELDER FRIENDS GET PIERCINGS FROM TATTOO PLACES - SO SHE ALSO WANTS ONE - BUT AFRAID THEY ARE NOT CLEAN. MOM RECENTLY DIVORCED, AND MOM IS A BUSY LAWYER - DAUGHTER SAYS TO DENTIST "I KEEP WORRYING ABOUT A LOT OF THINGS RECENTLY"

I. What is the most important barrier that you will need to overcome to improve the child's oral health?

- A. Teenage behavior
- B. Lack of mothers support
- C. His oral hygiene practices

II. Mum is very apprehensive or unhappy about tongue piercing. A Lot of kids have got infections from tongue piercings. What will be your advice to the child?

- A. Refer to oral surgeon to manage complications
- B. Ask mother to check if the tattooist is using sterilized instruments
- C. Get piercing at older age (when adult)
- D. Discourage her in getting piercing

P.O.W.E.R NOTES SBQ 24

I. Teenagers are capable in doing oral hygiene practice alone. So, having a divorced mother is not a barrier to maintain her oral hygiene. Child doesn't brush properly and that's the barrier that you need to overcome. So, you need to educate and motivate the patient.

II. Reference:

Intra oral and peri oral piercing are invasive procedures that carry significant local and systemic health risks. Complications include infections, swelling bleeding nerve damage, chipped teeth, gum recession, alteration to speech and swallowing or inhalation of lost or damaged piercings.

Other irreversible body modifications of the oral cavity including of the natural dentition should not be performed and dental practitioners should discourage individuals from having body modification in their oral cavity.

So, according to the guidelines, discourage her in getting piercing.

DISCLAIMER

THIS IS COPYRIGHTED CONTENT. Unauthorized use, including screenshots, copying, misuse, reuse, or resale of any content from this app, is strictly prohibited. Our app monitors and records all screenshots and recordings. Violators will face strict legal action.

PEDO+ORTHO

SBQ 25

PATIENT 12 YEARS OLD, CAME WITH 75 AND 85 WITH VARIOUS LESIONS. NO PERMANENT SUCCESSORS PRESENT SO YOU WANT TO TRY TO PRESERVE THEM AS LONG AS POSSIBLE. UPON XRAY YOU SEE 75 HAS A SMALL RADIOLUCENCY IN THE FURCATION, WHAT'S THE BEST TREATMENT FOR THIS TOOTH?

- A. Pulpotomy
- B. Pulpectomy
- C. Extraction
- D. Ipc

P.O.W.E.R NOTES SBQ 25

- I. Once the furcation is involved in the primary teeth the best option is to extract them. But in the given hx it's mentioned that no permanent successors present so you want to preserve them as long as possible, in this case you may need to perform pulpectomy.

THIS IS COPYRIGHTED CONTENT. Unauthorized use, including screenshots, copying, misuse, reuse, or resale of any content from this app, is strictly prohibited. Our app monitors and records all screenshots and recordings. Violators will face strict legal action.

DISCLAIMER

THIS IS COPYRIGHTED CONTENT. Unauthorized use, including screenshots, copying, misuse, reuse, or resale of any content from this app, is strictly prohibited. Our app monitors and records all screenshots and recordings. Violators will face strict legal action.

THIS IS COPYRIGHTED CONTENT. Unauthorized use, including screenshots, copying, misuse, reuse, or resale of any content from this app, is strictly prohibited. Our app monitors and records all screenshots and recordings. Violators will face strict legal action.

THIS IS COPYRIGHTED CONTENT. Unauthorized use, including screenshots, copying, misuse, reuse, or resale of any content from this app, is strictly prohibited. Our app monitors and records all screenshots and recordings. Violators will face strict legal action.

THIS IS COPYRIGHTED CONTENT. Unauthorized use, including screenshots, copying, misuse, reuse, or resale of any content from this app, is strictly prohibited. Our app monitors and records all screenshots and recordings. Violators will face strict legal action.

DISCLAIMER
THIS IS COPYRIGHTED CONTENT. Unauthorized use, including screenshots, copying, misuse, reuse, or resale of any content from this app, is strictly prohibited. Our app monitors and records all screenshots and recordings. Violators will face strict legal action.

PEDO+ORTHO

SBQ 26

12-YEAR-OLD GIRL IS LEAVING ABROAD SOON, AND CAME FOR A GENERAL CHECK-UP. YOU DID TREATMENT WHEN SHE WAS YOUNG, PRIMARY TEETH THAT WERE ALL OKAY BUT SHE RETURNS AFTER A FEW YEARS, ANTERIORS ARE HYPOMINERALIZED. WHAT IS THE REASON FOR LESIONS (IMAGE SHOWING ANTERIORS - HORIZONTAL WHITE HYPOPLASTIC BANDS)

- A. Amelogenesis imperfecta
- B. Dentinogenesis imperfecta
- C. Dentin dysplasia
- D. Chronological hypoplasia

P.O.W.E.R NOTES SBQ 26

- I. In amelogenesis imperfecta, dentinogenesis imperfecta and dentine dysplasia both primary and permanent teeth are affected. In the history it is mentioned that the primary teeth are ok. So, (A), (B), (C) are ruled out. Chronological dysplasia can happen due to childhood disturbances and nutritional disturbances.

THIS IS COPYRIGHTED CONTENT. Unauthorized use, including screenshots, copying, misuse, reuse, or resale of any content from this app, is strictly prohibited. Our app monitors and records all screenshots and recordings. Violators will face strict legal action.

DISCLAIMER

THIS IS COPYRIGHTED CONTENT. Unauthorized use, including screenshots, copying, misuse, reuse, or resale of any content from this app, is strictly prohibited. Our app monitors and records all screenshots and recordings. Violators will face strict legal action.

THIS IS COPYRIGHTED CONTENT. Unauthorized use, including screenshots, copying, misuse, reuse, or resale of any content from this app, is strictly prohibited. Our app monitors and records all screenshots and recordings. Violators will face strict legal action.

DISCLAIMER
THIS IS COPYRIGHTED CONTENT. Unauthorized use, including screenshots, copying, misuse, reuse, or resale of any content from this app, is strictly prohibited. Our app monitors and records all screenshots and recordings. Violators will face strict legal action.

DISCLAIMER

THIS IS COPYRIGHTED CONTENT. Unauthorized use, including screenshots, copying, misuse, reuse, or resale of any content from this app, is strictly prohibited. Our app monitors and records all screenshots and recordings. Violators will face strict legal action.

PEDO+ORTHO

SBQ 27

PATIENT'S PARENTS WERE WORRIED ABOUT THE RADIATION FROM BITEWING.

I. How will you reassure them?

- A. By telling them it's just a small exposure
- B. By telling it will not radiate to any of his body parts
- C. Bitewing radiograph is essential otherwise we cannot continue the treatment
- D. Continue without x-ray
- E. Tell them study shows that it doesn't cause cancer

II. Safest material for internal bleaching?

- A. Sodium perborate
- B. Carbamide peroxide 10%
- C. Hydrogen peroxide 30%
- D. H₂O₂ 3%

P.O.W.E.R NOTES SBQ 27

- I. X-rays have the potential to cause cancer. X-ray causes cancer with exposure quantity. So, (E) is ruled out.

If the x-ray is needed for the diagnosis and treatment planning, we can't continue the procedures without x-ray. So, option (D) is ruled out.

It's not the professional management of patient's and parent's concern. So, option (C) is ruled out.

By telling them it will not radiate to any other body parts It will not prevent the secondary radiation. So, option (B) is ruled out.

- II. Hydrogen peroxide 30% is a chairside material. Carbamide peroxide 10% which release peroxide 3% is used for home bleaching. Sodium perborate is used for non-vital bleaching (walking bleaching).

THIS IS COPYRIGHTED CONTENT. Unauthorized use, including screenshots, copying, misuse, reuse, or resale of any content from this app, is strictly prohibited. Our app monitors and records all screenshots and recordings. Violators will face strict legal action.

DISCLAIMER

THIS IS COPYRIGHTED CONTENT. Unauthorized use, including screenshots, copying, misuse, reuse, or resale of any content from this app, is strictly prohibited. Our app monitors and records all screenshots and recordings. Violators will face strict legal action.

DISCLAIMER
THIS IS COPYRIGHTED CONTENT. Unauthorized use, including screenshots, copying, misuse, reuse, or resale of any content from this app, is strictly prohibited. Our app monitors and records all screenshots and recordings. Violators will face strict legal action.

THIS IS COPYRIGHTED CONTENT. Unauthorized use, including screenshots, copying, misuse, reuse, or resale of any content from this app, is strictly prohibited. Our app monitors and records all screenshots and recordings. Violators will face strict legal action.

DISCLAIMER

PEDO+ORTHO

SBQ 28

I. 12yrs old boy marginal ridge carries.no pain.

- A. Ssc and pulpotomy
- B. Gic
- C. Composite
- D. SDF
- E. No treatment

II. Don't remember the complete question. But it was about extracting 12 on a child patient and doing what for rehabilitation.

- A. Extract 12 and wait for 13 to erupt into its place
- B. Extract and give an immediate cast cobalt denture
- C. Extract and give implant in the empty space

P.O.W.E.R NOTES SBQ 28

- I.
 - Marginal ridge is the cumulation of proximal and occlusal surfaces. It's a complex area.
 - GIC is not used as a permanent restorative material in primary or in permanent teeth.
 - Pulpotomy/ SDF is not required in marginal ridge caries. SDF is used to arrest the caries but it causes severe discolouration.
 - You will not leave a carious tooth with cavity without any treatment.
- II. Ideal treatment is to extract 12 and give acrylic denture for the space maintenance. 13 will not erupt in the place of 12, therefore, orthodontic bodily movement is needed. Implants are not given at the age of 12yrs. And can be given after 18yrs.

THIS IS COPYRIGHTED CONTENT. Unauthorized use, including screenshots, copying, misuse, reuse, or resale of any content from this app, is strictly prohibited. Our app monitors and records all screenshots and recordings. Violators will face strict legal action.

DISCLAIMER

THIS IS COPYRIGHTED CONTENT. Unauthorized use, including screenshots, copying, misuse, reuse, or resale of any content from this app, is strictly prohibited. Our app monitors and records all screenshots and recordings. Violators will face strict legal action.

THIS IS COPYRIGHTED CONTENT. Unauthorized use, including screenshots, copying, misuse, reuse, or resale of any content from this app, is strictly prohibited. Our app monitors and records all screenshots and recordings. Violators will face strict legal action.

DISCLAIMER
THIS IS COPYRIGHTED CONTENT. Unauthorized use, including screenshots, copying, misuse, reuse, or resale of any content from this app, is strictly prohibited. Our app monitors and records all screenshots and recordings. Violators will face strict legal action.

THIS IS COPYRIGHTED CONTENT. Unauthorized use, including screenshots, copying, misuse, reuse, or resale of any content from this app, is strictly prohibited. Our app monitors and records all screenshots and recordings. Violators will face strict legal action.

PEDO+ORTHO

SBQ 29

I. Picture with brown-black cervical lesion and have brown line defect in cervical third. What is this lesion in the picture?

- A. Incipient caries
- B. Progressing arrested caries
- C. Abrasion
- D. Disturbance in amelogenesis in early age
- E. Fluorosis

II. Cervical lesions best long term material to fill on the front teeth, Photo the caries is very near the cervical areas, and class 4 caries.

- A. Compomer
- B. Gic
- C. Amalgam
- D. Polyacid resin modified composite
- E. Zinc polycarboxylate cement

THIS IS COPYRIGHTED CONTENT. Unauthorized use, including screenshots, copying, misuse, reuse, or resale of any content from this app, is strictly prohibited. Our app monitors and records all screenshots and recordings. Violators will face strict legal action.

DISCLAIMER
THIS IS COPYRIGHTED CONTENT. Unauthorized use, including screenshots, copying, misuse, reuse, or resale of any content from this app, is strictly prohibited. Our app monitors and records all screenshots and recordings. Violators will face strict legal action.

Our app monitors and records all screenshots and recordings. Violators will face strict legal action.

THIS IS COPYRIGHTED CONTENT. Unauthorized use, including screenshots, copying, misuse, reuse, or resale of any content from this app, is strictly prohibited. Our app monitors and records all screenshots and recordings. Violators will face strict legal action.

THIS IS COPYRIGHTED CONTENT. Unauthorized use, including screenshots, copying, misuse, reuse, or resale of any content from this app, is strictly prohibited. Our app monitors and records all screenshots and recordings. Violators will face strict legal action.

DISCLAIMER

THIS IS COPYRIGHTED CONTENT. Unauthorized use, including screenshots, copying, misuse, reuse, or resale of any content from this app, is strictly prohibited. Our app monitors and records all screenshots and recordings. Violators will face strict legal action.

PEDO+ORTHO

P.O.W.E.R NOTES SBQ 29

- I. Incipient caries appears white. Arrested caries appears brown black. Amelogenesis imperfecta and fluorosis usually affect generally not in a single tooth. Abrasion is the non-carious, mechanical wear of tooth from interaction with objects other than tooth-tooth contact.
- II. In anterior teeth you concern about the aesthetics so, options (B), (C), (E) are ruled out. RMGIC has better retention in cervical area than compomer as it chemically bonds without a bonding agent.

CHARACTERISTIC	COMPOMERS	RMGICs Resin-Modified Glass Ionomer Cements)
Composition	Resin matrix with glass filler particles	Glass ionomer core with resin component
Setting Mechanism	Primarily light-cured with some acid-base reaction	Dual-setting: light-curing followed by acid-base reaction
Fluoride Release	Moderate, diminishes over time	Higher, sustained release
Physical Properties	Better aesthetics (translucency, color match), higher wear resistance	Lower wear resistance, more opaque
Bonding to Tooth Structure	Requires bonding agent, less moisture tolerance	Chemically bonds without bonding agent, better moisture tolerance
Clinical Applications	Anterior/posterior restorations, paediatric dentistry	Non-load bearing areas, high-caries-risk patients
Handling	Easier to sculpt and achieve fine details	Slightly challenging but improved compared to traditional glass ionomers
Aesthetic Properties	High, suitable for visible areas	Adequate for non-aesthetic areas

DISCLAIMER

THIS IS COPYRIGHTED CONTENT. Unauthorized use, including screenshots, copying, misuse, reuse, or resale of any content from this app, is strictly prohibited. Our app monitors and records all screenshots and recordings. Violators will face strict legal action.

PEDO+ORTHO

SBQ 30

PATIENT 12 YEAR OLD COMES TO YOU WITH MOTHER, SHE HAD AN ORTHO TREATMENT FROM AN OVERSEAS DENTIST BUT THE DENTIST DID NOT INFORM THE PATIENT REGARDING HIS MISSING PREMOLAR AND ANKYLOSED DECIDUOUS MOLAR. SHE HAS A GAP. SHE WANTS TO COMPLAIN.

I. What should you professionally advise her?

- A. Leave as he is an overseas dentist
- B. Write to the local authority body where treatment done
- C. Write to the treating dentist
- D. Put in social media about that dentist
- E. Write letter to newspaper about

II. What is the common source of fluorosis for children in non-fluoridated area?

- A. Swallowing adult toothpaste 1000- 1500mg
- B. Daily sodium fluoride tablet 1mg daily

III. Patient couldn't quit smoking for the past 10 years. But in the last month he quit smoking and vapes an electronic cigarette only. What advice which has scientific evidence you should provide?

- A. E cigarette has chemical compound that induce cancer
- B. E cigarette is best nrt you should continue
- C. E cigarette has proved to help in quitting smoking.
- D. If you have any symptoms contact the medical doctor.

IV. Pt had a history of smoking for 5 years. When you told her I'm ready to give help if she wishes to quit smoking ,she replied I'm not an addict i can quit even now.. you diagnosed her attitude prevents her from quitting smoking. what is the evidence based strategy you should provide?

- A. Reassure her that health benefits of quit smoking accrue at any age (same words)
- B. Acknowledge her and explain positives of quit smoking(same words)
- C. Tell the fact that if she doesnt quit smoking can cause serious health problems..
- D. Give quit smoking pamphlet and contact details

V. How to use cpp-acp?

- A. Place it finger apply to teeth spread using tongue.
- B. Use with mouthwash
- C. Use pea size on finger , apply on teeth for 3 min , and spit out .
- D. Use tooth brush to apply
- E. Use tray to apply

DISCLAIMER

THIS IS COPYRIGHTED CONTENT. Unauthorized use, including screenshots, copying, misuse, reuse, or resale of any content from this app, is strictly prohibited. Our app monitors and records all screenshots and recordings. Violators will face strict legal action.

DISCLAIMER

THIS IS COPYRIGHTED CONTENT. Unauthorized use, including screenshots, copying, misuse, reuse, or resale of any content from this app, is strictly prohibited. Our app monitors and records all screenshots and recordings. Violators will face strict legal action.

THIS IS COPYRIGHTED CONTENT. Unauthorized use, including screenshots, copying, misuse, reuse, or resale of any content from this app, is strictly prohibited. Our app monitors and records all screenshots and recordings. Violators will face strict legal action.

DISCLAIMER

PEDO+ORTHO

SBQ 30

VI. You have to work with technician in order to make new partial denture, Which of these item you may not task the laboratory in order to maintain your professionalism?

- A.Frame design
- B.Final polishing material
- C.Ridge Contour
- D.Clasp selection
- E.Treatment plan

P.O.W.E.R NOTES SBQ 30

- I. Patient wants to complain about an overseas dentist as they are disappointed with the treatment. You should not involve in the middle of the situation rather you should encourage the patient to communicate with the overseas dentist.

THE PROTOCOL THAT WE FOLLOW:

- 1.Recommend them to discuss with their dentist; if the patient doesn't want to talk to their previous dentist then,
- 2.Request dental records and discuss findings; if the patient is still not happy,
- 3.Give details of the organisations to complain; AHPRA and ACCC

- II. Swallowing the adult toothpaste is an incorrect option, so answer is (B).

- III. All e-cigarettes, even those that don't contain nicotine, can contain dangerous substances in the liquid and the aerosol. These can include number of known cancer-causing agents. Such as:
Formaldehyde, acetone, acetaldehyde, heavy metals like nickel, tin, lead

Direct health risks of vaping:

- Irritation of the mouth and airways
- Persistent coughing
- Nausea and vomiting
- Chest pain and palpitations
- Poisoning and seizures from inhaling too much nicotine or ingestion of e-liquid
- Burns or injury caused by e-cigarette overheating or exploding
- Nicotine dependence
- Respiratory problems and permanent lung damage
- Harm to developing adolescent brain
- DNA damage

E-cigarettes don't produce the tar found in the conventional cigarettes which is the main cause of lung cancer. However, many scientists are concerned that vaping could increase the risk of lung disease, heart disease and cancer.

DISCLAIMER

THIS IS COPYRIGHTED CONTENT. Unauthorized use, including screenshots, copying, misuse, reuse, or resale of any content from this app, is strictly prohibited. Our app monitors and records all screenshots and recordings. Violators will face strict legal action.

DISCLAIMER

THIS IS COPYRIGHTED CONTENT. Unauthorized use, including screenshots, copying, misuse, reuse, or resale of any content from this app, is strictly prohibited. Our app monitors and records all screenshots and recordings. Violators will face strict legal action.

THIS IS COPYRIGHTED CONTENT. Unauthorized use, including screenshots, copying, misuse, reuse, or resale of any content from this app, is strictly prohibited. Our app monitors and records all screenshots and recordings. Violators will face strict legal action.

DISCLAIMER

PEDO+ORTHO

P.O.W.E.R NOTES SBQ 30

IV. Patient is not acknowledging that he's addicted to smoking. Her attitude is preventing her from quitting. You can't threaten and scare the patient. It's always good to explain the health benefits of quitting rather than saying the side effects of smoking.

V. **Reference TG:**

Table 8. Examples of topical fluoride applications for patients at elevated risk of dental caries [NB1] (cont.)

Formulation	Usual directions for use
fluoride+CPP-ACP 900 ppm+10% cream	Use in adults and children for noncavitated white spot lesions twice daily after brushing with usual fluoride toothpaste. Patients should apply the cream to the teeth, hold in the mouth for 3 to 5 minutes, spit out excess and avoid rinsing the mouth [NB2].

VI. As a dentist you won't discuss or take their help in treatment planning. But you can discuss about the frame design, final polishing material, ridge contour, clasp selection with the technician.

DISCLAIMER

THIS IS COPYRIGHTED CONTENT. Unauthorized use, including screenshots, copying, misuse, reuse, or resale of any content from this app, is strictly prohibited. Our app monitors and records all screenshots and recordings. Violators will face strict legal action.

DISCLAIMER
THIS IS COPYRIGHTED CONTENT. Unauthorized use, including screenshots, copying, misuse, reuse, or resale of any content from this app, is strictly prohibited. Our app monitors and records all screenshots and recordings. Violators will face strict legal action.

THIS IS COPYRIGHTED CONTENT. Unauthorized use, including screenshots, copying, misuse, reuse, or resale of any content from this app, is strictly prohibited. Our app monitors and records all screenshots and recordings. Violators will face strict legal action.

DISCLAIMER

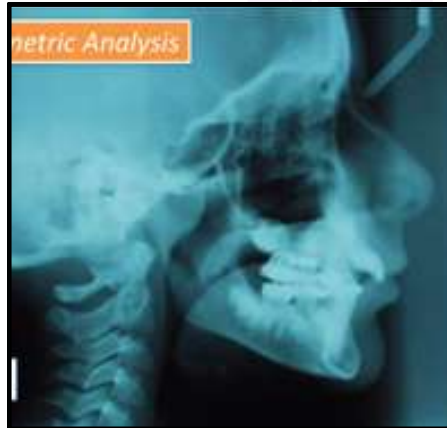THIS IS COPYRIGHTED CONTENT. Unauthorized use, including screenshots, copying, misuse, reuse, or resale of any content from this app, is strictly prohibited. Our app monitors and records all screenshots and recordings. Violators will face strict legal action.

THIS IS COPYRIGHTED CONTENT. Unauthorized use, including screenshots, copying, misuse, reuse, or resale of any content from this app, is strictly prohibited. Our app monitors and records all screenshots and recordings. Violators will face strict legal action.

PEDO+ORTHO

SBQ 31

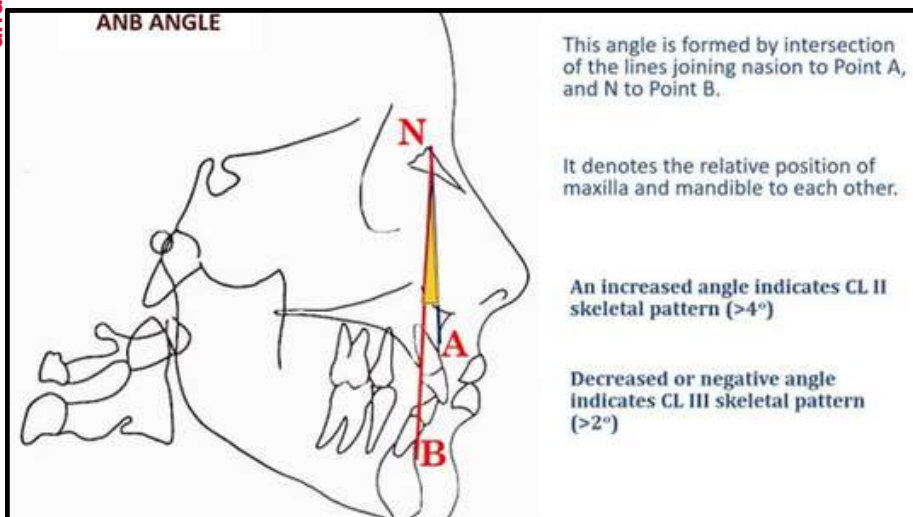
CHILD WAS ABOUT 11 YEARS OLD. LATERAL CEPHALOGRAM OF A CHILD GIVEN ASKING WHICH SKELETAL MALOCCLUSION IS THIS. (MOLAR RELATIONSHIP WAS NOT CLEAR - 1ST MOLAR WERE RETAINED). CENTRAL INCISORS: 11 WAS EDGE TO EDGE IN THE PICTURE, 21 WAS NORMAL. WHAT IS THE SKELETAL RELATIONSHIP?



- A. Class 2 div 2
- B. Class 1
- C. Class 3
- D. Cannot determine malocclusion pattern by only lateral cephalogram
- E. Class 2 div 1

P.O.W.E.R NOTES SBQ 31

Look at the point nasion, A and point B. It's greater than 4degree. There's incisor inclination and overjet. So, it's class 2 div 1. If the incisors are retroclined, then it's class 2 div 2.



DISCLAIMER

THIS IS COPYRIGHTED CONTENT. Unauthorized use, including screenshots, copying, misuse, reuse, or resale of any content from this app, is strictly prohibited. Our app monitors and records all screenshots and recordings. Violators will face strict legal action.

THIS IS COPYRIGHTED CONTENT. Unauthorized use, including screenshots, copying, misuse, reuse, or resale of any content from this app, is strictly prohibited. Our app monitors and records all screenshots and recordings. Violators will face strict legal action.

DISCLAIMER
THIS IS COPYRIGHTED CONTENT. Unauthorized use, including screenshots, copying, misuse, reuse, or resale of any content from this app, is strictly prohibited. Our app monitors and records all screenshots and recordings. Violators will face strict legal action.

THIS IS COPYRIGHTED CONTENT. Unauthorized use, including screenshots, copying, misuse, reuse, or resale of any content from this app, is strictly prohibited. Our app monitors and records all screenshots and recordings. Violators will face strict legal action.

DISCLAIMER

PEDO+ORTHO

SBQ 32

12 YEAR OLD MARYAM KNOCKED OUT HER FRONT TOOTH. MOTHER IS A RELATIVE OF YOU. YOU KNOW MOTHER IS VERY LOUSY (MOTHER IS VERY VOCAL ABOUT HER DAUGHTER IN FAMILY GATHERINGS, CAME TO YOU AFTER 6 HRS AND TOOTH WAS WRAPPED IN PLASTIC PLACED NEXT TO ICE IN THE LUNCHBOX. CHILD CALLED THE MOTHER AFTER A FEW HOURS ABOUT WHAT TO DO WITH THE KNOCKED TOOTH. SHE INSTRUCTED TO WRAP IT IN PLASTIC. THEY CAME TO YOUR CLINIC WITH THE KNOCKED TOOTH. SHE HAD CLASS 2 MALOCCLUSION

I. What is the viability of periodontal ligament?

- A. Non-viable
- B. Might be viable but less functional
- C. Highly viable
- D. Viable compromised
- E. Viable uncompromised

II. Your cousin is very upset and unhappy when you explained her the complications that can occur. She thinks the tooth will be back to normal and is not ready to accept otherwise. She wants the tooth to be fixed. How will you manage this?

- A. Advise her that you will refer her to a paedodontist right after fixing the avulsed tooth
- B. Reassure her that you are in the best position to manage this
- C. Ask her to trust you because you're a qualified professional beyond being her cousin
- D. Ask her to reconsider the matter and explain to her that she can call you any time for support and advise

III. To prevent further injury while playing football what would be your best advice to the child?

- A. To use custom mouth guard while playing football
- B. Correct class 2 malocclusion
- C. Stabilise maxilla

IV. What to tell Maryam regarding tooth avulsion if happens next time?

- A. Rinse in cold water for ten minutes and bag it
- B. Hold the tooth from the yellow part
- C. If can't visit immediately, put it in milk
- D. Keep it in the buccal vestibule

IV. What is the best medium to be used for avulsion.

- A. Milk
- B. Water
- C. No medium
- D. Saliva and keep the tooth in box

DISCLAIMER

THIS IS COPYRIGHTED CONTENT. Unauthorized use, including screenshots, copying, misuse, reuse, or resale of any content from this app, is strictly prohibited. Our app monitors and records all screenshots and recordings. Violators will face strict legal action.

DISCLAIMER

THIS IS COPYRIGHTED CONTENT. Unauthorized use, including screenshots, copying, misuse, reuse, or resale of any content from this app, is strictly prohibited. Our app monitors and records all screenshots and recordings. Violators will face strict legal action.

THIS IS COPYRIGHTED CONTENT. Unauthorized use, including screenshots, copying, misuse, reuse, or resale of any content from this app, is strictly prohibited. Our app monitors and records all screenshots and recordings. Violators will face strict legal action.

DISCLAIMER

PEDO+ORTHO

SBQ 32

VI. What can complicate the situation of this avulsed tooth

- A. Inflammatory resorption
- B. Ankylosis
- C. Grey or yellow discoloration
- D. Pulp canal obliteration

P.O.W.E.R NOTES SBQ 32

- I. **The PDL cells are most likely viable.** The tooth has been replanted immediately or within a very short period (about 15min) at the place of the accident.

The PDL cells may be viable but compromised. The tooth has been kept in a storage medium (e.g: milk, HBSS, saliva or saline) and the total extra oral time has been <60min.

The PDL cells are likely to be non-viable. The total extra oral dry time has been more than 60min, regardless of the tooth have been stored in a medium or not.

- II. Tooth will not have a favourable outcome after more than 6hrs of extra oral time. But you must fix the avulsed tooth and refer the patient to the specialist. You can replant the tooth, but the prognosis will be poor.

- III. Even though class 2 injuries lead to frequent injuries, 12yrs is not the age to correct the malocclusion orthodontically. Therefore, mouth guards are mandatory to prevent from sports injuries with or without the correction of malocclusions.

- IV. In avulsion it's always good to meet the dentist immediately. But if it's not possible tooth should be kept in a storage medium (e.g.: milk, HBSS, saliva or saline).

- V. Milk is the best storage medium. Even better than HBSS.

Milk > HBSS > saliva > saline

- VI. Inflammatory response will lead to immediate exfoliation, mobility, loosening. Ankylosis can lead to infra occlusion and unfavourable tooth but it can maintain the space. Mobility is the worst outcome.

DISCLAIMER

THIS IS COPYRIGHTED CONTENT. Unauthorized use, including screenshots, copying, misuse, reuse, or resale of any content from this app, is strictly prohibited. Our app monitors and records all screenshots and recordings. Violators will face strict legal action.

DISCLAIMER

THIS IS COPYRIGHTED CONTENT. Unauthorized use, including screenshots, copying, misuse, reuse, or resale of any content from this app, is strictly prohibited. Our app monitors and records all screenshots and recordings. Violators will face strict legal action.

THIS IS COPYRIGHTED CONTENT. Unauthorized use, including screenshots, copying, misuse, reuse, or resale of any content from this app, is strictly prohibited. Our app monitors and records all screenshots and recordings. Violators will face strict legal action.

DISCLAIMER

PEDO+ORTHO

SBQ 33

ETHAN 8 YEARS OLD AVULSION 11 AND 52. FATHER BROUGHT THE CHILD AFTER HE FELL ON FACE IN A RUGBY MATCH IN SCHOOL. CHILD WAS CLASS 2 DIV 1, THE TOOTH HASN'T BEEN FOUND YET AND THE COACH IS STILL LOOKING FOR IT. CHILD LOOKS CONFUSED AND NAUSEOUS. YOU ARE WAITING FOR THE TOOTH TO ARRIVE.

I. What should you do first?

- A. Check tetanus status
- B. Check brain concussion symptoms
- C. Check dental status
- D. Radiograph the inferior lip

II. Which tooth PRECLUDES reimplantation?

- A. Deciduous tooth can't reimplant
- B. Closed apex permanent
- C. Open apex permanent teeth after 60 minutes
- D. Tooth which has been manipulated from root

III. What to tell the kid to prevent this from happening

- A. Wear a custom-made mouthguard
- B. Correct his malocclusion
- C. Be more careful while playing
- D. Change the sport

IV. What will you suggest further if such types of injuries happen?

- A. Put it in milk
- B. Put it in water
- C. Hold it from yellow part of tooth

P.O.W.E.R NOTES SBQ 33

I. When the patient has neurological signs patient should be medically checked 1st rather than looking for the dental concerns. In the hx nausea and concussion are given.

II. Deciduous teeth are not re implanted.

Patient should be advised to wear the mouth guard to prevent from getting dental trauma from sports injuries.

Milk is the best storage medium. Even better than HBSS.

Milk > HBSS > saliva > saline

DISCLAIMER

THIS IS COPYRIGHTED CONTENT. Unauthorized use, including screenshots, copying, misuse, reuse, or resale of any content from this app, is strictly prohibited. Our app monitors and records all screenshots and recordings. Violators will face strict legal action.

DISCLAIMER
THIS IS COPYRIGHTED CONTENT. Unauthorized use, including screenshots, copying, misuse, reuse, or resale of any content from this app, is strictly prohibited. Our app monitors and records all screenshots and recordings. Violators will face strict legal action.

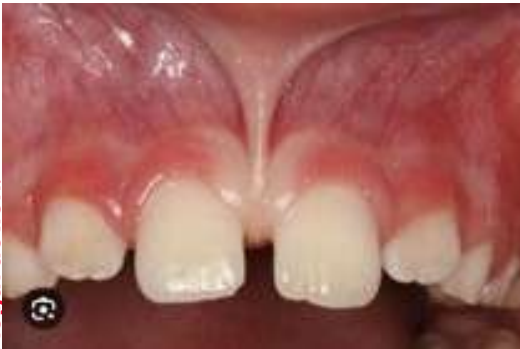THIS IS COPYRIGHTED CONTENT. Unauthorized use, including screenshots, copying, misuse, reuse, or resale of any content from this app, is strictly prohibited. Our app monitors and records all screenshots and recordings. Violators will face strict legal action.

DISCLAIMER

PEDO+ORTHO

SBQ 34

IN A RURAL AREA, JASON HE'S 10 YEARS OLD CASE AND PRINCIPAL DENTIST VISITING FORTNIGHTLY. ANOTHER DENTIST SAYS THAT THE ONLY WAY TO CLOSE THE DIASTEMA BETWEEN 11 AND 21 IS BY DOING FRENECTOMY AND THE PARENTS WITH THE CHILD COME TO YOUR PRACTICE AND THEY DON'T WISH FOR THAT PROCEDURE. CANINES AND UPPER 2ND PMS HAVE NOT ERUPTED YET. PARENTS DO NOT WANT TO GET FRENECTOMY DONE AND WANT ALTERNATIVE TREATMENTS. WHAT RECOMMENDATION YOU WILL GIVE THEM?



- A. Have to do the frenectomy, to close the diastema and then do ortho
- B. Do nothing and wait for the permanent canines to erupt
- C. If the frenectomy is done now the scar will not impede the ortho treatment.
- D. Start ortho treatment, lets the canines erupt and then do frenectomy

THIS IS COPYRIGHTED CONTENT. Unauthorized use, including screenshots, copying, misuse, reuse, or resale of any content from this app, is strictly prohibited. Our app monitors and records all screenshots and recordings. Violators will face strict legal action.

DISCLAIMER

THIS IS COPYRIGHTED CONTENT. Unauthorized use, including screenshots, copying, misuse, reuse, or resale of any content from this app, is strictly prohibited. Our app monitors and records all screenshots and recordings. Violators will face strict legal action.

DISCLAIMER
THIS IS COPYRIGHTED CONTENT. Unauthorized use, including screenshots, copying, misuse, reuse, or resale of any content from this app, is strictly prohibited. Our app monitors and records all screenshots and recordings. Violators will face strict legal action.

THIS IS COPYRIGHTED CONTENT. Unauthorized use, including screenshots, copying, misuse, reuse, or resale of any content from this app, is strictly prohibited. Our app monitors and records all screenshots and recordings. Violators will face strict legal action.

THIS IS COPYRIGHTED CONTENT. Unauthorized use, including screenshots, copying, misuse, reuse, or resale of any content from this app, is strictly prohibited. Our app monitors and records all screenshots and recordings. Violators will face strict legal action.

THIS IS COPYRIGHTED CONTENT. Unauthorized use, including screenshots, copying, misuse, reuse, or resale of any content from this app, is strictly prohibited. Our app monitors and records all screenshots and recordings. Violators will face strict legal action.

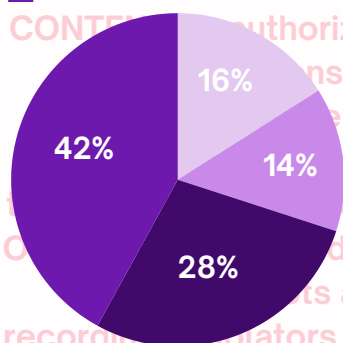
PEDO+ORTHO

P.O.W.E.R NOTES SBQ 34

- There are multiple things to concern in this case. Patient's age is 10yrs. Still there's time for canines to erupt and close this gap between the front teeth naturally. Some potential of closing is still there. There's a waiting period of starting the ortho treatment till the canine erupts. You must wait till the age of 12-13yrs.
- Blanch test and radiographic assessment are done to check for the abnormal frenum. Radiographic assessment – IOPA is taken to see the alveolar notch/depression.
- Frenectomy as a part of orthodontic treatment, can aid in diastema closure.
- When frenectomy is done before or after diastema closure in the presence of abnormal frenum has a better long- term stability.
- Abnormal labial frenum is also considered to be a potential cause of median diastema and has demonstrated a potential for relapse after closure with orthodontic treatment.
- Midline bony clefts can be associated with an abnormal frenum as its fibrous tissue insert into the notch in the alveolar bone. This inter-crestal bony cleft may keep the teeth apart and interrupt the formation of the transeptal fibres.
- Orthodontic relapse of median diastema was twice as great in patients with abnormal frenum compared with those with normal frenum attachment, and the risk of relapse reduced by performing frenectomy.
- Permanent retention without frenectomy can control orthodontic relapse but this can lead to cervical resorption. That's why majority advice to proceed with frenectomy.

TIMING OF FRENECTOMY IN RELATION TO ORTHODONTIC SPACE CLOSURE

- Before starting orthodontic Rx
- Timings doesn't matter
- Just before diastema closure
- After diastema closure



It's suggested that frenum resist mesial pressure, **frenectomy before orthodontic closure** should lead to **faster tooth movement**.

The rationale for closure of median diastema prior to **frenectomy** is to **improve the stability of the space closure** by consolidating the teeth **with scar tissues forming around the surgical site**. They also believe that with early frenectomy, old scar tissue may impede orthodontic space closure.

I. Patient is still 10yrs and orthodontic Rx is not recommended at this age. So frenectomy is not required to do right now. So, option (B) is the right answer.

DISCLAIMER

THIS IS COPYRIGHTED CONTENT. Unauthorized use, including screenshots, copying, misuse, reuse, or resale of any content from this app, is strictly prohibited. Our app monitors and records all screenshots and recordings. Violators will face strict legal action.

DISCLAIMER

THIS IS COPYRIGHTED CONTENT. Unauthorized use, including screenshots, copying, misuse, reuse, or resale of any content from this app, is strictly prohibited. Our app monitors and records all screenshots and recordings. Violators will face strict legal action.

THIS IS COPYRIGHTED CONTENT. Unauthorized use, including screenshots, copying, misuse, reuse, or resale of any content from this app, is strictly prohibited. Our app monitors and records all screenshots and recordings. Violators will face strict legal action.

DISCLAIMER

PEDO+ORTHO

SBQ 35

ORTHO MIDLINE DIASTEMA BETWEEN 11 AND 21. DIASTEMA MORE THAN 2MM SEEN IN PHOTOGRAPHS NOT MENTIONED IN WRITTEN. AGE OF CHILD 10 YEARS LABIAL FRENUM PRESENT CAUSING BLANCHING OF GINGIVA BETWEEN CENTRALS. IT DOESN'T HAVE PERMANENT PREMOLARS AND CANINES HAVE ERUPTED. FINANCIAL CONSTRAINTS. THEY HAD SEEN A PREVIOUS DENTIST AND HE TOLD ME CORRECTION OF DIASTEMA IS NOT POSSIBLE WITHOUT FRENECTOMY.

I. Parents not wishing for frenectomy. Come to you now for a checkup again. What is the best investigation?

- A. IOPA in upper central incisors
- B. Standard occlusal
- C. MRI of soft tissues - it means for thick frenum
- D. Cephalogram probing
- E. Occlusal view

II. A combined treatment of frenectomy and Ortho treatment was decided. Why would you consider doing frenectomy IMMEDIATELY before ortho treatment?

- A. Reduces scar tissue between centrals
- B. It closes the diastema faster(make move central incisors easier)
- C. If we don't do frenectomy it will hinder ortho treatment
- D. To allow better interproximal cleaning while using fixed ortho

III. Parents are worried about the procedure and financial constraints. looking at the picture you prefer to do frenectomy. What alternatives can you suggest?

- A. Monitor eruption of canine and then reassess the need of frenectomy at that stage
- B. Normal for the age
- C. Not normal, it will not close later on its own
- D. It will get close on its own as she grows
- E. Refer to ortho (not in all centres)

IV. What is hindrance for diastema closure?

- A. Having thick labial frenum
- B. Age of the child not suitable for the ortho treatment

V. Who will Give the consent, child is 12 years old?

- A. Child
- B. Both parents
- C. Child and mother
- D. Child and dentist
- E. No consent

DISCLAIMER

THIS IS COPYRIGHTED CONTENT. Unauthorized use, including screenshots, copying, misuse, reuse, or resale of any content from this app, is strictly prohibited. Our app monitors and records all screenshots and recordings. Violators will face strict legal action.

DISCLAIMER

THIS IS COPYRIGHTED CONTENT. Unauthorized use, including screenshots, copying, misuse, reuse, or resale of any content from this app, is strictly prohibited. Our app monitors and records all screenshots and recordings. Violators will face strict legal action.

THIS IS COPYRIGHTED CONTENT. Unauthorized use, including screenshots, copying, misuse, reuse, or resale of any content from this app, is strictly prohibited. Our app monitors and records all screenshots and recordings. Violators will face strict legal action.

DISCLAIMER

PEDO+ORTHO

P.O.W.E.R NOTES SBQ 35

- I. Blanching of gingiva – presence of abnormal frenum, patient is 12yrs old and canine have erupted. Before the eruption of canine 2mm gap is normal and 4mm gap is abnormal. After the eruption of canine 2mm is abnormal. Other than the blanch test IOPA is don't to see the alveolar notch.
- II. We have to choose an answer to support “doing frenectomy before the treatment.” So according to the reference given above; It's suggested that frenum resist mesial pressure, frenectomy before orthodontic closure should lead to faster tooth movement.
- III. If canines are not fully erupted then answer should be (A) and if canines are fully erupted then the median diastema can't get closed by its own in that case. Option (A), (B), (D) get ruled out. Frenectomy is needed. So, you have to refer the patient to the orthodontist. If option (E) is not given then the next best option is (C).
- IV. There's a hindrance of diastema closure because of the thickness of the labial frenum. That's why the natural diastema closure is not happening.
- V. Child is still 12yrs old. So, the consent is given by the parents.
14-16yrs both the child and parent can give the consent.

THIS IS COPYRIGHTED CONTENT. Unauthorized use, including screenshots, copying, misuse, reuse, or resale of any content from this app, is strictly prohibited. Our app monitors and records all screenshots and recordings. Violators will face strict legal action.

DISCLAIMER

THIS IS COPYRIGHTED CONTENT. Unauthorized use, including screenshots, copying, misuse, reuse, or resale of any content from this app, is strictly prohibited. Our app monitors and records all screenshots and recordings. Violators will face strict legal action.

THIS IS COPYRIGHTED CONTENT. Unauthorized use, including screenshots, copying, misuse, reuse, or resale of any content from this app, is strictly prohibited. Our app monitors and records all screenshots and recordings. Violators will face strict legal action.

DISCLAIMER
THIS IS COPYRIGHTED CONTENT. Unauthorized use, including screenshots, copying, misuse, reuse, or resale of any content from this app, is strictly prohibited. Our app monitors and records all screenshots and recordings. Violators will face strict legal action.

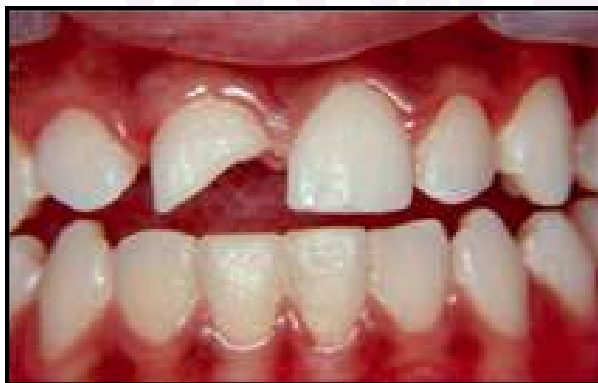DISCLAIMER

THIS IS COPYRIGHTED CONTENT. Unauthorized use, including screenshots, copying, misuse, reuse, or resale of any content from this app, is strictly prohibited. Our app monitors and records all screenshots and recordings. Violators will face strict legal action.

PEDO+ORTHO

SBQ 36

A 9 YEAR OLD BOY FELL DOWN WHILE PLAYING AND SUDDENLY HAD A HEADACHE AND FELT DIZZY. ALSO, 11/ 21 WAS FRACTURED.



I. What should be done immediately?

- A. Arrange to take him to the emergency department.
- B. Ask his father to take him to his medical practitioner.
- C. Not an issue, take him to the dentist
- D. Start required dental treatment
- E. Send the Patient home

II. A 9 year old boy fell while playing. There is fracture in respect to 11 and there is pinpoint exposure of pulp. What kind of fracture is it?

- A. Complicated crown fracture
- B. Uncomplicated crown fracture
- C. Complicated crown root fracture
- D. Crown infarction

III. You took a radiograph by paralleling technique in the midline of 11, 21. What is the other appropriate radiograph you need to take next?

- A. Opg
- B. Paralleling technique in 12 in center
- C. Paralleling technique in respect to 53 center
- D. Vertical shift the tube
- E. Lateral cephalogram

THIS IS COPYRIGHTED CONTENT. Unauthorized use, including screenshots, copying, misuse, reuse, or resale of any content from this app, is strictly prohibited. Our app monitors and records all screenshots and recordings. Violators will face strict legal action.

DISCLAIMER
THIS IS COPYRIGHTED CONTENT. Unauthorized use, including screenshots, copying, misuse, reuse, or resale of any content from this app, is strictly prohibited. Our app monitors and records all screenshots and recordings. Violators will face strict legal action.

DISCLAIMER

THIS IS COPYRIGHTED CONTENT. Unauthorized use, including screenshots, copying, misuse, reuse, or resale of any content from this app, is strictly prohibited. Our app monitors and records all screenshots and recordings. Violators will face strict legal action.

THIS IS COPYRIGHTED CONTENT. Unauthorized use, including screenshots, copying, misuse, reuse, or resale of any content from this app, is strictly prohibited. Our app monitors and records all screenshots and recordings. Violators will face strict legal action.

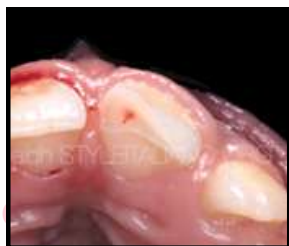DISCLAIMER

PEDO+ORTHO

SBQ 36

IV. What would you recommend as the Best immediate treatment for this patient?

(only 1 tooth was involved either 11 or 21. Pinpoint pulp exposure pic was given almost like this one)



- A. Dpc with mta
- B. Composite restoration
- C. Pulpectomy
- D. Extraction

V. Cyclist had a trauma. His friends bring him to you. You gave him a mirror and he sees a blood like pin - point appearance on the fractured anterior tooth. What is your treatment?

- A. Dpc
- B. Pulpotomy
- C. Ipc
- D. Pulpectomy

VI. The tooth wasn't mobile but the patient feels he can't bite because he feels as if it was hitting the incisal edge lower teeth. What kind of injury can it be?

- A. Palatal Luxation
- B. Extrusion
- C. Labial Luxation

THIS IS COPYRIGHTED CONTENT. Unauthorized use, including screenshots, copying, misuse, reuse, or resale of any content from this app, is strictly prohibited. Our app monitors and records all screenshots and recordings. Violators will face strict legal action.

DISCLAIMER
THIS IS COPYRIGHTED CONTENT. Unauthorized use, including screenshots, copying, misuse, reuse, or resale of any content from this app, is strictly prohibited. Our app monitors and records all screenshots and recordings. Violators will face strict legal action.

THIS IS COPYRIGHTED CONTENT. Unauthorized use, including screenshots, copying, misuse, reuse, or resale of any content from this app, is strictly prohibited. Our app monitors and records all screenshots and recordings. Violators will face strict legal action.

DISCLAIMER

THIS IS COPYRIGHTED CONTENT. Unauthorized use, including screenshots, copying, misuse, reuse, or resale of any content from this app, is strictly prohibited. Our app monitors and records all screenshots and recordings. Violators will face strict legal action.

THIS IS COPYRIGHTED CONTENT. Unauthorized use, including screenshots, copying, misuse, reuse, or resale of any content from this app, is strictly prohibited. Our app monitors and records all screenshots and recordings. Violators will face strict legal action.

DISCLAIMER

PEDO+ORTHO

P.O.W.E.R NOTES SBQ 36

- I. According to the history the patient has headache and dizziness. It's an emergency so, the patient should be sent to the emergency department.
- II. There's a pinpoint exposure of pulp. Therefore, the pulp is involved. It's a complicated crown fracture.
- III. Since maxillary central incisors are the most frequently affected teeth, the radiographs listed below are recommended to thoroughly examine the injured area:
 - One parallel periapical radiograph aimed through the midline to show the two maxillary central incisors.
 - One parallel periapical radiograph aimed at the maxillary right lateral incisors.
 - One parallel periapical radiograph aimed at the maxillary left lateral incisors.
 - One maxillary occlusal radiograph
 - One parallel periapical radiograph of the lower incisors centred on the two mandibular centrals.
- IV. Patient is 9yrs old. Mostly the roots are matured. In mature teeth partial pulpotomy is recommended for pinpoint exposure. That answer is not given, DPC is indicated for immature permanent teeth with pinpoint pulp exposure. In this question we believe that it's still an immature permanent.
- V. As mentioned above based on the age, maturity of roots according to the given radiographs you need to choose whether it's DPC or pulpotomy.
 - immature permanent with pinpoint exposure- DPC
 - mature permanent with pinpoint exposure- pulpotomy
- VI. If the traumatised tooth is not mobile but if it's hitting the incisal edge of the lower incisors, it is due to palatal luxation. Extrusive luxations are mobile. Extrusion takes place in the vertical plane whereas the palatal/labial luxation takes place in the antero-posterior plane.

THIS IS COPYRIGHTED CONTENT. Unauthorized use, including screenshots, copying, misuse, reuse, or resale of any content from this app, is strictly prohibited. Our app monitors and records all screenshots and recordings. Violators will face strict legal action.

DISCLAIMER

THIS IS COPYRIGHTED CONTENT. Unauthorized use, including screenshots, copying, misuse, reuse, or resale of any content from this app, is strictly prohibited. Our app monitors and records all screenshots and recordings. Violators will face strict legal action.

THIS IS COPYRIGHTED CONTENT. Unauthorized use, including screenshots, copying, misuse, reuse, or resale of any content from this app, is strictly prohibited. Our app monitors and records all screenshots and recordings. Violators will face strict legal action.

DISCLAIMER
THIS IS COPYRIGHTED CONTENT. Unauthorized use, including screenshots, copying, misuse, reuse, or resale of any content from this app, is strictly prohibited. Our app monitors and records all screenshots and recordings. Violators will face strict legal action.

THIS IS COPYRIGHTED CONTENT. Unauthorized use, including screenshots, copying, misuse, reuse, or resale of any content from this app, is strictly prohibited. Our app monitors and records all screenshots and recordings. Violators will face strict legal action.

WINSPERT
P.O.W.E.R
NOTES

PEDO+ORTHO

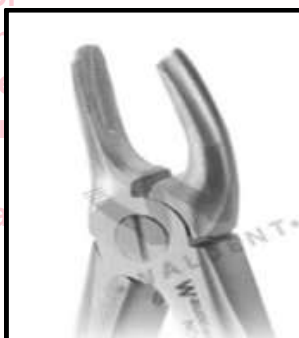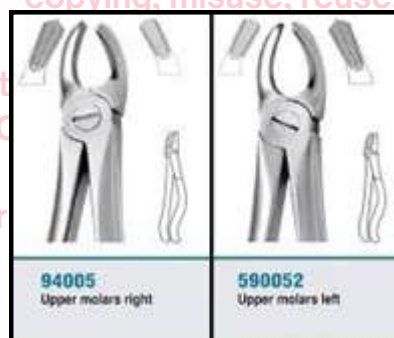SBQ 37

PRIMARY TEETH (MOD)

I. Picture of primary teeth occlusal view was given but it was cropped and rotated sideways, which are visible on the photograph (all were primary teeth only).

- A. 55 54 53 52
- B. 65 64 63 22
- C. 33 34 35 32
- D. 75 74 73 72

II. A small picture of two upper left and right and two lower extraction forceps was given. which one using for extracting 55



THIS IS COPYRIGHTED CONTENT. Unauthorized use, including screenshots, copying, misuse, reuse, or resale of any content from this app, is strictly prohibited. Our app monitors and records all screenshots and recordings. Violators will face strict legal action.

DISCLAIMER

THIS IS COPYRIGHTED CONTENT. Unauthorized use, including screenshots, copying, misuse, reuse, or resale of any content from this app, is strictly prohibited. Our app monitors and records all screenshots and recordings. Violators will face strict legal action.

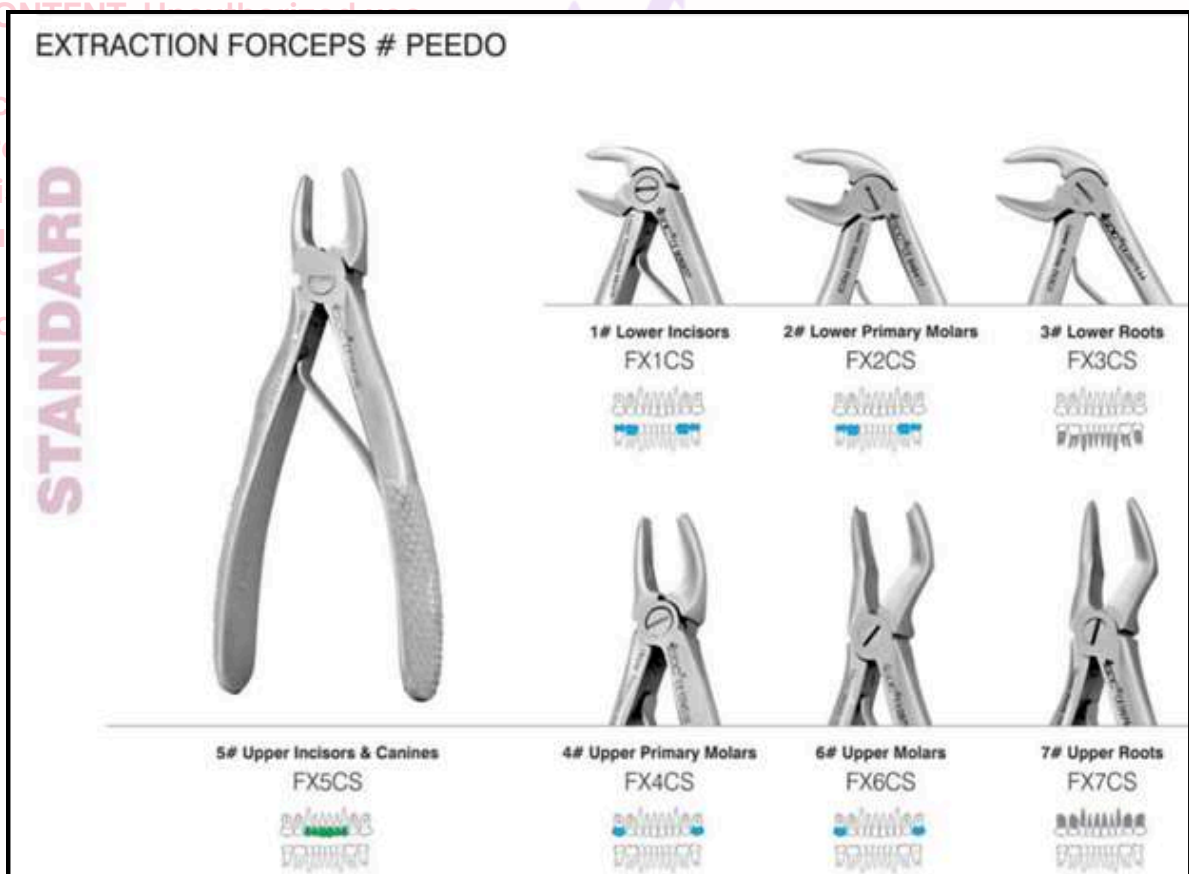
THIS IS COPYRIGHTED CONTENT. Unauthorized use, including screenshots, copying, misuse, reuse, or resale of any content from this app, is strictly prohibited. Our app monitors and records all screenshots and recordings. Violators will face strict legal action.

DISCLAIMER
THIS IS COPYRIGHTED CONTENT. Unauthorized use, including screenshots, copying, misuse, reuse, or resale of any content from this app, is strictly prohibited. Our app monitors and records all screenshots and recordings. Violators will face strict legal action.

PEDO+ORTHO

P.O.W.E.R NOTES SBQ 37

- I. In the question it's mentioned about the primary teeth. So, options (B) and (C) get ruled out. If the occlusal view shows upper teeth answer would be (A) whereas if the occlusal view shows lower teeth answer would be (D).
- II. Both the beaks are pointed in the upper primary molar forceps as there's no right and left forceps.
Upper molars forceps are pointed and bent. Upper premolar forceps are flat end and bent. Upper incisor forceps are straight and flat end. Upper root forceps are tapered.



THIS IS COPYRIGHTED CONTENT. Unauthorized use, including screenshots, copying, misuse, reuse, or resale of any content from this app, is strictly prohibited. Our app monitors and records all screenshots and recordings. Violators will face strict legal action.

DISCLAIMER

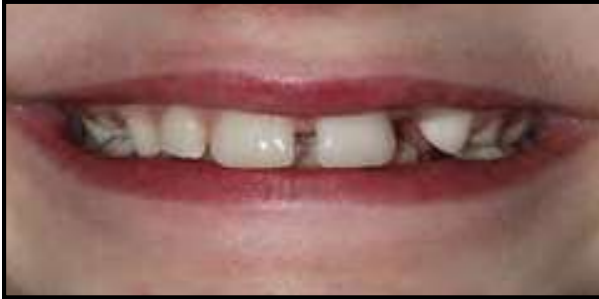THIS IS COPYRIGHTED CONTENT. Unauthorized use, including screenshots, copying, misuse, reuse, or resale of any content from this app, is strictly prohibited. Our app monitors and records all screenshots and recordings. Violators will face strict legal action.

DISCLAIMER
THIS IS COPYRIGHTED CONTENT. Unauthorized use, including screenshots, copying, misuse, reuse, or resale of any content from this app, is strictly prohibited. Our app monitors and records all screenshots and recordings. Violators will face strict legal action.

DISCLAIMER

THIS IS COPYRIGHTED CONTENT. Unauthorized use, including screenshots, copying, misuse, reuse, or resale of any content from this app, is strictly prohibited. Our app monitors and records all screenshots and recordings. Violators will face strict legal action.

PEDO+ORTHO

SBQ 38
DEEP BITE CASE 10 YEARS OLD. ONE LATERAL INCISOR IS MISSING


THIS IS COPYRIGHTED CONTENT. Unauthorized use, including screenshots, copying, misuse, reuse, or resale of any content from this app, is strictly prohibited. Our app monitors and records all screenshots and recordings. Violators will face strict legal action.

I. How to correct the deep bite?

OR

What is the treatment for the deep bite?

- A. Treatment with fixed ortho
- B. Use bite plane to intrude lower incisors
- C. Use Invisalign aligners for the alignment
- D. You will give removable appliance

DISCLAIMER
THIS IS COPYRIGHTED CONTENT. Unauthorized use, including screenshots, copying, misuse, reuse, or resale of any content from this app, is strictly prohibited. Our app monitors and records all screenshots and recordings. Violators will face strict legal action.

THIS IS COPYRIGHTED CONTENT. Unauthorized use, including screenshots, copying, misuse, reuse, or resale of any content from this app, is strictly prohibited. Our app monitors and records all screenshots and recordings. Violators will face strict legal action.

DISCLAIMER

THIS IS COPYRIGHTED CONTENT. Unauthorized use, including screenshots, copying, misuse, reuse, or resale of any content from this app, is strictly prohibited. Our app monitors and records all screenshots and recordings. Violators will face strict legal action.

THIS IS COPYRIGHTED CONTENT. Unauthorized use, including screenshots, copying, misuse, reuse, or resale of any content from this app, is strictly prohibited. Our app monitors and records all screenshots and recordings. Violators will face strict legal action.

THIS IS COPYRIGHTED CONTENT. Unauthorized use, including screenshots, copying, misuse, reuse, or resale of any content from this app, is strictly prohibited. Our app monitors and records all screenshots and recordings. Violators will face strict legal action.

DISCLAIMER

PEDO+ORTHO

P.O.W.E.R NOTES SBQ 38

- I.
 - Deep bite is not corrected at the mixed dentition period as it can be self corrected.
 - The overbite is greater after eruption of the prominent incisors and decreases with the eruption of the posterior teeth. If the skeletal bases are class I with normal incisor angulation, it's better to wait and watch till the eruption of the posterior teeth which results in resolution of deep bite.
 - For this reason intrusion as a part of early treatment is seldom required. It's often better to differ this treatment until the early permanent dentition.
 - Early childhood is the best time to treat complex deep bite.
 - Deep bites with anterior vertical maxillary excess showing gummy lines can be intercepted by high pull headgears.
 - So, option (A) is ruled out.
 - In deep bite cases bite plane is used to intrude the upper incisors not the lower incisors. And also not preferably at her age. So, option (B) is ruled out.
 - In non skeletal deep bites, a utility arch that incorporates molar and incisor teeth can be used during the mixed dentition to intrude, tip or reposition both molar and incisors.
 - With invasives stable results were obtained. Evaluating the effectiveness, safety and acceptability of aligners during primary and mixed dentition phases indicates comparable efficacies to traditional fixed appliances, with potential advantages in terms of treatment duration and patient comfort. Clear aligners playing a significant role in meeting the needs of the growing patients.
 - With aligner we can do minor corrections. There's no option saying no treatment, wait and observe. Between (C) and (D), option (C) has got the better aesthetics and easy maintenance of OH. With the removable appliances plaque retention is more due to the presence of wire components and it has got full coverage areas.

THIS IS COPYRIGHTED CONTENT. Unauthorized use, including screenshots, copying, misuse, reuse, or resale of any content from this app, is strictly prohibited. Our app monitors and records all screenshots and recordings. Violators will face strict legal action.

DISCLAIMER

THIS IS COPYRIGHTED CONTENT. Unauthorized use, including screenshots, copying, misuse, reuse, or resale of any content from this app, is strictly prohibited. Our app monitors and records all screenshots and recordings. Violators will face strict legal action.

THIS IS COPYRIGHTED CONTENT. Unauthorized use, including screenshots, copying, misuse, reuse, or resale of any content from this app, is strictly prohibited. Our app monitors and records all screenshots and recordings. Violators will face strict legal action.

DISCLAIMER
THIS IS COPYRIGHTED CONTENT. Unauthorized use, including screenshots, copying, misuse, reuse, or resale of any content from this app, is strictly prohibited. Our app monitors and records all screenshots and recordings. Violators will face strict legal action.

Our app monitors and records all screenshots and recordings. Violators will face strict legal action.

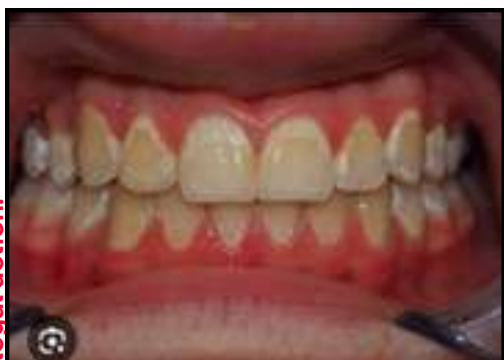DISCLAIMER
THIS IS COPYRIGHTED CONTENT. Unauthorized use, including screenshots, copying, misuse, reuse, or resale of any content from this app, is strictly prohibited. Our app monitors and records all screenshots and recordings. Violators will face strict legal action.

PEDO+ORTHO

SBQ 39

DEMINERALIZATION CASE

A LADY PATIENT CAME WITH THE CHIEF COMPLAINT OF WHITE DISCOLORATION IN HER FRONT TEETH. PATIENT HAD ORTHO TREATMENT IN THE PAST. THEY HAVE MENTIONED THAT ON BITEWING RADIOGRAPHS INTERPROXIMAL CARIES WERE EXTENDING INTO ENAMEL. SHE DRINKS A LOT OF COCA COLA. (HISTORY VARIATION - THE ORTHODONTIST TOOK OUT HER BRACES BECAUSE SHE DID NOT MAINTAIN GOOD ORAL HYGIENE)



I. What other investigation will help you for the diagnosis?

- A. Caries detecting dyes
- B. Caries risk assessment
- C. Caries detection using Briault probe

II. Which factor led to this situation?

- A. Plaque retention
- B. Ortho treatment
- C. Sugar/sugary drinks

III. How will you monitor these lesions in terms of the patient's chief complaint?

- A. 3 monthly bitewing review
- B. Topical fluoride application
- C. Do a 3 monthly review

THIS IS COPYRIGHTED CONTENT. Unauthorized use, including screenshots, copying, misuse, reuse, or resale of any content from this app, is strictly prohibited. Our app monitors and records all screenshots and recordings. Violators will face strict legal action.

DISCLAIMER

THIS IS COPYRIGHTED CONTENT. Unauthorized use, including screenshots, copying, misuse, reuse, or resale of any content from this app, is strictly prohibited. Our app monitors and records all screenshots and recordings. Violators will face strict legal action.

DISCLAIMER
THIS IS COPYRIGHTED CONTENT. Unauthorized use, including screenshots, copying, misuse, reuse, or resale of any content from this app, is strictly prohibited. Our app monitors and records all screenshots and recordings. Violators will face strict legal action.

THIS IS COPYRIGHTED CONTENT. Unauthorized use, including screenshots, copying, misuse, reuse, or resale of any content from this app, is strictly prohibited. Our app monitors and records all screenshots and recordings. Violators will face strict legal action.

DISCLAIMER

PEDO+ORTHO

P.O.W.E.R NOTES SBQ 39

- I. Even with the history of ortho Rx, if the patient has interproximal caries according to the bitewing, caries is the diagnosis. Orthodontic demineralisation doesn't involve the interproximal area. Bitewing shows the interproximal extension. And, patient has risk factors of cola intake and poor OH.

Caries detecting die is useful in extended carious lesion to see the extension of the cavity. Superficial, incipient, active caries to arrested, inactive caries can be differentiated with a blunt probe.

"Briault" probe is a sharp probe. If it was blunt probe (C) would be the best answer.

- II. Plaque retention and sugar intake both are important risk factors. Based on the given history you must select one of these. If both sugar and plaque are mentioned, then you will choose plaque. If both are present in the absence of poor OH, then you will choose sugar intake.

- III. In high caries risk we get bitewings in every 6months and review the patient every 3 months time.

THIS IS COPYRIGHTED CONTENT. Unauthorized use, including screenshots, copying, misuse, reuse, or resale of any content from this app, is strictly prohibited. Our app monitors and records all screenshots and recordings. Violators will face strict legal action.

DISCLAIMER

THIS IS COPYRIGHTED CONTENT. Unauthorized use, including screenshots, copying, misuse, reuse, or resale of any content from this app, is strictly prohibited. Our app monitors and records all screenshots and recordings. Violators will face strict legal action.

DISCLAIMER
THIS IS COPYRIGHTED CONTENT. Unauthorized use, including screenshots, copying, misuse, reuse, or resale of any content from this app, is strictly prohibited. Our app monitors and records all screenshots and recordings. Violators will face strict legal action.

DISCLAIMER

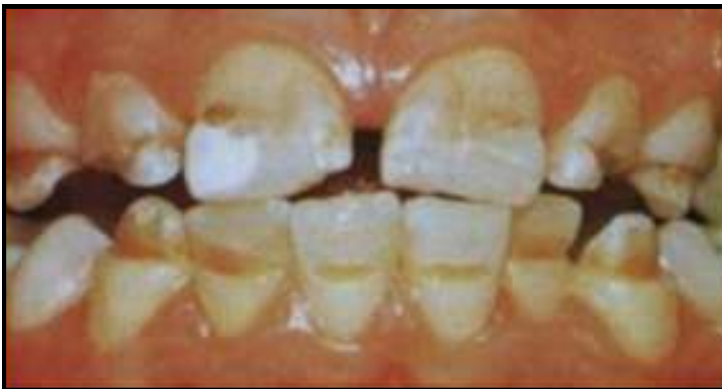THIS IS COPYRIGHTED CONTENT. Unauthorized use, including screenshots, copying, misuse, reuse, or resale of any content from this app, is strictly prohibited. Our app monitors and records all screenshots and recordings. Violators will face strict legal action.

PEDO+ORTHO

SBQ 40

ENAMEL HYPOMINERALIZATION

A 13 YEAR OLD PATIENT CAME BACK AFTER FEW YEARS TO YOU WITH HYPOPLASTIC SPOTS ON FRONT TEETH, IN THE PREVIOUS APPOINTMENT A FEW YEARS BACK AS A 5 YEAR OLD CHILD HE DIDN'T HAVE ANY SUCH LESIONS, EXCEPT FOR PREMOLARS ALL OTHER TEETH INCLUDING MOLARS HAD WHITE DISCOLORATION AND HYPOPLASTIC SPOTS. (HYPOMINERALISATION)



I. How will you restore or protect the molars from breakdown?

- A. SSC after tooth reduction
- B. Composite build up/restoration
- C. Gic restoration
- D. Resin modified GIC

II. What will be the treatment for anterior teeth?

- A. Porcelain veneer
 - B. Micro abrasion with fluoride application
 - C. Composite restoration
 - D. Bleaching
- (no composite veneer option was given)

THIS IS COPYRIGHTED CONTENT. Unauthorized use, including screenshots, copying, misuse, reuse, or resale of any content from this app, is strictly prohibited. Our app monitors and records all screenshots and recordings. Violators will face strict legal action.

DISCLAIMER

THIS IS COPYRIGHTED CONTENT. Unauthorized use, including screenshots, copying, misuse, reuse, or resale of any content from this app, is strictly prohibited. Our app monitors and records all screenshots and recordings. Violators will face strict legal action.

THIS IS COPYRIGHTED CONTENT. Unauthorized use, including screenshots, copying, misuse, reuse, or resale of any content from this app, is strictly prohibited. Our app monitors and records all screenshots and recordings. Violators will face strict legal action.

THIS IS COPYRIGHTED CONTENT. Unauthorized use, including screenshots, copying, misuse, reuse, or resale of any content from this app, is strictly prohibited. Our app monitors and records all screenshots and recordings. Violators will face strict legal action.

DISCLAIMER
THIS IS COPYRIGHTED CONTENT. Unauthorized use, including screenshots, copying, misuse, reuse, or resale of any content from this app, is strictly prohibited. Our app monitors and records all screenshots and recordings. Violators will face strict legal action.

THIS IS COPYRIGHTED CONTENT. Unauthorized use, including screenshots, copying, misuse, reuse, or resale of any content from this app, is strictly prohibited. Our app monitors and records all screenshots and recordings. Violators will face strict legal action.

DISCLAIMER

PEDO+ORTHO

P.O.W.E.R NOTES SBQ 40

In this case hypoplastic spots are to chronological / molar-incisor hypoplasia rather than amelogenesis imperfecta, because primary teeth were not involved.

- I. Ss-crown are done for the primary teeth not for the permanent. So, to protect the permanent molars we can do composite build-ups. PFM crowns are not indicated at the age of 13yrs. RMGIC doesn't have rigidity compared to composite to take up masticatory loads on molars.
- II. Bleaching is not helpful in hypoplastic spots. Porcelain veneers are not indicated in 13yrs old child as the gingival contours develop at the age of 18yrs. Micro abrasion with fluoride application will not be helpful in deep pits. Composite restoration is the best among the given.

TABLE 56.2 Possible Restorative Options for the Incisors

Technique	Advantages	Disadvantages
Full resin composite veneers	No destruction of tooth tissue, reversible and generally well tolerated even by anxious children. Excellent aesthetic result possible and easy to maintain.	Discolour with time. Tendency to fracture if placed at/over the incisal edge.
Enamel microabrasion	Minimal destruction of enamel, if carefully performed. Technique well tolerated.	Unpredictable. Teeth may rarely suffer postoperative sensitivity. Accidental exposure of dentine is possible where enamel is thin.
Localized resin composite restoration	Enamel destruction limited to defect, and full thickness need not be removed if opaque resin composite shades are used. Good aesthetic result possible.	Irreversible. Weakens tooth structure and large areas of dentine may be uncovered. Colour change and marginal discoloration with time.
Porcelain veneers	Good appearance.	Contraindicated in this age group because gingival contour not mature and stable tooth position not yet established.
Full-crown restoration	Good appearance.	Inappropriate until late second decade because immature pulp horns may be exposed. Gingival contour not mature and stable tooth position not yet established.

THIS IS COPYRIGHTED CONTENT. Unauthorized use, including screenshots, copying, misuse, reuse, or resale of any content from this app, is strictly prohibited. Our app monitors and records all screenshots and recordings. Violators will face strict legal action.

DISCLAIMER

THIS IS COPYRIGHTED CONTENT. Unauthorized use, including screenshots, copying, misuse, reuse, or resale of any content from this app, is strictly prohibited. Our app monitors and records all screenshots and recordings. Violators will face strict legal action.

DISCLAIMER
THIS IS COPYRIGHTED CONTENT. Unauthorized use, including screenshots, copying, misuse, reuse, or resale of any content from this app, is strictly prohibited. Our app monitors and records all screenshots and recordings. Violators will face strict legal action.

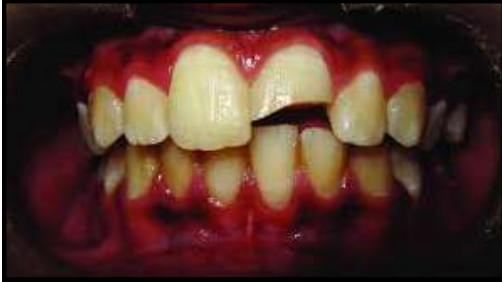recordings. Violators will face strict legal action.

PEDO+ORTHO

SBQ 41

TRAUMA CASE

THERE WAS A PICTURE OF A 14 YEAR OLD KID WITH A HISTORY OF TRAUMA, PATIENT HAS NO SYMPTOMS PICTURE WAS GIVEN.



I. What treatment will you do in this case?

- A. Dpc with calcium hydroxide
- B. Partial pulpotomy, calcium hydroxide, restore later
- C. Pulpectomy
- D. Partial pulpotomy with non setting MTA

II. Kid had fractured the tooth 3 days ago, parents kept the fragment in milk, what is the best way to restore the tooth:

Another variation - it was written that the fragment was incomplete

- A. Bond the fragment with composite
- B. RMGIC
- C. Porcelain veneer
- D. Composite filling

III. You took the iopa, what will be the best treatment plan for this tooth?

- A. Root canal therapy with permanent filling
- B. Root canal therapy with post and core
- C. Root canal therapy
- D. Apexification
- E. Coronal restoration

IV. What will be the next radiograph you'll take?

- A. Take iopa centering 13
- B. Take iopa centering 23
- C. Take iopa centering 31,41
- D. Take another iopa with different angle

THIS IS COPYRIGHTED CONTENT. Unauthorized use, including screenshots, copying, misuse, reuse, or resale of any content from this app, is strictly prohibited. Our app monitors and records all screenshots and recordings. Violators will face strict legal action.

DISCLAIMER
THIS IS COPYRIGHTED CONTENT. Unauthorized use, including screenshots, copying, misuse, reuse, or resale of any content from this app, is strictly prohibited. Our app monitors and records all screenshots and recordings. Violators will face strict legal action.

DISCLAIMER

THIS IS COPYRIGHTED CONTENT. Unauthorized use, including screenshots, copying, misuse, reuse, or resale of any content from this app, is strictly prohibited. Our app monitors and records all screenshots and recordings. Violators will face strict legal action.

PEDO+ORTHO

P.O.W.E.R NOTES SBQ 41

- I. It's a 14yr old patient's matured tooth with a complicated crown fracture. Conservative pulp treatment (partial pulpotomy) is the preferred treatment. **Non setting calcium hydroxide or non-staining MTA** are the suitable materials. Option (D) is incorrect because of the "non setting" word. There's no "non setting MTA" but there's non staining MTA. Non staining MTA is an absolute mandate in anterior. Otherwise it can cause tooth staining and much more treatment will be required later.

Therefore, the next best answer is option (B) partial pulpotomy with calcium hydroxide.

REFERENCE:

Treatment	
<ul style="list-style-type: none"> In patients where teeth have immature roots and open apices, it is very important to preserve the pulp. Partial pulpotomy or pulp capping are recommended in order to promote further root development Conservative pulp treatment (eg, partial pulpotomy) is also the preferred treatment in teeth with completed root development 	<ul style="list-style-type: none"> Non-setting calcium hydroxide or non-staining calcium silicate cements are suitable materials to be placed on the pulp wound If a post is required for crown retention in a mature tooth with complete root formation, root canal treatment is the preferred treatment

- II. When you have the tooth fragment, the best treatment is to bond the fragment with composite. But fragment should be completely intact. If it's an incomplete fragment, better not to bond the fragment to the tooth and instead better to do the composite build up.

REFERENCE:

- If the tooth fragment is available, it can be bonded back on to the tooth after rehydration and the exposed pulp is treated
- In the absence of an intact crown fragment for bonding, cover the exposed dentin with glass-ionomer or use a bonding agent and composite resin

DISCLAIMER

THIS IS COPYRIGHTED CONTENT. Unauthorized use, including screenshots, copying, misuse, reuse, or resale of any content from this app, is strictly prohibited. Our app monitors and records all screenshots and recordings. Violators will face strict legal action.

DISCLAIMER

THIS IS COPYRIGHTED CONTENT. Unauthorized use, including screenshots, copying, misuse, reuse, or resale of any content from this app, is strictly prohibited. Our app monitors and records all screenshots and recordings. Violators will face strict legal action.

THIS IS COPYRIGHTED CONTENT. Unauthorized use, including screenshots, copying, misuse, reuse, or resale of any content from this app, is strictly prohibited. Our app monitors and records all screenshots and recordings. Violators will face strict legal action.

DISCLAIMER

PEDO+ORTHO

P.O.W.E.R NOTES SBQ 41

III. This is a mature tooth with partial pulpotomy, so only a coronal restoration is required in the next visit. No RCT is required.

IV. There's no point of taking an IOP centring the canine. It's an incorrect view and unnecessary exposure. So, options (A) and (B) are incorrect. IOPA with another angulation is not required in crown fractures. It's required in horizontal root fractures, subluxation, crown-root fracture, alveolar fractures. Complicated crown fracture requires only one IOPA of that tooth. Additional radiographs are indicated if signs or symptoms of other potential injuries are present. Such as when there's an injury to the maxillary tooth, there's a potential for the mandibular tooth to get injured. So, option (D) is ruled out.

REFERENCE:

- Recommended radiographs:
 - One parallel periapical radiograph
 - Additional radiographs are indicated if signs or symptoms of other potential injuries are present

REFERENCE:

Since maxillary central incisors are the most frequently affected teeth, the radiographs listed below are recommended to thoroughly examine the injured area:

- One parallel periapical radiograph aimed through the midline to show the two maxillary central incisors.
- One parallel periapical radiograph aimed at the maxillary right lateral incisors (should also show the right canine and central incisor).
- One parallel periapical radiograph aimed at the maxillary left lateral incisor (should also show the left canine and central incisor).
- One maxillary occlusal radiograph.
- **At least one parallel periapical radiograph of the lower incisors centred on the two mandibular centrals.**

DISCLAIMER

THIS IS COPYRIGHTED CONTENT. Unauthorized use, including screenshots, copying, misuse, reuse, or resale of any content from this app, is strictly prohibited. Our app monitors and records all screenshots and recordings. Violators will face strict legal action.

THIS IS COPYRIGHTED CONTENT. Unauthorized use, including screenshots, copying, misuse, reuse, or resale of any content from this app, is strictly prohibited. Our app monitors and records all screenshots and recordings. Violators will face strict legal action.

DISCLAIMER
THIS IS COPYRIGHTED CONTENT. Unauthorized use, including screenshots, copying, misuse, reuse, or resale of any content from this app, is strictly prohibited. Our app monitors and records all screenshots and recordings. Violators will face strict legal action.

PEDO+ORTHO

SBQ 42

LATERAL CEPHALOGRAM

A PATIENT HAD PRESENTED TO THE CLINIC WITH HIS MOTHER. THE LATERAL CEPH AND OPG IMAGES WERE GIVEN.

I. What is the age of the patient according to opg?

- A. 6-7 years
- B. 8-9 years
- C. 9-11 years
- D. 12-14 years

II. Which are the missing teeth in the opg? (all opg's in different centers were different)

- A. All 1st premolars
- B. All 2nd premolars
- C. All 1st molars
- D. All 3rd molars

III. What is the skeletal relationship of maxilla and mandible in the lateral Cephalogram?

- A. Class I
- B. Class II div1
- C. Class II div2
- D. Class III
- E. Cannot be predicted

P.O.W.E.R NOTES SBQ 42

- This question requires OPG and LATERAL CEPHALOGRAM to answer.

THIS IS COPYRIGHTED CONTENT. Unauthorized use, including screenshots, copying, misuse, reuse, or resale of any content from this app, is strictly prohibited. Our app monitors and records all screenshots and recordings. Violators will face strict legal action.

DISCLAIMER

THIS IS COPYRIGHTED CONTENT. Unauthorized use, including screenshots, copying, misuse, reuse, or resale of any content from this app, is strictly prohibited. Our app monitors and records all screenshots and recordings. Violators will face strict legal action.

THIS IS COPYRIGHTED CONTENT. Unauthorized use, including screenshots, copying, misuse, reuse, or resale of any content from this app, is strictly prohibited. Our app monitors and records all screenshots and recordings. Violators will face strict legal action.

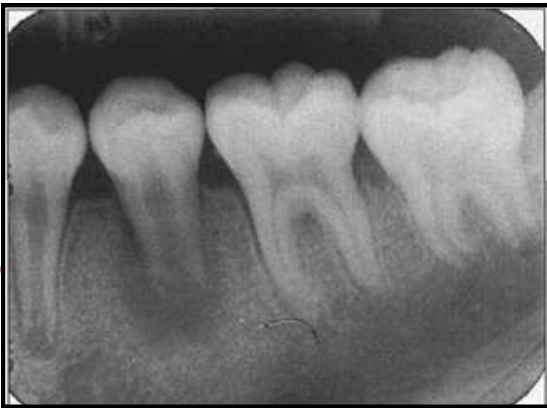DISCLAIMER
THIS IS COPYRIGHTED CONTENT. Unauthorized use, including screenshots, copying, misuse, reuse, or resale of any content from this app, is strictly prohibited. Our app monitors and records all screenshots and recordings. Violators will face strict legal action.

THIS IS COPYRIGHTED CONTENT. Unauthorized use, including screenshots, copying, misuse, reuse, or resale of any content from this app, is strictly prohibited. Our app monitors and records all screenshots and recordings. Violators will face strict legal action.

PEDO+ORTHO

SBQ 43

THE CHILD CAME WITH THE MOTHER FOR CHECK UP, THEY HAD A FLIGHT, YOU OBSERVED AN UNUSUAL FINDING WITH AN ERUPTED PREMOLAR. THE KID WAS 12 YEARS OLD AND THE APEX OF THE PREMOLAR WAS NOT FULLY FORMED (IMMATURE APEX). THERE WAS A PERIAPICAL RADIOLOGUCY AS WELL AS A RADIOLOGUCY ON THE INTERRADICULAR AREA ON BOTH SIDES OF THE TOOTH . BUT NO ASSOCIATED CARIES AND PULPAL SIGN. PUS COMING OUT FROM BUCCAL SINUS, THE CHILD SAYS NO HISTORY OF TRAUMA/ NO PRESENCE OF CARIES, IOPA SHOWS FLOATING PREMOLAR RADIOLOGUCY,



I. What is the most significant information that you will tell the mother regarding management.

- A. The presence of radiolucency in a healthy tooth like this is could be an underlying medical condition.
- B. Debridement of pulp and fill with mta
- C. Pulpotomy
- D. Debridement and dressing with calcium hydroxide.

II. Patient was going overseas for like two days so wanted extraction and with communication with parents they agreed for conservative treatment. So what will you do now?

- A. Debride pulp and close apex with mta application
- B. Debride pulp and fill
- C. Debride pulp and place caoh (apex was open)
- D. Pulpotomy

III. After treatment on patient recall you found the root closure was successful. what will you do now?

- A. Put corticosteroids and Refer to endodontist
- B. Wait till he turns 18 and then obturate
- C. You will obturate now

DISCLAIMER

THIS IS COPYRIGHTED CONTENT. Unauthorized use, including screenshots, copying, misuse, reuse, or resale of any content from this app, is strictly prohibited. Our app monitors and records all screenshots and recordings. Violators will face strict legal action.

DISCLAIMER

THIS IS COPYRIGHTED CONTENT. Unauthorized use, including screenshots, copying, misuse, reuse, or resale of any content from this app, is strictly prohibited. Our app monitors and records all screenshots and recordings. Violators will face strict legal action.

THIS IS COPYRIGHTED CONTENT. Unauthorized use, including screenshots, copying, misuse, reuse, or resale of any content from this app, is strictly prohibited. Our app monitors and records all screenshots and recordings. Violators will face strict legal action.

DISCLAIMER

PEDO+ORTHO

P.O.W.E.R NOTES SBQ 43

Radiographic features:

- Immature apex
- Periapical radiolucency
- Radiolucency in the interradicular area on both the sides of the tooth

Clinical feature:

- No caries
- No pulpal sign
- Pus coming out from the buccal sinus

Floating tooth with surrounding radiolucency in the absence of local factors mimic **Langerhans cell histiocytosis (LCH)** which is a form of eosinophilic granuloma.

The radiographic appearance of the lesions showed a radiolucent, destructive, often well defined process, with sometimes irregular margins (Fig. 2). They varied in size, and occasionally the loss of bone was so severe, with perforation of the cortical bone, that the teeth appeared to be 'floating in air'.

Tooth has lost it's all supporting structures. No history of trauma. It looks like an endo-perio lesion but there's no aetiology for endo and perio according to the given history. **Langerhans cell histiocytosis (LCH)** can be either unifocal or multifocal. It can mimic aggressive periodontitis.

The radiographic features are non-specific and may resemble, amongst others, odontogenic cysts, periapical lesions, periodontal disease, osteomyelitis or even malignant neoplasms. Can confirm the diagnosis with a histological examination (e.g. biopsy)

Awareness of oral manifestation of LCH may aid clinicians greatly in reducing morbidity and mortality associated with this debilitating condition. Early diagnosis helps in preventing spread to the organs.

Early diagnosis and effective treatment of LCH have been documented to not only prevent the progression of disease but also avoid further complications including orthopaedic disabilities, hearing impairment, diabetes insipidus, skin scarring, and neuropsychological defects, chronic pulmonary dysfunction, liver cirrhosis, secondary malignancies such as acute lymphoblastic leukemia or solid tumors, and growth retardation [18–23].

THIS IS COPYRIGHTED CONTENT. Unauthorized use, including screenshots, copying, misuse, reuse, or resale of any content from this app, is strictly prohibited. Our app monitors and records all screenshots and recordings. Violators will face strict legal action.

DISCLAIMER
THIS IS COPYRIGHTED CONTENT. Unauthorized use, including screenshots, copying, misuse, reuse, or resale of any content from this app, is strictly prohibited. Our app monitors and records all screenshots and recordings. Violators will face strict legal action.

DISCLAIMER

THIS IS COPYRIGHTED CONTENT. Unauthorized use, including screenshots, copying, misuse, reuse, or resale of any content from this app, is strictly prohibited. Our app monitors and records all screenshots and recordings. Violators will face strict legal action.

DISCLAIMER

THIS IS COPYRIGHTED CONTENT. Unauthorized use, including screenshots, copying, misuse, reuse, or resale of any content from this app, is strictly prohibited. Our app monitors and records all screenshots and recordings. Violators will face strict legal action.

PEDO+ORTHO

P.O.W.E.R NOTES SBQ 43

Treatment: multidisciplinary approach is required.

- Unifocal- curettage is enough.
- Multifocal – surgical excision, chemotherapy, radiotherapy or combination of these modalities.

Although unifocal (solitary) lesions of LCH successfully respond to curettage, the possibility of recurrences or new lesions still remains which makes a long-term follow-up necessary.

- According to the above given information, these clinical features suggestive of an underlying medical condition (e.g. Langerhans cell histiocytosis (LCH)). Therefore, the answer is option (A)
- Cannot proceed with extraction without doing a biopsy and confirming the diagnosis in this case. So, as the conservative management pulp debridement with closing the apex with MTA or calcium hydroxide is done. When both MTA and calcium hydroxide are given, MTA is chosen as it's superior. In option (C) it's mentioned calcium hydroxide was placed with an opened apex which means it must have used as an intercanal medicament and not as a barrier. In question (III) confirms the answer is option (A) for the above question (II) by mentioning "**root closure was successful**".
- This tooth requires further investigation (e.g. biopsy) to confirm the diagnosis so, cannot complete the treatment as in a normal tooth. Therefore, it requires specialist referral.

The radiographic features are non-specific and may resemble, amongst others, odontogenic cysts, periapical lesions, periodontal disease, osteomyelitis or even malignant neoplasms. Tissue for histologic examination should be obtained of an oral lesion suggestive of LCH. If it is possible, some unfixed issue should be sent rapidly to the pathologist. Such

CONTENT. Unauthorized use, including screenshots, copying, misuse, reuse, or resale of any content from this app, is strictly prohibited. Our app monitors and records all screenshots and recordings. Violators will face strict legal action.

DISCLAIMER

THIS IS COPYRIGHTED CONTENT. Unauthorized use, including screenshots, copying, misuse, reuse, or resale of any content from this app, is strictly prohibited. Our app monitors and records all screenshots and recordings. Violators will face strict legal action.

DISCLAIMER
THIS IS COPYRIGHTED CONTENT. Unauthorized use, including screenshots, copying, misuse, reuse, or resale of any content from this app, is strictly prohibited. Our app monitors and records all screenshots and recordings. Violators will face strict legal action.

THIS IS COPYRIGHTED CONTENT. Unauthorized use, including screenshots, copying, misuse, reuse, or resale of any content from this app, is strictly prohibited. Our app monitors and records all screenshots and recordings. Violators will face strict legal action.

DISCLAIMER

PEDO+ORTHO

SBQ 44

RETAINED CANINE

I. 13 year old patient, 13 had erupted, 23 was missing, patient has retained 63, what will you do next?

- A. Take opg
- B. Refer to orthodontist
- C. Tell the mother it is ok, this is normal tooth will erupt normally
- D. Take cbct

II. Opg was given root was dilacerated. How will you decide for the Impacted canine whether it should go for extraction or ortho extrusion.

- A. Severity of dilaceration
- B. Space present
- C. Direction of the impacted tooth

III. What will be the complications if the tooth was not extracted?

- A. Root resorption of adjacent tooth
- B. Cyst formation

P.O.W.E.R NOTES SBQ 44

- I. Clinical examination is done. But to provide a provisional diagnosis, investigations should be done. As the baseline OPG is needed. CBCT is done after performing the basic radiographs.
Whether to refer to the orthodontist or to tell the mother that the tooth will erupt normally, first we must know the provisional diagnosis. For that we must know the radiographic diagnosis.
- II. Severity of dilaceration doesn't have an effect because if it's in straight line. Dilacerated teeth will not erupt on its own and require orthodontic correction. Whether it can be corrected by orthodontic treatment or whether it require surgical removal can be decided by the direction of the impaction. The space for eruption can be created orthodontically if the direction is correct.
- III. If the tooth is impacted it might be associated with a dentigerous cyst, that's why taking a radiograph is important to rule it out. If you have already taken a radiograph and if it's showing that there is no cyst and if you are not referring the patient to the specialist, the chances of formation of new cysts is very low and the chances of root resorption of the adjacent teeth is very high.

REFERENCE

It's imperative that the patient is referred to an orthodontist for assessment and management of a suspected PEMPC (palatally ectopic maxillary permanent canines). Late referrals can involve longer and more complicated treatment and might result in further root resorption.

DISCLAIMER

THIS IS COPYRIGHTED CONTENT. Unauthorized use, including screenshots, copying, misuse, reuse, or resale of any content from this app, is strictly prohibited. Our app monitors and records all screenshots and recordings. Violators will face strict legal action.

DISCLAIMER
THIS IS COPYRIGHTED CONTENT. Unauthorized use, including screenshots, copying, misuse, reuse, or resale of any content from this app, is strictly prohibited. Our app monitors and records all screenshots and recordings. Violators will face strict legal action.

PEDO+ORTHO

SBQ 45

Child consuming cariogenic food. Which is the most cariogenic among given options, patient is allergic to milk, sesame and tree nuts

- A. Rice milk four times
- B. Fruit juice four times
- C. Fresh fruit 4 times
- D. Popcorn
- E. Twice a day breadsticks

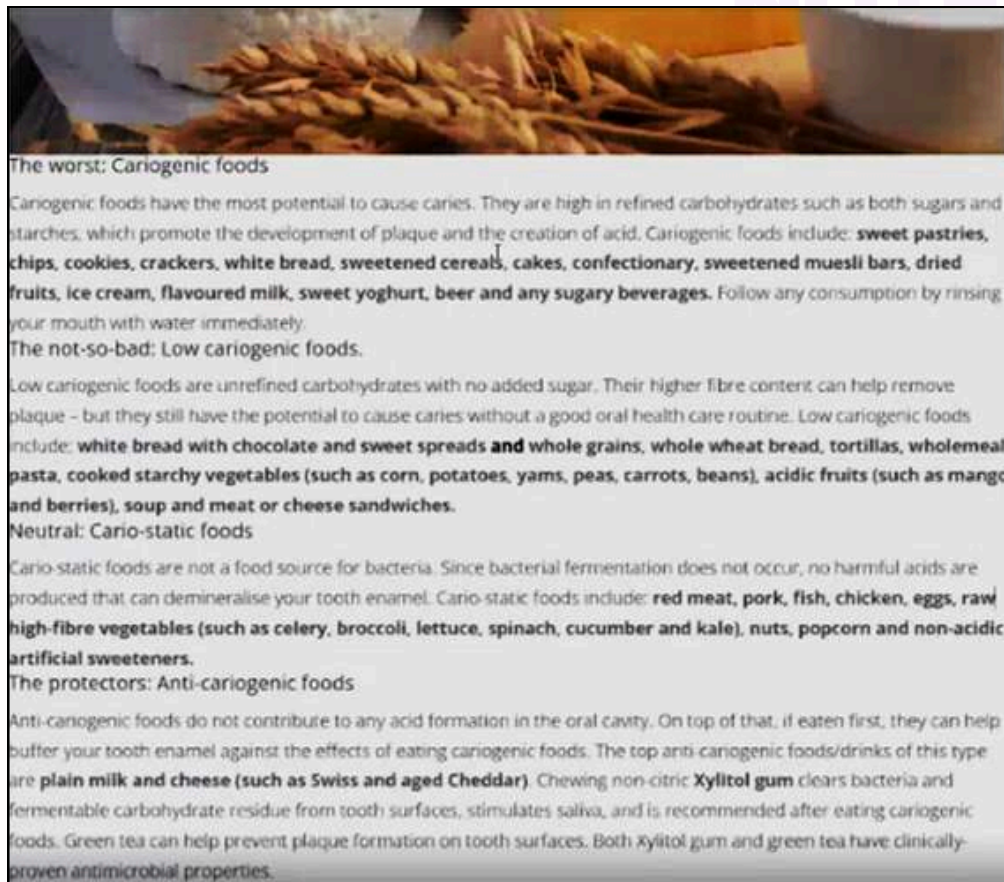
P.O.W.E.R NOTES SBQ 45

- Amongst the given fruit juice is most cariogenic as it contains both sugar and lower PH.

Reference Article: Sugars-rich Diet and Oral Health: Information for Dental Practitioners

Find it in Operative Subject-wise Article Folder

REFERENCE:



recordings. Violators will face strict legal action.

DISCLAIMER

THIS IS COPYRIGHTED CONTENT. Unauthorized use, including screenshots, copying, misuse, reuse, or resale of any content from this app, is strictly prohibited. Our app monitors and records all screenshots and recordings. Violators will face strict legal action.

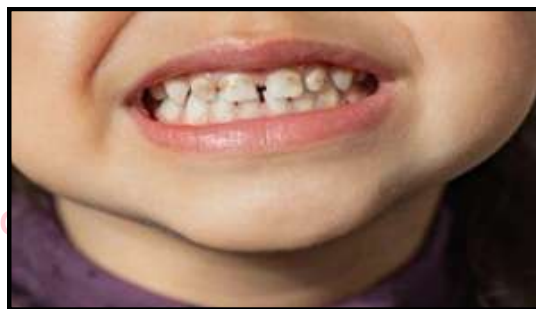DISCLAIMER
THIS IS COPYRIGHTED CONTENT. Unauthorized use, including screenshots, copying, misuse, reuse, or resale of any content from this app, is strictly prohibited. Our app monitors and records all screenshots and recordings. Violators will face strict legal action.

PEDO+ORTHO

SBQ 46

PEDO ANTERIOR CARIES

I. Picture of brown spot arrested caries on 51 61 on a 4 year old girl. What is the lesion



- A. Arrested caries
- B. Hypomineralization
- C. Chronological hypoplasia

II. How do you prevent this

- A. Fluoride varnish
- B. Fluoride gel
- C. Cpp-acp

III. You can see plaque on teeth what do you advise mom?

- A. To supervise him while brushing
- B. To give her a child strength toothpaste

IV. Which toothpaste will you advise the patient

- A. More frequent child toothpaste
- B. 5000 ppm toothpaste
- C. 900 ppm mouthwash daily

THIS IS COPYRIGHTED CONTENT. Unauthorized use, including screenshots, copying, misuse, reuse, or resale of any content from this app, is strictly prohibited. Our app monitors and records all screenshots and recordings. Violators will face strict legal action.

DISCLAIMER
THIS IS COPYRIGHTED CONTENT. Unauthorized use, including screenshots, copying, misuse, reuse, or resale of any content from this app, is strictly prohibited. Our app monitors and records all screenshots and recordings. Violators will face strict legal action.

THIS IS COPYRIGHTED CONTENT. Unauthorized use, including screenshots, copying, misuse, reuse, or resale of any content from this app, is strictly prohibited. Our app monitors and records all screenshots and recordings. Violators will face strict legal action.

DISCLAIMER

THIS IS COPYRIGHTED CONTENT. Unauthorized use, including screenshots, copying, misuse, reuse, or resale of any content from this app, is strictly prohibited. Our app monitors and records all screenshots and recordings. Violators will face strict legal action.

PEDO+ORTHO

P.O.W.E.R NOTES SBQ 46

- I.
 - HYPOPLASIA- pitting surfaces with reduced thickness of the enamel
 - HYPOMINERALISATION- appears as white spots
 - ARRESTED CARIES- appears as brown spots
- II.
 - Fluoride gels are recommended after age of 10yrs.
 - Fluoride varnish is helpful in patients with high caries risk.
 - Among the given varnish is superior.
- III. Plaque on teeth is a feature of improper, inadequate oral hygiene maintenance. The child is still 4yrs old and adult supervision is required until the age of 8-10yrs.
- IV. Toothpaste for people at elevated risk of dental caries:
Children at 18months- younger than 6yrs old = 1000ppm twice daily or 500-550ppm more frequently.

REFERENCE:

Toothpaste for people <u>not</u> at elevated risk of dental caries	
child younger than 18 months	twice-daily brushing without toothpaste
child 18 months to younger than 6 years	500 to 550 ppm (0.5 to 0.55 mg/g) fluoride twice daily, pea-sized amount [NB2]
child 6 years to adolescent	1000 to 1500 ppm (1 to 1.5 mg/g) fluoride twice daily
adolescent or adult	1000 to 1500 ppm (1 to 1.5 mg/g) fluoride twice daily
Toothpaste for people at elevated risk of dental caries [NB3]	
child younger than 18 months	twice-daily brushing with toothpaste may be recommended [NB2]
child 18 months to younger than 6 years	1000 ppm (1 mg/g) fluoride twice daily [NB2] OR more frequent use of 500 to 550 ppm (0.5 to 0.55 mg/g) fluoride [NB2]
child 6 years to adolescent	more frequent use of 1000 to 1500 ppm (1 to 1.5 mg/g) fluoride [NB2]
adolescent or adult	5000 ppm (5 mg/g) fluoride twice daily OR more frequent use of 1000 to 1500 ppm (1 to 1.5 mg/g) fluoride [NB2]

THIS IS COPYRIGHTED CONTENT. Unauthorized use, including screenshots, copying, misuse, reuse, or resale of any content from this app, is strictly prohibited. Our app monitors and records all screenshots and recordings. Violators will face strict legal action.

DISCLAIMER

THIS IS COPYRIGHTED CONTENT. Unauthorized use, including screenshots, copying, misuse, reuse, or resale of any content from this app, is strictly prohibited. Our app monitors and records all screenshots and recordings. Violators will face strict legal action.

DISCLAIMER
THIS IS COPYRIGHTED CONTENT. Unauthorized use, including screenshots, copying, misuse, reuse, or resale of any content from this app, is strictly prohibited. Our app monitors and records all screenshots and recordings. Violators will face strict legal action.

DISCLAIMER

THIS IS COPYRIGHTED CONTENT. Unauthorized use, including screenshots, copying, misuse, reuse, or resale of any content from this app, is strictly prohibited. Our app monitors and records all screenshots and recordings. Violators will face strict legal action.

PEDO+ORTHO

SBQ 47

HEALTH PROMOTION

YOUR FRIEND WHO IS A TEACHER IN A SCHOOL HAS ASKED YOU TO GIVE PRESENTATION ON ORAL HYGIENE FOR THIRD GRADERS. SHE SAYS HER STUDENTS HAVE POOR ORAL HYGIENE?

I. What topic will you choose?

- A. Teaching brushing techniques
- B. Telling importance of not consuming sugar
- C. Telling them to brush twice daily
- D. Telling them to brush twice daily with fluoride toothpaste.

II. A question on how you will conduct your presentation.

- A. Interacting with them and explaining them with the help of a model.
- B. Distribute toothbrush and toothpaste
- C. Distribute pamphlets

III. How do you assess the presentation was successful or that kids understood the presentation?

- A. Give a written questionnaire for parents to answer
- B. Feedback from teachers
- C. Ask the students to demonstrate what they have learnt
- D. Reassess by holding another presentation second time with the same children
- E. Do a clinical examination on the children

IV. A kid comes to you and opens her mouth and asks you to look at a problem regarding her teeth?

- A. You take consent from parents before checking her
- B. Ask the teacher to inform the issue to the parents
- C. Checking her now and asking the kid to visit your clinic with the parents.

V. The teacher's daughter has crowded teeth. She 's 12 year old crowding was seen in upper and lower arches .What is the pathway of referral for initial screening ?

- A. General dentist
- B. Orthodontist
- C. Endodontist
- D. Dental hygienist

DISCLAIMER

THIS IS COPYRIGHTED CONTENT. Unauthorized use, including screenshots, copying, misuse, reuse, or resale of any content from this app, is strictly prohibited. Our app monitors and records all screenshots and recordings. Violators will face strict legal action.

DISCLAIMER
THIS IS COPYRIGHTED CONTENT. Unauthorized use, including screenshots, copying, misuse, reuse, or resale of any content from this app, is strictly prohibited. Our app monitors and records all screenshots and recordings. Violators will face strict legal action.

THIS IS COPYRIGHTED CONTENT. Unauthorized use, including screenshots, copying, misuse, reuse, or resale of any content from this app, is strictly prohibited. Our app monitors and records all screenshots and recordings. Violators will face strict legal action.

DISCLAIMER

PEDO+ORTHO

P.O.W.E.R NOTES SBQ 47

- I. Option (B) and (D) can be easily rule out because you need to do the presentation on oral hygiene and not about dental caries.

These kids have poor oral hygiene as are not even brushing correctly.

REFERENCE:

A number of studies have shown successful reduction in caries through school-based tooth brushing (TB) programme.

The participating schools receive a start up TB lesson for teachers and students at the beginning of every year conducted by oral health staff.

The lesson includes detailed instruction on TB techniques and rules of the programme.

- II. The TB technique can be presented if we are interacting with the kids and explaining them with the help of the model.

- III. Immediately after the presentation option (C) is a good way to get to know whether the presentation is successful or not. Later on, you can receive the feedback from the teachers.

- IV. Clinical examination can't be done without the parent/legal guardian consent.

- V. Pathway of referral:

PRIMARY DENTAL CARE



SPECIALIST CARE

THIS IS COPYRIGHTED CONTENT. Unauthorized use, including screenshots, copying, misuse, reuse, or resale of any content from this app, is strictly prohibited. Our app monitors and records all screenshots and recordings. Violators will face strict legal action.

DISCLAIMER

THIS IS COPYRIGHTED CONTENT. Unauthorized use, including screenshots, copying, misuse, reuse, or resale of any content from this app, is strictly prohibited. Our app monitors and records all screenshots and recordings. Violators will face strict legal action.

THIS IS COPYRIGHTED CONTENT. Unauthorized use, including screenshots, copying, misuse, reuse, or resale of any content from this app, is strictly prohibited. Our app monitors and records all screenshots and recordings. Violators will face strict legal action.

THIS IS COPYRIGHTED CONTENT. Unauthorized use, including screenshots, copying, misuse, reuse, or resale of any content from this app, is strictly prohibited. Our app monitors and records all screenshots and recordings. Violators will face strict legal action.

DISCLAIMER
THIS IS COPYRIGHTED CONTENT. Unauthorized use, including screenshots, copying, misuse, reuse, or resale of any content from this app, is strictly prohibited. Our app monitors and records all screenshots and recordings. Violators will face strict legal action.

DISCLAIMER

THIS IS COPYRIGHTED CONTENT. Unauthorized use, including screenshots, copying, misuse, reuse, or resale of any content from this app, is strictly prohibited. Our app monitors and records all screenshots and recordings. Violators will face strict legal action.