



WINSPERT

ENDODONTICS

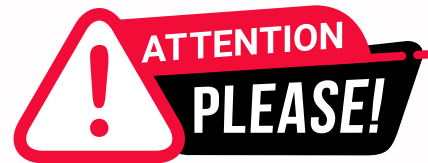H.O.T

HIGH-PRIORITY ORGANISED THEORY

NOTES

By Dr. Jigyasa Sharma





Dear Students,

We'd like to remind you about the importance of respecting the integrity of the resources provided in our app.

Please be aware that **WINSPERT HOT NOTES ARE COPYRIGHTED CONTENT. Unauthorized use, including screenshots, copying, misuse, reuse, or resale of any content from this app, is strictly prohibited.**

Our app monitors and records all screenshots and recordings. Violators will face strict legal action.

We're committed to providing you with the best tools for your success, and we appreciate your cooperation in maintaining a fair and secure learning environment.

Thank you for your understanding and continued dedication.

Best regards,
WINSPERT TEAM

ENDODONTICS

H.O.T TOPICS

- 1. Vertical root fracture. Pre-existing cracks in roots**
- 2. Pulp, disease and classification**
- 3. Investigations in endodontics, and neural pulp physiology**
- 4. Medical legal considerations in endodontics**
- 5. Endodontic guidelines in non-surgical treatments**
- 6. Endodontic emergencies**
- 7. Endodontic, restorations, and posts**
- 8. Endodontic failure**
- 9. Combined lesions**
- 10. Internal bleaching**
- 11. Surgical endodontics**

VERTICAL ROOT FRACTURE PRE-EXISTING CRACKS IN ROOTS

VERTICAL ROOT FRACTURES (VRF):

Source- Articles

- Vertical root fracture is the longitudinal (axial) fracture involving cementum, dentine and root canal system of a root.
- Based on International Endodontic journal VRF can be classified into:
 - a) **Incomplete**: If fracture only involves one side of root.
 - b) **Complete**: If fracture extends from one proximal aspect to opposite side of the root.
 - c) **Split tooth**: A VRF where there is visible separation of two components.

TEETH AND SURFACES AFFECTED

- VRF is **most frequently** seen in **Root canal filled** teeth. However, it can also occur in teeth with vital pulps.
- VRF usually has delayed presentation and can manifest between 2 and 5 years after RCT completion.
- Amongst the root canal filled teeth VRF is mostly associated with post treated tooth.
- Posterior teeth are significantly more likely to develop VRF than anterior teeth as they are subjected to higher Functional and Nonfunctional occlusal loading. Also parafunctional activity and non-working side interference also leads to excessive lateral forces on posterior teeth.
- A study revealed the tooth with greatest frequency of vertical root fracture is **maxillary second premolar** followed by **maxillary 1st premolar** and **mandibular first molar**.

59 years for both men and women (Table 1). The tooth type with the greatest frequency of vertical root fracture was the maxillary second premolar followed by the maxillary first premolar and mandibular first molar. The lowest frequency was in the mandibular central incisor and mandibular third molar followed by the mandibular lateral incisor and maxillary third molar (Table 2). Seven of the teeth were vital. 2 were

From the available evidence, it appears that maxillary (pre)-molar and mandibular molar teeth are most frequently affected by VRF (Cohen et al., 2006; Karygianni

Image: Source- Articles

- In anterior teeth (Maxillary Central incisors and canines): Fracture originated from cervical region more commonly than apical region.
- For other teeth: Cervical origin and apical origin fractures were at around same frequency.
- Fracture in mid region of tooth is rare.

DISCLAIMER

THIS IS COPYRIGHTED CONTENT. Unauthorized use, including screenshots, copying, misuse, reuse, or resale of any content from this app, is strictly prohibited. Our app monitors and records all screenshots and recordings. Violators will face strict legal action.

VERTICAL ROOT FRACTURE PRE-EXISTING CRACKS IN ROOTS

Etiology and Risk Factors of VRF:

- The quality and quantity of the residual sound tooth structure is critically linked with the fracture resistance of the root filled tooth.
- The teeth with Preexisting cracks are also more prone to fracture and VRF.
- The use of post in root filled teeth increases the risk of VRF significantly. Amongst the Post system used:
 - a) The post space preparation for use of cast posts results in undesirable removal of pericervical dentine which predisposes to VRF.
 - b) The use of screw post system is more prone for VRF as it generates unfavorable stress concentration at radicular dentine.
 - c) For this reason the use of pre-fabricated fiber post system (Passive) is preferred.
- The use of ultrasonic to remove post and fractured instrument from coronal and middle thirds of roots have increased risk of VRF and also initiating and propagating cracks.
- Flattened roots with narrow mesio-distal cross section like mesial root of mandibular molars and mesio buccal root of maxillary molar are more prone to fracture.
- During obturation with cold technique (lateral compaction) excessive force may be imparted to roots leading to VRF.

TABLE 1 Aetiological factors for VRF

Predisposing risks
<ul style="list-style-type: none"> • Structural integrity of the tooth • Presence of pre-existing cracks & fractures • Changes in biomechanical properties of dentine of root treated teeth • Anatomy and root canal morphology • Location of the tooth • Parafunction and/or unfavourable occlusal arrangement • Diet
Contributory risks
<ul style="list-style-type: none"> • Excessive removal of sound dentine during root canal treatment • Prolonged exposure to intracanal disinfectants and medicaments • Inappropriate execution of post-endodontic restoration

Image: Source- Articles

DISCLAIMER

THIS IS COPYRIGHTED CONTENT. Unauthorized use, including screenshots, copying, misuse, reuse, or resale of any content from this app, is strictly prohibited. Our app monitors and records all screenshots and recordings. Violators will face strict legal action.

DISCLAIMER
THIS IS COPYRIGHTED CONTENT. Unauthorized use, including screenshots, copying, misuse, reuse, or resale of any content from this app, is strictly prohibited. Our app monitors and records all screenshots and recordings. Violators will face strict legal action.

DISCLAIMER

THIS IS COPYRIGHTED CONTENT. Unauthorized use, including screenshots, copying, misuse, reuse, or resale of any content from this app, is strictly prohibited. Our app monitors and records all screenshots and recordings. Violators will face strict legal action.

VERTICAL ROOT FRACTURE PRE-EXISTING CRACKS IN ROOTS

Pathogenesis of VRF:

- Early stage of VRF is usually difficult to detect as no signs and symptoms may be seen.
- As the VRF progresses patient may present with signs and symptoms of apical periodontitis which includes:
 - a) Tenderness of percussion
 - b) Swelling
 - c) Tooth mobility
 - d) Evidence of marginal root fractures
 - e) Pain on biting
- When sinus tract is present in relation to VRF it is located mostly coronally (esp. mid root level or sometimes gingival margin level).
- Presence of multiple sinus tract is also a pathognomonic of VRF.

Radiographic presentation:

- Radiographic appearance of VRF varies from no obvious pathology to subtle periradicular bone loss to vertical bone defects to frank separation of root fragments.
- Radiographically Vertical bone defects includes classic J-shaped radiolucency or a halo radiolucency involving the furcation region.

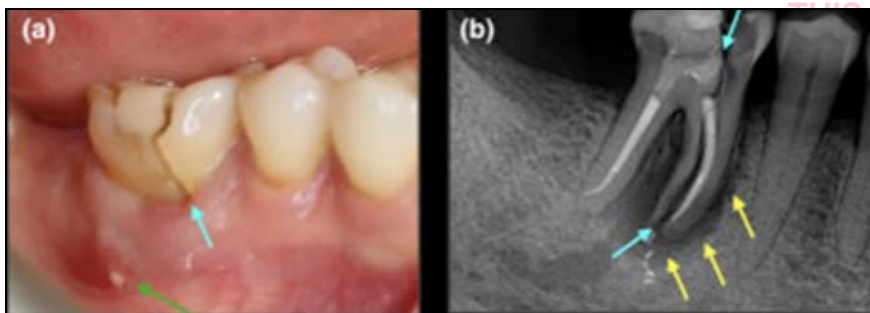


Fig: a) Visual separation of mesial aspect of tooth with small 2mm abscess (green arrow)
b) Visible separation of mesial root with periradicular radiolucency.

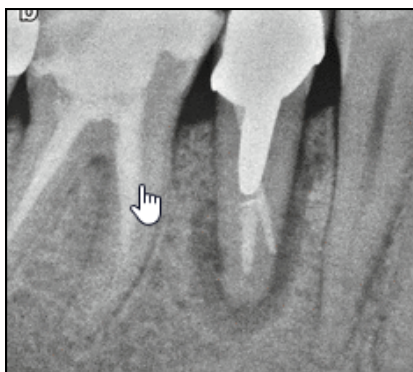


Fig: Classic J shaped radiolucency (source-Internet)

DISCLAIMER

THIS IS COPYRIGHTED CONTENT. Unauthorized use, including screenshots, copying, misuse, reuse, or resale of any content from this app, is strictly prohibited. Our app monitors and records all screenshots and recordings. Violators will face strict legal action.

DISCLAIMER
THIS IS COPYRIGHTED CONTENT. Unauthorized use, including screenshots, copying, misuse, reuse, or resale of any content from this app, is strictly prohibited. Our app monitors and records all screenshots and recordings. Violators will face strict legal action.

THIS IS COPYRIGHTED CONTENT. Unauthorized use, including screenshots, copying, misuse, reuse, or resale of any content from this app, is strictly prohibited. Our app monitors and records all screenshots and recordings. Violators will face strict legal action.

VERTICAL ROOT FRACTURE PRE-EXISTING CRACKS IN ROOTS

TABLE 2 Typical clinical and radiographic features of VRF

Clinical features of VRF
<ul style="list-style-type: none"> • +/- symptoms of apical periodontitis (e.g., tenderness to palpation and/or percussion, abscess etc.) • Direct visualization of a fracture • Isolated, narrow, deep periodontal pocket • Presence of a sinus/multiple sinuses • Mobility
Radiographic features of VRF
<p><i>Early stage VRF</i></p> <ul style="list-style-type: none"> • No obvious change +/- subtle crestal bone loss • Thickening of the periodontal ligament along axial root wall(s) <p><i>Advanced stage VRF</i></p> <ul style="list-style-type: none"> • J-shaped radiolucency • Halo radiolucency • (In)complete separation of root fragments

Image- Source-Article

Investigation:

- In suspected cases of VRF in endodontically treated teeth the presence of **deep narrow pocket depth of greater than 6mm** is pathognomonic sign. A narrow and flexible periodontal probe like UNC-15, PCP-12 or CLICK probe can be used for this purpose.
- **Visual detection of VRF:**
 - a) To detect a VRF, for visualization it is essential to use magnification and illumination which can be enhanced by using dye and fiber optic Trans illumination.
 - b) VRF (detection and extent) can sometimes be confirmed by removal of existing restoration and root filling materials where fracture line may be present along the pulpal floor extending down beyond canal entrances and involving the isthmus.
 - c) If VRF is not readily visualized it may be confirmed either by surgical exploration, or by careful examination of tooth after extraction with high magnification.
 - d) The surgical exploration is limited to buccal and when accessible palatal aspect of the root. (Mesial and distal aspect cannot be usually visualized with surgical exploration).
- Radiographic evaluation through Periapicals and CBCT can also be done where CBCT has more accuracy in detecting radiographic signs of periradicular bone loss indicative of VRF but not used routinely.

DISCLAIMER

THIS IS COPYRIGHTED CONTENT. Unauthorized use, including screenshots, copying, misuse, reuse, or resale of any content from this app, is strictly prohibited. Our app monitors and records all screenshots and recordings. Violators will face strict legal action.

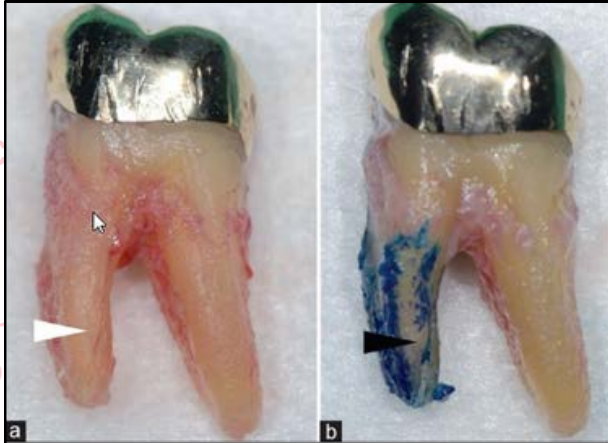
DISCLAIMER
THIS IS COPYRIGHTED CONTENT. Unauthorized use, including screenshots, copying, misuse, reuse, or resale of any content from this app, is strictly prohibited. Our app monitors and records all screenshots and recordings. Violators will face strict legal action.

THIS IS COPYRIGHTED CONTENT. Unauthorized use, including screenshots, copying, misuse, reuse, or resale of any content from this app, is strictly prohibited. Our app monitors and records all screenshots and recordings. Violators will face strict legal action.

DISCLAIMER

VERTICAL ROOT FRACTURE PRE-EXISTING CRACKS IN ROOTS

- Radiographic evaluation through Periapicals and CBCT can also be done where CBCT has more accuracy in detecting radiographic signs of periradicular bone loss indicative of VRF but not used routinely.
- CBCT can improve the diagnosis and management of complex endodontic problems.
- CBCT may be useful to diagnose radiographic feature of periradicular bone loss.



Clinical photographs of extracted tooth. (a) The extracted tooth showing a definite fracture line on the mesial root (white triangle). (b) The fracture line became more obvious after methylene blue staining (black triangle)

Image- Source-Article

Management:

- On a diagnosis of VRF, treatment is recommended as soon as possible to reduce the likelihood of various complications.
- The prognosis of tooth diagnosed with VRF is poor.
- In majority of cases Extraction is the choice of treatment.
- The aim of treatment of teeth with VRF which is restorable is to retain them in healthy functional state-Usually applicable for incomplete VRF only.
- In certain situations where retention of tooth is seemed demandable, root resection surgeries like root amputation or hemisection is an alternative option.

Objective of treatment:

- The objective is to eliminate the ingress of the microbes along the fracture line and prevent destruction of periodontium.

DISCLAIMER

THIS IS COPYRIGHTED CONTENT. Unauthorized use, including screenshots, copying, misuse, reuse, or resale of any content from this app, is strictly prohibited. Our app monitors and records all screenshots and recordings. Violators will face strict legal action.

DISCLAIMER

THIS IS COPYRIGHTED CONTENT. Unauthorized use, including screenshots, copying, misuse, reuse, or resale of any content from this app, is strictly prohibited. Our app monitors and records all screenshots and recordings. Violators will face strict legal action.

THIS IS COPYRIGHTED CONTENT. Unauthorized use, including screenshots, copying, misuse, reuse, or resale of any content from this app, is strictly prohibited. Our app monitors and records all screenshots and recordings. Violators will face strict legal action.

DISCLAIMER

VERTICAL ROOT FRACTURE PRE-EXISTING CRACKS IN ROOTS

Prevention of VRF:

- Comprehensive pre-operative assessment of teeth that requires endodontic treatment should be done including:
 - a) Factors affecting fracture resistance like residual tooth volume, number of remaining walls, pre-existing cracks and assessment of root canal morphology.
 - b) Assessment of the patients occlusion particularly any parafunctional habits like bruxism, interference to canine guidance should be done.(If diagnosed fabrication of occlusal splint and reestablishment of canine guidance should be done)
 - c) A pragmatic approach to access cavity and biomechanical preparation and obturation should be done to conserve sound tooth structure.
 - d) If post is required for retention of core posts should be passively cemented to root canals.

PRE-EXISTING CRACKS IN THE ROOT:

Source- Articles

- In a minimally restored or unrestored vital teeth preexisting cracks results in pulp infection and necrosis.
- The presence of preexisting cracks is a well-established predisposing etiological factor of VRF. If one crack is present in the root dentine repetitive occlusal loading can lead to propagation of the crack to VRF.
- The presence of preexisting crack is a negative prognostic factor in the outcome of endodontic therapy.
- The preexisting cracks in non-endodontically treated tooth which are incomplete are found to extend from root surface towards the root canal unlike VRF which originates from root canal wall.

All incomplete preexisting dentinal cracks observed in this study extended from the root surface toward the root canal. There were no incomplete cracks extending from the root canal wall toward the surface. This finding indicated that preexisting dentinal microcracks in nonendodontically treated teeth occurred at the root surface, which is contrary to the current understanding of VRFs in endodontically treated teeth, which frequently originated from the root canal wall

DISCLAIMER

THIS IS COPYRIGHTED CONTENT. Unauthorized use, including screenshots, copying, misuse, reuse, or resale of any content from this app, is strictly prohibited. Our app monitors and records all screenshots and recordings. Violators will face strict legal action.

DISCLAIMER
THIS IS COPYRIGHTED CONTENT. Unauthorized use, including screenshots, copying, misuse, reuse, or resale of any content from this app, is strictly prohibited. Our app monitors and records all screenshots and recordings. Violators will face strict legal action.

DISCLAIMER
THIS IS COPYRIGHTED CONTENT. Unauthorized use, including screenshots, copying, misuse, reuse, or resale of any content from this app, is strictly prohibited. Our app monitors and records all screenshots and recordings. Violators will face strict legal action.

VERTICAL ROOT FRACTURE PRE-EXISTING CRACKS IN ROOTS

Prevalence:

- Preexisting cracks are more common in older individuals (40-70 years) than younger individuals.
- More in mandibular teeth than in maxilla.
- Mostly occurs mesiodistally.

treated teeth. These preexisting dentinal microcracks were more common in the mandibular teeth of older patients (>40 years) and were typically found in the cervical and middle regions of root surface in the mesiodistal direction.

- Most commonly involved surface is:
 - a) Cervical and middle aspect of the root
 - b) Followed by cervical aspect alone
 - c) Then apical and middle third alone revealed least number of cracks.

17.8% of cracks were detected in the cervical region, 66.6% of cracks were in the cervical and middle aspect of the roots, 4.4% were present middle third of the root and 4.4% of cracks were located apically. Micro-CT images revealed

Image- Source-Article

Cause of preexisting crack:

- a) Restorative treatment
- b) Parafunctional habits
- c) Occlusal interferences
- d) Cumulative general wear
- e) After root canal preparation and filling

- Preexisting dentinal micro cracks are difficult to diagnose and treat.

THIS IS COPYRIGHTED
CONTENT. Unauthorized use,
including screenshots,
copying, misuse, reuse, or
resale of any content from
this app, is strictly prohibited.
Our app monitors and records
all screenshots and
recordings. Violators will face
strict legal action.

DISCLAIMER

THIS IS COPYRIGHTED CONTENT. Unauthorized use, including screenshots, copying, misuse, reuse, or resale of any content from this app, is strictly prohibited. Our app monitors and records all screenshots and recordings. Violators will face strict legal action.

DISCLAIMER
THIS IS COPYRIGHTED CONTENT. Unauthorized use, including screenshots, copying, misuse, reuse, or resale of any content from this app, is strictly prohibited. Our app monitors and records all screenshots and recordings. Violators will face strict legal action.

THIS IS COPYRIGHTED CONTENT. Unauthorized use, including screenshots, copying, misuse, reuse, or resale of any content from this app, is strictly prohibited. Our app monitors and records all screenshots and recordings. Violators will face strict legal action.

DISCLAIMER

PULP, DISEASE AND CLASSIFICATION

Source-Article, Walton, TG

- The pulp is the soft tissue inside the tooth, containing nerves, blood vessels, and connective tissue which plays a vital role in the tooth's vitality, sensory function, and response to stimuli.
- Dental pulp is susceptible to various diseases and conditions, which may be caused by factors such as trauma, caries, or infections.
- Pulp disease refers to any pathological condition affecting the dental pulp, which can range from reversible to irreversible stages.
- Pulp diseases are classified based on the severity of the condition, ranging from mild inflammation (reversible pulpitis) to complete pulp death (pulp necrosis).
- The classification typically divides pulp diseases into categories based on symptoms, such as reversible and irreversible pulpitis, and by the extent of the damage.

Classification of Pulp Diseases:

- Many different classifications has been advocated based on clinical and histological findings for pulp diseases.
- Classifying helps to establish accurate diagnosis which is essential to determine what clinical treatment is required.

The typical progression of pulp disease occurs through following stages:

- a) Normal
- b) Inflammation(pulpitis)
- c) Necrosis
- d) Infection and pulp degeneration

- The changes can be acute or chronic, reversible or irreversible and chronic conditions can have acute exacerbations any time.

THIS IS COPYRIGHTED
CONTENT. Unauthorized use,
including screenshots,
copying, misuse, reuse, or
resale of any content from
this app, is strictly prohibited.
Our app monitors and records
all screenshots and
recordings. Violators will face
strict legal action.

DISCLAIMER

THIS IS COPYRIGHTED CONTENT. Unauthorized use, including screenshots, copying, misuse, reuse, or resale of any content from this app, is strictly prohibited. Our app monitors and records all screenshots and recordings. Violators will face strict legal action.

DISCLAIMER
THIS IS COPYRIGHTED CONTENT. Unauthorized use, including screenshots, copying, misuse, reuse, or resale of any content from this app, is strictly prohibited. Our app monitors and records all screenshots and recordings. Violators will face strict legal action.

DISCLAIMER
THIS IS COPYRIGHTED CONTENT. Unauthorized use, including screenshots, copying, misuse, reuse, or resale of any content from this app, is strictly prohibited. Our app monitors and records all screenshots and recordings. Violators will face strict legal action.

PULP, DISEASE AND CLASSIFICATION

Table 1. Comparative terminology and classifications of pulp diseases used by various authors and organisations

World Health Organization ¹	Weine ²	Ingle ³	Seltzer & Bender ⁴	Cohen & Burns ⁵	Tronstad ⁶
NOTE: Normal pulp not mentioned)	(NOTE: Normal pulp not mentioned)	Healthy pulp	(NOTE: Normal pulp not mentioned)	Within normal limits Normal pulp Calcific metamorphosis	Healthy pulp
Pulpitis Initial (hyperaemia) Acute Suppurative (pulpal abscess) Chronic Chronic ulcerative Chronic hyperplastic (pulpal polyp) Other unspecified pulpitis Pulpitis unspecified	Pulpitis Hyperalgesia (reversible pulpitis) Hypersensitive dentine Hyperaemia Painful pulpitis Acute pulpalgia (acute pulpitis) Chronic pulpalgia (subacute pulpitis) Nonpainful pulpitis Chronic ulcerative pulpitis Chronic pulpitis (no caries) Chronic hyperplastic pulpitis (pulp polyp)	Pulpitis Hyper-reactive pulpalgia Hypersensitivity Hyperaemia Acute pulpalgia Incipient Moderate Advanced Chronic pulpalgia Hyperplastic pulposis	Pulpitis Incipient form of chronic pulpitis Acute pulpitis Chronic partial pulpitis with partial necrosis Chronic total pulpitis with partial liquefaction necrosis Chronic partial pulpitis (hyperplastic form)	Pulpitis Reversible Irreversible Asymptomatic irreversible pulpitis Hyperplastic pulpitis Internal resorption Canal calcification Symptomatic irreversible pulpitis	Pulpitis Asymptomatic pulpitis Symptomatic pulpitis
Necrosis of the pulp	Pulp necrosis	Pulp necrosis Liquefaction Sicca	Pulp necrosis	Necrosis Partial Complete	Necrotic pulp
Pulp degenerations Denticles Pulpal calcification Pulpal stones Abnormal hard tissue formation in pulp secondary or irregular dentine	Pulp degeneration Atrophy Dystrophic calcification Internal resorption	Pulp degeneration Atrophic pulposis Calcific pulposis Internal resorption	Pulp degeneration Atrophic pulp Dystrophic mineralization		

American Association of Endodontists' Glossary ⁷	Harty ⁸	Walton & Torabinejad ⁹	Grossman ¹⁰	Castellucci ¹¹	Stock ¹²	Bergenholtz ¹³
Normal pulp not mentioned)	Normal pulp	(NOTE: Normal pulp not mentioned)	(NOTE: Normal pulp not mentioned)	Healthy pulp	Normal pulp	Pulpa sana
Pulpitis Reversible pulpitis Irreversible pulpitis	Pulpitis Reversible pulpitis Irreversible pulpitis	Pulpitis Reversible pulpitis Irreversible pulpitis Hyperplastic pulpitis	Hyperaemia Pulpitis Acute pulpitis Chronic ulcerative pulpitis Chronic hyperplastic pulpitis	Pulpitis Hyperaemia Pulpitis irreversible	Concussed pulp Reversible pulpitis Irreversible pulpitis	Pulpitis
Pulp necrosis	Necrosis	Pulpal necrosis Pulp calcification Internal (intracanal) resorption	Necrosis Pulp degeneration Calcific Fibrous Atrophic Internal resorption	Necrosis	Pulpal necrosis Internal resorption	Necrosis pulpa

Image- Classification and terminologies from various sources: Article

- The diseases of pulp are progressive in nature and progress to other conditions if left untreated.

DISCLAIMER

THIS IS COPYRIGHTED CONTENT. Unauthorized use, including screenshots, copying, misuse, reuse, or resale of any content from this app, is strictly prohibited. Our app monitors and records all screenshots and recordings. Violators will face strict legal action.

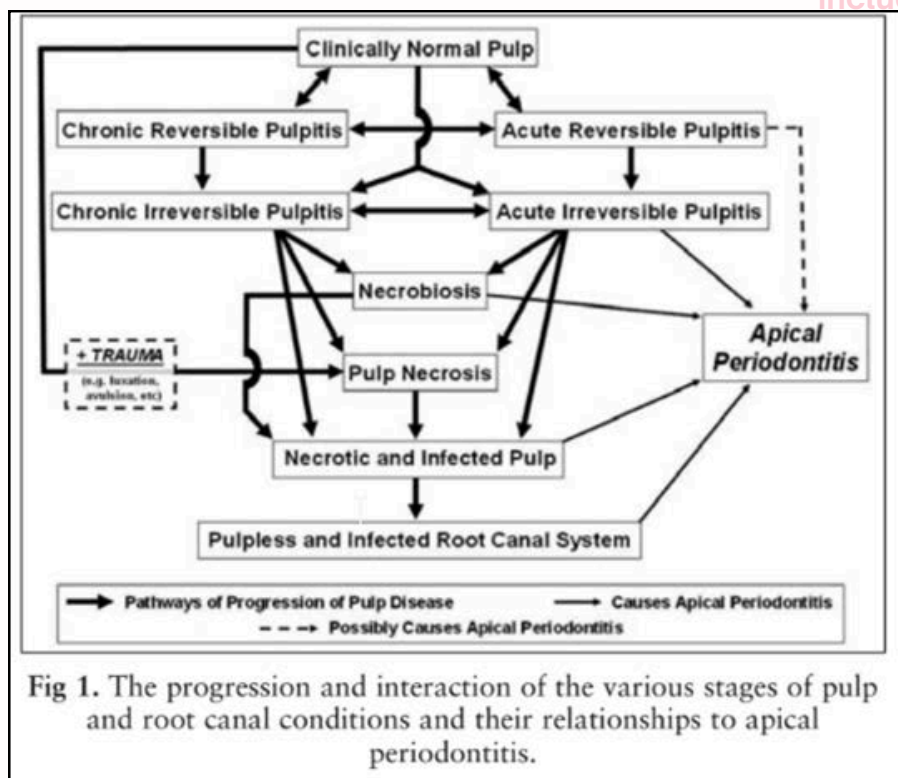
DISCLAIMER
THIS IS COPYRIGHTED CONTENT. Unauthorized use, including screenshots, copying, misuse, reuse, or resale of any content from this app, is strictly prohibited. Our app monitors and records all screenshots and recordings. Violators will face strict legal action.

THIS IS COPYRIGHTED CONTENT. Unauthorized use, including screenshots, copying, misuse, reuse, or resale of any content from this app, is strictly prohibited. Our app monitors and records all screenshots and recordings. Violators will face strict legal action.

DISCLAIMER

PULP, DISEASE AND CLASSIFICATION

Progression of pulp disease:



1) Normal Pulp

- A tooth with a normal pulp is clinically symptom free. Such a tooth does not reveal any radiographic signs of pathosis.
- It produces mild or transient response to various stimuli but nature and severity of response can vary depending on the age and state of the tooth.
- Dentine sensitivity with normal pulp (no pulpal inflammation can occur) if exposed and open dentinal tubules are present and when they are exposed to irritants but stops with removal of stimulus.
- **Response to Cold Stimuli:** Mild pain that lasts no longer than 1-2 seconds after removal of stimulus. Pain in response to cold in normal pulp is immediate and the intensity tends to decrease if the cold stimulus is maintained.
- **Response to Heat Stimuli:** No abnormal response. When heat is applied to uninfamed pulp the initial response is delayed and intensity increases with rise in temperature.
- **Percussion and palpation test:** No response
- **Radiographic Appearance:** No changes (Normal appearance of pulp and tooth)

DISCLAIMER

THIS IS COPYRIGHTED CONTENT. Unauthorized use, including screenshots, copying, misuse, reuse, or resale of any content from this app, is strictly prohibited. Our app monitors and records all screenshots and recordings. Violators will face strict legal action.

DISCLAIMER
THIS IS COPYRIGHTED CONTENT. Unauthorized use, including screenshots, copying, misuse, reuse, or resale of any content from this app, is strictly prohibited. Our app monitors and records all screenshots and recordings. Violators will face strict legal action.

THIS IS COPYRIGHTED CONTENT. Unauthorized use, including screenshots, copying, misuse, reuse, or resale of any content from this app, is strictly prohibited. Our app monitors and records all screenshots and recordings. Violators will face strict legal action.

THIS IS COPYRIGHTED CONTENT. Unauthorized use, including screenshots, copying, misuse, reuse, or resale of any content from this app, is strictly prohibited. Our app monitors and records all screenshots and recordings. Violators will face strict legal action.

PULP, DISEASE AND CLASSIFICATION

2) Reversible Pulpitis:

- Reversible pulpitis is a clinical condition associated with subjective and objective findings indicating presence of mild inflammation in the pulp tissue.
- If the cause is eliminated, inflammation will reverse and the pulp will return to its normal state.
- Reversible pulpitis is an acute condition or acute exacerbation of chronic condition. (Clinically in endodontic acute means painful and chronic means no pain or only mild discomfort)

Causative agents can be:

- i. Mild or short-acting stimuli such as incipient caries, cervical erosion, or occlusal attrition
- ii. Most operative procedures
- iii. Deep periodontal curettage
- iv. Enamel fractures resulting in exposure of dentinal tubules

- **Symptom:** Usually asymptomatic, pain is only felt with stimulus is applied to the tooth.
- **Pain characteristics:** Short and sharp in nature but not spontaneous, which usually ceases within few seconds or immediately upon removal of the stimulus.
- **Response to Cold stimulus:** Pain on extreme temperatures (like ice-cream over tap water) and sweets.
- **Response to heat:** Sometimes only.
- **Radiographic appearance:** No significant changes in periapical region, the only radiographic finding of note may be the cause of problem like caries, restoration etc.
- If pain on biting is also associated with the symptoms of reversible pulpitis crack in a tooth or restoration can be suspected.

Diagnosis of reversible Pulpitis:

- Diagnosis of reversible pulpitis should always be considered a provisional diagnosis.
- So once the provisional diagnosis is made it should be managed conservatively and reviewed after several weeks (generally 3 months is considered reliable time) which can confirm if the provisional diagnosis returned to normal pulpal state or progressed to irreversible pulpitis.

Treatment:

- Conservative pulp therapy with removal of cause and pathway of irritation.
- The removal of irritants and sealing and insulating the exposed dentin or vital pulp usually results in diminished symptoms and reversal of the inflammatory process in the pulp tissue.

DISCLAIMER

THIS IS COPYRIGHTED CONTENT. Unauthorized use, including screenshots, copying, misuse, reuse, or resale of any content from this app, is strictly prohibited. Our app monitors and records all screenshots and recordings. Violators will face strict legal action.

DISCLAIMER

THIS IS COPYRIGHTED CONTENT. Unauthorized use, including screenshots, copying, misuse, reuse, or resale of any content from this app, is strictly prohibited. Our app monitors and records all screenshots and recordings. Violators will face strict legal action.

THIS IS COPYRIGHTED CONTENT. Unauthorized use, including screenshots, copying, misuse, reuse, or resale of any content from this app, is strictly prohibited. Our app monitors and records all screenshots and recordings. Violators will face strict legal action.

DISCLAIMER

PULP, DISEASE AND CLASSIFICATION

2) Reversible Pulpitis:

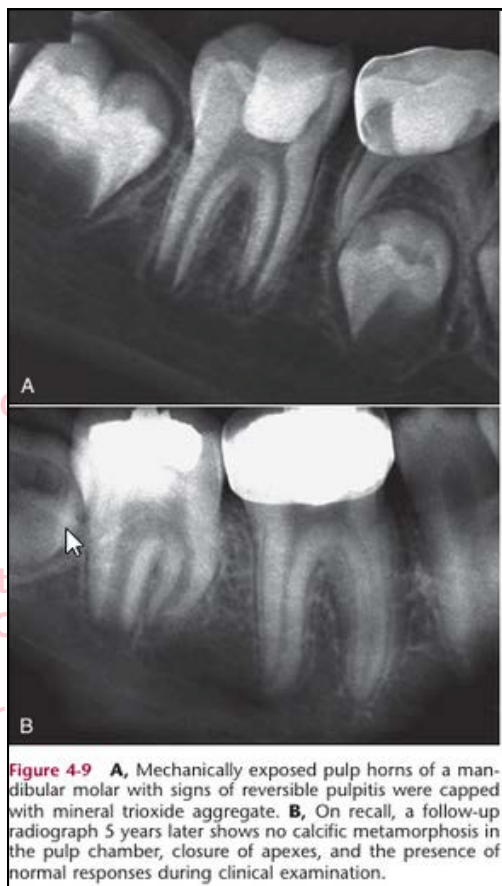


Image: source-Endodontic principle (Walton)

3) Irreversible Pulpitis

- Irreversible pulpitis is a severe inflammatory process that will not resolve even if the cause is removed.
 - **Symptom:** Classic symptom is lingering pain induced by thermal stimuli or Spontaneous pain (unprovoked) which wakes the patient at night and worsens on lying down is the hallmark of irreversible pulpitis.
 - **Pain characteristics:** Very sharp, lingering pain which is usually dull ache or throbbing in nature. Poorly localized if not associated with periapical pathosis i.e. early stages of irreversible pulpitis. (Even difficulty in localizing maxillary or mandibular teeth)
 - **Response to cold and hot stimulus:** Only mild temperature change (like tap water, breathing cold air) can induce very sharp pain that lingers for minutes to hours after stimulus is removed.
- In late stages of irreversible pulpitis, application of cold in patients with painful irreversible pulpitis may cause vasoconstriction, a drop in pulpal pressure, and subsequent pain relief.

DISCLAIMER

THIS IS COPYRIGHTED CONTENT. Unauthorized use, including screenshots, copying, misuse, reuse, or resale of any content from this app, is strictly prohibited. Our app monitors and records all screenshots and recordings. Violators will face strict legal action.

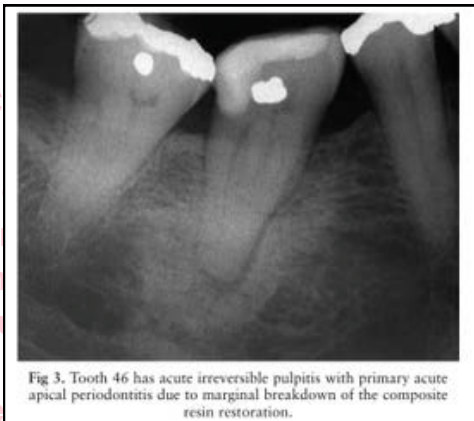
DISCLAIMER
THIS IS COPYRIGHTED CONTENT. Unauthorized use, including screenshots, copying, misuse, reuse, or resale of any content from this app, is strictly prohibited. Our app monitors and records all screenshots and recordings. Violators will face strict legal action.

THIS IS COPYRIGHTED CONTENT. Unauthorized use, including screenshots, copying, misuse, reuse, or resale of any content from this app, is strictly prohibited. Our app monitors and records all screenshots and recordings. Violators will face strict legal action.

PULP, DISEASE AND CLASSIFICATION

3) Irreversible Pulpitis:

- **Response to percussion:** If inflammation is confined to the pulp and has not extended periapically, teeth respond within normal limits to palpation and percussion. When periapical tissues are involved the pain is then well localized and may be tender to percussion.
- **Radiographic changes:** Not useful in diagnosis as no changes may be visible in early stages without any involvement of the periapical tissues. As the disease progresses to involve periapical tissue radiographic changes may be evident.



- Irreversible pulpitis can be further classified as:
 - a) Acute (symptomatic)-Pain may not be relieved even by normal analgesics.
 - b) Chronic (asymptomatic)-Much less severe pain or no pain which is more intermittent rather than continuous in nature.
 - c) Hyperplastic pulpitis (pulp polyp)-
 - It is a form of irreversible pulpitis that originates from overgrowth of a chronically inflamed young pulp onto the occlusal surface.
 - It is usually found in carious crowns of young patients.
 - Hyperplastic pulpitis is usually asymptomatic.
 - It appears as a reddish cauliflower-like outgrowth of connective tissue into caries that has resulted in a large occlusal exposure.
 - It is occasionally associated with clinical signs of irreversible pulpitis, such as spontaneous pain, as well as lingering pain to cold and heat stimuli.
 - The threshold to electrical stimulation is similar to that found in normal pulps. These teeth respond within normal limits when palpated or percussed.

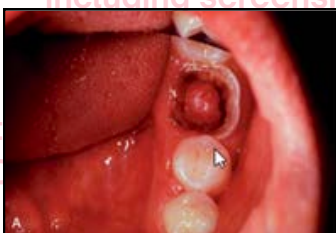

Image: Pulp polyp (source-Walton)

DISCLAIMER

THIS IS COPYRIGHTED CONTENT. Unauthorized use, including screenshots, copying, misuse, reuse, or resale of any content from this app, is strictly prohibited. Our app monitors and records all screenshots and recordings. Violators will face strict legal action.

DISCLAIMER

THIS IS COPYRIGHTED CONTENT. Unauthorized use, including screenshots, copying, misuse, reuse, or resale of any content from this app, is strictly prohibited. Our app monitors and records all screenshots and recordings. Violators will face strict legal action.

THIS IS COPYRIGHTED CONTENT. Unauthorized use, including screenshots, copying, misuse, reuse, or resale of any content from this app, is strictly prohibited. Our app monitors and records all screenshots and recordings. Violators will face strict legal action.

DISCLAIMER

PULP, DISEASE AND CLASSIFICATION

3) Irreversible Pulpitis

- **Treatment:**
Root canal treatment or extraction are usually recommended for teeth with symptoms of irreversible pulpitis.

4) Pulp Necrosis

- Pulp is encased in rigid walls, it has no collateral blood circulation, and its venules and lymphatics collapse under increased tissue pressure. Therefore irreversible pulpitis leads to liquefaction necrosis.
- A necrotic pulp should be suspected usually when the tooth does not respond to pulp sensibility tests (asymptomatic).
- **Pain characteristics:** No pain unless PDL is involved, where canal is infected leading to apical periodontitis.
Occasionally patients complain of dull continuous ache that is exacerbated by heat but relieved by cold water being held over the mouth. However this relief is only temporary and pain returns as soon as the tooth warms up.
- It may sometimes also be associated with episodes of spontaneous pain and discomfort (from periradicular tissues).
- The necrotic pulp acts as a source of nutrients for the bacteria which ingest the pulp tissue and render the teeth pulpless. (Which may occur within 1-2 months) of bacterial invasion.

5) Pulpless infected root canals

- The tooth will always be infected when it is pulpless.
- The tooth itself will always be painless however pain may arise from periradicular tissues that become inflamed from the presence of bacteria in the pulp space.
- **Response to pulp sensibility tests:** no response
- **Radiographic changes:** In early stages-no radiographic changes is seen however within 2-10 months radiolucency develops suggesting periapical involvement.
- Tenderness to **biting or percussion** is a typical sign of **apical periodontitis** which may be present before radiolucency hence a tenderness without periapical radiolucency will indicate either a necrotic pulp with infection or early stages of a pulpless infected root canal system.

THIS IS COPYRIGHTED CONTENT. Unauthorized use, including screenshots, copying, misuse, reuse, or resale of any content from this app, is strictly prohibited. Our app monitors and records all screenshots and recordings. Violators will face strict legal action.

DISCLAIMER

THIS IS COPYRIGHTED CONTENT. Unauthorized use, including screenshots, copying, misuse, reuse, or resale of any content from this app, is strictly prohibited. Our app monitors and records all screenshots and recordings. Violators will face strict legal action.

DISCLAIMER
THIS IS COPYRIGHTED CONTENT. Unauthorized use, including screenshots, copying, misuse, reuse, or resale of any content from this app, is strictly prohibited. Our app monitors and records all screenshots and recordings. Violators will face strict legal action.

DISCLAIMER
THIS IS COPYRIGHTED CONTENT. Unauthorized use, including screenshots, copying, misuse, reuse, or resale of any content from this app, is strictly prohibited. Our app monitors and records all screenshots and recordings. Violators will face strict legal action.

PULP, DISEASE AND CLASSIFICATION

6) Degenerative changes:

- Pulp usually responds to noxious stimuli by becoming inflamed but it may also response with degenerative changes like atrophy, fibrosis, calcifications, root resorption or hyperplasia.
 - Atrophy:** It is a normal physiologic response that occurs with age and is asymptomatic. The size of pulp chamber may be reduced. No treatment is required.
 - Pulp canal calcification:** Teeth with pulp canal calcification/obliteration may not have any symptoms if the pulp tissue within the calcifying or calcified canal is normal. However if the canal is infected it may show apical periodontitis with symptoms. Usually no response to **thermal test** but **electric pulp test (EPT)** may elicit normal or delayed response.

Radiographically-no evidence of the usual pulp chamber outline and root canal may appear narrow or not be evident at all.

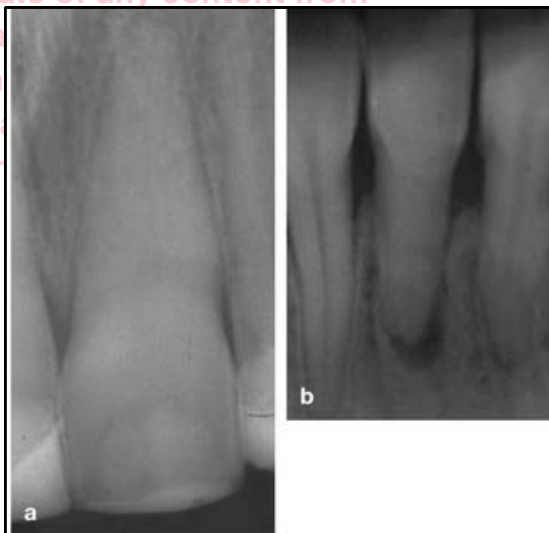


Fig 7. Teeth with pulp canal calcification. (A) Tooth 21 has a clinically normal pulp with no evidence of periapical pathosis but there are radiographic signs of pulp canal calcification. Endodontic treatment is not required for this tooth. (B) Tooth 41 has a pulpless, infected root canal system with chronic apical periodontitis. There is radiographic evidence of pulp canal calcification. Endodontic treatment is required for this tooth.

- Hyperplasia:** Pulp hyperplasia occurs mostly in young tooth with abundant blood supply and large carious lesion. Image: Pulp polyp (source-Walton)

DISCLAIMER

THIS IS COPYRIGHTED CONTENT. Unauthorized use, including screenshots, copying, misuse, reuse, or resale of any content from this app, is strictly prohibited. Our app monitors and records all screenshots and recordings. Violators will face strict legal action.

DISCLAIMER

THIS IS COPYRIGHTED CONTENT. Unauthorized use, including screenshots, copying, misuse, reuse, or resale of any content from this app, is strictly prohibited. Our app monitors and records all screenshots and recordings. Violators will face strict legal action.

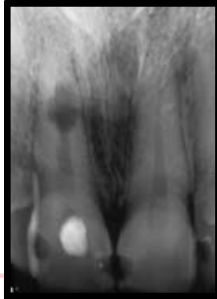THIS IS COPYRIGHTED CONTENT. Unauthorized use, including screenshots, copying, misuse, reuse, or resale of any content from this app, is strictly prohibited. Our app monitors and records all screenshots and recordings. Violators will face strict legal action.

THIS IS COPYRIGHTED CONTENT. Unauthorized use, including screenshots, copying, misuse, reuse, or resale of any content from this app, is strictly prohibited. Our app monitors and records all screenshots and recordings. Violators will face strict legal action.

PULP, DISEASE AND CLASSIFICATION

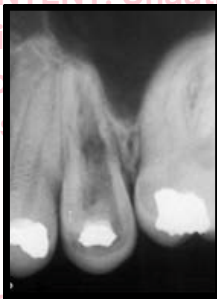6) Degenerative changes:

d) Internal resorption: 3 forms of internal resorption is present:



- i. **Surface resorption:** Unlikely to be diagnosed ever as only minor areas of resorption on root canal wall. No changes clinically, radiographically and no symptoms may be seen. No treatment is required.

Image: a) Inflammatory internal resorption



- ii. **Internal inflammatory resorption:** Can occur at any point along the length of pulp space, either coronally within the pulp chamber or within the root canal. Usually asymptomatic and recognized in routine radiographic examination. If symptoms are present it indicates acute apical periodontitis due to infected canal. **Radiographically** it will have oval shaped increase in size of part of root canal.

Image: b) Replacement internal resorption.

- iii. **Internal replacement resorption:** It is uncommon condition that occurs when the pulp undergoes metaplastic changes and dentine is resorbed and replaced by bone like hard tissue. **Radiographically** it will have an irregular enlargement of pulp space that will have bone like hard tissue filled in it.

7) Periapical diseases:

- As a consequence of pulpal necrosis, pathologic changes can occur in the periradicular tissues. In contrast to pulp, periradicular tissues have an almost unlimited source of undifferentiated cells that participate in inflammation and repair.
- Periapical diseases are usually a direct result of pulp diseases.

It can be further classified as:

- a) **Normal periapical tissues:** This condition represents a clinical and radiographic diagnostic category in which the tooth has normal periapical tissues and will not be abnormally sensitive to percussion or palpation testing. The teeth in this category have normal lamina dura and periodontal ligament structures.

- b) **Apical periodontitis:** (continued on next page)

DISCLAIMER

THIS IS COPYRIGHTED CONTENT. Unauthorized use, including screenshots, copying, misuse, reuse, or resale of any content from this app, is strictly prohibited. Our app monitors and records all screenshots and recordings. Violators will face strict legal action.

PULP, DISEASE AND CLASSIFICATION

7) Periapical diseases:

b) **Apical periodontitis:**

- i. **Symptomatic Apical periodontitis (SAP):** The first extension of pulpal inflammation into the periradicular tissues is called symptomatic apical periodontitis. Clinical features are moderate to severe spontaneous discomfort as well as pain on biting or percussion. If symptomatic apical periodontitis is an extension of pulpitis, its signs and symptoms will include responsiveness to cold, heat, and electricity. Cases of SAP caused by a necrotic pulp do not respond to vitality tests. Application of pressure by the fingertip or tapping with the butt end of a mirror handle (percussion) can cause marked to excruciating pain. SAP is not associated with an apical radiolucency. Occasionally, there may be slight radiographic changes, such as a "widening" of the PDL space or a very small radiolucent lesion. However, usually there is a normal PDL space with an intact lamina dura.

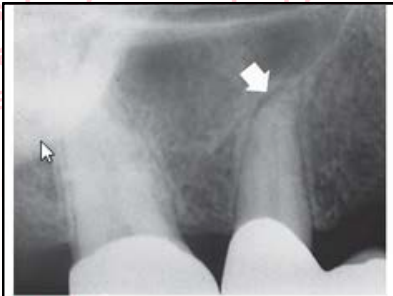


Figure 4-16 After cementing a three-unit bridge, the pre-molar developed clinical signs and symptoms of acute apical periodontitis, and the radiograph shows a widened periodontal ligament space (arrow).

- ii. **Asymptomatic Apical periodontitis (AAP):** It results from pulp necrosis and usually is a sequel to SAP. AAP is a clinical asymptomatic condition of pulpal origin associated with inflammation and destruction of periapical tissues. Because the pulp is necrotic, teeth with AAP do not respond to electrical or thermal stimuli. Percussion produces little or no pain. There may be slight sensitivity to palpation, indicating an alteration of the cortical plate of bone and extension of AAP into the soft tissues. Radiographic features range from interruption of the lamina dura to extensive destruction of periapical and interradicular tissues.
- c) **Condensing Osteitis:** Condensing osteitis, a variant of asymptomatic apical periodontitis, represents an increase in trabecular bone in response to persistent irritation. This lesion is usually found around the apices of mandibular posterior teeth, which show a probable cause of pulp inflammation or necrosis. It can be asymptomatic or associated with pain. Radiographically, the presence of a diffuse concentric arrangement of radiopacity around the root of a tooth is pathognomonic.

DISCLAIMER

THIS IS COPYRIGHTED CONTENT. Unauthorized use, including screenshots, copying, misuse, reuse, or resale of any content from this app, is strictly prohibited. Our app monitors and records all screenshots and recordings. Violators will face strict legal action.

PULP, DISEASE AND CLASSIFICATION

7) Periapical diseases:

c) Condensing Osteitis:

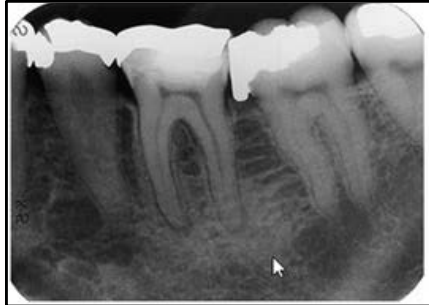

Fig: Condensing osteitis. Inflammation followed by necrosis in the pulp of the first molar has resulted in the diffuse radiopacity of periapical tissue.

d) **Apical abscess:** Acute apical abscess (AAA) is a localized or diffuse liquefaction lesion of pulpal origin. AAA is characterized by rapid onset and spontaneous pain. Depending on the severity of the reaction, patients with AAA usually have moderate to severe discomfort and/or swelling.

The chronic apical abscess (CAA) is an inflammatory lesion of pulpal origin that is characterized by the presence of a long-standing lesion that has resulted in an abscess that is draining to a mucosal (sinus tract) or skin surface. CAA is usually asymptomatic, except when there is occasional closure of the sinus pathway, which can cause pain.

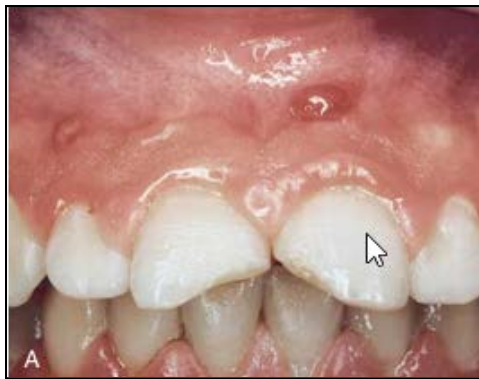

Fig: A sinus tract stoma associated with a necrotic pulp in the left central incisor.

THIS IS COPYRIGHTED CONTENT. Unauthorized use, including screenshots, copying, misuse, reuse, or resale of any content from this app, is strictly prohibited. Our app monitors and records all screenshots and recordings. Violators will face strict legal action.

DISCLAIMER

THIS IS COPYRIGHTED CONTENT. Unauthorized use, including screenshots, copying, misuse, reuse, or resale of any content from this app, is strictly prohibited. Our app monitors and records all screenshots and recordings. Violators will face strict legal action.

DISCLAIMER
THIS IS COPYRIGHTED CONTENT. Unauthorized use, including screenshots, copying, misuse, reuse, or resale of any content from this app, is strictly prohibited. Our app monitors and records all screenshots and recordings. Violators will face strict legal action.

THIS IS COPYRIGHTED CONTENT. Unauthorized use, including screenshots, copying, misuse, reuse, or resale of any content from this app, is strictly prohibited. Our app monitors and records all screenshots and recordings. Violators will face strict legal action.

DISCLAIMER
THIS IS COPYRIGHTED CONTENT. Unauthorized use, including screenshots, copying, misuse, reuse, or resale of any content from this app, is strictly prohibited. Our app monitors and records all screenshots and recordings. Violators will face strict legal action.

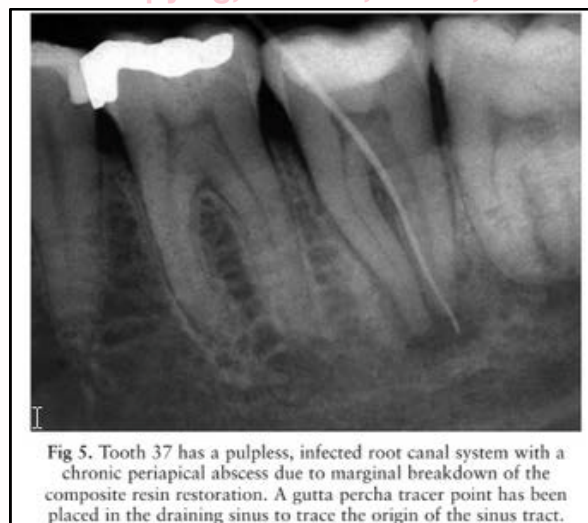
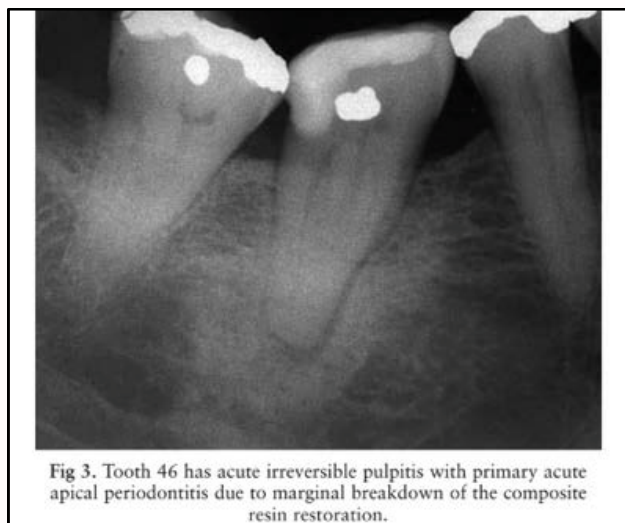
PULP, DISEASE AND CLASSIFICATION

7) Periapical diseases:

Examples of some typical diagnosis are:

- Acute irreversible pulpitis with primary acute apical periodontitis due to caries.
- Acute irreversible pulpitis with primary acute apical periodontitis due to breakdown of a restoration (Fig 3).
- Necrotic and infected pulp with primary acute apical periodontitis due to caries and restoration breakdown.
- Pulpless, infected root canal system with secondary acute apical periodontitis due to breakdown of the restoration.
- Pulpless, infected root canal system with a chronic apical abscess due to breakdown of the restoration (Fig 5).
- A pulpless, infected root canal system with secondary acute apical periodontitis due to breakdown of the restoration (Fig 6).
- A root-filled tooth with an infected root canal system and chronic apical periodontitis due to breakdown of the restoration (Fig 6).
- Pulpless, infected root canal system with chronic apical periodontitis due to a crack in the tooth and caries.
- A clinically normal pulp with pulp canal calcification but no signs of apical periodontitis (Fig 7a).

The fig mentioned are provided below:



Our app monitors and records all screenshots and recordings. Violators will face strict legal action.

DISCLAIMER

THIS IS COPYRIGHTED CONTENT. Unauthorized use, including screenshots, copying, misuse, reuse, or resale of any content from this app, is strictly prohibited. Our app monitors and records all screenshots and recordings. Violators will face strict legal action.

THIS IS COPYRIGHTED CONTENT. Unauthorized use, including screenshots, copying, misuse, reuse, or resale of any content from this app, is strictly prohibited. Our app monitors and records all screenshots and recordings. Violators will face strict legal action.

THIS IS COPYRIGHTED CONTENT. Unauthorized use, including screenshots, copying, misuse, reuse, or

DISCLAIMER
THIS IS COPYRIGHTED CONTENT. Unauthorized use, including screenshots, copying, misuse, reuse, or resale of any content from this app, is strictly prohibited. Our app monitors and records all screenshots and recordings. Violators will face strict legal action.

PULP, DISEASE AND CLASSIFICATION

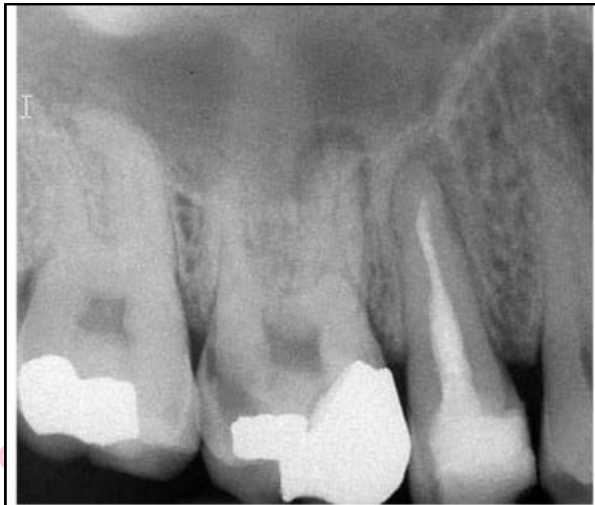

Fig 6. Tooth 16 has a pulpless, infected root canal system with secondary acute apical periodontitis due to the presence of caries on the distal surface and marginal breakdown of the amalgam restoration. Tooth 15 has an infected root canal system with chronic apical periodontitis due to breakdown of the composite resin restoration. The root canal filling is technically unsatisfactory.

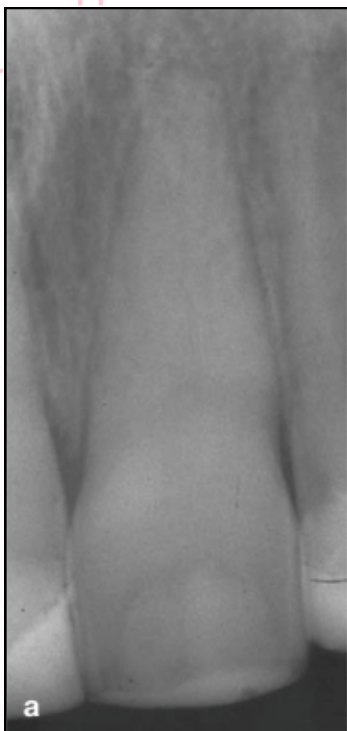

Fig 7. Teeth with pulp canal calcification. (A) Tooth 21 has a clinically normal pulp with no evidence of periapical pathosis but there are radiographic signs of pulp canal calcification. Endodontic treatment is not required for this tooth. (B) Tooth 41 has a pulpless,

THIS IS COPYRIGHTED CONTENT. Unauthorized use, including screenshots, copying, misuse, reuse, or resale of any content from this app, is strictly prohibited. Our app monitors and records all screenshots and recordings. Violators will face strict legal action.

THIS IS COPYRIGHTED CONTENT. Unauthorized use, including screenshots, copying, misuse, reuse, or resale of any content from this app, is strictly prohibited. Our app monitors and records all screenshots and recordings. Violators will face strict legal action.

Our app monitors and records all screenshots and recordings. Violators will face strict legal action.

DISCLAIMER

THIS IS COPYRIGHTED CONTENT. Unauthorized use, including screenshots, copying, misuse, reuse, or resale of any content from this app, is strictly prohibited. Our app monitors and records all screenshots and recordings. Violators will face strict legal action.

DISCLAIMER
THIS IS COPYRIGHTED CONTENT. Unauthorized use, including screenshots, copying, misuse, reuse, or resale of any content from this app, is strictly prohibited. Our app monitors and records all screenshots and recordings. Violators will face strict legal action.

INVESTIGATIONS IN ENDODONTICS AND NEURAL PULP PHYSIOLOGY

Source-Articles

Investigations in Endodontics:

The purpose of diagnosis in endodontics is to assess the condition of the tooth. Accurate diagnosis is imperative in all cases so appropriate treatment can be provided in timely manner.

1) History of the patient's pain:

- It is the first clinical data that a dentist must collect and consider.
- Type, Duration, Frequency, aggravating factors, effect of analgesic and tenderness to biting should be noted.

Once a provisional diagnosis is reached which should be based on patients chief complaint, their description of symptoms and thorough history. Then only Clinical (intraoral and extraoral) and radiographic examination is done to confirm the provisional diagnosis.

1) A) Clinical Tests: It includes-

a) **Transillumination test:** It may reveal hidden decay or fracture. In this test a strong light is placed behind the tooth, where vital tooth transmits the light well because of its translucency. A necrotic tooth appears dark and dull because of its compromised blood supply and degeneration of pigments into dentinal tubules.

b) **Pulp sensibility tests:** They measure the ability of pulp nerve fibers to respond to stimulus. The main function of pulp sensibility tests is to firstly determine if there is nerve response or not and secondly to assess the nature of the response. They are also referred to as vitality test which is a misnomer. These are used in diagnosis of lesions mostly not seen in radiographs.

2) Thermal tests: It depends on outward and inward movement of dentinal fluid.

a) The Cold test :

- It is most useful test in endodontic diagnosis -
- Various methods are used to apply cold to teeth which includes ice sticks (0o), CO2 sticks (-78o), ethyl chloride (-5o), dichlorodifluoromethane DDM (-50o). This DDM was reformulated into 1, 1, 1, 2-Tetrafluoroethane that has a low liquid temperature and is environmentally safe.
- Tetrafluoroethane (endo ice) is more likely to produce response than CO2 dry ice. Most commonly used is CO2 snow.
- Use of large cotton pellet than small one and spraying the cotton rather than dipping is more efficient.

DISCLAIMER

THIS IS COPYRIGHTED CONTENT. Unauthorized use, including screenshots, copying, misuse, reuse, or resale of any content from this app, is strictly prohibited. Our app monitors and records all screenshots and recordings. Violators will face strict legal action.

DISCLAIMER
THIS IS COPYRIGHTED CONTENT. Unauthorized use, including screenshots, copying, misuse, reuse, or resale of any content from this app, is strictly prohibited. Our app monitors and records all screenshots and recordings. Violators will face strict legal action.

DISCLAIMER

THIS IS COPYRIGHTED CONTENT. Unauthorized use, including screenshots, copying, misuse, reuse, or resale of any content from this app, is strictly prohibited. Our app monitors and records all screenshots and recordings. Violators will face strict legal action.

INVESTIGATIONS IN ENDODONTICS AND NEURAL PULP PHYSIOLOGY

Source-Articles

b)Heat test :

- The application of heated water or a softened heated gutta-percha used to deliver heat to the pulp.
- These method may produce sufficient heat to stimulate the C fibers and produce pain that lingers is prolonged and usually delayed about 2-4 seconds.
- These are not used routinely and used only when major symptom reported by patient is sensitivity to hot stimulus.

3)Electric pulp tester:

- It depends on ionic movement.
- It is designed to deliver electric current to stimulate the closest myelinated A delta fibers.
- It does not usually stimulate the unmyelinated C fibers.
- Method: Response is best achieved when electrode is placed at gingival third of the buccal surfaces of the natural tooth structure. A non-liquid based interface medium should be used (electrocardiogram gel).
- Indications: In cases of pulp canal and chamber calcification and recently traumatized tooth.




Figure 1: Electric pulp tester.

this app, is strictly prohibited. Our app monitors and records all screenshots and recordings. Violators will face strict legal action.

DISCLAIMER

THIS IS COPYRIGHTED CONTENT. Unauthorized use, including screenshots, copying, misuse, reuse, or resale of any content from this app, is strictly prohibited. Our app monitors and records all screenshots and recordings. Violators will face strict legal action.

DISCLAIMER
THIS IS COPYRIGHTED CONTENT. Unauthorized use, including screenshots, copying, misuse, reuse, or resale of any content from this app, is strictly prohibited. Our app monitors and records all screenshots and recordings. Violators will face strict legal action.

INVESTIGATIONS IN ENDODONTICS AND NEURAL PULP PHYSIOLOGY

Source-Articles

C) Pulp Vitality tests:

- The accurate determination of vitality of pulp is through the vascular supply and not response to sensory fibers.
- Only experimental methods are available for the measure of pulp vitality and it includes Pulp oximetry, Laser Doppler flowmetry, and Dual-wavelength spectrophotometry.

D) **Periradicular test:** It includes palpation, percussion, mobility, probing which helps to assess the integrity of attachment apparatus of the tooth.

E) **Radiographic Evaluations:** Only useful once the periapical pathosis is seen. Helps in determination of root morphology, extent of caries or existing restorations etc.

Table 4. Summary of the examination procedures that should be performed as part of any routine dental examination and diagnosis but particularly whenever pulp and/or periapical pathosis is suspected¹⁶

General medical history	As required for all dental procedures
Presenting complaint	Long and short term history, past and current symptoms, past and recent treatment, medications being used (prescribed and self administered) Description of PAIN: Location, onset, nature, duration, stimuli, relief, referred
Clinical examination	Puckering, indentation, draining sinus, facial asymmetry, caries, periodontal diseases, restorations, restoration margins, etc
Clinical tests	Periradicular tests Pulp sensibility tests
Radiographic examination	Percussion, palpation, mobility, periodontal probing Cold (CO ₂ dry ice at -78°C) Electric (in some cases e.g. when pulp canal calcification) Heat (if required, if patient complains of sensitivity to heat)
Other tests	Periapical radiographs, tube shifts, bitewings, occlusal, panoramic Biting on individual cusps (e.g. with a 'Tooth Slooth') Transillumination of the tooth with a fibre optic light Anaesthetic (e.g. block, infiltration, intra-periodontal ligament, etc.)
Investigation	Remove all restorations, caries, cracks Transillumination of the cavity, cusps, marginal ridges, etc Assess whether, and how, the tooth can be restored again Assess the need for any other treatment (e.g. periodontal) Assess the long term prognosis of the tooth (consider endodontic, periodontal and restorative aspects)

(Image -Source Article)

PULP NEUROPHYSIOLOGY:(Source -Articles)

- Pain is produced when a stimulus strong enough to trigger a nervous response is applied to a tooth.
- The intensity, location and quality of pain will differ depending on the type of stimulus as well as the type of nerve fibers excited in the process.

DISCLAIMER

THIS IS COPYRIGHTED CONTENT. Unauthorized use, including screenshots, copying, misuse, reuse, or resale of any content from this app, is strictly prohibited. Our app monitors and records all screenshots and recordings. Violators will face strict legal action.

DISCLAIMER
THIS IS COPYRIGHTED CONTENT. Unauthorized use, including screenshots, copying, misuse, reuse, or resale of any content from this app, is strictly prohibited. Our app monitors and records all screenshots and recordings. Violators will face strict legal action.

THIS IS COPYRIGHTED CONTENT. Unauthorized use, including screenshots, copying, misuse, reuse, or resale of any content from this app, is strictly prohibited. Our app monitors and records all screenshots and recordings. Violators will face strict legal action.

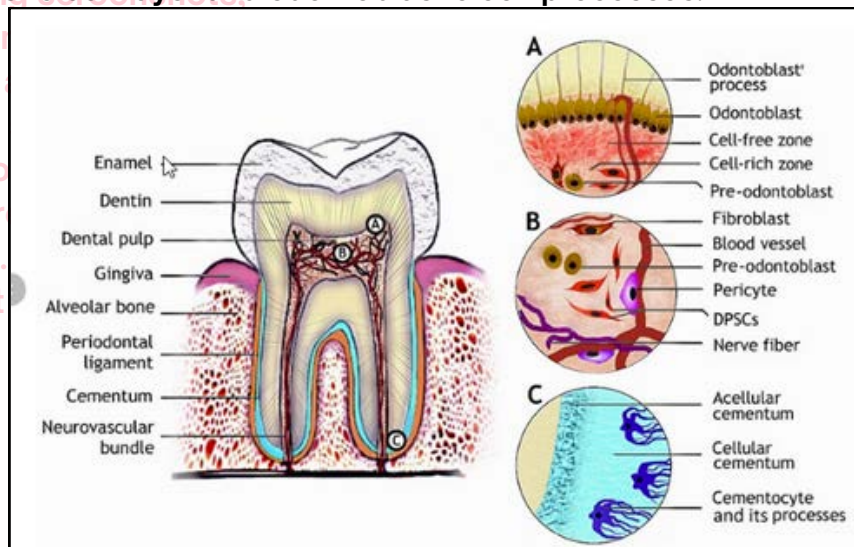
DISCLAIMER

INVESTIGATIONS IN ENDODONTICS AND NEURAL PULP PHYSIOLOGY

Source-Articles

Types of nerve fibers and their distribution inside the dental pulp:

- Teeth are supplied by the alveolar branch of trigeminal nerve (5th cranial nerve).
- Dental Pulp is highly innervated which contains sensory trigeminal afferent axons. Sympathetic efferent fibers regulate the blood flow.
- Anatomy: The cell body of these sensory neurons of the pulp is located at trigeminal ganglion, Thousands of Axons enter the pulp through apical foramen where they branch all over the pulp. The majority of nerve bundles reach the coronal dentin where they fan out to form the nerve plexus of Raschkow, where they anastomose and terminate as free nerve endings that synapse into the odontoblastic cell layer and odontoblastic cell processes.



(Image -Source Internet)

There are 2 types of sensory nerve fibers in the pulp which are:

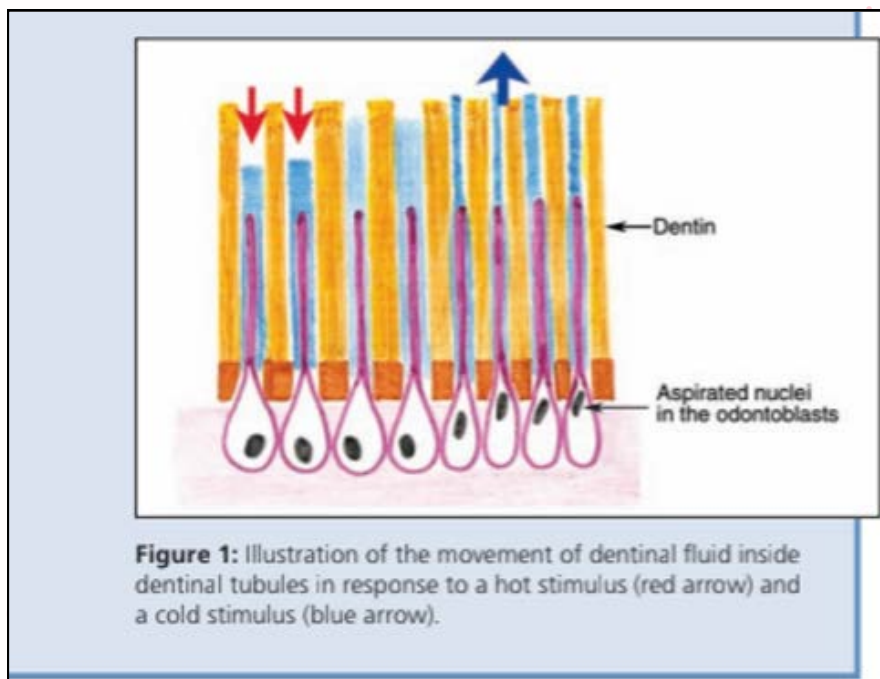
- Myelinated A fibers (A delta and A beta):** 99% of A fibers are A delta.
 - These are located mainly at the pulp dentin border in the coronal portion of the pulp and concentrated in the pulp horns.
 - A delta fibers are faster than C fibers as they transmit pain directly to thalamus, generating a fast sharp pain that is easily localized.
 - They respond to various stimuli through hydrodynamic effect (i.e. it depends on movement of dentinal fluids in the dentinal tubules in response to stimulus)
 - Heat or cold stimuli causes movement of fluid in dentinal tubules resulting in painful sensation in teeth with viable sensory pulp.
 - This response is due to rapid temperature change that causes a sudden fluid flow within the tubules which excites the A delta fibers.
 - A fibers are affected more by reduction of the pulpal blood flow as they cannot function in case of anoxia.

DISCLAIMER

THIS IS COPYRIGHTED CONTENT. Unauthorized use, including screenshots, copying, misuse, reuse, or resale of any content from this app, is strictly prohibited. Our app monitors and records all screenshots and recordings. Violators will face strict legal action.

INVESTIGATIONS IN ENDODONTICS AND NEURAL PULP PHYSIOLOGY

Source-Articles



ii) Unmyelinated C fibers:

- The C fibers are located deeper in the core of the pulp or pulp proper and extend into cell free zone underneath the odontoblastic layer, which may explain the diffuse pain (referred pain) from a specific tooth because nerve fibers innervate multiple teeth with multiple pulps.
- C fibers are influenced by many interneurons before reaching the thalamus, generating a slow pain which is characterized as dull and aching.
- Less excitable than A fibers and have higher threshold so require more stimulus to be activated.
- With continuous application of heat C fibers are affected and elicit an intense response.
- C fibers may survive even in the presence of hypoxia which explains the pain sensed during preparation for root canal in necrotic pulp.

THIS IS COPYRIGHTED CONTENT. Unauthorized use, including screenshots, copying, misuse, reuse, or resale of any content from this app, is strictly prohibited. Our app monitors and records all screenshots and recordings. Violators will face strict legal action.

DISCLAIMER

THIS IS COPYRIGHTED CONTENT. Unauthorized use, including screenshots, copying, misuse, reuse, or resale of any content from this app, is strictly prohibited. Our app monitors and records all screenshots and recordings. Violators will face strict legal action.

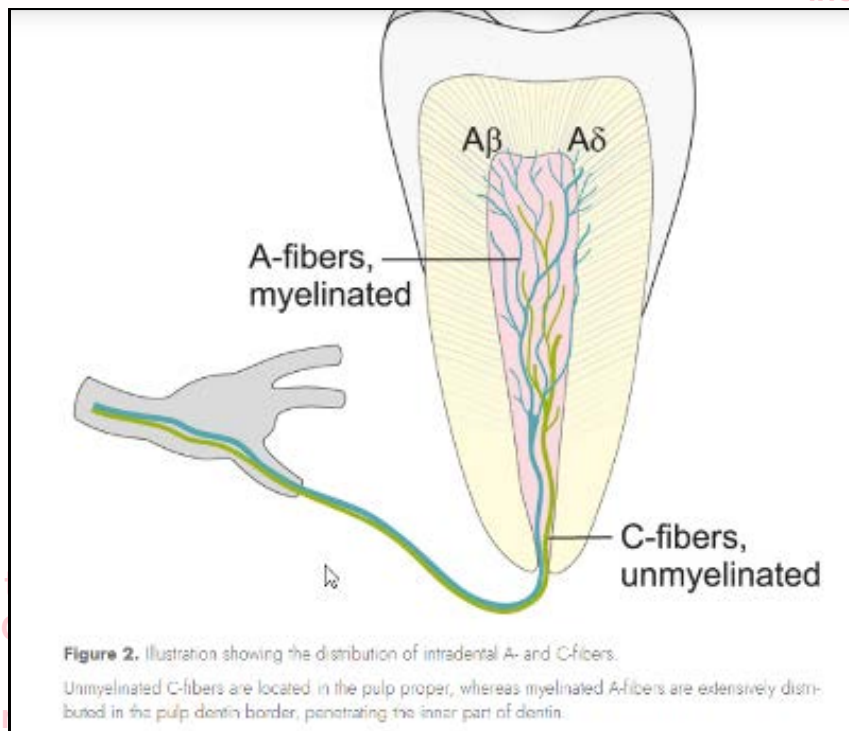
DISCLAIMER
THIS IS COPYRIGHTED CONTENT. Unauthorized use, including screenshots, copying, misuse, reuse, or resale of any content from this app, is strictly prohibited. Our app monitors and records all screenshots and recordings. Violators will face strict legal action.

THIS IS COPYRIGHTED CONTENT. Unauthorized use, including screenshots, copying, misuse, reuse, or resale of any content from this app, is strictly prohibited. Our app monitors and records all screenshots and recordings. Violators will face strict legal action.

DISCLAIMER

INVESTIGATIONS IN ENDODONTICS AND NEURAL PULP PHYSIOLOGY

Source-Articles



(Image-Source Internet)

Examples of Hydrodynamic effect of pain conduction in dentinal tubules:

Hypertonic solutions activate the intradental nerves through osmotic pressure,^{16,19,25,26} manifested clinically by the pain that results when saturated sucrose solutions come into constant contact with sensitive dentin. The patent dentinal tubules are an important factor in the induction of pain in sensitive dentin. This sensitivity is a direct response to the stimulation of the A fibres. Another example is the use of an etchant on the dentinal surface. The osmotic pressure of the acid used for etching the dentin is as important as the acid's chemical composition in the induction of pain because this osmotic pressure causes the outward fluid flow in the tubules, together with aspiration of the odontoblastic nucleus.²⁶⁻²⁸ The ionic concentration of the material also affects the reduction of pain in sensitive dentin. A normally irritant substance such as potassium chloride temporarily relieves pain because the high concentration of potassium temporarily blocks the conduction of nerve impulses, causing a hyperpolarization that decreases the excitability of the nerve fibres. This hyperpolarization is the basis for the addition of potassium ions to dentifrices.

(Image-Source Article)

DISCLAIMER

THIS IS COPYRIGHTED CONTENT. Unauthorized use, including screenshots, copying, misuse, reuse, or resale of any content from this app, is strictly prohibited. Our app monitors and records all screenshots and recordings. Violators will face strict legal action.

DISCLAIMER
THIS IS COPYRIGHTED CONTENT. Unauthorized use, including screenshots, copying, misuse, reuse, or resale of any content from this app, is strictly prohibited. Our app monitors and records all screenshots and recordings. Violators will face strict legal action.

THIS IS COPYRIGHTED CONTENT. Unauthorized use, including screenshots, copying, misuse, reuse, or resale of any content from this app, is strictly prohibited. Our app monitors and records all screenshots and recordings. Violators will face strict legal action.

THIS IS COPYRIGHTED CONTENT. Unauthorized use, including screenshots, copying, misuse, reuse, or resale of any content from this app, is strictly prohibited. Our app monitors and records all screenshots and recordings. Violators will face strict legal action.

MEDICAL LEGAL CONSIDERATIONS IN ENDODONTICS

Source-Articles

- Endodontic procedures can be technically challenging for dentists and unpleasant for the patients.
- Problem form endodontic treatment are more likely to lead to a complaint than any other area of dentistry.
- Endodontic patient frequently attend with varying degrees of pain, and while attempting to alleviate the pain many technical difficulties may occur like Difficulty in access, anesthesia, and anatomical complexities. This can lead to complaints by the patients.

Standard of care:

- There is no published standard of care specific to every field of dentistry.
- The goals of endodontics include elimination of pain, managing infection, disinfection and filling of root canal system and final restoration. These are the principle which guides a clinician in management of a patient.
- Policy or position statements from professional organizations that are prepared by experts' acts as benchmarks for clinicians to ensure they are practicing within the expected standard of care.
- ADA (Australian Dental Association) has no specific policy statements regarding endodontic treatment, however the ASE (Australian Society of endodontology) has started the process of preparing position statements regarding the core aspects of endodontic treatment.
- Duty of care is not modified by the experience level of health practitioner.
- Rural dentists have less access to resources and equipment when compared with metropolitan dentists but they are held to same standard of care as metropolitan dentists and must work within the bound of their training and experiences.
- Some patients from the rural area might be reluctant to travel and see specialist even when recommended by dentists so in such instances where complete treatment cannot be provided adequately, pain relief and stabilization should be offered as a short term alternative until the patients can receive definitive treatment and specialist care.
- It is essential that dentists work within their training and experience only and refer for specialist care when necessary. For example if a general dentist decides to perform higher risk and complex procedure like periapical surgeries which is usually done in a specialist setting, the general dentist will be held accountable to the same standard of care as specialist if any complication arises.

Our app monitors and records all screenshots and recordings. Violators will face strict legal action.

DISCLAIMER

THIS IS COPYRIGHTED CONTENT. Unauthorized use, including screenshots, copying, misuse, reuse, or resale of any content from this app, is strictly prohibited. Our app monitors and records all screenshots and recordings. Violators will face strict legal action.

MEDICAL LEGAL CONSIDERATIONS IN ENDODONTICS

Source-Articles

Use of Dental Dam on endodontics:

- Dental dam is of utmost essential in endodontics as it includes all aspects of non-surgical endodontic treatment including emergency extirpation of pulp for pain relief.
- Without the use dental dam an instrument should not be introduced to the root canal system.
- **Advantages:**
 - i. Reduces the bacterial contamination of root canal system
 - ii. Protects the patient's airway.
 - iii. Reduces contaminated aerosols in the dental operatory
- Ill-fitting or poorly applied dental dam will result in contamination of operative field and increased aerosol production, so any flaws should be remedied before the start of procedure.
- If a patient refuses the use of dental dam owing to medical concerns such as asthma or mouth breathing, comfort issues like gagging or claustrophobia, it does not mean we should perform treatment without it.
- It is responsibility of treating dentist to explain why dental dam is essential, and if the patient still cannot or will not tolerate it, then it is also the treating dentist's responsibility to decline to proceed with treatment.
- If dental dam is unable to be placed, the patient should either be referred to an endodontist for management or to prosthodontist for restorative treatment to allow for dam placement, or consider alternatives like extraction.

Duty of clinicians:

- Clinicians have a duty to warn the patients of possible risk and complication prior to patient's consenting for medical procedures.
- All patients 18 years and above have capacity to consent for themselves unless proven otherwise.
- However if a patient is incapacitated, consent can be taken from in order of preference:
 - a) A valid advanced directive/will.
 - b) Court appointed guardian
 - c) Patients attorney
 - d) Responsible family member- 1) Spouse 2) Children 3) Parents 4) Siblings 5) Grandparent 6) Grandchildren 7) Uncle/Aunt 8) Nephew/Niece
 - e) Dentist can decide if the treatment is in patients bests interest or not.
- Implied consent: Which is a form of assumed consent as a patient arrives and sits in a dental chair is valid for examination only, anything further including tests or investigation or treatment requires an explicit informed consent.

DISCLAIMER

THIS IS COPYRIGHTED CONTENT. Unauthorized use, including screenshots, copying, misuse, reuse, or resale of any content from this app, is strictly prohibited. Our app monitors and records all screenshots and recordings. Violators will face strict legal action.

DISCLAIMER
THIS IS COPYRIGHTED CONTENT. Unauthorized use, including screenshots, copying, misuse, reuse, or resale of any content from this app, is strictly prohibited. Our app monitors and records all screenshots and recordings. Violators will face strict legal action.

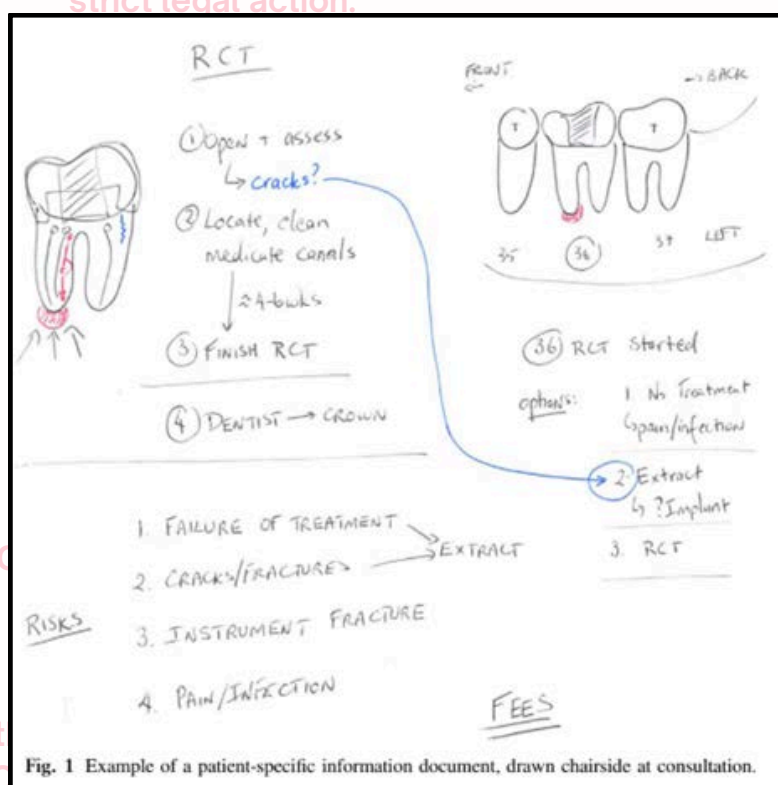
THIS IS COPYRIGHTED CONTENT. Unauthorized use, including screenshots, copying, misuse, reuse, or resale of any content from this app, is strictly prohibited. Our app monitors and records all screenshots and recordings. Violators will face strict legal action.

DISCLAIMER

MEDICAL LEGAL CONSIDERATIONS IN ENDODONTICS

Source-Articles

- The possible risks of treatment if not explained to the patient prior to the proposed treatment then the treating doctor will be liable to charges.
- A doctor has a duty to warn the patient of a material risk inherent in the proposed treatment. Determining what risks are material has two aspects, the objective aspect which refers to those risk that any reasonable patient would find material and subjective aspect which refers to those risk that a particular patient in context would find material.
- Patients usually have poor recollection of the information provided regarding dental procedure which can be improved with written information as well as verbal discussion.
- To gain a valid consent from a patient, following is required:
 - a) Patient must have capacity to consent
 - b) Patient must understand the information that is provided.
 - c) A discussion of all the reasonable options and alternative including the option of no treatment should be provided.
 - d) The consequences of not proceeding with treatment should be mentioned.
 - e) Patients should be warned about the material risk pertaining to the procedure.
 - f) Patient has the right to decide (Either consent or refuse) the treatment.



all screenshots and recordings. Violators will face strict legal action.

DISCLAIMER

THIS IS COPYRIGHTED CONTENT. Unauthorized use, including screenshots, copying, misuse, reuse, or resale of any content from this app, is strictly prohibited. Our app monitors and records all screenshots and recordings. Violators will face strict legal action.

DISCLAIMER
THIS IS COPYRIGHTED CONTENT. Unauthorized use, including screenshots, copying, misuse, reuse, or resale of any content from this app, is strictly prohibited. Our app monitors and records all screenshots and recordings. Violators will face strict legal action.

MEDICAL LEGAL CONSIDERATIONS IN ENDODONTICS

Source-Articles

Possible Complications and Patients right to complaint:

- When a patient suffers harm or believe they have been subjected to malpractice they have a right to make a complaint.
- They can complaint directly to the clinic/clinician, professional organizations such as ADA or regulatory bodies.
- Dentists have the highest rates of complaints amongst which Endodontics has the highest number of complaints in Australia.
- Complications can occur with endodontic procedures, however poor communication is the common cause of complaints. Dentists might not understand what information must be provided to gain a valid consent.
- Information about risk must be provided in such a way that the patient can understand and a written consent should be taken.
- Discussions about potential complication should be done on case by case basis depending on patient, tooth, site, restorative status, pulp anatomy and surrounding structures.
- A shortlist of possible risk in endodontics but not limited to this is provided:

- Failure of treatment
- Cracks/fractures of tooth structure
- Instrument fracture
- Post-operative pain or infection
- Perforation
- Discolouration
- Restoration fracture or loss
- Failure to anaesthetize
- Altered sensation
- Extrusion of medicament and/or root-filling material
- Inability to locate or clean canal anatomy
- Medication-related complications
- Misdiagnosis

- Patients must be explicitly informed about the risk of treatment failure as many can believe that endodontic treatment is for life.
- For example:
 - A) In a patient with bruxism, clenching or traumatic occlusion **risk of failure of treatment** from cracks or fractures should be explained prior to treatment as it is common.
 - B) **Instrument fracture** is an inherent risk of endodontic treatment, which is also a common source of complaints against dentists. Ideally patients should be warned about the risk in the initial consultation as some patient may desire to refrain from treatment and if the breakage does occur during treatment patient should be informed.

DISCLAIMER

THIS IS COPYRIGHTED CONTENT. Unauthorized use, including screenshots, copying, misuse, reuse, or resale of any content from this app, is strictly prohibited. Our app monitors and records all screenshots and recordings. Violators will face strict legal action.

DISCLAIMER

THIS IS COPYRIGHTED CONTENT. Unauthorized use, including screenshots, copying, misuse, reuse, or resale of any content from this app, is strictly prohibited. Our app monitors and records all screenshots and recordings. Violators will face strict legal action.

THIS IS COPYRIGHTED CONTENT. Unauthorized use, including screenshots, copying, misuse, reuse, or resale of any content from this app, is strictly prohibited. Our app monitors and records all screenshots and recordings. Violators will face strict legal action.

DISCLAIMER

MEDICAL LEGAL CONSIDERATIONS IN ENDODONTICS

Source-Articles

- C) **Altered sensation** is one of the most distressing complications that can range from temporary paresthesia, permanent paresthesia, anesthesia or hyperalgesia. Altered sensation is rare following non-surgical endodontic procedure but when it does occur usually follows treatment of mandibular molars and premolars. Surgical endodontics carries a real risk of altered or loss of sensations.
- D) **Significant extrusion of root canal filling material and sealer** into the inferior alveolar canal as it has close anatomical proximity to the roots can lead to harm and subsequent litigation. To mitigate this risk, pre-operative assessment is essential, the use of electronic apex locators, appropriately angulated pre and intraoperative radiographs, CBCT, good length control and care with placement of sealers can be done.
- E) Misdiagnosis or failure to diagnose a endodontic disease is also a common cause of complaint.

Radiography in endodontics:

- Good quality imaging will aid in accurate diagnosis and treatment of a condition.
- While performing endodontic procedures,
 - a) **At least 1 pre-operative radiograph for diagnosis and treatment planning.**
 - b) **One mid treatment radiograph to confirm the working length (even if an Electronic apex locator is used)**
 - c) **One post-operative radiograph to confirm the technical quality of the treatment performed and act as a control for future review is an absolute minimal.**
- Although use of electronic apex locator (EAL) is common, the readings from EAL should be verified with a radiograph.
- Dental dam must also be left in place during mid-treatment radiography.
- When accurate information cannot be obtained from intraoral radiography, CBCT can be used as an adjunct. However, use of CBCT should not be seen as a replacement for intraoral radiography as radiation exposure is more and is cumulative.

THIS IS COPYRIGHTED
CONTENT. Unauthorized use,
including screenshots,
copying, misuse, reuse, or
resale of any content from
this app, is strictly prohibited.
Our app monitors and records
all screenshots and
recordings. Violators will face
strict legal action.

DISCLAIMER

THIS IS COPYRIGHTED CONTENT. Unauthorized use, including screenshots, copying, misuse, reuse, or resale of any content from this app, is strictly prohibited. Our app monitors and records all screenshots and recordings. Violators will face strict legal action.

DISCLAIMER
THIS IS COPYRIGHTED CONTENT. Unauthorized use, including screenshots, copying, misuse, reuse, or resale of any content from this app, is strictly prohibited. Our app monitors and records all screenshots and recordings. Violators will face strict legal action.

DISCLAIMER
THIS IS COPYRIGHTED CONTENT. Unauthorized use, including screenshots, copying, misuse, reuse, or resale of any content from this app, is strictly prohibited. Our app monitors and records all screenshots and recordings. Violators will face strict legal action.

MEDICAL LEGAL CONSIDERATIONS IN ENDODONTICS

Source-Articles

Follow-up in Endodontics:

- Dentists have duty to follow up patients and test results, where appropriate.
- Dental trauma often requires a number of review appointments to ensure the tissues are healing appropriately, and timely manage complications if they occur. Patients must be informed of this as they may not show if they are symptom free.
- Patients must be informed about the importance of returning for reviews and consequences of not reviewing over time appropriately at the initial appointment.
- If the patient does not attend follow-up, they should be contacted to ensure that they will be seen appropriately either by you or another clinician.
- Sometimes patients may be referred to a specialist for a critical situation like avulsion, biopsy for suspected cancer. It is the responsibility of the clinician to ensure that these patients have organized these urgent appointments and patients understands the consequences of not doing so.

Difficult cases and Referral in Endodontics:

- Dentistry is a technically demanding and difficult profession and endodontics specifically deals with smallest environment in mouth with patient commonly experiencing pain and anxiety.
- Managing difficult patient requires a calm and professional approach. Empathy and listening skills are important as most patients will respond in their own way to cope with anxiety.

Anxious patients:

- These patients require more time to manage appropriately. Anxiety can manifest as distrust and behaviors that can cause stress in dentist patient relationship.
- Anxiety can lead to patients presenting with inconsistent histories and clinical findings, like nervous positive response to pulp testing which can lead to misdiagnosis.
- Extra time to appropriately manage anxious patients and modify behavior is essential to ensure patient is comfortable during treatment.
- Some patients can display aggressive and antisocial behavior, all practitioners have right to feel safe and maintain a safe environment for their staff.
- Dentists have no obligation to treat patients showing aggressive, threatening, abusive or racist behavior, provided it is not for discriminatory reasons. But, in such cases they should offer patient alternative options for their care.
- Legal advice may sometimes be required to terminate this clinician patient relationship so that the patient is still managed appropriately and the clinician's duty of care is maintained.

DISCLAIMER

THIS IS COPYRIGHTED CONTENT. Unauthorized use, including screenshots, copying, misuse, reuse, or resale of any content from this app, is strictly prohibited. Our app monitors and records all screenshots and recordings. Violators will face strict legal action.

DISCLAIMER

THIS IS COPYRIGHTED CONTENT. Unauthorized use, including screenshots, copying, misuse, reuse, or resale of any content from this app, is strictly prohibited. Our app monitors and records all screenshots and recordings. Violators will face strict legal action.

THIS IS COPYRIGHTED CONTENT. Unauthorized use, including screenshots, copying, misuse, reuse, or resale of any content from this app, is strictly prohibited. Our app monitors and records all screenshots and recordings. Violators will face strict legal action.

DISCLAIMER

MEDICAL LEGAL CONSIDERATIONS IN ENDODONTICS

Source-Articles

Right to Refuse:

- Just as the patient has right to refuse treatment clinician has right to refuse to a particular treatment, if it is not for discriminatory reasons.
- For example, in endodontics this could be, a patient insisting that an unrestorable tooth be saved when there is no reasonable possibility of treatment success. Or, a patient pushing the dentist to perform treatment that is beyond their scope or technical capabilities.
- However, declining a patient to treatment does carry responsibilities.
- Practitioner needs to inform the patient that they are welcome to seek a second opinion from another clinician.
- Practitioner must also facilitate transfer of treatment notes and clinical information where appropriate.

Referral:

- Referral is an essential and normal part of health care.
- Referral can be forwarding a patient to a senior colleague in the same practice, to a formal referral to an external specialist.
- Dentist must ensure that they have delegated the patient's care to a clinician with adequate training, skills and experience to provide adequate care.
- All clinician must ensure that they are working within the scope of their knowledge and training.
- When a patient reports to clinicians (general dentist or specialist) with teeth that have endodontic treatment initiated elsewhere, it is essential to make a preoperative assessment, confirmation of diagnosis and obtaining a valid consent before continuing treatment in such cases. This includes taking new pre-operative radiographs esp. if significant time has elapsed or if procedures have been performed in between.
- In cases, where a patient attend specialist for only part of management like retrieving broken instrument or locating a second mesio-buccal canal, (this is done mostly to reduce the financial burden on the patient) problems can occur regarding who will be responsible for the outcome if the patient decides to file a complaint in the event of treatment failure. So, for this reason it is best practice that a specialist who is taking over a management of the case should also complete the treatment.
- Assessment of difficulty is a skill learned over time, The AAE Case Difficulty Assessment Form is a useful tool to guide practitioners to assess difficulties which might require further experience or referral.
- Indemnity companies and ADA state branch often employ experienced clinicians as Community Relations Officers (CROs) who can assist dentist when difficult situations occur.
- Therefore, it is essential that all dentist inform their indemnity insurance of any patient interaction that might result in complaint. This ensures that further management is done appropriately.

DISCLAIMER

THIS IS COPYRIGHTED CONTENT. Unauthorized use, including screenshots, copying, misuse, reuse, or resale of any content from this app, is strictly prohibited. Our app monitors and records all screenshots and recordings. Violators will face strict legal action.

THIS IS COPYRIGHTED CONTENT. Unauthorized use, including screenshots, copying, misuse, reuse, or resale of any content from this app, is strictly prohibited. Our app monitors and records all screenshots and recordings. Violators will face strict legal action.

DISCLAIMER
THIS IS COPYRIGHTED CONTENT. Unauthorized use, including screenshots, copying, misuse, reuse, or resale of any content from this app, is strictly prohibited. Our app monitors and records all screenshots and recordings. Violators will face strict legal action.

DISCLAIMER

ENDODONTIC GUIDELINES IN NON-SURGICAL TREATMENTS

Source-Articles on non-surgical treatments in endodontics, irrigation technique, obturation technique

- The primary objective of endodontic treatment is to preserve the natural dentition through the prevention and/or treatment of pulpal and periradicular pathosis.
- The ASE (Australian Society of Endodontology Inc.) developed these guidelines that illustrate contemporary practice standards for root canal treatment supported by evidence.
- General dentists should have the required knowledge and experience regarding endodontic treatment to perform most non-surgical root canal procedures in uncomplicated permanent tooth.
- The standards of practice are constantly changing based on new evidences and technology. It is the responsibility of all practitioner to be lifelong learners to meet contemporary standards.
- Integration with or referral to specialist endodontist is still desirable in certain cases but referral may not be practicable in certain locations in Australia, hence the general dentist need to understand and practice within their competency to manage more complex cases if they choose to treat them.
- The scope of endodontics in dental practice includes:

The scope of endodontics in dental practice includes:

- Differential diagnosis and treatment of pain and/or swelling of pulpal and/or periapical origin.
- Urgent/emergency treatment of pain and/or swelling to include the pharmacologic use of antibiotics, anti-inflammatory agents, analgesic drugs and incision for drainage of localised abscesses.
- Urgent/emergency management of traumatic injuries to the dentoalveolar structures.
- Vital pulp treatment including pulp capping, and pulpotomy procedures.
- Non-surgical root canal treatment for the permanent dentition.
- Bleaching of discoloured teeth.
- Treatment procedures such as post and/or cores involving the root canal space.

CONTENT. Unauthorized use, including screenshots, copying, misuse, reuse, or resale of any content from this app, is strictly prohibited. Our app monitors and records all screenshots and recordings. Violators will face strict legal action.

DISCLAIMER

THIS IS COPYRIGHTED CONTENT. Unauthorized use, including screenshots, copying, misuse, reuse, or resale of any content from this app, is strictly prohibited. Our app monitors and records all screenshots and recordings. Violators will face strict legal action.

DISCLAIMER

THIS IS COPYRIGHTED CONTENT. Unauthorized use, including screenshots, copying, misuse, reuse, or resale of any content from this app, is strictly prohibited. Our app monitors and records all screenshots and recordings. Violators will face strict legal action.

DISCLAIMER

THIS IS COPYRIGHTED CONTENT. Unauthorized use, including screenshots, copying, misuse, reuse, or resale of any content from this app, is strictly prohibited. Our app monitors and records all screenshots and recordings. Violators will face strict legal action.

ENDODONTIC GUIDELINES IN NON-SURGICAL TREATMENTS

Source-Articles on non-surgical treatments in endodontics, irrigation technique, obturation technique

- The best approach to be followed by a competent practitioner in non-surgical treatment of root canal system includes following these aspects:

1) Diagnosis and Case difficulty assessment

Objective:

- An accurate endodontic diagnosis is crucial for formulating the treatment plan and it also assists with the determination of the prognosis.
- The assessment of a case involves:
 - Identification of the etiology of pulpal and periapical conditions
 - Determination of case difficulty and potential risks
- This assessment will help to decide whether to proceed with the treatment or if the referral of the patient to specialist is more appropriate.
- Root canal treatment should never be initiated without documenting diagnosis or assessing the restorability.

Rationale for case difficulty assessment:

- When the case difficulties are recognized and understood prior to treatment it will reduce or prevent adverse outcomes to the patient and reduce the risk of dentolegal problems for dental practitioners.
- If a dental practitioner encounter a case that is beyond their capabilities, they should refer the patient in a timely manner for specialist management.

The quality standard criteria for diagnosis and case difficulty assessment are:

- A definitive endodontic diagnosis should be documented, using terms for both pulpal and periapical diagnosis.
- A definitive diagnosis is reached only after integrating the patients dental and pain history (which gives provisional diagnosis) with clinical and radiographic examination that is also supported by specific tests.
- Case difficulty assessment as well as self-assessment for competency should be done before carrying out endodontic treatment.

The considerations and clinical approach involves:

- History including medical, dental, pain history and the patients presenting complaint will help to formulate a provisional diagnosis.
- After that all the relevant information from clinical and radiographic examination with the results of diagnostic test should be combined to confirm the diagnosis.

DISCLAIMER

THIS IS COPYRIGHTED CONTENT. Unauthorized use, including screenshots, copying, misuse, reuse, or resale of any content from this app, is strictly prohibited. Our app monitors and records all screenshots and recordings. Violators will face strict legal action.

DISCLAIMER

THIS IS COPYRIGHTED CONTENT. Unauthorized use, including screenshots, copying, misuse, reuse, or resale of any content from this app, is strictly prohibited. Our app monitors and records all screenshots and recordings. Violators will face strict legal action.

THIS IS COPYRIGHTED CONTENT. Unauthorized use, including screenshots, copying, misuse, reuse, or resale of any content from this app, is strictly prohibited. Our app monitors and records all screenshots and recordings. Violators will face strict legal action.

DISCLAIMER

ENDODONTIC GUIDELINES IN NON-SURGICAL TREATMENTS

Source-Articles on non-surgical treatments in endodontics, irrigation technique, obturation technique

Chief complaint. History of symptoms (if any)
 Medical and dental history. History of dental trauma (if any)
 Clinical examination—extra-oral and intra-oral examination
 Radiographic examination may include periapical radiograph(s), maxillary or mandibular occlusal radiograph, bitewing(s), limited FOV cone-beam computed tomography
 Clinical tests may include percussion, palpation, thermal/electric pulp testing, mobility, periodontal probing, transillumination, tooth slooth

Radiographs:

- Periapicals are the standard in root canal treatment.
- Limited Field of view (FOV) Cone beam computed tomography (CBCT) has been used recently in cases where diagnosis cannot be made based on Periapicals alone.

What not to do during case assessment

- Initiate root canal treatment without a documented diagnosis or assessment of restorability.
- Initiate root canal treatment in a case exceeding personal competence level.
- Initiate root canal treatment simply based on radiographic findings, such as the presence of a periapical radiolucency.
- Initiate root canal treatment without informing the patient of the diagnosis, case difficulty level and relevant complications and risks.
- Initiate root canal treatment in a complex case without informing the patient of the option of consulting a specialist.
- Use non-diagnostic terms in dental records.

2) Access cavity preparation

Objective:

- It is the first step in non-surgical endodontic treatment which is essential to reach the internal anatomy of the tooth.
- An ideal access cavity should allow unhindered entry to the complete root canal anatomy without excessive destruction of tooth structure.

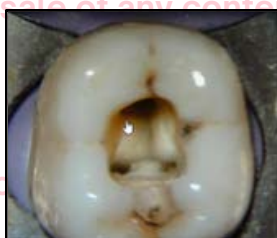

Image - Access cavity of a lower first molar; note the three canal orifices are connected by developmental (dark) lines. These lines are sometimes referred to as the dentine map. (Source-internet)

DISCLAIMER

THIS IS COPYRIGHTED CONTENT. Unauthorized use, including screenshots, copying, misuse, reuse, or resale of any content from this app, is strictly prohibited. Our app monitors and records all screenshots and recordings. Violators will face strict legal action.

DISCLAIMER

THIS IS COPYRIGHTED CONTENT. Unauthorized use, including screenshots, copying, misuse, reuse, or resale of any content from this app, is strictly prohibited. Our app monitors and records all screenshots and recordings. Violators will face strict legal action.

THIS IS COPYRIGHTED CONTENT. Unauthorized use, including screenshots, copying, misuse, reuse, or resale of any content from this app, is strictly prohibited. Our app monitors and records all screenshots and recordings. Violators will face strict legal action.

DISCLAIMER

THIS IS COPYRIGHTED CONTENT. Unauthorized use, including screenshots, copying, misuse, reuse, or resale of any content from this app, is strictly prohibited. Our app monitors and records all screenshots and recordings. Violators will face strict legal action.

ENDODONTIC GUIDELINES IN NON-SURGICAL TREATMENTS

Source-Articles on non-surgical treatments in endodontics, irrigation technique, obturation technique

Rationale:

- Inadequate access cavity preparation can lead to missed canal, inadequate cleaning, shaping and obturation, iatrogenic error, undetectable cracks and even failure of root canal treatment.
- The access cavity should act as a reservoir for an irrigant which will act as a disinfectant and lubricant,
- It should also allow placement of suitable interim restoration.

The quality standard criteria for access cavity preparation are:

- a) First step is isolation with rubber dam.
- b) Adequate access cavity preparation should have an unimpeded access to all canal orifices and into root canal system.
- c) This should be done with minimal removal of tooth structure.
- d) The size of cavity should be appropriate-neither too small to hinder cleaning nor too wide compromising the integrity of tooth structure,
- e) If root canal access is exceedingly difficult pre-operative referral to specialist should be done.(e.g. With calcified pulp space or presence of extra coronal restoration)

Clinical approach and considerations for access cavity preparation:

- a) Anatomical landmarks, esp. CEJ serve as a reliable guide to accessing the pulp chamber. The pulp chamber is always at the center of the tooth at the level of CEJ.
- b) Assessment of the long axis of tooth is also important as inclined tooth are prone to perforations when the bur is not directed accordingly.
- c) It should be planned by visualizing and analyzing the tooth anatomy, clinical examination of hard and soft tissues around tooth and radiographic evaluation of pulp chamber to identify the shape, size and any calcifications.

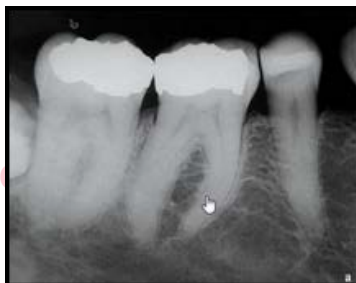

Image: Lower first molar with significantly reduced pulp chamber height, pulp calcifications and signs of canal sclerosis; this tooth will be more challenging to access.

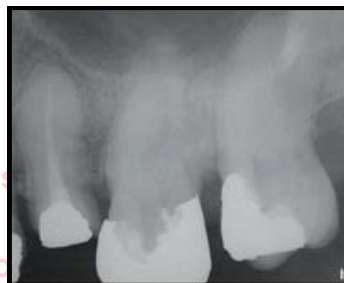

Image: The canals in this upper first molar tooth appear to be completely sclerosed.

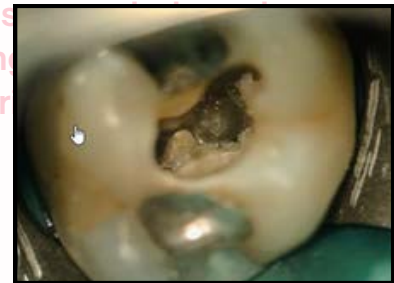

Image: Pulp calcifications obscuring the canal orifices

DISCLAIMER

THIS IS COPYRIGHTED CONTENT. Unauthorized use, including screenshots, copying, misuse, reuse, or resale of any content from this app, is strictly prohibited. Our app monitors and records all screenshots and recordings. Violators will face strict legal action.

DISCLAIMER

THIS IS COPYRIGHTED CONTENT. Unauthorized use, including screenshots, copying, misuse, reuse, or resale of any content from this app, is strictly prohibited. Our app monitors and records all screenshots and recordings. Violators will face strict legal action.

THIS IS COPYRIGHTED CONTENT. Unauthorized use, including screenshots, copying, misuse, reuse, or resale of any content from this app, is strictly prohibited. Our app monitors and records all screenshots and recordings. Violators will face strict legal action.

DISCLAIMER

ENDODONTIC GUIDELINES IN NON-SURGICAL TREATMENTS

Source-Articles on non-surgical treatments in endodontics, irrigation technique, obturation technique

- d) Appropriate coronal access provides convenience form, the concept of straight line access to the orifice minimized procedural errors in subsequent procedures.

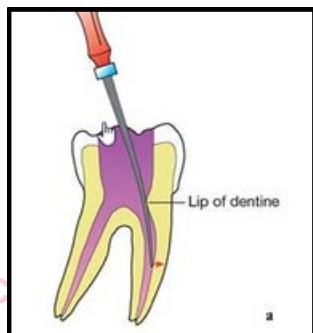


Image-Inadequate straight line access resulting in the tip of the file attempting to straighten itself (red arrow).

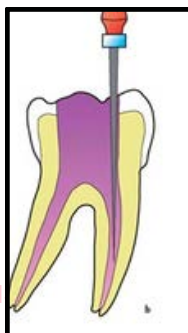

Image-Refining the shape of the access cavity results in unimpeded, straight line access into the root canal.

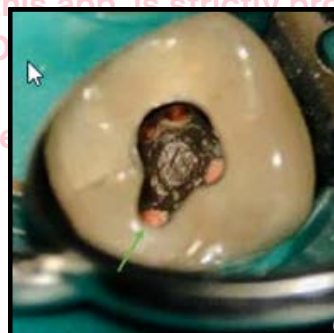


Image-The mesio-buccal corner of the access cavity has been modified (green arrow) to ensure straight line access into the mesiobuccal canal of this lower molar.

- e) To facilitate visualization of any existing cracks or caries beneath a restoration removal of existing restoration is recommended.
- f) All caries should be removed before gaining access into pulp chamber.
- g) The access is completed when the coronal dentine does not hinder access to instrumentation of root canals.

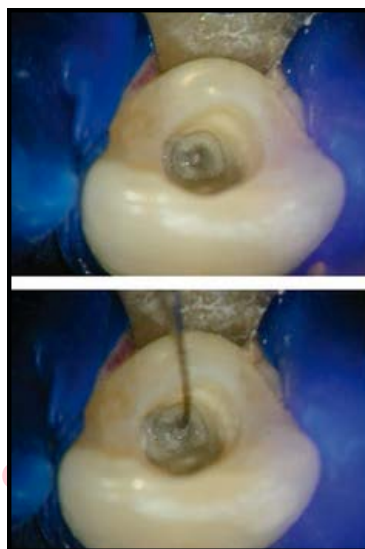

Image: a) Access cavity in an upper incisor with correct orientation allowing excellent visualization b) Although the canal is sclerosed it can still be located and negotiated with a small file.

What not to do during access cavity preparation

- Leave residual caries beneath existing or defective restorations.
- Prepare the access cavity too small or too large (overextension into the walls or floor of the pulp chamber).
- Inadequately remove pulp stones or other mineralisations.
- Excessively sacrifice dentine or perforate the pulp chamber floor.
- Create damage to the pulpal floor obscuring root canal orifices.

DISCLAIMER

THIS IS COPYRIGHTED CONTENT. Unauthorized use, including screenshots, copying, misuse, reuse, or resale of any content from this app, is strictly prohibited. Our app monitors and records all screenshots and recordings. Violators will face strict legal action.

DISCLAIMER

THIS IS COPYRIGHTED CONTENT. Unauthorized use, including screenshots, copying, misuse, reuse, or resale of any content from this app, is strictly prohibited. Our app monitors and records all screenshots and recordings. Violators will face strict legal action.

DISCLAIMER

THIS IS COPYRIGHTED CONTENT. Unauthorized use, including screenshots, copying, misuse, reuse, or resale of any content from this app, is strictly prohibited. Our app monitors and records all screenshots and recordings. Violators will face strict legal action.

ENDODONTIC GUIDELINES IN NON-SURGICAL TREATMENTS

Source-Articles on non-surgical treatments in endodontics, irrigation technique, obturation technique

3) Root Canal Preparation:

Objective:

- The objective of root canal preparation is to facilitate the disinfection and obturation of root canal space.
- A tapered shape preparation from the orifice is done to provide apical resistance form during obturation.

Rationale:

- Root canal preparation allows the removal of canal contents and penetration of irrigation solutions into the apical and lateral spaces of the root canal system.
- Preparation errors like ledges and perforation significantly reduces the clinical outcomes.

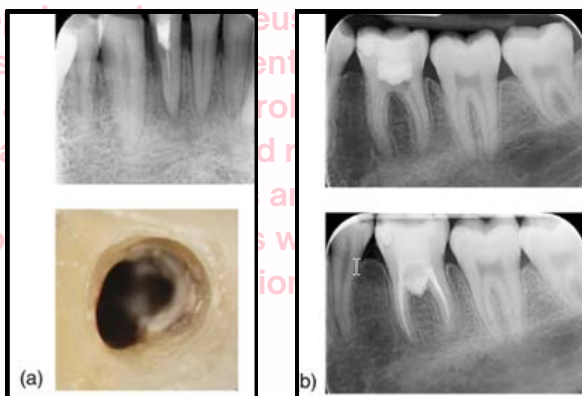


Image: a) Lateral perforation of mandibular anterior (clinical and radiographic view)
b) perforation into the furcation of mandibular molar

- A minimum canal size of (e.g. Size 25 with apical 0.06 taper) is desirable for adequate irrigation and antimicrobial effect.
- Adequate removal of canal content, microorganisms and biofilm, requires a direct and prolonged contact of irrigants with the canal wall.

The quality standard criteria for root canal preparation are:

- a) A conscious determination and maintenance of exact apical endpoint of preparation (i.e. the working length) should be done and canal preparation should be restricted to the confines of the root canal space. The importance of accurately determining the working length (from the coronal reference point to the apical endpoint of the root canal) is critical.
- b) The canal preparation should be done in consistent manner such that there is ability to predictably enlarge canal spaces to mechanically remove vital or necrotic tissues and microorganisms.
- c) The preparation should provide effective space for antimicrobial solutions and intracanal medicament, including effective space for the insertion and compaction of obturating material to the determined working length.

DISCLAIMER

THIS IS COPYRIGHTED CONTENT. Unauthorized use, including screenshots, copying, misuse, reuse, or resale of any content from this app, is strictly prohibited. Our app monitors and records all screenshots and recordings. Violators will face strict legal action.

DISCLAIMER

THIS IS COPYRIGHTED CONTENT. Unauthorized use, including screenshots, copying, misuse, reuse, or resale of any content from this app, is strictly prohibited. Our app monitors and records all screenshots and recordings. Violators will face strict legal action.

THIS IS COPYRIGHTED CONTENT. Unauthorized use, including screenshots, copying, misuse, reuse, or resale of any content from this app, is strictly prohibited. Our app monitors and records all screenshots and recordings. Violators will face strict legal action.

DISCLAIMER

ENDODONTIC GUIDELINES IN NON-SURGICAL TREATMENTS

Source-Articles on non-surgical treatments in endodontics, irrigation technique, obturation technique

The quality standard criteria for root canal preparation are:

- d) Instruments and treatment sequences should be selected such that it will minimize the damage to radicular structures.
- e) Dentists should have in-depth understanding of procedural errors development and ways to avoid them.
- f) Patient oriented decision making should be done and there should be candid communication when recognizing the procedural errors.

Clinical approach and consideration in root canal preparation:

- Each tooth has unique anatomy and morphology, hence there is no standardized apical canal preparation size or width.
- Canal shaping is dictated by initial canal size, irrigation regime, and obturation technique employed, however, a minimum canal size is currently required for adequate cleaning and obturation.
- The ideal apical point of termination of root canal preparation which is the working length is 0.5-1.0 mm from the radiographic apex.
- The working length should be determined by electronic apex locator in conjunction with verifying radiographs.
- Care must be taken that apical canal enlargement is not done at an excessive expense of coronal dentine (Like in molar and premolars the thickness of radicular wall near furcation is in some sections 1.0mm or less) where perforation can occur.
- In RCT of teeth with vital pulp complete removal of pulp tissue and creating space for obturating material is usually sufficient, however, in cases with infected pulpal necrosis antimicrobial efficiency is of utmost importance.
- Mechanical enlargement of canal spaces (both with hand files and rotary instruments) dramatically decreases the presence of microorganisms present in the canal however it cannot render the canal system sterile.
- So, the use of antimicrobial irrigants is essential in addition to mechanical preparation technique.

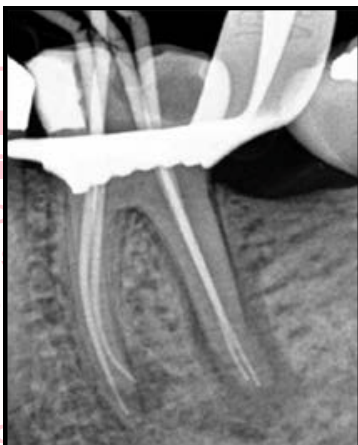


Image: Master cone radiograph. The four separate canals are terminating at different lengths. It would not have been possible to estimate this accurately using a preoperative radiograph only, and an apex locator with radiograph was essential

DISCLAIMER

THIS IS COPYRIGHTED CONTENT. Unauthorized use, including screenshots, copying, misuse, reuse, or resale of any content from this app, is strictly prohibited. Our app monitors and records all screenshots and recordings. Violators will face strict legal action.

DISCLAIMER

THIS IS COPYRIGHTED CONTENT. Unauthorized use, including screenshots, copying, misuse, reuse, or resale of any content from this app, is strictly prohibited. Our app monitors and records all screenshots and recordings. Violators will face strict legal action.

THIS IS COPYRIGHTED CONTENT. Unauthorized use, including screenshots, copying, misuse, reuse, or resale of any content from this app, is strictly prohibited. Our app monitors and records all screenshots and recordings. Violators will face strict legal action.

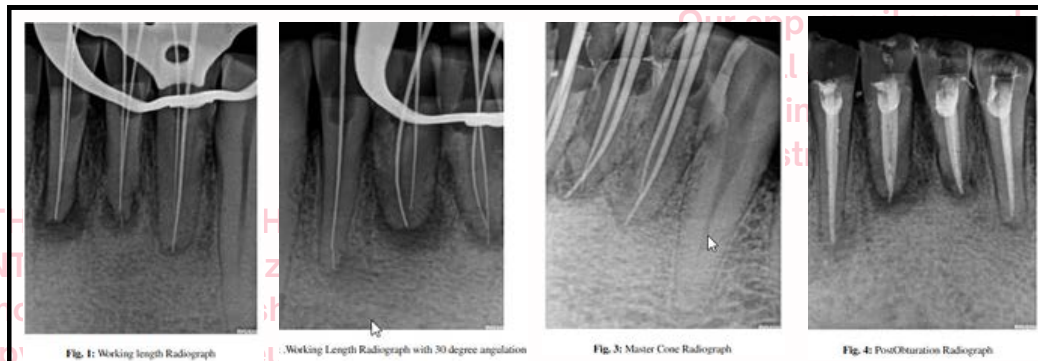
DISCLAIMER

ENDODONTIC GUIDELINES IN NON-SURGICAL TREATMENTS

Source-Articles on non-surgical treatments in endodontics, irrigation technique, obturation technique

Clinical approach and consideration in root canal preparation:

- Presented below is a series of radiograph taken during root canal treatment.
(Source-Internet: research gate)



What not to do during canal preparation

- Overextend working length and thereby over-enlarge the apical foramen.
- Use excessively large files in a curved canal with the result of various preparation errors.
- Work in a dry canal.
- Prematurely use larger files, resulting in canal straightening.
- Overuse and overwork files, risking file fracture.

4) Irrigation and medicament used in root canal treatment:

Objective:

- The objective of root canal preparation is to facilitate the disinfection and obturation of root canal space.
- A tapered shape preparation from the orifice is done to provide apical resistance form during obturation.

THIS IS COPYRIGHTED CONTENT. Unauthorized use, including screenshots, copying, misuse, reuse, or resale of any content from this app, is strictly prohibited. Our app monitors and records all screenshots and recordings. Violators will face strict legal action.

DISCLAIMER

THIS IS COPYRIGHTED CONTENT. Unauthorized use, including screenshots, copying, misuse, reuse, or resale of any content from this app, is strictly prohibited. Our app monitors and records all screenshots and recordings. Violators will face strict legal action.

DISCLAIMER
THIS IS COPYRIGHTED CONTENT. Unauthorized use, including screenshots, copying, misuse, reuse, or resale of any content from this app, is strictly prohibited. Our app monitors and records all screenshots and recordings. Violators will face strict legal action.

DISCLAIMER

THIS IS COPYRIGHTED CONTENT. Unauthorized use, including screenshots, copying, misuse, reuse, or resale of any content from this app, is strictly prohibited. Our app monitors and records all screenshots and recordings. Violators will face strict legal action.

ENDODONTIC GUIDELINES IN NON-SURGICAL TREATMENTS

Source-Articles on non-surgical treatments in endodontics, irrigation technique, obturation technique

4) Irrigation and medicament used in root canal treatment:

Objective:

- The primary purpose of using the root canal irrigants is to treat and prevent the recurrence of infection and biofilms within the root canal system.
- It also provides lubrication for mechanical canal preparation, flushes debris out, dissolves organic tissue remnants and remove the smear layer.
- Inaccessible areas like Fins, isthmus, lateral canals are not contacted during instrumentations and debris and biofilm can remain here, thus, irrigation is needed to complement mechanical preparation to achieve effective disinfection.
- It also removes the smear layer created during instrumentation. Smear layers can harbor microorganisms and prevent the penetration of antimicrobial agents and sealers into the dentinal tubules.
- Irrigation is also required to dissolve the organic material (in the form of vital or necrotic pulp) and the organic components of biofilm.
- When endodontic treatment is completed over multiple appointments intracanal medicaments are used (antimicrobial or anti-inflammatory pastes)

The quality standard criteria for the use of irrigation and medicaments are:

- a) Utilization of rubber dam which is mandatory in root canal treatment.
- b) When using positive pressure technique using side vented needle that does not bind in the canal.
- c) Excessive pressure during irrigation should be avoided.
- d) Irrigants and medicaments should be placed within the confines of the root canal.
- e) Dentist must understand the safety, efficacy, usage features and interactions of all materials used.

THIS IS COPYRIGHTED
CONTENT. Unauthorized use,
including screenshots,
copying, misuse, reuse, or
resale of any content from
this app, is strictly prohibited.
Our app monitors and records
all screenshots and
recordings. Violators will face
strict legal action.

DISCLAIMER

THIS IS COPYRIGHTED CONTENT. Unauthorized use, including screenshots, copying, misuse, reuse, or resale of any content from this app, is strictly prohibited. Our app monitors and records all screenshots and recordings. Violators will face strict legal action.

DISCLAIMER

THIS IS COPYRIGHTED CONTENT. Unauthorized use, including screenshots, copying, misuse, reuse, or resale of any content from this app, is strictly prohibited. Our app monitors and records all screenshots and recordings. Violators will face strict legal action.

DISCLAIMER

THIS IS COPYRIGHTED CONTENT. Unauthorized use, including screenshots, copying, misuse, reuse, or resale of any content from this app, is strictly prohibited. Our app monitors and records all screenshots and recordings. Violators will face strict legal action.

ENDODONTIC GUIDELINES IN NON-SURGICAL TREATMENTS

Source—Articles on non-surgical treatments in endodontics, irrigation technique, obturation technique

Clinical approach and considerations for irrigants and medicaments:

Solutions and medicaments used in root canal systems:

- Properties of an ideal irrigating material are given below but there is no single material which has all the properties hence combination of solution in specific sequence is used.

Attributes of an ideal irrigant

Effectiveness in core functions—broad spectrum antimicrobial action, including biofilm disinfection and dissolution in areas of complex canal anatomy, removal of smear layer and dissolution of vital and necrotic pulp.

Tooth factors—non-staining, maintenance of tooth mechanical properties, compatibility with dental materials, lubrication during instrumentation, flushing of debris.

Safety—non-toxic, non-caustic, non-allergenic, non-irritant to periapical tissues.

Cost—low purchase price, rapid action, stable in storage.

Table 1 Characteristics of an optimal irrigating solution in root canal treatment

Characteristics
Low cost
Washing action
Reduction of friction
Improving cutting of dentine by the instruments
Temperature control
Dissolution of organic and inorganic matter
Good penetration within the root canal system
Killing of planktonic microbes
Killing of biofilm microbes
Detachment of biofilm
Non-toxic to periapical tissue
Non-allergenic
Does not react with negative consequences with other dental materials
Does not weaken dentin

DISCLAIMER

THIS IS COPYRIGHTED CONTENT. Unauthorized use, including screenshots, copying, misuse, reuse, or resale of any content from this app, is strictly prohibited. Our app monitors and records all screenshots and recordings. Violators will face strict legal action.

DISCLAIMER

THIS IS COPYRIGHTED CONTENT. Unauthorized use, including screenshots, copying, misuse, reuse, or resale of any content from this app, is strictly prohibited. Our app monitors and records all screenshots and recordings. Violators will face strict legal action.

THIS IS COPYRIGHTED CONTENT. Unauthorized use, including screenshots, copying, misuse, reuse, or resale of any content from this app, is strictly prohibited. Our app monitors and records all screenshots and recordings. Violators will face strict legal action.

resale of any content from this app, is strictly prohibited. Our app monitors and records all screenshots and recordings. Violators will face strict legal action.

ENDODONTIC GUIDELINES IN NON-SURGICAL TREATMENTS

Source-Articles on non-surgical treatments in endodontics, irrigation technique, obturation technique

Sodium Hypochlorite (NaOCl):

- Sodium hypochlorite (NaOCl) is used as a primary irrigant during root canal preparation as it is the only irrigant that disinfects and dissolves the organic material.
- Hypochlorite is used in the concentration of 0.5-6%.
- To maximize the effectiveness of hypochlorite solution it should be frequently refreshed and kept in motion by agitation or continuous irrigation.
- Studies have confirmed the superiority of high concentrations of fluoride over 1 and 2 %.
- Between buffered and unbuffered sodium hypochlorite solution there is no clinically relevant significant difference in the antimicrobial activity.
- Hypochlorite solution is used throughout instrumentation, but the canal should be rinsed in between the use of Hypochlorite and EDTA or Hypochlorite and CHX (Chlorhexidine) with saline or sterile water, because:
 - Alternating use of NaOCl and EDTA without in-between rinse of water or saline will abolish the antibacterial activity of NaOCl, the tissues that have been exposed to EDTA will not be effectively dissolved by NaOCl.
 - If NaOCl is used immediately after EDTA as a final rinse then it causes erosion on dentine.
 - If hypochlorite comes in contact with CHX, an orange precipitate that contains potential carcinogenic PCA (Para-Chloroaniline) is formed.
- Sterile saline and water cannot be used as main irrigant as they neither have tissue dissolving ability nor antimicrobial activity.

EDTA:

- EDTA is a chelator that is used after hypochlorite, EDTA is neutral or slightly alkaline. Precipitation of EDTA occurs at acidic pH.
- Smear layer removal (inorganic component) is achieved by 1 min irrigation of 15-17% EDTA.
- EDTA only affects the inorganic part of the dentine and the smear layer, and complete removal can only be achieved when NaOCl is used as the first rinse before EDTA.
- EDTA has little or no antimicrobial activity.
- When mixed with CHX, EDTA forms a cloudy precipitate, when mixed or alternated with NaOCl it weakens the activity of NaOCl.
- After the use of EDTA a final antimicrobial rinse is often done with NaOCl but it should be brief due to the potential erosive effect.

DISCLAIMER

THIS IS COPYRIGHTED CONTENT. Unauthorized use, including screenshots, copying, misuse, reuse, or resale of any content from this app, is strictly prohibited. Our app monitors and records all screenshots and recordings. Violators will face strict legal action.

DISCLAIMER

THIS IS COPYRIGHTED CONTENT. Unauthorized use, including screenshots, copying, misuse, reuse, or resale of any content from this app, is strictly prohibited. Our app monitors and records all screenshots and recordings. Violators will face strict legal action.

DISCLAIMER

THIS IS COPYRIGHTED CONTENT. Unauthorized use, including screenshots, copying, misuse, reuse, or resale of any content from this app, is strictly prohibited. Our app monitors and records all screenshots and recordings. Violators will face strict legal action.

ENDODONTIC GUIDELINES IN NON-SURGICAL TREATMENTS

Source-Articles on non-surgical treatments in endodontics, irrigation technique, obturation technique

Chlorhexidine (CHX):

- CHX is used in dentistry for plaque prevention and disinfection because of its good antimicrobial activity.
- CHX is cytotoxic to human cells but it does not cause pain comparable to NaOCl if accidentally extruded to periapical area.
- CHX does not dissolve organic or inorganic matter and therefore it cannot be used as an only irrigating solution.
- CHX binds to hard tissue and remains antimicrobial (the substantivity effect of CHX) which is one of the main reason for its use.
- Allergic reactions has been reported.
- CHX when used is mostly used in concentration of 2 %.

Calcium Hydroxide (Ca (OH)₂):

- It may be used as a paste in multiple visit treatments.
- High PH has been implicated in canal disinfection and may aid in dissolution of pulp remnants.
- When extruded beyond the apex it may cause nerve damage and tissue necrosis.

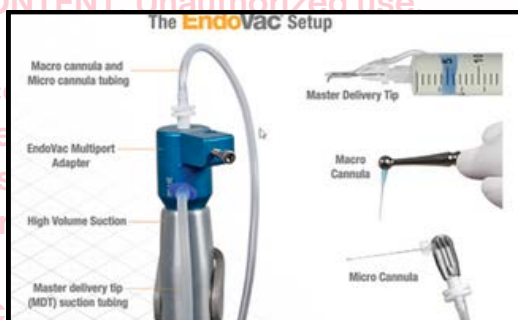Irrigation system used:

- The various methods of irrigation system that are used are:



- 1) Traditional needle and syringe with side vented needles (positive pressure technique)

- 2) Machine driven systems like automatic pumps, vibrating tips, sonic and ultrasonic techniques.
- 3) EndoActivator and Vibratec and other various ultrasonic irrigation technique where the irrigant is directed into the canal through the vibrating tip. The ultrasonic tips deliver irrigants directly into the canal space which helps in cleaning even the most difficult areas such as long and narrow isthmuses between two canals



- 4) The EndoVac uses negative pressure to achieve safe irrigation in the apical canal.

Image-Endovac System (Source-Internet)

DISCLAIMER

THIS IS COPYRIGHTED CONTENT. Unauthorized use, including screenshots, copying, misuse, reuse, or resale of any content from this app, is strictly prohibited. Our app monitors and records all screenshots and recordings. Violators will face strict legal action.

DISCLAIMER
THIS IS COPYRIGHTED CONTENT. Unauthorized use, including screenshots, copying, misuse, reuse, or resale of any content from this app, is strictly prohibited. Our app monitors and records all screenshots and recordings. Violators will face strict legal action.

THIS IS COPYRIGHTED CONTENT. Unauthorized use, including screenshots, copying, misuse, reuse, or resale of any content from this app, is strictly prohibited. Our app monitors and records all screenshots and recordings. Violators will face strict legal action.

DISCLAIMER

ENDODONTIC GUIDELINES IN NON-SURGICAL TREATMENTS

Source-Articles on non-surgical treatments in endodontics, irrigation technique, obturation technique

- b) Studies have shown that agitation of irrigant by active needle irrigation (sonic or ultrasonic activation) increases the tissue dissolution of NaOCl, up to over 10 fold as compared to passive irrigation (no activation or refreshments)
- c) The negative pressure technique (Endovac) can be used for irrigation of the most apical ends of the canals without the risk of extrusion of the solution over positive pressure technique. When positive pressure technique is used side vented needles are safer compared to open ended needles, preferably small gauge needles 27 gauge or 30 gauge (most preferable)
- d) In the EndoVac System the irrigant is applied to the pulp chamber or coronal root canal from where it is sucked down the canal and back via the needle i.e. the direction of the irrigant flow is reversed, which creates the negative pressure at the apical foramen and thereby prevents the possibility of irrigant extrusion.

What not to do during irrigation

- Extrude NaOCl beyond the apex under pressure; extrusion can cause severe swelling and ecchymosis.
- Alternate NaOCl and EDTA irrigation cycles.
- Allow NaOCl to contact CHX, in which case a toxic brown-orange precipitate will form.
- Use local anaesthetic or other non-active irrigation solutions.
- Allow CHX and EDTA to come into contact, in which case a white precipitate will form.

5) Root canal Obturation:

Objective:

- It aims to minimize space in the root canal system after removal of root canal contents, which reduces the ability of any remaining microorganisms to persist and has positive role in the long term outcome of endodontic treatment.

Rationale:

- Root canal obturation should fill the entire root canal system as completely as possible, so that it provides a barrier that prevents nutrients, oral microorganisms and their byproducts from reaching residual microorganisms and the periapical tissues.
- Typical obturation materials include Gutta-Percha (GP) and sealer (cement).
- There are several techniques in clinical use that allow the placement of root canal filling materials to working length, these are cold lateral compaction, Vertical Compaction and Carrier-Based Obturation.

DISCLAIMER

THIS IS COPYRIGHTED CONTENT. Unauthorized use, including screenshots, copying, misuse, reuse, or resale of any content from this app, is strictly prohibited. Our app monitors and records all screenshots and recordings. Violators will face strict legal action.

DISCLAIMER

THIS IS COPYRIGHTED CONTENT. Unauthorized use, including screenshots, copying, misuse, reuse, or resale of any content from this app, is strictly prohibited. Our app monitors and records all screenshots and recordings. Violators will face strict legal action.

THIS IS COPYRIGHTED CONTENT. Unauthorized use, including screenshots, copying, misuse, reuse, or resale of any content from this app, is strictly prohibited. Our app monitors and records all screenshots and recordings. Violators will face strict legal action.

DISCLAIMER

ENDODONTIC GUIDELINES IN NON-SURGICAL TREATMENTS

Source-Articles on non-surgical treatments in endodontics, irrigation technique, obturation technique

The quality standard criteria for root canal obturation are:

- a) Root canal system should be completely filled with obturation material, which should be void free and contained within the root canal system.
- b) The technique and the obturating material used should be appropriate for each case and clinician's skill level.
- c) Sound quality of root canal filling should be demonstrated with radiographs.

Clinical Approach and Considerations for root canal obturation:

- a) The obturation should terminate within 0-1mm from WL and should be well compacted.
- b) Overfilling of root canal filling materials including GP and sealers is related to potential damage of sensitive tissue such as inferior alveolar nerve, inducing paresthesia, anesthesia, hypoesthesia or dysesthesia via mechanical or chemical mechanisms.
- c) Certain conditions like open apices, ledges, transportation of the canal or the proximity to anatomical structures can make obturation difficult and pose a risk of extrusion of filling material.

Materials:

- Gutta Percha is the most common solid root canal filling material, which contains 20% gutta percha, 60-70% Zinc oxide, plasticizing agents (waxes and resins), barium sulfate, coloring agents and trace metals.
- Gutta percha has low level of toxicity, it is also an inert material which causes no lesions of chemical origin if it contacts the neurovascular bundle which makes it the material of choice in endodontic treatment, and hence passage of GP beyond the apex rarely causes paresthesia.
- When using GP clinicians should take into consideration of the different tapers and the consequences to the fit and retention.
- The role of sealer is to fill the minor spaces that cannot be filled with the core material.
- The sealers commonly used are Zinc oxide eugenol base sealers and calcium hydroxide based sealers where zinc oxide eugenol sealer is the most commonly used sealer where toxicity is due to eugenol.
- Recently, for single cone technique calcium-silicate cements have been recommended by ASE guidelines.

DISCLAIMER

THIS IS COPYRIGHTED CONTENT. Unauthorized use, including screenshots, copying, misuse, reuse, or resale of any content from this app, is strictly prohibited. Our app monitors and records all screenshots and recordings. Violators will face strict legal action.

DISCLAIMER

THIS IS COPYRIGHTED CONTENT. Unauthorized use, including screenshots, copying, misuse, reuse, or resale of any content from this app, is strictly prohibited. Our app monitors and records all screenshots and recordings. Violators will face strict legal action.

DISCLAIMER

THIS IS COPYRIGHTED CONTENT. Unauthorized use, including screenshots, copying, misuse, reuse, or resale of any content from this app, is strictly prohibited. Our app monitors and records all screenshots and recordings. Violators will face strict legal action.

ENDODONTIC GUIDELINES IN NON-SURGICAL TREATMENTS

Source-Articles on non-surgical treatments in endodontics, irrigation technique, obturation technique

Obturation technique:

- Several technique has been described and no technique is superior to another.
- The approach to filling of the tooth should be determined by considering the root canal morphology, the skill of the operator, and the available armamentarium, and the technique should be decided prior to starting root canal treatment whenever possible.
- Regardless of the technique used, the final fill should demonstrate no space between canal wall and filling material and should be filled without voids to predetermined working length.
- Broadly, the techniques for filling canal with GP can be divided into -
 - a) Use of Cold gutta-percha: Most simple to master, but cannot be compacted into irregularities within the canal system, which must be filled with sealer. It can be used in number of ways:
 - Full-length single point: Recently use is increased with engine driven systems.
 - Apical (sectional) single point: Not recommended as the technique was unpredictable
 - Lateral condensation: It is the technique of choice for many clinician.
 - 1) It involves placement of master (primary point) at the end point of preparation that should fit properly giving some resistance to withdrawal (tug back) followed by insertion of additional (accessory) point alongside.
 - 2) A spreader is placed alongside the master point, inserted to within 1mm of the end point of preparation, it effectively compacts the master point apically and laterally improving the adaptation of master point and also creating that space for accessory points.
 - 3) The flaring of the canal is mostly done to advance the spreader well into the canal.

The requirements for successful lateral condensation are therefore:

 - 1- A flared canal preparation with a definite apical stop.
 - 2- A well-fitting master gutta-percha point of standard size and taper.
 - 3- A series of spreaders of the appropriate size and shape.
 - 4- An assortment of accessory points which match the size and taper of spreaders.
 - 5- An appropriate sealer.

 - 4) After the initial stages of lateral compaction technique the completion is relatively straight forward which includes:

DISCLAIMER

THIS IS COPYRIGHTED CONTENT. Unauthorized use, including screenshots, copying, misuse, reuse, or resale of any content from this app, is strictly prohibited. Our app monitors and records all screenshots and recordings. Violators will face strict legal action.

DISCLAIMER

THIS IS COPYRIGHTED CONTENT. Unauthorized use, including screenshots, copying, misuse, reuse, or resale of any content from this app, is strictly prohibited. Our app monitors and records all screenshots and recordings. Violators will face strict legal action.

DISCLAIMER

THIS IS COPYRIGHTED CONTENT. Unauthorized use, including screenshots, copying, misuse, reuse, or resale of any content from this app, is strictly prohibited. Our app monitors and records all screenshots and recordings. Violators will face strict legal action.

ENDODONTIC GUIDELINES IN NON-SURGICAL TREATMENTS

Source-Articles on non-surgical treatments in endodontics, irrigation technique, obturation technique

4) After the initial stages of lateral compaction technique the completion is relatively straight forward which includes:

1- The master point, spreader, accessory points and sealer should be carefully arranged to ensure that they can be handled efficiently.

2- The canal should be dried thoroughly with paper points. Use of alcohol to promote effective drying is not recommended for inexperienced operators.

3- The sealer should mix, carried into the canal and smeared (buttered) onto the canal wall. Sealer application can be achieved using a hand file rotated anti-clockwise, by coating a paper point and inserting into the canal, or by coating the master point itself. There is no need to apply a large volume of sealer with spiral filler.




4- The master point should be buttered lightly with sealer and then inserted immediately to the full distance so that to notch made by the tweezers lies at the reference point.

5- The spreader is then placed alongside the point and pushed apically with controlled force until it reached the appropriate depth, 1 mm from the end-point of preparation. The direction of force should be apical with no lateral rocking of the spreader to prevent root fracture. In straight canals the spreader can be rotated at the same time as being pushed apically; however, this is contraindicated in curved canals. Apical pressure should be applied in a constant manner for approximately 10 s to achieve the appropriate compaction of the gutta-percha in an apical and lateral direction. In curved canals the spreader should be applied either lateral to or on the outer aspect of the master point; it should not be applied along the inner aspect of the curve or the spreader is likely to pierce the point and drag it out subsequently.

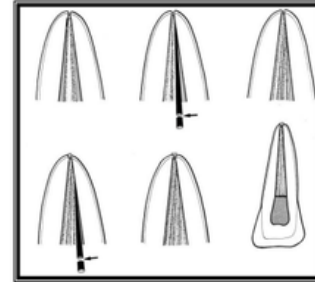
6- The first accessory point should be inserted into the space created by the spreader and seated fully.

7- The spreader is then cleaned and reinserted immediately into the canal as described above. On this occasion the spreader will not enter the canal to the same length.


8- The second accessory point is inserted into the space.

9- The sequence of spreader application and point insertion continuous until the canal is full. The number of additional points required will vary from case to case.



10- If the final restoration is not post-retained, the excess gutta-percha emerging from the canal should be removed with a hot instrument and condensed vertically at the orifice with a plugger that fits the canal tightly to ensure a satisfactory coronal seal. In anterior teeth the gutta-percha should be reduced to below the gingival level in order to maintain the translucency of the crown and to prevent the possibility of sealer staining the dentin; in posterior teeth the gutta-percha should be sealed off at the canal orifice.



b) Use of heat softened gutta-percha.

c) Use of solvent softened gutta-percha

- The compaction of GP can be achieved using thermal or non-thermal compaction techniques.
- The use of single cone technique is increased recently with the advent of engine-driven systems. This technique considers the final root preparation to match the final file and hence the need for only a single matched cone.
- Care should be taken regarding appropriate apical termination and sizing as is achieved with other obturation techniques particularly in complex canal anatomies while doing single cone obturation.
- Following obturation of the root canal with the thermoplastic technique thermal nerve injury inducing paresthesia has been reported caused by apical extrusion of the GP esp. after excessive root canal preparation.

DISCLAIMER

THIS IS COPYRIGHTED CONTENT. Unauthorized use, including screenshots, copying, misuse, reuse, or resale of any content from this app, is strictly prohibited. Our app monitors and records all screenshots and recordings. Violators will face strict legal action.

THIS IS COPYRIGHTED CONTENT. Unauthorized use, including screenshots, copying, misuse, reuse, or resale of any content from this app, is strictly prohibited. Our app monitors and records all screenshots and recordings. Violators will face strict legal action.

DISCLAIMER
THIS IS COPYRIGHTED CONTENT. Unauthorized use, including screenshots, copying, misuse, reuse, or resale of any content from this app, is strictly prohibited. Our app monitors and records all screenshots and recordings. Violators will face strict legal action.

ENDODONTIC GUIDELINES IN NON-SURGICAL TREATMENTS

Source-Articles on non-surgical treatments in endodontics, irrigation technique, obturation technique

What not to do during root canal obturation

- Perform obturation if skill or armamentarium is not appropriate for the case.
- Disregard concerns regarding complete disinfection of the root canal system.
- Fail to protect vulnerable structures such as the inferior alveolar nerve.
- Ignore root canal anatomy when deciding upon a specific obturation technique.

6) Restoration of root canal treated teeth

Objective:

- The restoration of the root canal treated tooth is essential to return the tooth to aesthetic and occlusal function and to prevent subsequent complications.
- A suitable restoration should be placed as soon as practically possible.

Rationale:

- The long term patient and clinician measured outcomes of root canal treated teeth can be negatively affected by microbial re-contamination, tooth fracture, recurrent caries and periodontal complications associated with a restoration of insufficient quality.
- When there is only unsuccessful root canal treatment it can be treated conservatively by retreatment, but recurrent caries and tooth fracture are the most common causes of extraction of endodontically treated teeth which should be avoided.

The quality standard criteria for restoration of root canal treated teeth are:

- a) There should be prompt placement of a definitive restoration whenever possible.
- b) Consideration should be taken for conservative restorations like onlays and direct overlay restoration instead of full coverage crowns should be done.
- c) Replacement of previous restorations should be done based on radiographic and clinical assessment.

DISCLAIMER

THIS IS COPYRIGHTED CONTENT. Unauthorized use, including screenshots, copying, misuse, reuse, or resale of any content from this app, is strictly prohibited. Our app monitors and records all screenshots and recordings. Violators will face strict legal action.

DISCLAIMER

THIS IS COPYRIGHTED CONTENT. Unauthorized use, including screenshots, copying, misuse, reuse, or resale of any content from this app, is strictly prohibited. Our app monitors and records all screenshots and recordings. Violators will face strict legal action.

DISCLAIMER

THIS IS COPYRIGHTED CONTENT. Unauthorized use, including screenshots, copying, misuse, reuse, or resale of any content from this app, is strictly prohibited. Our app monitors and records all screenshots and recordings. Violators will face strict legal action.

ENDODONTIC GUIDELINES IN NON-SURGICAL TREATMENTS

Source-Articles on non-surgical treatments in endodontics, irrigation technique, obturation technique

Clinical approach and considerations:

- a) The identification of etiology the pulpal complications and planning of the final restoration is crucial to be done during the diagnosis and treatment planning stages.
- b) In cases of previously restored teeth which is symptomatic, the clinical and radiographic assessments of previous restorations is often insufficient to identify the cause of endodontic disease, hence the removal of the restorations is recommended whenever possible.
- c) The type of the final restoration should take into consideration several preoperative and intraoperative factors, which includes patient's expectations (including costs and esthetics), tooth function and occlusion.
- d) It is mandatory to effectively remove materials which can cause discoloration like root sealer, pulp remnants and discolored restorative material from the pulp canal space esp. in esthetically challenging cases.
- e) A case by case approach is best practice for restoration of root canal treated teeth:
 - For anterior teeth: Anterior teeth often only require a direct restoration but if there is extensive loss of coronal tissues an extra coronal restoration may also be required for anterior tooth.
 - For posterior teeth: Maxillary premolars and molars mostly in cases of extensive loss of tooth structure, benefit from receiving a suitable cuspal coverage restoration. However, with intact marginal ridges and overall sufficient structure, a direct intracoronal restoration should be considered for even posterior teeth. When possible onlays should be considered for posterior teeth, in preference to full crowns to preserve the tooth structure, place margins in favorable supragingival locations, optimize forces and allow options for future restorations.
- f) Occlusion and articulation should be considered when restoring root canal treated teeth.
- g) Extensive tooth loss and damage to marginal ridges render the tooth more prone to fracture making prompt restoration a necessity.
- h) When not able to clean and fill the root canal adequately, and in presence of apical periodontitis/symptoms a direct composite restoration can be placed as an interim restoration.
- i) Any provision for intracanal post and placement of core materials should be carried out with rubber dam isolation.

DISCLAIMER

THIS IS COPYRIGHTED CONTENT. Unauthorized use, including screenshots, copying, misuse, reuse, or resale of any content from this app, is strictly prohibited. Our app monitors and records all screenshots and recordings. Violators will face strict legal action.

DISCLAIMER

THIS IS COPYRIGHTED CONTENT. Unauthorized use, including screenshots, copying, misuse, reuse, or resale of any content from this app, is strictly prohibited. Our app monitors and records all screenshots and recordings. Violators will face strict legal action.

DISCLAIMER

THIS IS COPYRIGHTED CONTENT. Unauthorized use, including screenshots, copying, misuse, reuse, or resale of any content from this app, is strictly prohibited. Our app monitors and records all screenshots and recordings. Violators will face strict legal action.

ENDODONTIC GUIDELINES IN NON-SURGICAL TREATMENTS

Source-Articles on non-surgical treatments in endodontics, irrigation technique, obturation technique

What not to do during the restoration of root canal-treated teeth

- Use a temporary material as a long-term restoration following the completion of root canal treatment.
- Delay a cuspal-coverage restoration for a root canal-treated tooth deemed at risk of fracture.
- Retain potentially discolouring materials in the pulp chamber space of aesthetically relevant teeth.
- Expose root canal filling materials in the absence of adequate isolation.

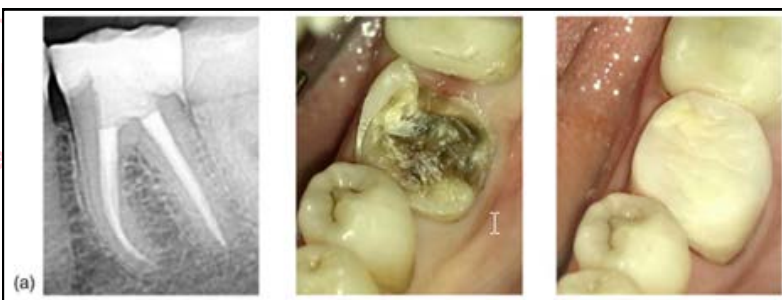

Image: Direct composite resin Overlay

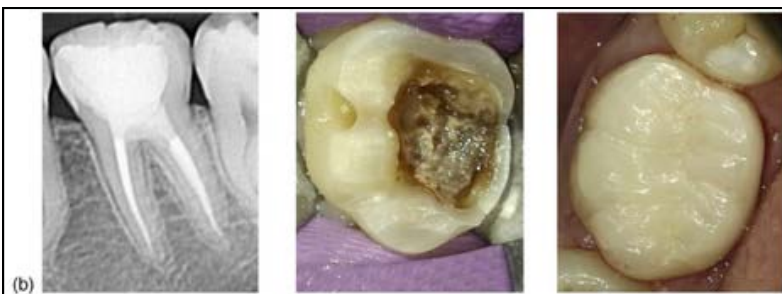


Image: Bonded Ceramic Onlay

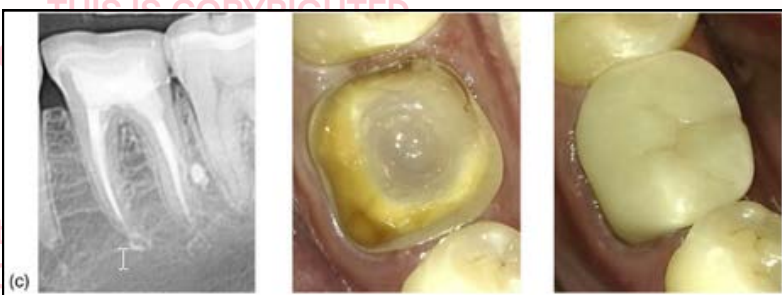


Image: Ceramic Full crown restoration

DISCLAIMER

THIS IS COPYRIGHTED CONTENT. Unauthorized use, including screenshots, copying, misuse, reuse, or resale of any content from this app, is strictly prohibited. Our app monitors and records all screenshots and recordings. Violators will face strict legal action.

DISCLAIMER
THIS IS COPYRIGHTED CONTENT. Unauthorized use, including screenshots, copying, misuse, reuse, or resale of any content from this app, is strictly prohibited. Our app monitors and records all screenshots and recordings. Violators will face strict legal action.

THIS IS COPYRIGHTED CONTENT. Unauthorized use, including screenshots, copying, misuse, reuse, or resale of any content from this app, is strictly prohibited. Our app monitors and records all screenshots and recordings. Violators will face strict legal action.

ENDODONTIC GUIDELINES IN NON-SURGICAL TREATMENTS

Source-Articles on non-surgical treatments in endodontics, irrigation technique, obturation technique

7) Recall and outcome assessment

Objective:

- Regular clinical and radiographic assessment following root canal treatment is necessary to assess whether the procedure has led to the expected outcome.

Rationale:

- Root canal treatment, like any other procedure does not always achieve all the desired outcome, systematically scheduling recall appointments allows for identification of possible complications and regarding the subsequent course of action.
- Possible management options in the presence of disease include further monitoring and orthograde or retrograde re-treatment and tooth extraction.
- Recall supports the understanding of treatment outcomes for the operator leading towards modification in the endodontic management of teeth.

The quality standard criteria for recall and outcome assessment are:

- Scheduling appropriate recalls following endodontic treatment.
- Follow up should include appropriate clinical and radiographic examination.
- All the findings and associated options should be discussed with the patient.

Clinical approach and considerations:

- The optimal root canal treatment outcomes desired are resolution of symptoms, tooth survival and the presence of normal periapical findings, however it is not necessarily attained in all cases and case conditions may change over time, therefore adequate recall is necessary.
- The recall schedule may vary depending on the preexisting condition. A 6 month or 1 year recall with a radiographic examination is an option for follow up, however the schedule may be adjusted according to clinical condition.
- Recall is also important for the operator as it allows one to estimate their own success rate.
- Recall appointments should be planned upon completion of root canal treatment and is the responsibility of the operator that has provided the treatment.
- If an issue is identified, this should be discussed with the patient and subsequent management should be arranged.

What not to do in follow-up care

- Fail to organise recalls following the completion of root canal treatment.
- Use unsuitable radiograph(s) for comparison of treatment outcome.
- Neglect to share decision-making and informed consent when the desired outcomes are not obtained.
- Fail to assess the treatment outcomes and modify future management, if required.

DISCLAIMER

THIS IS COPYRIGHTED CONTENT. Unauthorized use, including screenshots, copying, misuse, reuse, or resale of any content from this app, is strictly prohibited. Our app monitors and records all screenshots and recordings. Violators will face strict legal action.

THIS IS COPYRIGHTED CONTENT. Unauthorized use, including screenshots, copying, misuse, reuse, or resale of any content from this app, is strictly prohibited. Our app monitors and records all screenshots and recordings. Violators will face strict legal action.

DISCLAIMER

THIS IS COPYRIGHTED CONTENT. Unauthorized use, including screenshots, copying, misuse, reuse, or resale of any content from this app, is strictly prohibited. Our app monitors and records all screenshots and recordings. Violators will face strict legal action.

ENDODONTIC EMERGENCIES

Source-Articles, TG, textbook of endodontic principle and practice

- Endodontic emergencies are usually associated with pain and/or swelling and require immediate diagnosis and treatment. Causes of such emergencies are a combination of irritants that induce severe inflammation in the pulp or periradicular tissues.
- Pain results from two factors related to inflammation:
 - i. **Chemical mediators:** Chemical mediators can cause pain directly by activating nociceptors, causing spontaneous pain, or by lowering their response threshold, which causes, for example, a heightened response to normally non-pain producing thermal stimuli.
 - ii. **Pressure:** Inflammatory mediators may also cause pain indirectly by increasing vascular permeability and producing edema. Edema results in increased fluid pressure, which mechanically stimulates pain receptors.
- Reducing the concentration of chemical mediators and allowing release of pressure from the root canal system and from the periapical region are both effective treatment measures.

Endodontic emergencies can be:

- 1) **Pre-treatment emergencies:** It is a situation in which the patient is seen initially with severe pain and swelling. Problems occur with both diagnosis and treatment.
- 2) **Interappointment and Post-obturation emergencies:** These are also known as flare-ups and occurs after endodontic appointment. Although it is undesirable event, it is relatively easier to manage as the offending tooth has already been identified and a diagnosis previously established.
 - Whether a pretreatment, interappointment, or post obturation problem, it is important to differentiate between a true emergency and the less critical urgency. A true emergency is a condition requiring an unscheduled office visit with diagnosis and treatment. The visit cannot be rescheduled because of the severity of the problem. Urgency indicates a less severe problem, thus a visit may be scheduled for mutual convenience of the patient and the dentist.
 - Key questions that can be asked to a Patient(over a telephone as well) to determine the severity of the emergency are:

1. Does the problem disturb your sleeping, eating, working, concentrating, or other daily activities? (A true emergency disrupts the patient's activities or quality of life.)
2. How long has this problem been bothering you? (A true emergency has rarely been severe for more than a few hours to 2 days.)
3. Have you taken any pain medication? Was the medication ineffective? (Analgesics do not relieve the pain of a true emergency.)

DISCLAIMER

THIS IS COPYRIGHTED CONTENT. Unauthorized use, including screenshots, copying, misuse, reuse, or resale of any content from this app, is strictly prohibited. Our app monitors and records all screenshots and recordings. Violators will face strict legal action.

DISCLAIMER

THIS IS COPYRIGHTED CONTENT. Unauthorized use, including screenshots, copying, misuse, reuse, or resale of any content from this app, is strictly prohibited. Our app monitors and records all screenshots and recordings. Violators will face strict legal action.

DISCLAIMER

THIS IS COPYRIGHTED CONTENT. Unauthorized use, including screenshots, copying, misuse, reuse, or resale of any content from this app, is strictly prohibited. Our app monitors and records all screenshots and recordings. Violators will face strict legal action.

ENDODONTIC EMERGENCIES

Source-Articles, TG, textbook of endodontic principle and practice

Pre-treatment emergencies: It can be further divided into:

a) Without symptomatic Apical Periodontitis:

- If the time permits the ideal treatment is complete cleaning and shaping of the root canals (Root canal treatment)
- When minimal time is available pulpotomy is also usually effective.

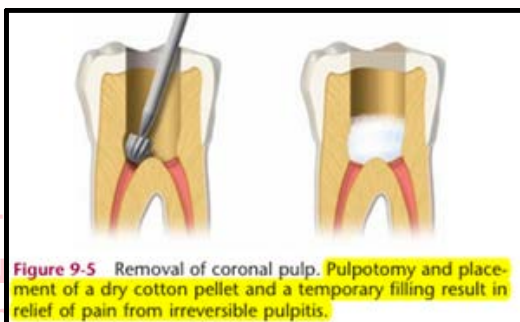


Figure 9-5 Removal of coronal pulp. Pulpotomy and placement of a dry cotton pellet and a temporary filling result in relief of pain from irreversible pulpitis.

b) With symptomatic Apical Periodontitis:

- In patients with extreme tenderness on percussion, a partial or total pulpectomy (as previously described) is appropriate.
- Reducing the occlusion to eliminate contact has been shown to aid in relief of symptoms in some cases.

c) Pulp Necrosis with Apical Pathosis:

- Treatment now is biphasic: (1) remove or reduce the pulp irritants and (2) relieve the apical fluid pressure (when possible)
- Pain with pulp necrosis may be with no swelling, localized swelling, or diffuse with more extensive swelling.

1) Pulp Necrosis with no swelling:

- In pulp necrosis without swelling, the teeth may contain vital inflamed tissues in the apical canal and have inflamed painful peri-radicular tissues (symptomatic apical periodontitis), or alternatively the lesion may have expanded and formed an abscess confined within the bone. Root canal treatment should be done. The aim is to reduce the canal irritants and to try to encourage some drainage through the tooth.

2) Pulp Necrosis with Localized Swelling:

- Here, the abscess has now invaded regional soft tissues and at times, there is purulence in the canal. Radiographic findings range from no periapical change (seldom) to a large radiolucency. Again, treatment is biphasic. First and most important is debridement (complete cleaning and shaping if time permits) of the canal or canals. Second in importance is drainage. Localized swelling (whether fluctuant or non-fluctuant) should be incised. Drainage accomplishes relief of pressure and pain and removal of a very potent irritant which is purulence.

DISCLAIMER

THIS IS COPYRIGHTED CONTENT. Unauthorized use, including screenshots, copying, misuse, reuse, or resale of any content from this app, is strictly prohibited. Our app monitors and records all screenshots and recordings. Violators will face strict legal action.

DISCLAIMER

THIS IS COPYRIGHTED CONTENT. Unauthorized use, including screenshots, copying, misuse, reuse, or resale of any content from this app, is strictly prohibited. Our app monitors and records all screenshots and recordings. Violators will face strict legal action.

THIS IS COPYRIGHTED CONTENT. Unauthorized use, including screenshots, copying, misuse, reuse, or resale of any content from this app, is strictly prohibited. Our app monitors and records all screenshots and recordings. Violators will face strict legal action.

DISCLAIMER

ENDODONTIC EMERGENCIES

Source-Articles, TG, textbook of endodontic principle and practice

- In teeth that drain readily after opening, instrumentation should be confined to the root canal system. In patients with a periradicular abscess but no drainage through the canal, penetration of the apical foramen with small files may initiate drainage and release of pressure.
- The teeth should never be left open to drain (open dressing not recommended) as a canal exposed to the oral cavity is a potential home for bacteria, food debris and even viruses. If continuous drainage (weeping canal) does occur patient should sit for some time and usually the flow will cease and the access may be closed.
- An **odontogenic infection** is called **localized** if it causes dental pain **without facial swelling** and systemic features, but it can show periapical, pericoronal or periodontal abscesses, the signs of abscess include visible pus, localized swelling on the gum or fluctuant tissue. Antibiotic treatment is not required for localized odontogenic infection.
- If there is **spreading odontogenic infection**, without severe or systemic features which is indicated by presence of facial swelling without systemic or severe features than oral antibiotic is indicated along with active dental treatment to address the source of the infection.

For antibiotic therapy of spreading odontogenic infections without systemic or severe features, use:

- 1 metronidazole 400 mg (child: 10 mg/kg up to 400 mg) orally, 12-hourly for 5 days

PLUS EITHER

- 1 phenoxymethylpenicillin 500 mg (child: 12.5 mg/kg up to 500 mg) orally, 6-hourly for 5 days
- OR
- 2 amoxicillin 500 mg (child: 15 mg/kg up to 500 mg) orally, 8-hourly for 5 days

OR (as a single preparation)

- 2 amoxicillin+clavulanate 875+125 mg (child 2 months or older: 22.5+3.2 mg/kg up to 875+125 mg) orally, 12-hourly for 5 days.

For patients hypersensitive to penicillins (see pp.31-5), use:

clindamycin 300 mg (child: 7.5 mg/kg up to 300 mg) orally, 8-hourly for 5 days.*

this app, is strictly prohibited.
Our app monitors and records
all screenshots and
recordings. Violators will face
strict legal action.

DISCLAIMER

THIS IS COPYRIGHTED CONTENT. Unauthorized use, including screenshots, copying, misuse, reuse, or resale of any content from this app, is strictly prohibited. Our app monitors and records all screenshots and recordings. Violators will face strict legal action.

DISCLAIMER

THIS IS COPYRIGHTED CONTENT. Unauthorized use, including screenshots, copying, misuse, reuse, or resale of any content from this app, is strictly prohibited. Our app monitors and records all screenshots and recordings. Violators will face strict legal action.

DISCLAIMER

THIS IS COPYRIGHTED CONTENT. Unauthorized use, including screenshots, copying, misuse, reuse, or resale of any content from this app, is strictly prohibited. Our app monitors and records all screenshots and recordings. Violators will face strict legal action.

ENDODONTIC EMERGENCIES

Source-Articles, TG, textbook of endodontic principle and practice

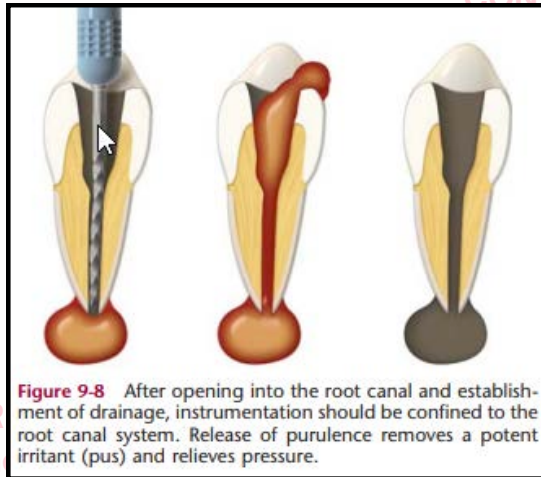
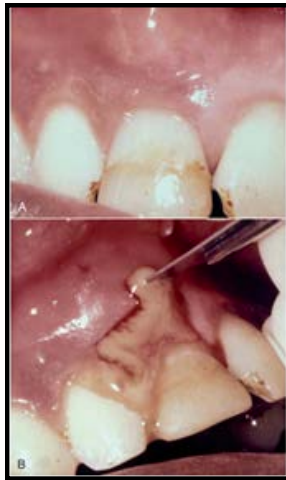

Figure 9-8 After opening into the root canal and establishment of drainage, instrumentation should be confined to the root canal system. Release of purulence removes a potent irritant (pus) and relieves pressure.

Image:

- A) Localized swelling.
B) Incision for drainage after cleaning and shaping offending incisor.

3) Pulp Necrosis with diffuse swelling:

- Rapidly progressive and spreading swellings, commonly referred to as cellulitis, are not localized and may have dissected into the facial spaces.
- If there is spreading odontogenic infection with severe and systemic features, where,

Severe Features:

- a) Significant facial swelling and pain
- b) Trismus
- c) Swelling in the neck
- d) Difficulty swallowing
- e) Difficulty breathing

Systemic Features:

- a) Pallor
- b) Sweating
- c) Tachycardia
- d) Axillary temperature above 38 degree celcius.

Urgent transfer of the patient to the hospital with oral and maxillofacial surgeon or any appropriate specialist is indicated where along with active dental treatment intravenous antibiotic is initiated.

Management of spreading infection with severe or systemic features involves:

- maintaining a patent airway (do not lie the patient flat)
- resuscitation
- draining pus by incising affected spaces and placing drains
- removing the tooth or otherwise addressing the source of infection
- obtaining blood and other samples for culture and susceptibility testing
- intravenous antibiotic therapy.

DISCLAIMER

THIS IS COPYRIGHTED CONTENT. Unauthorized use, including screenshots, copying, misuse, reuse, or resale of any content from this app, is strictly prohibited. Our app monitors and records all screenshots and recordings. Violators will face strict legal action.

DISCLAIMER

THIS IS COPYRIGHTED CONTENT. Unauthorized use, including screenshots, copying, misuse, reuse, or resale of any content from this app, is strictly prohibited. Our app monitors and records all screenshots and recordings. Violators will face strict legal action.

THIS IS COPYRIGHTED CONTENT. Unauthorized use, including screenshots, copying, misuse, reuse, or resale of any content from this app, is strictly prohibited. Our app monitors and records all screenshots and recordings. Violators will face strict legal action.

DISCLAIMER

ENDODONTIC EMERGENCIES

Source-Articles, TG, textbook of endodontic principle and practice

For empirical antibiotic therapy of spreading odontogenic infection with severe or systemic features (including Ludwig angina), in conjunction with surgical intervention, use:

- 1 benzylpenicillin intravenously
patients requiring intensive care support: 2.4 g (child: 50 mg/kg up to 2.4 g) 4-hourly
patients not requiring intensive care support: 1.8 g (child: 50 mg/kg up to 1.8 g) 4-hourly

PLUS

metronidazole 500 mg (child: 12.5 mg/kg up to 500 mg)
intravenously, 12-hourly

OR (as a single preparation)

- 2 amoxicillin+clavulanate intravenously
adult: 1+0.2 g 6-hourly*†
child 3 months or older: 25+5 mg/kg up to 1+0.2 g 6-hourly.‡§

For patients with immediate nonsevere or delayed nonsevere hypersensitivity to penicillins (see pp.31–5), use:

cefazolin 2 g (child: 50 mg/kg up to 2 g) intravenously, 8-hourly;
for adults requiring intensive care support, use 6-hourly dosing

PLUS

metronidazole 500 mg (child: 12.5 mg/kg up to 500 mg)
intravenously, 12-hourly.

For patients with immediate severe or delayed severe hypersensitivity to penicillins (see pp.31–5), as a single-drug regimen, use:

- 1 clindamycin 600 mg (child: 15 mg/kg up to 600 mg)
intravenously, 8-hourly
- OR
- 2 lincomycin 600 mg (child: 15 mg/kg up to 600 mg) intravenously,
8-hourly.

DISCLAIMER

THIS IS COPYRIGHTED CONTENT. Unauthorized use, including screenshots, copying, misuse, reuse, or resale of any content from this app, is strictly prohibited. Our app monitors and records all screenshots and recordings. Violators will face strict legal action.

DISCLAIMER
THIS IS COPYRIGHTED CONTENT. Unauthorized use, including screenshots, copying, misuse, reuse, or resale of any content from this app, is strictly prohibited. Our app monitors and records all screenshots and recordings. Violators will face strict legal action.

DISCLAIMER

THIS IS COPYRIGHTED CONTENT. Unauthorized use, including screenshots, copying, misuse, reuse, or resale of any content from this app, is strictly prohibited. Our app monitors and records all screenshots and recordings. Violators will face strict legal action.

ENDODONTIC EMERGENCIES

Source-Articles, TG, textbook of endodontic principle and practice

Inter-Appointment Emergencies:

- The interappointment flare-up is a true emergency and is so severe that an unscheduled patient visit and treatment are often required. Despite judicious and careful treatment procedures, complications, such as pain, swelling, or both, may occur.
- Flare-ups are quite uncommon in teeth with vital pulps.
- They commonly occur in teeth with necrotic pulp especially with a periapical diagnosis of symptomatic apical periodontitis or acute apical abscess.
- Although not a definitive risk factor, flare up is associated with over instrumentation, pushing debris out of the apex, completing the root canal treatment in one visit.
- Reassurance is the most important part of treatment with interappointment flare ups.
- If flare-up occurred in previously vital pulp with complete debridement than it is unlikely to be a true flare-up and patient reassurance with mild analgesic may suffice. However, it is important to check that the temporary restoration is not in traumatic occlusion.
- If flare-up occurred in previously vital pulp with incomplete debridement, it is likely that the tissue remnants have now become inflamed and now are a major irritant, here the working length should be rechecked and canal should be cleaned properly.
- If flare up occurred in previously necrotic pulp without swelling then the abscess is likely to be confined in the bone and can be very painful. The tooth is opened and the canal is gently re-cleaned and irrigated with sodium hypochlorite. Drainage should be established if possible. If there is active drainage from the tooth after opening, the canal should be re-cleaned or debridement should be completed with copious irrigation. If there is no drainage, the tooth should also be lightly instrumented, gently irrigated, medicated with calcium hydroxide paste, and then closed.
- If flare up occurred in previously necrotic pulp with swelling then, they are best managed with incision and drainage along with debridement of canals.
- With flare-up patients should be contacted daily until symptoms resolve. If the symptoms doesn't resolve then appropriate referral should be done.

DISCLAIMER

THIS IS COPYRIGHTED CONTENT. Unauthorized use, including screenshots, copying, misuse, reuse, or resale of any content from this app, is strictly prohibited. Our app monitors and records all screenshots and recordings. Violators will face strict legal action.

DISCLAIMER

THIS IS COPYRIGHTED CONTENT. Unauthorized use, including screenshots, copying, misuse, reuse, or resale of any content from this app, is strictly prohibited. Our app monitors and records all screenshots and recordings. Violators will face strict legal action.

DISCLAIMER

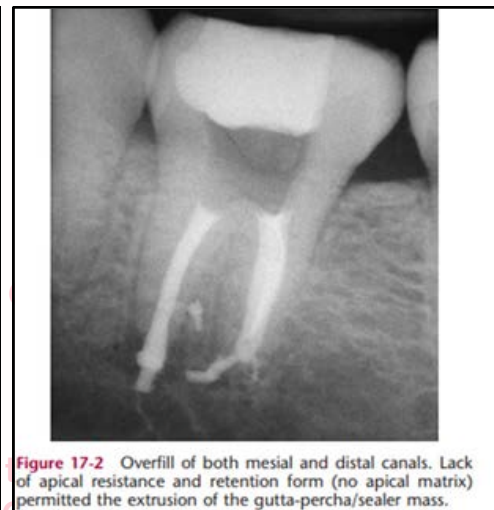
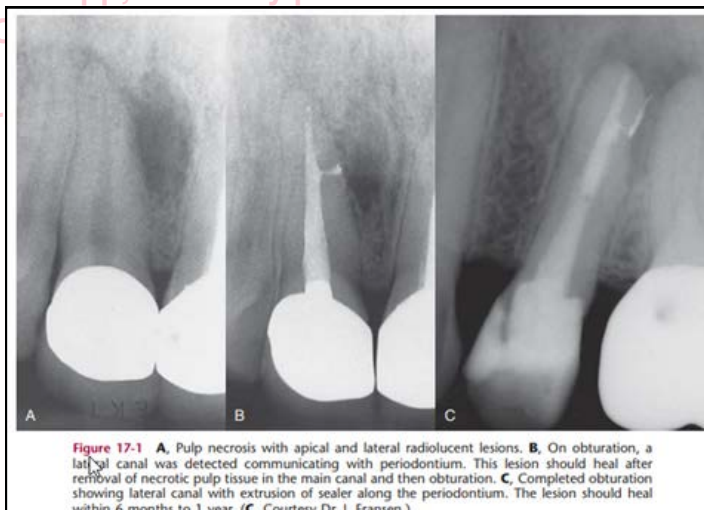
THIS IS COPYRIGHTED CONTENT. Unauthorized use, including screenshots, copying, misuse, reuse, or resale of any content from this app, is strictly prohibited. Our app monitors and records all screenshots and recordings. Violators will face strict legal action.

ENDODONTIC EMERGENCIES

Source-Articles, TG, textbook of endodontic principle and practice

Post-Obturation Emergencies:

- True emergencies post-obturation are infrequent, although pain at the mild level is common. Therefore active intervention is seldom necessary. Symptoms usually will resolve spontaneously.
- The post obturation pain most commonly tends to occur in the first 24 hours of the treatment.
- Overfilling/overobturation leads to most post obturation discomfort and pain.
- Both GP and sealer are toxic and irritants when comes in contact with tissues to a certain degree. A tapered apical preparation with no core materials and a small amount of sealer (small sealer extrusion only) passing out of the foramen is not a significant problem as the irritation from sealer should resolve if adequate compaction of GP is done.
- Compared to over filling under filling is less of a problem.
- Lack of apical seal is even more important than irritation from the materials, as absence of adequate apical barrier prevents sufficient compaction leading to inadequate obturation.



- Post obturation pain also relates to pre obturation pain.
- For the management, re-treatment is recommended when the prior treatment is obviously inadequate.
- Apical surgery is often required when an acute apical abscess develops, and there is uncorrectable, inadequate root canal treatment. If root canal treatment was acceptable, incision and drainage of swelling after obturation (an occasional occurrence) should be performed. Swelling usually resolves without further treatment.
- If the patient reports severe pain, although there is no evidence of acute apical abscess and the root canal treatment has been well done. These patients are treated with reassurance and appropriate analgesics and the symptoms usually subside spontaneously.
- Patients with postobturation emergencies that do not respond to therapy should be referred to an endodontist for other treatment modalities such as surgery.

DISCLAIMER

THIS IS COPYRIGHTED CONTENT. Unauthorized use, including screenshots, copying, misuse, reuse, or resale of any content from this app, is strictly prohibited. Our app monitors and records all screenshots and recordings. Violators will face strict legal action.

THIS IS COPYRIGHTED CONTENT. Unauthorized use, including screenshots, copying, misuse, reuse, or resale of any content from this app, is strictly prohibited. Our app monitors and records all screenshots and recordings. Violators will face strict legal action.

DISCLAIMER
THIS IS COPYRIGHTED CONTENT. Unauthorized use, including screenshots, copying, misuse, reuse, or resale of any content from this app, is strictly prohibited. Our app monitors and records all screenshots and recordings. Violators will face strict legal action.

ENDODONTIC EMERGENCIES

Source-Articles, TG, textbook of endodontic principle and practice

Adverse events associated with endodontic emergencies and their Triggers:

Source- Articles on endodontic mishaps and broken instruments

- **Complaints** regarding endodontic treatment occurs commonly and the triggers are amongst malpractice, negligence or accidents.
- Negligence is a mistake whereas malpractice is a wilful breach of duty of care.
- Along with complaints made to regulators patients may also seek legal actions for damages. Litigation involves compiling the details of the complaint and its impact on the patient, with clinical notes, reports from expert like other general dentists or specialists, to assess whether the treatment provided was adequate, reasonable and necessary. It also involves determining the extent of loss or damage suffered as a result of the treatment.
- In general practice most common events leading to complaint occurred from broken instrument (24%) followed by perforations (22%) and reactions to irrigants solutions or medicaments (5%)
- A common triad of error involves failure to diagnose, failure to treat and failure to refer.
- For prevention of such adverse events various measures can be applied like:
 - a) Seeking additional opinions on a clinically complex situation like true endo-perio lesions that requires multidisciplinary approach.
 - b) Assessing difficulty of endodontic cases prior to treatment including evaluating teeth for canal curvature and patency, presence of calcified canals on radiographs.
 - c) When an instrument separation occurs and cannot be retrieved immediately the patient should be informed and advised of the event and referred to endodontist for management.
 - d) Removal of fractured segment is more influenced by anatomy of tooth, degree of root canal curvature and location of the fragment than the specific technique used.
 - e) A technique utilizing Gates-Glidden burs and ultrasonic has recently been advocated to remove fractured instruments from root canals.
 - f) For management of broken instrument: Creation of a straight line access is the first step to allow maximum visibility of the broken file. The two phase removal of broken instrument technique involves using hand instruments to bypass the fragments and applying ultrasonic device to loosen it. If the fragment is broken in the coronal end then after bypassing the fragment the coronal flaring of the root canal orifices should be done for enhanced access and visualization. After that the bypassed segment can be removed with ultrasonic device.
 - g) The degree of curvature of root is the most important factor influencing the successful management of separated instruments.

DISCLAIMER

THIS IS COPYRIGHTED CONTENT. Unauthorized use, including screenshots, copying, misuse, reuse, or resale of any content from this app, is strictly prohibited. Our app monitors and records all screenshots and recordings. Violators will face strict legal action.

DISCLAIMER

THIS IS COPYRIGHTED CONTENT. Unauthorized use, including screenshots, copying, misuse, reuse, or resale of any content from this app, is strictly prohibited. Our app monitors and records all screenshots and recordings. Violators will face strict legal action.

DISCLAIMER

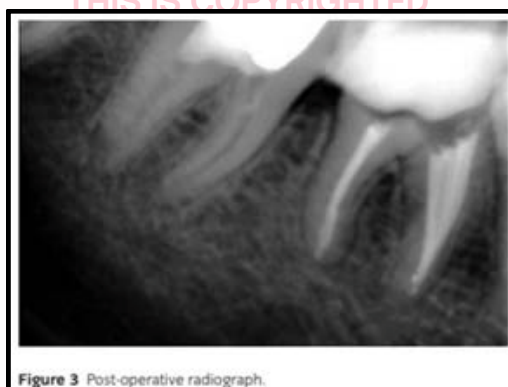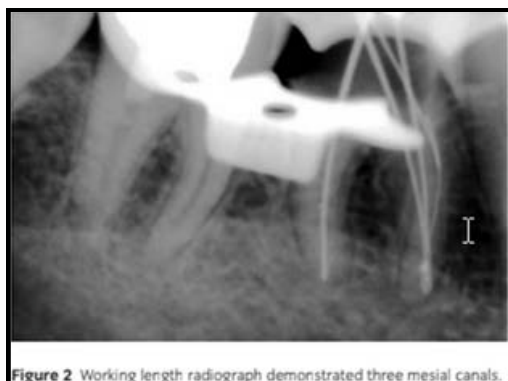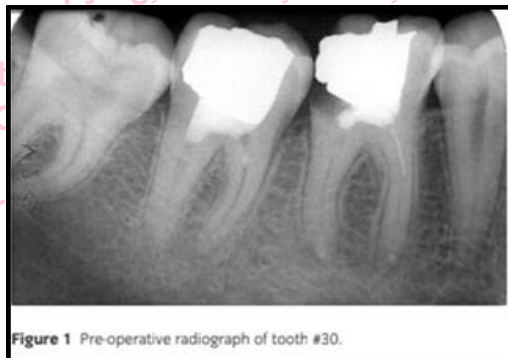THIS IS COPYRIGHTED CONTENT. Unauthorized use, including screenshots, copying, misuse, reuse, or resale of any content from this app, is strictly prohibited. Our app monitors and records all screenshots and recordings. Violators will face strict legal action.

ENDODONTIC EMERGENCIES

Source-Articles, TG, textbook of endodontic principle and practice

- h) To reduce the incidence of missed canal such as middle mesial canal in lower molars which is present in 1-15% of the cases, tooth should be examined carefully clinically and radiographically to detect possible anatomical variations. A radiographic tube-shift technique may reveal additional canals or canal bifurcations which will also reduce the incidence of perforation and separated instrument, use of magnification is also considered helpful.
- i) In most cases, the middle mesial canal is hidden by a dentinal projection of the mesial aspect of pulp chamber walls. This dentinal growth is usually located between the two main canals and should be removed carefully in order to detect additional canals. Ultrasonic technology is a very useful tool to clean such area effectively.

A radiographic example of case with broken instrument and presence of missed mesial canal is presented with the final radiographic image after management:



DISCLAIMER

THIS IS COPYRIGHTED CONTENT. Unauthorized use, including screenshots, copying, misuse, reuse, or resale of any content from this app, is strictly prohibited. Our app monitors and records all screenshots and recordings. Violators will face strict legal action.

DISCLAIMER

THIS IS COPYRIGHTED CONTENT. Unauthorized use, including screenshots, copying, misuse, reuse, or resale of any content from this app, is strictly prohibited. Our app monitors and records all screenshots and recordings. Violators will face strict legal action.

THIS IS COPYRIGHTED CONTENT. Unauthorized use, including screenshots, copying, misuse, reuse, or resale of any content from this app, is strictly prohibited. Our app monitors and records all screenshots and recordings. Violators will face strict legal action.

DISCLAIMER

ENDODONTIC EMERGENCIES

Source-Articles, TG, textbook of endodontic principle and practice

Table 2. Endodontic events that may trigger a complaint

Failure to recognise a canal (e.g. MB2 in upper first molars)
Perforations
Separation of instruments
Ledges or transportation of canals
Not adequately treating cases with complex anatomy (e.g. dens invaginatus, or teeth with unusual root canal morphology)
Not taking sufficient radiographs to properly diagnose and treat the case, or taking excessive radiographs due to poor alignment or other radiographic errors
Extrusion of irrigation solutions
Extrusion of root filling materials or sealers from the confines of the root canal system
Air embolism from the use of compressed air in the root canal space
Sinus perforations
Nerve damage
Infection requiring hospitalization

Table 3: Examples of malpractice, negligence and accidents in endodontics

Malpractice	Negligence	Accidents
Not using dental dam	Fracture of tooth due to improper selection of clamp. Failure to ensure leak proof dental dam	Fracture of a clamp Tear in rubber dam due to the dam being weakened by chemical solvents or sharp instruments
Using blunt, rusty or corroded files.	Improper use of rotary files (e.g. unwrapping files that have bound onto the root canal walls)	Extrusion of droplets of fluid into the periapical tissues when using normal irrigation methods
Failure to inform the patient of possible complications or consequences of treatment.	Failure to recognise and manage perforations	Late discovery of vertical/horizontal root fractures midway through treatment that renders the tooth un-restorable.
Performing root treatment of a tooth with a hopeless periodontal prognosis of that is not restorable		
Cementing a crown or post-core after root canal therapy with grossly deficient margins	Failure to check/or adjust occlusion of temporary or final restorations of the access form	Rubber dam clamp being dislodged by tongue movement.

DISCLAIMER

THIS IS COPYRIGHTED CONTENT. Unauthorized use, including screenshots, copying, misuse, reuse, or resale of any content from this app, is strictly prohibited. Our app monitors and records all screenshots and recordings. Violators will face strict legal action.

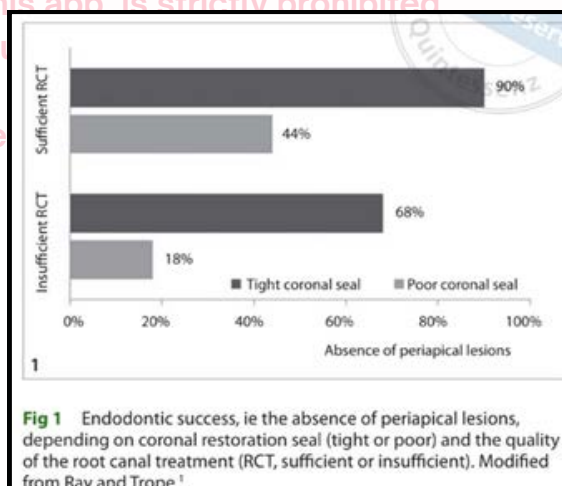
DISCLAIMER
THIS IS COPYRIGHTED CONTENT. Unauthorized use, including screenshots, copying, misuse, reuse, or resale of any content from this app, is strictly prohibited. Our app monitors and records all screenshots and recordings. Violators will face strict legal action.

DISCLAIMER

THIS IS COPYRIGHTED CONTENT. Unauthorized use, including screenshots, copying, misuse, reuse, or resale of any content from this app, is strictly prohibited. Our app monitors and records all screenshots and recordings. Violators will face strict legal action.

ENDODONTIC RESTORATIONS AND POSTS

- Endodontic restorations and posts are critical components in the rehabilitation of endodontically treated teeth, ensuring their functionality and longevity.
- After root canal therapy, a tooth often becomes structurally compromised, requiring restorative procedures to restore its strength and protect it from further damage. Posts are commonly used to provide additional support when there is insufficient remaining tooth structure to retain a core material.
- Every orthograde endodontic treatment requires restoration of the coronal (access) cavity. The specific type of restoration used depends on the amount of residual coronal tooth structure.
- Best long term successful endodontic treatment is dependent on both adequate endodontic and restorative treatment.
- Leaking coronal restorations dramatically reduces the chance of endodontic treatment success. Proper coronal restoration without any marginal leakage is at least as important as endodontic treatment itself for apical periodontal health and even has improved success rate.



Type of restoration recommended on the basis of remaining tooth structure:

1) Direct composite restoration:

- Most stable results are obtained when the access cavity has all the four walls intact (Class 1).
- Recommended when at least 3 or 4 coronal walls are intact with at least one marginal ridge.
- It can also be used in cases of two surface class 2 cavities with barely undermined tooth structure.
- Flowable Bulk-Fill composites are the choice of materials when restoring Endodontically treated teeth (ETT) directly because of their low shrinkage stresses as well as self-adaptational properties, but studies have shown that commercially available materials is not equally performative.
- However, the choice for direct composite restoration may be influenced by undermined and weakened residual coronal walls.

DISCLAIMER

THIS IS COPYRIGHTED CONTENT. Unauthorized use, including screenshots, copying, misuse, reuse, or resale of any content from this app, is strictly prohibited. Our app monitors and records all screenshots and recordings. Violators will face strict legal action.

DISCLAIMER

THIS IS COPYRIGHTED CONTENT. Unauthorized use, including screenshots, copying, misuse, reuse, or resale of any content from this app, is strictly prohibited. Our app monitors and records all screenshots and recordings. Violators will face strict legal action.

DISCLAIMER

THIS IS COPYRIGHTED CONTENT. Unauthorized use, including screenshots, copying, misuse, reuse, or resale of any content from this app, is strictly prohibited. Our app monitors and records all screenshots and recordings. Violators will face strict legal action.

ENDODONTIC RESTORATIONS AND POSTS

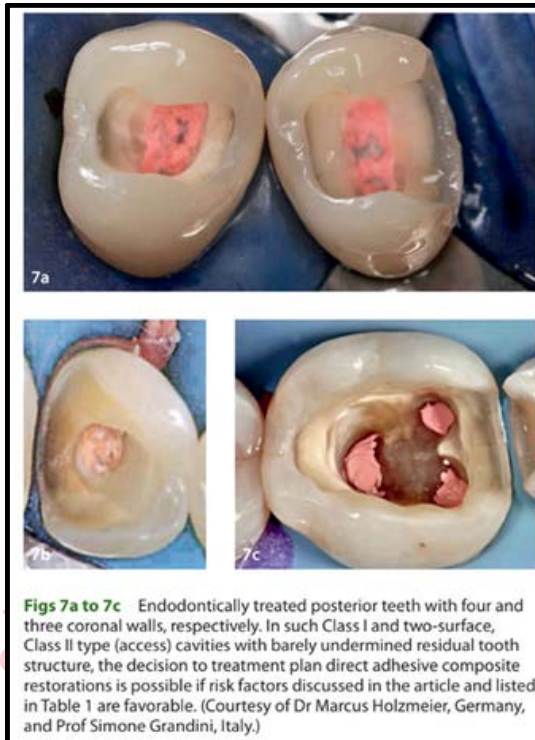


Image: Source- Article on post and core in Endodontically treated teeth (ETT)

- Patient related factors like Occlusal patterns, presence of parafunctional habits like nocturnal bruxism, dietary habits like consumption of hard nuts and candies that place stress on the restoration causing the filling to flex, or consumption of chewing gum or ice that weakens the adhesive interface significantly are the potential risk factors that leads to fracture of restoration and can influence the choice of restoration from direct restoration to cuspal coverage or even a crown.

2) Cuspal Coverage:

- In cases with few or undermined coronal walls (loss of both marginal ridges but walls still present) and undermined or loss of cusps cuspal coverage without full crown placement is recommended.
- Cuspal coverage is typically carried out indirectly with adhesive composite or all ceramic onlay or partial crown.

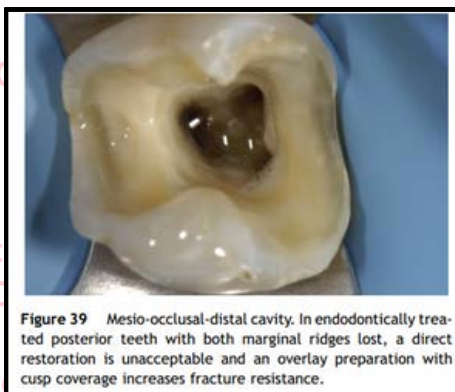

Image-Source-internet (Article on restoration of endodontically treated posterior tooth)

DISCLAIMER

THIS IS COPYRIGHTED CONTENT. Unauthorized use, including screenshots, copying, misuse, reuse, or resale of any content from this app, is strictly prohibited. Our app monitors and records all screenshots and recordings. Violators will face strict legal action.

DISCLAIMER

THIS IS COPYRIGHTED CONTENT. Unauthorized use, including screenshots, copying, misuse, reuse, or resale of any content from this app, is strictly prohibited. Our app monitors and records all screenshots and recordings. Violators will face strict legal action.

THIS IS COPYRIGHTED CONTENT. Unauthorized use, including screenshots, copying, misuse, reuse, or resale of any content from this app, is strictly prohibited. Our app monitors and records all screenshots and recordings. Violators will face strict legal action.

DISCLAIMER

ENDODONTIC RESTORATIONS AND POSTS

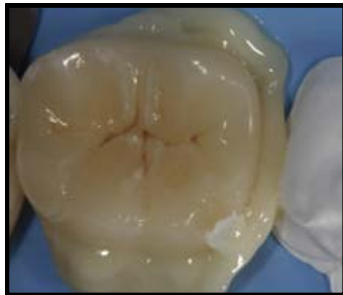

Image: Indirect Ceramic overlay restoration

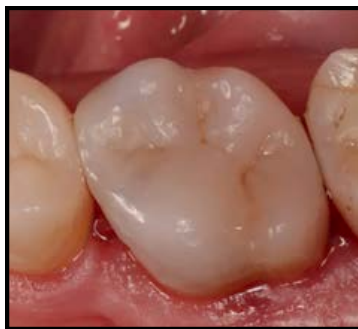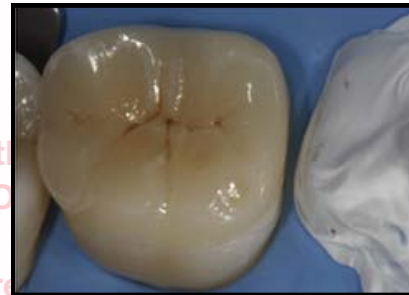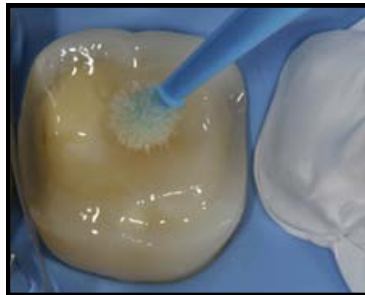


Image-Maxillary right molar treated with direct composite overlay (cuspal coverage) (Internet)

3) Full Crown without post placement

- It is recommended when no walls are remaining but the tooth is exhibiting limited tissue loss (that is when there is less than 50% of tooth loss).
- Crowns are proven to function well as a long-term restorative measure in such cases.
- The creation of circumferential ferrule is important for full crown preparation. The recommended ferrule is 1.5-2mm which provides fracture resistance to endodontically treated tooth.
- **In cases where ferrule cannot be achieved Crown lengthening** procedures that is: orthodontic extrusion (if time permits) is advised over surgical crown lengthening rather than restoring the tooth with lack of ferrule.
- The tooth can be restored with metal, porcelain fused metal or all ceramic crowns.
- The core build up should be done using conventional self-curing adhesive and core build up composite prior to crown placement.

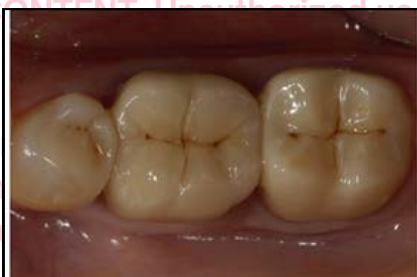

Figure 44 A modern restorative approach: an indirect adhesive composite onlay, a metal-ceramic (in a tooth without aesthetic demand) and a monolithic zirconia in the presence of reduced occlusal space.

Image-(Source Internet)

DISCLAIMER

THIS IS COPYRIGHTED CONTENT. Unauthorized use, including screenshots, copying, misuse, reuse, or resale of any content from this app, is strictly prohibited. Our app monitors and records all screenshots and recordings. Violators will face strict legal action.

DISCLAIMER

THIS IS COPYRIGHTED CONTENT. Unauthorized use, including screenshots, copying, misuse, reuse, or resale of any content from this app, is strictly prohibited. Our app monitors and records all screenshots and recordings. Violators will face strict legal action.

THIS IS COPYRIGHTED CONTENT. Unauthorized use, including screenshots, copying, misuse, reuse, or resale of any content from this app, is strictly prohibited. Our app monitors and records all screenshots and recordings. Violators will face strict legal action.

DISCLAIMER

ENDODONTIC RESTORATIONS AND POSTS

Fig 5 In cases where placement of a conventional crown is planned, preparation of a ferrule is advised. Reprinted from Naumann⁵⁴ with permission.

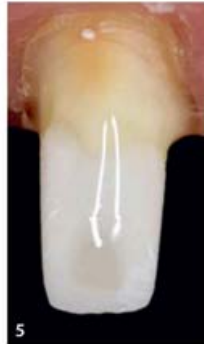

Fig 6 CAD/CAM construction of an all-ceramic overlay. For posterior teeth presenting with few or undermined walls, cuspal coverage with a partial crown or an adhesively placed onlay is advised. (Courtesy of Dr Andreas Bindl, Switzerland.)

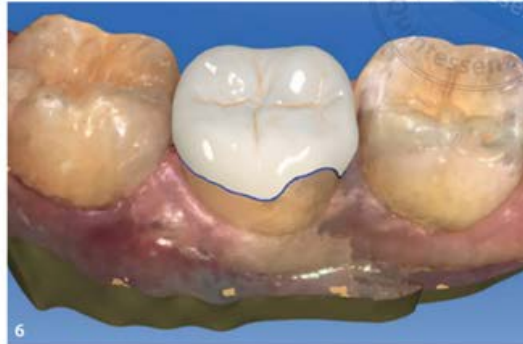

Image: (Source-Article)

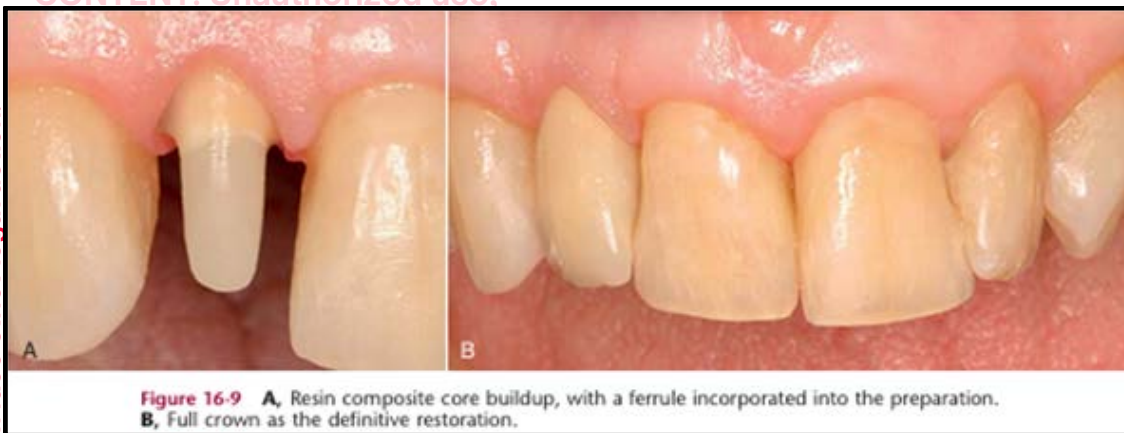


Image: (Source- Walton)

4) Post placement:

- A root post is primarily used to improve retention of coronal restoration in an endodontically treated tooth with extensive loss of crown structure that is more than 50% of loss of tooth structure. For example, A case of three surface Class 2 (Mesio-occluso-distal) MOD cavity involving both marginal ridges, the coronal loss is on average 63% hence crowning the tooth with post is necessary.

Various types of posts available are:

- a) Metallic prefabricated posts
- b) Cast posts
- c) Fiber reinforced composite (FRC) posts
- d) Zirconia posts

- Studies and reviews have confirmed the superiority of fiber reinforced posts when the use of post is indicated.

DISCLAIMER

THIS IS COPYRIGHTED CONTENT. Unauthorized use, including screenshots, copying, misuse, reuse, or resale of any content from this app, is strictly prohibited. Our app monitors and records all screenshots and recordings. Violators will face strict legal action.

DISCLAIMER

THIS IS COPYRIGHTED CONTENT. Unauthorized use, including screenshots, copying, misuse, reuse, or resale of any content from this app, is strictly prohibited. Our app monitors and records all screenshots and recordings. Violators will face strict legal action.


THIS IS COPYRIGHTED CONTENT. Unauthorized use, including screenshots, copying, misuse, reuse, or resale of any content from this app, is strictly prohibited. Our app monitors and records all screenshots and recordings. Violators will face strict legal action.

DISCLAIMER

ENDODONTIC RESTORATIONS AND POSTS

Fiber reinforced composite posts:

- They are made up of carbon, quartz or glass fibers embedded in a matrix of epoxy or methacrylate resin.
- The adhesion between quartz or glass fibers and resin matrix is enhanced by fiber silanization prior to embedding.
- They are available in different shapes like cylindrical, cylindroconical, conical, double tapered. Double tapered posts adapt better to endodontically treated tooth thus limiting the amount of dentine removal in post space preparation. For oval shaped canals, oval shaped posts are available.



Advantages of fiber posts over other types of posts:

- The fiber post has elastic modulus similar to that of the dentine hence there is relatively uniform stress distribution to the root and surrounding tissues providing protective effect against root fracture.
- Titanium, stainless steel or zirconia have elastic modulus above the dentine, and in the presence of rigid posts, stress is transmitted internally that concentrates towards the apical level increasing the risk of VRF.
- Fiber posts are easy to place, cost effective and esthetic.
- Fiber post simplify post endodontic restoration procedure as they eliminate the laboratory step when compared with cast posts.
- Fiber post are relatively easy to remove in case endodontic retreatment is necessary which can be done by boring through the middle of the post with ultrasonic or a rotary instrument.
- Glass fiber posts are associated with low failure rates compared to other type of posts.
- Glass fiber posts exhibit lower stress peaks in finite element analysis and thus is superior.
- Glass fiber post offer most favorable optical properties for reproducing the natural aspect of the restored teeth.

DISCLAIMER

THIS IS COPYRIGHTED CONTENT. Unauthorized use, including screenshots, copying, misuse, reuse, or resale of any content from this app, is strictly prohibited. Our app monitors and records all screenshots and recordings. Violators will face strict legal action.

DISCLAIMER

THIS IS COPYRIGHTED CONTENT. Unauthorized use, including screenshots, copying, misuse, reuse, or resale of any content from this app, is strictly prohibited. Our app monitors and records all screenshots and recordings. Violators will face strict legal action.

THIS IS COPYRIGHTED CONTENT. Unauthorized use, including screenshots, copying, misuse, reuse, or resale of any content from this app, is strictly prohibited. Our app monitors and records all screenshots and recordings. Violators will face strict legal action.

DISCLAIMER

ENDODONTIC RESTORATIONS AND POSTS

Adhesive Luting of fiber posts:

- The fiber posts are passively retained into the root canal; therefore, the effectiveness of the adhesive cement and luting procedure plays a vital role in overall clinical performance of fiber posts.
- The most frequent failure mode of fiber post is post debonding.
- Achieving stable adhesion to intraradicular dentine mainly at the apical level is a challenge due to various factors.
- Endodontic irrigants like sodium hypochlorite, EDTA, hydrogen peroxide, RC prep, Calcium hydroxide, sealers negatively affect the adhesion of luting agents. Also, the remnants of plasticized GP and sealer while post space preparation also hinder the chemical interaction and penetration of luting agent. Therefore, to enhance post retention a careful debridement of the post space walls with the use of ultrasonic instrument and EDTA should be performed prior to cementation.
- Post luting immediately after root canal obturation with the use of ZOE sealers should be avoided as the residues of unset sealer might be displaced from the apical portion of the canal by paper points and micro brushes, and be spread over the post space walls, then interfering with cement polymerization. The post retention will not be influenced after 1 week of obturation.
- The best luting agent for the cementation of fiber post with evidence currently is with the use of etch and rinse adhesive in combination with dual cure resin cements.
- To simplify the dual step, etch and rinse technique, a single step self-etch adhesive resin cement is introduced. However, these self-adhesive cements achieve inferior bond strength to dentine when compared with two step etch and rinse technique. More research is required for more reliable results.
- For the curing mode of the cement, use of light cure materials is not advised in post luting, as it is difficult for the light to fully penetrate the post space even if translucent post (both carbon fiber post and glass fiber post) is used.
- Hence, dual cure resins provide the most reliability to achieve proper cement polymerization all along the dowel(post) space. Although they can polymerize even in complete absence of light, the use of light to cure develops better mechanical properties. So, Light curing is suggested to be done in dual cure resins.

The fiber posts can be further categorized as:

- 1) Glass fiber posts
- 2) Carbon fiber posts
- 3) Quartz fiber posts
- 4) Polyethylene fiber posts

DISCLAIMER

THIS IS COPYRIGHTED CONTENT. Unauthorized use, including screenshots, copying, misuse, reuse, or resale of any content from this app, is strictly prohibited. Our app monitors and records all screenshots and recordings. Violators will face strict legal action.

DISCLAIMER

THIS IS COPYRIGHTED CONTENT. Unauthorized use, including screenshots, copying, misuse, reuse, or resale of any content from this app, is strictly prohibited. Our app monitors and records all screenshots and recordings. Violators will face strict legal action.

DISCLAIMER

THIS IS COPYRIGHTED CONTENT. Unauthorized use, including screenshots, copying, misuse, reuse, or resale of any content from this app, is strictly prohibited. Our app monitors and records all screenshots and recordings. Violators will face strict legal action.

ENDODONTIC RESTORATIONS AND POSTS

Adhesion of resin composite to post surface for cementation or core build up:

- To enhance the adhesion to fiber post surface, silanization of quartz and glass fiber posts can be done, however silanization is not effective on resin post reinforced by carbon fibers.
- For the chair side procedures, pretreatment of post surface with 10% hydrogen peroxide for 20 minutes is effective to improve fiber post to resin composite adhesion.
- Silicoating of the substrate followed by silanization is another method which can be done either chairside (Cojet System) or in laboratory (Rocatec system) is recommended for improving bond strength of resin composites to zirconia posts.

In terms of radiopacity of Posts:

- Among the fiber posts-
 - a) Glass fiber post appear the most radiolucent according to the article on Current prospective on post system by ADJ but more radiopaque glass fiber post system is available now.
 - b) Quartz fiber posts are slightly brighter than glass but still not very radiopaque.
 - c) Carbon fiber posts are more radiopaque (brighter/white on x-ray) but not as much as metal or zirconia posts.
- Metal or zirconia posts appear the most radiopaque, hence they appear brightest on Xray.
- The low radiodensity of polyethylene fibers is the limitation of these reinforcing materials.

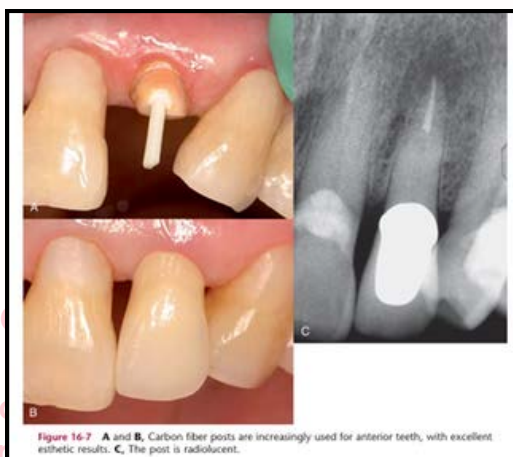

Image: (Source- Walton)

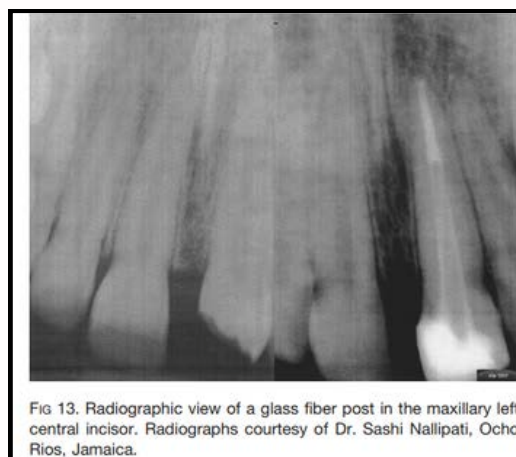


FIG 13. Radiographic view of a glass fiber post in the maxillary left central incisor. Radiographs courtesy of Dr. Sashi Nallipati, Ocho Rios, Jamaica.

Image-Source Post Placement and Restoration of Endodontically Treated Teeth: A Literature Review, AAE (American Association of Endodontics), Journal of endodontics.

DISCLAIMER

THIS IS COPYRIGHTED CONTENT. Unauthorized use, including screenshots, copying, misuse, reuse, or resale of any content from this app, is strictly prohibited. Our app monitors and records all screenshots and recordings. Violators will face strict legal action.

DISCLAIMER

THIS IS COPYRIGHTED CONTENT. Unauthorized use, including screenshots, copying, misuse, reuse, or resale of any content from this app, is strictly prohibited. Our app monitors and records all screenshots and recordings. Violators will face strict legal action.

THIS IS COPYRIGHTED CONTENT. Unauthorized use, including screenshots, copying, misuse, reuse, or resale of any content from this app, is strictly prohibited. Our app monitors and records all screenshots and recordings. Violators will face strict legal action.

DISCLAIMER

ENDODONTIC FAILURE

Source- Articles, TG, Textbook of Endodontic Principle and Practice

- The various causes of endodontic failure can be, loss of or inadequate coronal seal, inadequate debridement and disinfection, missed canals, vertical root fractures, significant periodontal disease, coronal fractures, poor aseptic technique and procedural errors such as loss of length, ledging, zipping and perforations.

Potential causes of failure:

1) Lack of proper Apical seal:

- Bacteria, tissue debris and other irritants are usually not entirely removed during cleaning and shaping, which leads to potential source of irritation that may lead to failure.
- Sealing in these irritants during obturation prevent their escape to surrounding tissue, and some bacteria lose vitality with the lack of substrate, other bacteria remain dormant waiting for substrate to proliferate and cause irritation.
- If coronal seal is lacking these remnants can be irritating and cause inflammation leading to failure.

Prevention: Proper apical seal should be achieved during obturation, which can be confirmed by a 'tug back' of the master cone prior to obturation.

2) Lack of coronal seal:

- A coronal seal is extremely important, If the myriad of irritants in the oral cavity gain access to periapical tissues, they may cause inflammation and treatment failure. Irritants include substances in saliva such as microorganisms, food, chemicals, or other agents that pass through the mouth.
- If coronal gutta-percha with sealer obturation is exposed to saliva, dissolution of sealer and leakage over a relatively short period of time may occur. This results in leakage of bacteria, toxins, and chemicals into and around the gutta-percha. The sealer loss will lead to communication from the oral cavity to the periapex or periodontium via a lateral canal or apical foramen.
- Proper coronal seal is hence very important to avoid failure.
- Coronal exposure of the obturating material for more than a short period of time through loss of restoration, recurrent caries, or open margins requires retreatment. The time of exposure requiring retreatment is undetermined but probably depends on varied factors such as quality of obturation, length of canal, and surface area of exposure.

DISCLAIMER

THIS IS COPYRIGHTED CONTENT. Unauthorized use, including screenshots, copying, misuse, reuse, or resale of any content from this app, is strictly prohibited. Our app monitors and records all screenshots and recordings. Violators will face strict legal action.

DISCLAIMER

THIS IS COPYRIGHTED CONTENT. Unauthorized use, including screenshots, copying, misuse, reuse, or resale of any content from this app, is strictly prohibited. Our app monitors and records all screenshots and recordings. Violators will face strict legal action.

DISCLAIMER

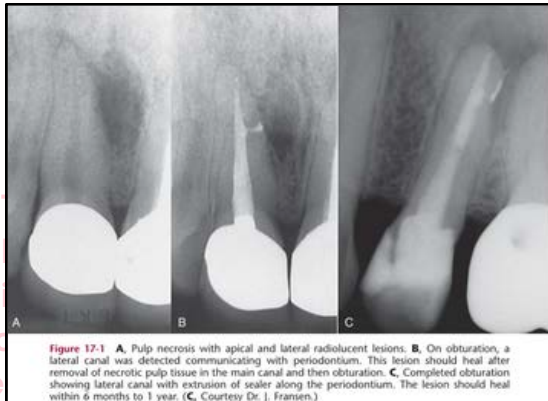
THIS IS COPYRIGHTED CONTENT. Unauthorized use, including screenshots, copying, misuse, reuse, or resale of any content from this app, is strictly prohibited. Our app monitors and records all screenshots and recordings. Violators will face strict legal action.

ENDODONTIC FAILURE

Source- Articles, TG, Textbook of Endodontic Principle and Practice

3) Lack of lateral seal:

- Lateral canals are found in middle aspect of the canal and they constitute a potential communication for irritants from the canal to the lateral periodontium. So, establishment of lateral seal is important, although not as much as apical and coronal seal.



4) Procedural accidents

- Various procedural accidents can lead to endodontic failure. When an accident occurs during root canal treatment, the patient should be informed about
 - (1) the incident,
 - (2) procedures necessary for correction,
 - (3) alternative treatment modalities, and
 - (4) the effect of this accident on prognosis.
- Proper medicolegal documentation is necessary.
- These includes:

A) Over Fill of the canal

- Overfills are undesirable, failures increase with time when the primary obturating material is extruded. Overfills leads to increased inflammation with delayed or impaired healing.
- Post obturation discomfort is increased after over fills, as it leads to inadequate apical seal and also irritation from the material itself.
- Obturating materials both sealer and core are irritants though to a greater and lesser degree.
- Lack of apical seal is even more important than irritation from materials.

Cause:

- It is usually caused by over instrumentation through the apical constriction or lack of proper taper in the prepared canals.
- When the apex is open naturally or its constriction is removed during cleaning and shaping, there is no matrix against which condensation can be done adequately and uncontrolled condensation leads to extrusion of materials.
- Inflammatory root resorption or incomplete development of root also causes over filling.

DISCLAIMER

THIS IS COPYRIGHTED CONTENT. Unauthorized use, including screenshots, copying, misuse, reuse, or resale of any content from this app, is strictly prohibited. Our app monitors and records all screenshots and recordings. Violators will face strict legal action.

THIS IS COPYRIGHTED CONTENT. Unauthorized use, including screenshots, copying, misuse, reuse, or resale of any content from this app, is strictly prohibited. Our app monitors and records all screenshots and recordings. Violators will face strict legal action.

DISCLAIMER

DISCLAIMER

THIS IS COPYRIGHTED CONTENT. Unauthorized use, including screenshots, copying, misuse, reuse, or resale of any content from this app, is strictly prohibited. Our app monitors and records all screenshots and recordings. Violators will face strict legal action.

ENDODONTIC FAILURE

Source- Articles, TG, Textbook of Endodontic Principle and Practice

Prevention:

- The taper form of preparation helps to form an adequate apical matrix for gutta percha compaction, and even if only a small amount of sealer is extruded the irritation from sealer will resolve. Therefore, a proper taper form of preparation with apical matrix or barrier is necessary.

Treatment:

- When signs or symptoms of endodontic failure appear, apical surgery may be required to remove the material from apical tissues and place root-end filling material. Long-term prognosis is dictated by the quality of the apical seal, the amount and biocompatibility of extruded material, host response, and toxicity and sealing ability of the root-end filling material.

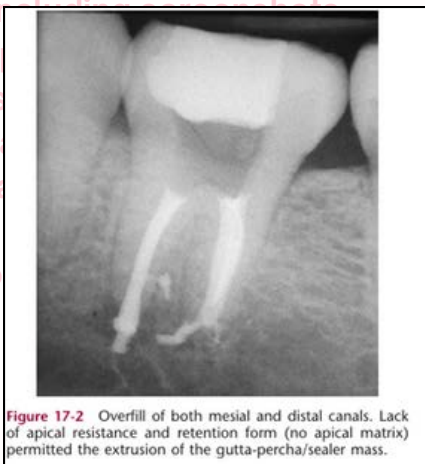


Figure 17-2 Overfill of both mesial and distal canals. Lack of apical resistance and retention form (no apical matrix) permitted the extrusion of the gutta-percha/sealer mass.

B) Under fill of canals

- Underfill results when both preparation and obturation are short of the desired working length or when the obturation does not extend to the prepared length that may contribute to long term failure.
- The optimal preparation/obturation length for a necrotic pulp is 0.5 to 1 mm short of the radiographic apex. For a vital pulp, the length is 0 to 2 mm short.
- Preparation or obturation short of these lengths may leave existing or potential irritants in the apical canal. Periapical inflammation may develop over an extended period of time, depending on the volume of irritants or the balance established between irritants and the immune system.
- Under fills are less of a problem when compared to overfills.

Cause:

- It can be caused due to natural barrier in the canal, ledge formation during preparation, insufficient flaring, poorly adapted master cone, inadequate condensation pressure.

DISCLAIMER

THIS IS COPYRIGHTED CONTENT. Unauthorized use, including screenshots, copying, misuse, reuse, or resale of any content from this app, is strictly prohibited. Our app monitors and records all screenshots and recordings. Violators will face strict legal action.

DISCLAIMER

THIS IS COPYRIGHTED CONTENT. Unauthorized use, including screenshots, copying, misuse, reuse, or resale of any content from this app, is strictly prohibited. Our app monitors and records all screenshots and recordings. Violators will face strict legal action.

THIS IS COPYRIGHTED CONTENT. Unauthorized use, including screenshots, copying, misuse, reuse, or resale of any content from this app, is strictly prohibited. Our app monitors and records all screenshots and recordings. Violators will face strict legal action.

DISCLAIMER

ENDODONTIC FAILURE

Source- Articles, TG, Textbook of Endodontic Principle and Practice

Prevention:

- By passing of the natural or artificial barrier can be done to create a smooth funnel shaped taper.
- Use of nickel titanium rotary files with increased taper improves the predictability.

Treatment:

- Removal of underfilled gutta-percha and retreatment is preferred. Forcing gutta-percha apically by increased spreader or plugger pressure can fracture the root.

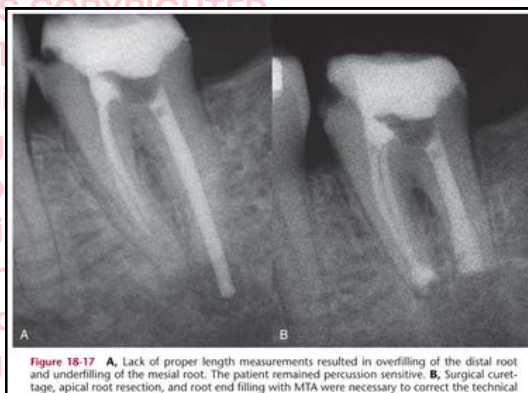


Figure 18-17 A, Lack of proper length measurements resulted in overfilling of the distal root and underfilling of the mesial root. The patient remained percussion sensitive. B, Surgical curettage, apical root resection, and root end filling with MTA were necessary to correct the technical

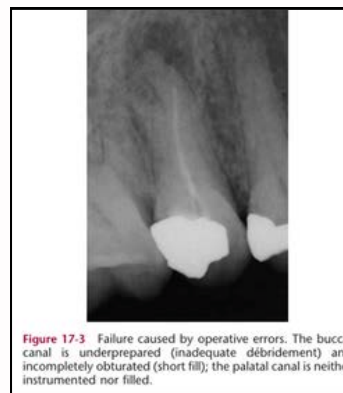


Figure 17-3 Failure caused by operative errors. The buccal canal is underprepared (inadequate débridement) and incompletely obturated (short fill); the palatal canal is neither instrumented nor filled.

C) Perforations during access cavity preparation:

- The prime objective of an access cavity is to provide an unobstructed or straight-line pathway to the apical foramen. Accidents, such as excess removal of tooth structure or perforation, may occur during attempts to locate canals.

Cause:

- The pulp system is located in the long axis of the tooth. Lack of attention to the degree of axial inclination of a tooth in relation to adjacent teeth and to alveolar bone may result in either gouging or perforation of the crown or the root at various levels.

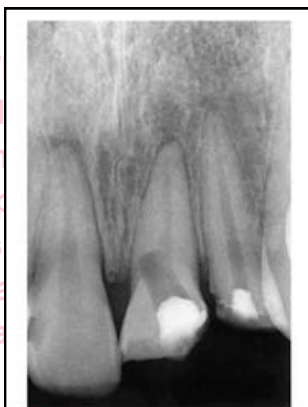

Figure 18-1 A misdirected bur created severe gouging and near-perforation during an otherwise routine access cavity preparation.

DISCLAIMER

THIS IS COPYRIGHTED CONTENT. Unauthorized use, including screenshots, copying, misuse, reuse, or resale of any content from this app, is strictly prohibited. Our app monitors and records all screenshots and recordings. Violators will face strict legal action.

DISCLAIMER

THIS IS COPYRIGHTED CONTENT. Unauthorized use, including screenshots, copying, misuse, reuse, or resale of any content from this app, is strictly prohibited. Our app monitors and records all screenshots and recordings. Violators will face strict legal action.

THIS IS COPYRIGHTED CONTENT. Unauthorized use, including screenshots, copying, misuse, reuse, or resale of any content from this app, is strictly prohibited. Our app monitors and records all screenshots and recordings. Violators will face strict legal action.

DISCLAIMER

ENDODONTIC FAILURE

Source- Articles, TG, Textbook of Endodontic Principle and Practice

Cause:

- Searching for the pulp chamber or orifices of canals through an underprepared access cavity may also result in accidents.

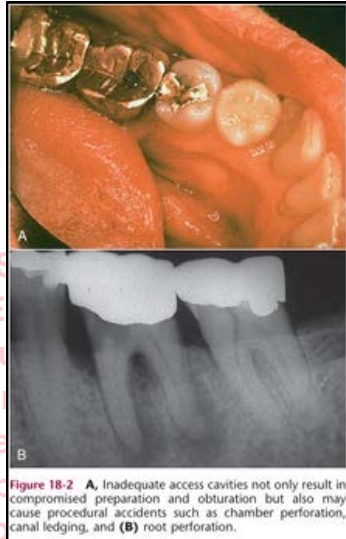


Figure 18-2 A, Inadequate access cavities not only result in compromised preparation and obturation but also may cause procedural accidents such as chamber perforation, canal ledging, and (B) root perforation.

- Failing to recognize when the bur passes through a small or flattened (disklike) pulp chamber in a multirooted tooth may also result in gouging or perforation of the furcation.

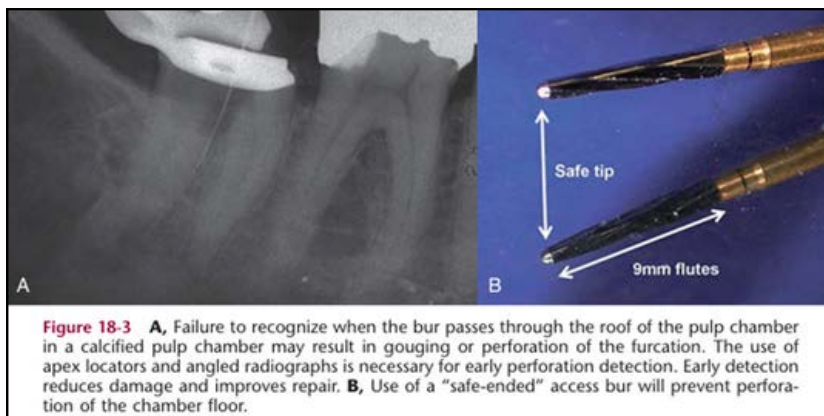


Figure 18-3 A, Failure to recognize when the bur passes through the roof of the pulp chamber in a calcified pulp chamber may result in gouging or perforation of the furcation. The use of apex locators and angled radiographs is necessary for early perforation detection. Early detection reduces damage and improves repair. B, Use of a "safe-ended" access bur will prevent perforation of the chamber floor.

THIS IS COPYRIGHTED CONTENT. Unauthorized use, including screenshots, copying, misuse, reuse, or resale of any content from this app, is strictly prohibited. Our app monitors and records all screenshots and recordings. Violators will face strict legal action.

DISCLAIMER

THIS IS COPYRIGHTED CONTENT. Unauthorized use, including screenshots, copying, misuse, reuse, or resale of any content from this app, is strictly prohibited. Our app monitors and records all screenshots and recordings. Violators will face strict legal action.

DISCLAIMER
THIS IS COPYRIGHTED CONTENT. Unauthorized use, including screenshots, copying, misuse, reuse, or resale of any content from this app, is strictly prohibited. Our app monitors and records all screenshots and recordings. Violators will face strict legal action.

THIS IS COPYRIGHTED CONTENT. Unauthorized use, including screenshots, copying, misuse, reuse, or resale of any content from this app, is strictly prohibited. Our app monitors and records all screenshots and recordings. Violators will face strict legal action.

DISCLAIMER

ENDODONTIC FAILURE

Source- Articles, TG, Textbook of Endodontic Principle and Practice

Prevention

- Thorough knowledge of tooth morphology, including both surface and internal anatomy and their relationships, is mandatory to prevent pulp chamber perforations.
- Location and angulation of the tooth must be related to adjacent teeth and alveolar bone to avoid a misaligned access preparation.
- Radiographs should be taken from different angulations as they are a 2-dimensional projection of 3-dimensional object, to determine the size and extent of the pulp chamber including calcifications and resorptions.
- Failure to recognize when the bur passes through the roof of the pulp chamber if the chamber is calcified may result in gouging or perforation of the furcation. After penetration of the roof of the chamber, using a “safe ended” access bur, such as the Endo Z or a pulp shaper bur, will prevent perforation of the chamber floor.
- The use of apex locators and angled radiographs is necessary for early perforation detection. Early detection reduces damage caused by continued treatment (irrigation, cleaning and shaping) and improves the prognosis for nonsurgical repair.
- To ensure proper visualization of the crown root alignment and also providing adequate isolation a spilt dam can be used.
- To orient the access, a bur may be placed in the preparation hole (secured with cotton pellets) and then radio graphed. This provides information about depth of access in relation to canal location. A direct facial radiograph will show the mesiodistal relationship; a mesial- or distal-angled film will show the faciolingual location. This procedure is helpful for locating small canals.
- Magnification loupes (2.5 mm or greater) along with transillumination will aid in locating canal orifices.

Treatment:

- Perforations will mostly lead to immediate and continuous hemorrhage. Early detection of perforation is of utmost importance. Early signs of perforations can be one or more of the following:
 - a) Sudden pain during working length determination when local anesthesia was adequate.
 - b) Sudden appearance of hemorrhage
 - c) Burning pain or bad taste during irrigation with sodium hypochlorite
 - d) Radiographically malpositioned file
 - e) PDL reading from an apex locator, far short from the working length
- When perforation has occurred or suspected referral to endodontist is recommended as a specialist is better equipped to manage these patients. Also, if failure occurs surgical retreatment may be necessary.

DISCLAIMER

THIS IS COPYRIGHTED CONTENT. Unauthorized use, including screenshots, copying, misuse, reuse, or resale of any content from this app, is strictly prohibited. Our app monitors and records all screenshots and recordings. Violators will face strict legal action.

ENDODONTIC FAILURE

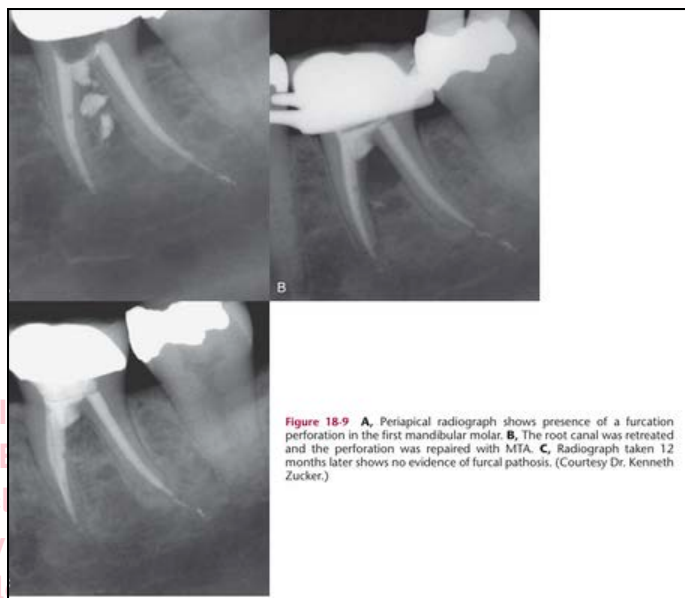
Source- Articles, TG, Textbook of Endodontic Principle and Practice

Treatment of lateral Canal perforation:

- The location and size of perforations are important. If the defect is at or above the crestal bone height, they can be easily repaired with standard restorative material such as composite, GIC, amalgam or in some cases full crown with margins extending apically to cover the defect and the prognosis is favorable. Periodontal curettage or flap surgeries may be required sometimes to place the restorative material.
- If the perforations are below the crestal bone in the coronal third of the root the prognosis is poorest. Attachment often recedes and a periodontal pocket form, with attachment loss extending apically to at least the depth of the defect. The treatment goal is to position the apical portion of the defect above crestal bone. Orthodontic root extrusion is generally the procedure of choice for teeth in the esthetic zone. Crown lengthening may be considered when the esthetic result will not be compromised or when adjacent teeth require surgical periodontal therapy. MTA is the material of choice to repair these perforations as they provide excellent seal.

Treatment of Furcation perforations:

- If feasible, non-surgical repair of furcation perforations are preferred over surgical intervention. Perforations occurring during access preparation should be sealed immediately, but the patency of the canals must be protected. Immediate repair of the perforations with MTA offers the best results for perforation repair.



DISCLAIMER

THIS IS COPYRIGHTED CONTENT. Unauthorized use, including screenshots, copying, misuse, reuse, or resale of any content from this app, is strictly prohibited. Our app monitors and records all screenshots and recordings. Violators will face strict legal action.

DISCLAIMER

THIS IS COPYRIGHTED CONTENT. Unauthorized use, including screenshots, copying, misuse, reuse, or resale of any content from this app, is strictly prohibited. Our app monitors and records all screenshots and recordings. Violators will face strict legal action.

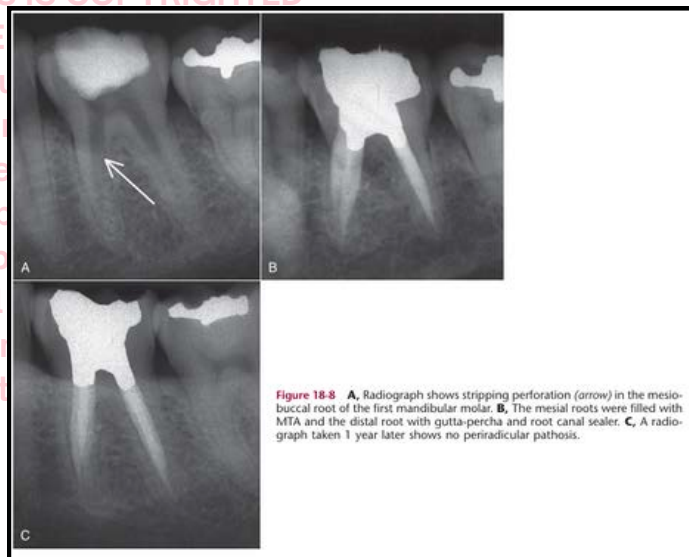
DISCLAIMER

THIS IS COPYRIGHTED CONTENT. Unauthorized use, including screenshots, copying, misuse, reuse, or resale of any content from this app, is strictly prohibited. Our app monitors and records all screenshots and recordings. Violators will face strict legal action.

ENDODONTIC FAILURE

Source- Articles, TG, Textbook of Endodontic Principle and Practice

- A perforation of furcation can be either direct type or stripping type.
- Direct perforation is more of a punched-out defect into the furcation with a bur and is accessible. This type of defect should be repaired immediately with MTA (if possible). If dryness can be achieved it can be sealed with GIC or composite. Prognosis is good if sealed immediately.
- A stripping perforation involves the furcation side of the coronal root surface and results from excessive flaring with files or drills. They are generally not accessible unlike direct perforations which are accessible and these may require more elaborated repair procedure like surgical repair.



- Surgical alternatives are hemisection, bicuspidization, root amputation, and intentional replantation. Teeth with divergent roots and bone levels that allow preparation of adequate crown margins are suitable for either hemisection or bicuspidization. Intentional replantation is indicated when the defect is inaccessible or when multiple problems exist, such as a perforation combined with a separated instrument, or when the prognosis with other surgical procedures is poor. The prognosis of surgically altered teeth is guarded.

DISCLAIMER

THIS IS COPYRIGHTED CONTENT. Unauthorized use, including screenshots, copying, misuse, reuse, or resale of any content from this app, is strictly prohibited. Our app monitors and records all screenshots and recordings. Violators will face strict legal action.

DISCLAIMER

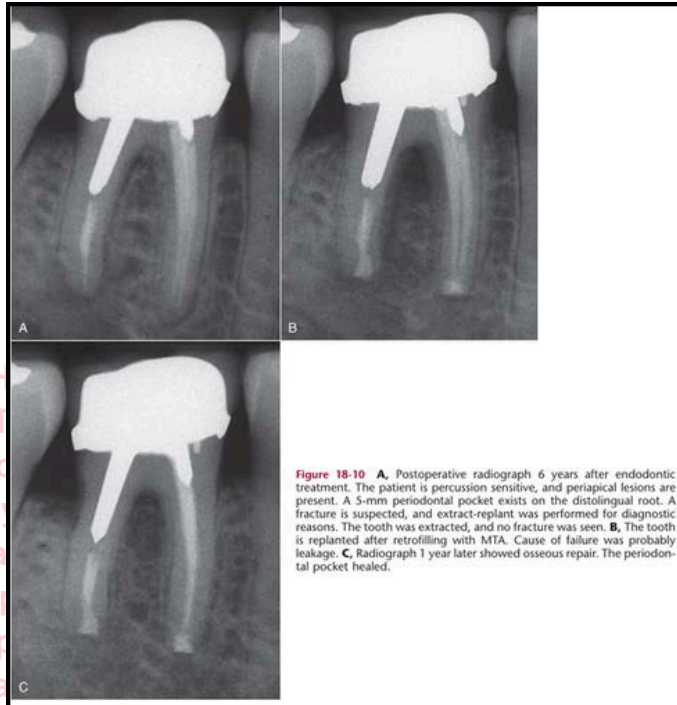
THIS IS COPYRIGHTED CONTENT. Unauthorized use, including screenshots, copying, misuse, reuse, or resale of any content from this app, is strictly prohibited. Our app monitors and records all screenshots and recordings. Violators will face strict legal action.

THIS IS COPYRIGHTED CONTENT. Unauthorized use, including screenshots, copying, misuse, reuse, or resale of any content from this app, is strictly prohibited. Our app monitors and records all screenshots and recordings. Violators will face strict legal action.

DISCLAIMER

ENDODONTIC FAILURE

Source- Articles, TG, Textbook of Endodontic Principle and Practice



D) Ledge Formation

- A ledge can be created when the working length can no longer be negotiated and the original patency of the canal is lost.

Cause:

- Inadequate straight-line access to the canal.
- Inadequate irrigation or lubrication.
- Excessive enlargement of curved canals with files.
- Packing debris in the apical portion of the canal.

Prevention

- Prevention begins with the preoperative radiographs for curvatures, length and size.
- The canals most prone to ledging are longer, curved and small in diameter and care should be taken when leaning and shaping of the canals. Working length should be adequately determined as a short working length is a prelude to ledge formation.

DISCLAIMER

THIS IS COPYRIGHTED CONTENT. Unauthorized use, including screenshots, copying, misuse, reuse, or resale of any content from this app, is strictly prohibited. Our app monitors and records all screenshots and recordings. Violators will face strict legal action.

DISCLAIMER

THIS IS COPYRIGHTED CONTENT. Unauthorized use, including screenshots, copying, misuse, reuse, or resale of any content from this app, is strictly prohibited. Our app monitors and records all screenshots and recordings. Violators will face strict legal action.

THIS IS COPYRIGHTED CONTENT. Unauthorized use, including screenshots, copying, misuse, reuse, or resale of any content from this app, is strictly prohibited. Our app monitors and records all screenshots and recordings. Violators will face strict legal action.

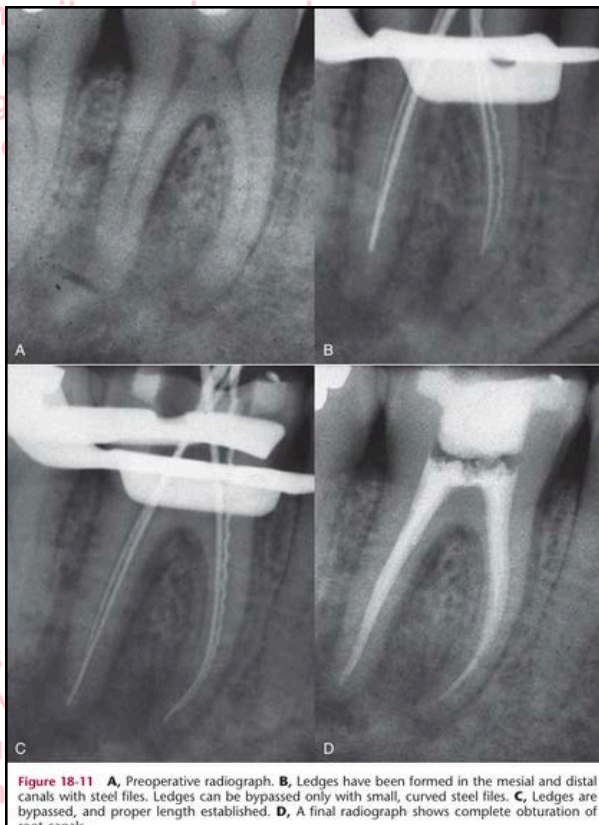
DISCLAIMER

ENDODONTIC FAILURE

Source- Articles, TG, Textbook of Endodontic Principle and Practice

Treatment:

- It is difficult to correct a ledge once created.
- An initial attempt should be made to bypass the ledge with a No. 10 steel file to regain working length. The file tip about 2 -3mm is sharply bent and worked in the canal in the direction of canal curvature.
- To feel the catch of the original canal space a picking motion can be used. If the original canal is located the file is then worked with a reaming motion and occasionally an up-and-down movement to maintain the space and remove debris.
- If the original canal cannot be located by this method, cleaning and shaping of the existing canal space is completed at the new working length. At times, flaring of the canal may allow the ledge to be bypassed by providing improved access to the apical canal.
- Failure of root canal treatment associated with ledging depends on the amount of debris left in the uninstrumented and unfilled portion of the canal. Generally, cleaned apical ledges have good prognoses.



DISCLAIMER

THIS IS COPYRIGHTED CONTENT. Unauthorized use, including screenshots, copying, misuse, reuse, or resale of any content from this app, is strictly prohibited. Our app monitors and records all screenshots and recordings. Violators will face strict legal action.

DISCLAIMER

THIS IS COPYRIGHTED CONTENT. Unauthorized use, including screenshots, copying, misuse, reuse, or resale of any content from this app, is strictly prohibited. Our app monitors and records all screenshots and recordings. Violators will face strict legal action.

DISCLAIMER

THIS IS COPYRIGHTED CONTENT. Unauthorized use, including screenshots, copying, misuse, reuse, or resale of any content from this app, is strictly prohibited. Our app monitors and records all screenshots and recordings. Violators will face strict legal action.

ENDODONTIC FAILURE

Source- Articles, TG, Textbook of Endodontic Principle and Practice

E) Artificial Canal creation

Cause:

- Deviation from the original pathway of the root canal system and creation of an artificial canal cause an exaggerated ledge. It is initiated by the factors that cause ledge formation.
- It occurs when a ledge is created and the proper working length is lost. And, the operator, eager to regain that length, “bores” apically with each file, thus creating an artificial canal, if used persistently it leads to perforation of root surface.

Prevention:

- Prevention of formation of ledge will avoid formation of artificial canal.

Treatment:

- Negotiating the original canal that has an exaggerated ledge is normally very difficult. The incidence of original canal location, renegotiation and preparation is very rare

F) Root perforations

- Roots may be perforated at different levels during cleaning and shaping. Location of the perforation (apical, middle, or cervical) and the stage of treatment affect prognosis. The periodontal response to the injury is affected by the level and size of the perforation.

1) Apical perforation:

Causes:

- Apical perforations occur through the apical foramen (over instrumentation) or through the body of the root (perforated new canal).
- Instrumentation of the canal beyond the apical constriction results in perforation. Incorrect working length or inability to maintain proper working length causes “zipping” or “blowing out” of the apical foramen.
- The appearance of fresh hemorrhage in the canal or on instruments, pain during canal preparation in a previously asymptomatic tooth, and sudden loss of the apical stop are indicators of foramen perforation. Extension of the largest (final) file beyond the radiographic apex is also a sign.

Treatment

- Treatment includes establishing a new working length, creating an apical seat (taper), and obturating the canal to its new length.
- Depending on the size and location of the apical foramen, a new working length 1 to 2 mm short of the point of perforation should be established.
- The canal is then cleaned, shaped, and obturated to the new working length. The master cone must have a positive apical stop at the working length before obturation. Placement of MTA as an apical barrier can prevent extrusion of obturation materials.

DISCLAIMER

THIS IS COPYRIGHTED CONTENT. Unauthorized use, including screenshots, copying, misuse, reuse, or resale of any content from this app, is strictly prohibited. Our app monitors and records all screenshots and recordings. Violators will face strict legal action.

DISCLAIMER

THIS IS COPYRIGHTED CONTENT. Unauthorized use, including screenshots, copying, misuse, reuse, or resale of any content from this app, is strictly prohibited. Our app monitors and records all screenshots and recordings. Violators will face strict legal action.

THIS IS COPYRIGHTED CONTENT. Unauthorized use, including screenshots, copying, misuse, reuse, or resale of any content from this app, is strictly prohibited. Our app monitors and records all screenshots and recordings. Violators will face strict legal action.

DISCLAIMER

ENDODONTIC FAILURE

Source- Articles, TG, Textbook of Endodontic Principle and Practice

2) Lateral (Mid root) Perforation:

Causes:

- Inability to maintain the canal curvature is the main cause of ledge formation, if the original canal is lost and artificial canal is formed it can lead to mid root or apical perforation.

Prevention:

- To avoid these perforations, the same factors mentioned earlier for prevention of ledge formation should be considered: (1) degree of canal curvature and size and (2) inflexibility of the larger files, especially stainless-steel files.

3) Coronal root perforations:

Causes:

- Coronal root perforations occur during access preparation while trying to locate canal orifices or during flaring procedures with files, Gates-Glidden drills, or Peeso reamers.
- Repair and prevention as mentioned above.

G) Aspiration or ingestion:

- Aspiration of instruments is a serious accident which results in failure but can be easily avoided by use of proper rubber dam.

H) Extrusion of Irrigation:

- Wedging of a needle in the canal (or out of a perforation) with forceful expression of irrigant (usually NaOCl) causes penetration of irrigants into the periradicular tissues leading to inflammation and discomfort for patients.
- Extrusion of NaOCl into the periapical tissues can cause a life-threatening emergency. Loose placement of irrigation needles and careful irrigation with light pressure or use of a perforated needle prevents extrusion of irrigants.
- Sudden prolonged and sharp pain during irrigation followed by rapid diffuse swelling usually indicates penetration of solution into the periradicular tissues. The acute episode will subside spontaneously with time.

I) Vertical root fractures:

- Complete vertical root fractures lead to untreatable failure.

**Refer to H.O.T notes for VRF*

J) Perforation during post space formation:

- To prevent root perforation, gutta-percha may be removed to the desired level with heated pluggers or electronic heating device.

**Refer to H.O.T notes for post space accidents.*

DISCLAIMER

THIS IS COPYRIGHTED CONTENT. Unauthorized use, including screenshots, copying, misuse, reuse, or resale of any content from this app, is strictly prohibited. Our app monitors and records all screenshots and recordings. Violators will face strict legal action.

DISCLAIMER

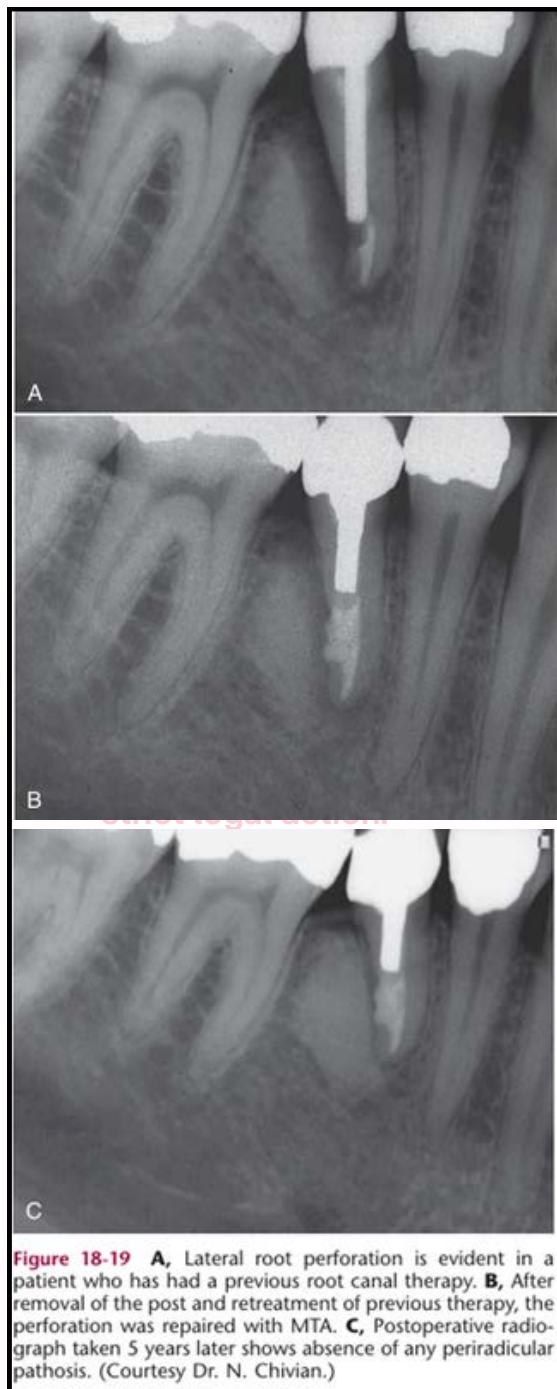
THIS IS COPYRIGHTED CONTENT. Unauthorized use, including screenshots, copying, misuse, reuse, or resale of any content from this app, is strictly prohibited. Our app monitors and records all screenshots and recordings. Violators will face strict legal action.

THIS IS COPYRIGHTED CONTENT. Unauthorized use, including screenshots, copying, misuse, reuse, or resale of any content from this app, is strictly prohibited. Our app monitors and records all screenshots and recordings. Violators will face strict legal action.

DISCLAIMER

ENDODONTIC FAILURE

Source- Articles, TG, Textbook of Endodontic Principle and Practice



including screenshots,
copying, misuse, reuse, or
resale of any content from
this app, is strictly prohibited.
Our app monitors and records
all screenshots and
recordings. Violators will face
strict legal action.

DISCLAIMER

THIS IS COPYRIGHTED CONTENT. Unauthorized use, including screenshots, copying, misuse, reuse, or resale of any content from this app, is strictly prohibited. Our app monitors and records all screenshots and recordings. Violators will face strict legal action.

THIS IS COPYRIGHTED
CONTENT. Unauthorized use,
including screenshots,
copying, misuse, reuse, or
resale of any content from
this app, is strictly prohibited.
Our app monitors and records
all screenshots and
recordings. Violators will face
strict legal action.

THIS IS COPYRIGHTED
CONTENT. Unauthorized use,
including screenshots,
copying, misuse, reuse, or
resale of any content from
this app, is strictly prohibited.
Our app monitors and records
all screenshots and
recordings. Violators will face
strict legal action.

DISCLAIMER
THIS IS COPYRIGHTED CONTENT. Unauthorized use, including screenshots, copying, misuse, reuse, or resale of any content from this app, is strictly prohibited. Our app monitors and records all screenshots and recordings. Violators will face strict legal action.

COMBINED LESIONS

- Endodontic and periodontal diseases can sometimes appear with very similar signs and symptoms. Thus, diagnosis can be challenging.
- Treatment and prognosis of endodontic-periodontal diseases depend on the etiology and correct diagnosis of the specific condition.

Pathways for communication between Dental Pulp and periodontium

Source- Walton + Article on Endo Perio lesion

- Several pathways are there for the communication between the pulp and periodontal tissues. Most of them are anatomical pathways but some can be pathological or iatrogenic in origin.

1) Apical Foramen

- The apical foramen is the principal route of communication between the pulp and periodontium.
- Sometimes, it may allow travel of bacteria and their byproducts from root canal to periapical tissues or in cases of periodontal disease it may allow bacteria to travel from periodontium to pulp.

2) Lateral and Accessory Canals:

- They are the small branches of communication between the pulp and periodontal tissues.
- It is estimated that 30% to 40% of all teeth have lateral or accessory canals, mostly found in the apical third of the root.
- A study (De Deus) reported that 17% of the teeth examined had lateral canals in the apical third of the root, about 9% in the middle third, and less than 2% in the coronal third.
- Accessory canals in the furcation of molars may also be a direct pathway of communication between the pulp and the periodontium.
- Patent accessory canals are a potential pathway for the spread of microorganisms and their toxic byproducts, as well as other irritants, from the pulp to the PDL and vice versa, resulting in an inflammatory process in the involved tissues.

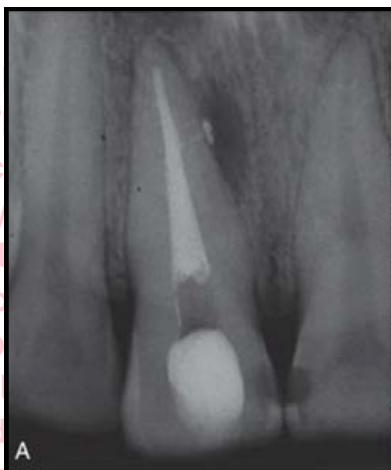

Image: Maxillary central incisor with radiopaque material extruding through lateral canal. (Source-Walton)

DISCLAIMER

THIS IS COPYRIGHTED CONTENT. Unauthorized use, including screenshots, copying, misuse, reuse, or resale of any content from this app, is strictly prohibited. Our app monitors and records all screenshots and recordings. Violators will face strict legal action.

DISCLAIMER

THIS IS COPYRIGHTED CONTENT. Unauthorized use, including screenshots, copying, misuse, reuse, or resale of any content from this app, is strictly prohibited. Our app monitors and records all screenshots and recordings. Violators will face strict legal action.

THIS IS COPYRIGHTED CONTENT. Unauthorized use, including screenshots, copying, misuse, reuse, or resale of any content from this app, is strictly prohibited. Our app monitors and records all screenshots and recordings. Violators will face strict legal action.

DISCLAIMER

COMBINED LESIONS

3) Dentinal Tubules

- Dentin is a permeable tissue due to presence of dentinal tubules, which can potentially form a communication between the pulp and periodontium.
- These tubules are normally protected externally by enamel in the coronal portion of tooth and cementum in the radicular portion of tooth. These layers helps to limit the permeability of tubules at the outer extent of the tooth.
- Cementum acts as a protective barrier, but direct communication may be established between the pulp and the periodontium via patent dentinal tubules if the cementum is missing.
- The cementum may be missing as a result of developmental defects, disease processes, or damaged during scaling and root planning especially in patients with long standing periodontal disease who require frequent cleaning of the root surface.
- In some teeth (about 30%) there is naturally occurring gap at the CEJ (Cemento enamel junction) where neither enamel nor cementum is protecting the dentine.
- Dental trauma or parafunction including bruxism can also damage cementum, and if damaged the dentinal tubules are exposed creating a pathway for bacteria to travel between pulp and periodontium.
- Cementum can sometimes delaminate from the underlying dentine in localized area which are referred to as cemental tears, that is thought to be caused as some teeth have inherent weakness at the junction of cementum and dentine predisposing to cemental tears.
- As the dentine is left unprotected in the areas beneath cemental tears it can lead to passage of bacteria between periodontal tissues and root canal system.

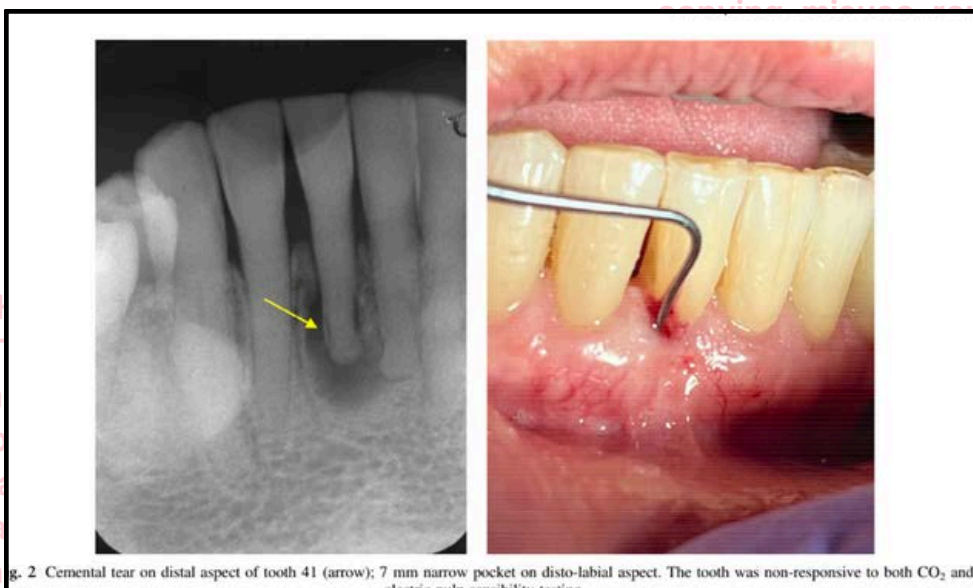


Fig. 2 Cemental tear on distal aspect of tooth 41 (arrow); 7 mm narrow pocket on disto-labial aspect. The tooth was non-responsive to both CO₂ and

(Source- Article)

DISCLAIMER

THIS IS COPYRIGHTED CONTENT. Unauthorized use, including screenshots, copying, misuse, reuse, or resale of any content from this app, is strictly prohibited. Our app monitors and records all screenshots and recordings. Violators will face strict legal action.

DISCLAIMER

THIS IS COPYRIGHTED CONTENT. Unauthorized use, including screenshots, copying, misuse, reuse, or resale of any content from this app, is strictly prohibited. Our app monitors and records all screenshots and recordings. Violators will face strict legal action.

DISCLAIMER

THIS IS COPYRIGHTED CONTENT. Unauthorized use, including screenshots, copying, misuse, reuse, or resale of any content from this app, is strictly prohibited. Our app monitors and records all screenshots and recordings. Violators will face strict legal action.

COMBINED LESIONS

4) Developmental grooves and malformations

- Radicular grooves also known as palato-gingival grooves due to incomplete in folding of enamel organ and HERS can lead to communication between dental pulp and periodontium.
- These grooves are difficult for patient to clean even if meticulous hygiene is maintained.
- Most commonly found on the disto- palatal surface of maxillary lateral incisor teeth. They also occur on maxillary central incisor and lingual surface of mandibular second molars.

5) Non-Anatomic Pathways

- Pathological causes like perforating inflammatory root resorption or cracks in the root can lead to non-anatomical communication between pulp and periapical tissues.
- Iatrogenic causes like perforation of root or furcation during endodontic or restorative procedure will lead to direct communication between the root canal system, its contents and periodontium.

Etiological and contributing factors for endo-perio lesion (Source-Walton)

- Bacteria, fungi, viruses and spirochetes along with their byproducts found in dental pulp can cause lesions in periodontium as well. Non-living pathogens like foreign bodies (such as dentin and cementum chips, root canal filling materials, food debris, inflamed epithelium, cholesterol crystals, Russell bodies, Rushton hyaline bodies are also possible etiological factors for endo perio lesion.
- Inadequate endodontic treatment is an important contributing factor as it allows canal reinfection which leads to treatment failure and inflammatory reactions in periodontal tissues.

Effect of Endodontic lesion on Periodontal tissues: (Source-Article and Walton)

- When the pulp becomes infected, it elicits an inflammatory response of the PDL at the apical foramen or adjacent to openings of lateral and accessory canals.
- This inflammatory response causes localized attachment loss and tissue damage close to the area of communication. In patients with healthy periodontium and intact cementum layer endodontic infections will mostly resolve after appropriate endodontic treatment which removes the source of infection and the periodontal tissues is usually not affected.
- If a patient has an active periodontal disease or damage to the cementum endodontic infection can exacerbate or maintain existing periodontal infections.
- Procedural errors during root canal treatment can also cause inflammatory response in the periodontium. However, these are usually transient in nature and resolves quickly if the materials are confined within the canal space.

DISCLAIMER

THIS IS COPYRIGHTED CONTENT. Unauthorized use, including screenshots, copying, misuse, reuse, or resale of any content from this app, is strictly prohibited. Our app monitors and records all screenshots and recordings. Violators will face strict legal action.

DISCLAIMER

THIS IS COPYRIGHTED CONTENT. Unauthorized use, including screenshots, copying, misuse, reuse, or resale of any content from this app, is strictly prohibited. Our app monitors and records all screenshots and recordings. Violators will face strict legal action.

THIS IS COPYRIGHTED CONTENT. Unauthorized use, including screenshots, copying, misuse, reuse, or resale of any content from this app, is strictly prohibited. Our app monitors and records all screenshots and recordings. Violators will face strict legal action.

DISCLAIMER

COMBINED LESIONS

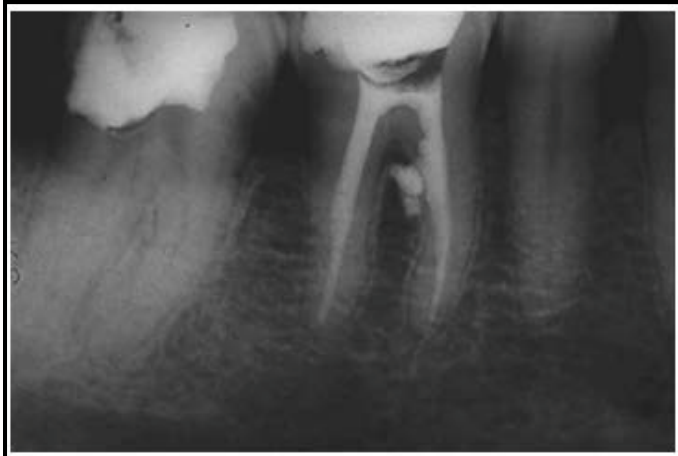


Figure 6-2 Inadequate canal access and instrumentation in a mandibular first molar. As a result, strip perforation and gross extrusion of sealer has occurred.

Fig: Strip perforation resulting in periodontal damage (Source-Walton)

Effect of Periodontal Disease on the Pulp: (Source-Walton and article)

- It appears that the pulp is usually not severely affected by periodontal disease until the defect has reached the apex.
- In teeth with only periodontal disease, the pulp is mostly not affected, despite of the severity of bone loss or extensiveness of the periodontal disease. However, when the periodontal disease is of such extent that a pocket reaches the apical foramen the pulps defense is lost resulting in infection and necrosis in some cases.

Classification of Endodontic and Periodontal lesions: (Source-Article, Walton and Internet)

A) Based on origin of infection (Simon et.al)

1) Primary periodontal Disease:

- It is primarily caused by periodontal pathogens where the accumulation of plaque and calculus results in inflammatory response and leads to loss of alveolar bone.

Clinical Findings:

- The bone loss is clinically probed as a wide based pocket. Gingival recession with mobile teeth may also be seen as the disease progress.
- Lesions of periodontal origin usually but not always involve multiple teeth.
- Generally minimal or no pain is seen unless an acute exacerbation occurs leading to periodontal abscess.

THIS IS COPYRIGHTED CONTENT. Unauthorized use, including screenshots, copying, misuse, reuse, or resale of any content from this app, is strictly prohibited. Our app monitors and records all screenshots and recordings. Violators will face strict legal action.

DISCLAIMER
THIS IS COPYRIGHTED CONTENT. Unauthorized use, including screenshots, copying, misuse, reuse, or resale of any content from this app, is strictly prohibited. Our app monitors and records all screenshots and recordings. Violators will face strict legal action.

DISCLAIMER

THIS IS COPYRIGHTED CONTENT. Unauthorized use, including screenshots, copying, misuse, reuse, or resale of any content from this app, is strictly prohibited. Our app monitors and records all screenshots and recordings. Violators will face strict legal action.

DISCLAIMER

THIS IS COPYRIGHTED CONTENT. Unauthorized use, including screenshots, copying, misuse, reuse, or resale of any content from this app, is strictly prohibited. Our app monitors and records all screenshots and recordings. Violators will face strict legal action.

COMBINED LESIONS

Classification of Endodontic and Periodontal lesions:
(Source-Article, Walton and Internet)

A) Based on origin of infection (Simon et.al)

1) Primary periodontal Disease:

- It is primarily caused by periodontal pathogens where the accumulation of plaque and calculus results in inflammatory response and leads to loss of alveolar bone.

Clinical Findings:

- The bone loss is clinically probed as a wide based pocket. Gingival recession with mobile teeth may also be seen as the disease progress.
- Lesions of periodontal origin usually but not always involve multiple teeth.
- Generally minimal or no pain is seen unless an acute exacerbation occurs leading to periodontal abscess.

Radiographic Finding:

- Usually, angular bone loss or horizontal bone loss is seen extending from cervical region towards the apex.
- Attachment loss due to periodontal disease usually begins at proximal regions or in the furcation regions in a multirooted tooth.

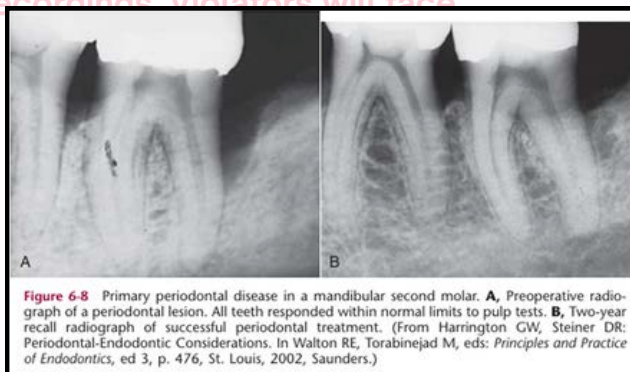
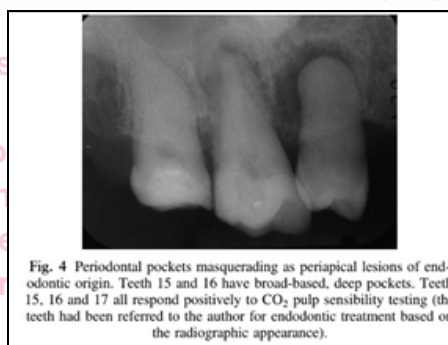



Fig: (Source-Walton)

- In cases where apical extent of bone loss is severe enough, the periodontal pocket can mimic a periapical lesion which is due to the projection geometry of the X-ray overlapping the pocket and apex of tooth.



- Therefore, Pulp sensibility testing is necessary in all cases.

DISCLAIMER

THIS IS COPYRIGHTED CONTENT. Unauthorized use, including screenshots, copying, misuse, reuse, or resale of any content from this app, is strictly prohibited. Our app monitors and records all screenshots and recordings. Violators will face strict legal action.

THIS IS COPYRIGHTED CONTENT. Unauthorized use, including screenshots, copying, misuse, reuse, or resale of any content from this app, is strictly prohibited. Our app monitors and records all screenshots and recordings. Violators will face strict legal action.

DISCLAIMER
THIS IS COPYRIGHTED CONTENT. Unauthorized use, including screenshots, copying, misuse, reuse, or resale of any content from this app, is strictly prohibited. Our app monitors and records all screenshots and recordings. Violators will face strict legal action.

COMBINED LESIONS

Pulp testing:

- Generally, pulp sensibility testing is normal.
- This is an important tool to distinguish between primary endodontic lesion and primary periodontal lesion.

Prognosis:

- The prognosis depends on the stage of the periodontal disease and efficacy of periodontal treatment.

2) Primary Periodontal with secondary Endodontic Lesion

- If the marginal periodontitis progresses, it leads to attachment loss exposing the lateral accessory canals and even the apical foramen. In this case, the pulp may become necrotic as a result of infection entering via lateral canals or the apical foramen.

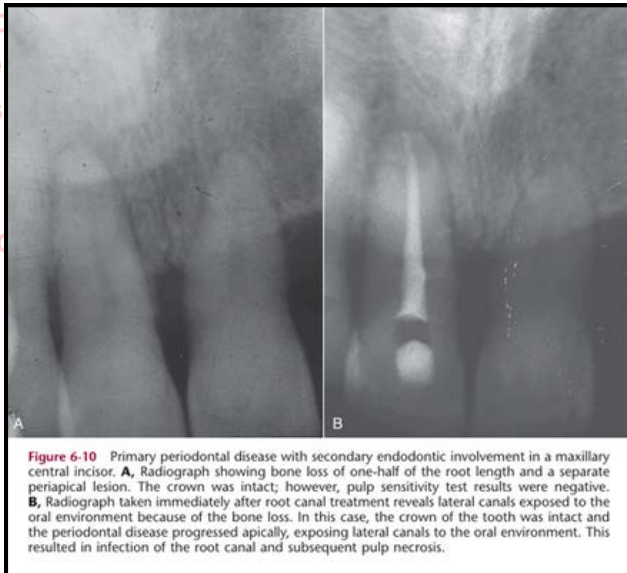


Fig: (Source-Walton)

Radiographic and Clinical Finding:

- These lesions can appear very similar to primary endodontic and secondary periodontal lesions and true combined lesions.
- However, accurate diagnosis may be achieved if no other obvious cause for endodontic infection is seen such as deep caries or restoration.

Treatment:

- Treatment involves addressing both the disease with periodontal treatment and root canal treatment.
- In multirooted tooth where periodontal disease is mostly associated with single root, root resection and hemi section can be considered if periodontal status of remaining tooth structure is deemed adequate.

DISCLAIMER

THIS IS COPYRIGHTED CONTENT. Unauthorized use, including screenshots, copying, misuse, reuse, or resale of any content from this app, is strictly prohibited. Our app monitors and records all screenshots and recordings. Violators will face strict legal action.

DISCLAIMER

THIS IS COPYRIGHTED CONTENT. Unauthorized use, including screenshots, copying, misuse, reuse, or resale of any content from this app, is strictly prohibited. Our app monitors and records all screenshots and recordings. Violators will face strict legal action.

THIS IS COPYRIGHTED CONTENT. Unauthorized use, including screenshots, copying, misuse, reuse, or resale of any content from this app, is strictly prohibited. Our app monitors and records all screenshots and recordings. Violators will face strict legal action.

DISCLAIMER

COMBINED LESIONS

Prognosis:

- Prognosis is generally determined by the severity of periodontal disease and patients' response to treatment.
- Prognosis is generally poor for single rooted tooth with apico-marginal defects.

3) Primary endodontic lesion:

- Endodontic infection generally causes inflammatory response in periapical tissue adjacent to apical foramen causing apical periodontitis.

Clinical and radiographic Findings:

- If periapical or periradicular radiolucency is present an endodontic cause may be expected if the tooth is negative to pulp testing and periodontal attachment levels are normal.
- In some cases, an acute exacerbation of a chronic apical abscess in a tooth with a necrotic pulp may drain coronally through the PDL into the gingival sulcus which is a draining sinus within the pdl space rather than through the bone and overlying soft tissues.
- These conditions can be misdiagnosed as a periodontal abscess or a primary endodontic and secondary periodontal condition.
- However, if the tooth is tender to percussion and the attachment loss or draining sinus is confined to a single tooth and is not interproximal primary endodontic condition can be suspected.

Pulp tests:

- It will reveal an abnormal or completely absent response.

Treatment and prognosis:

- Primary endodontic infections including their associated pockets and draining sinuses heal rapidly once the infected pulp has been removed from the offending tooth and the canal is cleaned and dressed.
- Periodontal intervention is usually not required.

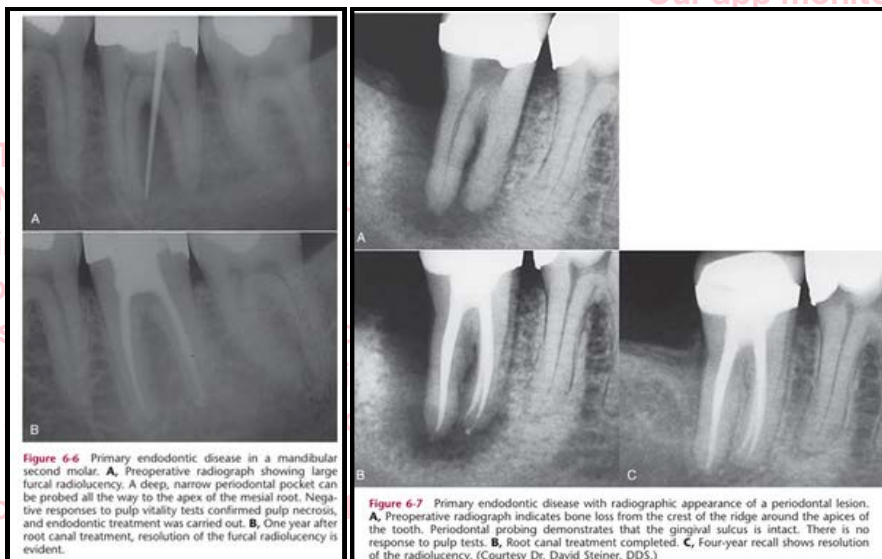


Fig: (Source-Walton)

DISCLAIMER

THIS IS COPYRIGHTED CONTENT. Unauthorized use, including screenshots, copying, misuse, reuse, or resale of any content from this app, is strictly prohibited. Our app monitors and records all screenshots and recordings. Violators will face strict legal action.

THIS IS COPYRIGHTED CONTENT. Unauthorized use, including screenshots, copying, misuse, reuse, or resale of any content from this app, is strictly prohibited. Our app monitors and records all screenshots and recordings. Violators will face strict legal action.

DISCLAIMER
THIS IS COPYRIGHTED CONTENT. Unauthorized use, including screenshots, copying, misuse, reuse, or resale of any content from this app, is strictly prohibited. Our app monitors and records all screenshots and recordings. Violators will face strict legal action.

COMBINED LESIONS

4) Primary endodontic lesion with secondary periodontal involvement

- If primary endodontic lesion is left untreated continued suppuration can sometimes lead to secondary involvement resulting in periodontal defect that becomes involved with plaque and calculus.

Radiographic Findings:

- A clear widening of the PDL space of the affected tooth extending from apical to cervical can be observed.

Pulp Tests:

- Pulp tests will usually reveal absence of response.

Probing:

- A solitary but wider pocket extending toward the apex is usually found.

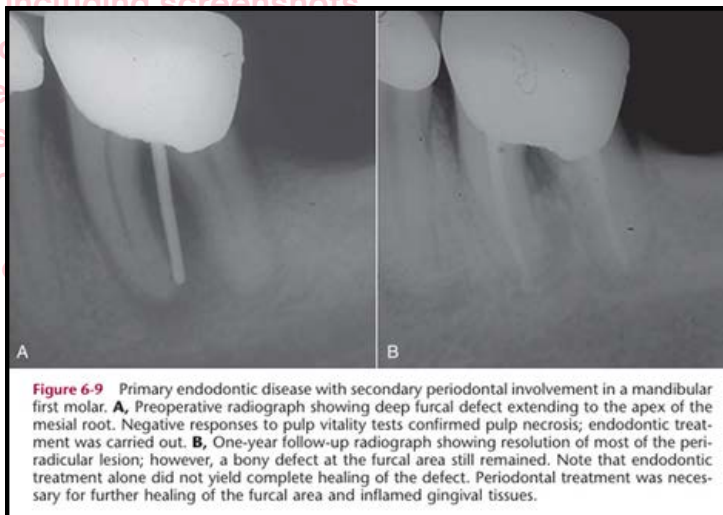


Figure 6-9 Primary endodontic disease with secondary periodontal involvement in a mandibular first molar. **A**, Preoperative radiograph showing deep furcal defect extending to the apex of the mesial root. Negative responses to pulp vitality tests confirmed pulp necrosis; endodontic treatment was carried out. **B**, One-year follow-up radiograph showing resolution of most of the peri-radicular lesion; however, a bony defect at the furcal area still remained. Note that endodontic treatment alone did not yield complete healing of the defect. Periodontal treatment was necessary for further healing of the furcal area and inflamed gingival tissues.

Treatment and Prognosis:

- Once the periodontal tissues are secondarily involved both the endodontic treatment and periodontal treatment is necessary.
- With endodontic treatment alone, only that part of the lesion that is of endodontic etiology will heal to the level of the secondary periodontal lesion.
- Primary endodontic disease with secondary periodontal involvement should first be treated with endodontic therapy. Treatment results should be evaluated in 2 to 3 months and only then should periodontal treatment be considered. This sequence of treatment allows sufficient time for initial tissue healing and better assessment of the periodontal condition.
- It also reduces the potential risk of introducing bacteria and their byproducts during the initial phase of healing.
- After adequate endodontic treatment the prognosis depends on the appropriate periodontal intervention and patient compliance with oral hygiene measure and response to treatment.

DISCLAIMER

THIS IS COPYRIGHTED CONTENT. Unauthorized use, including screenshots, copying, misuse, reuse, or resale of any content from this app, is strictly prohibited. Our app monitors and records all screenshots and recordings. Violators will face strict legal action.

DISCLAIMER

THIS IS COPYRIGHTED CONTENT. Unauthorized use, including screenshots, copying, misuse, reuse, or resale of any content from this app, is strictly prohibited. Our app monitors and records all screenshots and recordings. Violators will face strict legal action.

THIS IS COPYRIGHTED CONTENT. Unauthorized use, including screenshots, copying, misuse, reuse, or resale of any content from this app, is strictly prohibited. Our app monitors and records all screenshots and recordings. Violators will face strict legal action.

DISCLAIMER

COMBINED LESIONS

5) True Combined lesions:

- It is the least common type of endodontic periodontal lesion.
- True combined endo-perio diseases occur when an endodontic disease progressing coronally joins with a concurrent or unrelated infected periodontal pocket progressing apically.

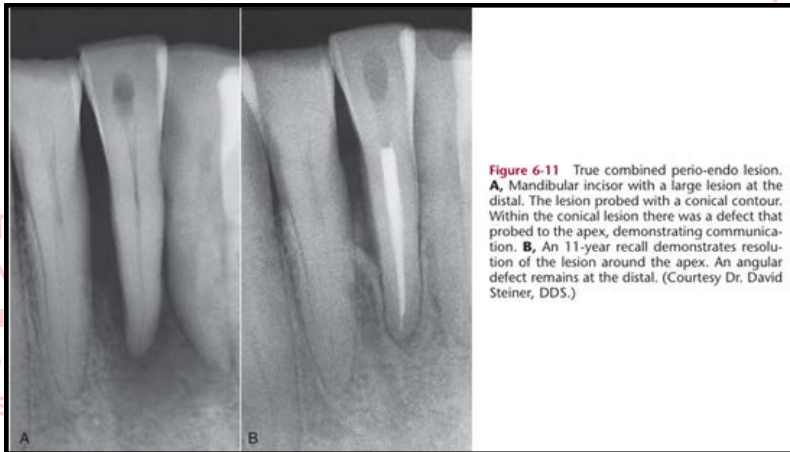


Fig: (Source-Walton)

Clinical and Radiographical Findings:

- These lesions may be clinically and radiographically indistinguishable from primary endodontic with secondary periodontal lesions and Primary periodontal with secondary endodontic lesions.
- Extensive bony radiolucency from endodontic and periodontal origins are found associated with the affected tooth. This is due to the long-standing nature of this condition.
- Depending on the stage of the disease, the lesions may or may not communicate. The radiographic appearance of combined endo-perio disease may be similar to that of a vertically fractured tooth

Treatment and prognosis:

- Because they are two separate conditions management must involve both endodontic and periodontal treatment.
- Due to the nature of combine lesions the bone loss is substantial causing negative impact on prognosis.
- The guarded prognosis must be disclosed to patient and taken into consideration while treating the disease.
- Extraction is usually recommended for single rooted tooth.
- For multi rooted tooth, hemisection of the tooth or root resection of the infected root can be considered.

DISCLAIMER

THIS IS COPYRIGHTED CONTENT. Unauthorized use, including screenshots, copying, misuse, reuse, or resale of any content from this app, is strictly prohibited. Our app monitors and records all screenshots and recordings. Violators will face strict legal action.

DISCLAIMER

THIS IS COPYRIGHTED CONTENT. Unauthorized use, including screenshots, copying, misuse, reuse, or resale of any content from this app, is strictly prohibited. Our app monitors and records all screenshots and recordings. Violators will face strict legal action.

THIS IS COPYRIGHTED CONTENT. Unauthorized use, including screenshots, copying, misuse, reuse, or resale of any content from this app, is strictly prohibited. Our app monitors and records all screenshots and recordings. Violators will face strict legal action.

DISCLAIMER

COMBINED LESIONS

b) A new classification purposed by 2017 world workshop on classification of periodontal and peri-implant diseases and condition:

- This classification has categories based on present disease status and the prognosis of the tooth involved, with a view to aid in treatment planning.
- The endodontic periodontal lesions are broadly categorized as either having root damage or not.

Table 1. Classification of endodontic-periodontal lesions. (From Papapanou *et al.*,⁴³ reproduced with permission and courtesy of John Wiley and Sons)

Endo-periodontal lesion with root damage	Root fracture or cracking	
	Root canal or pulp chamber perforation	
	External root resorption	
Endo-periodontal lesion without root damage	Endo-periodontal lesion in periodontitis patients	Grade 1—narrow deep periodontal pocket in 1 tooth surface
		Grade 2—wide deep periodontal pocket in 1 tooth surface
		Grade 3—deep periodontal pockets in > 1 tooth surface
	Endo-periodontal lesion in non-periodontitis patterns	Grade 1—narrow deep periodontal pocket in 1 tooth surface
		Grade 2—wide deep periodontal pocket in 1 tooth surface
		Grade 3—deep periodontal pockets in > 1 tooth surface

Image-Article

- However, the most commonly and widely accepted classification is based on origin by Simon et.al

THIS IS COPYRIGHTED CONTENT. Unauthorized use, including screenshots, copying, misuse, reuse, or resale of any content from this app, is strictly prohibited. Our app monitors and records all screenshots and recordings. Violators will face strict legal action.

DISCLAIMER

THIS IS COPYRIGHTED CONTENT. Unauthorized use, including screenshots, copying, misuse, reuse, or resale of any content from this app, is strictly prohibited. Our app monitors and records all screenshots and recordings. Violators will face strict legal action.

DISCLAIMER

THIS IS COPYRIGHTED CONTENT. Unauthorized use, including screenshots, copying, misuse, reuse, or resale of any content from this app, is strictly prohibited. Our app monitors and records all screenshots and recordings. Violators will face strict legal action.

THIS IS COPYRIGHTED CONTENT. Unauthorized use, including screenshots, copying, misuse, reuse, or resale of any content from this app, is strictly prohibited. Our app monitors and records all screenshots and recordings. Violators will face strict legal action.

THIS IS COPYRIGHTED CONTENT. Unauthorized use, including screenshots, copying, misuse, reuse, or resale of any content from this app, is strictly prohibited. Our app monitors and records all screenshots and recordings. Violators will face strict legal action.

DISCLAIMER

COMBINED LESIONS

Treatment Options for endo-perio lesions:

- If the etiology of endo perio lesions are not clear a consultation with specialist and referral for appropriate diagnosis is indicated.
- a) **Non-Surgical treatment of Endodontic Periodontal Disease:**
 - The treatment involves a multi-disciplinary approach.
 - Generally, treatment involves initiating endodontic treatment followed by a period of monitoring to allow the endodontic component of the disease to heal.
 - The monitoring phase allows the extent endodontic involvement to be fully assessed which in turn allows more accurate assessment of periodontal involvement and treatment needs.
 - The length of monitoring period before periodontal treatment is controversial and recommendations range from immediate treatment to delay up to 6 months.
 - In cases where the root canal has already been filled and it appears adequate in the radiograph then it is impossible to determine whether there is endodontic involvement or not. In such cases endodontic retreatment along with periodontal treatment is suggested however there is increase risk of treatment failure and the time and cost of the treatment is also increased.

b) Surgical treatment of endodontic periodontal disease:

- With more extensive periodontal defects a surgical approach to the treatment may be considered.
- The objective of the treatment is to remove the infected bioburden (in the form of plaque and calculus) and allow regeneration of periodontal tissues. The aim of such treatment is regeneration rather than repair.

Surgical Approaches:

- The most common form of surgical treatment is Open flap debridement of the affected tooth.
- Surgical treatments such as root resection or periodontally regenerative modalities can be considered as a form of reconstructive treatment.
- Grafting materials (both autologous and heterologous) can also be used either alone or along with (GTR) Guided tissue Regeneration as a means to improve the infra bony defects.
- In the comparison between open flap debridement and grafting procedures either alone or with GTR, the latter has shown more improvement in the extensive periodontal involvement

DISCLAIMER

THIS IS COPYRIGHTED CONTENT. Unauthorized use, including screenshots, copying, misuse, reuse, or resale of any content from this app, is strictly prohibited. Our app monitors and records all screenshots and recordings. Violators will face strict legal action.

DISCLAIMER

THIS IS COPYRIGHTED CONTENT. Unauthorized use, including screenshots, copying, misuse, reuse, or resale of any content from this app, is strictly prohibited. Our app monitors and records all screenshots and recordings. Violators will face strict legal action.

DISCLAIMER

THIS IS COPYRIGHTED CONTENT. Unauthorized use, including screenshots, copying, misuse, reuse, or resale of any content from this app, is strictly prohibited. Our app monitors and records all screenshots and recordings. Violators will face strict legal action.

COMBINED LESIONS

Guided tissue Regeneration (GTR)

- Guided tissue regeneration (GTR) is one form of regenerative treatment. It is based on the principle of placing a membrane that acts as a physical barrier to connective tissue and gingival epithelium during healing.
- GTR membrane stops the cells from C.T and gingival epithelium to proliferate into infra bony defect after debridement. This allows the opportunities to cells from PDL and surrounding bone to proliferate and grow into the space under the membrane.
- This barrier also stabilizes and maintains space for the blood clot that acts as a scaffold when the cells repopulate the area during regeneration.
- The difficulty with GTR is the technique sensitivity and the risk of membrane exposure that leads to bacterial contamination of the site.

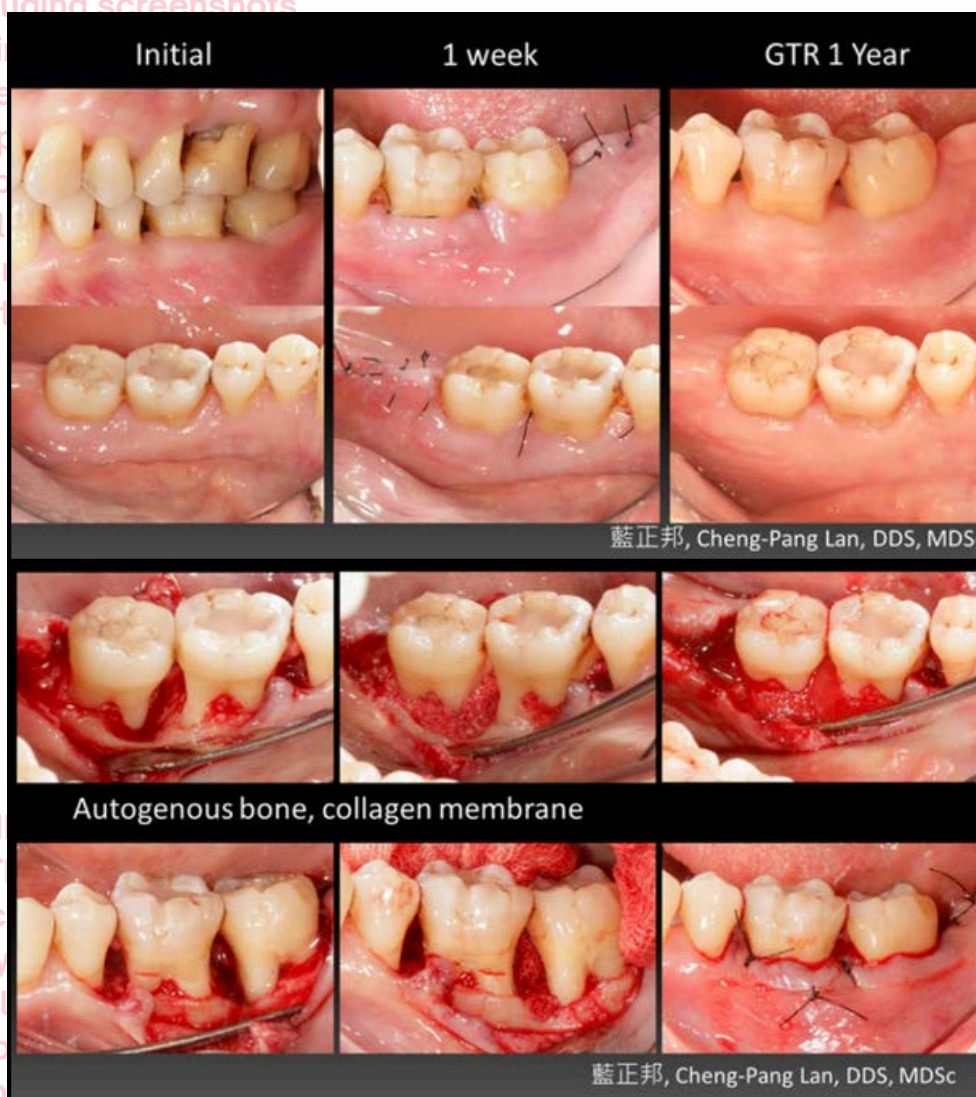

Image-Article

DISCLAIMER

THIS IS COPYRIGHTED CONTENT. Unauthorized use, including screenshots, copying, misuse, reuse, or resale of any content from this app, is strictly prohibited. Our app monitors and records all screenshots and recordings. Violators will face strict legal action.

DISCLAIMER

THIS IS COPYRIGHTED CONTENT. Unauthorized use, including screenshots, copying, misuse, reuse, or resale of any content from this app, is strictly prohibited. Our app monitors and records all screenshots and recordings. Violators will face strict legal action.

DISCLAIMER

THIS IS COPYRIGHTED CONTENT. Unauthorized use, including screenshots, copying, misuse, reuse, or resale of any content from this app, is strictly prohibited. Our app monitors and records all screenshots and recordings. Violators will face strict legal action.

COMBINED LESIONS

Healing of Periodontal surgeries:

- Wound healing modifiers can be used to aid in healing during periodontal surgery.
- Most commonly used preparations are derived from Procaine enamel matrix protein which plays a significant role in formation of attachment between dentin and cementum.
- EMD (Enamel matrix derivatives) can be applied to the root surface to help initiate the process of tissue regeneration. EMD shows equal effectiveness whether used with grafts or alone.

THIS IS COPYRIGHTED CONTENT. Unauthorized use, including screenshots, copying, misuse, reuse, or resale of any content from this app, is strictly prohibited. Our app monitors and records all screenshots and recordings. Violators will face strict legal action.

THIS IS COPYRIGHTED CONTENT. Unauthorized use, including screenshots, copying, misuse, reuse, or resale of any content from this app, is strictly prohibited. Our app monitors and records all screenshots and recordings. Violators will face strict legal action.

THIS IS COPYRIGHTED CONTENT. Unauthorized use, including screenshots, copying, misuse, reuse, or resale of any content from this app, is strictly prohibited. Our app monitors and records all screenshots and recordings. Violators will face strict legal action.

DISCLAIMER

THIS IS COPYRIGHTED CONTENT. Unauthorized use, including screenshots, copying, misuse, reuse, or resale of any content from this app, is strictly prohibited. Our app monitors and records all screenshots and recordings. Violators will face strict legal action.

DISCLAIMER
THIS IS COPYRIGHTED CONTENT. Unauthorized use, including screenshots, copying, misuse, reuse, or resale of any content from this app, is strictly prohibited. Our app monitors and records all screenshots and recordings. Violators will face strict legal action.

INTERNAL BLEACHING

Source- Articles on tooth discoloration, walking bleach technique, Text book of endodontic principle and practice 4th edition, Odell

- Tooth discoloration especially in the anterior region causes significant cosmetic impairment and patients usually seek for various measures to correct it.
- Although invasive restorative procedures such as crowns and veneers to correct the discoloration are available, tooth whitening can be achieved partially or totally by more conservative bleaching procedures that also has added benefit of simplicity of the procedure and reduced cost.
- Procedures for bleaching can be internal or external with various approaches.
- To better understand bleaching techniques, it is important to know the causes of discoloration, location of the discoloring agent, and the treatment modalities available.

Causes of tooth discoloration

- The causes of discoloration can be natural(acquired) or iatrogenic(inflicted) in nature. The natural discoloration can be on the surface or incorporated into the tooth structure that can result from flaws in enamel or traumatic injury. The iatrogenic discoloration can result from certain dental procedures and materials and can be reduced or prevented with the use of non-staining endodontic materials and placing them on a level apical to the gingival crevice whenever possible.

A) Natural discolorations

1) Pulp Necrosis

- Bacterial, mechanical, or chemical irritation of the pulp may result in necrosis. Tissue disintegration byproducts are then released, and these colored compounds may permeate tubules to stain surrounding dentin.
- The degree of discoloration is directly related to how long the pulp has been necrotic. The longer the discoloration compounds are present in the pulp chamber, the greater the discoloration.
- Internal bleaching can be a good treatment option for this type of discoloration.

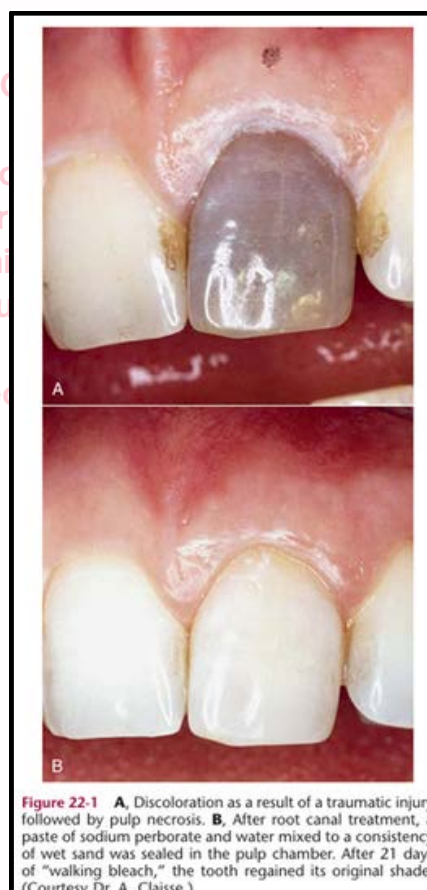

Figure 22-1 A, Discoloration as a result of a traumatic injury followed by pulp necrosis. B, After root canal treatment, a paste of sodium perborate and water mixed to a consistency of wet sand was sealed in the pulp chamber. After 21 days of "walking bleach," the tooth regained its original shade. (Courtesy Dr. A. Claisse.)

Image- Source Walton

DISCLAIMER

THIS IS COPYRIGHTED CONTENT. Unauthorized use, including screenshots, copying, misuse, reuse, or resale of any content from this app, is strictly prohibited. Our app monitors and records all screenshots and recordings. Violators will face strict legal action.

DISCLAIMER
THIS IS COPYRIGHTED CONTENT. Unauthorized use, including screenshots, copying, misuse, reuse, or resale of any content from this app, is strictly prohibited. Our app monitors and records all screenshots and recordings. Violators will face strict legal action.

THIS IS COPYRIGHTED CONTENT. Unauthorized use, including screenshots, copying, misuse, reuse, or resale of any content from this app, is strictly prohibited. Our app monitors and records all screenshots and recordings. Violators will face strict legal action.

DISCLAIMER

INTERNAL BLEACHING

Source- Articles on tooth discoloration, walking bleach technique, Text book of endodontic principle and practice 4th edition, Odell

2) Intrapulpal hemorrhage

- It is associated with an impact injury to the tooth causing disrupted coronal blood vessels, hemorrhage and lysis of erythrocytes.
- If the pulp becomes necrotic the discoloration remains and increases with time, if the pulp survives the tooth regains its original shade.
- Internal bleaching can be a successful treatment option.

3) Calcific metamorphosis

- It is an extensive formation of tertiary (irregular secondary) dentin in the pulp chamber or on canal walls.
- Usually occurs after impact injury that does not lead to pulp necrosis.
- The temporary disruption of blood supply with partial destruction of odontoblast occurs that are replaced by cells that rapidly produce irregular dentin and as a result the crowns appear flat and they gradually decrease in translucency and acquire a yellowish or yellow-brown discoloration.
- The pulp usually remains vital and root canal treatment is not required so if patient wants color correction external bleaching is attempted first and only if unsuccessful RCT followed by internal bleaching is carried out.

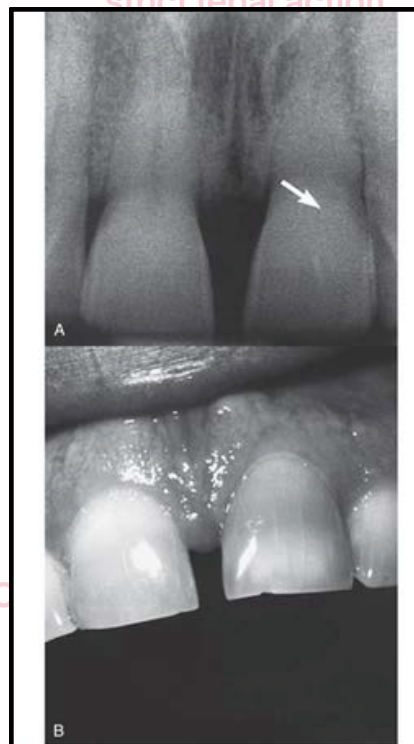


Figure 22-2 Calcific metamorphosis. Impact trauma resulted in reversible pulp damage with (A) extensive tertiary dentin formation (arrow) and (B) lost translucency and darkening of the crown. These teeth present difficulties with root canal treatment and internal bleaching.

Image- Source Walton

4) Age

- In older patients' color changes in crown occurs physiologically due to extensive dentin apposition along with thinning of enamel.
- Food and beverages also have cumulative discoloring effect.

THIS IS COPYRIGHTED CONTENT. Unauthorized use, including screenshots, copying, misuse, reuse, or resale of any content from this app, is strictly prohibited. Our app monitors and records all screenshots and recordings. Violators will face strict legal action.

DISCLAIMER

THIS IS COPYRIGHTED CONTENT. Unauthorized use, including screenshots, copying, misuse, reuse, or resale of any content from this app, is strictly prohibited. Our app monitors and records all screenshots and recordings. Violators will face strict legal action.

DISCLAIMER
THIS IS COPYRIGHTED CONTENT. Unauthorized use, including screenshots, copying, misuse, reuse, or resale of any content from this app, is strictly prohibited. Our app monitors and records all screenshots and recordings. Violators will face strict legal action.

INTERNAL BLEACHING

Source- Articles on tooth discoloration, walking bleach technique, Text book of endodontic principle and practice 4th edition, Odell

5) Developmental defects

- Tooth discoloration can occur from developmental defects in enamel and dentin during tooth formation.
- The various causes of developmental defects are:

a) Endemic Fluorosis:

- It occurs due to ingestion of excessive amount of fluoride during tooth formation.
- The teeth is not discolored during eruption but may appear chalky and the porous surface gradually absorb stains from chemicals in the oral cavity.
- As the effect is on the porous enamel such teeth are bleached externally.

b) Systemic Drugs:

- Administration or ingestion of certain drugs during tooth formation can result in discoloration which can be severe. The most common is tetracycline staining.
- The discoloration is bilateral affecting multiple teeth in both arches and it ranges from yellow through brownish to dark grey.
- Tetracycline staining can be divided into 3 groups based on severity.
 - i) First degree: Light yellow, light brown or light gray discoloration uniformly throughout crown without banding.
 - ii) Second degree: More intense but also without banding.
 - iii) Third degree: It is very intense and clinical crown shows horizontal color banding mostly in the cervical region.

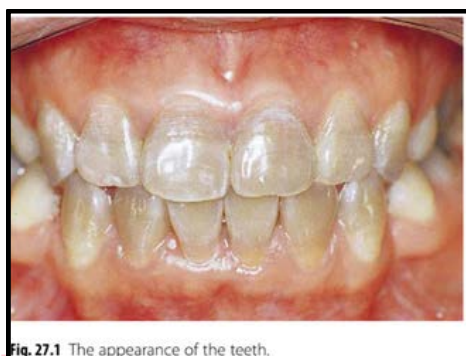

Fig. 27.1 The appearance of the teeth.

Fig: Tetracycline staining (Odell case 27)

- Treatment option involves external bleaching only if lighter defects is present but is not predictable, other is RCT followed by internal bleaching which can have more predictable results.

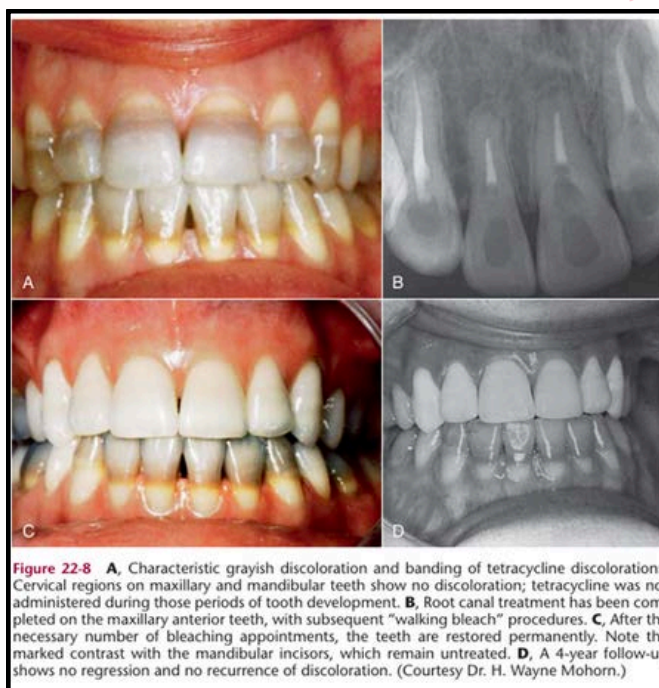


Image- Walton

DISCLAIMER

THIS IS COPYRIGHTED CONTENT. Unauthorized use, including screenshots, copying, misuse, reuse, or resale of any content from this app, is strictly prohibited. Our app monitors and records all screenshots and recordings. Violators will face strict legal action.

DISCLAIMER
THIS IS COPYRIGHTED CONTENT. Unauthorized use, including screenshots, copying, misuse, reuse, or resale of any content from this app, is strictly prohibited. Our app monitors and records all screenshots and recordings. Violators will face strict legal action.

INTERNAL BLEACHING

Source- Articles on tooth discoloration, walking bleach technique, Text book of endodontic principle and practice 4th edition, Odell

c) Defects in tooth formation:

- The defects in tooth formation when confined to enamel can be hypoplastic defects, hypomineralized defect or hypo maturation defects.
- The hypoplastic defects occurs due to deficiency in protein matrix formation and leads to porous pitted defect with irregular surface.

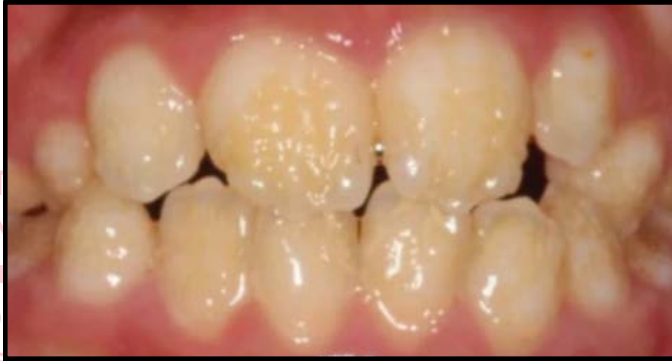

Fig: Enamel Hypoplasia with pitting defects(source-internet)

- The hypocalcification/hypomineralized defect is due to the deficiency in mineral content resulting in opaque or bright white spot on a smooth surface.

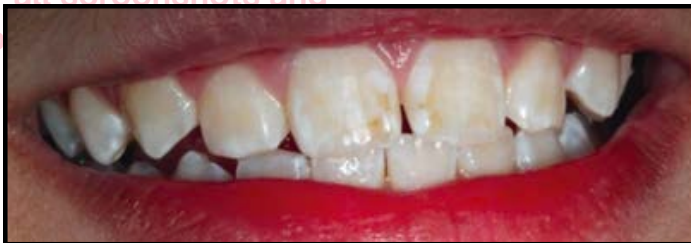

Fig: Hypomineralization defects as diffuse opacities (source-Internet)

- Hypo maturation defects can show both types of defects (pitted and smooth surface defects)
- In hereditary defects like amelogenesis imperfecta and dentinogenesis imperfecta both deciduous and permanent dentition are involved.
- Enamel defects can also manifest from disturbances in formation of enamel due to systemic diseases in the first 2 years of life and the location and teeth affected are based on chronological pattern. These mostly manifest as hypoplastic or hypomineralized banding type of surface defect which acquires stain in the oral cavity , which is known as chronological hypoplasia.

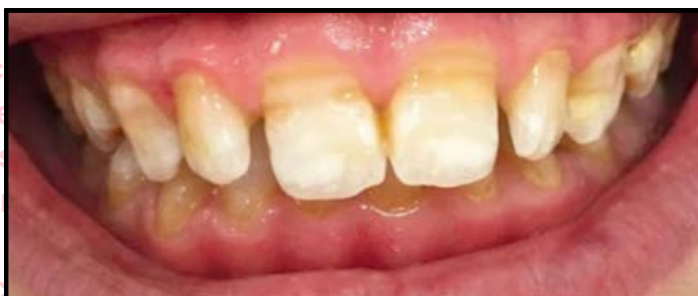

Fig: Chronological Hypoplasia (Source- Internet)

DISCLAIMER

THIS IS COPYRIGHTED CONTENT. Unauthorized use, including screenshots, copying, misuse, reuse, or resale of any content from this app, is strictly prohibited. Our app monitors and records all screenshots and recordings. Violators will face strict legal action.

DISCLAIMER

THIS IS COPYRIGHTED CONTENT. Unauthorized use, including screenshots, copying, misuse, reuse, or resale of any content from this app, is strictly prohibited. Our app monitors and records all screenshots and recordings. Violators will face strict legal action.

THIS IS COPYRIGHTED CONTENT. Unauthorized use, including screenshots, copying, misuse, reuse, or resale of any content from this app, is strictly prohibited. Our app monitors and records all screenshots and recordings. Violators will face strict legal action.

DISCLAIMER

INTERNAL BLEACHING

Source- Articles on tooth discoloration, walking bleach technique, Text book of endodontic principle and practice 4th edition, Odell

- For patient showing chronological pattern of the defect inquiry should be made on history for possible cause which can be:
 - Pre-term birth
 - Rhesus incompatibility
 - Incubation as neonate
 - Maternal Vit D deficiency
 - Severe systemic disturbance from meningitis, encephalitis, severe measles or pneumonia during first 2 years of life
 - Minor fever or infections such as ear infections can also result in such defects.
- These enamel defects are seen on the surfaces based on which surface mineralization of the permanent dentition was taking place when the infection occurred below image can be used as guideline.

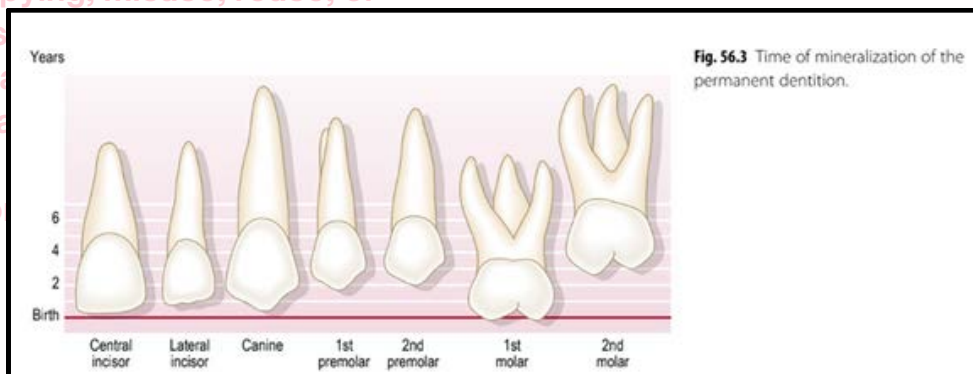


Fig: (Source- Odell case 56)

- Based on the severity of the defect these teeth can be air abraded or bleached.
- d) Blood Dyscrasias and other factors:**
- Various systemic conditions can cause severe lysis of erythrocytes which can result in severe discoloration.
 - Erythroblastosis fetalis caused by Rh incompatibility results staining of the forming dentin leading to severe discoloration.

B) Latrogenic or Inflicted Discolorations

- Discoloration can occur from various materials and chemicals and this type of discoloration is usually avoidable and difficult to correct by bleaching alone.

1) Pulp Necrosis

DISCLAIMER

THIS IS COPYRIGHTED CONTENT. Unauthorized use, including screenshots, copying, misuse, reuse, or resale of any content from this app, is strictly prohibited. Our app monitors and records all screenshots and recordings. Violators will face strict legal action.

DISCLAIMER

THIS IS COPYRIGHTED CONTENT. Unauthorized use, including screenshots, copying, misuse, reuse, or resale of any content from this app, is strictly prohibited. Our app monitors and records all screenshots and recordings. Violators will face strict legal action.

THIS IS COPYRIGHTED CONTENT. Unauthorized use, including screenshots, copying, misuse, reuse, or resale of any content from this app, is strictly prohibited. Our app monitors and records all screenshots and recordings. Violators will face strict legal action.

DISCLAIMER

INTERNAL BLEACHING

Source- Articles on tooth discoloration, walking bleach technique, Text book of endodontic principle and practice 4th edition, Odell

B) Latrogenic or Inflicted Discolorations

- Discoloration can occur from various materials and chemicals and this type of discoloration is usually avoidable and difficult to correct by bleaching alone.

1) Pulp Necrosis

- Most common and severe cause of single tooth discolorations are obturating materials.
- Incomplete removal of materials from the pulp chamber on completion of treatment results in dark discoloration.
- Primary offenders are sealer remnants in the tooth.
- Various types of sealers are available for dental use, and all of them often cause discoloration.

ROOT CANAL SEALERS	BRAND NAME
1. Zinc Oxide Eugenol based sealers	Roth sealer Kerr PCS Procosseal Endomethasone
2. Epoxy resin based sealers	AH Plus AH 26 Top Seal 2- Seal
3. Silicon based sealers	RoekoSeal Gutta flow
4. MTA based sealers	Endo-CPM-Sealer MTA Obtura ProRoot Endo Sealer MTA fillapex
5. Calcium-silicate-Phosphate based bio-ceramic sealers	Endosequence/Root SP iRoot BP Bioaggregate
6. Methacrylate resin based sealer	First generation- Hydron Second generation- EndoREZ, Realseal Third generation- Epiphany, FibreFill Fourth generation- Realiseal SE, Metaseal SE, Smartseal
7. Calcium-phosphate based sealers	Capseal I Capseal II

Image- Source-Article on Endodontic Sealers": Current Concepts and Comparative analysis: Internet

- Based on the research carried out on tooth discoloration by Australian endodontic Society, the conclusion was made that amongst the epoxy resin sealer AH 26 darkens more than any other epoxy resin sealers mostly due to presence of silver content. Nowadays a silver free version of AH26 is also available. (Source- Article)
- A literature review (on tooth discoloration from endodontic materials) reviews a study done to assess the degree of discoloration induced by different sealers which concluded that after 3,6 and 9 months the severity of tooth discoloration from highest to lowest was Endofill > ZOE > Tubuliseal > AH 26 > GP > Apatite root sealer III > Cavizol > Distilled water.
- Elkhazin investigated the discoloration effects of AH plus, Endo Rez, Selapex and Kerr Pulp sealer on a root canal treated tooth with GP and one of the sealers. All four showed discoloration that increased with time.
- Hence it can be concluded that all the obturating materials cause some amount of discoloration if not placed properly.
- Removing all obturation materials to a level just cervical to the gingival margin can prevent such discoloration.
- Internal bleaching can be done and the prognosis depends on the constituents of the sealers as sealers with metallic components do not bleach well and regress with time.

DISCLAIMER

THIS IS COPYRIGHTED CONTENT. Unauthorized use, including screenshots, copying, misuse, reuse, or resale of any content from this app, is strictly prohibited. Our app monitors and records all screenshots and recordings. Violators will face strict legal action.

DISCLAIMER

THIS IS COPYRIGHTED CONTENT. Unauthorized use, including screenshots, copying, misuse, reuse, or resale of any content from this app, is strictly prohibited. Our app monitors and records all screenshots and recordings. Violators will face strict legal action.

DISCLAIMER

THIS IS COPYRIGHTED CONTENT. Unauthorized use, including screenshots, copying, misuse, reuse, or resale of any content from this app, is strictly prohibited. Our app monitors and records all screenshots and recordings. Violators will face strict legal action.

INTERNAL BLEACHING

Source- Articles on tooth discoloration, walking bleach technique, Text book of endodontic principle and practice 4th edition, Odell

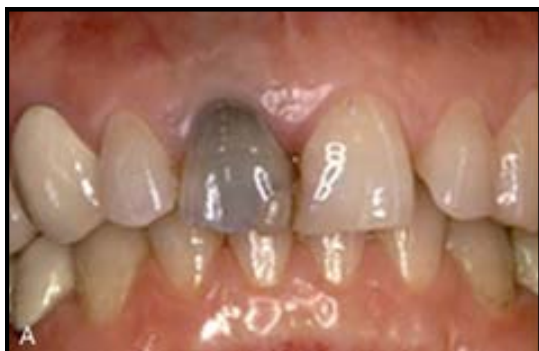

Image- Discoloration as a result of improper removal of obturating materials Source-Walton

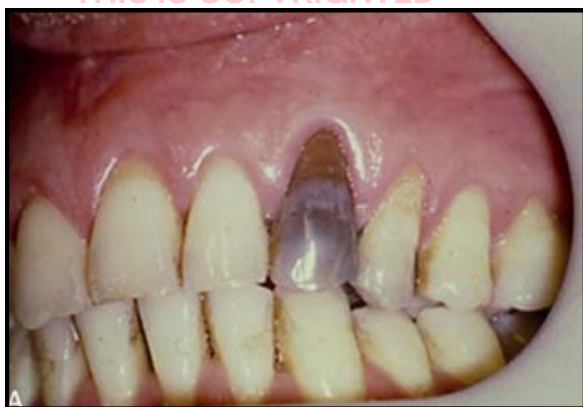
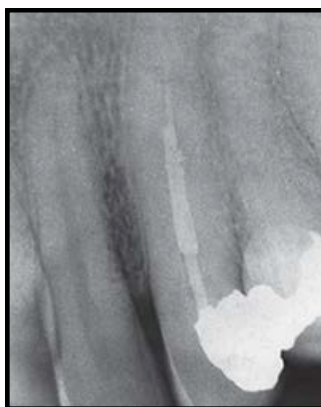
Image- Severe discoloration of canine due to poor root canal treatment where material extended into the pulp chamber causing discoloration. Source-Walton



2) Remnants of Pulpal Tissue

- Pulp remnants remaining in the crown usually in the pulp horns leads to gradual discoloration.
- Dissemination of blood components into the dentinal tubules caused by pulp extirpation or traumatically induced internal pulp bleeding can lead to discoloration.
- Usually, internal bleaching is successful in such cases.

3) Intracanal medicaments

- Several medicaments have potential to cause internal discoloration of the dentin.
- Intracanal medications are sealed in the root canal space in direct contact with dentin, sometimes for long periods, allowing for their penetration and oxidization which has tendency to discolor the dentin gradually.
- Phenolic and iodoform based medicaments results in discoloration and iodoform based discoloration are more severe.
- Ledermix which is used in endodontics because of its antimicrobial and anti-inflammatory effect also results in discoloration. Studies has shown that discoloration with ledermix is more severe when compared to other intracanal medicaments like calcium hydroxide, Clindamycin, CHX which can also cause discoloration. (Articles)

DISCLAIMER

THIS IS COPYRIGHTED CONTENT. Unauthorized use, including screenshots, copying, misuse, reuse, or resale of any content from this app, is strictly prohibited. Our app monitors and records all screenshots and recordings. Violators will face strict legal action.

THIS IS COPYRIGHTED CONTENT. Unauthorized use, including screenshots, copying, misuse, reuse, or resale of any content from this app, is strictly prohibited. Our app monitors and records all screenshots and recordings. Violators will face strict legal action.

DISCLAIMER
THIS IS COPYRIGHTED CONTENT. Unauthorized use, including screenshots, copying, misuse, reuse, or resale of any content from this app, is strictly prohibited. Our app monitors and records all screenshots and recordings. Violators will face strict legal action.

THIS IS COPYRIGHTED CONTENT. Unauthorized use, including screenshots, copying, misuse, reuse, or resale of any content from this app, is strictly prohibited. Our app monitors and records all screenshots and recordings. Violators will face strict legal action.

THIS IS COPYRIGHTED CONTENT. Unauthorized use, including screenshots, copying, misuse, reuse, or resale of any content from this app, is strictly prohibited. Our app monitors and records all screenshots and recordings. Violators will face strict legal action.

INTERNAL BLEACHING

Source- Articles on tooth discoloration, walking bleach technique, Text book of endodontic principle and practice 4th edition, Odell

- A non-staining alternative to ledermix is odontopaste used in Australia which replaces the tetracycline component that leads to discoloration to clindamycin. (Articles)
- It has been reported that antibiotic pastes as well as MTA based products can also lead to discoloration.
- Hence, it should be noted that all type of endodontic materials can lead to discoloration of varying degrees.
- These can be treated with internal bleaching procedure and corrected.

4) Coronal restorations

- Both metallic and composite restoration can discolor the tooth.
- Amalgam is the worst offender because its dark-colored elements may turn dentin dark gray. If used to restore an access preparation, amalgam often discolors the crown which are difficult to bleach and tends to reoccur with time.
- Microleakage of composites causes discoloration, open margins may permit chemicals to permeate between the restoration and tooth structure staining the underlying dentin.
- Composites may become discolored with time and alter the shade of the crown. These conditions can sometimes be corrected by replacing the old composite with a new well-sealed esthetic restoration or bleaching procedures as well.

Materials Used for bleaching:

- Commonly used materials are hydrogen peroxide, sodium perborate and carbamide peroxide. Sodium perborate and carbamide peroxide are chemical agents which are gradually degrade to release low levels of hydrogen peroxide.
 1. **Hydrogen Peroxide:** It is a powerful oxidizer and mostly used in the concentration of 30 to 35 % (Superoxyl, Perhydrol). Although it will bleach quickly, other chemicals which release lower concentrations are preferred.
 2. **Carbamide Peroxide:** It is also known as urea hydrogen peroxide and available in concentrations from 3% - 15%. The most commonly used concentration is 10 % carbamide peroxide which breaks down into urea, ammonia, carbon dioxide and approx. 3.5 % hydrogen peroxide. They are mostly used for external bleaching only.
 3. **Sodium Perborate:** It is the material of choice for internal bleaching. Sodium perborate is stable when dry, but in the presence of acid, warm air, or water, it decomposes to form sodium metaborate, hydrogen peroxide, and nascent oxygen. Various types of sodium perborate preparations are available: monohydrate, trihydrate, and tetrahydrate. They differ in oxygen content, which determines their bleaching efficacy. Commonly used sodium perborate preparations are alkaline and their pH depends on the amount of hydrogen peroxide released and the residual sodium metaborate.

DISCLAIMER

THIS IS COPYRIGHTED CONTENT. Unauthorized use, including screenshots, copying, misuse, reuse, or resale of any content from this app, is strictly prohibited. Our app monitors and records all screenshots and recordings. Violators will face strict legal action.

THIS IS COPYRIGHTED CONTENT. Unauthorized use, including screenshots, copying, misuse, reuse, or resale of any content from this app, is strictly prohibited. Our app monitors and records all screenshots and recordings. Violators will face strict legal action.

DISCLAIMER
THIS IS COPYRIGHTED CONTENT. Unauthorized use, including screenshots, copying, misuse, reuse, or resale of any content from this app, is strictly prohibited. Our app monitors and records all screenshots and recordings. Violators will face strict legal action.

INTERNAL BLEACHING

Source- Articles on tooth discoloration, walking bleach technique, Text book of endodontic principle and practice 4th edition, Odell

Bleaching Techniques (Source-Articles and Walton)

A) Internal Bleaching

- It is also known as non-vital bleaching and is done in conjunction with root canal treatment.
- The common method available for internal bleaching are **Thermocatalytic** technique and the **walking bleach** technique.
- Walking bleach is preferred.
 1. **Thermocatalytic technique:**
 - It involves placing the oxidizing agent in the pulp chamber and applying heat by heat lamps, flamed instruments or electrical heating device.
 - This procedure increases the risk of external cervical root resorption due to combination of bleaching material with heat and is not recommended for routine internal bleaching.
 2. **Walking Bleach technique:**
 - This is the recommended technique used in all situations requiring internal bleaching.
 - It is the safest technique and also requires the least chairside time.
 - Sodium perborate tetrahydrate mixed with distilled water in the ratio of 2:1 is suitable to use as a bleaching agent for walking bleach.
 - In case of severe discoloration only, 3% hydrogen peroxide(H₂O₂) can be applied instead of water.
 - The use of 30% H₂O₂ is not recommended as it also increases the risk of cervical resorptions.

Clinical performance, Application technique and steps for Walking bleach

1. Firstly, it is important to determine whether the discoloration is caused by internal staining, the surface of the tooth should be cleaned thoroughly to estimate the degree of external discoloration.
2. Prior to treatment a radiograph must be taken to check the quality of root filling, which should have adequate coronal apical seal and filling of the canal space, if inadequate root canal filling should be replaced and the filling material should be completely set before starting bleaching therapy.
3. Deficient restorations should be identified before bleaching therapy and should be replaced, and carious lesions restored. However, if permanent restoration is done prior to bleaching the color of tooth resulting from bleaching cannot be reliably predicted. Therefore, the most recommended method is to remove the existing restorations or caries prior to bleaching then place temporary restorations, perform bleaching and after around 2 weeks of shade stabilization place permanent restorations.

DISCLAIMER

THIS IS COPYRIGHTED CONTENT. Unauthorized use, including screenshots, copying, misuse, reuse, or resale of any content from this app, is strictly prohibited. Our app monitors and records all screenshots and recordings. Violators will face strict legal action.

DISCLAIMER

THIS IS COPYRIGHTED CONTENT. Unauthorized use, including screenshots, copying, misuse, reuse, or resale of any content from this app, is strictly prohibited. Our app monitors and records all screenshots and recordings. Violators will face strict legal action.

THIS IS COPYRIGHTED CONTENT. Unauthorized use, including screenshots, copying, misuse, reuse, or resale of any content from this app, is strictly prohibited. Our app monitors and records all screenshots and recordings. Violators will face strict legal action.

DISCLAIMER

INTERNAL BLEACHING

Source- Articles on tooth discoloration, walking bleach technique, Text book of endodontic principle and practice 4th edition, Odell

- Clinical performance, Application technique and steps for Walking bleach
- 4. Now, a rubber dam should be placed before preparation of the access cavity, then the access cavity should be shaped such that the remnants of restorative materials, root filling materials and necrotic pulp tissue are removed completely. Additional cleaning of the pulp cavity with 1-3% sodium hypochlorite to remove difficult, accessible remnants of pulp tissue is recommended.
- 5. Conditioning of the dentine of pulp chamber with 37% H₃PO₄ (Phosphoric acid) to remove the smear layer of pulp chamber dentine is not recommended as it may lead to increased diffusion of bleaching material into the periodontium.
- 6. To improve the cervical seal, the root filling should be reduced 1-2 mm below the Cemento-enamel junction (CEJ) which can be controlled by placing a periodontal probe into the pulp cavity, because the root filling does not prevent the diffusion of bleaching agent to apical foramen effectively. Hence, a 2mm layer of GIC or composite is essential where the sealing material should reach the level epithelial attachment or CEJ.
- 7. Before, application of bleaching agent the enamel margins of the cavity should be etched with 37% H₃PO₄ to enable an adhesive temporary filling after bleaching agent is applied.
- 8. Now the bleaching agent should be applied with a amalgam carrier or plugger and can be kept intracoronally for up to 28-30 days.
- 9. Successful bleaching is achieved after 1 to 4 visits. Patients should be instructed to evaluate the tooth color on a daily basis and return when the bleaching is acceptable.
- 10. As a temporary filling, a sound seal with composite or compomer is required for effective bleaching and to avoid microleakage of bleaching agent into the oral cavity.
- 11. It is often difficult to place a temporary filling material on a soft sodium perborate mixture or a cotton pellet. So, a cotton pellet covered with boding agent is placed on sodium perborate mixture and then light cured. The temporary filling is only attached to the enamel margins and during this phase there is increased risk of fracture that should be mentioned to the patient.
- 12. Following effective bleaching the access cavity should be restored permanently with a composite that is attached adhesively to enamel and dentine.
- 13. A radiograph of the bleached tooth should be taken after treatment to diagnose cervical resorption as early as possible, which should be done within the first year of bleaching.

DISCLAIMER

THIS IS COPYRIGHTED CONTENT. Unauthorized use, including screenshots, copying, misuse, reuse, or resale of any content from this app, is strictly prohibited. Our app monitors and records all screenshots and recordings. Violators will face strict legal action.

INTERNAL BLEACHING

Source- Articles on tooth discoloration, walking bleach technique, Text book of endodontic principle and practice 4th edition, Odell

Prognosis and color stability after internal bleaching:

- Complete color matching with the adjacent tooth is regarded as optimal result. However, darkening after internal bleaching can be observed occasionally.

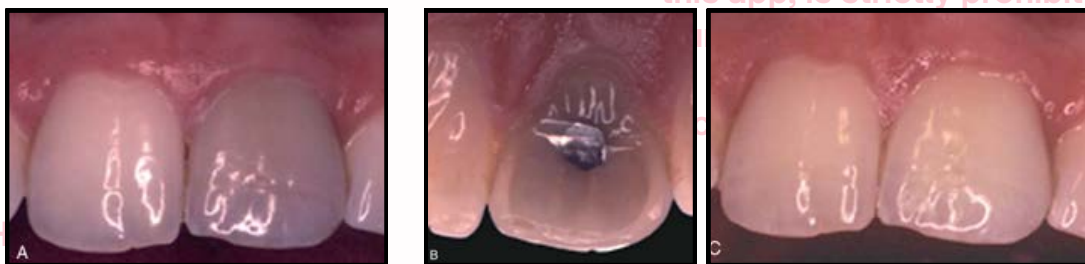

Image-A, Discoloration of endodontically treated incisor. B, Failure to remove all remnants of pulpal tissue from the chamber and amalgam placed in the access cavity appear to be the causes of discoloration, C, Removal of amalgam, intracoronary bleaching, and placement of a new composite restored esthetics. (Courtesy Dr. A. Claisse).(Source-Walton)

Prognosis and color stability after internal bleaching:

a) External Cervical resorption:

- Occurrence of external cervical resorption is a serious complication following internal bleaching.
- It is asymptomatic and only discovered in routine radiographs. However, sometimes swelling of the papilla and percussion sensitivity of the bleached teeth can be observed.
- Studies have shown that most common cause of external cervical resorption is orthodontic treatment followed by dental trauma, surgery and intracoronary bleaching.
- The oxidizing agent particularly 30% Hydrogen peroxide is thought to be the main culprit and incidence is increased more when the chemicals are combined with heat.

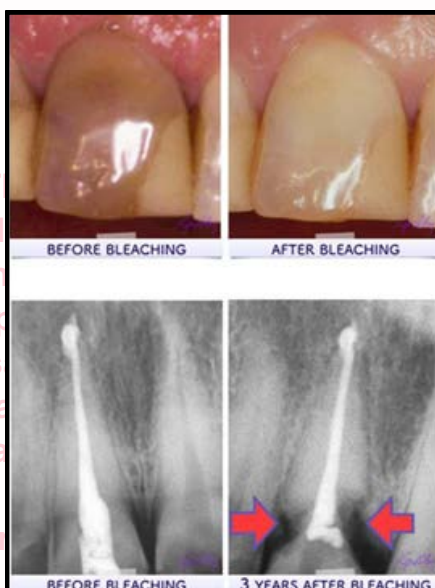

Image- Source (Internet)

DISCLAIMER

THIS IS COPYRIGHTED CONTENT. Unauthorized use, including screenshots, copying, misuse, reuse, or resale of any content from this app, is strictly prohibited. Our app monitors and records all screenshots and recordings. Violators will face strict legal action.

DISCLAIMER

THIS IS COPYRIGHTED CONTENT. Unauthorized use, including screenshots, copying, misuse, reuse, or resale of any content from this app, is strictly prohibited. Our app monitors and records all screenshots and recordings. Violators will face strict legal action.

DISCLAIMER

THIS IS COPYRIGHTED CONTENT. Unauthorized use, including screenshots, copying, misuse, reuse, or resale of any content from this app, is strictly prohibited. Our app monitors and records all screenshots and recordings. Violators will face strict legal action.

INTERNAL BLEACHING

Source- Articles on tooth discoloration, walking bleach technique, Text book of endodontic principle and practice 4th edition, Odell

b) Coronal fracture:

- Increased brittleness of the tooth structure especially when heat is applied is also thought to occur due to bleaching.

c) Chemical burns:

- Sodium perborate is safe however 30% hydrogen peroxide if used is caustic and can cause chemical burns.

B) External Bleaching

- It is also known as vital bleaching.
- The use of 10 % carbamide peroxide gels placed in a night guard is the recommended concentration for external bleaching technique.

Note on policy specified by on bleaching procedures:

- Hydrogen peroxide is an active bleaching agent used to bleach teeth. The effective concentration for hydrogen peroxide ranges from 3- 6% (for home use) to 35 % (for some in-office use).
- Work Safe Australia's guidelines state that hydrogen peroxide concentration above 5 % as hazardous substance increasing variety of teeth whitening products are available for direct sale to Australian consumer as over the counter (OTC) product.
- Only dental practitioners who have been trained, educated and attained competence on teeth whitening can assess whether it is safe for an individual to undergo tooth whitening.
- Only dentists can supply patients with bleaching products incorporating hydrogen peroxide exceeding 6 % or carbamide peroxide exceeding 18%.

2. Position

- 2.1. Only dental practitioners who have been educated, trained, and attained competence in teeth whitening can assess whether it is safe for individual patients to undergo teeth whitening, and to diagnose and treat any dental or oral health problems that need to be addressed first to minimise any potential discomfort or health risks associated with exposure to bleaching agents.
- 2.2. Only dentists should be able to supply patients with teeth whitening (bleaching) products incorporating hydrogen peroxide at concentrations exceeding 6% or carbamide peroxide exceeding 18%.
- 2.3. Teeth whitening should only be performed if the treatment can be justified, and after a comprehensive dental examination has been conducted by a dentist.
- 2.4. Risks and costs associated with the treatment should be explained to the patient and documented along with informed consent. Practitioners should ensure that patients have realistic and reasonable expectations regarding the results of the bleaching treatment.
- 2.5. Regulatory authorities must take appropriate action to educate the public about the risks of tooth whitening procedures undertaken by persons other than dental practitioners and encourage them to report any concerns they have about teeth whitening products or services to the appropriate authorities.
- 2.6. The Australian Competition and Consumer Commission (ACCC) should continually monitor the advertising and supply of teeth whitening products and services to assess and enforce compliance with relevant legislation, including state and territory poisons laws, mandatory labelling standards for cosmetics, and provisions of the *Competition and Consumer Act 2010* relating to product safety, product liability, product advertising, and mandatory reporting of adverse events causing consumer harm.

Image- Ada policy position on tooth whitening

DISCLAIMER

THIS IS COPYRIGHTED CONTENT. Unauthorized use, including screenshots, copying, misuse, reuse, or resale of any content from this app, is strictly prohibited. Our app monitors and records all screenshots and recordings. Violators will face strict legal action.

DISCLAIMER

THIS IS COPYRIGHTED CONTENT. Unauthorized use, including screenshots, copying, misuse, reuse, or resale of any content from this app, is strictly prohibited. Our app monitors and records all screenshots and recordings. Violators will face strict legal action.

DISCLAIMER

THIS IS COPYRIGHTED CONTENT. Unauthorized use, including screenshots, copying, misuse, reuse, or resale of any content from this app, is strictly prohibited. Our app monitors and records all screenshots and recordings. Violators will face strict legal action.

SURGICAL ENDODONTICS

Source- Articles and Walton

- Non-surgical root canal therapy is highly successful procedure for most endodontic cases if diagnosis and treatment is done accurately. Success rates of orthograde endodontic treatment (RCT) ranges from 47-97%.
- If a root canal treatment fails it can either be treated by non-Surgical endodontic retreatment or endodontic surgery. Failures are more likely to be associated with pre-operative presence of periapical radiolucency, root filling with voids, root filling more than 2mm short of the radiographic apex, unsatisfactory coronal restoration.
- Non-surgical endodontic retreatment provides a better opportunity to clean the pulp space than surgical approach. But there are situations where retreatment is inappropriate.
- The evidence shows that although endodontic surgery may show favorable outcome in the short term, long term more favorable outcome is achieved by retreatment.
- Endodontic surgery is actually endodontic treatment through a surgical flap.
- The purposes of endodontic surgery include sealing of all portals of exits to the root canal system and the isthmuses, eliminating bacteria and their byproducts from contaminating the periradicular tissues, and providing an environment that allows for regeneration of peri radicular tissues.

Periapical Surgery

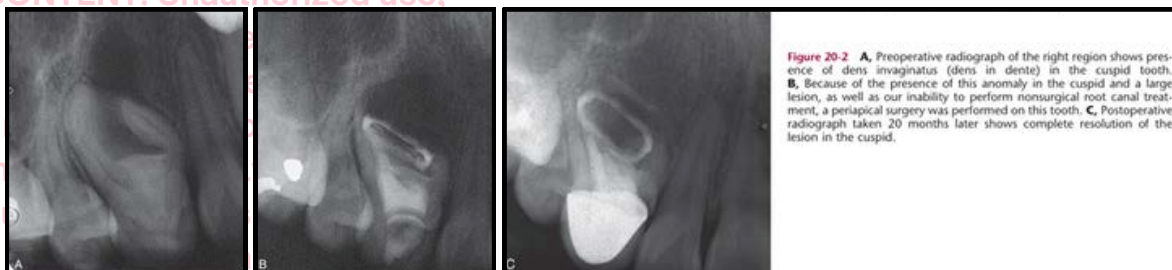
- Periapical surgery (PAS) is commonly performed to remove a portion of the root with undebrided canal space or to seal the canal apically when a complete seal cannot be accomplished with nonsurgical root canal treatment through the crown approach.

Indications:

- The main indications for PAS are anatomic problems, procedural accidents, irretrievable materials in the root canal, symptomatic cases, and horizontal apical fracture, as well as biopsy and corrective surgery.

A) Anatomical problems

- A nonnegotiable, blocked canal, or severe root curvature may prevent adequate cleaning and shaping or obturation. Nonsurgical, as well as surgical, endodontic treatments are indicated in these cases. Non-surgical root canal therapy or retreatment (if possible) before surgery improves the surgical success rate.



recordings. Violators will face strict legal action.

DISCLAIMER

THIS IS COPYRIGHTED CONTENT. Unauthorized use, including screenshots, copying, misuse, reuse, or resale of any content from this app, is strictly prohibited. Our app monitors and records all screenshots and recordings. Violators will face strict legal action.

DISCLAIMER

THIS IS COPYRIGHTED CONTENT. Unauthorized use, including screenshots, copying, misuse, reuse, or resale of any content from this app, is strictly prohibited. Our app monitors and records all screenshots and recordings. Violators will face strict legal action.

DISCLAIMER

THIS IS COPYRIGHTED CONTENT. Unauthorized use, including screenshots, copying, misuse, reuse, or resale of any content from this app, is strictly prohibited. Our app monitors and records all screenshots and recordings. Violators will face strict legal action.

SURGICAL ENDODONTICS

Source- Articles and Walton

B) Procedural Accidents

- Separated instruments, ledging, perforations, and gross overfills may cause failure of root canal treatment, which will require surgical intervention. If symptoms or lesions develop or persist after the accidents, PAS is usually necessary.

C) Irretrievable materials in the root canal

- Irretrievable posts or dowels or root filling materials, such as silver cones, amalgam, or non-absorbable pastes, often prevent retreatment or their removal would result in further damage to the root structure. The best alternative is a surgical approach and placement of a root-end filling material.

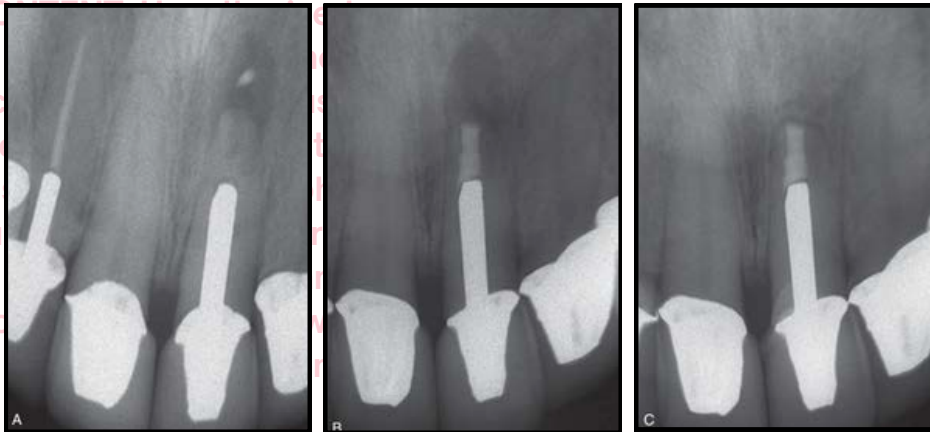


Image- A, Failed root canal treatment in the left maxillary lateral incisor requires periapical surgery. B, the root end is resected; a cavity is prepared and filled with MTA. C, Postoperative film after 1 year showing complete healing (Source-Walton)

D) Symptomatic cases

- Most symptoms disappear after complete cleaning and obturation of root canals. However, in cases where symptoms persist after meticulous performance of these procedures, PAS should be considered to identify the cause or causes for the persistence of the symptoms.

E) Horizontal Apical Fracture

- Although most traumatic horizontal apical fractures usually heal without intervention, occasionally the apical portion of a root becomes necrotic and cannot be treated nonsurgically. In these cases, the apical portion of the root should be removed and the apical seal should be evaluated.

E) Biopsy

- Although most periapical lesions are of pulpal origin, nonpulpal lesions do exist. Presence of a vital pulp in a tooth with a radicular radiolucency, undefined periapical lesions in teeth with vital pulps in patients with a history of previous malignancy, or lip paresthesia or anesthesia are indications for biopsy.

DISCLAIMER

THIS IS COPYRIGHTED CONTENT. Unauthorized use, including screenshots, copying, misuse, reuse, or resale of any content from this app, is strictly prohibited. Our app monitors and records all screenshots and recordings. Violators will face strict legal action.

DISCLAIMER

THIS IS COPYRIGHTED CONTENT. Unauthorized use, including screenshots, copying, misuse, reuse, or resale of any content from this app, is strictly prohibited. Our app monitors and records all screenshots and recordings. Violators will face strict legal action.

THIS IS COPYRIGHTED CONTENT. Unauthorized use, including screenshots, copying, misuse, reuse, or resale of any content from this app, is strictly prohibited. Our app monitors and records all screenshots and recordings. Violators will face strict legal action.

DISCLAIMER

SURGICAL ENDODONTICS

Source- Articles and Walton

Indications for surgical endodontics¹⁶

1. Periradicular disease associated with a tooth where iatrogenic or developmental anomalies prevent non-surgical root canal treatment being undertaken.
2. Periradicular disease in a root-filled tooth where non-surgical root canal retreatment cannot be undertaken or has failed, or when it may be detrimental to the retention of the tooth (eg obliterated root canals, teeth with full coverage restorations where conventional access may jeopardise the underlying core, the presence of a post whose removal may carry a high risk of root fracture).
3. Where a biopsy of periradicular tissue is required.
4. Where visualisation of the periradicular tissues and tooth root is required when perforation or root fracture is suspected.
5. Where it may not be expedient to undertake prolonged nonsurgical root canal retreatment because of patient considerations.

Image- Source article

Contraindications

- The four major contraindications for PAS are (1) anatomic factors, (2) medical or systemic complications, (3) indiscriminate use of surgery, and (4) an unidentified cause of treatment failure

1) Anatomic factors

- Inaccessibility to surgical site because of tooth location, spaces such as maxillary sinus or nasal fossa, unusual bony configuration, or proximity of neurovascular bundles may be contraindications or at least require caution or special approaches.
- For example, a thick external oblique ridge associated with a mandibular molar or apices contiguous with the mandibular canal may compromise surgical access.

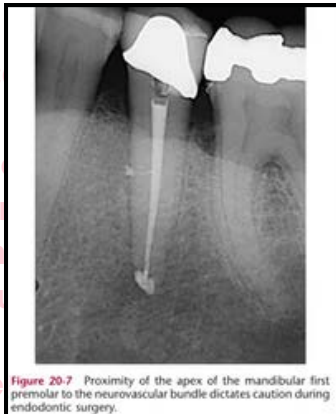

Figure 20-7 Proximity of the apex of the mandibular first premolar to the neurovascular bundle dictates caution during endodontic surgery.

THIS IS COPYRIGHTED CONTENT. Unauthorized use, including screenshots, copying, misuse, reuse, or resale of any content from this app, is strictly prohibited. Our app monitors and records all screenshots and recordings. Violators will face strict legal action.

DISCLAIMER
THIS IS COPYRIGHTED CONTENT. Unauthorized use, including screenshots, copying, misuse, reuse, or resale of any content from this app, is strictly prohibited. Our app monitors and records all screenshots and recordings. Violators will face strict legal action.

DISCLAIMER

THIS IS COPYRIGHTED CONTENT. Unauthorized use, including screenshots, copying, misuse, reuse, or resale of any content from this app, is strictly prohibited. Our app monitors and records all screenshots and recordings. Violators will face strict legal action.

THIS IS COPYRIGHTED CONTENT. Unauthorized use, including screenshots, copying, misuse, reuse, or resale of any content from this app, is strictly prohibited. Our app monitors and records all screenshots and recordings. Violators will face strict legal action.

DISCLAIMER

SURGICAL ENDODONTICS

Source- Articles and Walton

2) Medical or Systemic Complications

- Serious systemic health problems or extreme apprehension make the patient a poor candidate for PAS. Surgery may also be contraindicated in patients with blood disorders, terminal disease, uncontrolled diabetes, severe heart disease and immune compromised patients.

3) Indiscriminate Use of Surgery

- Surgery is not indicated when a nonsurgical approach would probably result in success. The practice of managing all accessible periapical lesions or large periradicular lesions surgically is unethical and contraindicated.

4) Unidentified Cause of Treatment Failure

- Using surgery to correct a treatment failure for which the cause cannot be identified is unlikely to be successful.

Contraindications to surgical endodontics

There are few absolute contraindications to endodontic surgery, however the following should be considered:

1. Patient factors, including the presence of severe systemic disease and psychological considerations.
2. Dental factors including:
 - unusual bony or root configurations
 - lack of surgical access
 - possible involvement of neurovascular structures
 - where the tooth is subsequently unrestorable
 - where there is poor supporting tissue
 - poor general oral status.
3. The skill, training, facilities available, and experience of the operator, should also be considered.

Image- Source Article

Clinical Steps

1) Clinical and radiographic assessment:

- A through intraoral and extraoral assessment should be done.
- A long cone parallel periapical radiograph provides a good diagnostic yield, however additional angled periapical radiographs can provide further information on root morphology in multirooted tooth or information about potential perforations of posts if suspected)
- At least 3mm of tissue beyond the radiographic apex should be assessed.
- Careful examinations will lead to accurate diagnosis.

DISCLAIMER

THIS IS COPYRIGHTED CONTENT. Unauthorized use, including screenshots, copying, misuse, reuse, or resale of any content from this app, is strictly prohibited. Our app monitors and records all screenshots and recordings. Violators will face strict legal action.

THIS IS COPYRIGHTED CONTENT. Unauthorized use, including screenshots, copying, misuse, reuse, or resale of any content from this app, is strictly prohibited. Our app monitors and records all screenshots and recordings. Violators will face strict legal action.

DISCLAIMER

DISCLAIMER
THIS IS COPYRIGHTED CONTENT. Unauthorized use, including screenshots, copying, misuse, reuse, or resale of any content from this app, is strictly prohibited. Our app monitors and records all screenshots and recordings. Violators will face strict legal action.

SURGICAL ENDODONTICS

Source- Articles and Walton

Clinical Steps

2) Treatment planning

- After diagnosis and discussions on treatment options consent should be taken.
- Referral should be made to the dentist who is appropriate to handle such cases.

3) Clinical management

- The use of CHX mouth rinse to reduce plaque formation pre procedurally may be beneficial.
- Where possible, local anesthesia should be the method of choice for anesthesia. LA also leads to hemostasis at the surgical site which is beneficial.
- Use of magnification provides improved visualization and control of the surgical site.

4) Flap design

- Flap that allows adequate exposure to the surgical site of the surgery for the operator.
- The following general guidelines and principles should be used during flap design:

1. The flap should be designed for maximum access to the site of surgery.
2. Adequate blood supply to the reflected tissue is maintained with a wide flap base.
3. Incisions over bony defects or over the periradicular lesion should be avoided; these might cause post-surgical soft tissue fenestrations or nonunion of the incision.
4. The actual bony defect is larger than the size observed radiographically.
5. A minimal flap, which should include at least one tooth on either side of the intended tooth, should be used.
6. Acute angles in the flap must be avoided. Sharp corners are difficult to reposition and suture and may become ischemic and slough, resulting in delayed healing and possibly scar formation.
7. Incisions and reflections include periosteum as part of the flap. Any remaining pieces or tags of cellular nonreflected periosteum will hemorrhage, compromising visibility.
8. The interdental papilla must not be split (incised through) and should be either fully included or excluded from the flap.
9. Vertical incisions must be extended to allow the retractor to rest on bone and not crush portions of the flap.

Image- Walton

- The surgical flap design depends on number of factors which includes access to and size of periradicular lesion, periodontal status, state of coronal tooth structure, nature and extent of coronal restorations, aesthetics, adjacent anatomical structures.
- Relieving incision should be placed on sound bone.

DISCLAIMER

THIS IS COPYRIGHTED CONTENT. Unauthorized use, including screenshots, copying, misuse, reuse, or resale of any content from this app, is strictly prohibited. Our app monitors and records all screenshots and recordings. Violators will face strict legal action.

DISCLAIMER

THIS IS COPYRIGHTED CONTENT. Unauthorized use, including screenshots, copying, misuse, reuse, or resale of any content from this app, is strictly prohibited. Our app monitors and records all screenshots and recordings. Violators will face strict legal action.

DISCLAIMER

THIS IS COPYRIGHTED CONTENT. Unauthorized use, including screenshots, copying, misuse, reuse, or resale of any content from this app, is strictly prohibited. Our app monitors and records all screenshots and recordings. Violators will face strict legal action.

SURGICAL ENDODONTICS

Source- Articles and Walton

Clinical Steps

4) Flap design

a) Semilunar/submarginal curved flap design

- The submarginal curved flap is a slightly curved, half-moon-shaped, horizontal incision made in the attached gingiva with the convexity nearest the free gingival margin.
- Semilunar flap design is not used in periapical surgery due to lack of predictability in determining and size of lesion and increased scarring.

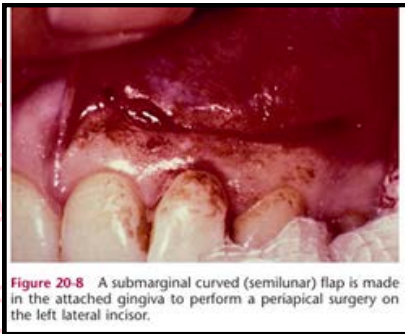

Figure 20-8 A submarginal curved (semilunar) flap is made in the attached gingiva to perform a periapical surgery on the left lateral incisor.

b) Sub marginal triangular and rectangular flap

- Triangular or rectangular flaps are known as modified submarginal curved flap. A scalloped horizontal incision (Ochsenbein-Luebke) is made in the attached gingiva with one or two accompanying vertical incisions.
- It is most successful with maxillary anterior teeth with crowns.
- However, this also does not provide visibility as good as full mucoperiosteal flap and also leads to scarring.

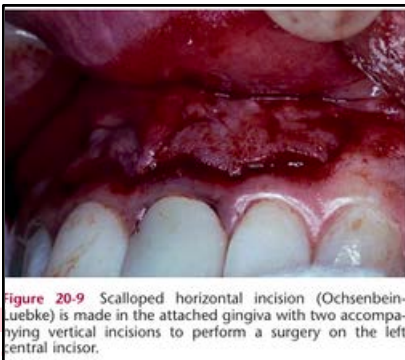


Figure 20-9 Scalloped horizontal incision (Ochsenbein-Luebke) is made in the attached gingiva with two accompanying vertical incisions to perform a surgery on the left central incisor.

c) Full mucoperiosteal flap:

- The full mucoperiosteal (sulcular) flap consists of an incision at the gingival crest with full elevation of the interdental papillae, free gingival margin, attached gingiva, and alveolar mucosa. It may have either a single (triangular) or double (rectangular) vertical-releasing incision. It allows maximal access and visibility, precludes incising over a bony defect, and has fewer tendencies toward hemorrhage.

DISCLAIMER

THIS IS COPYRIGHTED CONTENT. Unauthorized use, including screenshots, copying, misuse, reuse, or resale of any content from this app, is strictly prohibited. Our app monitors and records all screenshots and recordings. Violators will face strict legal action.

DISCLAIMER

THIS IS COPYRIGHTED CONTENT. Unauthorized use, including screenshots, copying, misuse, reuse, or resale of any content from this app, is strictly prohibited. Our app monitors and records all screenshots and recordings. Violators will face strict legal action.

THIS IS COPYRIGHTED CONTENT. Unauthorized use, including screenshots, copying, misuse, reuse, or resale of any content from this app, is strictly prohibited. Our app monitors and records all screenshots and recordings. Violators will face strict legal action.

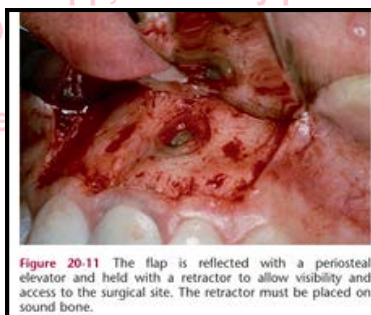
SURGICAL ENDODONTICS

Source- Articles and Walton

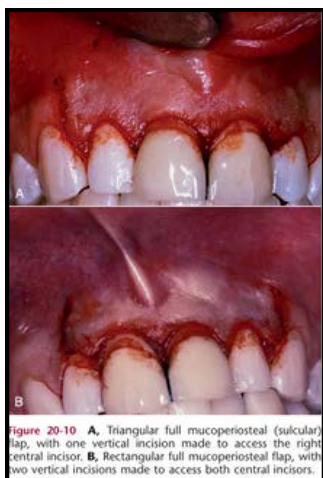

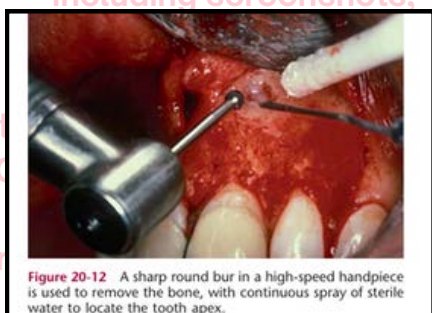
Image- Walton

- Once the horizontal incision and incisions. The tissue is reflected with a sharp periosteal elevator
- The tissue is reflected beyond the mucogingival junction to a level that will provide adequate access to the root apex, provide visibility of the surgical site, and allow a retractor to be placed on sound bone.



5) Osteotomy

- The assessment of the length and axis of the root should be made to ensure that bone is removed accurately at desired site.
- If the cortical plate is thin or absent curettes may be used to expose the roots.
- Bone removal should be carried out with a bur in a reverse air handpiece, cooled by copious sterile saline or sterile water.
- Steel or tungsten carbide burs are preferred to diamond burs as they generate less heat.
- Light shaving motion should be used to reduce the heat generated and for adequate visibility.
- Sufficient bone removal should be done that allows access to the root end.



THIS IS COPYRIGHTED CONTENT. Unauthorized use, including screenshots, copying, misuse, reuse, or resale of any content from this app, is strictly prohibited. Our app monitors and records all screenshots and recordings. Violators will face strict legal action.

DISCLAIMER
THIS IS COPYRIGHTED CONTENT. Unauthorized use, including screenshots, copying, misuse, reuse, or resale of any content from this app, is strictly prohibited. Our app monitors and records all screenshots and recordings. Violators will face strict legal action.

DISCLAIMER

THIS IS COPYRIGHTED CONTENT. Unauthorized use, including screenshots, copying, misuse, reuse, or resale of any content from this app, is strictly prohibited. Our app monitors and records all screenshots and recordings. Violators will face strict legal action.

DISCLAIMER

THIS IS COPYRIGHTED CONTENT. Unauthorized use, including screenshots, copying, misuse, reuse, or resale of any content from this app, is strictly prohibited. Our app monitors and records all screenshots and recordings. Violators will face strict legal action.

SURGICAL ENDODONTICS

Source- Articles and Walton

6) Periradicular curettage

- The soft tissue in the periradicular region should be removed with curettes for adequate visualization of root apex.
- The majority of inflammatory soft tissue should be removed but if violation of anatomical structures is likely soft tissue can be left as they are reparative in nature.
- Pathological tissue should be sent for histological evaluation if possible.

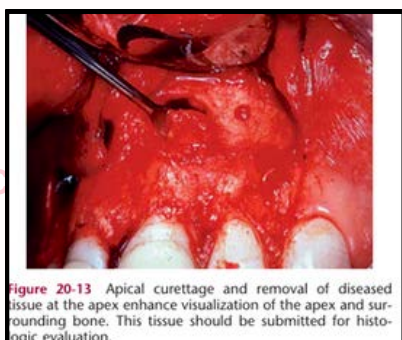


Figure 20-13 Apical curettage and removal of diseased tissue at the apex enhance visualization of the apex and surrounding bone. This tissue should be submitted for histologic evaluation.

7) Root end resection

- Resection of the root should be carried out as close as possible to 90 degrees with the long axis of the tooth. This reduces the number of exposed dentinal tubules and ensures access to all apical anatomy.
- If possible, at least 3 mm of root end should be resected with a rotating tapered fissured bur with copious irrigation.
- The resected root end should be examined under magnification, if possible, to ensure that the resection is complete.

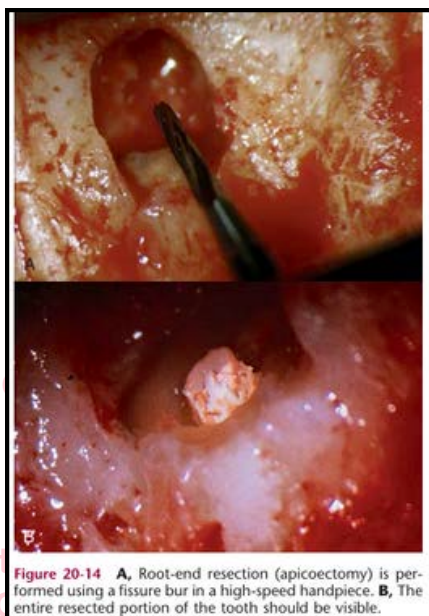


Figure 20-14 A, Root-end resection (apicoectomy) is performed using a fissured bur in a high-speed handpiece. B, The entire resected portion of the tooth should be visible.

THIS IS COPYRIGHTED CONTENT. Unauthorized use, including screenshots, copying, misuse, reuse, or resale of any content from this app, is strictly prohibited. Our app monitors and records all screenshots and recordings. Violators will face strict legal action.

DISCLAIMER
THIS IS COPYRIGHTED CONTENT. Unauthorized use, including screenshots, copying, misuse, reuse, or resale of any content from this app, is strictly prohibited. Our app monitors and records all screenshots and recordings. Violators will face strict legal action.

DISCLAIMER

THIS IS COPYRIGHTED CONTENT. Unauthorized use, including screenshots, copying, misuse, reuse, or resale of any content from this app, is strictly prohibited. Our app monitors and records all screenshots and recordings. Violators will face strict legal action.

DISCLAIMER

THIS IS COPYRIGHTED CONTENT. Unauthorized use, including screenshots, copying, misuse, reuse, or resale of any content from this app, is strictly prohibited. Our app monitors and records all screenshots and recordings. Violators will face strict legal action.

SURGICAL ENDODONTICS

Source- Articles and Walton

8) Root end cavity preparation:

- The preparation should be 3 mm deep, in the long axis of the tooth.
- The root end preparations is best carried out with ultrasonically powered tip at low power with a light touch.
- Consideration should be given to remove the smear layer with EDTA or citric acid, esp. if bur is used.

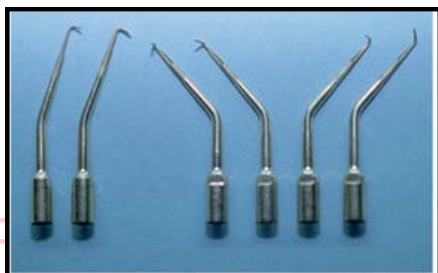


Figure 20-15 A variety of ultrasonic tips are available to prepare root-end cavities for various roots.



Figure 20-17 A, Root-end cavity prepared by a small inverted bur. B, Root-end cavity prepared by an ultrasonic bur.

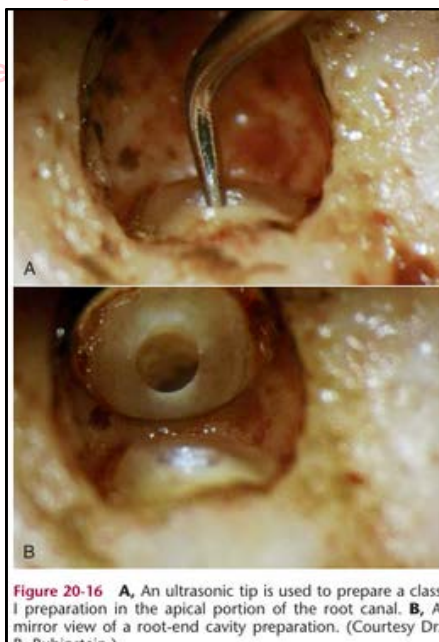


Figure 20-16 A, An ultrasonic tip is used to prepare a class I preparation in the apical portion of the root canal. B, A mirror view of a root-end cavity preparation. (Courtesy Dr. R. Rubinstein.)

9) Root end cavity filling

- The root end preparation should be isolated from fluids including blood.
- A suitable hemostatic agent should be placed in the bony crypt and root end cavity dried.
- The root end filling material should be compacted into the cavity with a small plugger to ensure dense fill. No excess material should be on the resected root face.
- A biologically compatible material should be used. MTA is osteo and cement inductive material and has high success rate.
- Composite resin, GIC, super EBA, reinforced ZoE can also be considered.

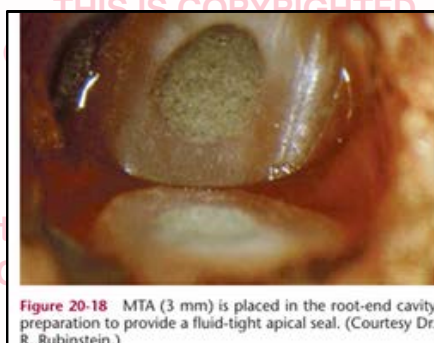

Figure 20-18 MTA (3 mm) is placed in the root-end cavity preparation to provide a fluid-tight apical seal. (Courtesy Dr. R. Rubinstein.)

DISCLAIMER

THIS IS COPYRIGHTED CONTENT. Unauthorized use, including screenshots, copying, misuse, reuse, or resale of any content from this app, is strictly prohibited. Our app monitors and records all screenshots and recordings. Violators will face strict legal action.

DISCLAIMER

THIS IS COPYRIGHTED CONTENT. Unauthorized use, including screenshots, copying, misuse, reuse, or resale of any content from this app, is strictly prohibited. Our app monitors and records all screenshots and recordings. Violators will face strict legal action.

DISCLAIMER

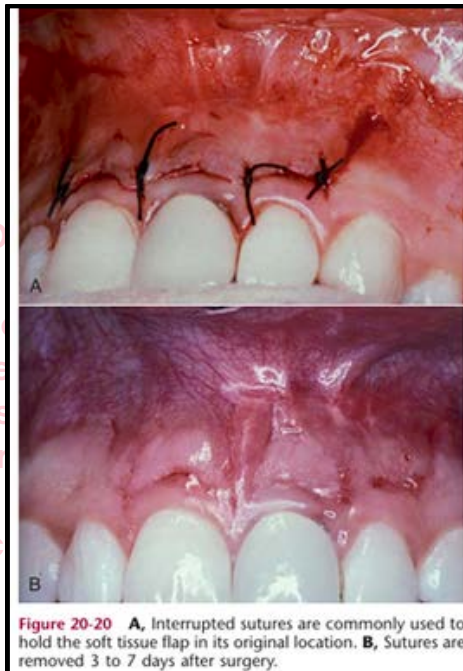THIS IS COPYRIGHTED CONTENT. Unauthorized use, including screenshots, copying, misuse, reuse, or resale of any content from this app, is strictly prohibited. Our app monitors and records all screenshots and recordings. Violators will face strict legal action.

SURGICAL ENDODONTICS

Source- Articles and Walton

10) Closure of the surgical site

- The soft tissue flap is re apposed with sutures; optimal healing is obtained from primary closure.
- After suturing the tissue is compressed for 3-5 mins with damp gauze.
- Synthetic mono filament sutures are preferred, and should be removed after 48-96 hours post operatively.



11) Post-Surgical considerations

- Post operative complications are uncommon. However post operative pain and swelling, hemorrhage, ecchymosis and infection can occur.
- Pain can be managed with analgesics; hemorrhage should be controlled intraoperatively.
- Post-op swelling can be reduced by application of ice pack for the first 4-6 hrs after surgery.
- Ecchymosis may occur which is self-limiting within 2 weeks after surgery.

THIS IS COPYRIGHTED CONTENT. Unauthorized use, including screenshots, copying, misuse, reuse, or resale of any content from this app, is strictly prohibited. Our app monitors and records all screenshots and recordings. Violators will face strict legal action.

DISCLAIMER

THIS IS COPYRIGHTED CONTENT. Unauthorized use, including screenshots, copying, misuse, reuse, or resale of any content from this app, is strictly prohibited. Our app monitors and records all screenshots and recordings. Violators will face strict legal action.

THIS IS COPYRIGHTED CONTENT. Unauthorized use, including screenshots, copying, misuse, reuse, or resale of any content from this app, is strictly prohibited. Our app monitors and records all screenshots and recordings. Violators will face strict legal action.

THIS IS COPYRIGHTED CONTENT. Unauthorized use, including screenshots, copying, misuse, reuse, or resale of any content from this app, is strictly prohibited. Our app monitors and records all screenshots and recordings. Violators will face strict legal action.

DISCLAIMER
THIS IS COPYRIGHTED CONTENT. Unauthorized use, including screenshots, copying, misuse, reuse, or resale of any content from this app, is strictly prohibited. Our app monitors and records all screenshots and recordings. Violators will face strict legal action.

DISCLAIMER

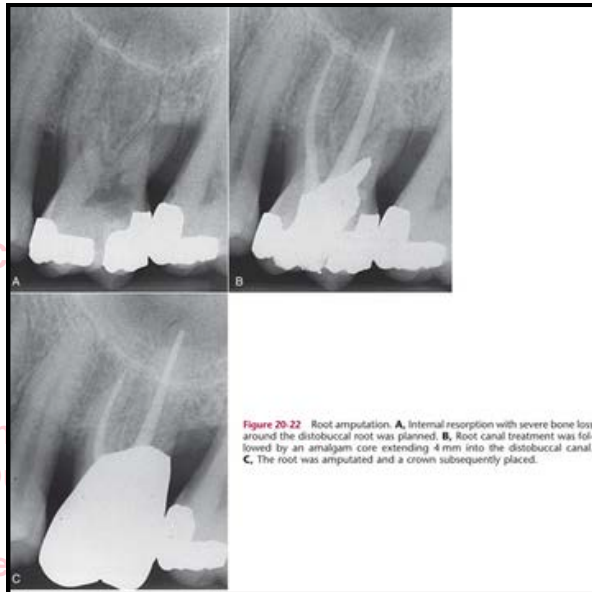
THIS IS COPYRIGHTED CONTENT. Unauthorized use, including screenshots, copying, misuse, reuse, or resale of any content from this app, is strictly prohibited. Our app monitors and records all screenshots and recordings. Violators will face strict legal action.

SURGICAL ENDODONTICS

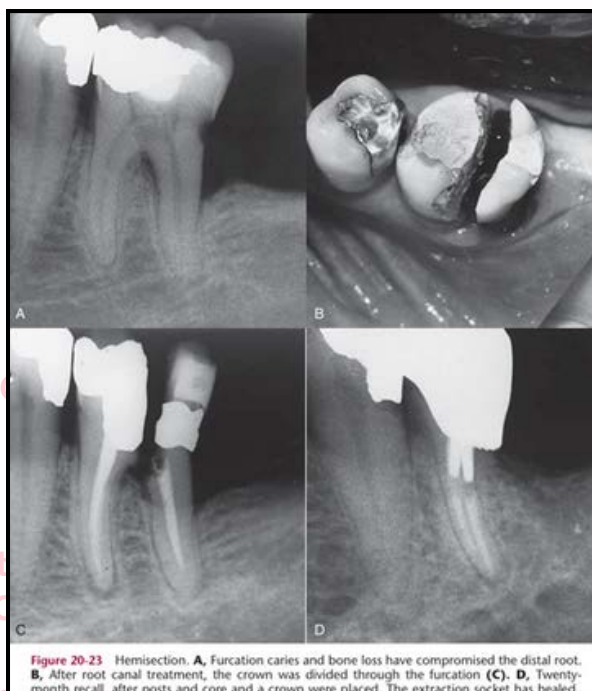
Source- Articles and Walton

Root amputation, Hemisection, Bicuspidization

- **Root amputation** is the removal of one or more roots of a multirooted tooth. The involved root, or roots, is separated at the junction of the root and the crown. In general, this procedure is performed in maxillary molars but can be performed for mandibular molars.



- **Hemisection** is the surgical division of a multirooted tooth. In mandibular molars the tooth is divided bucco-lingually through the bifurcation. In maxillary molars the cut is made mesiodistally, also through the furcation. The defective or periodontally involved root, or roots, and its coronal crown are then removed.



DISCLAIMER

THIS IS COPYRIGHTED CONTENT. Unauthorized use, including screenshots, copying, misuse, reuse, or resale of any content from this app, is strictly prohibited. Our app monitors and records all screenshots and recordings. Violators will face strict legal action.

DISCLAIMER

THIS IS COPYRIGHTED CONTENT. Unauthorized use, including screenshots, copying, misuse, reuse, or resale of any content from this app, is strictly prohibited. Our app monitors and records all screenshots and recordings. Violators will face strict legal action.

THIS IS COPYRIGHTED CONTENT. Unauthorized use, including screenshots, copying, misuse, reuse, or resale of any content from this app, is strictly prohibited. Our app monitors and records all screenshots and recordings. Violators will face strict legal action.

THIS IS COPYRIGHTED CONTENT. Unauthorized use, including screenshots, copying, misuse, reuse, or resale of any content from this app, is strictly prohibited. Our app monitors and records all screenshots and recordings. Violators will face strict legal action.

strict legal action.

DISCLAIMER

THIS IS COPYRIGHTED CONTENT. Unauthorized use, including screenshots, copying, misuse, reuse, or resale of any content from this app, is strictly prohibited. Our app monitors and records all screenshots and recordings. Violators will face strict legal action.

SURGICAL ENDODONTICS

Source- Articles and Walton

Root amputation, Hemisection, Bicuspidization

- Bicuspidization** is typically a surgical division of a mandibular molar. The crown and root of both halves are retained. If severe bone loss or destruction of tooth structure is confined primarily to the furcation area, hemisection and furcal curettage may allow retention of both halves. Each half may be restored to approximate a bicuspid; thus, the term bicuspidization is used for this procedure.

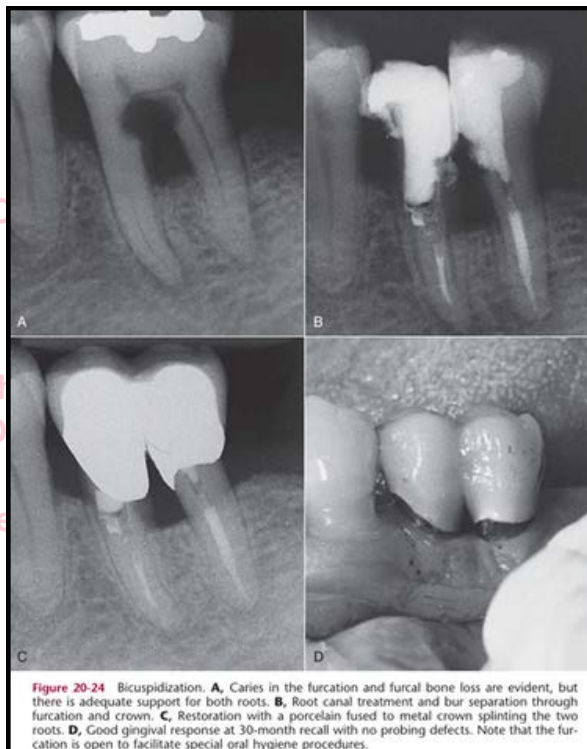


Image- Walton

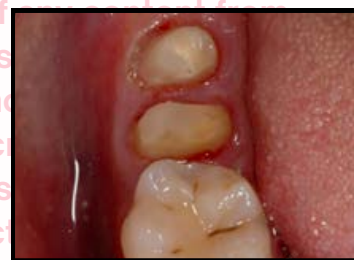
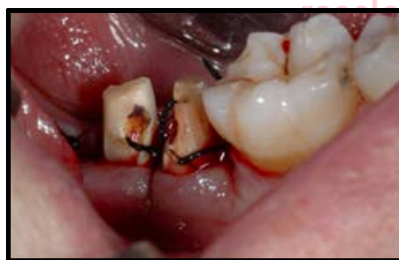
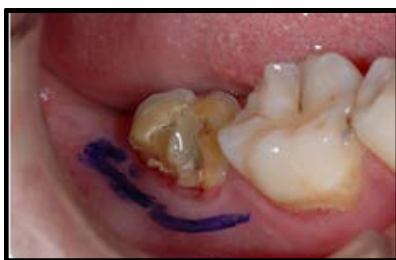Image- Bicuspidization procedure of mandibular molar (Source- Article)

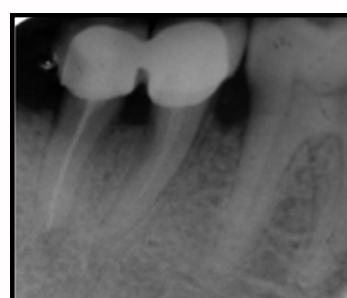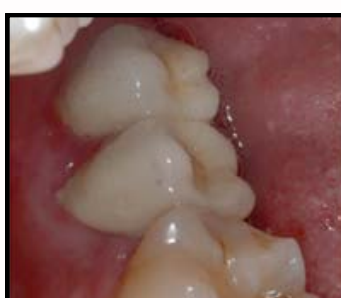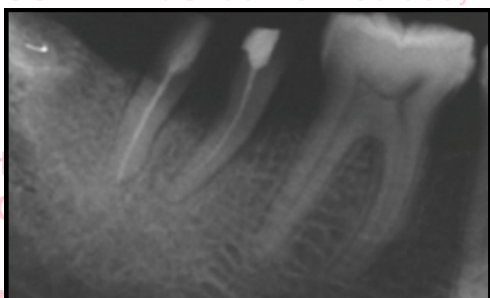


Image- Root canal and crowning of bicuspidized tooth (Source-Article)

DISCLAIMER

THIS IS COPYRIGHTED CONTENT. Unauthorized use, including screenshots, copying, misuse, reuse, or resale of any content from this app, is strictly prohibited. Our app monitors and records all screenshots and recordings. Violators will face strict legal action.

DISCLAIMER

THIS IS COPYRIGHTED CONTENT. Unauthorized use, including screenshots, copying, misuse, reuse, or resale of any content from this app, is strictly prohibited. Our app monitors and records all screenshots and recordings. Violators will face strict legal action.

THIS IS COPYRIGHTED CONTENT. Unauthorized use, including screenshots, copying, misuse, reuse, or resale of any content from this app, is strictly prohibited. Our app monitors and records all screenshots and recordings. Violators will face strict legal action.

THIS IS COPYRIGHTED CONTENT. Unauthorized use, including screenshots, copying, misuse, reuse, or resale of any content from this app, is strictly prohibited. Violators will face strict legal action.

THIS IS COPYRIGHTED CONTENT. Unauthorized use, including screenshots, copying, misuse, reuse, or resale of any content from this app, is strictly prohibited. Violators will face strict legal action.

SURGICAL ENDODONTICS

Source- Articles and Walton

Indications and contraindications for root amputation, bicuspidization and hemisection

Box 20-1
Indications and Contraindications for Root Amputation, Hemisection, and Bicuspidization
INDICATIONS FOR ROOT AMPUTATION OR HEMISECTION <ul style="list-style-type: none"> ■ Presence of severe bone loss in a nonsurgical treatable periodontally involved root or furcation ■ Untreatable roots with broken instruments, perforations, caries, resorption, and vertical root fracture or calcified canals ■ Preservation of strategically important root(s) and its accompanying crown
CONTRAINDICATIONS FOR ROOT AMPUTATION OR HEMISECTION <ul style="list-style-type: none"> ■ Insufficient bony support for the remaining root(s) ■ Root fusion or proximity so that root separation is not possible ■ Strong abutment teeth available (the involved tooth should be extracted and a prosthesis fabricated) ■ Inability to complete root canal treatment on the remaining root(s)
INDICATIONS FOR BICUSPIDIZATION <ul style="list-style-type: none"> ■ Furcation perforation ■ Furcation pathosis from periodontal disease ■ Buccolingual cervical caries or fracture into furcation
CONTRAINDICATIONS FOR BICUSPIDIZATION <ul style="list-style-type: none"> ■ Deep furcation (thick floor of pulp chamber) ■ Unrestorable half ■ Periodontal disease (each half must be periodontally sound) ■ Inability to complete root canal treatment on either half ■ Root fusion ■ Severe periodontal disease

Image- Source: Walton

THIS IS COPYRIGHTED CONTENT. Unauthorized use, including screenshots, copying, misuse, reuse, or resale of any content from this app, is strictly prohibited. Our app monitors and records all screenshots and recordings. Violators will face strict legal action.

THIS IS COPYRIGHTED CONTENT. Unauthorized use, including screenshots, copying, misuse, reuse, or resale of any content from this app, is strictly prohibited. Our app monitors and records all screenshots and recordings. Violators will face strict legal action.

THIS IS COPYRIGHTED CONTENT. Unauthorized use, including screenshots, copying, misuse, reuse, or resale of any content from this app, is strictly prohibited. Our app monitors and records all screenshots and recordings. Violators will face strict legal action.

DISCLAIMER

THIS IS COPYRIGHTED CONTENT. Unauthorized use, including screenshots, copying, misuse, reuse, or resale of any content from this app, is strictly prohibited. Our app monitors and records all screenshots and recordings. Violators will face strict legal action.

DISCLAIMER
THIS IS COPYRIGHTED CONTENT. Unauthorized use, including screenshots, copying, misuse, reuse, or resale of any content from this app, is strictly prohibited. Our app monitors and records all screenshots and recordings. Violators will face strict legal action.

DISCLAIMER

THIS IS COPYRIGHTED CONTENT. Unauthorized use, including screenshots, copying, misuse, reuse, or resale of any content from this app, is strictly prohibited. Our app monitors and records all screenshots and recordings. Violators will face strict legal action.