



UAF VOL 2

ULTIMATE ADVANCE FILE

P.O.W.E.R

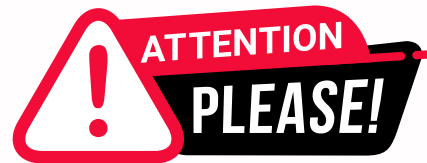PREPARATION OF ADC WITH WINSPERT EXPERT REVIEW

NOTES



OPERATIVE

By Dr. Jigyasa Sharma



Dear Students,

We'd like to remind you about the importance of respecting the integrity of the resources provided in our app.

Please be aware that **WINSPERT POWERNOTES ARE COPYRIGHTED CONTENT. Unauthorized use, including screenshots, copying, misuse, reuse, or resale of any content from this app, is strictly prohibited.**

Our app monitors and records all screenshots and recordings. Violators will face strict legal action.

We're committed to providing you with the best tools for your success, and we appreciate your cooperation in maintaining a fair and secure learning environment.

Thank you for your understanding and continued dedication.

Best regards,
WINSPERT TEAM



R.A.S.H TECHNIQUE

R- **RULE** OUT

A- DOES IT **ANSWER** OUR QUESTION

S- **SEQUENCE** WISE WHAT COMES 1ST

H- WHAT IS GIVEN IN THE **HISTORY**

SOLVE ADC QUESTIONS AT
lightning speed!

OPERATIVE

SBQ 1

PATIENT COMES FOR SOME COMPLAINT. SHE IS TAKING MEDICATION FOR RHEUMATOID ARTHRITIS, SHE'S FEELING DIFFICULT TO BRUSH TEETH, A MOTIVATED PATIENT, SHE ALSO SAYS HER EYES ARE ALSO DRY NOW.

I. You suspect it may be Sjogrens, what finding in the patient will trigger you for a referral of the patient to a medical practitioner for further assessment?

- A. Ph of saliva 5.5
- B. Stimulated salivary flow rate 0.4ml/min
- C. Parotid takes 30 seconds to produce saliva

II. As she is at high risk for caries, what advice will suggest to her?

- A. 5000 ppm dentifrice
- B. Acidulated fluoride phosphate gel/ 3 monthly in the office
- C. CPP-ACP

P.O.W.E.R NOTES SBQ 1

Patient is taking medication for rheumatic arthritis which is a systemic autoimmune disease. Patient might be having secondary Sjogren's syndrome as she gives a history of "DRY EYES".

- I. • Saliva ph. = 5.5 is quite acidic. This will trigger you for referring.
- 30 seconds is a good timing for the parotid gland to produce saliva.
- Stimulated salivary flow is the most important factor to get hyposalivation assessed.

Reference:

Table 3. Diagnostic tests for Sjögren's syndrome^{2,3,10,14,21,23}

| |
|--|
| Testing for ocular involvement |
| Schirmer's I test: quantitative measure of tear production over a specific period of time |
| Rose Bengal eye stain: reveals breaks in the corneal-epithelial surface to evaluate ocular surface irritation |
| Patient history of ocular symptoms |
| Testing for oral involvement |
| Salivary sialometry: low salivary flow is defined as less than 1.5 ml of saliva per 15 minutes |
| Labial minor salivary gland biopsy: showing lymphocytic sialoadenitis with a focus score of ≥ 1 per 4 mm ² of tissue |
| Examination for salivary gland enlargement: parotid and/or submandibular |
| Patient history of oral symptoms |
| Systemic tests |
| Presence of Ro/SSA and La/SSB autoantibodies in patients serum |
| Presence of rheumatoid factor in patients serum |

DISCLAIMER

THIS IS COPYRIGHTED CONTENT. Unauthorized use, including screenshots, copying, misuse, reuse, or resale of any content from this app, is strictly prohibited. Our app monitors and records all screenshots and recordings. Violators will face strict legal action.

DISCLAIMER

THIS IS COPYRIGHTED CONTENT. Unauthorized use, including screenshots, copying, misuse, reuse, or resale of any content from this app, is strictly prohibited. Our app monitors and records all screenshots and recordings. Violators will face strict legal action.

THIS IS COPYRIGHTED CONTENT. Unauthorized use, including screenshots, copying, misuse, reuse, or resale of any content from this app, is strictly prohibited. Our app monitors and records all screenshots and recordings. Violators will face strict legal action.

DISCLAIMER

OPERATIVE

P.O.W.E.R NOTES SBQ 1

- II. • CPP-ACP is good but using it alone is not the best.
• Patients with dry mouth we avoid the use of acidulated phosphate gel.
• Therefore, 5000ppm toothpaste is the best answer among the give.

Reference: **TG-TABLE 07**

THIS IS COPYRIGHTED CONTENT. Unauthorized use, including screenshots, copying, misuse, reuse, or resale of any content from this app, is strictly prohibited. Our app monitors and records all screenshots and recordings. Violators will face strict legal action.

THIS IS COPYRIGHTED CONTENT. Unauthorized use, including screenshots, copying, misuse, reuse, or resale of any content from this app, is strictly prohibited. Our app monitors and records all screenshots and recordings. Violators will face strict legal action.

THIS IS COPYRIGHTED CONTENT. Unauthorized use, including screenshots, copying, misuse, reuse, or resale of any content from this app, is strictly prohibited. Our app monitors and records all screenshots and recordings. Violators will face strict legal action.

THIS IS COPYRIGHTED CONTENT. Unauthorized use, including screenshots, copying, misuse, reuse, or resale of any content from this app, is strictly prohibited. Our app monitors and records all screenshots and recordings. Violators will face strict legal action.

THIS IS COPYRIGHTED CONTENT. Unauthorized use, including screenshots, copying, misuse, reuse, or resale of any content from this app, is strictly prohibited. Our app monitors and records all screenshots and recordings. Violators will face strict legal action.

DISCLAIMER

THIS IS COPYRIGHTED CONTENT. Unauthorized use, including screenshots, copying, misuse, reuse, or resale of any content from this app, is strictly prohibited. Our app monitors and records all screenshots and recordings. Violators will face strict legal action.

DISCLAIMER

THIS IS COPYRIGHTED CONTENT. Unauthorized use, including screenshots, copying, misuse, reuse, or resale of any content from this app, is strictly prohibited. Our app monitors and records all screenshots and recordings. Violators will face strict legal action.

DISCLAIMER

THIS IS COPYRIGHTED CONTENT. Unauthorized use, including screenshots, copying, misuse, reuse, or resale of any content from this app, is strictly prohibited. Our app monitors and records all screenshots and recordings. Violators will face strict legal action.

OPERATIVE

SBQ 2

PREGNANT LADY IN WEEK 6-7 OF HER PREGNANCY (FIRST TRIMESTER). THE PATIENT SAYS, BEFORE, I LIVED IN A MAJOR CITY AND HAVE NOW MOVED TO A RURAL AREA. SHE IS WORRIED ABOUT THE UPCOMING BABY'S ORAL HYGIENE.

I. Before the age of 18 months. What do you recommend?

- A. 1000 ppm fluoride
- B. Wipe teeth no toothpaste once daily
- C. 1500 fluoride
- D. Tablet fluoride

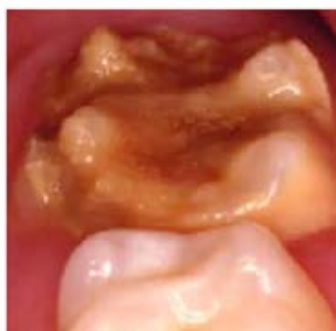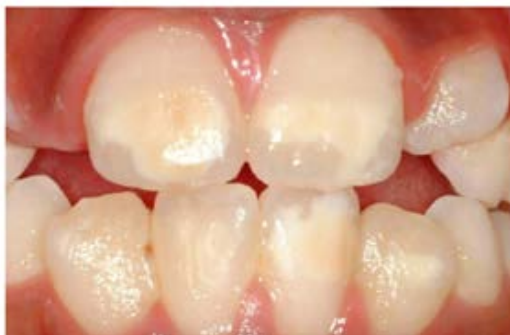II. Mother brings her child at the age of 18 months. What do you recommend?

- A. Brushing once daily
- B. 1000 ppm F toothpaste
- C. Fluoride gel foam in office 3 monthly
- D. Fluoride varnish

III. Pregnancy morning sickness. What's your advice?

- A. Rinse sodium bicarbonate mouthwash
- B. Brush immediately
- C. Stop taking acidic beverages
- D. Smear 5000 ppm toothpaste with your finger after vomiting. (Only in some centers)
- E. Use 220 ppm fluoride mouthwash immediately after vomiting (only in some centers)

IV. In the next appointment. She brought her 8 year old elder son who is having white spots on incisors and molars. What do you think is the reason for this?



- A. Calcium deficiency
- B. Malnutrition
- C. Multifactorial with genetic component
- D. Tetracycline prescribed for early childhood infection.

DISCLAIMER

THIS IS COPYRIGHTED CONTENT. Unauthorized use, including screenshots, copying, misuse, reuse, or resale of any content from this app, is strictly prohibited. Our app monitors and records all screenshots and recordings. Violators will face strict legal action.

DISCLAIMER

THIS IS COPYRIGHTED CONTENT. Unauthorized use, including screenshots, copying, misuse, reuse, or resale of any content from this app, is strictly prohibited. Our app monitors and records all screenshots and recordings. Violators will face strict legal action.

THIS IS COPYRIGHTED CONTENT. Unauthorized use, including screenshots, copying, misuse, reuse, or resale of any content from this app, is strictly prohibited. Our app monitors and records all screenshots and recordings. Violators will face strict legal action.

DISCLAIMER

OPERATIVE

SBQ 2

V. How will you manage the molars (in a few centres) (and incisors)?

- A. Fluoride varnish 3 monthly
- B. Reduce discolored tooth and restore
- C. Composite restoration
- D. Microabrasion
- E. Apply Cpp acp only.

P.O.W.E.R NOTES SBQ 2

I. Toothpaste is not recommended for infants below 18 months except for those who are at a higher risk. Among the given (B) is the best option.

Reference: **TG Page no. 67**

- II. • When there's no caries we will not immediately prescribe varnish fluoride gel. If the patient is at low risk of caries, we will not prescribe these.
- It's recommended to brush twice.
 - After 18 months we can prescribe fluoridated toothpaste.

Reference: **TG Page no. 67**

- III. • In pregnancy morning sickness patient vomits and has a risk of intrinsic erosion.
- The agents that we can use soon after vomiting to avoid erosion are:
 1. Sodium bicarbonate
 2. Fluoride
 3. Water
 - According to the sequence sodium bicarbonate comes 1st, 2nd best option is fluoride, 3rd best option is water. Fluoride is the most preventive re-mineralising agent.
 - It's not recommended to brush immediately when you have an acidic exposure in mouth as it can lead enamel wear off. Option (B) is ruled out.
 - It's a good advice to stop taking acidic beverages but it's not the best answer among the give as it is not addressing the aetiology. Option (C) is ruled out.
 - Applying a smear of toothpaste on the teeth is also a good option but it requires rinsing with water prior to application. So, option (D) is an incomplete option. But in pregnancy applying toothpaste can trigger nausea. Option (D) is ruled out.
 - So (A) becomes the best answer.

DISCLAIMER

THIS IS COPYRIGHTED CONTENT. Unauthorized use, including screenshots, copying, misuse, reuse, or resale of any content from this app, is strictly prohibited. Our app monitors and records all screenshots and recordings. Violators will face strict legal action.

DISCLAIMER

THIS IS COPYRIGHTED CONTENT. Unauthorized use, including screenshots, copying, misuse, reuse, or resale of any content from this app, is strictly prohibited. Our app monitors and records all screenshots and recordings. Violators will face strict legal action.

THIS IS COPYRIGHTED CONTENT. Unauthorized use, including screenshots, copying, misuse, reuse, or resale of any content from this app, is strictly prohibited. Our app monitors and records all screenshots and recordings. Violators will face strict legal action.

DISCLAIMER

OPERATIVE

P.O.W.E.R NOTES SBQ 2

III. Reference:

For patients with hyperemesis:

- Rinse mouth with tap water straight after vomiting or immediately rinse with a solution of bicarbonate of soda (1 teaspoon of baking soda in a glass of water).
- Wait at least 30 minutes after vomiting before brushing teeth with fluoridated toothpaste.
- Chew sugar free gum to stimulate saliva to clear and neutralise acids.

EROSION Article

Application of concentrated topical fluorides to teeth prior to an erosive challenge: the application of concentrated topical fluoride gels and varnishes before the erosive challenge is likely to take place was found experimentally to provide some inhibition of demineralisation of both roots and crowns

For exogenous erosion, the following useful alternatives should be suggested to the patient:

- drinking more water, particularly between meals;
- limiting the frequency of acidic foods and drinks by restricting to main meals; finish with a small piece of cheese or a drink of milk;
- consuming fruit juices, soft drinks and sports drinks through a straw;
- rinsing the mouth with water after any acidic challenge to teeth;
- substituting non acidic alternatives instead of acidic drinks eg. flavoured milk instead of all soft drinks and cordial;
- swallowing Vitamin C tablets or solutions rather than chewing.

THIS IS COPYRIGHTED CONTENT. Unauthorized use, including screenshots, copying, misuse, reuse, or any content from strictly prohibited. Our app monitors and records all screenshots and recordings. Violators will face strict legal action.

DISCLAIMER
THIS IS COPYRIGHTED CONTENT. Unauthorized use, including screenshots, copying, misuse, reuse, or resale of any content from this app, is strictly prohibited. Our app monitors and records all screenshots and recordings. Violators will face strict legal action.

CONTENT. Unauthorized use, including screenshots, copying, misuse, reuse, or resale of any content from this app, is strictly prohibited. Our app monitors and records all screenshots and recordings. Violators will face strict legal action.

DISCLAIMER

THIS IS COPYRIGHTED CONTENT. Unauthorized use, including screenshots, copying, misuse, reuse, or resale of any content from this app, is strictly prohibited. Our app monitors and records all screenshots and recordings. Violators will face strict legal action.

OPERATIVE

P.O.W.E.R NOTES SBQ 2

- IV. • According to the given picture, the diagnosis: molar incisor hypo-mineralisation in the anterior and molar incisor hypoplasia in the posterior.
- There are multiple reasons which could lead to MIH. MIH can be due to nutritional deficiencies and environmental factors. Genetics play a role in MIH as well. That is why Answer is Option (C)
 - Amelogenesis imperfecta is a genetic involvement. In AI both primary and the permanent teeth are affected. All the teeth are affected. Therefore, this cannot be the cause.
 - Calcium deficiency can be one of the reasons, but calcium deficiency alone cannot be a cause. In MIH both Ca and protein matrix formation are involved. There's a malformation in the protein matrix formation.
 - Childhood disease can lead to malnutrition and lead to reduced nutrition intake.
 - Tetracycline stains can give rise to brown stains in the teeth, but it will not be a reason for hypo-mineralised brown spots.

Reference:

The causative mechanism of MIH is still unclear,^{7,13} but the clinical presentation of localised and asymmetrical lesions suggests a systemic origin with the disruption in the amelogenesis process most probably occurring in the early maturation stage or even earlier at the late secretory phase.² In general, the condition seems to be multifactorial and systemic factors such as acute or chronic illnesses or exposure to environmental pollutants during the last gestational trimester and first three years of life have been suggested as causative or contributing factors.^{13,14} The number of affected teeth was associated with the time when the potential systemic disturbance occurred; children with prenatal, perinatal and postnatal problems showing more affected teeth in increasing order.¹⁴ Multiple possible causes have been suggested in the literature, for instance, respiratory tract infections, perinatal complications, dioxins, oxygen starvation, low birth weight, calcium and phosphate metabolic disorders, frequent childhood diseases, use of antibiotics and prolonged breast feeding.² In addition, some studies^{15,16} raise the possibility of a genetic role in the aetiology of MIH, indicating that a genetic variation may interact with systemic factors leading to MIH.

recordings. Violators will face strict legal action.

DISCLAIMER

THIS IS COPYRIGHTED CONTENT. Unauthorized use, including screenshots, copying, misuse, reuse, or resale of any content from this app, is strictly prohibited. Our app monitors and records all screenshots and recordings. Violators will face strict legal action.

DISCLAIMER

THIS IS COPYRIGHTED CONTENT. Unauthorized use, including screenshots, copying, misuse, reuse, or resale of any content from this app, is strictly prohibited. Our app monitors and records all screenshots and recordings. Violators will face strict legal action.

DISCLAIMER

THIS IS COPYRIGHTED CONTENT. Unauthorized use, including screenshots, copying, misuse, reuse, or resale of any content from this app, is strictly prohibited. Our app monitors and records all screenshots and recordings. Violators will face strict legal action.

OPERATIVE

P.O.W.E.R NOTES SBQ 2

- V. • Molars are best managed with the crowns.
 • 2nd best option is the composite restorations.
 • Micro-abrasion will be helpful in hypo-mineralised anterior teeth. Molars are hypoplastic and micro-abrasion will not be helpful.
 • CPP-ACP or fluoride alone will not be helpful in restoring the hypoplastic defects. They will be helpful to strengthen the tooth structure.
 • There are no underlying stains to reduce prior to restoration. So, options (B) is ruled out.

Reference: **ODELL**

| Technique | Advantages | Disadvantages |
|---------------------------------------|---|---|
| Full resin composite veneers | No destruction of tooth tissue, reversible and generally well tolerated even by anxious children. Excellent aesthetic result possible and easy to maintain. | Discolour with time. Tendency to fracture if placed at/over the incisal edge. |
| Enamel microabrasion | Minimal destruction of enamel, if carefully performed. Technique well tolerated. | Unpredictable. Teeth may rarely suffer postoperative sensitivity. Accidental exposure of dentine is possible where enamel is thin. |
| Localized resin composite restoration | Enamel destruction limited to defect, and full thickness need not be removed if opaque resin composite shades are used. Good aesthetic result possible. | Irreversible. Weakens tooth structure and large areas of dentine may be uncovered. Colour change and marginal discoloration with time. |
| Porcelain veneers | Good appearance. | Contraindicated in this age group because gingival contour not mature and stable tooth position not yet established. |
| Full-crown restoration | Good appearance. | Inappropriate until late second decade because immature pulp horns may be exposed. Gingival contour not mature and stable tooth position not yet established. |

Treatment

◆ What Treatment Options are Available for the Molars?

Extraction is considered an appropriate treatment for the permanent first molar with a poor long-term prognosis, particularly when, as here, caries is also present. Preservation of these molars through adulthood would require provision of full-coverage crowns. These have a finite lifespan, and their intermittent replacement; the risks of undetected leakage, caries and pulpal involvement; localized periodontitis; and the expense and inconvenience would all cause significant difficulties during the lifetime of the patient.

for full coronal coverage restorations later in life. A preventive resin restoration can be provided for the less severely affected molar in the lower right quadrant.

Molars in MIH are often considered highly sensitive to a variety of stimuli and are known to be difficult to anaesthetize locally.

DISCLAIMER

THIS IS COPYRIGHTED CONTENT. Unauthorized use, including screenshots, copying, misuse, reuse, or resale of any content from this app, is strictly prohibited. Our app monitors and records all screenshots and recordings. Violators will face strict legal action.

DISCLAIMER

THIS IS COPYRIGHTED CONTENT. Unauthorized use, including screenshots, copying, misuse, reuse, or resale of any content from this app, is strictly prohibited. Our app monitors and records all screenshots and recordings. Violators will face strict legal action.

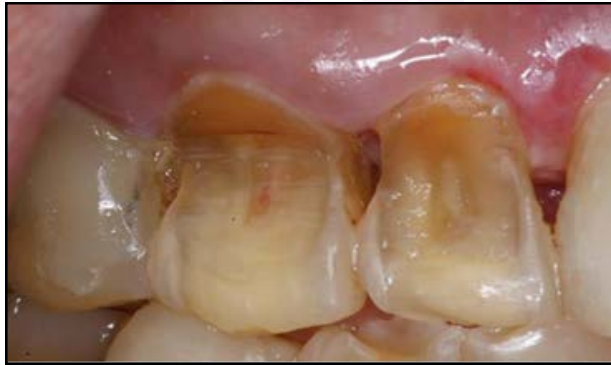THIS IS COPYRIGHTED CONTENT. Unauthorized use, including screenshots, copying, misuse, reuse, or resale of any content from this app, is strictly prohibited. Our app monitors and records all screenshots and recordings. Violators will face strict legal action.

DISCLAIMER

OPERATIVE

SBQ 3

SON BROUGHT HIS FATHER FOR CHECKUP WHO WAS 65 YEARS OLD. PATIENT HAD SENSITIVITY OVER THE LESIONS. (EXACTLY SAME PICTURE GIVEN)



I. What do these lesions look like?

- A. Abrasion
- B. Erosion
- C. Abfraction
- D. Caries

II. What is the pink spot?

- A. Vital pulp
- B. Staining
- C. Non vital pulp
- D. Dentinal sclerosis
- E. Caries

III. What will you ask the patient to diagnose definitively?

- A. Ask about sensitivity
- B. Ask about diet
- C. Ask about oral hygiene habits

IV. What advice do you give this patient?

- A. Eat veggies and fruit with meals
- B. Limit consumption of veggie
- C. Oral Hygiene instructions

V. Where is the highest caries site in elderly adults?

- A. Anterior proximal
- B. Posterior proximal
- C. Root dentine

THIS IS COPYRIGHTED CONTENT. Unauthorized use, including screenshots, copying, misuse, reuse, or resale of any content from this app, is strictly prohibited. Our app monitors and records all screenshots and recordings. Violators will face strict legal action.

DISCLAIMER
THIS IS COPYRIGHTED CONTENT. Unauthorized use, including screenshots, copying, misuse, reuse, or resale of any content from this app, is strictly prohibited. Our app monitors and records all screenshots and recordings. Violators will face strict legal action.

DISCLAIMER

THIS IS COPYRIGHTED CONTENT. Unauthorized use, including screenshots, copying, misuse, reuse, or resale of any content from this app, is strictly prohibited. Our app monitors and records all screenshots and recordings. Violators will face strict legal action.

OPERATIVE

SBQ 3

VI. Why would you restore these teeth other than protecting pulp?

- A. Prevent future pain
- B. Restore contour of the tooth
- C. To improve structural integrity of the tooth
- D. Restore esthetics

VII. Same patient asked for reduced dexterity. What will you advise?

- A. Powered tooth brushing
- B. Normal tooth brushing
- C. Water flossing

VIII. Caries in old age which are non symptomatic what would you use to arrest them (here patient also can't visit dentist for care, and he has less manual dexterity)

- A. SDF
- B. Cpp Acp and fluoride
- C. Fluoride varnish
- D. Fluoride gel
- E. Restoration with composite

IX. Another patient who has a habit of eating fruits throughout the day because her naturopath had advised her to take fruits throughout the day. What advice would you give her?

- A. Advice her to take it in the form of juice
- B. Ask her to reduce the frequency of fruit eating to once per day
- C. Ask her to eat along with meals
- D. Refer her to naturopath

P.O.W.E.R NOTES SBQ 3

- I.
 - Abfraction will not involve the entire labial surface of the tooth.
 - Abfraction and abrasions are only NCCL. So, options (A) and (C) are ruled out.
 - Erosive tooth wear is a combination of severe tooth erosion and other contributory factors of tooth brushing and abrasion.
- II. Vital pulp reflecting through the underlying dentin and can be seen as a pink spot.
- III. If the provisional diagnosis is erosion, then we need to ask questions based on erosion.

All the given options are correct. When all the options are correct apply RASH technique.

Option (B) is the best among all.

DISCLAIMER

THIS IS COPYRIGHTED CONTENT. Unauthorized use, including screenshots, copying, misuse, reuse, or resale of any content from this app, is strictly prohibited. Our app monitors and records all screenshots and recordings. Violators will face strict legal action.

THIS IS COPYRIGHTED CONTENT. Unauthorized use, including screenshots, copying, misuse, reuse, or resale of any content from this app, is strictly prohibited. Our app monitors and records all screenshots and recordings. Violators will face strict legal action.

DISCLAIMER
THIS IS COPYRIGHTED CONTENT. Unauthorized use, including screenshots, copying, misuse, reuse, or resale of any content from this app, is strictly prohibited. Our app monitors and records all screenshots and recordings. Violators will face strict legal action.

OPERATIVE

P.O.W.E.R NOTES SBQ 3

IV. Eat fruits and veggie with meal will reduce acidic consumption.

We cannot say the patient to limit consumption of veggie.

Reference:

Other categories of people at high risk of erosion are those that exercise extensively, distance swimmers using swimming pools, wine assessors, and citrus orchardists. There have been a number of reports of vegetarians with advanced erosion, resulting from excessive consumption of berries and fruits. Chronic asthma sufferers can experience advanced erosion caused by frequent use of certain asthma medication eg. puffers.

- V. • Proximal caries is prevalent in young adults/ teenagers.
• Proximal plaque is highly saturated with sucrose.
• Elderly patients suffer from hyposalivation, dry mouth and periodontal problems.
• These risk factors are involved with cervical and root caries.
- VI. • We can use desensitising agents to seal the dentinal tubules and to avoid sensitivity issues and pain in the future. So, option (A) is ruled out.
• Options (B), (C), (D) all are correct.
• But to avoid further break down and improve the structural integrity of the tooth, we need to restore the tooth. so, among the given (C) is the best.
- VII. In case of reduced dexterity normal tooth brush or water floss won't be helpful. Therefore, among the given option (A) is the best.
- VIII. • Non symptomatic caries in old age can be arrested with SDF, CPP-ACP and fluoride.
• But CPP-ACP and fluoride will not prevent further destruction. And they will require multiple compliance.
• Therefore, SDF is the best among the given. It also doesn't require multiple compliance. Suits best in geriatric patients as they can't come for multiple visits and it's an ART technique.
• Restoration is not required as these lesions are non- symptomatic.

Reference on next page

DISCLAIMER

THIS IS COPYRIGHTED CONTENT. Unauthorized use, including screenshots, copying, misuse, reuse, or resale of any content from this app, is strictly prohibited. Our app monitors and records all screenshots and recordings. Violators will face strict legal action.

DISCLAIMER
THIS IS COPYRIGHTED CONTENT. Unauthorized use, including screenshots, copying, misuse, reuse, or resale of any content from this app, is strictly prohibited. Our app monitors and records all screenshots and recordings. Violators will face strict legal action.

THIS IS COPYRIGHTED CONTENT. Unauthorized use, including screenshots, copying, misuse, reuse, or resale of any content from this app, is strictly prohibited. Our app monitors and records all screenshots and recordings. Violators will face strict legal action.

DISCLAIMER

OPERATIVE

P.O.W.E.R NOTES SBQ 3

VIII. Reference:

ARTICLE: Improving the oral health of frail and functionally dependant elderly

The material of choice, particularly for root surface lesions, is a high-viscosity glass ionomer cement (GIC) in conjunction with atraumatic restorative treatment (ART). ART is a minimally invasive approach particularly suited to aged care.⁶³ GIC leaches fluoride and

Minimal intervention treatment using glass ionomer cement (GIC) and silver fluoride is ideal in aged care. However, GIC has limitation in dry mouths with low pH caused by polypharmacy or disease. Palliative and definitive treatment techniques need to be individualized with consideration of a patient's ability to maintain their own mouths as well as their mental and physical competence.

- IX.
- It's always advisable to eat fruits rather than consuming as juices because juice contains more sugars which can lead to high caries risk. Option (A) is ruled out.
 - If she is only taking fruits, she can't take it only once a day. Option (B) is ruled out.
 - During every mealtime, oral environment will become acidic. It will take minimum of 30 mins for the mouth to be neutralised. Saliva washes away the acidity with its buffering mechanism.
 - Eating fruits with main meals and reduce in between food pattern is the best advice.

THIS IS COPYRIGHTED CONTENT. Unauthorized use, including screenshots, copying, misuse, reuse, or resale of any content from this app, is strictly prohibited. Our app monitors and records all screenshots and recordings. Violators will face strict legal action.

DISCLAIMER

THIS IS COPYRIGHTED CONTENT. Unauthorized use, including screenshots, copying, misuse, reuse, or resale of any content from this app, is strictly prohibited. Our app monitors and records all screenshots and recordings. Violators will face strict legal action.

THIS IS COPYRIGHTED CONTENT. Unauthorized use, including screenshots, copying, misuse, reuse, or resale of any content from this app, is strictly prohibited. Our app monitors and records all screenshots and recordings. Violators will face strict legal action.

DISCLAIMER
THIS IS COPYRIGHTED CONTENT. Unauthorized use, including screenshots, copying, misuse, reuse, or resale of any content from this app, is strictly prohibited. Our app monitors and records all screenshots and recordings. Violators will face strict legal action.

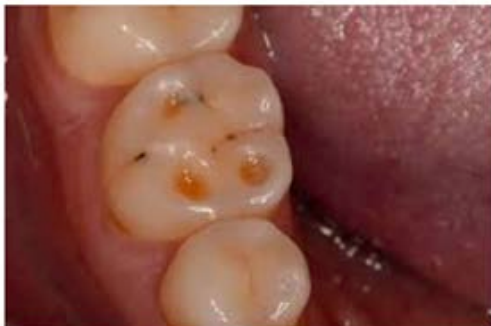THIS IS COPYRIGHTED CONTENT. Unauthorized use, including screenshots, copying, misuse, reuse, or resale of any content from this app, is strictly prohibited. Our app monitors and records all screenshots and recordings. Violators will face strict legal action.

THIS IS COPYRIGHTED CONTENT. Unauthorized use, including screenshots, copying, misuse, reuse, or resale of any content from this app, is strictly prohibited. Our app monitors and records all screenshots and recordings. Violators will face strict legal action.

OPERATIVE

SBQ 4

PATIENT PRESENTED TO YOU WITH SENSITIVITY. SHE IS VERY HEALTH CONSCIOUS. EVERY MORNING SHE DRINKS LEMON JUICE. SHE SHOWED A PHOTOGRAPH TAKEN BY HER PREVIOUS DENTIST 5 YEARS AGO.



I. What could be in her Medical history if present can be related to this lesion?

- A. GERD
- B. Celiac disease
- C. Asthma

II. What feature will help you identify this lesion?

- A. Cupping of cusp
- B. Flattened cusp
- C. Fractured cusp

III. How will you assess the activity of the lesion?

- A. Unstained exposed dentine
- B. Amalgam islands
- C. Stains

IV. What is the least affected surface in her situation?

- A. Upper labial
- B. Lower lingual
- C. Posterior buccal
- D. Occlusal
- E. Upper palatal

THIS IS COPYRIGHTED CONTENT. Unauthorized use, including screenshots, copying, misuse, reuse, or resale of any content from this app, is strictly prohibited. Our app monitors and records all screenshots and recordings. Violators will face strict legal action.

DISCLAIMER
THIS IS COPYRIGHTED CONTENT. Unauthorized use, including screenshots, copying, misuse, reuse, or resale of any content from this app, is strictly prohibited. Our app monitors and records all screenshots and recordings. Violators will face strict legal action.

THIS IS COPYRIGHTED CONTENT. Unauthorized use, including screenshots, copying, misuse, reuse, or resale of any content from this app, is strictly prohibited. Our app monitors and records all screenshots and recordings. Violators will face strict legal action.

DISCLAIMER

THIS IS COPYRIGHTED CONTENT. Unauthorized use, including screenshots, copying, misuse, reuse, or resale of any content from this app, is strictly prohibited. Our app monitors and records all screenshots and recordings. Violators will face strict legal action.

OPERATIVE

P.O.W.E.R NOTES SBQ 4

- I.
 - Weather extrinsic or intrinsic erosion, the occlusal surfaces of the posteriors will be affected. According to the given history the provisional diagnosis is extrinsic erosion.
 - Coeliac disease is a gastrointestinal disease not a vomiting disease. Option (B) is ruled out.
 - Asthma has an indirect relationship with erosion as asthma medication can cause erosion. Mostly the buccal surfaces of the teeth are involved.
 - GERD and Bulimia are associated with vomiting and intrinsic erosion. Mostly palatal surfaces of the anterior teeth are involved.
 - Both options (A) and (C) are correct but (A) is the best.

Reference:

Chronic asthma sufferers can experience advanced erosion caused by frequent use of certain asthma medication eg. puffers.

Table 2. Characteristics of dental erosion associated with different causative factors

| Form of erosion | Affected areas |
|----------------------------|--|
| All | Affected tooth surface is smooth and appears crazed. |
| Dietary | Depends on cause. |
| Medication | Occlusal surfaces of the molars and palatal surfaces of the upper molars. |
| Gastric reflux or vomiting | Occlusal surfaces of the molars and palatal surfaces of the upper anteriors and premolars. |
| Occupational | Usually buccal surfaces of the upper and lower anterior teeth. |

- II.
 - Flattening and fracturing of cusps are associated with ATTRITION.
 - Cupping of cusps is associated with EROSION.

DISCLAIMER

THIS IS COPYRIGHTED CONTENT. Unauthorized use, including screenshots, copying, misuse, reuse, or resale of any content from this app, is strictly prohibited. Our app monitors and records all screenshots and recordings. Violators will face strict legal action.

DISCLAIMER
THIS IS COPYRIGHTED CONTENT. Unauthorized use, including screenshots, copying, misuse, reuse, or resale of any content from this app, is strictly prohibited. Our app monitors and records all screenshots and recordings. Violators will face strict legal action.

OPERATIVE

P.O.W.E.R NOTES SBQ 4

- III. • Presence of stains shows inactive lesions of erosions, whereas absence of stains shows active lesions of erosions.
- If patient has amalgam restorations with erosion the tooth surface will wear off, but the amalgam will not and results in raised amalgam restorations. These appear as “AMALGAM ISLANDS”. But in this situation, we cannot differentiate whether it’s ACTIVE or INACTIVE erosion.
- IV. • Patient has a habit of lemon juice consumption. Which is associated with extrinsic erosion.
- In extrinsic erosion mostly the facial and buccal surfaces are involved.
- In the question it’s asked about the “least affected surfaces” therefore, mostly affected surfaces get ruled out. So, options (A), (C), (D) get ruled out.
- Compared to upper palatal and lower lingula surfaces, upper palatal surfaces are mostly involved.
- So, the least involved surface is lower lingula surface. Tongue is helpful in protecting these surfaces are as well.

OPERATIVE

SBQ 5

PATIENT COMPLAINTS OF DISCOMFORT IN THE UPPER POSTERIOR REGION (VARIATION IN DIFFERENT QUADRANTS AT DIFFERENT CENTERS). IOPA WAS GIVEN. IN IOPA (CLASS 2 FILLING WERE PRESENT WITH OPEN CONTACTS BETWEEN 25 AND 26) IOPA SIMILAR TO THAT ON UAF FILE (SCENARIO SAID STAGE 2 GRADE B PERIODONTITIS, ANDX RAY GIVEN-BITEWING WAS PROVIDED SHOWING OPEN CONTACT WITH MISSING AMALGAM, PATIENT HAS DULL PAIN WHILE EATING AND NO SYMPTOMS BY HOT OR COLD FOOD.

I. What's the reason for the patient's discomfort?

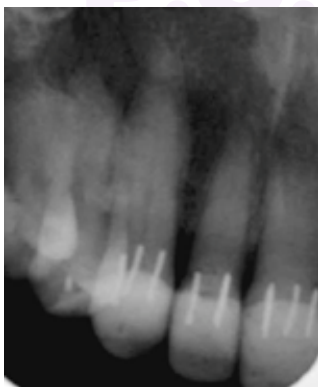
- A. Open contact 25-26
- B. Food lodgement
- C. Pocket formation
- D. Secondary caries (couldn't see caries on IOPA)

II. What has caused the open contact?

- A. Narrow wedge
- B. Over contouring of matrix band
- C. Not enough thickness of matrix band

III. What X Ray you will take to assess the gingival seal of restoration?

- A. opg
- B. bitewing,
- C. periapical x ray
- D. cbct
- E. occlusal x ray



IV. Another patient Pins supported restoration in relation to 25 were visible on IOPA provided. What causes her severe pain?

- A. Multiple pins entering pulp
- B. Marginal leakage through restoration
- C. Split root

DISCLAIMER

THIS IS COPYRIGHTED CONTENT. Unauthorized use, including screenshots, copying, misuse, reuse, or resale of any content from this app, is strictly prohibited. Our app monitors and records all screenshots and recordings. Violators will face strict legal action.

DISCLAIMER

THIS IS COPYRIGHTED CONTENT. Unauthorized use, including screenshots, copying, misuse, reuse, or resale of any content from this app, is strictly prohibited. Our app monitors and records all screenshots and recordings. Violators will face strict legal action.

THIS IS COPYRIGHTED CONTENT. Unauthorized use, including screenshots, copying, misuse, reuse, or resale of any content from this app, is strictly prohibited. Our app monitors and records all screenshots and recordings. Violators will face strict legal action.

DISCLAIMER

OPERATIVE

P.O.W.E.R NOTES SBQ 5

- I.
 - Patient experience dull pain while eating but no symptoms by hot and cold. Which means there can be a periodontal involvement rather than having a pulpal involvement. Patient is diagnosed with stage 2 grade B periodontitis.
 - Secondary caries is not given in the history. So, option (D) is ruled out.
 - Open contact on its own will not cause pain.
 - There can be pe periodontal pocket formation as the patient is diagnosed with periodontitis. Pocket formation on its own will not cause pain.
 - Patient has dull pain only while eating. So, pain can be due to food lodgement.
- II. Open contact can be due to **not using a wedge** in class II cavity restoration. Which means separation of teeth is not adequate. But if that answer is not given open contact can be due few other reasons. They are:
 1. Not using a correct size of wedge for that particular embrasure can lead to this. Whereas **using a narrow wedge** when it requires a large size of wedge. This can lead to no adequate separation.
 2. **Using a thick matrix** band can also be a reason. Wedge compensate the thickness of the matrix band. Matrix and is used to create a wall in class II restoration. Therefore, matrix band should not be too thick as it will need a wider size wedge to compensate that thickness. So, option (C) gets ruled out.
 3. Over tighten matrix band will results in open contacts
 4. Not placing and adapting the matrix band and tofflemire retainer well can results in open contacts. This is why sectional matrix band system more superior in creating better contacts in class II restorations.

Over contouring will results in over hanging of restoration and bulky, tight contacts. So, there won't be open contacts with an over contoured restoration. Option (B) gets ruled out. Under contouring will results in open contacts.
- III.
 - Bitewing is suitable for multiple restoration, assessing multiple teeth, for interproximal caries. It helps in opening up the contacts so, proximal caries is seen better.

Reference:

Bitewing radiographic examination of the Class II composite restorations is commonly performed for diagnosis and preoperative planning of posterior teeth. The American Dental Association (ADA) recommends a posterior bitewing exam for adults with high caries risk every six to eighteen months. In contrast, exams can be recommended for adults with low caries risk every two to three years [1,2,3]. From a radiographic point of view, successful restorative treatment can be measured by the absence of radiographic signs suggestive of underlining carious lesions, open margins, voids, or overhang [4,5]. However, determining the health status of the restoration is challenging when radiolucent areas (radiolucencies) are associated. Particularly for Class II restorations because of the proximal gingival interface. Misdiagnosing radiolucencies may lead to unnecessary restoration replacement or a delayed diagnosis with failure in timely access to dental care.

DISCLAIMER

THIS IS COPYRIGHTED CONTENT. Unauthorized use, including screenshots, copying, misuse, reuse, or resale of any content from this app, is strictly prohibited. Our app monitors and records all screenshots and recordings. Violators will face strict legal action.

DISCLAIMER

THIS IS COPYRIGHTED CONTENT. Unauthorized use, including screenshots, copying, misuse, reuse, or resale of any content from this app, is strictly prohibited. Our app monitors and records all screenshots and recordings. Violators will face strict legal action.

THIS IS COPYRIGHTED CONTENT. Unauthorized use, including screenshots, copying, misuse, reuse, or resale of any content from this app, is strictly prohibited. Our app monitors and records all screenshots and recordings. Violators will face strict legal action.

DISCLAIMER

OPERATIVE

P.O.W.E.R NOTES SBQ 5

IV. Pin amalgam restorations are not used now as there are drawbacks associated with them. they can:

1. Cause pulpal damage (when pins penetrating to pulp)
 2. Can create discrepancies within the margins
 3. Can leads to micro cracks and fractures within the dentin
- In the scenario patient is experiencing severe pain. Severe pain is associated with PDL/ pulpal pain.
 - Split root will have a dull pain on biting. So, option (C) gets ruled out.
 - Sharp shooting severe pain is associated with crack tooth as it involves pulp.
 - Pins entering the pulp will be associated pain soon after the procedure not some time afterwards. Therefore, option (A) gets ruled out.
 - When there are pins there's a challenge to adaptation and creating marginal gaps within the restoration which can lead to marginal leakage through restoration and cause pain.
 - So, among the given, option (B) is the best.

Reference: **Sturdevants**

Penetration Into the Pulp and Perforation of the External Tooth Surface

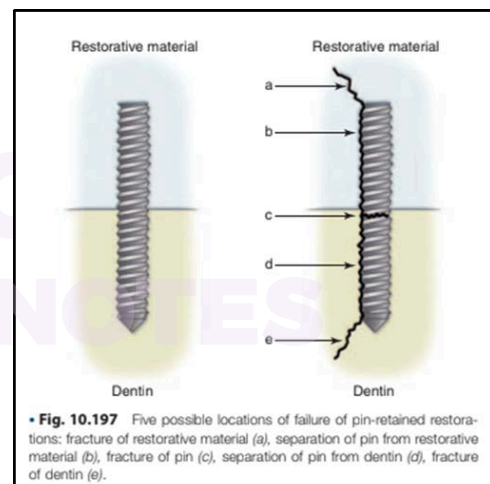
Penetration into the pulp or perforation of the external surface of the tooth is obvious if hemorrhage occurs in the pinhole after removal of the drill. Usually the operator is able to perceive when pulp penetration or root perforation has occurred by an abrupt loss of resistance of the drill to hand pressure. Also if a standard or Link Series pin continues to thread into the tooth beyond the 2-mm depth of the pinhole, this is an indication of a penetration or perforation. A pulpal penetration might be suspected if the patient is anesthetized and has sudden sensitivity when the pinhole is being completed or the pin is being placed. However, if the patient still has profound pulpal anesthesia, pulpal penetration of the pinhole or pin may not be perceived.

Possible Problems With Pins

Failure of Pin-Retained Restorations

The failure of pin-retained restorations might occur at any of five different locations (Fig. 10.197). Failure may occur (1) within the restoration (restoration fracture), (2) at the interface between the pin and the restorative material (pin-restoration separation), (3) within the pin (pin fracture), (4) at the interface between the pin

and dentin, and (5) within dentin (dentin fracture). Failure is more likely to occur at the pin-dentin interface than at the pin-restoration interface. The operator must keep these areas of potential failure in mind at all times and apply necessary principles to reduce failure risk.



strict legal action.

THIS IS COPYRIGHTED CONTENT. Unauthorized use, including screenshots, copying, misuse, reuse, or resale of any content from this app, is strictly prohibited. Our app monitors and records all screenshots and recordings. Violators will face strict legal action.

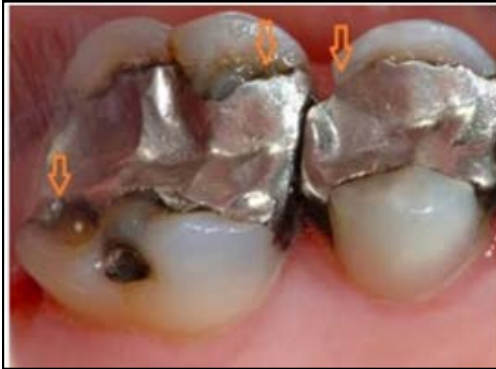THIS IS COPYRIGHTED CONTENT. Unauthorized use, including screenshots, copying, misuse, reuse, or resale of any content from this app, is strictly prohibited. Our app monitors and records all screenshots and recordings. Violators will face strict legal action.

DISCLAIMER
THIS IS COPYRIGHTED CONTENT. Unauthorized use, including screenshots, copying, misuse, reuse, or resale of any content from this app, is strictly prohibited. Our app monitors and records all screenshots and recordings. Violators will face strict legal action.

OPERATIVE

SBQ 6

MMF UAF MIXED - NATUROPATH REPLACEMENT SCENARIO. THIS HAD OPTIONS VARIATION - A PICTURE WAS GIVEN WITH AMALGAM RESTORATION. ASKING FOR FINDING ON RESTORATION, THERE WERE NO SECONDARY CARIES CLINICALLY AND RADIOGRAPHICALLY. BUT THE PATIENT IS A NATUROPATH AND REQUESTING TO REPLACE ALL AMALGAM FILLINGS.



I. What is the defect seen on premolar?

- A. Creep
- B. Corrosion
- B. Ditch
- C. Secondary caries
- D. Thermal expansion

II. What do you advise to the patient?

- A. Don't change and no treatment
- B. Remove and do indirect
- C. Remove all amalgam and do composite
- D. Restore only if the gap is more than 400 micrometers.

III. Patient still wants to replace all amalgam. What material will you choose?

- A. Composite
- B. Gic
- C. Rmgic
- D. Compomer

IV. What is the most important thing you will take into consideration?

- A. Safety of amalgam vapour generation
- B. Risk of teeth become non vital
- C. Tooth fracture

V. Patient wants to do resin composite, how will it bind to the tooth?

- A. Make undercuts.
- B. Etching and bonding to tooth structure.
- C. Proximal grooves and boxes.

DISCLAIMER

THIS IS COPYRIGHTED CONTENT. Unauthorized use, including screenshots, copying, misuse, reuse, or resale of any content from this app, is strictly prohibited. Our app monitors and records all screenshots and recordings. Violators will face strict legal action.

DISCLAIMER

THIS IS COPYRIGHTED CONTENT. Unauthorized use, including screenshots, copying, misuse, reuse, or resale of any content from this app, is strictly prohibited. Our app monitors and records all screenshots and recordings. Violators will face strict legal action.

THIS IS COPYRIGHTED CONTENT. Unauthorized use, including screenshots, copying, misuse, reuse, or resale of any content from this app, is strictly prohibited. Our app monitors and records all screenshots and recordings. Violators will face strict legal action.

DISCLAIMER

OPERATIVE

P.O.W.E.R NOTES SBQ 6

- I.
 - According to the scenario, there's no secondary caries clinically and radiographically. So, there is no need of replacing the amalgam.
 - Options (B), (D), (E) get ruled out easily.
 - Among options (A) and (C), CREEP is a phenomenon/ process and DITCH is a defect. In the question it's asked about the "defect".

Reference: **STURDVENT**

Creep. Creep is defined as time dependent plastic deformation of a material under static load or constant stress. This property is important with silver amalgam. Conventional low copper amalgam materials have high creep values and exhibit poor marginal integrity over time as the amalgam creeps into a thin layer and then breaks off creating marginal ditching. Contemporary high copper amalgams have low creep values and maintain good marginal integrity as a function of time.

Creep is one of the few properties that has a demonstrated ability to predict clinical performance. Amalgam materials with low creep values perform well clinically when compared with amalgams with high creep values.

Reference: **GOOGLE**

In dental amalgam restorations, creep is a phenomenon where the material deforms under constant stress, leading to marginal breakdown or "ditching". Ditching refers to the formation of a gap or groove at the junction between the amalgam restoration and the tooth, often caused by creep. High-copper amalgams, which have lower creep rates compared to low-copper amalgams, are less prone to ditching.

THIS IS COPYRIGHTED CONTENT. Unauthorized use, including screenshots, copying, misuse, reuse, or resale of any content from this app, is strictly prohibited. Our app monitors and records all screenshots and recordings. Violators will face strict legal action.

DISCLAIMER

THIS IS COPYRIGHTED CONTENT. Unauthorized use, including screenshots, copying, misuse, reuse, or resale of any content from this app, is strictly prohibited. Our app monitors and records all screenshots and recordings. Violators will face strict legal action.

DISCLAIMER
THIS IS COPYRIGHTED CONTENT. Unauthorized use, including screenshots, copying, misuse, reuse, or resale of any content from this app, is strictly prohibited. Our app monitors and records all screenshots and recordings. Violators will face strict legal action.

DISCLAIMER

THIS IS COPYRIGHTED CONTENT. Unauthorized use, including screenshots, copying, misuse, reuse, or resale of any content from this app, is strictly prohibited. Our app monitors and records all screenshots and recordings. Violators will face strict legal action.

OPERATIVE

P.O.W.E.R NOTES SBQ 6

- ii. • According to the scenario, there's no secondary caries clinically and radiographically. So, there is no need of replacing the amalgam.
- Therefore, options (B) and (C) get ruled out.
- There are defects in amalgam restoration. (e.g. ditch) even though there's no secondary caries at this stage there can be secondary caries in the future.
- Therefore, among the given the best answer is (D).

Marginal gap formation (or "ditching") is the deterioration of the amalgam-tooth interface as a result of enamel wear and/or restoration edge fracture (Fig. 3.6A). Improper tooth preparation may predispose an amalgam restoration to ditching. It can be diagnosed visually or by the explorer dropping into an opening as it crosses the margin. Shallow ditching less than 0.5 mm deep usually is not a reason for restoration replacement because the area is self-cleaning and not prone to caries development.¹⁶ Such a restoration usually looks worse than it really is. The ongoing self-sealing property of amalgam allows the restoration to continue serving adequately if it can be satisfactorily cleaned and maintained. If the ditch is too deep to be cleaned or jeopardizes the integrity of the remaining restoration or tooth structure, the restoration should be replaced.¹⁶ However, marginal gaps near the gingival wall frequently become areas of secondary caries development and correction of these areas is indicated.¹⁷

Localized voids, which result from poor condensation of the amalgam, may also occur at the margins of amalgam restorations. If the void is at least 0.3 mm deep and is located in the gingival third of the tooth crown, the restoration is judged as defective and should be repaired or replaced. Accessible small voids in other marginal areas where the enamel is thicker may be corrected by enamel recontouring or repairing with a small restoration.

- iii. • According to the given picture it's a large restoration. Among the given composite is the best as it's a permanent restorative material and it's strong and suits better in large fillings.
- GIC is a temporary filling and option (B) gets ruled out.
- RMGIC is not a good material for posterior occlusal surfaces.
- Compomer is inferior to composites.
- Among the given option (A) is the best.

DISCLAIMER

THIS IS COPYRIGHTED CONTENT. Unauthorized use, including screenshots, copying, misuse, reuse, or resale of any content from this app, is strictly prohibited. Our app monitors and records all screenshots and recordings. Violators will face strict legal action.

DISCLAIMER

THIS IS COPYRIGHTED CONTENT. Unauthorized use, including screenshots, copying, misuse, reuse, or resale of any content from this app, is strictly prohibited. Our app monitors and records all screenshots and recordings. Violators will face strict legal action.

THIS IS COPYRIGHTED CONTENT. Unauthorized use, including screenshots, copying, misuse, reuse, or resale of any content from this app, is strictly prohibited. Our app monitors and records all screenshots and recordings. Violators will face strict legal action.

DISCLAIMER

OPERATIVE

P.O.W.E.R NOTES SBQ 6

IV. All the given answers are correct. But according to the sequence, (A) is the best.

Reference:

If amalgam is clinically indicated, only pre-encapsulated amalgam should be used by dental practitioners. If placing or removing dental amalgam, measures should be taken to minimise exposure to mercury vapour, including the use of rubber dam, adequate water supply and high-volume evacuation.

V. Secondary retentive features such as:

- Under cuts
- Proximal grooves and boxes
- Are important in amalgam restorations.
- Composites will bind both chemically and mechanically to the tooth structure. So, etching and bonding is required for composites.
- Composites bind together their constituent materials through both chemical and mechanical means. Chemical bonding, such as through covalent or ionic bonds, creates strong, direct connections between the matrix and reinforcement phases. Mechanical bonding, like interlocking or friction, provides a physical hold, often in conjunction with chemical bonding.