



WINSPERT

ORTHODONTICS

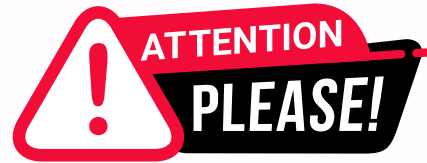H.O.T

HIGH-PRIORITY ORGANISED THEORY

NOTES

By Dr. Jigyasa Sharma





Dear Students,

We'd like to remind you about the importance of respecting the integrity of the resources provided in our app.

Please be aware that **WINSPERT HOT NOTES ARE COPYRIGHTED CONTENT. Unauthorized use, including screenshots, copying, misuse, reuse, or resale of any content from this app, is strictly prohibited.**

Our app monitors and records all screenshots and recordings. Violators will face strict legal action.

We're committed to providing you with the best tools for your success, and we appreciate your cooperation in maintaining a fair and secure learning environment.

Thank you for your understanding and continued dedication.

Best regards,
WINSPERT TEAM

Table of Contents

ORTHODONTICS H.O.T TOPICS

HOT TOPIC	Page
Orthodontic Demineralisation	04
External Cervical Resorption	10
Missing Canines & Missing Permanent Teeth	15
Space Maintenance	18
Lateral Cephalogram Classification of Malocclusions	24
Diastema & Deep Bite Management	30
Invisalign	38

ORTHODONTIC DEMINERALIZATION

Source- Article on Orthodontic demineralization (ADA)

- As patients progress from childhood to teenage years, they progress through periods of high caries risk with the change in life style and microflora.
- Removable and Fixed orthodontic treatments also alter the oral micro flora. This can dramatically increase the risk of caries.
- It is important that caries risk assessment is undertaken for teenagers, particularly before bonding of fixed appliances, since these impede the mechanical oral hygiene.
- Specific advice on prevention and homecare protocols should be tailored to each patient.
- Recall intervals should also be adjusted to suit individual caries risk.
- During orthodontic treatment retentive areas are created that favor biofilm accumulation.
- Traditional fixed appliances produce stagnation zones which produce a challenge to mechanical plaque control.
- Bracket design also influences both caries risk and periodontal parameters.
- The surface roughness of appliance and the type of ligature used also affects the retention of plaque.
 - i. Elastomeric ligature “O-rings “show greater plaque retention then self-ligating brackets, this increases the risk of demineralization around brackets.
 - ii. Ceramic brackets exhibit less long-term biofilm accumulation then metal brackets.
 - iii. Lingual appliances significantly alter the biofilm of the wearer in the first 2 months of treatment and cause increased plaque retention associated with gingival appliances.
- When using similar oral hygiene practices, patients undergoing aligner therapy have significantly better oral health and gingival status than those undergoing traditional fixed orthodontic therapy. (This is attributed to the fact that aligners can be removed for cleaning).
- The rate at which plaque biofilm is accumulated around brackets is also associated with the presence of residual bracket cements. This can be reduced by:
 - a) Making an effort to reduce excess adhesives around bands and brackets, by cleaning up performed manually.
 - b) Using Flash free brackets. (Less accumulation of plaque then conventional bracket design)

DISCLAIMER

THIS IS COPYRIGHTED CONTENT. Unauthorized use, including screenshots, copying, misuse, reuse, or resale of any content from this app, is strictly prohibited. Our app monitors and records all screenshots and recordings. Violators will face strict legal action.

DISCLAIMER

THIS IS COPYRIGHTED CONTENT. Unauthorized use, including screenshots, copying, misuse, reuse, or resale of any content from this app, is strictly prohibited. Our app monitors and records all screenshots and recordings. Violators will face strict legal action.

ORTHODONTIC DEMINERALIZATION

Ways to reduce the risk of high caries in patients undergoing orthodontic therapy

a) Mechanical plaque control:

- All teenage patients should use a fluoride dentifrice (Concentration as per fluoride guidelines)
- The benefits of frequent tooth brushing are:

Table 1. Benefits of frequent tooth cleaning

- Reduced biofilm area and volume
- Reduced biofilm thickness, thus altered composition
- Lower production of organic acids by the biofilm
- Lower production of volatile sulphur compounds by the biofilm
- Delivery of fluoride (remineralization, lower acid production)
- Delivery of phosphates which lower calculus formation
- Micropolishing of external stains from accessible tooth surfaces
- Delivery of anti-plaque agents (triclosan, stannous and zinc compounds, etc.)

- The presence of Orthodontic appliance makes oral hygiene more difficult.

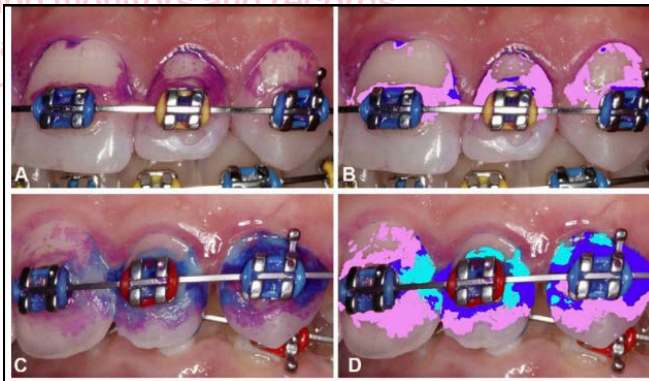


Fig. 1 Common plaque biofilm-related issues in teenage orthodontic patients. (a) An orthodontic patient with reasonable oral hygiene, where the teeth have been stained with 3-tone disclosing dye (GC TriPlaque ID™ gel). (b) Digitally filtered version of the image from panel A, showing young plaque less than 24 hours old as pink, and mature plaque as purple. (c) An orthodontic patient with poor oral hygiene and a cariogenic plaque biofilm, using the same dye staining method. (d) The digitally filtered image shows extensive plaque coverage of the teeth, with areas of high acid production (shown in light blue).

- When there is poor control p tooth brushing, biofilm accumulation around appliances can drive chronic gingivitis and lead to tissue overgrowth and decalcification of enamel.

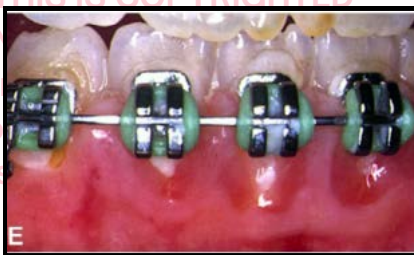

Fig: Inflammatory changes from poor plaque control when fixed orthodontic appliance is used

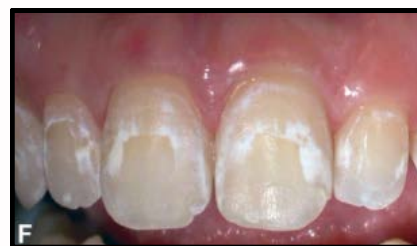

Fig: Demineralization spots seen on bracket removal

DISCLAIMER

THIS IS COPYRIGHTED CONTENT. Unauthorized use, including screenshots, copying, misuse, reuse, or resale of any content from this app, is strictly prohibited. Our app monitors and records all screenshots and recordings. Violators will face strict legal action.

ORTHODONTIC DEMINERALIZATION

How to achieve plaque control?

a) Mechanical Plaque control

- Multi color plaque disclosing dyes can help clinicians identify rapidly where patients are struggling with mechanical cleaning.
- A 2 colored dye will show newly formed dental plaque aged less than 1 day old as pink, and stain the older plaques as blue / purple.
- This can very informative to identify high caries risk areas around brackets and also helps professionals provide targeted oral hygiene education.
- Motivational interviewing should be the approach for this type of education.

tion. This education should be undertaken using motivational interviewing (MI), which is a collaborative, person-centred form of guiding to elicit and strengthen motivation for change. MI is grounded in there being a good rapport between the clinician and the patient, with mutual respect, with the clinician being "in tune" with the patient's compliance challenges, and with their ambivalence versus readiness for changes to address better compliance. The clinician plays a helping and supporting role rather than taking an expert stance. Using the MI approach, the clinician calls forth from the patient their own internal motivation and commitment towards better oral hygiene compliance. The MI approach has strong evidence base in terms of promoting effective oral health behaviours.¹⁷

- For effective plaque control using manual tooth brushing alone is not effective. A powered tooth brush provides more important benefits over manual tooth brush especially when special orthodontic heads are used as the brittles pattern and materials have been optimized for use around orthodontic brushes.

use around orthodontic appliances.¹⁹ If a powered brush is recommended, an appropriate dedicated orthodontic brush head should be used, since these have been found to outperform regular brush heads.²⁰

DISCLAIMER

THIS IS COPYRIGHTED CONTENT. Unauthorized use, including screenshots, copying, misuse, reuse, or resale of any content from this app, is strictly prohibited. Our app monitors and records all screenshots and recordings. Violators will face strict legal action.

DISCLAIMER

THIS IS COPYRIGHTED CONTENT. Unauthorized use, including screenshots, copying, misuse, reuse, or resale of any content from this app, is strictly prohibited. Our app monitors and records all screenshots and recordings. Violators will face strict legal action.

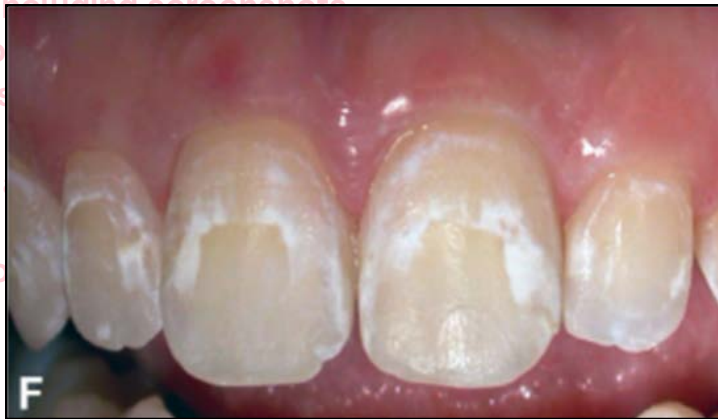ORTHODONTIC DEMINERALIZATION

How to achieve plaque control?

b) Chemical Plaque control:

- Chemical plaque control agents can be a useful adjunct to mechanical measures as they can enhance the control of plaque along with gingivitis.
- Mouth rinses and interdental flossing and brushing is a powerful adjunct.
- For patients with orthodontic appliance the ideal protocol for plaque control is:
 1. Brush
 2. Interdental cleaning
 3. Rinse

Enamel decalcification with Orthodontic treatment (Ortho demineralization spots)



- Fixed orthodontic treatment causes increased incidence of enamel demineralization, which affects both longevity and appearance of dentition.

appearance and longevity of the dentition. A recent meta-analysis that included 14 studies of white spot lesions in orthodontic patients calculated an incidence rate of 45.8%, and a prevalence rate of 68.4% in patients under orthodontic treatment.⁴⁸ In any one patient, up to 30% of the buccal surfaces may be affected. A greater severity and extent of mineral loss is seen when sensitive fluorescence methods are used to

- **Fixed appliance** alters the composition of plaque biofilm. Higher levels of key pathogens like streptococcus mutans, and caries associated organisms are found in teenagers undergoing orthodontic treatment who have numerous white spot lesions.
- **The major goal of clinician is** to monitor the patient's caries risk status and take actions that favor the health of the teeth.
- **This will involve multiple actions** including diet, oral hygiene and application of remineralizing agents such as fluoride and CPP-ACP (Casein phosphopeptides)

DISCLAIMER

THIS IS COPYRIGHTED CONTENT. Unauthorized use, including screenshots, copying, misuse, reuse, or resale of any content from this app, is strictly prohibited. Our app monitors and records all screenshots and recordings. Violators will face strict legal action.

DISCLAIMER

THIS IS COPYRIGHTED CONTENT. Unauthorized use, including screenshots, copying, misuse, reuse, or resale of any content from this app, is strictly prohibited. Our app monitors and records all screenshots and recordings. Violators will face strict legal action.

ORTHODONTIC DEMINERALIZATION

Enamel decalcification with Orthodontic treatment (Ortho demineralization spots)

Numerous investigations have shown anti-cariogenic effects of CPP-ACP through promoting remineralization of enamel subsurface lesions.⁵⁸⁻⁶¹ A recent systematic review showed that CPP-ACP with fluoride incorporated into it was superior to fluoride alone for arresting and reversing early occlusal carious lesions.⁶² CPP-ACP also influences the composition of dental plaque, via prebiotic effects.⁶³ Elevating levels of calcium and fluoride ions at the tooth surface and within the dental plaque fluid suppresses acid production, while phosphate ions contribute to buffering of plaque pH changes.⁶⁴

Various Forms of CPP ACP and fluoride used for prevention:

- **Topical application of CPP-ACP** can Reverse the appearance of decalcified enamel during fixed orthodontic treatment.

ment.⁶⁷⁻⁶⁹ The basis of this effect is that neutral ions such as CaHPO_4^0 are produced, which are localized at the tooth surface, allowing subsequent diffusion of these ions deep into the body of white spot lesion, such that remineralization occurs throughout the body of the lesion, restoring both its structure and the normal optical appearance of enamel.⁷⁰ This makes the outcome superior to using conventional fluoride dentifrices or high concentration fluoride gels, since precipitation of calcium fluoride on the surface of the white spot lesion may restrict the passage of ions into the deeper, more affected layers.⁶⁸

- **Topical crème containing CPP-ACP and Fluoride** prevent development of new white spot lesions during orthodontic treatment.
- **CPP-ACP can also be delivered** in a 22,600 ppm Fluoride varnish.
- **Such varnishes** have value of treating white spot lesions.
- It is not prudent to wait until debanding to initiate treatment for white spot lesions during orthodontic treatment.
- They should be treated with appropriate material like CPP-ACP crème or fluoride varnish containing CPP-ACP.
- Using only fluoride rinse is not enough, because fluoride ions can only promote remineralization of enamel when sufficient salivary or plaque calcium phosphate are available. In most cases, calcium ions are lacking limiting effective remineralization.
- **Using Tooth surface** protection materials around brackets and bands is a valuable approach to reduce and prevent ortho-demineralization spots.

DISCLAIMER

THIS IS COPYRIGHTED CONTENT. Unauthorized use, including screenshots, copying, misuse, reuse, or resale of any content from this app, is strictly prohibited. Our app monitors and records all screenshots and recordings. Violators will face strict legal action.

DISCLAIMER

THIS IS COPYRIGHTED CONTENT. Unauthorized use, including screenshots, copying, misuse, reuse, or resale of any content from this app, is strictly prohibited. Our app monitors and records all screenshots and recordings. Violators will face strict legal action.

ORTHODONTIC DEMINERALIZATION

Various Forms of CPP ACP and fluoride used for prevention:

demonstrated.⁷⁹ Use of surface protection materials or specially designed cements could be a very useful means to deliver bioavailable fluoride, calcium, and phosphate ions around the bracket and onto the tooth surface, preventing mineral loss and promoting remineralization.

A further approach is to alter the enamel surface of teeth with fixed appliances to make them more resistant to caries, by enhancing the uptake of fluoride from professionally applied gels. The phenomena of

Follow-up and Maintenance:

- It is essential for patient's general dentist to design suitable interval for patients recall so that significant dental problems do not develop during orthodontic treatment.
- The timing of recall should take into account the optimal timing for therapeutic measures, such as application of fluoride varnishes that release both fluoride and CPP-ACP or fluoride alone.
- These are more effective when applied 3 monthly.

THIS IS COPYRIGHTED CONTENT. Unauthorized use, including screenshots, copying, misuse, reuse, or resale of any content from this app, is strictly prohibited. Our app monitors and records all screenshots and recordings. Violators will face strict legal action.

DISCLAIMER

THIS IS COPYRIGHTED CONTENT. Unauthorized use, including screenshots, copying, misuse, reuse, or resale of any content from this app, is strictly prohibited. Our app monitors and records all screenshots and recordings. Violators will face strict legal action.

THIS IS COPYRIGHTED CONTENT. Unauthorized use, including screenshots, copying, misuse, reuse, or resale of any content from this app, is strictly prohibited. Our app monitors and records all screenshots and recordings. Violators will face strict legal action.

EXTERNAL CERVICAL RESORPTION

Sources: External cervical resorption: Radiological diagnosis and literature (Review), External cervical resorption- predisposing factors and pathogenesis a review.

- Dental resorption is considered to be a challenge to dentistry due to its complexity. Root resorption (RR) represents a pathological process that causes the loss of cementum, dentine and/or enamel, almost irreversibly, concerning vital and non-vital teeth, as a result of odontoclastic function.
- Although root resorption is necessary in temporary dentition to enable the eruption of the permanent successors (physiological root resorption), root resorption of permanent teeth is unfavorable.
- Generally, Root resorption can simply be classified as internal or external resorption, depending on the location on the root surface. External root resorption can be further subclassified into surface resorption, external inflammatory resorption, external replacement resorption, external cervical resorption, transient apical resorption. One of the least understood types of external resorption is external cervical resorption.
- External cervical resorption (ECR) is an aggressive and uncommon form of external resorption that initiates at the cervical aspect of the tooth.
- ECR is a dynamic and pathological process characterized by its cervical position on the tooth, arising immediately below the epithelial attachment and the coronal part of the bone, this zone being named the zone of the connective tissue attachment.
- It is an aggressive form of resorption where in most cases, the symptoms begin to develop when the resorption reaches its advanced phase Hence, ECR may be diagnosed only after irreversible damage to the tooth structure has been diagnosed.

Pathogenesis of ECR

- The pathogenesis primarily focuses on two basic aspects:
 - a) Histopathology of lesion
 - ECR is believed to be derived from disruption of the Periodontal ligament (PDL) which subsequently induces inflammation.
 - Following the infiltration of inflammatory cells, granulation tissue form and penetrate the dentin.
 - The resorption lesion extends circumferentially and apico-coronally, thus creating multiple resorption channels inside the root.

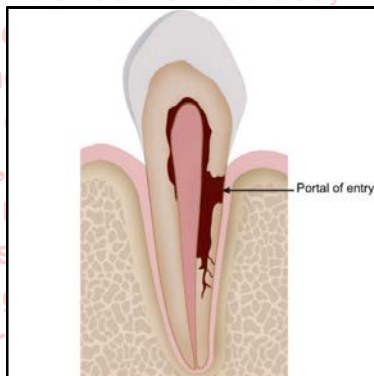


Fig: Schematic representation of histological patterns of ECR lesion.

DISCLAIMER

THIS IS COPYRIGHTED CONTENT. Unauthorized use, including screenshots, copying, misuse, reuse, or resale of any content from this app, is strictly prohibited. Our app monitors and records all screenshots and recordings. Violators will face strict legal action.

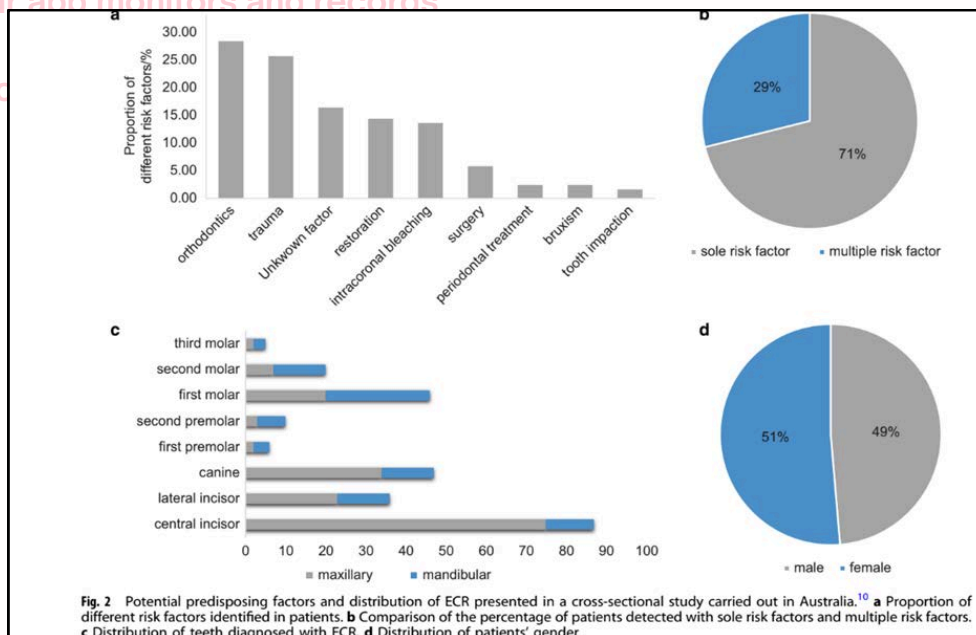
EXTERNAL CERVICAL RESORPTION

Pathogenesis of ECR

- The pathogenesis primarily focuses on two basic aspects:
 - Cellular and molecular mechanisms of osteoclastogenesis**
 - The exact cause of inflammatory response in ECR is controversial.
 - Two hypotheses, with regards to activation of osteoclastogenesis, are available:
 - The inflammation theory:** This theory proposes that the resorption is initiated due to non-infectious exogenous stimulation, which induces local inflammation in periodontium.
 - The Infection theory:** This theory considers the mechanism of ECR is similar to periodontitis, i.e., the presence of microorganisms is essential

Potential Predisposing Factors of ECR:

- Multiple risk factors are associated with ECR.
- Various studies have been conducted to know the prevalence of predisposing factors leading to ECR.



DISCLAIMER

THIS IS COPYRIGHTED CONTENT. Unauthorized use, including screenshots, copying, misuse, reuse, or resale of any content from this app, is strictly prohibited. Our app monitors and records all screenshots and recordings. Violators will face strict legal action.

EXTERNAL CERVICAL RESORPTION

Major Predisposing factors:

1) Orthodontics

- Orthodontics is a commonly identified risk factor not only in ECR but other types of external root resorption.
- Maxillary anterior teeth, especially maxillary canines and maxillary central incisors showed a high susceptibility to ECR during and after orthodontic treatment in reviews.
- It is well established that Orthodontic forces lead to inflammatory apical root resorption but that ceases as soon as the orthodontic force application stops.
- On the other hand, ECR can occur several years after the completion of Orthodontic treatment.
- ECR does not occur immediately after orthodontic treatment. An interval of several years is commonly seen in majority of the cases, where other predisposing factors may also contribute to initiation and continuation of ECR.

2) Trauma

- It is a prominent risk factor for root resorption.
- In terms of acute injury, the majority of ECR cases were detected in 2-5 months following trauma.
- In chronic injury, the time lag between injury and resorption initiation is usually long.

3) Intra-coronal bleaching

- It is the first predisposing factor discovered by clinicians.
- It is considered that the physical and chemical properties of bleaching agents and permeability of dentin are three major factors contributing to occurrence of post bleaching ECR.
- The coronal sealing of root canal with glass ionomer cement (GIC) is a feasible way to reduce the possibility of periodontal and cervical leakage.

In recent years, the introduction of sodium perborate mixed with water as a substitute for hydrogen peroxide has brought about a considerable decrease in the morbidity of post-bleaching ECR.¹⁰² 35% carbamide peroxide showed a combination of sodium perborate's safety and hydrogen peroxide's efficacy in clinical practice.¹⁰¹

DISCLAIMER

THIS IS COPYRIGHTED CONTENT. Unauthorized use, including screenshots, copying, misuse, reuse, or resale of any content from this app, is strictly prohibited. Our app monitors and records all screenshots and recordings. Violators will face strict legal action.

DISCLAIMER

THIS IS COPYRIGHTED CONTENT. Unauthorized use, including screenshots, copying, misuse, reuse, or resale of any content from this app, is strictly prohibited. Our app monitors and records all screenshots and recordings. Violators will face strict legal action.

EXTERNAL CERVICAL RESORPTION

Clinical presentation of ECR:

- There is no classic presentation of ECR.
- The lesion often begins asymptotically, insidiously, being accidentally discovered at a clinical and/or radiological routine check-up. This is characteristic for the initial lesions, discovered in early stages.
- In more advanced cases, when the defect is in the proximity of the pulp chamber or even perforates it, patients may report symptoms similar to reversible or irreversible pulpitis (temperature sensitivity) and/or symptoms similar to apical periodontitis (percussion pain, fistula).
- In initial stages, vitality tests are within normal limits, as long as there is no involvement of the pulp and the pulp has not become necrotic.
- The cavities resulting from ECR are hard and scratchy on probing, giving a feeling of mineralized tissue. In addition, the edges are sharp, like a knife.
- A **pink spot** can be observed in the cervical third area of the ECR teeth, being a pathognomonic sign of this entity.
- This is due to the high vascularity of the granulomatous tissue, which can be visible through the thin enamel in the cervical area.
- The presence of granulomatous tissue is also the reason why bleeding is observed during probing. However, the appearance of pink spots is quite rare.

Radiologic interpretation:

- From a radiological point of view, the lesions can be symmetrical or asymmetrical.
- Their margins can vary from well-defined and smooth, to poorly defined and rough, or with no clear limits between the lesion and the healthy dental tissues.
- ECR may appear radiolucent (if the lesion is identified in its active resorption phase), radiopaque (if the lesion is detected in the repair phase as a result of ossification of the granulomatous tissue) or there may be combinations of both phases (the lesion appearing radiopaque and radiolucent).
- In addition, ECR lesions can be misdiagnosed as internal resorption (IR).

Investigations:

- Multiple periapical radiographs can be performed from various angles. In the case of ECR, the lesion will look as if it is moving with the change of horizontal angle of the X-ray tube.
- The lesions located buccally move in the opposite direction, while those located lingually move in the same direction with the parallax shift. This can also help to determine the location of the lesion when clinically it is not possible.
- The use of CBCT leads to a more accurate diagnosis, assessment and/or management of difficult endodontic cases in ECR.
- Using CBCT has exceeded the limits of bi-dimensional radiographs and the true nature of the lesion, size, circumferential extension and proximity to the root canal can be identified.
- The improved precision of CBCT has not only the advantage of a more accurate recognition, evaluation and classification of ECR, but it helps also in the selection of the most suitable management plan.

DISCLAIMER

THIS IS COPYRIGHTED CONTENT. Unauthorized use, including screenshots, copying, misuse, reuse, or resale of any content from this app, is strictly prohibited. Our app monitors and records all screenshots and recordings. Violators will face strict legal action.

DISCLAIMER

THIS IS COPYRIGHTED CONTENT. Unauthorized use, including screenshots, copying, misuse, reuse, or resale of any content from this app, is strictly prohibited. Our app monitors and records all screenshots and recordings. Violators will face strict legal action.

EXTERNAL CERVICAL RESORPTION

Treatment of ECR

- The final aim of the management strategy is to ensure that the tooth diagnosed with ECR is maintained in a healthy and functional status on the dental arch, avoiding tooth extraction, and to improve aesthetics when indicated.
- In order to maintain the affected tooth on the dental arch, in a healthy and functional status, it is necessary to properly restore the tooth, by excavating the resorptive tissue, closing of the subsequent defect and portals of entry in order to arrest the resorptive process.
- Depending on the extent of the damage, the location of the lesion and its nature, two main therapeutic strategies can be proposed:
 - i. Internal repair or/and
 - ii. external repair.
- In some of the cases, when the lesion has perforated the root canal walls or this may happen during the excavation of the resorptive process, endodontic treatment might be required as well.

THIS IS COPYRIGHTED CONTENT. Unauthorized use, including screenshots, copying, misuse, reuse, or resale of any content from this app, is strictly prohibited. Our app monitors and records all screenshots and recordings. Violators will face strict legal action.

THIS IS COPYRIGHTED CONTENT. Unauthorized use, including screenshots, copying, misuse, reuse, or resale of any content from this app, is strictly prohibited. Our app monitors and records all screenshots and recordings. Violators will face strict legal action.

THIS IS COPYRIGHTED CONTENT. Unauthorized use, including screenshots, copying, misuse, reuse, or resale of any content from this app, is strictly prohibited. Our app monitors and records all screenshots and recordings. Violators will face strict legal action.

DISCLAIMER

THIS IS COPYRIGHTED CONTENT. Unauthorized use, including screenshots, copying, misuse, reuse, or resale of any content from this app, is strictly prohibited. Our app monitors and records all screenshots and recordings. Violators will face strict legal action.

DISCLAIMER
THIS IS COPYRIGHTED CONTENT. Unauthorized use, including screenshots, copying, misuse, reuse, or resale of any content from this app, is strictly prohibited. Our app monitors and records all screenshots and recordings. Violators will face strict legal action.

MISSING CANINES AND MISSING PERMANENT TEETH

(Sources: Missing canines (ADA), Bilaterally congenitally missing maxillary canines (ADJ CASE REPORT, Bilateral agenesis of maxillary permanent canines review literature CASE REPORT)

- Hypodontia and oligodontia are both conditions related to the congenital absence of teeth (tooth agenesis), but they differ in the number of missing teeth.
- Hypodontia refers to the absence of fewer than 6 teeth (excluding third molars), while oligodontia refers to the absence of 6 or more teeth (also excluding third molars).
- A severe form of hypodontia or oligodontia refers to absence of more than six teeth, excluding third molars.
- Oligodontia is often associated with positional and morphological changes of remaining teeth as well as growth disturbances of the maxillofacial skeleton.
- The absence of permanent canines, first molars and second molars are extremely rare and often seen in association with oligodontia, in particular syndromic oligodontia.
- Early diagnosis of ectopic or missing canine is important.
- Hypodontia is often characterized by retention of deciduous teeth beyond its shedding age. 80% of individuals with hypodontia lack only one or two teeth.

Prevalence of Missing (agenesis) of permanent teeth

- The **third molars** are the most common missing teeth followed by **permanent second premolars** and **upper lateral incisors**.

teeth beyond their shedding age. Approximately, 80% of individuals with hypodontia lack only one or two teeth.^[28] Third molars are the most common missing teeth, that is, 25% of the population,^[1] followed by permanent second premolars and upper lateral incisors.^[9] The number and pattern of missing teeth

- **Hypodontia** is seen with many syndromes, but most frequently with X linked ectodermal dysplasia.
- **Oligodontia** may be associated with other ectodermal abnormalities and syndromes and consequently the treatment of these patients needs a multi-disciplinary approach.

DISCLAIMER

THIS IS COPYRIGHTED CONTENT. Unauthorized use, including screenshots, copying, misuse, reuse, or resale of any content from this app, is strictly prohibited. Our app monitors and records all screenshots and recordings. Violators will face strict legal action.

DISCLAIMER

THIS IS COPYRIGHTED CONTENT. Unauthorized use, including screenshots, copying, misuse, reuse, or resale of any content from this app, is strictly prohibited. Our app monitors and records all screenshots and recordings. Violators will face strict legal action.

MISSING CANINES AND MISSING PERMANENT TEETH

Retained Primary teeth

- The **retention** of primary tooth beyond its normal 'exfoliation date' usually can be attributed to the permanent successor (or neighboring permanent tooth) being either congenitally missing, impacted or mal-positioned
- The **deciduous maxillary canines are the most commonly reported retained deciduous tooth**, because it is more likely that a permanent canine will deviate from its normal course of eruption and become impacted.
- The **primary teeth** that have been found to be present (prolonged retention) in the order of frequency of occurrence is **maxillary canines, mandibular second molars, maxillary second molars and mandibular canines**.

Ectopic eruption of maxillary permanent canines:

- Eruption occurs in mesial and labial direction, During the eruption phase it is possible to palpate it high in the labial sulcus.

Causes of ectopic eruption of permanent maxillary canines:

- Genetic factors, bone disease, tumors, cysts, crowding and persisting deciduous canines are attributed.

Transposition is relatively rare, and can occur with first premolars and less often with lateral incisors or even less with central incisors or second premolars.

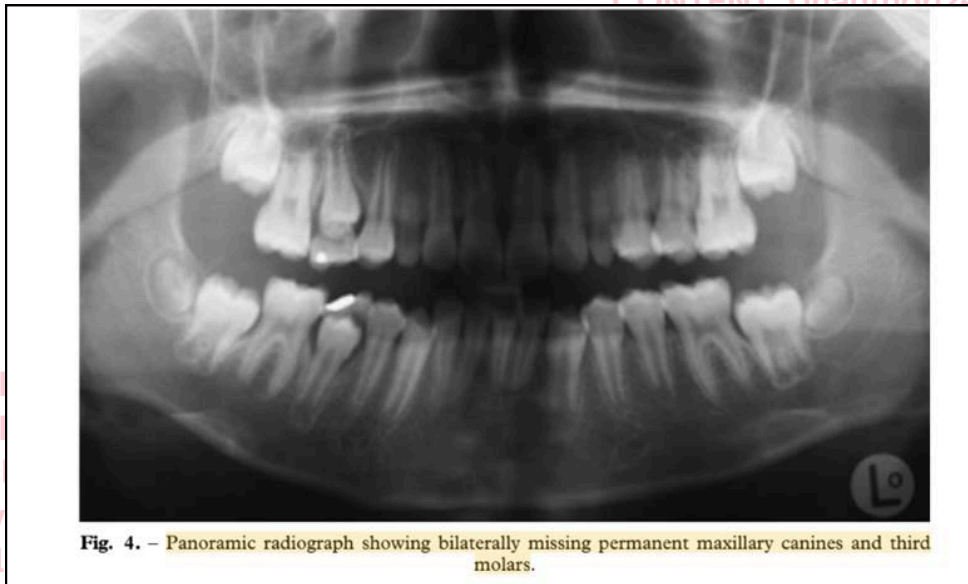

Fig. 4. – Panoramic radiograph showing bilaterally missing permanent maxillary canines and third molars.

DISCLAIMER

THIS IS COPYRIGHTED CONTENT. Unauthorized use, including screenshots, copying, misuse, reuse, or resale of any content from this app, is strictly prohibited. Our app monitors and records all screenshots and recordings. Violators will face strict legal action.

MISSING CANINES AND MISSING PERMANENT TEETH

Management of agenesis or impacted permanent canines:

- Aggenesis of permanent canines is often part of a bigger picture, including severe hypodontia and associate medical problems.
- The management option should be selected based on the most appropriate for the family at the time of presentation.
- Early radiographic investigation (by the age of 10-11 years) must be undertaken whenever there is any doubt regarding the eruption pattern of permanent canines.
- Various treatment can be proposed based on specific case history and age of presentation like:
 - a) Not to intervene at a young age like 10-11 years of age and the child's family would decide later to seek orthodontic or prosthetic treatment. (This can be considered when the family is having financial constraints during this phase)
 - b) Another option is to refer the patient to orthodontist for further management.
 - c) When there are retained deciduous canine sometimes, they can be built up to resemble permanent canines.

*Note:

- **Infant Oral Mutilation (IOM)** is a traditional practice of extracting healthy deciduous tooth germs in infant children mostly performed in sub- Saharan African Countries by village healers.

of infant children. The practice is commonly performed in sub-Saharan African countries by village healers, who view the gingival swellings in the areas most commonly corresponding to the unerupted canines as 'tooth worms' or 'nylon teeth'.²⁻⁴ It is believed that these developing teeth are responsible for symptoms such as diarrhoea, vomiting and fever among infants, and their removal is an accepted remedy.^{2,4,5}

Removal methods are typically crude, involving the use of unsterilized tools by the traditional healers, who have no formal medical training but are recognized by the community as competent to provide health care.^{2,4-6} This can lead to the transmission of infectious diseases.⁴ Despite IOM being carried out in

- It is a practice of removing developing tooth germs, commonly the mandibular canine, in infants up to age of 1 year.
- **Subsequent complications** include missing, impacted or hypoplastic permanent anterior and canine teeth.
- It is important that general dental practitioners are aware of this practice and resulting complications when treating families from sub- Saharan East Africa.

DISCLAIMER

THIS IS COPYRIGHTED CONTENT. Unauthorized use, including screenshots, copying, misuse, reuse, or resale of any content from this app, is strictly prohibited. Our app monitors and records all screenshots and recordings. Violators will face strict legal action.

DISCLAIMER
THIS IS COPYRIGHTED CONTENT. Unauthorized use, including screenshots, copying, misuse, reuse, or resale of any content from this app, is strictly prohibited. Our app monitors and records all screenshots and recordings. Violators will face strict legal action.

SPACE MAINTENANCE

(Source: Space maintenance: An overview for clinicians (Article))

- Primary teeth play an important role in aesthetics and function in the developing child.
- They also help to hold space for the permanent successors and guide them into occlusion.
- Space maintenance for early loss of primary teeth has therefore become an important part of interceptive orthodontic and pedodontics treatment.
- Common causes for premature loss of primary teeth include caries and trauma
- Changes such as mid-line shifts and dental arch length reduction can be seen in the permanent dentition as a result of early loss.
- The loss of a deciduous canine tooth is more likely to result in a mid-line shift, whereas loss of a second deciduous molar, especially if the loss occurs before nine years of age, can result in a decrease in arch length.
- The occurrence of space loss increases with time following premature extraction, with deciduous upper second molar spaces showing the greatest rate and amount of space loss.
- Primary canines and molars, when added together, take up more space in the dental arch than permanent canines and premolars. The potential space created by this size differential is defined as the leeway space.
- Maintaining leeway space can potentially prevent up to 4.3 mm of crowding (bilaterally) on eruption of the permanent dentition.
- Thus, space maintenance following early loss of deciduous teeth can help to prevent the need for future extensive fixed appliance treatment in mild to moderate crowding cases.
- Management of cases with premature loss of primary teeth often requires multidisciplinary interaction between general dental practitioners, orthodontists and pediatric dentists.

Indications for space maintenance

- Space maintenance appliances should be prescribed on an individual need basis.
- Special consideration should be given to maintaining arch length when there has been early loss of deciduous second molars, where deciduous first molars are lost before the eruption of the permanent first molars, or following unilateral loss of deciduous canines.

DISCLAIMER

THIS IS COPYRIGHTED CONTENT. Unauthorized use, including screenshots, copying, misuse, reuse, or resale of any content from this app, is strictly prohibited. Our app monitors and records all screenshots and recordings. Violators will face strict legal action.

DISCLAIMER

THIS IS COPYRIGHTED CONTENT. Unauthorized use, including screenshots, copying, misuse, reuse, or resale of any content from this app, is strictly prohibited. Our app monitors and records all screenshots and recordings. Violators will face strict legal action.

SPACE MAINTENANCE

Contraindication of space maintenance:

- When the successor tooth is close to eruption, space maintenance is not required. As an assessment guide, **for every 1 mm of bone over the permanent successor**, eruption of a premolar into the mouth will likely take **four to five months**.
- In cases of severe crowding where there may not be space for the permanent tooth even if space is held, space maintenance may not be beneficial.
- Where there has been unilateral loss of a primary canine or first molar, shifting of the midline may be a concern. This can be challenging to correct, and therefore, contralateral extraction may be advised to counteract this phenomenon.
- Space maintenance is not required for early loss of primary incisor teeth unless it is for aesthetic reasons.
- Removable appliances** are not recommended in children that are unlikely to comply with full time wear, or if the space will need to be held for an extended period of time.
- Fixed space maintaining appliances** are usually plaque retentive and may predispose to caries and periodontal problems. Hence, they are not recommended in high caries risk patients.

Types of space maintainers:

- Space maintainers can be
 - fixed or removable,
 - Unilateral or bilateral appliances.

a) Band and loop space maintainers:

- The band and loop are a unilateral fixed cantilevered space maintainer, commonly used in the posterior segments.
- It consists of a band fitted around a tooth soldered to a loop of heavy gauge stainless steel that maintains arch length.
- The appliance can be used in the maxilla or mandible, and must be wide enough Bucco-lingually to allow eruption of the permanent successor.

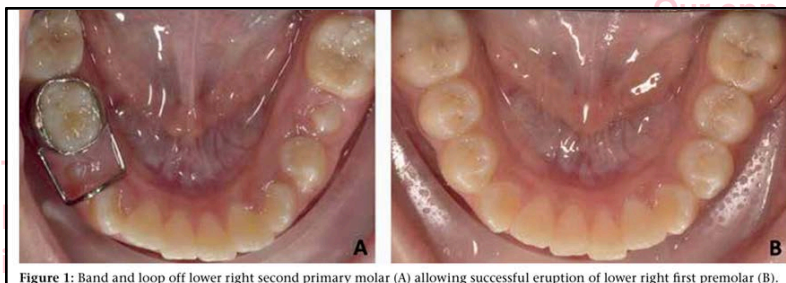


Figure 1: Band and loop off lower right second primary molar (A) allowing successful eruption of lower right first premolar (B).

- As the loop has limited strength and cannot withstand high chewing forces, the appliance should be restricted to holding the space of one tooth.
- For early loss of a primary first molar, it is useful to place the band and loop as soon as possible and also before the eruptive forces of the first permanent molar causes mesial drift of the second primary molar.
- When a second primary molar is lost early, the band and loop is usually placed on the first permanent molar.

DISCLAIMER

THIS IS COPYRIGHTED CONTENT. Unauthorized use, including screenshots, copying, misuse, reuse, or resale of any content from this app, is strictly prohibited. Our app monitors and records all screenshots and recordings. Violators will face strict legal action.

DISCLAIMER

THIS IS COPYRIGHTED CONTENT. Unauthorized use, including screenshots, copying, misuse, reuse, or resale of any content from this app, is strictly prohibited. Our app monitors and records all screenshots and recordings. Violators will face strict legal action.

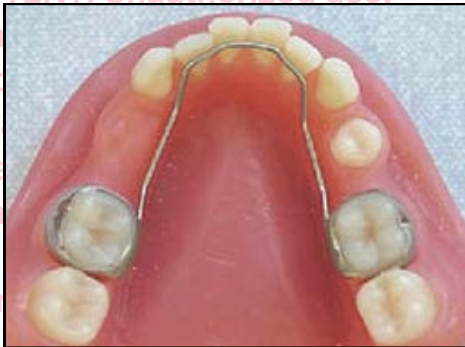SPACE MAINTENANCE

b) Crown and loop space maintainers:

- The crown and loop space maintainer are a less commonly used variation of the band and loop.
- It can be used when there is less tooth structure remaining and the tooth may benefit from a stainless-steel crown.
- A stainless-steel crown soldered with a loop to span the edentulous space is placed over the compromised tooth.

c) Lower lingual holding arch (LLHA) space maintainers:

- It is one of the most popular space maintainers used in clinical practice.
- The appliance consists of a heavy gauge stainless steel wire adapted to the lingual aspect of the mandibular arch, soldered to molar bands bilaterally.



- It is recommended that the wire contacts the cingulae of the lower permanent incisors staying 1-1.5 mm above the gingiva.
- LLHAs are an **ideal appliance** to use when there has been **bilateral loss of lower primary molars**.
- The LLHA has been shown to effectively hold arch length by preventing lingual tipping of anterior teeth and mesial movement of posterior teeth.
- As permanent incisors initially erupt lingually to their primary predecessors, a lingual arch appliance is not recommended prior to eruption of the permanent lower incisor teeth so that their eruption is not hindered.
- Common problems with the lingual arch include distortion and breakage.
- Plaque retention and caries can also occur, hence extra effort is necessary to keep the appliance clean.

d) Modified LLHAs

- A modified LLHA can be fabricated for the upper arch if the bite is not deep, otherwise lower incisal contact makes these appliances very difficult to tolerate.

DISCLAIMER

THIS IS COPYRIGHTED CONTENT. Unauthorized use, including screenshots, copying, misuse, reuse, or resale of any content from this app, is strictly prohibited. Our app monitors and records all screenshots and recordings. Violators will face strict legal action.

DISCLAIMER

THIS IS COPYRIGHTED CONTENT. Unauthorized use, including screenshots, copying, misuse, reuse, or resale of any content from this app, is strictly prohibited. Our app monitors and records all screenshots and recordings. Violators will face strict legal action.

SPACE MAINTENANCE

e) Nance palatal arch

- The Nance Palatal Arch (NPA) maintains arch length when primary molars are lost unilaterally or bilaterally in upper jaw.
- There is an acrylic button lightly contacting the palate on the most anterior and superior part of the heavy gauge trans palatal arch wire that is soldered to molar bands bilaterally.

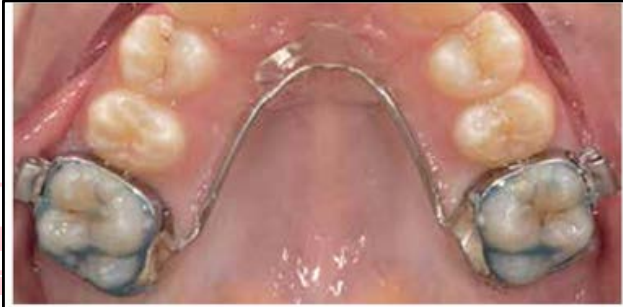

Figure 2: Nance Palatal Arch placed to allow eruption of upper first premolars.

- The acrylic button adds stability to the appliance and allows the palatal vault to be utilized as anchorage.
- The NPA can also be useful in preventing rotation and tipping of the upper permanent molars following early loss of deciduous second molars.
- One drawback of the NPA is that it has been reported to cause palatal mucosal irritation and it can be difficult to clean.

f) Trans palatal arch space maintainer:

- As with the NPA, it consists of heavy gauge stainless steel wire extending across the palate between contralateral molars. It is adapted to the curve of the palatal vault and an omega loop is usually incorporated at the midline.
- The TPA can be adjusted to maintain molars in three planes of space, and can be used for expansion or constriction via adjustment of the omega loop.
- An advantage of the TPA over the NPA is a reduction in mucosal irritation as there is no acrylic incorporated into its design.
- It is also less likely to interfere with speech or oral hygiene.

g) The Groper Fixed Anterior Bridge

- The Groper Fixed Anterior Bridge can be used when anterior teeth have been lost and aesthetics is a concern.
- This appliance consists of a lingual arch wire attached to bands on the deciduous second molars.
- Replacement anterior teeth are attached to the wire.

DISCLAIMER

THIS IS COPYRIGHTED CONTENT. Unauthorized use, including screenshots, copying, misuse, reuse, or resale of any content from this app, is strictly prohibited. Our app monitors and records all screenshots and recordings. Violators will face strict legal action.

DISCLAIMER

THIS IS COPYRIGHTED CONTENT. Unauthorized use, including screenshots, copying, misuse, reuse, or resale of any content from this app, is strictly prohibited. Our app monitors and records all screenshots and recordings. Violators will face strict legal action.

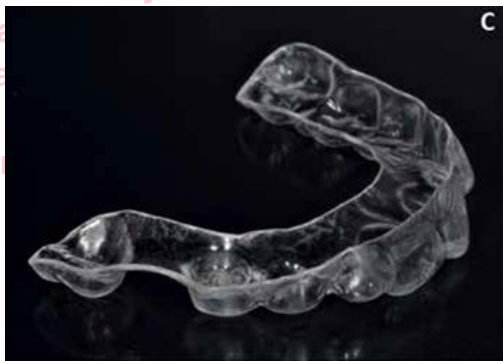SPACE MAINTENANCE

h) Partial denture

- A partial denture is commonly used when there is early loss of an incisor, if teeth have been lost on both sides of the arch, or when a band and loop space maintainer cannot span the required length of the edentulous space.
- The partial denture is also useful because it can replace occlusal function when multiple teeth are missing. As early loss of a primary incisor is not an indicator for space maintenance, partial dentures are placed in these situations solely to improve appearance.
- Adjustment is required as permanent teeth erupt.

i) Vacuum formed retainers (VFRs)

- They are a commonly used type of removable space maintainer.
- Usually, night time wear is sufficient to prevent drifting of adjacent teeth and resulting space loss.
- VFRs are clear sheets of plastic which are heated and adapted to stone models of a patient's teeth using a vacuum machine.



- These space maintainers are inexpensive to make and easy to replace as other teeth are lost or begin erupting and displace the retainer.

Advantages and disadvantages of removeable and fixed space maintainers:

- Oral hygiene management is more difficult with fixed space maintainers than removable types.
- However, fixed options decrease the need for patient compliance, and usually have a greater acceptance due to decreased bulk and speech alterations compared to their removable equivalents.
- Speech disturbances from removable appliances tend to be short lived, however, with significant or complete resolution by the seventh day of wear.

DISCLAIMER

THIS IS COPYRIGHTED CONTENT. Unauthorized use, including screenshots, copying, misuse, reuse, or resale of any content from this app, is strictly prohibited. Our app monitors and records all screenshots and recordings. Violators will face strict legal action.

DISCLAIMER

THIS IS COPYRIGHTED CONTENT. Unauthorized use, including screenshots, copying, misuse, reuse, or resale of any content from this app, is strictly prohibited. Our app monitors and records all screenshots and recordings. Violators will face strict legal action.

SPACE MAINTENANCE

Median survival rates of space maintainers:

- Various studies have been conducted.

Table 1: Median survival time of various space maintainers according to Qudeimat and Fayle (1998)

Space Maintainer	Median Survival Time
Lower lingual holding arch	4 months
Nance appliance	6 months
Removable partial denture	9 months
Band and loop	13 months

THIS IS COPYRIGHTED CONTENT. Unauthorized use, including screenshots, copying, misuse, reuse, or resale of any content from this app, is strictly prohibited. Our app monitors and records all screenshots and recordings. Violators will face strict legal action.

THIS IS COPYRIGHTED CONTENT. Unauthorized use, including screenshots, copying, misuse, reuse, or resale of any content from this app, is strictly prohibited. Our app monitors and records all screenshots and recordings. Violators will face strict legal action.

THIS IS COPYRIGHTED CONTENT. Unauthorized use, including screenshots, copying, misuse, reuse, or resale of any content from this app, is strictly prohibited. Our app monitors and records all screenshots and recordings. Violators will face strict legal action.

THIS IS COPYRIGHTED CONTENT. Unauthorized use, including screenshots, copying, misuse, reuse, or resale of any content from this app, is strictly prohibited. Our app monitors and records all screenshots and recordings. Violators will face strict legal action.

DISCLAIMER

THIS IS COPYRIGHTED CONTENT. Unauthorized use, including screenshots, copying, misuse, reuse, or resale of any content from this app, is strictly prohibited. Our app monitors and records all screenshots and recordings. Violators will face strict legal action.

DISCLAIMER
THIS IS COPYRIGHTED CONTENT. Unauthorized use, including screenshots, copying, misuse, reuse, or resale of any content from this app, is strictly prohibited. Our app monitors and records all screenshots and recordings. Violators will face strict legal action.

LATERAL CEPHALOGRAM


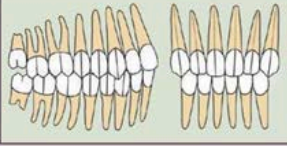
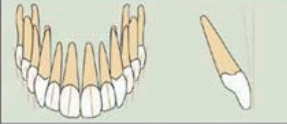



(CLASSIFICATION OF MALOCCLUSION)

(Source- Handbook of Orthodontics (Martyn and Andrew))

- Malocclusion can be defined as an appreciable deviation from the ideal that may be considered aesthetically or functionally unsatisfactory.

Classification of malocclusion

- Angle classified occlusion according to the molar relationship and this remains the most internationally recognized classification of malocclusion.
- When looking at ideal occlusion, Angle found that the mesio-buccal cusp of the upper first permanent molar should occlude with the sulcus between the mesial and distal buccal cusps of the lower first permanent molar. He therefore based his classification of occlusion on this relative mesiodistal position.
- Andrews six 6 keys of occlusion includes:

Box 1.2 Andrews Six Keys of Occlusion		
KEY 1		Key 1 Molar relationship - the distal surface of the distal marginal ridge of the upper first permanent molar occludes with the mesial surface of the mesial marginal ridge of the lower second molar. The mesio-buccal cusp of the upper first permanent molar falls within the groove between the mesial and middle cusps of the lower first permanent molar
KEY 2		Key 2 Crown angulation or mesio-distal tip - the gingival portion of the long axis of each tooth crown is distal to the occlusal portion of that axis. The degree of tip varies with each tooth type
KEY 3		Key 3 Crown inclination or labio-lingual/bucco-lingual torque - for the upper incisors the occlusal portion of the crowns labial surface is labial to the gingival portion. In all other crowns, the occlusal portion of the labial or buccal surface is lingual to the gingival portion
KEY 4		Key 4 Rotations - there should be an absence of any tooth rotations within the dental arches
KEY 5		Key 5 Spacing - there should be an absence of any spacing within the dental arches
KEY 6		Key 6 Occlusal plane - the occlusal plane should be flat

this app, is strictly prohibited. Our app monitors and records all screenshots and recordings. Violators will face strict legal action.

DISCLAIMER

THIS IS COPYRIGHTED CONTENT. Unauthorized use, including screenshots, copying, misuse, reuse, or resale of any content from this app, is strictly prohibited. Our app monitors and records all screenshots and recordings. Violators will face strict legal action.

DISCLAIMER

THIS IS COPYRIGHTED CONTENT. Unauthorized use, including screenshots, copying, misuse, reuse, or resale of any content from this app, is strictly prohibited. Our app monitors and records all screenshots and recordings. Violators will face strict legal action.

LATERAL CEPHALOGRAM

(CLASSIFICATION OF MALOCCLUSION)

1) Angles Class I malocclusion:

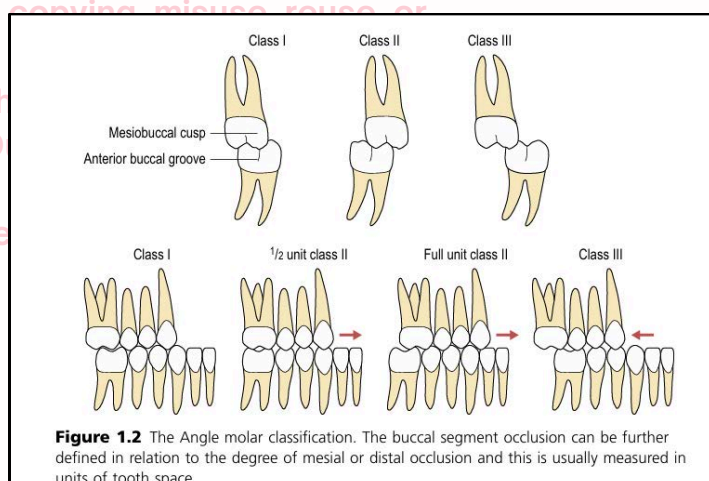
- The position of the dental arches is normal, with first molars in normal occlusion.

2) Angles Class II malocclusion:

- The relations of the dental arches are abnormal, with all the mandibular teeth occluding distal to normal.
- Angle recognized two subdivisions under class II:
 - Class II division 1—upper incisors are protruding
 - Class II division 2—upper incisors are lingually inclined.

3) Angles Class III malocclusion:

- The relations of the dental arches are also abnormal, with all mandibular teeth occluding mesial to normal.



Lateral cephalometric analysis:

- Cephalometric radiography is a specialized radiographic technique concerned with imaging the craniofacial region in a standardized and reproducible manner.
- This assessment can provide detailed information on the relationship of skeletal, dental and soft tissue elements within the craniofacial region.
- Information on the relationship of the jaws and dentition in both the anteroposterior and vertical planes of space and their relationship with the soft tissue profile is an important factor in orthodontic diagnosis and treatment planning.
- A detailed analysis of the dentoskeletal relationship aids in treatment planning and determining the appropriate treatment approach.
- Cephalometric analysis can provide the orthodontist with much useful clinical information.
- A cephalometric analysis should supplement a thorough clinical examination and not attempt to replace it.

DISCLAIMER

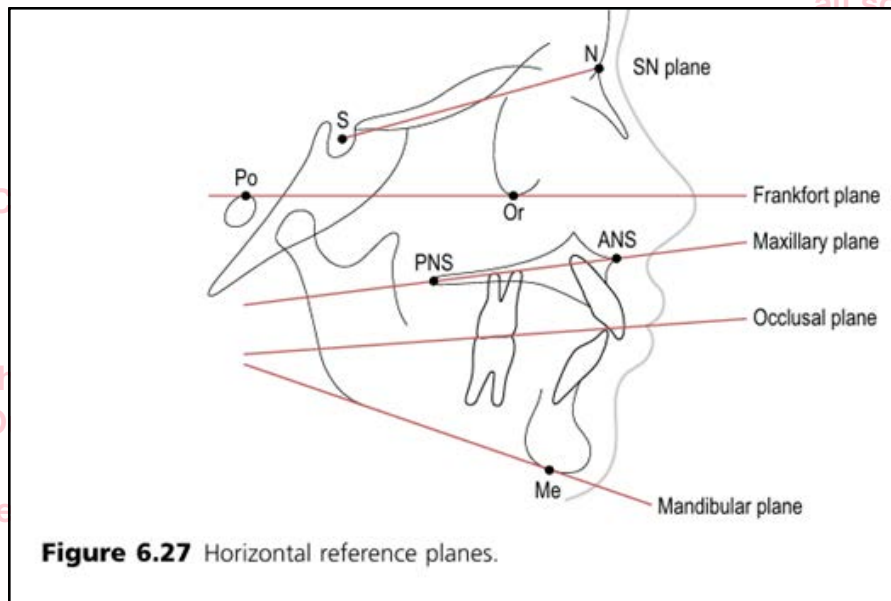
THIS IS COPYRIGHTED CONTENT. Unauthorized use, including screenshots, copying, misuse, reuse, or resale of any content from this app, is strictly prohibited. Our app monitors and records all screenshots and recordings. Violators will face strict legal action.

LATERAL CEPHALOGRAM (CLASSIFICATION OF MALOCCLUSION)

Tracing of lateral Cephalometric radiograph:

A) Horizontal reference planes:

- A number of horizontal planes are commonly used as references in the construction of other measurements or they are related to each other within a cephalometric analysis.



These include:

1) Frankfort horizontal plane

- The Frankfort plane is a horizontal reference constructed as a line through porion to orbitale, which can be used both clinically and cephalometrically to orientate the head.

2) Sella-nasion plane

- The Sella-nasion (SN) plane is constructed as a line extending from Sella to nasion and represents the anteroposterior extent of the anterior cranial base
- It is commonly used as a reference plane because of its reliability.

3) Maxillary plane

- The maxillary plane is constructed using a line connecting the anterior and posterior nasal spines, and serves as a horizontal reference for the maxilla.

4) Occlusal plane

- The occlusal plane is constructed using a line connecting the tip of the lower incisor edges to the midpoint between the upper and lower first permanent molar cusps.

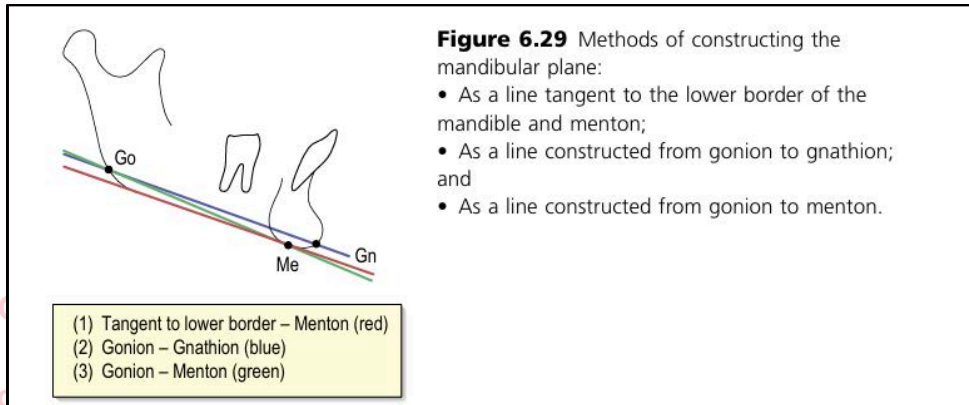
DISCLAIMER

THIS IS COPYRIGHTED CONTENT. Unauthorized use, including screenshots, copying, misuse, reuse, or resale of any content from this app, is strictly prohibited. Our app monitors and records all screenshots and recordings. Violators will face strict legal action.

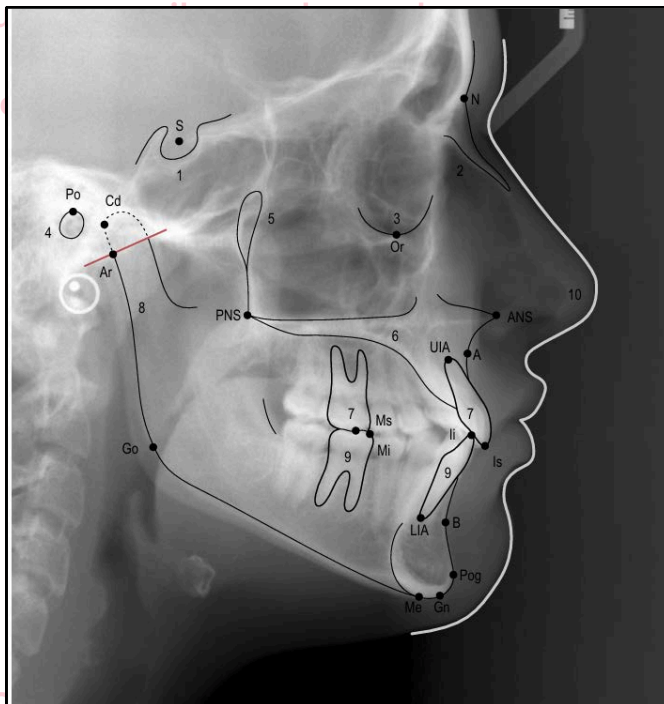
LATERAL CEPHALOGRAM (CLASSIFICATION OF MALOCCLUSION)

5) Mandibular plane

- The mandibular plane serves as a horizontal reference line for the mandible and can be constructed using several methods.



- A lateral cephalogram showing important landmarks:



including screenshots,
copying, misuse, reuse, or
resale of any content from
this app, is strictly prohibited.
Our app monitors and records
all screenshots and
recordings. Violators will face
strict legal action.

DISCLAIMER

THIS IS COPYRIGHTED CONTENT. Unauthorized use, including screenshots, copying, misuse, reuse, or resale of any content from this app, is strictly prohibited. Our app monitors and records all screenshots and recordings. Violators will face strict legal action.

DISCLAIMER

THIS IS COPYRIGHTED CONTENT. Unauthorized use, including screenshots, copying, misuse, reuse, or resale of any content from this app, is strictly prohibited. Our app monitors and records all screenshots and recordings. Violators will face strict legal action.

THIS IS COPYRIGHTED
CONTENT. Unauthorized use,
including screenshots,
copying, misuse, reuse, or
resale of any content from
this app, is strictly prohibited.
Our app monitors and records
all screenshots and
recordings. Violators will face
strict legal action.

LATERAL CEPHALOGRAM

(CLASSIFICATION OF MALOCCLUSION)

Important Landmarks:

- Sella (S): the midpoint of the sella turcica (pituitary fossa).
- Nasion (N): the most anterior point on the frontonasal suture in the midline.
- Porion (Po): the upper- and outer-most point on the external auditory meatus.
- Orbitale (Or): the most inferior and anterior point on the orbital margin.
- Condylion (Cd): the most posterior and superior point on the mandibular condyle.
- Articulare (Ar): the point of intersection of the posterior margin of the ascending mandibular ramus and the outer margin of the posterior cranial base.
- Gnathion (Gn): the most anterior and inferior point on the bony chin.
- Menton (Me): the most inferior point of the mandibular symphysis in the midline.
- Pogonion (Pog): the most anterior point on the bony chin.
- Gonion (Go): the most posterior and inferior point on the angle of the mandible.
- Point A (Subspinale): The deepest point on the curved profile of the maxilla between the anterior nasal spine and alveolar crest.
- Point B (Supramentale): the deepest point on the curved profile of the mandible between the chin and alveolar crest.
- Anterior nasal spine (ANS): the tip of the bony anterior nasal spine in the midline.
- Posterior nasal spine (PNS): the tip of the posterior nasal spine in the midline (located as a continuation of the base of the pterygopalatine fossa where it intersects with the nasal floor).

Assessing the anteroposterior skeletal relationship.

- A number of methods for assessing the anteroposterior jaw relationship have been proposed.

A) The ANB angle

- The ANB angle provides a relatively simple and commonly used assessment of anteroposterior jaw relations.
- The SN plane represents the anterior cranial base, whilst points A and B represent the anterior surfaces of the maxillary and mandibular apical bases, respectively.

a) The anteroposterior position of the maxilla is calculated by measuring the angle SN to point A (SNA) ($81^\circ \pm 3^\circ$)

b) The anteroposterior position of the mandible is calculated by measuring the angle SN to point B (SNB) ($78^\circ \pm 3^\circ$)

c) The relative difference in the anteroposterior relationship of the maxilla and mandible is measured by the difference between the SNA and SNB angles, or ANB angle ($3^\circ \pm 2^\circ$).

DISCLAIMER

THIS IS COPYRIGHTED CONTENT. Unauthorized use, including screenshots, copying, misuse, reuse, or resale of any content from this app, is strictly prohibited. Our app monitors and records all screenshots and recordings. Violators will face strict legal action.

LATERAL CEPHALOGRAM (CLASSIFICATION OF MALOCCLUSION)

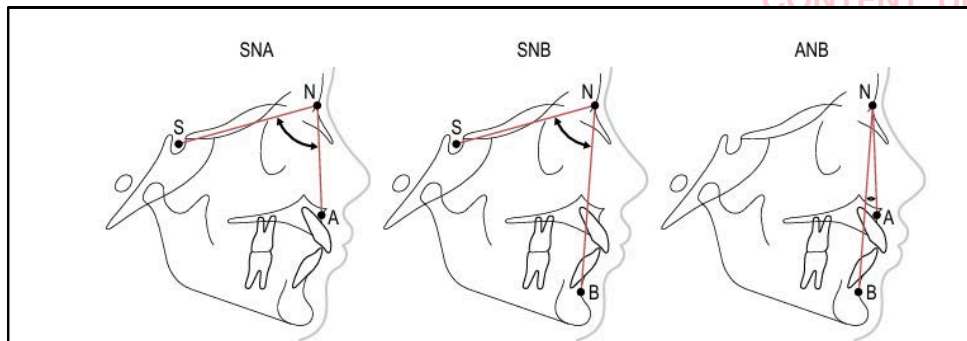
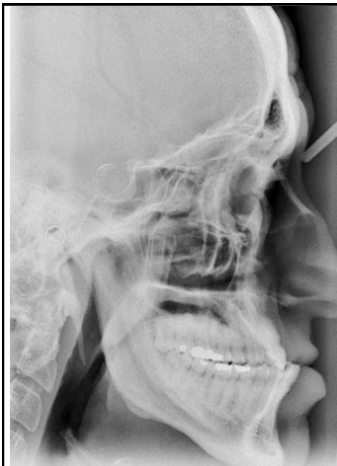

Figure 6.30 SNA, SNB and ANB angles.

Table 6.3 Classification of anteroposterior skeletal pattern using the ANB angle

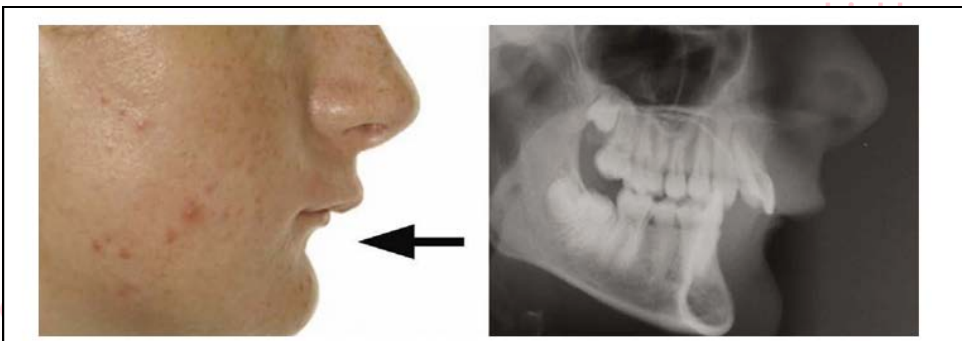Skeletal class	ANB angle
Class I	2–4°
Class II	> 4°
Class III	< 2°

Some examples:



1) malocclusion in an adult.

Fig: Lateral skull radiograph showing a class III malocclusion in an adult.



2) Fig: Fig: Class II Div 1.

DISCLAIMER

THIS IS COPYRIGHTED CONTENT. Unauthorized use, including screenshots, copying, misuse, reuse, or resale of any content from this app, is strictly prohibited. Our app monitors and records all screenshots and recordings. Violators will face strict legal action.

DISCLAIMER

THIS IS COPYRIGHTED CONTENT. Unauthorized use, including screenshots, copying, misuse, reuse, or resale of any content from this app, is strictly prohibited. Our app monitors and records all screenshots and recordings. Violators will face strict legal action.

DIASTEMA AND DEEP BITE MANAGEMENT

Sources: (Deep overbite—A review, Management of maxillary midline diastema with emphasis on etiology, Labial frenectomy: current clinical practice of orthodontists in the United Kingdom)

- The maxillary midline diastema is one of the dentoalveolar disorders that cause special concern to parents and patients, specifically given its position.
- Among five-year old children, during the period of primary dentition, maxillary midline diastema appears in 97% of cases along with primate spaces, this predicts a future development of the mixed and permanent dentition without crowding.
- The presence of maxillary midline diastema is a normal characteristic in the development of the stomatognathic system in the mixed dentition period, especially in the initial phase of the eruption of permanent maxillary central incisors (“ugly duckling” stage). This is self-correcting with the eruption of canines.
- The clinician should evaluate various parameters, including patient’s age and stage of growth, in order to define the final diagnosis.
- Before the adoption of any treatment plan, it is crucial to precisely determine if there is “actual” need for treatment and Treatment timing primarily depends on the cause of the problem and must always be individualized.
- The ideal option is the one that addresses the diastema, along with the cause of the problem.

Etiology of midline diastema and management with cause

1) Imperfect fusion at midline of premaxilla

- The existing gap is occupied by connective and epithelial tissue, while fibers of the maxillary labial frenum or gingival fibers (especially interdental) are often inserted and attached in that site.
- The final diagnosis of an imperfect fusion must be based on a radiograph.

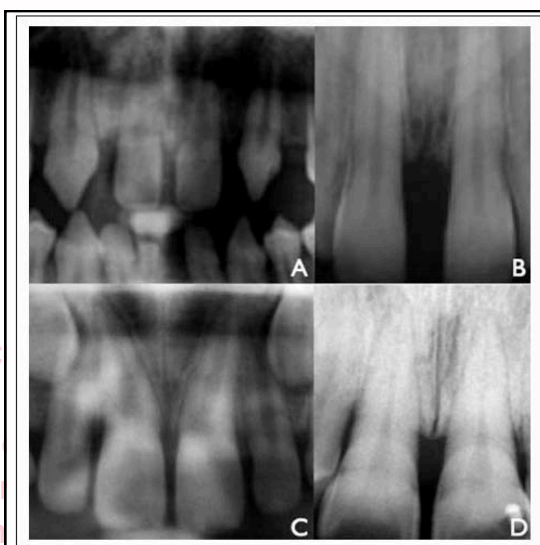

Figure 1. A—A normal V-shaped bone structure slightly bisected by the intermaxillary suture. The diastema is due to congenital absence of lateral incisors B—Abnormal, W-shaped, alveolar process between the maxillary central incisors. C—Abnormal suture wider than normal. D—Abnormal, spade-shaped, alveolar process between the maxillary central incisors.

DISCLAIMER

THIS IS COPYRIGHTED CONTENT. Unauthorized use, including screenshots, copying, misuse, reuse, or resale of any content from this app, is strictly prohibited. Our app monitors and records all screenshots and recordings. Violators will face strict legal action.

DISCLAIMER

THIS IS COPYRIGHTED CONTENT. Unauthorized use, including screenshots, copying, misuse, reuse, or resale of any content from this app, is strictly prohibited. Our app monitors and records all screenshots and recordings. Violators will face strict legal action.

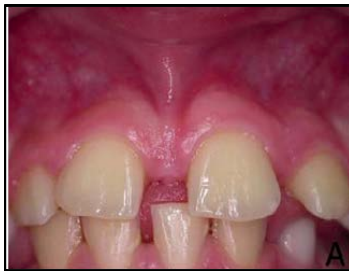DIASTEMA AND DEEP BITE MANAGEMENT

Treatment:

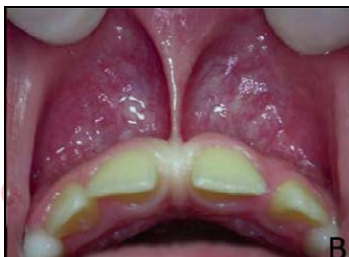- Treatment is based on surgical excision of the fibers attached to the residual suture by proceeding with an osteotomy along the intermaxillary suture.
- This intervention must be performed after the orthodontic closure of the diastema, in order for tissue healing and fiber remodeling to occur in the new position of the teeth.
- In cases where relapse occurs, the same procedure must be repeated.
- Moreover, when the imperfect fusion makes the diastema closure impossible, the surgery must be performed before the closure of the diastema.

2) Hypertrophic or malposed upper labial frenum

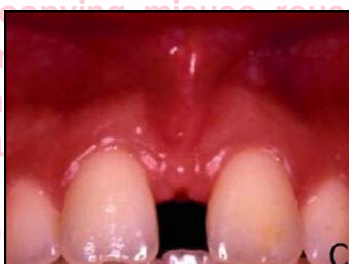- There is remarkable consensus among scientists concerning the existence of a cause-effect relationship between the presence of hypertrophic or malposed maxillary labial frenum and the maxillary midline diastema.
- But the cause-effect relationship between the abnormal labial frenum or the imperfect fusion at midline of pre maxilla and the maxillary midline diastema needs to be further investigated.
- When frenum fibers are inserted quite deeply, the presence of an abnormal labial frenum can be diagnosed by observation alone or by stretching the upper lip and observing the ischemia caused to the interdental papilla.
- Miller recommended that the frenum should be characterized as pathologic when it is unusually wide or there is no apparent zone of attached gingiva along the midline.



A) Diagnosis by observation alone



B) Diagnosis of an abnormal labial frenum by stretching the upper lip and observing the ischemia caused to the interdental papilla.



C) Diagnosis of an abnormal labial frenum by observation of an unusually wide frenum, with no apparent zone of attached gingiva along the midline.

DISCLAIMER

THIS IS COPYRIGHTED CONTENT. Unauthorized use, including screenshots, copying, misuse, reuse, or resale of any content from this app, is strictly prohibited. Our app monitors and records all screenshots and recordings. Violators will face strict legal action.

DISCLAIMER

THIS IS COPYRIGHTED CONTENT. Unauthorized use, including screenshots, copying, misuse, reuse, or resale of any content from this app, is strictly prohibited. Our app monitors and records all screenshots and recordings. Violators will face strict legal action.

DIASTEMA AND DEEP BITE MANAGEMENT

2) Hypertrophic or malposed upper labial frenum

- However, evaluating the frenum (normal or pathologic) is sometimes rather difficult, especially in borderline cases. All clinical data should be assessed in relation to patient's age, as well as to other parameters relevant to the problem.

Treatment:

- The management of this specific condition initially involves the orthodontic closure of the diastema. Then, the frenum must be surgically removed and the orthodontic appliances must be retained in place during healing. By choosing this approach, the tissue expected to form in the new position will help retain the result of treatment.
- Nevertheless, occasionally, when the frenum is particularly hypertrophic and inhibits the orthodontic closure of the diastema, it is necessary to surgically reposition the frenum nasally before the end of orthodontic treatment.
- **Both the approaches are followed.**
- The above options must be performed only when the diastema persists after the eruption of permanent canines, as, in most cases, the eruption of the canines leads to spontaneous closure of the maxillary midline diastema.

3) Diastema as part of normal development:

- Permanent maxillary central incisors can normally erupt with a diastema that will be reduced in size with the eruption of the lateral incisors and will completely disappear with the eruption of the canines.

4) Congenitally missing lateral incisors:

- In these cases, the maxillary central incisors tend to occupy the existing space and move distally resulting in local spacing in the maxillary anterior region.
- Early diagnosis of the congenital absence, based on a radiograph examination, is a matter of great importance for the progress of these cases.
- The diastemas due to congenital absence of lateral incisors can be treated orthodontically with closure of the diastema and proper guidance of the canines to the position of the missing lateral incisors and of the posterior teeth mesially.

5) Supernumerary teeth at the midline:

- A mesiodens is usually interposed between the roots of the maxillary central incisors and does not allow them to move to the midline and close the diastema.
- When supernumerary teeth are normally orientated, they are more likely to cause a delayed eruption of permanent teeth, while when they are inverted, they usually cause bodily displacement of the permanent incisors, torsion and midline diastema.
- Diagnosis is exclusively based on the radiographic examination, unless the mesiodens has erupted.
- **Treatment involves the removal of the supernumerary tooth as soon as diagnosed**, without causing injury to the adjacent teeth.

DISCLAIMER

THIS IS COPYRIGHTED CONTENT. Unauthorized use, including screenshots, copying, misuse, reuse, or resale of any content from this app, is strictly prohibited. Our app monitors and records all screenshots and recordings. Violators will face strict legal action.

DISCLAIMER

THIS IS COPYRIGHTED CONTENT. Unauthorized use, including screenshots, copying, misuse, reuse, or resale of any content from this app, is strictly prohibited. Our app monitors and records all screenshots and recordings. Violators will face strict legal action.

DIASTEMA AND DEEP BITE MANAGEMENT

5) Supernumerary teeth at the midline:

- Often, timely removal of the impediment allows central incisors eruption forces to close the diastema, without any further intervention. If this does not occur, then the diastema is usually corrected by using orthodontic forces.

Frenectomy as a treatment option in cases of midline diastema where the cause is abnormal frenal attachment

- Firstly, the diagnosis of abnormal frenal attachment is necessary.
- Diagnostic tests that help to identify an abnormal frenum include:
 - Blanch test:** It is clinical examination of assessing blanching of the mucogingival tissues palatal to the maxillary central incisors when pulling the upper lip away
 - Intraoral radiograph:** To assess the presence of a midline bony cleft.
- When abnormal frenal attachment is the cause frenectomy should always be done as a part of the treatment in conjunction with orthodontic closure of midline diastema.
- The timing of frenectomy can be:
 - Before starting orthodontic treatment
 - Just before diastema closure
 - After diastema closure
- The rationale for closure of median diastema prior to frenectomy is to improve the stability of space closure by consolidating the teeth with scar tissues forming around the surgical site.
- The rationale for frenectomy before commencing closure of median diastema, especially where the frenum is thick and bulky, is that space closure may cause discomfort and it is suggested that the frenum resists mesial pressure, and frenectomy before orthodontic closure could lead to faster tooth movement.
- Frenectomy should be accompanied by orthodontic space closure and is not recommended before the eruption of permanent canines.
- For the retention of the treatment following frenectomy and space closure, Long-term retention with a bonded retainer supplemented with a vacuum-formed retainer is recommended regardless of whether a frenectomy has been performed.
- The most preferred timing of frenectomy was after diastema closure followed by just before space closure based on a study.

DISCLAIMER

THIS IS COPYRIGHTED CONTENT. Unauthorized use, including screenshots, copying, misuse, reuse, or resale of any content from this app, is strictly prohibited. Our app monitors and records all screenshots and recordings. Violators will face strict legal action.

DISCLAIMER

THIS IS COPYRIGHTED CONTENT. Unauthorized use, including screenshots, copying, misuse, reuse, or resale of any content from this app, is strictly prohibited. Our app monitors and records all screenshots and recordings. Violators will face strict legal action.

DIASTEMA AND DEEP BITE MANAGEMENT

Deep Bite:

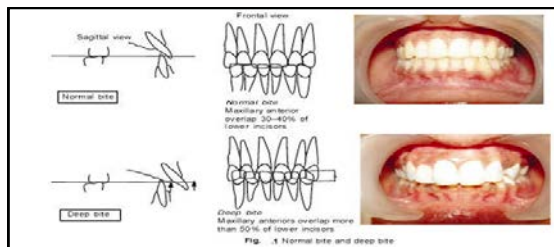
- Deep bite is one of the frequently seen malocclusions next to crowding.
- It can occur along with other associated malocclusions and is one of the most perpetuating and damaging malocclusions that can jeopardize the periodontal support, occlusion itself or TMJ.
- The **deep over bite or deep bite** can be defined by the excess amount or percentage of overlap of the lower incisors by the upper incisors.
- Deep bite (or deep overbite) is present when the mandibular incisors occlusal edges occlude apical to the cingulum of the maxillary incisors.
- This may be due to overeruption of either the maxillary or mandibular anterior.
- The term "**closed bite**" describes condition of excessive overbite, where the vertical measurement between the maxillary and mandibular incisal margins is excessive when the mandible brought into habitual or centric occlusion. Closed bite is excessive overbite resulting from loss of posterior teeth.
- Excessive overbite is most prevalent in the mixed dentition and is a self-correcting transient malocclusion.

Classification

1) According to its origin

i. Dental deep bites (Simple)

- Dental deep bites occur due to over-eruption of anterior or infra occlusion of molars.



ii. Skeletal deep bite (Complex)

- Complex deep bite is a deep bite associated with basic skeletal features with which the alveolar process cannot cope.

2) According to Function:

i. True Deep bite:

- This is caused by infra-occlusion of the posterior segments i.e., molars.
- Seen in class II div II.

ii. Pseudo Deep bite:

- It is caused by overeruption of the anterior teeth that already has normal eruption of posterior segment teeth.
- Seen in class II div I malocclusions.

DISCLAIMER

THIS IS COPYRIGHTED CONTENT. Unauthorized use, including screenshots, copying, misuse, reuse, or resale of any content from this app, is strictly prohibited. Our app monitors and records all screenshots and recordings. Violators will face strict legal action.

DISCLAIMER

THIS IS COPYRIGHTED CONTENT. Unauthorized use, including screenshots, copying, misuse, reuse, or resale of any content from this app, is strictly prohibited. Our app monitors and records all screenshots and recordings. Violators will face strict legal action.

DIASTEMA AND DEEP BITE MANAGEMENT

Management of deep overbite:

- The extent of the intermaxillary distance "freeway space" is an important factor in treatment planning.
- When the freeway space is minimal or even absent the problem is more severe.

Treatment modalities in growing and non growing patients

1) Growing patients

- Intrude anterior
- Erupt posteriors
- Combination of posterior eruption and anterior intrusion

2) Non growing patients (little or no growth expected)

- Orthognathic surgery
- Intrusion of anterior (posterior extrusion invariably relapses)

- Whatever the treatment modality the management of deep bite is by intrusion of anterior, extrusion of posteriors or combination of the both.

a) Intrusion of anteriors:

- Deep bite with large interlabial gap (In a relaxed mandibular position, an individual has normal of 2 to 4 mm), intrusion is the ideal choice. Here, Extrusion of posteriors may deteriorate the esthetics and further increase the interlabial gap.
- If the distance between the incisal edge of the maxillary central incisor to the lower most border of the upper lip is large (an average or normal of 2 to 4 mm) associated with a high smile line or "gummy smile", the best method of treating a deep overbite may be by intrusion of the upper incisors.
- In a Class II, division 1 type of malocclusion with large vertical facial height, extrusion of posterior teeth may cause serious functional, esthetic, and stability problems. Extrusion of molar further causes the downward and backward rotation of the mandible worsening the condition. In those cases, the intrusion of anteriors is the treatment option.
- Intrusion mechanics are considered if there is inadequate or normal freeway space. Encroachment of this space by extrusion of posterior teeth is determinant and bound to relapse.

DISCLAIMER

THIS IS COPYRIGHTED CONTENT. Unauthorized use, including screenshots, copying, misuse, reuse, or resale of any content from this app, is strictly prohibited. Our app monitors and records all screenshots and recordings. Violators will face strict legal action.

DISCLAIMER
THIS IS COPYRIGHTED CONTENT. Unauthorized use, including screenshots, copying, misuse, reuse, or resale of any content from this app, is strictly prohibited. Our app monitors and records all screenshots and recordings. Violators will face strict legal action.

DIASTEMA AND DEEP BITE MANAGEMENT

b) Extrusion of molars:

- In deep bite with redundant upper and /or lower lips, or no interlabial gap, posterior extrusive mechanics may be desirable.
- If the distance between the incisal edge of the maxillary central incisor to the lower most border of the upper lip is normal then the choice of correction of deep bite by an intrusion of maxillary incisors is often contraindicated since it will give the patient an edentulous appearance. Extrusion of posteriors is the treatment option.
- In patients having excessive overbite with Class II, division 2 type of skeletal malocclusion, an extrusion of the posterior teeth may be the treatment of choice.
- Extrusion mechanics are considered if there is adequate interocclusal space.

Treatment planning in different age groups:

a) Treatment planning in primary dentition

- Both deep bite and open bite malocclusion occur in the primary dentition.
- Open bite is more common. Anterior deep bites in the primary dentition are fairly common but are rarely treated.
- Indications for treatment in the primary dentition include impingement on the palatal mucosa, excessive grinding, clenching, and headaches if they are believed to be secondary to the deep bite

b) Treatment planning for mixed dentition

- The overbite is greater just after eruption of the prominent incisors and decreases with eruption of the posterior teeth.
- If the skeletal bases are class I with normal incisor angulation, it is better to wait and watch till the eruption of the posterior teeth which results in resolution of deep bite.
- Early childhood is the best time to treat complex deep bite.
- Functional jaw orthopedic appliances can then guide the eruption of the permanent dentition upper molars, while eruption can be manipulated with and help control vertical skeletal growth.
- Cervical headgear produces more eruption of the upper molars and with functional appliance either the upper or lower molars erupt more.
- Deep bites with anterior vertical maxillary excess showing gummy smiles can be intercepted by high pull headgears.
- Class I skeletal deep bites with horizontal growth pattern can also be intercepted with the myofunctional appliances

DISCLAIMER

THIS IS COPYRIGHTED CONTENT. Unauthorized use, including screenshots, copying, misuse, reuse, or resale of any content from this app, is strictly prohibited. Our app monitors and records all screenshots and recordings. Violators will face strict legal action.

DISCLAIMER

THIS IS COPYRIGHTED CONTENT. Unauthorized use, including screenshots, copying, misuse, reuse, or resale of any content from this app, is strictly prohibited. Our app monitors and records all screenshots and recordings. Violators will face strict legal action.

DIASTEMA AND DEEP BITE MANAGEMENT

Treatment planning in different age groups:

c) Treatment planning for early permanent dentition

- Comprehensive orthodontic treatment is usually required to treat the cases of deep bite.
- In cases of simple dental deep bites and when there is a normal interocclusal distance in the mandibular postural position, treatment by arch leveling mechanics alone may be possible.

d) Treatment planning in adults

- In adult patient showing excessive deep overbite with accompanying, high smile line, decreased vertical facial height and alveolar problems, the length of treatment may be very long.
- In this instance, the patient should be given a choice for an Orthognathic correction of the problem.
- In these patients, the treatment plan to correct the excessive overbite should be done in conjunction with an oral-maxillofacial surgeon.

Deep bites can be treated using removable, fixed or myofunctional appliances.

THIS IS COPYRIGHTED CONTENT. Unauthorized use, including screenshots, copying, misuse, reuse, or resale of any content from this app, is strictly prohibited. Our app monitors and records all screenshots and recordings. Violators will face strict legal action.

THIS IS COPYRIGHTED CONTENT. Unauthorized use, including screenshots, copying, misuse, reuse, or resale of any content from this app, is strictly prohibited. Our app monitors and records all screenshots and recordings. Violators will face strict legal action.

INVISALIGN

- Orthodontic aligners have revolutionized the field of orthodontics, providing an aesthetically pleasing and comfortable solution for the treatment of malocclusions.
- In recent years, there has been a growing interest in the use of aligners in growing patients, including those with mixed and primary dentition.
- Mixed dentition represents a pivotal moment in the oral development of pediatric patients, characterized by the coexistence of primary and permanent teeth. This phase, which generally occurs between the ages of 6 and 12, is crucial for early diagnosis and orthodontic intervention to prevent or correct occlusal and functional anomalies
- In recent decades, orthodontics has witnessed significant advancements in techniques and materials, among which clear aligners stand out.
- Clear aligners offer an esthetic and less invasive solution compared to traditional fixed appliance.
- The popularity of aligners is growing, especially among young patients seeking a less invasive and more aesthetically pleasing option.
- However, the application of aligners in growing patients remains relatively unexplored, with studies focused predominantly on adolescents and adults.

a) Early Benefits and Challenges of Early Orthodontic Treatment with Aligners

- Conditions such as posterior crossbite, Class III dentoskeletal issues, impacted teeth, and excessive overjet can all benefit from interceptive treatment.
- The primary aim of early treatment is to establish a conducive growth environment, enhancing aesthetics and minimizing future complexities.
- Early orthodontic treatment effectively addresses interceptive orthodontic issues in growing patients.
- However, treatment success is significantly influenced by complexity, with more challenging corrections necessitating additional aligners.

b) Impact of Aligners on Gingival and Periodontal Modifications:

- Orthodontic interventions have traditionally been aimed at achieving dental alignment, but contemporary approaches also consider their effects on gingival and periodontal health.
- **Clear aligners**, such as the **Invisalign First System**, not only serve as tools for achieving dental aesthetics but also potentially contribute to improved periodontal well-being compared to traditional fixed appliances.

DISCLAIMER

THIS IS COPYRIGHTED CONTENT. Unauthorized use, including screenshots, copying, misuse, reuse, or resale of any content from this app, is strictly prohibited. Our app monitors and records all screenshots and recordings. Violators will face strict legal action.

DISCLAIMER

THIS IS COPYRIGHTED CONTENT. Unauthorized use, including screenshots, copying, misuse, reuse, or resale of any content from this app, is strictly prohibited. Our app monitors and records all screenshots and recordings. Violators will face strict legal action.

INVISALIGN

- Studies have suggested that Use of Invisalign first system is effective in treatment of deep bite and dental crowding in a growing patient.
- Invisalign First system combined with an appropriate treatment staging is a valid strategy to solve orthodontic issues such as dental crowding, arch forms, and space loss for normal dental eruption.
- Furthermore, a good esthetic, proper oral hygiene and stable results are obtained using Invisalign First system.
- Invisalign First system is an optimal and effective therapeutic choice in growing patient with deep bite and dental crowding.

A case report pictures of growing male patient (7-year-old) with dentoskeletal class I, dental crowding and inadequate space for 12 and 42 eruptions,

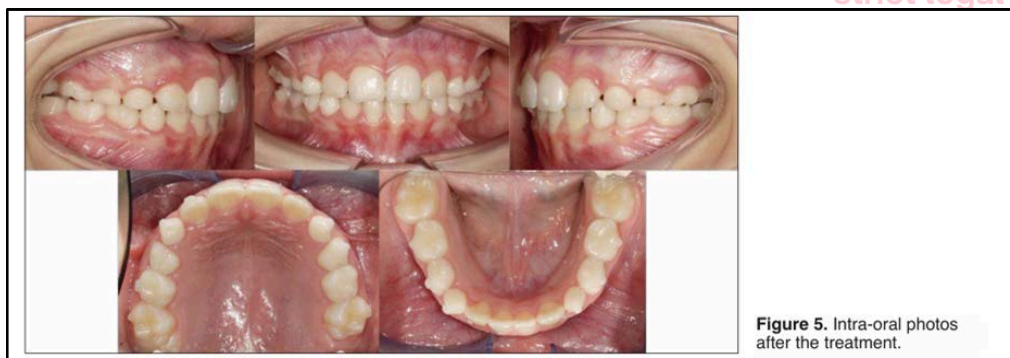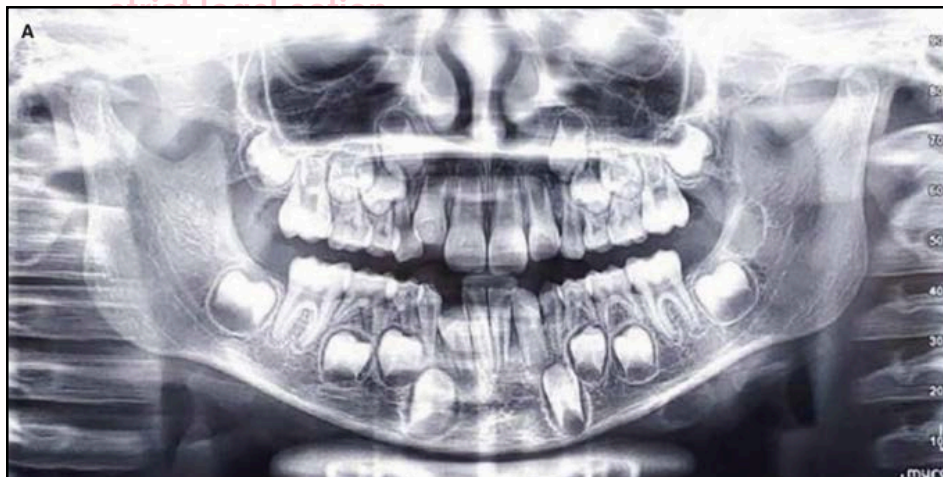

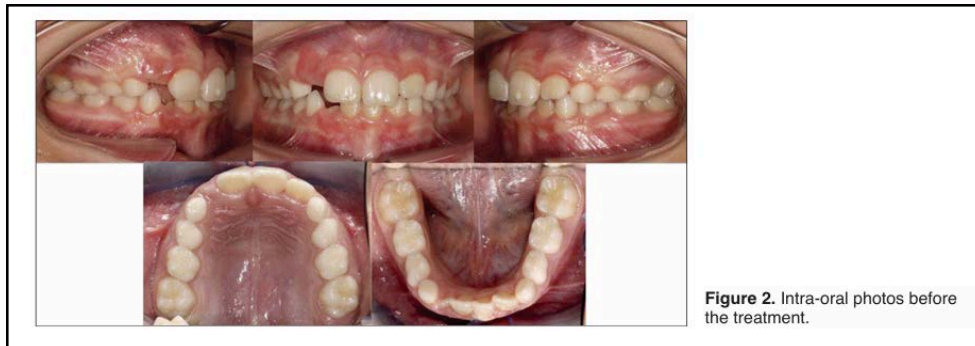
Fig: After treatment with Invisalign First System

DISCLAIMER

THIS IS COPYRIGHTED CONTENT. Unauthorized use, including screenshots, copying, misuse, reuse, or resale of any content from this app, is strictly prohibited. Our app monitors and records all screenshots and recordings. Violators will face strict legal action.

DISCLAIMER

THIS IS COPYRIGHTED CONTENT. Unauthorized use, including screenshots, copying, misuse, reuse, or resale of any content from this app, is strictly prohibited. Our app monitors and records all screenshots and recordings. Violators will face strict legal action.