



OSCE Lens Card

PINK SET: ULCER IN A PATIENT WITH BROKEN FILLING CASE

Cluster 1: Clinical Information Gathering

Key Words

1

HISTORY

- HOPC: Any symptoms with broken teeth/ filling? Swellings?
- Ulcer for the first time? Always the same area? Numbness/ burning sensation? Ulcer anywhere else too?
- Medical history - Medical conditions, medications and allergies. Last blood test?
- Dental history - Previous dental visits, brushing habits, restricted tongue movements?
- Social history - Smoking, alcohol, grinding?

2

CAUSES FOR ULCER:

Trauma, RAS, ulcer of unknown origin.

3

INVESTIGATIONS:

- E/O - Swelling over face/ neck, fever.
- I/O - Detailed examination of the broken tooth.
Tongue movements.
Ulcer anywhere else?
Detailed check for ulcer.
X-rays: Periapical x-ray.
Gum examination.
Ref to oral medicine specialist for biopsy.
Ref to GP for blood test.

Diagram





OSCE Lens Card

PINK SET: MISSING LATERAL INCISORS CASE

Cluster 1: Clinical Information Gathering

Key Words

1

HISTORY

- HOPC: Missing teeth? Big appearance of front teeth? Space in between the front teeth? Any concerns mentioned by the child?
- Medical history - Overall growth? medical conditions, medications and allergies.
- Dental history - Previous dental visits/ records.
- Family history - Close family members with similar appearance?
- Social history - Parafunctional habits?

2

EXPLANATION:

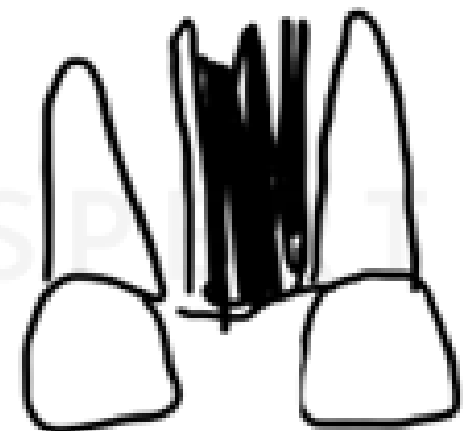

Thick frenum attachment, mesiodens, parafunctional habits, jaw-tooth discrepancy, Missing laterals.

3

INVESTIGATIONS:

- E/O - Face profile.
 - I/O - Detailed examine all teeth and count.
- X-rays: Occlusal
(Periapical x-ray and OPG.)
Gum examination.
Blanch test.
Early referral to an orthodontist.

Diagram





OSCE Lens Card

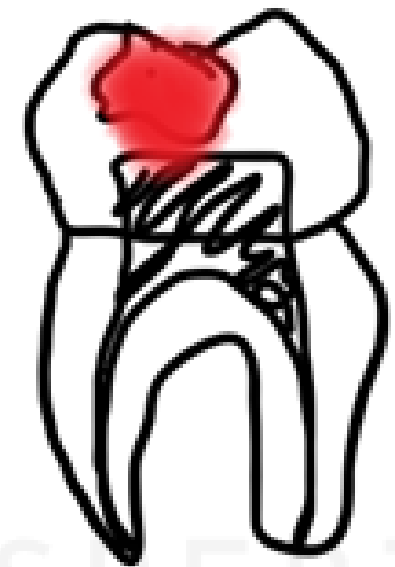**PINK SET: PATIENT TRAVELLING AND IN
UNBEARABLE PAIN**

Cluster 2: Diagnosis and Management

Key Words

- 1** HOPC: Pain nature? Pain medications? Swelling over gums/face? Understanding the patient's travel situation.
- 2** EXPLANATION OF FINDINGS & DIAGNOSIS: Chronic irreversible pulpitis.
- 3** MANAGEMENT:
 - No treatment.
 - Prescribe pain medications (Check M/H) and LA.
 - Because of time constraints, we can't do: Emergency pulpectomy.
 - Refer to a dentist at a travel place.
- 4** HEALTH PROMOTION ASPECTS:
 - Regular dental visits.
 - Oral hygiene routine (Brushing twice daily and flossing).

Diagram





OSCE Lens Card

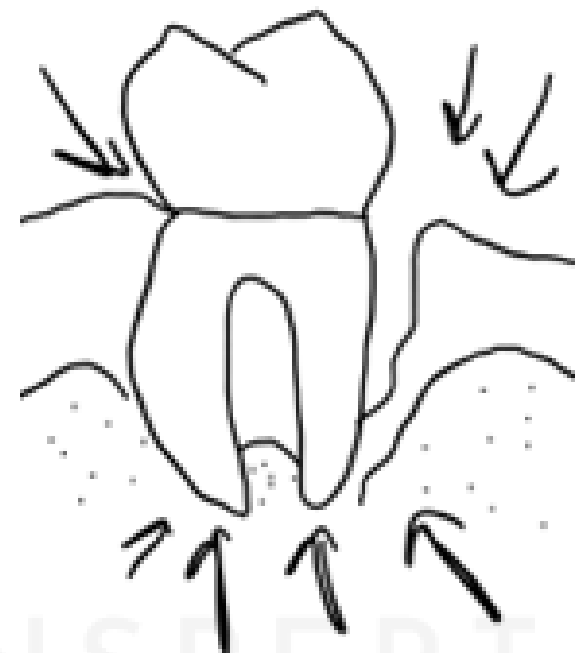
PINK SET: PERIODONTAL ABSCESS CASE

Cluster 2: Diagnosis and Management

Key Words

- 1 HOPC: Pain? Swelling? Wobbly teeth?
Discharge? Any symptoms with other teeth?
- 2 EXPLANATION OF FINDINGS & DIAGNOSIS:
Periodontal abscess and chronic generalised moderate periodontitis.
- 3 RELEVANT HISTORY:
Medical history (blood test), regular dental visits and oral hygiene, smoking as primary.
- 4 MANAGEMENT:
 - No treatment.
 - LA, deep clean, irrigate with sterile saline and review.
 - Referral to periodontist if not responding.
 - If profound immunocompromised status - prescribe antibiotics after treatment.
- 5 HEALTH PROMOTION ASPECTS:
 - Regular dental visits.
 - Oral hygiene routine (Brushing twice daily and flossing).
 - Medical history (regular blood tests).
 - Advice on quitting smoking.
 - Stress management.

Diagram





OSCE Lens Card

PINK SET: INFORMED CONSENT FOR EXTRACTION CASE

Cluster 3: Clinical Treatment and Evaluation

Key Words

- 1** HOPC: Pain? Swelling?
- 2** Explanation of findings, x-ray and diagnosis.
- 3** **RELEVANT HISTORY:**
Medical history, Smoking/ alcohol?
- 4** **MANAGEMENT:**
 - No treatment.
 - Treatment by me after explaining risks.
 - Referral to oral surgeon/ experienced colleague.
 - Prescription of pain medications.
 - Post-operative instructions.
 - Review - discussion on replacement options.
- 5** **HEALTH PROMOTION ASPECTS:**
 - Regular dental visits.
 - Optimum oral hygiene.
 - Advice on quitting smoking - brochures and online support.

Diagram

Explain with x-ray given.
No need for diagrams,
focus on health
promotional aspects more.



OSCE Lens Card

PINK SET: PAIN IN RC TREATED TOOTH CASE

Cluster 3: Clinical Treatment and Evaluation

Key Words

- 1 HOPC: Is the pain similar to before doing RCT? Any trigger? Any reason for the band around the tooth?
- 2 Explanation of findings and x-ray.
- 3 **RELEVANT HISTORY:**
Grinding? Habit of eating hard foods?
- 4 **UNDERSTAND CAUSES:**
High point, band impingement or post-operative pain.
- 5 **TREATMENT AND EVALUATION:**
 - No treatment.
 - High point reduction.
 - Reassurance for post-op pain.
 - Avoid eating hard foodstuffs from that side.
- 5 **HEALTH PROMOTION ASPECTS:**
 - Optimum oral hygiene.

Diagram

Explain with x-ray given.