



WINSPERT

OPERATIVE

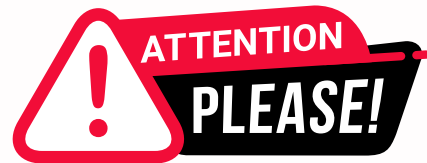H.O.T

HIGH-PRIORITY ORGANISED THEORY

NOTES

By Dr. Jigyasa Sharma





Dear Students,

We'd like to remind you about the importance of respecting the integrity of the resources provided in our app.

Please be aware that **WINSPERT HOT NOTES ARE COPYRIGHTED CONTENT. Unauthorized use, including screenshots, copying, misuse, reuse, or resale of any content from this app, is strictly prohibited.**

Our app monitors and records all screenshots and recordings. Violators will face strict legal action.

We're committed to providing you with the best tools for your success, and we appreciate your cooperation in maintaining a fair and secure learning environment.

Thank you for your understanding and continued dedication.

Best regards,
WINSPERT TEAM

OPERATIVE

H.O.T TOPICS

- 1. TOOTH WEAR**
- 2. CRACKED TOOTH**
- 3. CARIES DIAGNOSIS**
(CLINICAL + RADIOGRAPHICAL)
- 4. CARIES RISK**
- 5. CARIES MANAGEMENT**
- 6. RESTORATIVE MATERIAL**
- 7. DRUG ABUSE/RADIATION/ DRY MOUTH/ SJOGREN/ CARIES**

TOOTH WEAR

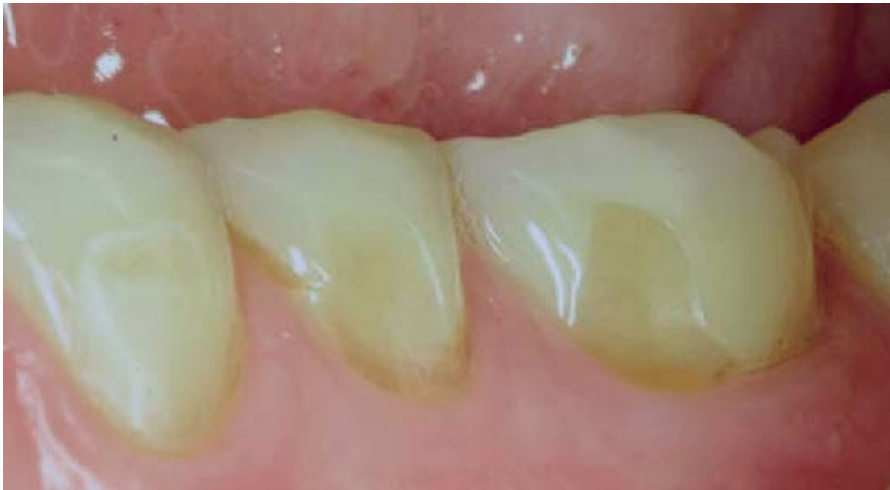Tooth wear mainly comprises of Erosion, Abrasion, Attrition and Abfraction.

EROSION

The loss of surface tooth structure by chemical action in the continued presence of demineralizing agents with low pH is defined as Erosion. (Sturdevant 7th edition)

Erosive Tooth wear:

The loss of dental hard tissues through the process of erosion, attrition and abrasion in combination, with erosion being the dominant factor. Here, although erosive agents are often the predominant factor, tooth brushing and other abrasive agents in the diet may accelerate the loss of tooth structure. (Source: Odell and Sturdevant)



Facial erosive tooth wear. No intact enamel along the gingival margin, but a silky-glazed appearance of the surface. Age of patient: 35 years. Known etiological factors: acidic fruits (lemon, orange) and fresh squeezed lemon and orange juice. (Source-Internet: Research gate)

THIS IS COPYRIGHTED
CONTENT. Unauthorized use,
including screenshots,
copying, misuse, reuse, or
resale of any content from
this app, is strictly prohibited.
Our app monitors and records
all screenshots and
recordings. Violators will face
strict legal action.

DISCLAIMER

THIS IS COPYRIGHTED CONTENT. Unauthorized use, including screenshots, copying, misuse, reuse, or resale of any content from this app, is strictly prohibited. Our app monitors and records all screenshots and recordings. Violators will face strict legal action.

DISCLAIMER
THIS IS COPYRIGHTED CONTENT. Unauthorized use, including screenshots, copying, misuse, reuse, or resale of any content from this app, is strictly prohibited. Our app monitors and records all screenshots and recordings. Violators will face strict legal action.

THIS IS COPYRIGHTED CONTENT. Unauthorized use, including screenshots, copying, misuse, reuse, or resale of any content from this app, is strictly prohibited. Our app monitors and records all screenshots and recordings. Violators will face strict legal action.

DISCLAIMER

TOOTH WEAR

It is the chemical dissolution of dental hard tissues and is caused by acids.

(Source: Odell)

Acids responsible for erosion are stronger and different to acids that are produced from fermentation of carbohydrates by plaque microorganisms which cause caries.

Etiology of erosion:

Table 1. Causes of exogenous and endogenous erosion

The more common causes of exogenous erosion;

Dietary citrus fruits, fruit juices, carbonated beverages, vinegar and pickles

Medicines ascorbic acid, HCl replacement therapy, frequent acetylsalicylic acid use, some iron tonics, some cough suppressant syrups, some antiseptic mouthrinses.

Occupational wine assessment, acid vapours (battery workshops)

Recreational improperly chlorinated large swimming pools, heated spas (Zero DT, 1996).

The more common causes of endogenous erosion are vomiting, regurgitation or reflux due to;

Anatomical defects eg. hiatus hernia, deficient gastro-oesophageal sphincter, oesophageal diverticulosis

Psychological problems eg. anorexia nervosa/ bulimia, severe alcoholism, severe stress

Medication for some severe health problems chemotherapy, severe asthma, or other drugs severely irritating the gastric mucosa

Side effect of some cytostatic drugs

Associated with peptic ulcer or uremia

Prolonged nausea during pregnancy

THIS IS COPYRIGHTED CONTENT. Unauthorized use, including screenshots, copying, misuse, reuse, or resale of any content from this app, is strictly prohibited. Our app monitors and records all screenshots and recordings. Violators will face strict legal action.

DISCLAIMER
THIS IS COPYRIGHTED CONTENT. Unauthorized use, including screenshots, copying, misuse, reuse, or resale of any content from this app, is strictly prohibited. Our app monitors and records all screenshots and recordings. Violators will face strict legal action.

THIS IS COPYRIGHTED CONTENT. Unauthorized use, including screenshots, copying, misuse, reuse, or resale of any content from this app, is strictly prohibited. Our app monitors and records all screenshots and recordings. Violators will face strict legal action.

(Image Source: Erosion Article)

Erosion can be of two types based on the sources :

Intrinsic acid erosion-Regurgitation of gastric contents into the mouth as occurs in GERD is the most common source of intrinsic erosion-mainly HCL. (PH of gastric acid -1.2). (Source-Article)

Rumination- It is a unusual practice which involves habitual chewing of food, swallowing and then regurgitating the food mixed with stomach acid to be chewed and swallowed again.It is thought to affect mostly young , healthy and mainly professional people. (Source -Odell)

DISCLAIMER

THIS IS COPYRIGHTED CONTENT. Unauthorized use, including screenshots, copying, misuse, reuse, or resale of any content from this app, is strictly prohibited. Our app monitors and records all screenshots and recordings. Violators will face strict legal action.

TOOTH WEAR

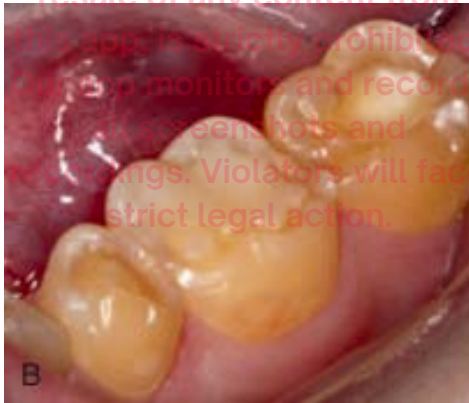Eating and Psychological disorders: Anorexia and bulimia which mostly affects females can cause regurgitation related gastric erosion .

Bulimia nervosa-Patients have a stable body weight where they eat and drink in binges and self induce vomiting to control their bodyweight.

Anorexia nervosa-Patients loose body weight by starving themselves and/or vomiting to lose weight in a attempt to improve their body self image. (Source-Odell)

Surfaces affected from Intrinsic Erosion

- Endogenous agents cause generalized erosion on the Lingual , incisal and occlusal surfaces. (Source-Sturdevant)
- Gastric reflux and vomiting- Occlusal surface of the molars. Palatal surfaces of upper anterior and premolars. (Source-Erosion Article)



(Fig:Generalized Erosion caused by endogenous Fluids)
(Source-Sturdevant)

Extrinsic acid erosion: Can be dietary, industrial or pharmacological .It involves consumption of acidic food , drinks and acidic medications. Acids include Phosphoric, citric, acetic,tartaric,ascorbic and malic acids. (PH of extrinsic acid -varies from 2.5-4.0). (Source-Article)

Surfaces affected from extrinsic erosion

- Exogenous agents such as sucking lemon juice over the years may cause crescent shaped or dish-shaped defects (which are rounded as opposed to angular)on the surfaces of the teeth exposed to the agent. Mainly labial /buccal surface. (Source- Sturdevant)
- Occupational (such as wine tasters)-buccal surfaces of upper and lower anterior teeth. (Source -Article)
- Medication - Occlusal surfaces of the molars and palatal surfaces of upper molars (Source -Article)

DISCLAIMER

THIS IS COPYRIGHTED CONTENT. Unauthorized use, including screenshots, copying, misuse, reuse, or resale of any content from this app, is strictly prohibited. Our app monitors and records all screenshots and recordings. Violators will face strict legal action.

DISCLAIMER
THIS IS COPYRIGHTED CONTENT. Unauthorized use, including screenshots, copying, misuse, reuse, or resale of any content from this app, is strictly prohibited. Our app monitors and records all screenshots and recordings. Violators will face strict legal action.

THIS IS COPYRIGHTED CONTENT. Unauthorized use, including screenshots, copying, misuse, reuse, or resale of any content from this app, is strictly prohibited. Our app monitors and records all screenshots and recordings. Violators will face strict legal action.

DISCLAIMER

TOOTH WEAR

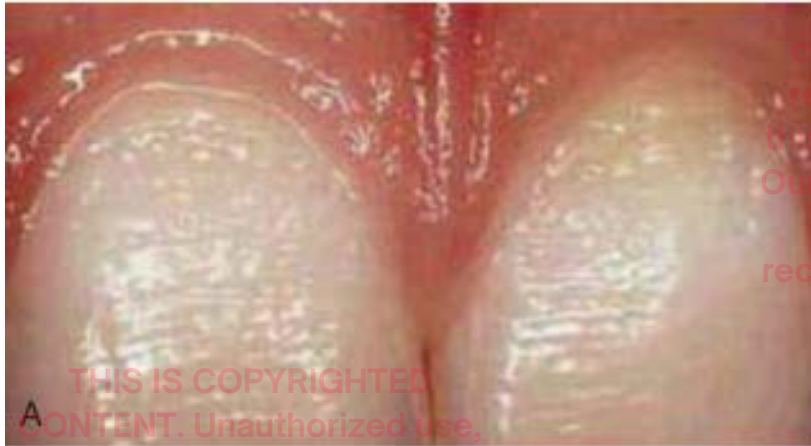

Fig-Crescent shaped defect on labial surface
(Source-Sturdevant)

Although erosion is caused by agents with lower PH, PH is NOT a direct indicator of erosive potential. As other chemical accompanying the strong acid may modify the erosive potential. For example- Yoghurt has PH of 4.0 but is not erosive as it has high concentration of calcium and phosphate ions which inhibits the erosive demineralization of apatite through the Common ion effect. Also, Mature red wine is less erosive than young red/white wines which is presumed to be because of presence of many other chemicals which inhibit demineralization.

(Source-Erosion Article)

Signs and symptoms of erosion: (Source-article)

Can range from slight loss of tooth surface to extensive loss of tissue with pulp exposure and abscess formation.

Symptoms range from (No symptom through sensitivity to severe pain associated with pulp exposure)

In enamel Early signs of erosion includes:

- Rounding of sharp angles
- Dentin cupping or scooping
- Thinning of enamel
- Any restoration present may appear to be above the tooth surface (e.g-amalgam islands)
- On exposed root surfaces erosion appears as detectable softening of the surface and is indistinguishable from root caries, but progresses more rapidly than dental caries.

DISCLAIMER

THIS IS COPYRIGHTED CONTENT. Unauthorized use, including screenshots, copying, misuse, reuse, or resale of any content from this app, is strictly prohibited. Our app monitors and records all screenshots and recordings. Violators will face strict legal action.

DISCLAIMER
THIS IS COPYRIGHTED CONTENT. Unauthorized use, including screenshots, copying, misuse, reuse, or resale of any content from this app, is strictly prohibited. Our app monitors and records all screenshots and recordings. Violators will face strict legal action.

THIS IS COPYRIGHTED CONTENT. Unauthorized use, including screenshots, copying, misuse, reuse, or resale of any content from this app, is strictly prohibited. Our app monitors and records all screenshots and recordings. Violators will face strict legal action.

THIS IS COPYRIGHTED CONTENT. Unauthorized use, including screenshots, copying, misuse, reuse, or resale of any content from this app, is strictly prohibited. Our app monitors and records all screenshots and recordings. Violators will face strict legal action.

THIS IS COPYRIGHTED CONTENT. Unauthorized use, including screenshots, copying, misuse, reuse, or resale of any content from this app, is strictly prohibited. Our app monitors and records all screenshots and recordings. Violators will face strict legal action.

TOOTH WEAR

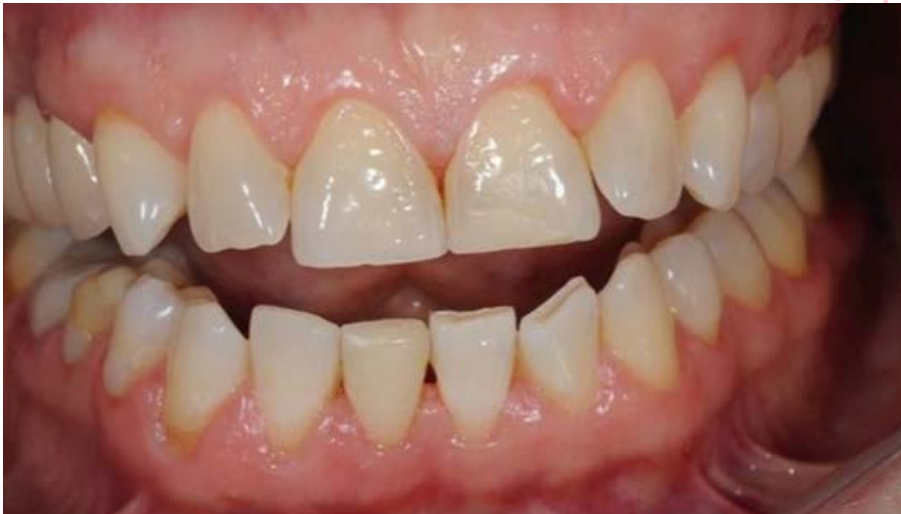

Fig-shows less than 50% loss with signs of erosive tooth wear on the buccal (facial) surface but also some loss of the incisal edge. (Source-Internet)

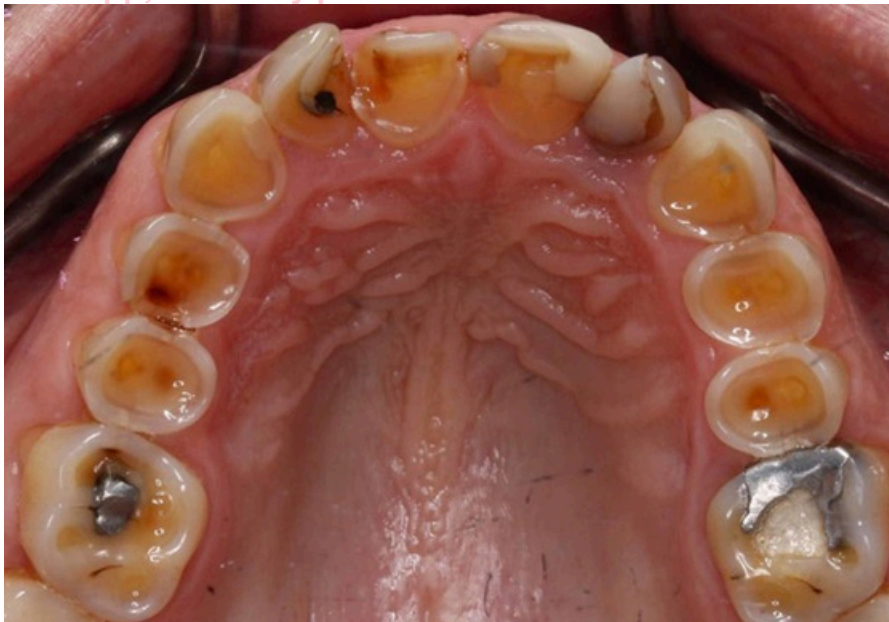

Fig-Severe erosive toothwear with characteristic cupping out lesion with an enamel halo

THIS IS COPYRIGHTED CONTENT. Unauthorized use, including screenshots, copying, misuse, reuse, or resale of any content from this app, is strictly prohibited. Our app monitors and records all screenshots and recordings. Violators will face strict legal action.

THIS IS COPYRIGHTED CONTENT. Unauthorized use, including screenshots, copying, misuse, reuse, or resale of any content from this app, is strictly prohibited. Our app monitors and records all screenshots and recordings. Violators will face strict legal action.

DISCLAIMER
THIS IS COPYRIGHTED CONTENT. Unauthorized use, including screenshots, copying, misuse, reuse, or resale of any content from this app, is strictly prohibited. Our app monitors and records all screenshots and recordings. Violators will face strict legal action.

DISCLAIMER

THIS IS COPYRIGHTED CONTENT. Unauthorized use, including screenshots, copying, misuse, reuse, or resale of any content from this app, is strictly prohibited. Our app monitors and records all screenshots and recordings. Violators will face strict legal action.

DISCLAIMER

THIS IS COPYRIGHTED CONTENT. Unauthorized use, including screenshots, copying, misuse, reuse, or resale of any content from this app, is strictly prohibited. Our app monitors and records all screenshots and recordings. Violators will face strict legal action.

TOOTH WEAR

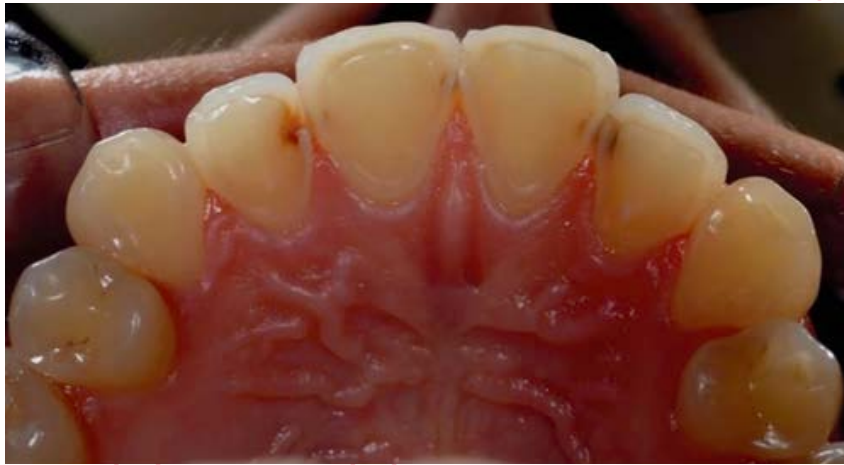

Fig- Erosion has removed all of the palatal (Source-Internet)

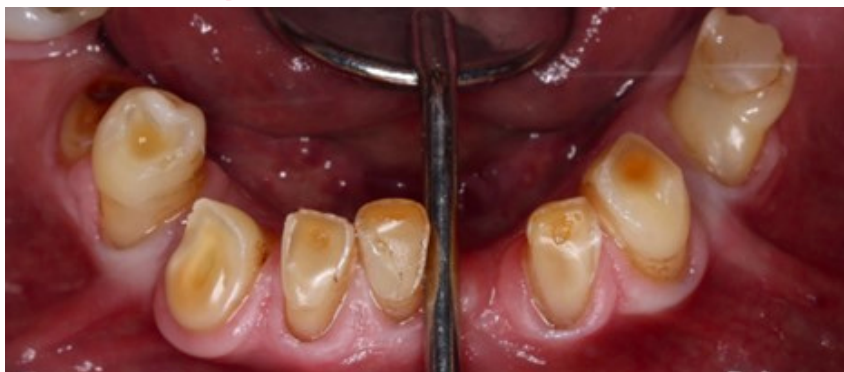

Fig-Severe erosive tooth wear of combined etiology (i.e erosion ,attrition and abrasion)
(Source- Internet)

THIS IS COPYRIGHTED
CONTENT. Unauthorized use,
including screenshots,
copying, misuse, reuse, or
resale of any content from
this app, is strictly prohibited.
Our app monitors and records
all screenshots and
recordings. Violators will face
strict legal action.

DISCLAIMER

THIS IS COPYRIGHTED CONTENT. Unauthorized use, including screenshots, copying, misuse, reuse, or resale of any content from this app, is strictly prohibited. Our app monitors and records all screenshots and recordings. Violators will face strict legal action.

THIS IS COPYRIGHTED
CONTENT. Unauthorized use,
including screenshots,
copying, misuse, reuse, or
resale of any content from
this app, is strictly prohibited.
Our app monitors and records
all screenshots and
recordings. Violators will face
strict legal action.

DISCLAIMER
THIS IS COPYRIGHTED CONTENT. Unauthorized use, including screenshots, copying, misuse, reuse, or resale of any content from this app, is strictly prohibited. Our app monitors and records all screenshots and recordings. Violators will face strict legal action.

THIS IS COPYRIGHTED
CONTENT. Unauthorized use,
including screenshots,
copying, misuse, reuse, or
resale of any content from
this app, is strictly prohibited.
Our app monitors and records
all screenshots and
recordings. Violators will face
strict legal action.

TOOTH WEAR

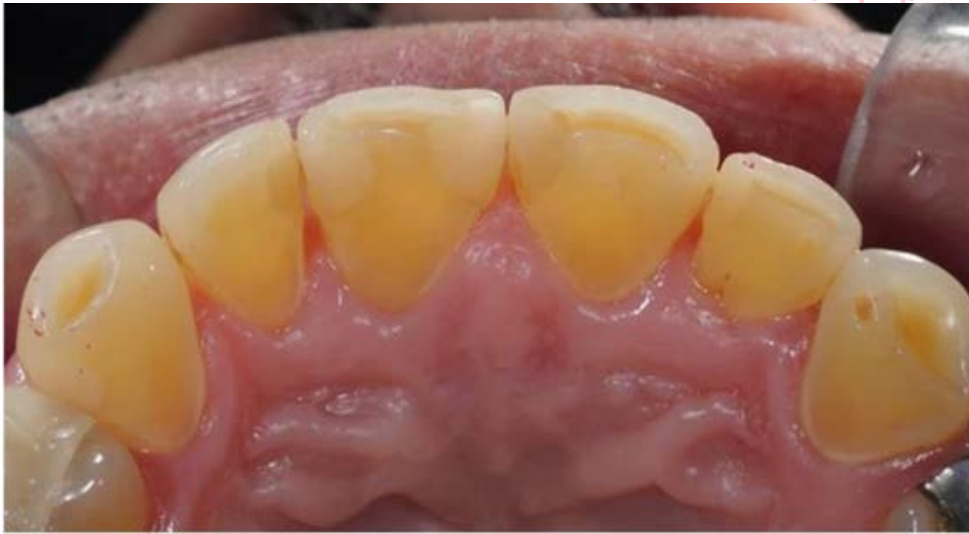

Fig- Erosion with greater than 50% of the surface affected. (Source-Internet)

Pathophysiology of erosion:

If erosion continues signs become more exaggerated leading to eventual total loss of enamel. With time following repeated erosive episodes, the cementum /dentine becomes very soft and is easily damaged by brushing ,coarse food or dental scaling and polishing leading to sensitivity. (Source-Article)

Factors affecting erosion/Risk factors of erosion:

- Period of time the erosive acid remain in contact with tooth
- Frequency of contact .
- Drug use or severe dehydration following extreme exercises or sports.
- Maturity of enamel with increase resistance to acidic dissolution reduces susceptibility to caries , However there is no evidence that erosive potential is reduced .This is because erosive acids dissolve even fluorapatites which inhibits dissolution by weaker caries causing acids.
- Interproximal surfaces rarely gets eroded as there is usually presence of plaque and thick acquired pellicle. As salivary pellicle Does protect the teeth from erosion. (Source -Article)

THIS IS COPYRIGHTED CONTENT. Unauthorized use, including screenshots, copying, misuse, reuse, or resale of any content from this app, is strictly prohibited. Our app monitors and records all screenshots and recordings. Violators will face strict legal action.

DISCLAIMER

THIS IS COPYRIGHTED CONTENT. Unauthorized use, including screenshots, copying, misuse, reuse, or resale of any content from this app, is strictly prohibited. Our app monitors and records all screenshots and recordings. Violators will face strict legal action.

THIS IS COPYRIGHTED CONTENT. Unauthorized use, including screenshots, copying, misuse, reuse, or resale of any content from this app, is strictly prohibited. Our app monitors and records all screenshots and recordings. Violators will face strict legal action.

DISCLAIMER
THIS IS COPYRIGHTED CONTENT. Unauthorized use, including screenshots, copying, misuse, reuse, or resale of any content from this app, is strictly prohibited. Our app monitors and records all screenshots and recordings. Violators will face strict legal action.

TOOTH WEAR

Investigations:

- Diet assessment: A thorough diet record should be logged in by the patient to
- Determine the true consumption of acidic foods or cariogenic food, as the causative agents is of utmost importance for diagnosing and managing the condition. (Source-Odell)
- Impressions or study casts or intraoral scans: Helps to monitor the progression of future erosion as these will provide a baseline record. (Source-Odell)
- Absence of Stains on surfaces of tooth- helps in determining the activity status of the lesion and can also be used as a means to confirm active erosion. As erosive acids dissolves Extrinsic stains. (Source -Odell)

Management of erosion:

- Accurate diagnosis along with its cause and patient awareness is the first step in management of erosion. When the dental erosion is diagnosed, it is important to investigate and identify the acid source, and to determine if the process is ongoing. The aim of treatment is to eliminate the cause of acid exposure or minimize the effects of acid exposure where it is not possible to remove the acid source. (Source-Article)
- The second step is to help patient control the cause if possible and then if necessary protect the teeth against further damage.
- In active erosion; Prevention is most important but where that is not possible composite resins can be used to protect enamel
- In inactive erosions: Restorative treatments can be considered depending upon the severity of the lesion.
- For example-Crowns to establish Vertical dimension or composites for aesthetics. (Source article)
- Intrinsic erosion is most difficult to control and protect the teeth against. Seeking medical help is always recommended in cases of intrinsic erosion. Patients with anorexia and bulimia nervosa are more difficult to manage as the patients are not willing to acknowledge they have a eating disorder.
- In case of erosion due to extrinsic causes patients are usually very willing and able to control the causes.

There are 4 steps necessary in the management of erosion cases:

01. Behavioral aspect of control: Behavioral control measures to help in reducing erosive damage particularly from intrinsic erosion includes

- Rinsing the mouth immediately after acid attack with water, milk or if possible 220ppm Fluoride mouthrinse.
- Not brushing for atleast 30 mins after an attack, to permit some salivary stabilization of the tooth mineral structure.
- For extrinsic erosion, following alternative can be suggested to the patient
- Drinking more water especially between meals

DISCLAIMER

THIS IS COPYRIGHTED CONTENT. Unauthorized use, including screenshots, copying, misuse, reuse, or resale of any content from this app, is strictly prohibited. Our app monitors and records all screenshots and recordings. Violators will face strict legal action.

DISCLAIMER

THIS IS COPYRIGHTED CONTENT. Unauthorized use, including screenshots, copying, misuse, reuse, or resale of any content from this app, is strictly prohibited. Our app monitors and records all screenshots and recordings. Violators will face strict legal action.

THIS IS COPYRIGHTED CONTENT. Unauthorized use, including screenshots, copying, misuse, reuse, or resale of any content from this app, is strictly prohibited. Our app monitors and records all screenshots and recordings. Violators will face strict legal action.

DISCLAIMER

TOOTH WEAR

- Restricting the frequency of acidic food and drinks to meal times-finish with a small piece of cheese or milk.
- Using straw to consume fruit juices, soft drinks and sport drinks.
- Rinsing the mouth with water after any acidic challenge to teeth.
- Substituting acidic drinks with non acidic alternatives. For example-Flavoured milk instead of all soft drinks and cordial
- Swallowing Vit C capsules rather than chewing.

02. Chemical aspect of control:

- Use of anta acid preparation to neutralize acids -esp gastric reflux.(not very practical or effective as compared to rinsing with water)
- Addition of calcium, magnesium or fluoride ions to beverages to reduce their erosive potential.(most experiments demonstrated that the amount of these ions needed to inhibit the erosive effect were very high that it would be impractical to do it)
- Application of concentrated topical fluoride gels (acidulated gels twice as effective than neutral fluoride gels) and varnishes to teeth before the erosive challenge. The timing of application is crucial.
- For wine tasters before an extensive period of tasting -Self or professional application the day before the judging session did not affect the taste discrimination.
- For nocturnal reflux- self application of gels in the evenings and
- For morning reflux- self application of gels in evenings or early morning is the most effective.

03. Physical aspect of control:

- Coating vulnerable surface with unfilled resins or GIC
- Placement of protective adhesive restorations.
- Crowns where severe loss of tooth structure is present.
- (Note: Full coverage crowns are not a total solution to severe erosions as the erosive acids will continue to attack the tooth structure apical to the crowns. In case of active erosion Restorative work should be avoided.) (Source -Article)
- In case of severely worn dentition leading to loss of vertical dimension such as in case of erosive tooth wear two potential treatment philosophies can be used to manage the occlusion during provision of new restorations:
 - *Reorganized approach: In this option restorations are placed at an increased occlusal vertical dimension.*
 - *Confirmatory approach: Existing jaw relationship is maintained and short anterior crowns confirming to the existing intercuspal position and vertical dimension can be provided in this option.*(Source -Odell)

DISCLAIMER

THIS IS COPYRIGHTED CONTENT. Unauthorized use, including screenshots, copying, misuse, reuse, or resale of any content from this app, is strictly prohibited. Our app monitors and records all screenshots and recordings. Violators will face strict legal action.

DISCLAIMER

THIS IS COPYRIGHTED CONTENT. Unauthorized use, including screenshots, copying, misuse, reuse, or resale of any content from this app, is strictly prohibited. Our app monitors and records all screenshots and recordings. Violators will face strict legal action.

THIS IS COPYRIGHTED CONTENT. Unauthorized use, including screenshots, copying, misuse, reuse, or resale of any content from this app, is strictly prohibited. Our app monitors and records all screenshots and recordings. Violators will face strict legal action.

DISCLAIMER

TOOTH WEAR

• BOX 61.2 Advantages and Disadvantages of Options for Managing the Occlusal Relationship	
Options for Managing the Occlusal Relationship	Advantages and Disadvantages
Conformative approach	The new restorations are placed, conforming to the existing occlusal vertical dimension and intercuspal position. This means that the patient needs to make minimal adaptation to the new restorations because they will replicate the existing habitual bite (occlusion). However, if teeth are being prepared for full-coverage indirect restorations, the height of the tooth must be reduced further to produce occlusal clearance for the crowns, and this may expose the pulp. The conformative approach is usually appropriate for direct restorations, single crowns and simple bridges, where adequate sound or restored teeth predictably maintain the stability of the existing occlusion.
Reorganized	This is required when the existing occlusal vertical dimension is not conducive to provision of new restorations of adequate shape and size with a predictable outcome. For example, in this case, it is beneficial to reorganize the occlusion when providing multiple restorations that contribute to anterior guidance. In cases of tooth wear, the vertical dimension often needs to be increased and a new occlusal relationship defined to correct the maxillary-mandibular relationships and provide restorations with appropriate crown size and shape. The retruded-contact position is chosen because it is reproducible and can act as the new intercuspal position.

(Image Source: Odell)

- **Continuing monitoring of erosive damage-After control has been achieved or restorations are placed it is essential to monitor for sometime as endogenous erosion in particular has a habit of reoccurring. Recurrent dentinal sensitivity is a frequent useful indicator of continuing demineralization. (Source- Article)**

Methods of monitoring:

For short term continuing loss of enamel structure (i.e over six weeks to 3 months)

- Place a small circle of unfilled resin on the lingual surface of vulnerable tooth, A lip of lost enamel may be visible by dental loupes around the area protected by resin.
- Placing A scratch line across vulnerable enamel using NO.12 scalpel Blade ,if the scratch diminishes or disappears over a one month period active erosion is present.

For long term monitoring of continued loss of enamel structure-

Repetitive impressions of vulnerable teeth, from which dies are formed. And then assessment of loss of dimension with calipers will indicate that the erosion is still active. (Source - Article)

DISCLAIMER

THIS IS COPYRIGHTED CONTENT. Unauthorized use, including screenshots, copying, misuse, reuse, or resale of any content from this app, is strictly prohibited. Our app monitors and records all screenshots and recordings. Violators will face strict legal action.

DISCLAIMER
THIS IS COPYRIGHTED CONTENT. Unauthorized use, including screenshots, copying, misuse, reuse, or resale of any content from this app, is strictly prohibited. Our app monitors and records all screenshots and recordings. Violators will face strict legal action.

THIS IS COPYRIGHTED CONTENT. Unauthorized use, including screenshots, copying, misuse, reuse, or resale of any content from this app, is strictly prohibited. Our app monitors and records all screenshots and recordings. Violators will face strict legal action.

DISCLAIMER

TOOTH WEAR

The various stages of care plan in case of erosive tooth wear includes:

Stage	Reason
Diagnostic and care planning phase	To provide study casts articulated in the retruded jaw relationship at an appropriate vertical dimension of occlusion – a diagnostic wax-up and a surgical stent for the crown lengthening. This clear stent shows the proposed new crown margin positions, ensuring that sufficient bone is removed 3–4 mm apical to this. In addition, radiographs, photographs and vitality testing will be carried out as well as nonsurgical periodontal treatment to optimize oral hygiene and to ensure resolution of any periodontal inflammation. This is always the most important phase of care delivery – ‘failing to plan is planning to fail’!
Diagnostic try-in/ mock-up	A matrix of the wax-up can be used to do an intraoral try-in by using a bis-acryl composite material, to show the patient the eventual shape and relationships of the planned crowns to the new gingival architecture. Once the patient has approved this, the surgical stent can be constructed. The wax-up can also be used to produce a matrix, which is used to guide the composite bonding or, if crowns are to be provided, as a matrix to guide the preparations and the construction of the provisional restorations, using a bis-acryl composite temporary crown material.
Surgical phase	To gain length for retention of the restorations. Usually, the upper arch is treated first because it is technically easier. The direct composite resin restorations establish the new anterior guidance, which can be copied into future crowns once the occlusion has stabilized or if the direct composites require replacement with indirect restorations.
Healing period	The interval between periodontal surgery and placement of provisional crowns should be in the order of a few weeks because there is some evidence that the tissues can heal back to their original position. Definitive restorations can be provided once the gingival contour is stable, usually around 3–6 months after surgery.
Restorative phase	Provision of direct composite resin restorations at an increased vertical dimension of occlusion. If the ‘Dahl approach’ is used to manage the occlusal vertical dimension, a further 3–6 months will be required to allow relative axial movement of teeth to re-established posterior occlusal contacts.
Maintenance phase	Once the posterior occlusal contacts have re-established, a hard occlusal splint should be provided to protect the restorations from future wear caused by parafunctional habits such as bruxism.

(Image Source: Odell)

THIS IS COPYRIGHTED CONTENT. Unauthorized use, including screenshots, copying, misuse, reuse, or resale of any content from this app, is strictly prohibited. Our app monitors and records all screenshots and recordings. Violators will face strict legal action.

DISCLAIMER

THIS IS COPYRIGHTED CONTENT. Unauthorized use, including screenshots, copying, misuse, reuse, or resale of any content from this app, is strictly prohibited. Our app monitors and records all screenshots and recordings. Violators will face strict legal action.

CONTENT. Unauthorized use, including screenshots, copying, misuse, reuse, or resale of any content from this app, is strictly prohibited. Our app monitors and records all screenshots and recordings. Violators will face strict legal action.

DISCLAIMER
THIS IS COPYRIGHTED CONTENT. Unauthorized use, including screenshots, copying, misuse, reuse, or resale of any content from this app, is strictly prohibited. Our app monitors and records all screenshots and recordings. Violators will face strict legal action.

TOOTH WEAR

ATTRITION

The mechanical wear of occlusal or incisal tooth structure that results from functional or parafunctional movements of the mandible is known as attrition.

(Source-Sturdevant) It is the loss of dental hard tissues and is caused by physical action of tooth grinding against tooth.

A certain degree of attrition is expected with age, however abnormally advanced attrition must be noted. If abnormal attrition is present, functional movements should be evaluated and inquiry should be carried out in regard to potential parafunctional habits such as tooth grinding/clenching (Bruxism).

Etiology:

It is well established that parafunctional habit such as tooth grinding (Bruxism) is the mostly the causative factor for advanced attrition.

Bruxism: It is a repetitive teeth clenching, grinding, bracing or thrusting of the mandible. It can occur both during sleep or when awake. (Source-TG)

Sleep bruxism: The etiology of sleep bruxism is complex and multifactorial but is not fully understood. "OCCLUSAL FACTORS" does not cause sleep bruxism. It is suggested that the onset of sleep bruxism is related to sleep-stage transitions as in sleep bruxism Rhythmic masticatory muscle activity peaks in minutes before REM (rapid eye movement) sleep. (Source -TG)

The common triggers of bruxism includes;

Box 17. Common triggers of bruxism

- caffeine and other stimulants, including herbal stimulants
- alcohol
- smoking
- snoring
- obstructive sleep apnoea
- stress and anxiety
- antidepressants
 - selective serotonin reuptake inhibitors (SSRIs)
 - serotonin and noradrenaline reuptake inhibitors (SNRIs)
- antipsychotics
- amfetamines
 - dexamfetamine
 - lisdexamfetamine
 - metamfetamine
 - MDMA (ecstasy)
- cocaine

(Image Source: TG)

DISCLAIMER

THIS IS COPYRIGHTED CONTENT. Unauthorized use, including screenshots, copying, misuse, reuse, or resale of any content from this app, is strictly prohibited. Our app monitors and records all screenshots and recordings. Violators will face strict legal action.

DISCLAIMER
THIS IS COPYRIGHTED CONTENT. Unauthorized use, including screenshots, copying, misuse, reuse, or resale of any content from this app, is strictly prohibited. Our app monitors and records all screenshots and recordings. Violators will face strict legal action.

THIS IS COPYRIGHTED CONTENT. Unauthorized use, including screenshots, copying, misuse, reuse, or resale of any content from this app, is strictly prohibited. Our app monitors and records all screenshots and recordings. Violators will face strict legal action.

DISCLAIMER

TOOTH WEAR

Signs and Symptoms:

- Heavy occlusal loading or clenching may result in presence of craze lines that are limited to enamel (i.e. Do not progress through DEJ into dentin). Craze lines are not sensitive and do not require treatment but may be evidence of excessive masticatory muscle activity. (Source-Sturdevant)

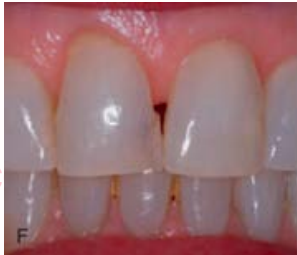

Image-Enamel craze lines (Source- Sturdevant 7th edition)

- Cupped out areas/lesions: In some older patient cupped out areas are seen as cusp tips/incisal edges are worn off and the exposed, softer dentin wears off faster than the surrounding enamel, although there may also be an erosive component to the process.
- Areas of horizontal/vertical fracture development may be present. (Source-Sturdevant).
- Severe wear of the upper and lower teeth can occur in case of advanced attrition leading to short clinical crown and collapsed occlusion (Vertical dimension). (Source-odell)
- In severe cases, signs of secondary dentine formation with sclerosis of the pulp chambers may be seen. (Source-Odell)

Note: Erosive tooth wear is a common occurrence where attrition and erosion both be main factors along with abrasion.

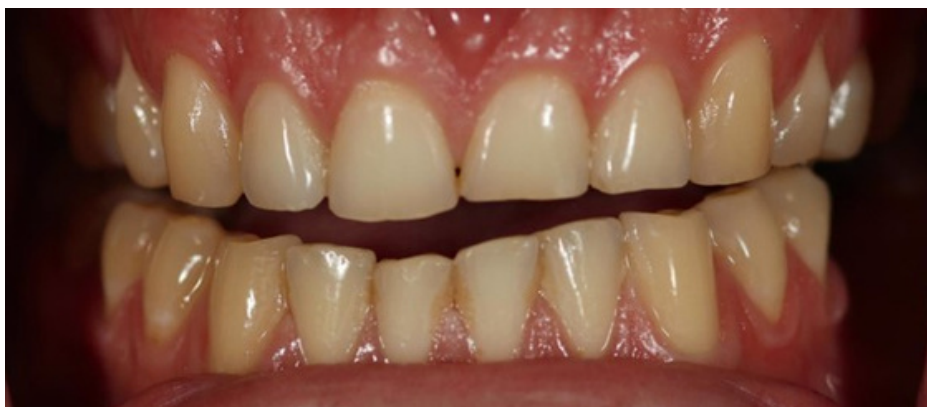

Image: Tooth wear due to bruxism (Source: Internet)

DISCLAIMER

THIS IS COPYRIGHTED CONTENT. Unauthorized use, including screenshots, copying, misuse, reuse, or resale of any content from this app, is strictly prohibited. Our app monitors and records all screenshots and recordings. Violators will face strict legal action.

DISCLAIMER
THIS IS COPYRIGHTED CONTENT. Unauthorized use, including screenshots, copying, misuse, reuse, or resale of any content from this app, is strictly prohibited. Our app monitors and records all screenshots and recordings. Violators will face strict legal action.

THIS IS COPYRIGHTED CONTENT. Unauthorized use, including screenshots, copying, misuse, reuse, or resale of any content from this app, is strictly prohibited. Our app monitors and records all screenshots and recordings. Violators will face strict legal action.

DISCLAIMER

TOOTH WEAR

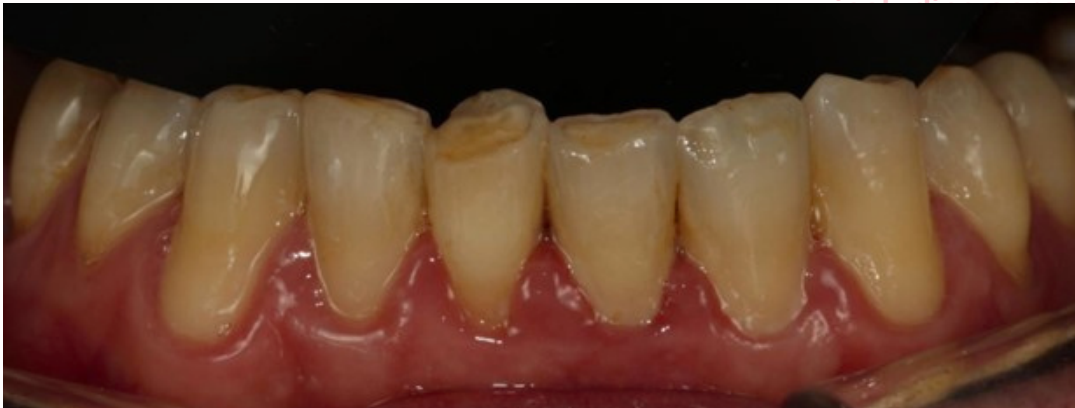

Image: Moderate tooth wear due to attrition affecting mandibular anterior teeth
(Source: Internet)

Investigations:

Accurate and extensive history and examination to know presence of any parafunctional habits and its triggers.

In case of erosive tooth wear where either erosion or attrition or both can be the main causative factor following investigations will help:

- **Radiographs:** In case of severe attrition with reduced crown height radiographs can be taken to assess the bone levels, root morphology and possible periapical pathology. OPG which would provide a useful survey of all maxillary and mandibular teeth. Periapical radiographs with paralleling (Long Cone) technique for assessment of bone levels can be done.
- **Maxillary and Mandibular Study Casts:** It will help to determine the ideal restorative treatment option. To plan the restorations of excessively worn teeth the cast should be articulated in a retruded contact position (RCP) on a fully/semiadjustable articulator using a facebow. *(Note: RCP is a reproducible jaw relationship)*

Uses of Study Casts:

- The study casts mounted to RCP can be used to analyze the patient's occlusion.
- To help determine the appropriate occlusal vertical dimension at which the final restoration could be provided.
- To produce a diagnostic wax-up at increased vertical dimension to provide the purposed shape of the restorations.
- By duplicating the diagnostic wax up in stone and forming a soft vacuum-formed splint or silicone matrix around it, a surgical stent for crown lengthening (to know the final gingival contour) and a provisional chairside crowns can be constructed.

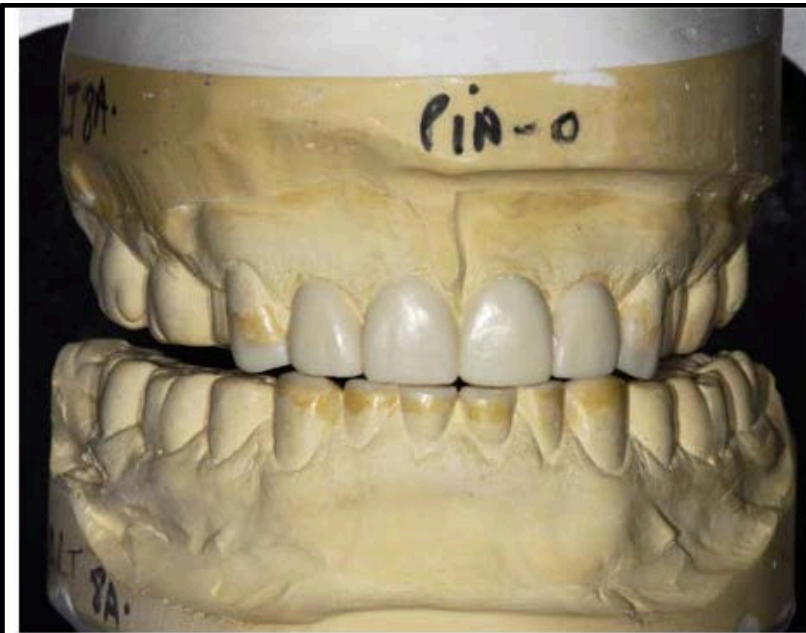DISCLAIMER

THIS IS COPYRIGHTED CONTENT. Unauthorized use, including screenshots, copying, misuse, reuse, or resale of any content from this app, is strictly prohibited. Our app monitors and records all screenshots and recordings. Violators will face strict legal action.

DISCLAIMER
THIS IS COPYRIGHTED CONTENT. Unauthorized use, including screenshots, copying, misuse, reuse, or resale of any content from this app, is strictly prohibited. Our app monitors and records all screenshots and recordings. Violators will face strict legal action.

DISCLAIMER
THIS IS COPYRIGHTED CONTENT. Unauthorized use, including screenshots, copying, misuse, reuse, or resale of any content from this app, is strictly prohibited. Our app monitors and records all screenshots and recordings. Violators will face strict legal action.

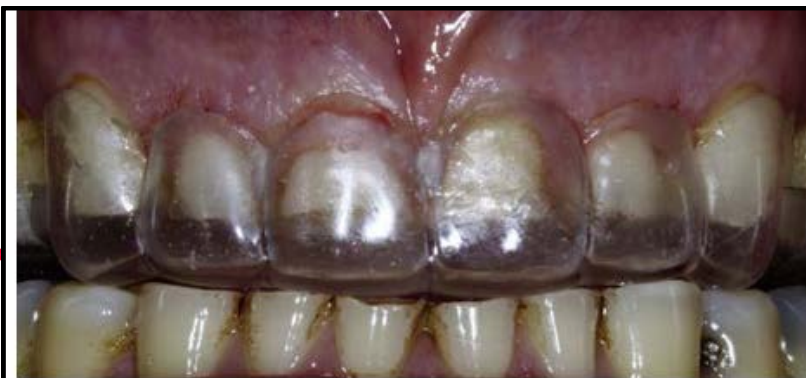TOOTH WEAR



• **Fig. 61.2** Maxillary and mandibular study casts articulated on a semi-adjustable articulator and a diagnostic wax-up of the anterior maxillary and mandibular dentition at an increased vertical dimension of occlusion.

THIS IS COPYRIGHTED CONTENT. Unauthorized use, including screenshots, copying, misuse, reuse, or sale of any content from this app, is strictly prohibited. Our app monitors and records all screenshots and recordings. Violators will face strict legal action.

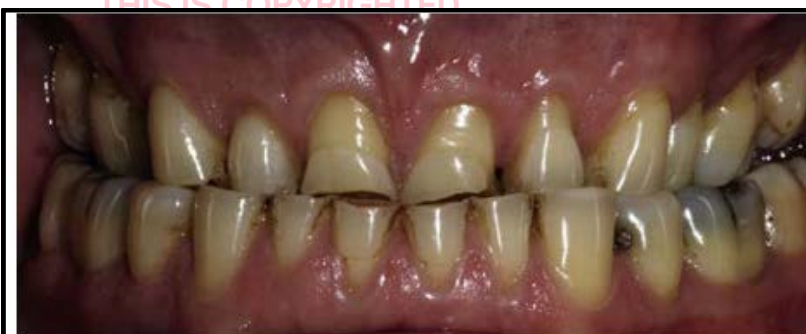(Source: Odell)



• **Fig. 61.4** The vacuum-formed stent in situ, indicating the level of gingival tissue removal required.

THIS IS COPYRIGHTED CONTENT. Unauthorized use, including screenshots, copying, misuse, reuse, or sale of any content from this app, is strictly prohibited. Our app monitors and records all screenshots and recordings. Violators will face strict legal action.

(Source: Odell)



• **Fig. 61.3** The maxillary anterior teeth after surgical crown lengthening. Note the apical repositioning of the gingival margin. This will provide increased surface area for bonding of restorations or an improved axial wall height for subsequent indirect crown preparations.

(Source: Odell)

TOOTH WEAR

Management:

- The identification of the cause and addressing any triggers is the first step in managing any tooth wear cases.
- As bruxism remains the primary cause of attrition, the identification of sleep and awake bruxism will determine the treatment plan accordingly.

Sleep bruxism can be managed by:

- Avoiding risk factors.
- Relaxation techniques
- Hypnotherapy
- Biofeedback
- Cognitive behavioural therapy (CBT)
- Improving sleep hygiene

Awake bruxism can be managed by:

- Habit recognition and reversal
- Stress management: To protect the teeth from attrition during sleep bruxism Full coverage intraoral appliances (Splints or dental guards) can be used. These appliances not only protect the teeth but also reduce muscle strain and loading of temporomandibular joints.

For managing, erosive tooth wear with severe loss of tooth structure refer to H.O.T Notes of erosion.

THIS IS COPYRIGHTED CONTENT. Unauthorized use, including screenshots, copying, misuse, reuse, or resale of any content from this app, is strictly prohibited. Our app monitors and records all screenshots and recordings. Violators will face strict legal action.

DISCLAIMER

THIS IS COPYRIGHTED CONTENT. Unauthorized use, including screenshots, copying, misuse, reuse, or resale of any content from this app, is strictly prohibited. Our app monitors and records all screenshots and recordings. Violators will face strict legal action.

THIS IS COPYRIGHTED CONTENT. Unauthorized use, including screenshots, copying, misuse, reuse, or resale of any content from this app, is strictly prohibited. Our app monitors and records all screenshots and recordings. Violators will face strict legal action.

THIS IS COPYRIGHTED CONTENT. Unauthorized use, including screenshots, copying, misuse, reuse, or resale of any content from this app, is strictly prohibited. Our app monitors and records all screenshots and recordings. Violators will face strict legal action.

DISCLAIMER
THIS IS COPYRIGHTED CONTENT. Unauthorized use, including screenshots, copying, misuse, reuse, or resale of any content from this app, is strictly prohibited. Our app monitors and records all screenshots and recordings. Violators will face strict legal action.

TOOTH WEAR

ABRASION

Abnormal tooth surface loss resulting from direct frictional force between teeth and external objects or from frictional forces between contacting teeth in the presence of abrasive medium is known as abrasion. (Source -Sturdevant)

It is the wear of dental hard tissues which is caused by physical means other than teeth grinding together. (Source-Odell)

Etiology- The etiology of the lesion is multifactorial .

Cervical abrasion is most commonly associated with toothbrush trauma.

Habitual chewing on hard objects (e.g., paper clips, pens, pencils) or chronic use of agents with high abrasivity (e.g., smokeless tobacco, inadequately washed vegetables) may result in loss of occlusal-surface tooth structure. (Source-Sturdevant)

- Cervical abrasion is commonly seen as a rounded notch in the gingival portion of the facial aspects of the teeth.

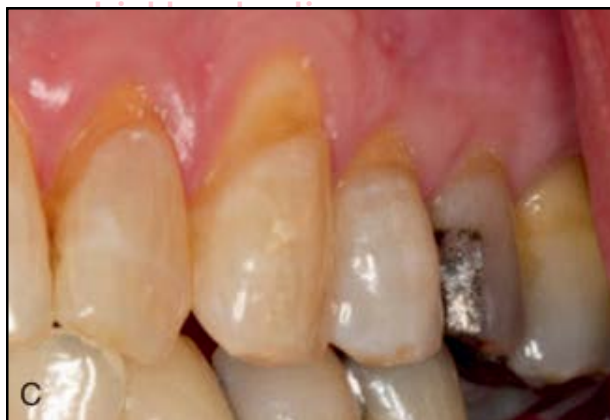

Fig: Rounded cervical lesion associated with toothbrush abrasion (Source-Sturdevant)

- These lesions are also commonly referred to as NCCL (Non Carious Cervical Lesions).
- The presence of these lesions does not automatically warrant intervention.

DISCLAIMER

THIS IS COPYRIGHTED CONTENT. Unauthorized use, including screenshots, copying, misuse, reuse, or resale of any content from this app, is strictly prohibited. Our app monitors and records all screenshots and recordings. Violators will face strict legal action.

DISCLAIMER
THIS IS COPYRIGHTED CONTENT. Unauthorized use, including screenshots, copying, misuse, reuse, or resale of any content from this app, is strictly prohibited. Our app monitors and records all screenshots and recordings. Violators will face strict legal action.

DISCLAIMER

THIS IS COPYRIGHTED CONTENT. Unauthorized use, including screenshots, copying, misuse, reuse, or resale of any content from this app, is strictly prohibited. Our app monitors and records all screenshots and recordings. Violators will face strict legal action.

TOOTH WEAR

ABFRACTION

Abfractions are cervical, wedge-shaped defects which are angular as opposed to rounded-like in abrasion but in abfraction the possible causative factor may include excessive flexure of the tooth as a result of heavy, eccentric occlusal forces. The heavy occlusal loading may also result in development of pronounced occlusal wear facet. (Source-Sturdevant)

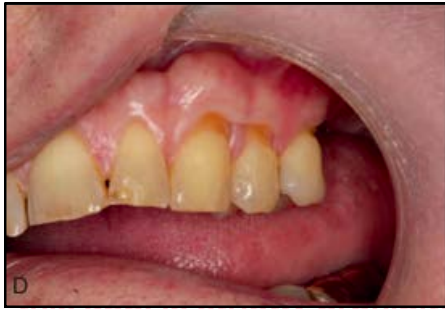

Fig: Idiopathic erosion lesions in cervical areas are hypothesized to be associated with abnormal. (Source-Sturdevant)

It is hypothesized that the flexural force produces tension stress in the affected wedge-shaped region on the tooth side, away from the tooth-bending direction, resulting in loss of the surface tooth structure by microfractures, which is termed abfraction. Proponents of this hypothesis add that microfractures may increase the rate of tooth structure loss during abrasion from tooth brushing and/ or from acids in the diet or biofilm. Opponents of this hypothesis note that these cervical lesions have been detected in individuals who do not have any apparent evidence of heavy occlusal forces (such as wear facets and/or fremitus). The general consensus among experts is that the etiology of these lesions (both abrasion and abfraction) is multifactorial and that well-designed clinical research studies are required to gain better understanding relative to the etiology of cervical abrasion and abfraction defects, which are generally referred to as noncarious cervical lesions (NCCLs).

Management of Non Carious Cervical lesions (NCCLs) (Abrasion and abfraction).

- Although presence of these lesions does not automatically warrant intervention, Restoration is a preferred option.
- Microfilled composites are the material of choice to treat NCCLs.

2. Better overall survival rates were observed for CRs compared with RMGICs and GICs for restoring class V lesions in participants after HNRT.

• Fig: Reference from live class. *CR-Composite restorations

- Hybrid composites are however associated with pop off dislodgement of restorations as hybrid composites have higher modulus of elasticity so is not flexible (more stiff) hence the restoration cannot withstand the pressure caused by flexure of tooth structure.

DISCLAIMER

THIS IS COPYRIGHTED CONTENT. Unauthorized use, including screenshots, copying, misuse, reuse, or resale of any content from this app, is strictly prohibited. Our app monitors and records all screenshots and recordings. Violators will face strict legal action.

DISCLAIMER
THIS IS COPYRIGHTED CONTENT. Unauthorized use, including screenshots, copying, misuse, reuse, or resale of any content from this app, is strictly prohibited. Our app monitors and records all screenshots and recordings. Violators will face strict legal action.

THIS IS COPYRIGHTED CONTENT. Unauthorized use, including screenshots, copying, misuse, reuse, or resale of any content from this app, is strictly prohibited. Our app monitors and records all screenshots and recordings. Violators will face strict legal action.

DISCLAIMER

CRACKED TOOTH

Cracks and Fractures are relatively common problems in dental practice. According to American Association of Endodontic 1997 classification, longitudinal tooth fractures are divided into 5 types.

- Craze lines
- Fractured cusp
- Cracked tooth
- Split tooth
- Vertical root fracture

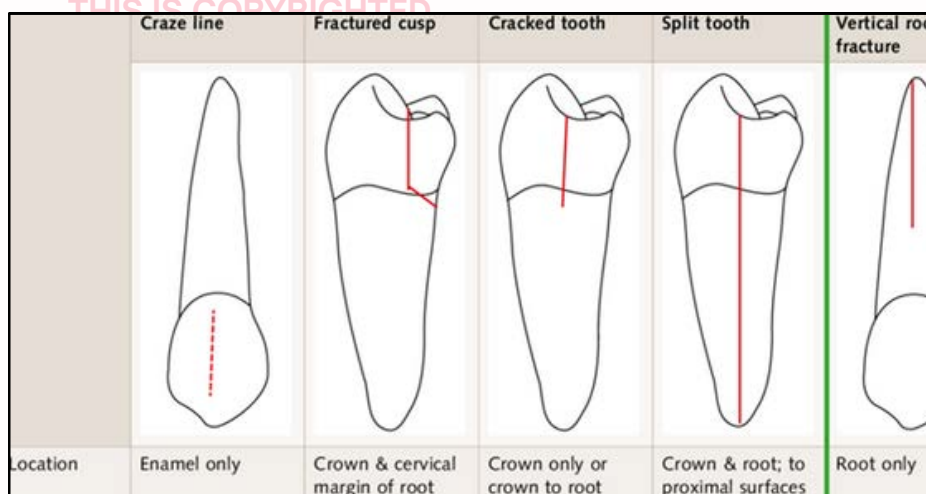


Fig: Classification of longitudinal fractures (adapted from Rivera & Walton 2009)

- **Craze lines** are limited to enamel (i.e. they do not progress through DEJ into dentin) (Source-Sturdevant 7th edition)
- **Fractured cusp** - A fracture is a defect where there is a break between two parts and the fragments have separated. Complete cusp fracture is commonly seen on posterior teeth. Most frequently fractured cusps are Non -Functional Cusps. Specifically most frequently fractured teeth are Mandibular molars and second premolars (Lingual cusp fracture more often which is a Nonfunctional cusp). Maxillary premolars also frequently fracture where buccal cusp-Non-functional cusp, fractures more often.) (Source-Sturdevant 7th edition)
- **Cracked tooth** is defined as an incomplete fracture originating from the crown and sometimes extending subgingivally. The prevalence of crack varies from 10%-70 %. (Source-Article ADJ cracked tooth)
- **Split tooth**: The crack extends from crown runs down the root surface and splits the teeth in two parts, which is often a result of an untreated cracked tooth.
- **Vertical root fracture**: Vertical cracks that extends in the root towards the apex.

DISCLAIMER

THIS IS COPYRIGHTED CONTENT. Unauthorized use, including screenshots, copying, misuse, reuse, or resale of any content from this app, is strictly prohibited. Our app monitors and records all screenshots and recordings. Violators will face strict legal action.

THIS IS COPYRIGHTED CONTENT. Unauthorized use, including screenshots, copying, misuse, reuse, or resale of any content from this app, is strictly prohibited. Our app monitors and records all screenshots and recordings. Violators will face strict legal action.

THIS IS COPYRIGHTED CONTENT. Unauthorized use, including screenshots, copying, misuse, reuse, or resale of any content from this app, is strictly prohibited. Our app monitors and records all screenshots and recordings. Violators will face strict legal action.

DISCLAIMER
THIS IS COPYRIGHTED CONTENT. Unauthorized use, including screenshots, copying, misuse, reuse, or resale of any content from this app, is strictly prohibited. Our app monitors and records all screenshots and recordings. Violators will face strict legal action.

CRACKED TOOTH

CRACK TOOTH

- A crack is a defect where there is break in two parts but without separation of fragments. A crack in a tooth involves Enamel and dentin and/Cementum, Crack may also extend to pulp space in some cases.
- A crack just as fracture may or may not cause pulpal disease and periradicular disease, Depending on whether the bacteria can penetrate the tooth via the crack to reach the pulp space. (Source-Article on crack tooth syndrome)

Signs and symptoms: (Source- Articles on crack tooth)

- There is no classic symptoms for cracks.
- The presenting symptoms are dependent on the underlying disease processes in the dental pulp and periradicular tissues that have been cause by the crack.
- Cracked teeth present a clinical challenge mainly due to non-specificity of their symptoms.
- The symptoms ranged from : (Either appearing alone or in combinations)
 1. Pain on biting (most frequent symptom that makes clinicians suspect a crack tooth)
 2. Sensitivity to cold
 3. Spontaneous pain
 4. Asymptomatic with minimal clinical progression
 5. Sensitivity to heat
 6. Pain on application and release of pressure.
 7. Crack tooth also has been associated undiagnosed diffuse long standing pain of 3 months without the presence of sensitivity to cold or pain on biting.

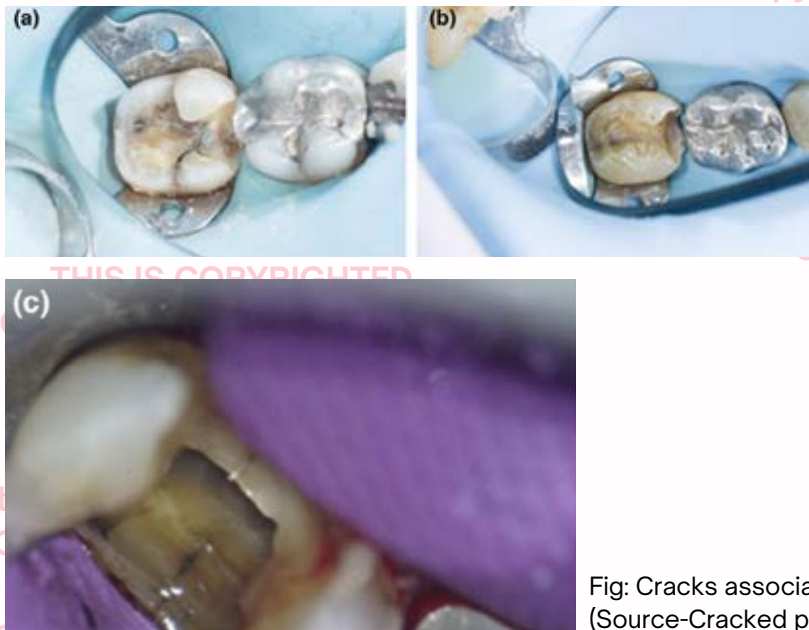


Fig: Cracks associated with posterior tooth
(Source-Cracked posterior tooth article)

DISCLAIMER

THIS IS COPYRIGHTED CONTENT. Unauthorized use, including screenshots, copying, misuse, reuse, or resale of any content from this app, is strictly prohibited. Our app monitors and records all screenshots and recordings. Violators will face strict legal action.

THIS IS COPYRIGHTED CONTENT. Unauthorized use, including screenshots, copying, misuse, reuse, or resale of any content from this app, is strictly prohibited. Our app monitors and records all screenshots and recordings. Violators will face strict legal action.

DISCLAIMER
THIS IS COPYRIGHTED CONTENT. Unauthorized use, including screenshots, copying, misuse, reuse, or resale of any content from this app, is strictly prohibited. Our app monitors and records all screenshots and recordings. Violators will face strict legal action.

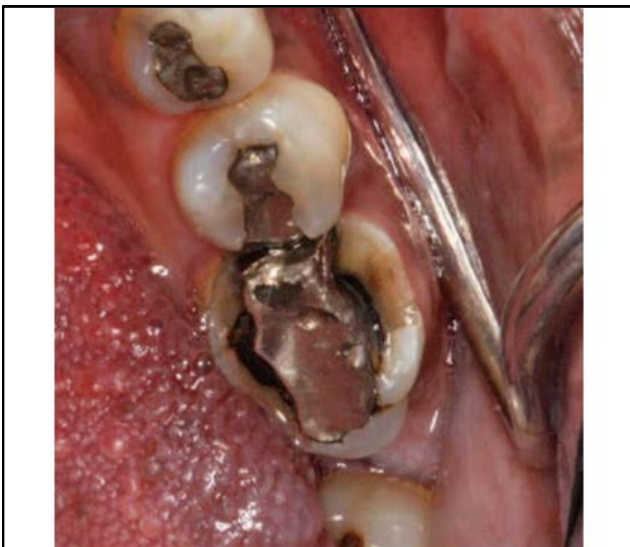CRACKED TOOTH

Biomechanics of crack progression: (Source -Article on cracked posterior tooth)

- The biomechanics of crack initiation and propagation is dependent on three major factors: Materials properties, loading factors and environmental issues.
- Coronal dentin demonstrates a significant resistance to progressive crack extension compared to deeper dentin.
- Toughening mechanisms within the dentin includes:
 - a) Crack deflection and shielding.
 - b) Uncracked ligament bridges
 - c) Filled dentinal tubules causing deflection and bridging.
- These mechanisms prevent the cracks from travelling linearly, which explains the relative slow progression of cracks through coronal dentin.

Predisposing factors for crack/fractures:

- Teeth with extensive caries.
- Teeth with large restorations (most commonly associated)
- Teeth where remaining cusps have little dentin support.
- Anatomically deep developmental fissures that cross between marginal or cusp ridges also predispose posterior tooth to fracture.
- Heavy occlusal loading with clenching, grinding or bruxing of teeth.



• **Fig. 3.10** Extensively restored teeth with weakened and fractured cusps. Note the distal developmental fissure in the second molar, which further predisposes the distal cusps to fracture.

Fig: Source (Sturdevant 7th edition)

DISCLAIMER

THIS IS COPYRIGHTED CONTENT. Unauthorized use, including screenshots, copying, misuse, reuse, or resale of any content from this app, is strictly prohibited. Our app monitors and records all screenshots and recordings. Violators will face strict legal action.

DISCLAIMER
THIS IS COPYRIGHTED CONTENT. Unauthorized use, including screenshots, copying, misuse, reuse, or resale of any content from this app, is strictly prohibited. Our app monitors and records all screenshots and recordings. Violators will face strict legal action.

DISCLAIMER

THIS IS COPYRIGHTED CONTENT. Unauthorized use, including screenshots, copying, misuse, reuse, or resale of any content from this app, is strictly prohibited. Our app monitors and records all screenshots and recordings. Violators will face strict legal action.

THIS IS COPYRIGHTED CONTENT. Unauthorized use, including screenshots, copying, misuse, reuse, or resale of any content from this app, is strictly prohibited. Our app monitors and records all screenshots and recordings. Violators will face strict legal action.

THIS IS COPYRIGHTED CONTENT. Unauthorized use, including screenshots, copying, misuse, reuse, or resale of any content from this app, is strictly prohibited. Our app monitors and records all screenshots and recordings. Violators will face strict legal action.

CRACKED TOOTH

Investigations: (Source Articles, Odell)

- "The path of the crack" must be determined as far as possible because this will determine the treatment options.
- The ability to visualize the break in continuity of the tooth structure varies on the location of the crack.
- The first step in the investigation of the tooth involves removal of all restorations, caries and cracks from the teeth.
- The teeth should then be assessed to determine whether there is a pulp exposure.
- Selective cuspal loading / Tooth sleuth is used to identify the cusp or cusps which are cracked.
- Various tools such as magnification, Transillumination, quantitative light induced fluorescence and laser may aid in visualization of cracks, though with varying degree of accuracy.
- The various investigations for identifying the causative tooth, in case of suspected cracks are:

Investigation	Significance
Tests of sensibility of all teeth in the upper right quadrant should be performed, either with an electric pulp tester or a cold stimulus.	The pain must originate from a vital tooth. It is also possible that the cracked tooth might be hypersensitive. This could aid diagnosis though hypersensitivity to testing would not be expected in the absence of pain on eating hot and cold foods. Vitality might also affect the choice of treatment.
Close examination with a good light (bright fiberoptic light is especially useful for transillumination). A soluble dye such as a disclosing agent may be painted onto the crown. After the excess is washed off, small amounts may remain in the crack, rendering it visible.	May reveal a crack.
Attempts to stimulate the pain by pressing the handle of an instrument against each cusp, preferably from more than one direction.	Pain indicates a cracked cusp, and the causative cusp is identified.
Asking the patient to bite hard on a soft object such as a cotton wool roll.	This transmits pressure to the whole occlusal surface and forces the cusps slightly apart. Pain on biting suggests a cracked tooth.
Placing a wooden wedge/tooth sleuth against each cusp in turn and asking the patient to bite on each.	This is a more selective test to identify the cusp or cusps which are cracked. By placing the wedge on different surfaces of the cusp, it may be possible to tell in which direction the crack runs. There may be pain on biting, but pain that is worse on release of pressure is said to be characteristic.
Radiography	To exclude the possibility of caries and to assess the feasibility of root filling, the tooth should be necessary. Radiography is unlikely to be of direct help in diagnosis and may not be necessary if other investigations successfully identify the cracked cusp.

Fig: Source - Odell Case 11

- The most effective diagnostic tools for crack tooth are pain on biting replicators- FrackFinder or Tooth Slooth.

DISCLAIMER

THIS IS COPYRIGHTED CONTENT. Unauthorized use, including screenshots, copying, misuse, reuse, or resale of any content from this app, is strictly prohibited. Our app monitors and records all screenshots and recordings. Violators will face strict legal action.

CRACKED TOOTH

Diagnosis: (Source -Articles)

- The proper diagnosis of the pulp status is necessary to determine the management options.
- Based on extent of pulpal involvement, in a crack tooth, a provisional diagnosis of crack tooth with reversible pulpitis or irreversible pulpitis can be made.
- Only a provisional diagnosis of reversible pulpitis can be made which needs to be confirmed and this can only be done when the pulp recovers that requires at least 6-8 weeks.
- A 3 month period provides a longer time period to enable the operator to distinguish between pulp necrosis and a clinically normal pulp-both of which are symptomless.

Management of cracks:

- The general management of cracked tooth involves immobilizing the cracked segments to prevent symptoms and crack progression concurrent with adequate treatment that addresses the pulp status.(Article)
- Immobilization can be accomplished in short term with orthodontic banding, occlusal adjustment or composite resin splinting, while long term management may be through mechanical splinting with direct or indirect cuspal restorations.
- So broadly two types of treatment modalities are present-
 - a) Single stage treatment with definitive restoration.
 - b) Multistage treatment which involves an interim phase to monitor pulpal conditions.

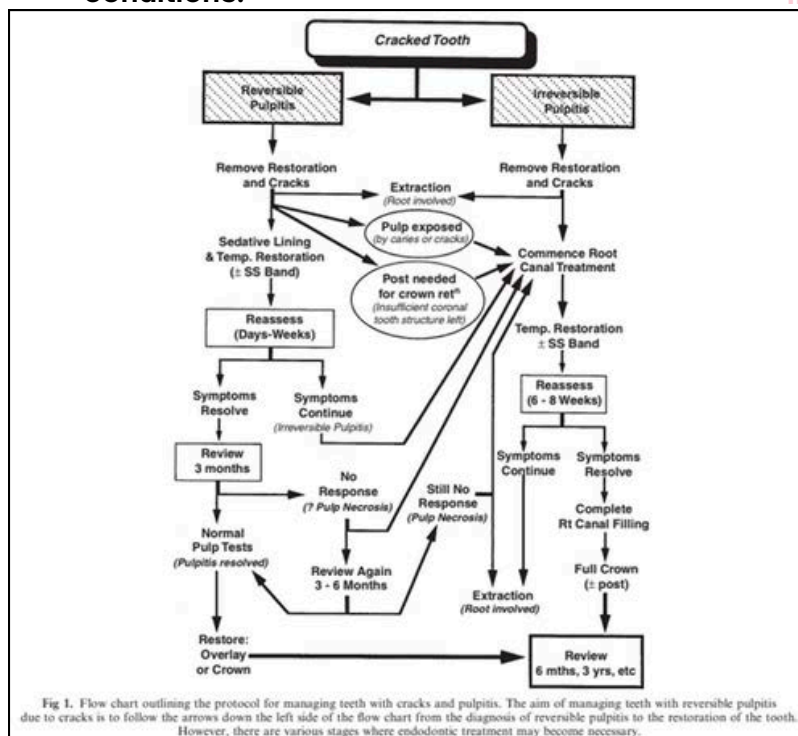


Fig: Source-article on crack tooth syndrome

DISCLAIMER

THIS IS COPYRIGHTED CONTENT. Unauthorized use, including screenshots, copying, misuse, reuse, or resale of any content from this app, is strictly prohibited. Our app monitors and records all screenshots and recordings. Violators will face strict legal action.

DISCLAIMER
THIS IS COPYRIGHTED CONTENT. Unauthorized use, including screenshots, copying, misuse, reuse, or resale of any content from this app, is strictly prohibited. Our app monitors and records all screenshots and recordings. Violators will face strict legal action.

CRACKED TOOTH

- Cracked tooth associated with pretreatment probing depth of less than 6 mm has better prognosis after being endodontically treated than a tooth with deeper probing depths.(Article)
- The various restoration options for cracked teeth/Cusps with their advantages and disadvantages is given in the table below:

Option	Advantages and Disadvantages
No treatment	This is not an option, even if the patient is willing to put up with the pain. Cracks may propagate into the pulp, allow bacterial contamination and devitalize the tooth.
Removal of the cracked portion, followed by restoration	This is unsafe. Levering of the cracked portion risks a catastrophic fracture with pulpal communication. Many cracks are incomplete and leverage may propagate them in unpredictable directions. Occasionally, the fragment will be limited to the enamel and dentine of the crown, particularly where the tooth already contains a large restoration undermining the cusp, but even then a deliberate fracture is not recommended.
Full- or partial-coverage indirect gold restoration	This is the treatment of choice. The preparation should finish supragingivally, wherever possible. Gold is malleable and allows some plastic deformation, which is not possible with ceramics or composites, which are more brittle. Full occlusal coverage is needed to protect the tooth from further damage, and a casting can provide some splinting, reducing the potential for further cracks.
Full-coverage bonded porcelain crown	Full coverage with porcelain bonded to metal has the advantage of better appearance, but the ceramic is brittle. This disadvantage may be offset by using an adhesive to lute the crown. There is then the potential for the crack to be sealed by the infiltrating cement.
Adhesive restoration	In theory, an adhesive restoration would cement the crack and prevent movement of the two fragments. However, on curing, adhesive materials undergo polymerization shrinkage, which places further stress on the crack and may propagate it further. Modern adhesive restorative materials undergo significantly less shrinkage, so this option may be indicated.
Porcelain inlay/onlay	These have the same disadvantages of metal-fused-to-porcelain crowns.

Fig: Source-Odell Case 11

CARIES DIAGNOSIS

Caries Diagnosis should imply the human professional summation of all signs and symptoms of the disease to identify of the past or present occurrence of caries.

Caries detection and assessment is necessary to come to a caries diagnosis.

Caries detection is an objective method of determining whether the disease is present by observing changes in enamel, dentin and cementum which are consistent with having caused by caries.

Caries assessment aims to characterize the lesions once detected as active, inactive or arrested using parameters such as color, size and surface integrity, relationship to plaque stagnation.

The caries diagnosis depends on Clinical examination and Radiographic evaluation. Visual and tactile examination of each accessible surface should be completed to determine the presence of caries or sound surface, after that the site of lesion origin, surfaces involved, extent, Activity and level of severity also helps determine the classification of the carious lesion.

CLINICAL EXAMINATION: (Source-Articles)

- The first step involves removal of bulk of plaque. This is done as caries mostly occur under biofilm (plaque), so the surfaces are cleaned by instructing the patient to brush their teeth or professionally cleaning the teeth and using floss to clean the interproximal areas.
- Saliva is also a factor which often disguises enamel alterations, so **Refractive index (n)** of enamel is important.
- Sound enamel is translucent with Refractive index (n) of 1.6.
- When the enamel is wet, the index is reduced to 1.3 (this happens as the enamel pores fills with water). When caries /Demineralized Refractive index (n) is again decreased from normal as enamel porosity absorb more water so caries extending only till enamel may not be visible when wet.
- So, isolation with cotton rolls followed by air drying for 5 sec is necessary to detect caries involving Enamel only. As it is difficult to detect when wet.
- But, if the lesion is extended to dentin and the lesion creates gray shadow under enamel when wet so detection is easy on wet surface.
- Hence, for accurate detection of caries : Firstly, examine when wet to detect the caries in dentin
- Secondly, air dry for 5 sec to detect enamel caries.

DISCLAIMER

THIS IS COPYRIGHTED CONTENT. Unauthorized use, including screenshots, copying, misuse, reuse, or resale of any content from this app, is strictly prohibited. Our app monitors and records all screenshots and recordings. Violators will face strict legal action.

DISCLAIMER
THIS IS COPYRIGHTED CONTENT. Unauthorized use, including screenshots, copying, misuse, reuse, or resale of any content from this app, is strictly prohibited. Our app monitors and records all screenshots and recordings. Violators will face strict legal action.

DISCLAIMER
THIS IS COPYRIGHTED CONTENT. Unauthorized use, including screenshots, copying, misuse, reuse, or resale of any content from this app, is strictly prohibited. Our app monitors and records all screenshots and recordings. Violators will face strict legal action.

CARIES DIAGNOSIS

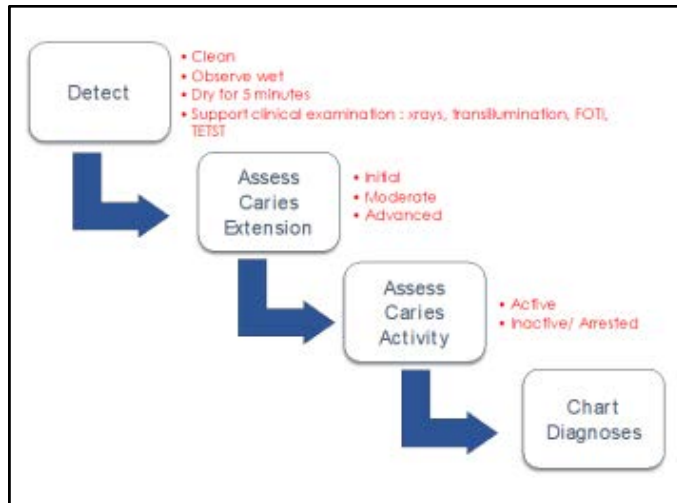


Fig: Source - Tufts Article on Caries Detection

Sharp eyes and Blunt ball ended probe is used for Visual and tactile examination. Use of explorer or sharp instrument leads to micro cavitation of non cavitated lesions.

Status of each carious lesion: The ICDAS (International Caries Detection and Assessment System) Scoring system is a visual classification system for assessing and scoring caries based on the severity of the lesion. The **ICDAS II** is more refined and precise version of ICDAS scoring.

Codes include from 0-6, Code (1-3) relate to increasingly progressive stages of enamel lesion and Code (4-6) relates to increasingly progressive stages of dentine lesion.

- **CODE 0:** Sound Tooth Surface: No evidence of caries, the tooth appears sound, with no caries-related discoloration or opacity after air drying.
- **CODE 1:** First Visual Change in Enamel: A white or brown opacity (non-cavitated lesion) appears on enamel surface or pits and fissures that can be detected only after drying the tooth surface (5 seconds with air)
- **CODE 2:** Distinct Visual Change in enamel: White or brown opacity visible without air drying (i.e. When wet)
- **CODE 3:** Localized Enamel Breakdown (no visible dentin): Represents a white or brown spot with enamel loss at surface level. There is Localized breakdown of enamel surface, creating a small cavity or rough area. Here the lesion has not extended to the dentin.
- **CODE 4:** Underlying dark shadow from dentin (No cavitation): A dark shadow (gray/brown) is visible through the enamel suggesting the caries has extended to the dentin. Surface may appear intact or minimally broken.
- **CODE 5:** Distinct Cavity with Visible Dentin: A cavity is clearly visible, with dentin exposed and accessible to visual inspection.
- **CODE 6:** Extensive Distinct Cavity with Visible Dentin: A large, extensive cavity (Frank cavitation) with visible dentin and significant structural loss of the tooth.

DISCLAIMER

THIS IS COPYRIGHTED CONTENT. Unauthorized use, including screenshots, copying, misuse, reuse, or resale of any content from this app, is strictly prohibited. Our app monitors and records all screenshots and recordings. Violators will face strict legal action.

DISCLAIMER

THIS IS COPYRIGHTED CONTENT. Unauthorized use, including screenshots, copying, misuse, reuse, or resale of any content from this app, is strictly prohibited. Our app monitors and records all screenshots and recordings. Violators will face strict legal action.

THIS IS COPYRIGHTED CONTENT. Unauthorized use, including screenshots, copying, misuse, reuse, or resale of any content from this app, is strictly prohibited. Our app monitors and records all screenshots and recordings. Violators will face strict legal action.

DISCLAIMER

CARIES DIAGNOSIS

Table 2. The International Caries Detection and Assessment System (ICDAS II) criteria for smooth, pit/fissure surfaces, and CARS*

When wet, surfaces may reveal... Normal appearance	White or brown spot lesions	A shadow from dentine plus/minus enamel loss	Cavitation with exposed dentine	Extensive cavitation
Code 0 or 1?	Code 2 or 3?	Code 4	Code 5	Code 6
But drying for 5 seconds exposes...				
Nothing else Code 0	Nothing else Code 2			
White or brown spot lesions Code 1	Enamel loss Code 3			

*Caries along restorations and sealants. Note that a non-carious defect along a restoration or sealant margin would be coded 0.

Image-Source (Evans Article)

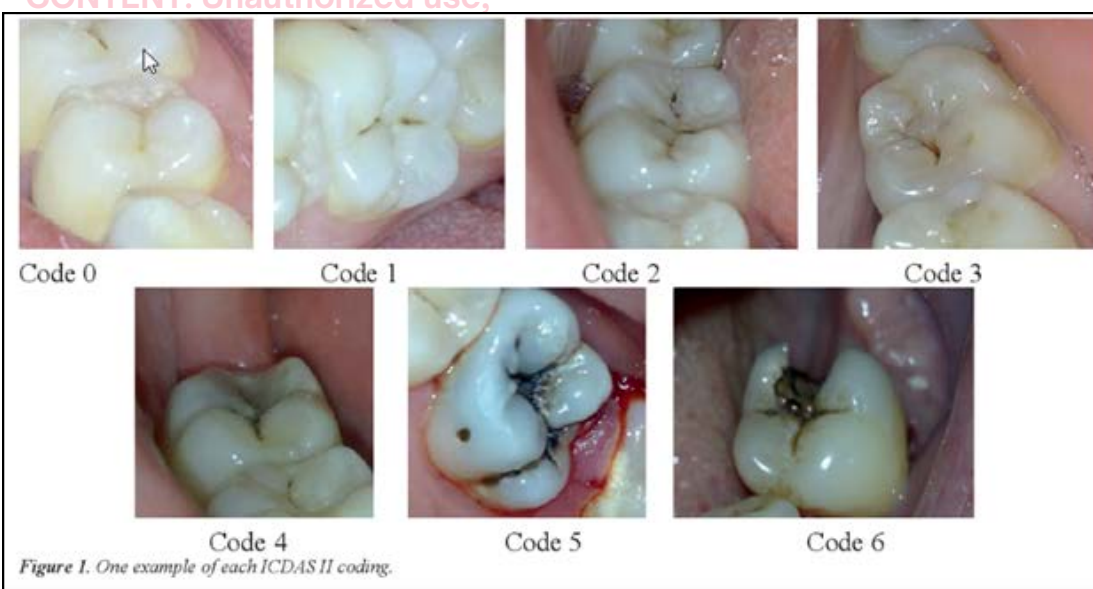


Fig: image showing ICDAS CODES (Source- Internet)

To support the clinical examination the following can be done:

- **Radiographic examination:** Radiographs with bitewing technique are highly sensitive for detecting proximal caries that cannot be detected visually, it also helps in estimating the depth of lesion and monitoring disease progression.
- **Temporary Elective tooth separation technique (TETST):** This will allow direct visual access to the proximal surfaces. A small elastomeric band is kept between teeth around contact areas for 2 hours to 7 days and removed at 2nd visit.

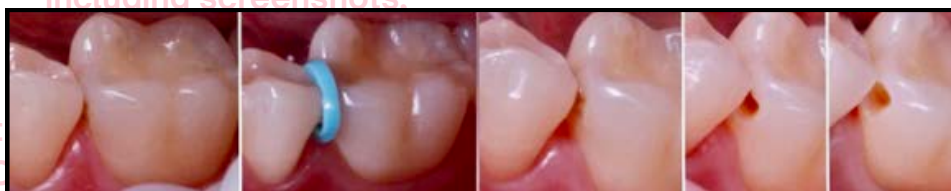

Fig: TETST (Source- Tufts Article)

DISCLAIMER

THIS IS COPYRIGHTED CONTENT. Unauthorized use, including screenshots, copying, misuse, reuse, or resale of any content from this app, is strictly prohibited. Our app monitors and records all screenshots and recordings. Violators will face strict legal action.

DISCLAIMER
THIS IS COPYRIGHTED CONTENT. Unauthorized use, including screenshots, copying, misuse, reuse, or resale of any content from this app, is strictly prohibited. Our app monitors and records all screenshots and recordings. Violators will face strict legal action.

THIS IS COPYRIGHTED CONTENT. Unauthorized use, including screenshots, copying, misuse, reuse, or resale of any content from this app, is strictly prohibited. Our app monitors and records all screenshots and recordings. Violators will face strict legal action.

DISCLAIMER

CARIES DIAGNOSIS

- **Fiber-optic trans illumination (FOTI):** It is based on the phenomenon of light scattering to increase the contrast between normal and carious enamel. A high intensity white light from a fiber optic hand piece should be used with deemed room lightening and without the use of operating light. The light probe is placed above the gingival margin of the tooth, For posterior proximal caries the tooth should be illuminated from both buccal and lingual aspects and observed from the occlusal surface. For anterior proximal caries the tooth is illuminated from buccal surface and observed from the lingual surface.

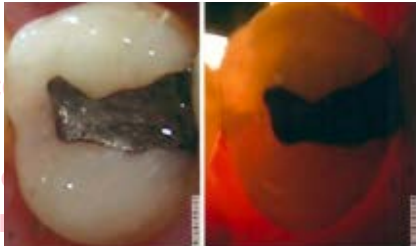


Fig: FOTI (Source- Tufts Article)

- **Quantitative Light induced Fluorescence (QLF):** It is also based on fluorescence. When a lesion is present, an increase light scattering makes the lesion appear as dark spots on a bright green background.

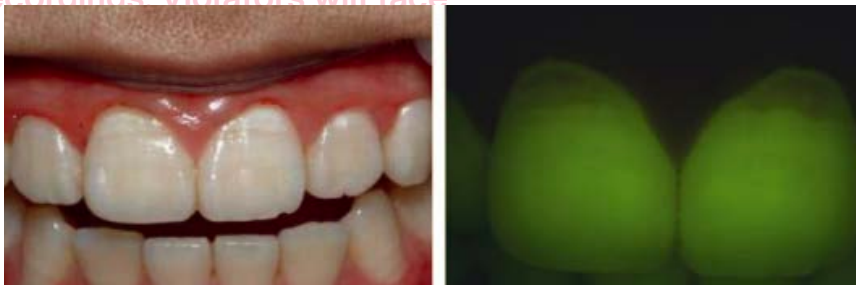

Fig: Source-TUFTS article

- Once a carious lesion is detected the severity of the lesion (initial, moderate, advanced) and the activity status (Active or Arrested) should also be determined.
- Areas that are more susceptible to develop carious lesion depending on patients age should be examined thoroughly (E.g. for younger patients-pit and fissures and proximal surfaces, old age-root caries)
- Amongst the fissure anatomy (U,V,I and Bottle type) I and bottle type is more susceptible as it is narrower and more difficult to clean.
- Initial lesions appear as white spot lesions.
- Although color (lighter brown color in active lesions) occurs and texture (Softness) is the best indicator of active lesion.
- An arrested lesion is dark and hard in texture.

DISCLAIMER

THIS IS COPYRIGHTED CONTENT. Unauthorized use, including screenshots, copying, misuse, reuse, or resale of any content from this app, is strictly prohibited. Our app monitors and records all screenshots and recordings. Violators will face strict legal action.

DISCLAIMER
THIS IS COPYRIGHTED CONTENT. Unauthorized use, including screenshots, copying, misuse, reuse, or resale of any content from this app, is strictly prohibited. Our app monitors and records all screenshots and recordings. Violators will face strict legal action.

THIS IS COPYRIGHTED CONTENT. Unauthorized use, including screenshots, copying, misuse, reuse, or resale of any content from this app, is strictly prohibited. Our app monitors and records all screenshots and recordings. Violators will face strict legal action.

DISCLAIMER

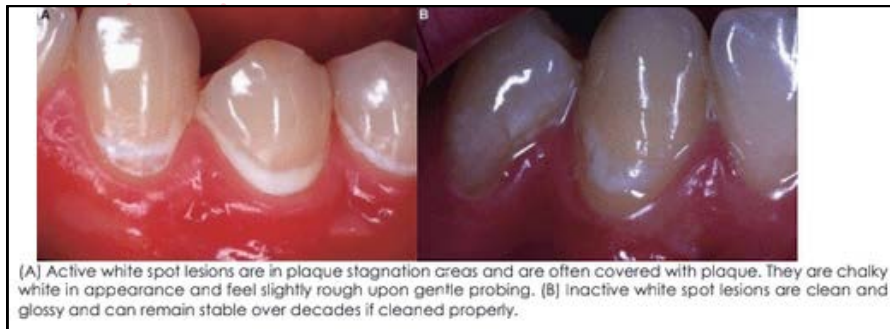CARIES DIAGNOSIS

Assessment of caries activity of carious lesion:

Characteristics of active and inactive caries lesions		
Activity assessment factor	Caries lesion activity assessment descriptors	
	Likely to be inactive/arrested	Likely to be active
Location of the lesion	Lesion is NOT in a biofilm/plaque stagnation area	Lesion is in a biofilm/plaque stagnation area (pit/fissure, approximal, gingival)
Biofilm/Plaque over the lesion	Not thick or sticky	Thick and/or sticky
Surface appearance	Shiny, color: brown, black	Matte/opaque/loss of luster, color: white-yellow
Tactile feeling	Smooth, enamel/ hard dentin	Rough enamel/soft dentin
Gingival status (if the lesion is located near the gingiva)	No inflammation, no bleeding on probing	Inflammation, bleeding on probing

Ekstrand KR, Zero DT, Martignon S, Pitts NB. Lesion activity assessment. Monogr Oral Sci 2009;21:63-90 (See Chaps. 4.1 and 4.3 for additional information on caries activity assessment)

Image: Source- Tufts Article



- Unless frank cavitation is evident, the diagnosis of dentine caries is via radiographic bitewing survey. (Source: Evans Article)

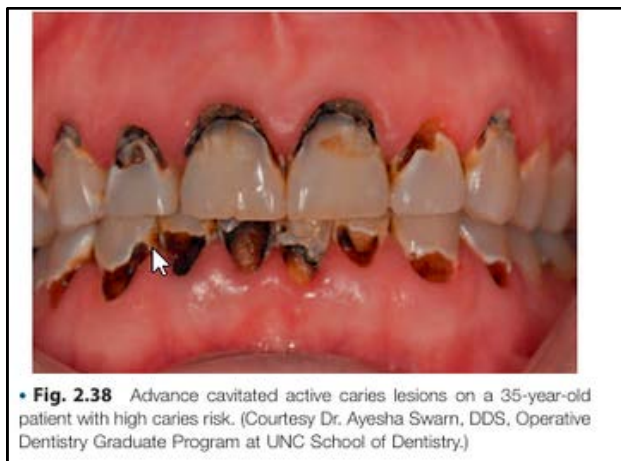

Image: Source- Sturdevant

DISCLAIMER

THIS IS COPYRIGHTED CONTENT. Unauthorized use, including screenshots, copying, misuse, reuse, or resale of any content from this app, is strictly prohibited. Our app monitors and records all screenshots and recordings. Violators will face strict legal action.

DISCLAIMER
THIS IS COPYRIGHTED CONTENT. Unauthorized use, including screenshots, copying, misuse, reuse, or resale of any content from this app, is strictly prohibited. Our app monitors and records all screenshots and recordings. Violators will face strict legal action.

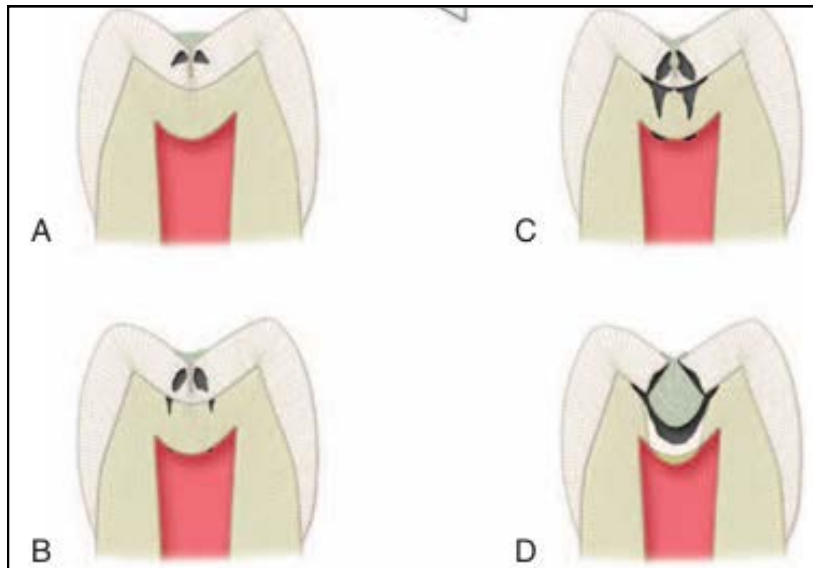
THIS IS COPYRIGHTED CONTENT. Unauthorized use, including screenshots, copying, misuse, reuse, or resale of any content from this app, is strictly prohibited. Our app monitors and records all screenshots and recordings. Violators will face strict legal action.

THIS IS COPYRIGHTED CONTENT. Unauthorized use, including screenshots, copying, misuse, reuse, or resale of any content from this app, is strictly prohibited. Our app monitors and records all screenshots and recordings. Violators will face strict legal action.

THIS IS COPYRIGHTED CONTENT. Unauthorized use, including screenshots, copying, misuse, reuse, or resale of any content from this app, is strictly prohibited. Our app monitors and records all screenshots and recordings. Violators will face strict legal action.

DISCLAIMER

CARIES DIAGNOSIS



• **Fig. 2.16** Progression of caries in pits and fissures. A, Initial lesions develop on the lateral walls of the fissure. Demineralization follows the direction of the enamel rods, spreading laterally as it approaches the dentinoenamel junction (DEJ). B, Soon after the initial enamel lesion occurs, a reaction can be seen in the dentin and pulp. Forceful probing of the lesion at this stage can result in damage to the weakened porous enamel and accelerate the progression of the lesion. Clinical detection at this stage should be based on observation of discoloration and opacification of the enamel adjacent to the fissure. These changes can be observed by careful cleaning and drying of the fissure. C, Initial cavitation of the opposing walls of the fissure cannot be seen on the occlusal surface. Opacification can be seen that is similar to the previous stage. Remineralization of the enamel because of trace amounts of fluoride in the saliva may make progression of pit-and-fissure lesions more difficult to detect. D, Extensive cavitation of the dentin and undermining of the covering enamel darken the occlusal surface (see Fig. 2.17).

Image: Progression of Carious Lesion (Source- Sturdevant)

THIS IS COPYRIGHTED
CONTENT. Unauthorized use,
including screenshots,
copying, misuse, reuse, or
resale of any content from
this app, is strictly prohibited.
Our app monitors and records
all screenshots and
recordings. Violators will face
strict legal action.

DISCLAIMER

THIS IS COPYRIGHTED CONTENT. Unauthorized use, including screenshots, copying, misuse, reuse, or resale of any content from this app, is strictly prohibited. Our app monitors and records all screenshots and recordings. Violators will face strict legal action.

THIS IS COPYRIGHTED
CONTENT. Unauthorized use,
including screenshots,
copying, misuse, reuse, or
sale of any content from
this app, is strictly prohibited.
Our app monitors and records
all screenshots and
recordings. Violators will face
strict legal action.

DISCLAIMER
THIS IS COPYRIGHTED CONTENT. Unauthorized use, including screenshots, copying, misuse, reuse, or resale of any content from this app, is strictly prohibited. Our app monitors and records all screenshots and recordings. Violators will face strict legal action.

THIS IS COPYRIGHTED
CONTENT. Unauthorized use,
including screenshots,
copying, misuse, reuse, or
sale of any content from
this app, is strictly prohibited.
Our app monitors and records
all screenshots and
recordings. Violators will face
strict legal action.

THIS IS COPYRIGHTED CONTENT. Unauthorized use, including screenshots, copying, misuse, reuse, or resale of any content from this app, is strictly prohibited. Our app monitors and records all screenshots and recordings. Violators will face strict legal action.

DISCLAIMER

CARIES DIAGNOSIS

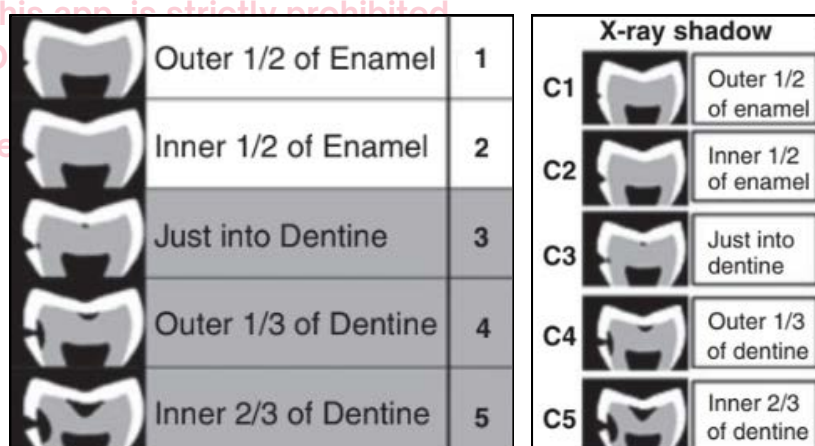
Radiographic Examinations - (Source: Evans Article)

- Radiolucencies are scored according to five category system proposed by Mejare.

Table 3. Criteria for scoring bitewing radiolucencies on occlusal and approximal surfaces (after Mejare, 1999)

Criteria for Bitewing Radiolucency Scores	
C0	No radiolucency evident (not recorded)
C1	Radiolucency is evident within the <i>outer half</i> of enamel
C2	Radiolucency extends to the <i>inner half</i> of enamel and may reach the DEJ
C3	Radiolucency extends <i>just beyond</i> the DEJ
C4	Radiolucency is evident within the <i>outer third</i> of dentine
C5	Radiolucency extends to the <i>inner two thirds</i> of dentine and may reach the pulp

Image: Source- Evans Article



- In water fluoridated community, Radiographic evaluation is preferred over visual and tactile examination for caries detection due to incidence of occult/hidden caries. (Where there is subsurface demineralization that starts at dentin beneath the enamel and enamel can look normal.) (Source-Odell)
- The management will depend on the extent of the carious lesion after following the diagnostic criteria with both clinical and radiographic examination.

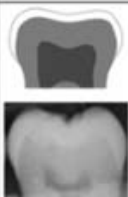
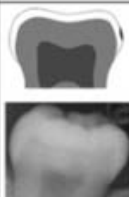


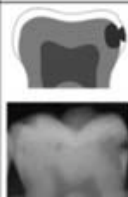

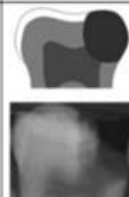
Description	No radiolucency	Radiolucency in the outer half of the enamel	Radiolucency in the inner half of the enamel ± EDJ (enamel-dentin junction)	Radiolucency limited to the outer one-third of dentin	Radiolucency reaching the middle one-third of dentin	Radiolucency reaching the inner one-third of dentin, clinically cavitated	Radiolucency into the pulp, clinically cavitated
Schematic and radiographic examples							

Fig: Image showing schematic and radiographic carious lesions (Source-Internet)

DISCLAIMER

THIS IS COPYRIGHTED CONTENT. Unauthorized use, including screenshots, copying, misuse, reuse, or resale of any content from this app, is strictly prohibited. Our app monitors and records all screenshots and recordings. Violators will face strict legal action.

DISCLAIMER
THIS IS COPYRIGHTED CONTENT. Unauthorized use, including screenshots, copying, misuse, reuse, or resale of any content from this app, is strictly prohibited. Our app monitors and records all screenshots and recordings. Violators will face strict legal action.

THIS IS COPYRIGHTED CONTENT. Unauthorized use, including screenshots, copying, misuse, reuse, or resale of any content from this app, is strictly prohibited. Our app monitors and records all screenshots and recordings. Violators will face strict legal action.

CARIES RISK

Dental caries is a preventable, chronic, and biofilm-mediated disease modulated by diet. This multifactorial, oral disease is caused primarily by an imbalance of the oral flora (biofilm) due to the presence of fermentable dietary carbohydrates on the tooth surface over time.

- At the tooth level, dental caries activity is characterized by localized demineralization and loss of tooth structure.
- At the tooth surface and subsurface level, dental caries lesions result from a dynamic process of damage (demineralization) and restitution (remineralization) of the tooth matter.
- This process of demineralization and remineralization takes place several times a day over the life of the tooth and are modulated by many factors including number and type of microbial flora in the biofilm, diet, oral hygiene, genetics, dental anatomy, dentin and enamel composition, use of fluorides and other chemotherapeutic agents, saliva composition, salivary flow, and buffering capacity. (Source-Sturdevant 7th edition)

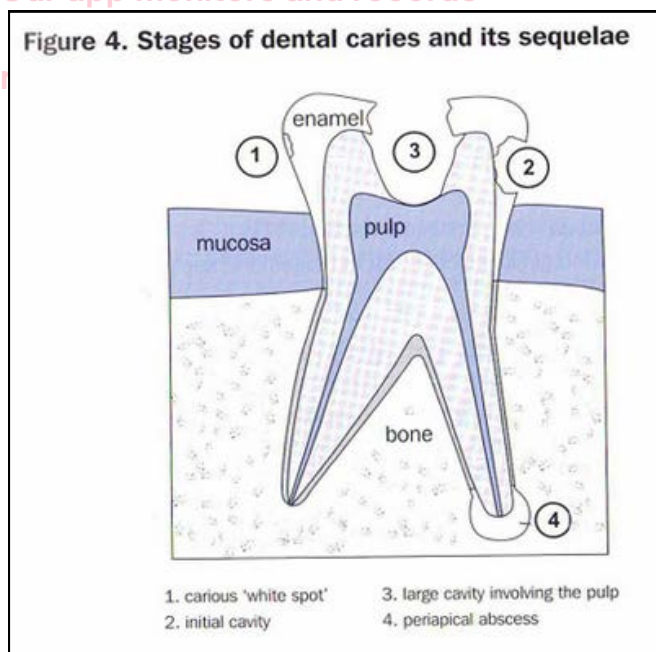


Fig: Source - TG

DENTAL CARIES RISK ASSESMENT

- A risk is an event that may or may not occur-it is essentially an uncertain circumstance in life. An understanding and application of caries risk assessment (CRA) principles requires an appreciation of risk in context of health status, health care delivery and health care outcome.(Source -CRA In MID Article)

DISCLAIMER

THIS IS COPYRIGHTED CONTENT. Unauthorized use, including screenshots, copying, misuse, reuse, or resale of any content from this app, is strictly prohibited. Our app monitors and records all screenshots and recordings. Violators will face strict legal action.

DISCLAIMER
THIS IS COPYRIGHTED CONTENT. Unauthorized use, including screenshots, copying, misuse, reuse, or resale of any content from this app, is strictly prohibited. Our app monitors and records all screenshots and recordings. Violators will face strict legal action.

DISCLAIMER
THIS IS COPYRIGHTED CONTENT. Unauthorized use, including screenshots, copying, misuse, reuse, or resale of any content from this app, is strictly prohibited. Our app monitors and records all screenshots and recordings. Violators will face strict legal action.

CARIES RISK

Dental Caries Risk Assessment

- A risk is an event that may or may not occur-it is essentially an uncertain circumstance in life. An understanding and application of caries risk assessment (CRA) principles requires an appreciation of risk in context of health status, health care delivery and health care outcome.(Source -CRA In MID Article)
- Recently a number of caries activity tools have been devised by various organizations to assist the clinicians. These instruments include:
 1. The Caries Management By Risk Assessment (CaMBRA) protocol
 2. The electronic online Cariogram Programme
 3. The Caries Risk Assessment Tool (CAT)
- The first tool **CaMBRA** was originally designed for use in an educational environment and recently been validated for adult use.
- The second tool **Cariogram** has received rapid acceptance in Europe as a useful predictor for caries progression in children.
- The third tool **CAT** has been favorably compared with other instruments for use in infants and young children and the format has been adopted as a component of dental home policy by American Academy of Pediatric Dentistry (AAPD)
- However, each of these instruments has been found to have limitation, particularly in prediction of high risk individual residing in low caries community.
- Most studies conclude that past caries experience is still most reliable predictor of future caries experience in children. (Source-CRA in MID Article)

THIS IS COPYRIGHTED CONTENT. Unauthorized use, including screenshots, copying, misuse, reuse, or resale of any content from this app, is strictly prohibited. Our app monitors and records all screenshots and recordings. Violators will face strict legal action.

DISCLAIMER

THIS IS COPYRIGHTED CONTENT. Unauthorized use, including screenshots, copying, misuse, reuse, or resale of any content from this app, is strictly prohibited. Our app monitors and records all screenshots and recordings. Violators will face strict legal action.

THIS IS COPYRIGHTED CONTENT. Unauthorized use, including screenshots, copying, misuse, reuse, or resale of any content from this app, is strictly prohibited. Our app monitors and records all screenshots and recordings. Violators will face strict legal action.

DISCLAIMER
THIS IS COPYRIGHTED CONTENT. Unauthorized use, including screenshots, copying, misuse, reuse, or resale of any content from this app, is strictly prohibited. Our app monitors and records all screenshots and recordings. Violators will face strict legal action.

DISCLAIMER

THIS IS COPYRIGHTED CONTENT. Unauthorized use, including screenshots, copying, misuse, reuse, or resale of any content from this app, is strictly prohibited. Our app monitors and records all screenshots and recordings. Violators will face strict legal action.

CARIES RISK

THIS IS COPYRIGHTED
CONTENT. Unauthorized use,

FACTORS	HIGH (1)	MODERATE (2)	LOW (3)
1. Local Factors			
Plaque/Calculus	Generalised	Localised	Minimal/none
2. Dental Conditions			
*Visible cavitations	Yes		No
Filling in last 3 years	Yes		No
Inadequate saliva flow	Yes		No
Exposed dentine		Yes	No
Deep enamel pits/fissures		Yes	No
Radiographic proximal lesions		Yes	No
White spot enamel lesions		Yes	No
Orthodontic appliances present	Yes		No
3. Medical History			
Gastro Reflux (infancy)	Yes		No
Asthma inhalants	Yes		No
Hypo salivary medications (ADHD)	Yes		No
Radiation therapy	Yes		No
4. Dietary Habits			
Snacks between meals	>3 times	1 – 3 times	Infrequent
Daily soft drinks	Yes	Infrequent	No
5. Environmental			
Sports drinks	Yes		No
6. Protective Factors			
Fluoridated water	No		Yes
Fluoridated toothpaste	No		Yes
Fluoride mouth rinse		No	Yes
Extra chewing gum		No	Yes
Chlorhexidine mouth rinse		No	Yes
Other antiseptic mouth rinse		No	Yes
7. Laboratory Tests			
CariCult™	HIGH	MEDIUM	LOW
CariScreen™	>9,500	9000 – 9,500	<9,000
CARIES RISK ASSESSMENT	HIGH	MODERATE	LOW

Fig: Author modified CaMBRA data collection form (Source-Article)

copying, misuse, reuse, or
resale of any content from
this app, is strictly prohibited.
Our app monitors and records
all screenshots and
recordings. Violators will face
strict legal action.

DISCLAIMER

THIS IS COPYRIGHTED CONTENT. Unauthorized use, including screenshots, copying, misuse, reuse, or resale of any content from this app, is strictly prohibited. Our app monitors and records all screenshots and recordings. Violators will face strict legal action.

DISCLAIMER
THIS IS COPYRIGHTED CONTENT. Unauthorized use, including screenshots, copying, misuse, reuse, or resale of any content from this app, is strictly prohibited. Our app monitors and records all screenshots and recordings. Violators will face strict legal action.

CARIES RISK

- Dental caries risk assessment involves quantification of risk factors such as Diet, saliva quality and quantity, plaque characteristics, oral hygiene habits and use of fluoridated products. (Source-TG)
- The case history and clinical examination provides an overview of unfavorable exposures to potential caries risk factors, namely:
 - a) Sucrose intake (Diet)
 - b) Fluoride use
 - c) Dental plaque
 - d) Tooth morphology
 - e) Salivary characteristics. (Source-Evans Article)
- Risk indicators include: (Source- Article on CRA in children)
 - a) Past caries experience -increases the risk
 - b) Low socio economic status - increases the risk
 - c) Sugar consumption- Frequency of intake is directly related to caries ,increase frequency leads to increase caries experience
 - d) Oral hygiene habits: Frequency of brushing with fluoridated tooth paste determines the risk.
 - e) Saliva: Decrease salivary secretion increases the risk, thicker mucous saliva and lack of buffering capacity of saliva also increases the increases the caries incidence.
 - f) Bacteria: Bacteria are poor indicator of future caries.

THIS IS COPYRIGHTED CONTENT. Unauthorized use, including screenshots, copying, misuse, reuse, or resale of any content from this app, is strictly prohibited. Our app monitors and records all screenshots and recordings. Violators will face strict legal action.

DISCLAIMER

THIS IS COPYRIGHTED CONTENT. Unauthorized use, including screenshots, copying, misuse, reuse, or resale of any content from this app, is strictly prohibited. Our app monitors and records all screenshots and recordings. Violators will face strict legal action.

THIS IS COPYRIGHTED CONTENT. Unauthorized use, including screenshots, copying, misuse, reuse, or resale of any content from this app, is strictly prohibited. Our app monitors and records all screenshots and recordings. Violators will face strict legal action.

THIS IS COPYRIGHTED CONTENT. Unauthorized use, including screenshots, copying, misuse, reuse, or resale of any content from this app, is strictly prohibited. Our app monitors and records all screenshots and recordings. Violators will face strict legal action.

DISCLAIMER
THIS IS COPYRIGHTED CONTENT. Unauthorized use, including screenshots, copying, misuse, reuse, or resale of any content from this app, is strictly prohibited. Our app monitors and records all screenshots and recordings. Violators will face strict legal action.

DISCLAIMER

THIS IS COPYRIGHTED CONTENT. Unauthorized use, including screenshots, copying, misuse, reuse, or resale of any content from this app, is strictly prohibited. Our app monitors and records all screenshots and recordings. Violators will face strict legal action.

CARIES RISK

1. DIET ASSESMENT OF CARIES RISK

- One of the main risk factors for caries is frequent exposure to refined dietary sugar.
- Diet analysis consists of two elements: enquiry into life style and into dietary components themselves. Analysis of the diet may be performed in variety of ways, the patient can be asked to recall all foods consumed over the previous 24 hours, this is not very effective as it relies on good memory and honesty. The most effective method is for patient to keep a written record of their diet for 4 consecutive days, including 2 working and 2 leisure days. (Source-ODELL)
- Ideally, the analysis should be performed before any dietary advice is given. (Source-Odell)
- A Diet assessment of caries risk tool was developed to help health care professionals efficiently assess dietary contributors to caries risk.

Diet assessment of caries risk.			
KEY AREA	PROBABLE RESPONSE	RELATIVE RISK	DESIRED BEHAVIOR GUIDELINES*
Number of Meals/Snacks	< 6/day	Low	3-6/day
	> 6/day	Moderate	
Meal/Snack Structure	Structured	Low	Structured meal pattern
	Unstructured/grazing	Moderate	
Sugared Beverages†			
Quantity	< 12 ounces/day	Low	6-8 ounces of 100 percent juice or other sugared beverage/day; < 12 ounces of sugared soda pop/day
	12-20 ounces/day	Moderate	
	> 20 ounces/day	High	
Timing	With meals	Low	With meals
	With snacks	Moderate	
	Between meals/snacks	High	
Frequency	1 exposure/day	Low	1 exposure/day
	2-3 exposures/day	Moderate	
	≥ 4 exposures/day High	High	
Length of exposure	< 15 minutes	Low	< 15 minutes
	15-30 minutes	Moderate	
	> 30 minutes	High	
Drinking style	Straw	Low	Straw
	Open container	Moderate	
	Swishing within mouth	High	
* The desired behavior guidelines are based on dietary guidelines and current practice and are presented for adolescents and adults. Sources: U.S. Department of Agriculture ⁶ and U.S. Department of Health and Human Services and U.S. Department of Agriculture. ⁷			
† Sugared beverages include 100 percent juice, juice drinks, soda pop, sports drinks, energy drinks, and sugared coffee and tea.			

Fig: Diet assessment of caries risk criteria (Source-Chair side diet assessment Article by Dr.Marshall.

- Having knowledge about patient's dietary behaviors that are associated with caries risk is essential when providing specific individualized recommendations that may reduce caries risk.

DISCLAIMER

THIS IS COPYRIGHTED CONTENT. Unauthorized use, including screenshots, copying, misuse, reuse, or resale of any content from this app, is strictly prohibited. Our app monitors and records all screenshots and recordings. Violators will face strict legal action.

DISCLAIMER
THIS IS COPYRIGHTED CONTENT. Unauthorized use, including screenshots, copying, misuse, reuse, or resale of any content from this app, is strictly prohibited. Our app monitors and records all screenshots and recordings. Violators will face strict legal action.

CARIES RISK

- The Diet Assessment of caries risk is designed to identify diets that place people at high risk of developing caries. Only dietary recommendations tailored to patients lifestyle are likely to be adopted. (Odell+Article)
- Individual foods and beverages are not consumed in isolation and dietary recommendation for oral health can have ripple effects on other aspects of diet. Thus it is helpful for oral health practitioners to have knowledge of patients preferred food, accessibility to food and current dietary habits so they can individualize recommendations and provide anticipatory guidance to patients.
*Anticipatory guidelines is a health promotion guidelines designed to promote health and prevent diseases.
- Using a 24 hour dietary recall tool helps practitioners identify the patients dietary framework within which current behavior exists. Practitioners should consider how diet recommendations fit within the patient's dietary framework or whether the framework requires any modifications to support or enable his/her Oral health care recommendations.

24-HOUR RECALL

A 24-hour recall is an interviewer-administered dietary assessment tool designed to gather information about food and beverage intakes and meal patterns. Open-ended prodding questions are asked to facilitate recall of foods and beverages consumed. The 24-hour recall also can be used to identify food preferences and areas in which the patient is receptive to change. For example, the interviewer's questions might follow the following format:

- What did you eat or drink first yesterday? Approximately what time was that? Where were you when you consumed it? Did you have anything to eat or drink with the reported beverage or food?
 - When did you next eat or drink anything? And what did you consume? About how much did you have? How long did it take you to consume the beverage or food?
- The interview can continue with similar prodding questions until the patient indicates that is all he or she consumed. Then the interviewer can look for and address potential discrepancies in the patient's recall.
- I noticed you reported nothing to drink from noon on. Is this typical?
 - Do you like to eat fruits or vegetables?

Image- (Source -Article)

- For example: A patient who consumes 6 (20 ounce sugared, carbonated) beverages, which provide approximately 1500 calories per day to this patient recommending this patient to "Quit drinking " or "Switch to diet " does not acknowledge the fact that these beverages provide more than 50 % of the patients energy intake and the patient will be hungry if they follow the recommendation. Without anticipatory guidance dietary recommendation the pt. may return to the dentist by quitting the beverages but having same quantity of sports drink or a diet beverage combined with a sugar loaded snack throughout the day.

DISCLAIMER

THIS IS COPYRIGHTED CONTENT. Unauthorized use, including screenshots, copying, misuse, reuse, or resale of any content from this app, is strictly prohibited. Our app monitors and records all screenshots and recordings. Violators will face strict legal action.

DISCLAIMER
THIS IS COPYRIGHTED CONTENT. Unauthorized use, including screenshots, copying, misuse, reuse, or resale of any content from this app, is strictly prohibited. Our app monitors and records all screenshots and recordings. Violators will face strict legal action.

DISCLAIMER
THIS IS COPYRIGHTED CONTENT. Unauthorized use, including screenshots, copying, misuse, reuse, or resale of any content from this app, is strictly prohibited. Our app monitors and records all screenshots and recordings. Violators will face strict legal action.

CARIES RISK

Anticipatory guidance to support the dietary recommendation to decrease Mountain Dew* intake.

DESIRED MODIFICATION

- Limited Mountain Dew intake, as opposed to the current consumption of a 12-pack of Mountain Dew per day.

RATIONALE FOR MODIFICATION

- Prolonged exposure to sugared beverage increases caries risk.

SUGGESTED STRATEGIES TO ACHIEVE DESIRED MODIFICATION

- Switch to diet Mountain Dew.*
- Gradually decrease Mountain Dew by mixing with diet Mountain Dew and finally replacing with all diet Mountain Dew.
- Replace Mountain Dew with sugar-free alternative (that is, tea, water, diet cola).
- Limit Mountain Dew consumption to meals.

CONFOUNDERS TO ACHIEVING DESIRED MODIFICATION

- Energy intake; Mountain Dew provides 1,900 calories. Without this energy, patient will be hungry. Anticipatory guidance should emphasize structured meal patterns and MyPyramid⁶ food choices to prevent frequent intake of foods containing fermentable carbohydrates.
- Caffeine intake; patient likely will need caffeine replacement, because otherwise he or she likely will treat probable headaches with Mountain Dew; patient will be less likely to attempt behavior change in the future.

Fig: (Source -Article)

THIS IS COPYRIGHTED CONTENT. Unauthorized use, including screenshots, copying, misuse, reuse, or resale of any content from this app, is strictly prohibited. Our app monitors and records all screenshots and recordings. Violators will face strict legal action.

THIS IS COPYRIGHTED CONTENT. Unauthorized use, including screenshots, copying, misuse, reuse, or resale of any content from this app, is strictly prohibited. Our app monitors and records all screenshots and recordings. Violators will face strict legal action.

THIS IS COPYRIGHTED CONTENT. Unauthorized use, including screenshots, copying, misuse, reuse, or resale of any content from this app, is strictly prohibited. Our app monitors and records all screenshots and recordings. Violators will face strict legal action.

DISCLAIMER

THIS IS COPYRIGHTED CONTENT. Unauthorized use, including screenshots, copying, misuse, reuse, or resale of any content from this app, is strictly prohibited. Our app monitors and records all screenshots and recordings. Violators will face strict legal action.

DISCLAIMER
THIS IS COPYRIGHTED CONTENT. Unauthorized use, including screenshots, copying, misuse, reuse, or resale of any content from this app, is strictly prohibited. Our app monitors and records all screenshots and recordings. Violators will face strict legal action.

CARIES RISK

2. ASSESSMENT OF DENTAL PLAQUE CONTROL (Source-Evans article)

- Visible plaque indicates that the toothbrush with the toothpaste has not reached that part of mouth recently to disrupt the biofilm.
- At the initial clinical examination and at every appointment thereafter, dental plaque distribution can be recorded according to plaque index.
- Twelve sites are assessed :The buccal and lingual surfaces of 1st permanent molars (8 Sites) and the buccal and lingual surfaces of upper and lower permanent incisors(4 sites).The site on buccal and lingual surfaces of each tooth is the area adjacent to gingival margin, extending from papilla to papilla. Individual surface scores are summated to give the patient a score which has maximum value of 36.

Criteria for Plaque Index (Silness & Loe, 1964)

3 = **thick** plaque is visible along gingival margin (no need to probe)
 2 = plaque is **visible** along gingival margin, with or without air drying (no need to probe)
 1 = following air drying, plaque is **not visible** but **can be wiped off** with an explorer
 0 = following air drying, plaque is **not visible** nor **cannot** be wiped off with an explorer

Notes: 1 If an index tooth is missing, score the nearest tooth in that sextant. If there are no teeth in the sextant, enter X.
 2 If plaque thickness varies along the gingival margin, score according to the worst situation.
 3 The overall score is the sum of the 12 surface scores (maximum of 36).

Fig 1. Criteria and instructions for reporting the Plaque Index scores, and one panel of recording boxes for the scores. (Note: There are 13 panels of boxes on an A4 sized form.)

Buccal			Lingual		
16	11	26	16	11	26
46	41	36	46	41	36

Date _____ Score _____

Fig: Source -Article Evans

- **Assessment of dental plaque thickness and fermentation can be done by using disclosing dyes. Supragingival plaque can be stained with:**
 - a) 2 tone disclosing dye which indicates the area of immature and mature plaque biofilm and persisting oral hygiene problems. The old plaque is stained blue and new plaque (less than 24 hours) is stained pink.
 - b) 3 tone disclosing dye has additional chemistry included so that regions of highly acid producing mature plaque produces light blue or green color.

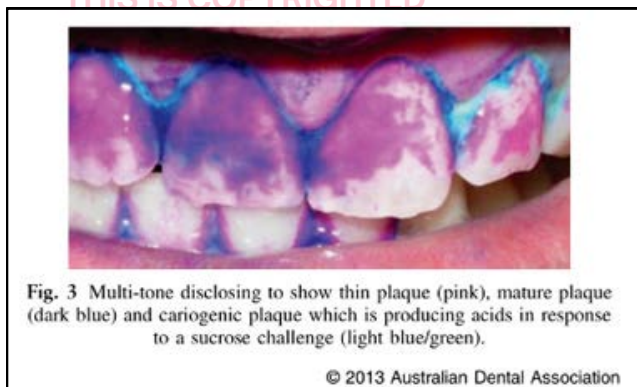


Fig: MID article

DISCLAIMER

THIS IS COPYRIGHTED CONTENT. Unauthorized use, including screenshots, copying, misuse, reuse, or resale of any content from this app, is strictly prohibited. Our app monitors and records all screenshots and recordings. Violators will face strict legal action.

THIS IS COPYRIGHTED CONTENT. Unauthorized use, including screenshots, copying, misuse, reuse, or resale of any content from this app, is strictly prohibited. Our app monitors and records all screenshots and recordings. Violators will face strict legal action.

DISCLAIMER
 THIS IS COPYRIGHTED CONTENT. Unauthorized use, including screenshots, copying, misuse, reuse, or resale of any content from this app, is strictly prohibited. Our app monitors and records all screenshots and recordings. Violators will face strict legal action.

CARIES RISK

3. SALIVA ASSESSMENT (Source-MID principles and objective Article)

- The patients overall water intake should be assessed since this can dramatically affect the production of saliva at rest.
- A thorough assessment of salivary parameters at rest and after stimulation should be done for caries risk assessment.
- Measuring of resting salivary flow must be undertaken prior to reclining the patient or any manipulation of soft tissues.(How to measure: Assess the visual formation of single visible micro droplet from the orifice of each labial salivary gland in labial mucosa of lower lip within 30 sec)
- The next step is to assess the resting salivary viscosity and PH.
- If anomalies are found in resting parameters then examination of stimulated salivary flow, viscosity and PH should be conducted.
- The quantity (mL/min) of stimulated whole saliva produced by chewing paraffin gums for 2 minutes can be noted, if the quantity is less than 1 ml in 2 minutes the caries risk is considered to be high.
- Salivary Consistency: Visually assess the resting salivary consistency in the oral cavity. Sticky frothy saliva: Residues Frothy bubbly saliva: Increased Viscosity Watery clear saliva: Normal Viscosity
- Testing pH - Resting Saliva & Stimulated Saliva
Highly acidic saliva will be in the red section, pH 5.0 - 5.8. Moderately acidic saliva will be found in the yellow section, pH 6.0 - 6.6. Healthy saliva will be in the green section pH 6.8- 7.8.

4. THE STATUS OF EACH LESION

- Final assessment of patient at risk follows the completion of the clinical examination and bitewing radiographic survey.
- Following the clinical examination and bitewing radiography the caries risk status of the patient is determined pragmatically.
- At first visit the risk of caries is determined solely on clinical presentation of dentition and at later follow up, risk is determined according to the incidence rate of new lesions and progression status of existing lesions.

Criteria for Caries Risk Status		
Caries Risk	New patient	Recall patient
Low	1. No clinical signs of caries 2. May have bitewing radiolucencies not greater than C3	1. <1 new lesion per year 2. Or no progression of existing radiolucencies
Medium	1. No frank cavitation 2. May have sticky pits or fissures 3. And/or bitewing radiolucencies not greater than C4	1. 1 new lesion per year 2. And/or progression of existing radiolucencies
High	1. Untreated frank cavities 2. And/or extensive white spot lesions 3. And/or C5 bitewing radiolucencies	1. >1 new lesion per year

Fig: Caries risk status criteria for patient with Permanent tooth (Adult)

DISCLAIMER

THIS IS COPYRIGHTED CONTENT. Unauthorized use, including screenshots, copying, misuse, reuse, or resale of any content from this app, is strictly prohibited. Our app monitors and records all screenshots and recordings. Violators will face strict legal action.

DISCLAIMER
THIS IS COPYRIGHTED CONTENT. Unauthorized use, including screenshots, copying, misuse, reuse, or resale of any content from this app, is strictly prohibited. Our app monitors and records all screenshots and recordings. Violators will face strict legal action.

THIS IS COPYRIGHTED CONTENT. Unauthorized use, including screenshots, copying, misuse, reuse, or resale of any content from this app, is strictly prohibited. Our app monitors and records all screenshots and recordings. Violators will face strict legal action.

DISCLAIMER

CARIES RISK

Table 3. Criteria for caries risk for a child who has a primary dentition only

Caries risk	New patient	Recall patient
Low	<ul style="list-style-type: none"> • dmfs = 0 • ICDAS II codes < 2 • No radiolucencies • No sites with Plaque Index = 3 	<ul style="list-style-type: none"> • < 1 new lesion per year* and no progression of existing lesions
At-risk	<ul style="list-style-type: none"> • dmfs > 0 • Demineralized enamel – ICDAS II codes > 1 • C1 or greater radiolucencies 	<ul style="list-style-type: none"> • 1 new lesion per year* and/or progression of existing lesions • Any site with Plaque Index = 3 in cases where dmfs = 0
At-risk – High	<ul style="list-style-type: none"> • Any site with Plaque Index = 3 in cases where dmfs = 0 • Not assigned to new patient 	<ul style="list-style-type: none"> • > 1 new lesion per year*

*... on approximal surfaces as diagnosed by bitewing scores C1 or greater or else on other surfaces diagnosed as ICDAS II code 2 or greater.

Fig: Caries risk status criteria for patient with primary dentition only.(Child)

Table 4. Criteria for caries risk for a child who has a mixed or permanent dentition

Caries risk	New patient	Recall patient
Low	<ul style="list-style-type: none"> • dmfs + DMFS = 0 • ICDAS II codes < 2 • No radiolucencies • No sites with Plaque Index = 3 • No hypomineralized or hypoplastic 6s or 7s 	<ul style="list-style-type: none"> • < 1 new lesion per year* • and no progression of existing lesions
At-risk	<ul style="list-style-type: none"> • dmfs > 0 • Demineralized enamel – ICDAS II codes > 1 or greater • C1 or greater radiolucencies • Any site with Plaque Index = 3 in cases where dmfs + DMFS = 0 • dmfs + DMFT = 0 but 6s or 7s are hypomineralized or hypoplastic 	<ul style="list-style-type: none"> • 1 new lesion per year* • and/or progression of existing lesions • Any site with Plaque Index = 3 in cases where dmfs + DMFS = 0 • dmfs + DMFT = 0 but 6s or 7s are hypomineralized or hypoplastic
At-risk – High	<ul style="list-style-type: none"> • Not assigned to new patient 	<ul style="list-style-type: none"> • > 1 new lesion per year*

*...on approximal surfaces as diagnosed by bitewing codes C1 or greater or on other surfaces diagnosed as ICDAS II code 2 or greater.

Fig: Caries risk status criteria for child patient with mixed or permanent dentition (Source-Evans article)

***Note -For Radiographic and clinical criteria's refer to hot topics of Caries Diagnosis**

THIS IS COPYRIGHTED CONTENT. Unauthorized use, including screenshots, copying, misuse, reuse, or resale of any content from this app, is strictly prohibited. Our app monitors and records all screenshots and recordings. Violators will face strict legal action.

THIS IS COPYRIGHTED CONTENT. Unauthorized use, including screenshots, copying, misuse, reuse, or resale of any content from this app, is strictly prohibited. Our app monitors and records all screenshots and recordings. Violators will face strict legal action.

CARIES MANAGEMENT

Caries management efforts must be directed not only at the tooth level (traditional or surgical treatment) but also at the total-patient level (caries management by risk assessment).

Restorative treatment does not cure the caries process. Instead, identifying and managing the risk factors for caries must be the **primary focus**, in addition to the restorative repair of damage caused by caries.

Prevention and minimal intervention management of dental caries (before cavitation) includes several strategies that promote remineralization and arrest further decay. The caries management system is a 10 step noninvasive strategy to arrest and remineralize early lesions. The governing principle of caries management includes:

- a) The patient at risk
- b) The status of each lesions
- c) Patient management
- d) Clinical management
- e) Monitoring

Ten steps of the Caries Management System

- 1 Diet assessment
- 2 Plaque assessment
- 3 Bitewing radiographic survey
- 4 Diagnosis and caries risk assessment
- 5 Preparation of treatment plan
- 6 Case presentation at which patient is informed about:
 - Dental caries:
 - Arrest
 - Reversal/natural repair (remineralisation)
 - Prevention
 - Number and status of current lesions
 - Role of dental practitioner in caries management
 - Role of home care in caries prevention
 - Current caries risk status
 - Result of diet assessment and recommendations
- 7 Oral hygiene coaching
- 8 Topical fluoride application (both professional and home care)
- 9 Monitoring of plaque control and treatment outcomes at each visit
- 10 Recall program tailored to caries risk status

Image- Source (Evans Article)

*Note for risk assessments and status of lesion refer to Hot notes of risk assessment and caries diagnosis.

DISCLAIMER

THIS IS COPYRIGHTED CONTENT. Unauthorized use, including screenshots, copying, misuse, reuse, or resale of any content from this app, is strictly prohibited. Our app monitors and records all screenshots and recordings. Violators will face strict legal action.

DISCLAIMER
THIS IS COPYRIGHTED CONTENT. Unauthorized use, including screenshots, copying, misuse, reuse, or resale of any content from this app, is strictly prohibited. Our app monitors and records all screenshots and recordings. Violators will face strict legal action.

CARIES MANAGEMENT

- The management of patient at risk involves approach that can be individualized to the patients risk factors:
 - Dietary modification**-Patient should understand the diet-caries relationship. Avoiding sticky food, high consumption of refined sugars, between meals snacks should be strongly advised.

Table 1.3 Dietary advice

Aims	Methods
Reduce the amount of sugar	Check manufacturers' labels and avoid foods with sugars such as sucrose, glucose and fructose listed early in the ingredients. Natural sugars (e.g. honey, brown sugar) are as cariogenic as purified or added sugars. When sweet foods are required, choose those containing sweetening agents such as saccharin, acesulfame-K and aspartame. Diet formulations contain less sugar than their standard counterparts. Reduce the sweetness of drinks and foods. Become accustomed to a less sweet diet overall.
Restrict frequency of sugar intakes to meal times as far as possible	Try to reduce snacking. When snacks are required select 'safe snacks' such as cheese, crisps, fruit or sugar-free sweets, such as mints or chewing gum (which not only has no sugar but also stimulates salivary flow and increases plaque pH). Use artificial sweeteners in drinks taken between meals.
Speed clearance of sugars from the mouth	Never finish meals with a sugary food or drink. Follow sugary foods with a sugar-free drink, chewing gum or a protective food such as cheese.

- Plaque reduction**-By providing Oral hygiene instruction to ensure effective Tooth brushing and interdental cleaning. The aim is to reduce the plaque index score (Bleeding on Probing).
 - Tooth surface modification** by using remineralizing agents such as fluorides, pit and fissure sealants.
 - Salivary modifications** which can be achieved by addressing causes of dry mouth.
 - Only if Cavitation** has occurred-remove the infected tooth structure and restore the cavity using minimally destructive methods and adhesive dental materials. (Tg + Articles)
- The Clinical management: Risk based management options are:**
Preventive, Preservative (Non-invasive), and operative (Invasive)
 - Fundamentally, non cavitated lesions in primary and especially permanent dentition are managed by preservative noninvasive means, only cavitated lesions are managed operatively.
 - Non-cavitated lesions are managed by Home care measures to control plaque-Tooth brushing twice with fluoridated toothpaste. In addition, combination of Professional fluoride varnish and home use of fluoride toothpaste (Means of primary prevention of caries) accelerates the remineralization process.
 - For less advanced pit and fissure lesions: Most conservative and effective approach is resin based sealant application (GIC sealant preferred only in cases with issues on moisture control as an interim measure, e.g. newly erupted tooth). Sealants should be placed, without removal of any tooth structure.

DISCLAIMER

THIS IS COPYRIGHTED CONTENT. Unauthorized use, including screenshots, copying, misuse, reuse, or resale of any content from this app, is strictly prohibited. Our app monitors and records all screenshots and recordings. Violators will face strict legal action.

DISCLAIMER

THIS IS COPYRIGHTED CONTENT. Unauthorized use, including screenshots, copying, misuse, reuse, or resale of any content from this app, is strictly prohibited. Our app monitors and records all screenshots and recordings. Violators will face strict legal action.

CARIES MANAGEMENT

- Now based on the radiographic criteria of each lesion discovered on bitewing survey, management protocols are present for adult permanent dentition, primary dentition and mixed permanent and childhood permanent dentition.

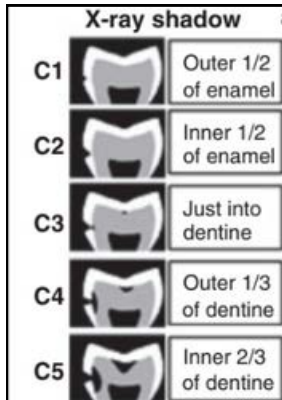


Table 5. Protocol for the management of lesions following caries diagnosis based on the bitewing radiographic survey

Lesion Management Protocol	
Lesion score	Treatment
C1	Do not restore – apply topical fluoride and monitor
C2	Do not restore – apply topical fluoride and monitor
C3	Do not restore – apply topical fluoride and monitor
C4	Do not restore <i>without further consideration</i>
C5	Restore now – it is almost certain that the cavity has breached the DEJ
Caries Risk	Further consideration for surfaces scored C4
Low and Medium	<ul style="list-style-type: none"> Restore <i>only if</i> the radiolucency extends <i>fully 1/3</i> into dentine, or following tooth separation when cavitation is confirmed Otherwise <i>do not</i> restore because it is most likely: <ul style="list-style-type: none"> that the approximal surface is not cavitated, and that the lesion has arrested Apply topical fluoride and monitor: <ul style="list-style-type: none"> to arrest and remineralise active lesions, or to maintain arrested lesions
High	<ul style="list-style-type: none"> Restore now Apply topical fluoride and monitor: <ul style="list-style-type: none"> to arrest and remineralise lesions not yet showing radiographically, and to prevent recurrent caries

Fig: Management protocol for Adult Permanent Dentition. (Source -Evans)


DISCLAIMER

THIS IS COPYRIGHTED CONTENT. Unauthorized use, including screenshots, copying, misuse, reuse, or resale of any content from this app, is strictly prohibited. Our app monitors and records all screenshots and recordings. Violators will face strict legal action.

DISCLAIMER
THIS IS COPYRIGHTED CONTENT. Unauthorized use, including screenshots, copying, misuse, reuse, or resale of any content from this app, is strictly prohibited. Our app monitors and records all screenshots and recordings. Violators will face strict legal action.

DISCLAIMER
THIS IS COPYRIGHTED CONTENT. Unauthorized use, including screenshots, copying, misuse, reuse, or resale of any content from this app, is strictly prohibited. Our app monitors and records all screenshots and recordings. Violators will face strict legal action.

CARIES MANAGEMENT

Lesion code		Management
ICDAS II	1-2	<ul style="list-style-type: none"> Apply fluoride varnish to arrest and remineralize active lesions and to maintain arrested lesions
	3	<ul style="list-style-type: none"> Restore only if associated bitewing radiolucency extends deeper than C3 otherwise apply resin-based sealant or protect with GIC and review in 6 months (bitewings)
Bitewing	4-6	Restore
	C1	Do not restore – apply topical fluoride and monitor
	C2	Do not restore – apply topical fluoride and monitor
	C3	Do not restore without further consideration
	C4	Restore now only if tooth is not due to exfoliate*
	C5	Restore now only if tooth is not due to exfoliate*
		
Further consideration of C3 surfaces		<ul style="list-style-type: none"> Do not restore within 12 months of exfoliation* Restore if shadow is evident below marginal ridge Otherwise separate tooth to confirm cavitation and restore only if cavitated Implement preventive strategy to: <ul style="list-style-type: none"> – arrest active lesions – remineralize lesions – maintain arrested lesions – preserve first molars (take particular care)

*Clue – less than ½ of root remains.

Fig: Management protocol for primary teeth based on radiographic survey.


Lesion code		Management
ICDAS II	1-2	<ul style="list-style-type: none"> Apply fluoride varnish to (1) arrest and remineralize active lesions and (2) maintain arrested lesions
	3-4	<ul style="list-style-type: none"> Restore with UCSR* only if associated radiolucency extends deeper than C4 otherwise apply resin-based sealant and review in 6 months (bitewings)
	5	<ul style="list-style-type: none"> Restore with UCSR*
Bitewing	6	Restore
	C1	Do not restore – apply topical fluoride and monitor
	C2	Do not restore – apply topical fluoride and monitor
	C3	Do not restore – apply topical fluoride and monitor
	C4	Do not restore without further consideration
	C5	Restore now
		
Further consideration of C4 surfaces		<ul style="list-style-type: none"> If possible, separate teeth and restore only if cavitated is revealed If not possible to separate, restore only if radiolucency extends fully ½ through dentine Otherwise, do not restore because it is more likely than not that the approximal surface: <ul style="list-style-type: none"> – is not cavitated – and lesion progression could be arrested or has already arrested Implement preventive strategy to: <ul style="list-style-type: none"> – arrest active lesions – remineralize lesions – maintain arrested lesions

Fig: Management protocol for child or adolescent with mixed or permanent dentition.(Source-Evans)

- For overall management of a patient with high caries risk the treatment should be prioritized and phases of treatment should be sequenced which includes:

Phase of treatment	Items of treatment	Reasons
Immediate phase	Caries removal from the lower right first molar, access cavity preparation for endodontics, drainage, irrigation with sodium hypochlorite and placement of a temporary restoration	Essential if the tooth is to be saved and to remove the source of the apical infection. There is also an urgent need to minimize further destruction of this tooth, which may soon be unrestorable. The temporary restoration is necessary to facilitate rubber dam isolation during future endodontic treatment, and it will also stabilize the occlusion and stop mesial drift.
Stabilization of caries	Removal of caries and placement of temporary restorations in all carious teeth in visits by quadrants/two quadrants	To prevent further tooth destruction and progression to carious exposure while other phases of treatment are being carried out.
Preventive treatment	Dietary analysis, oral hygiene instruction, fluoride advice	Should start immediately and extend throughout the treatment plan, to reduce the high caries rate and ensure the long-term future of the dentition.
Permanent restoration	Will depend on what is found while placing temporary restorations	Permanent restorations may be left until last; stabilization takes priority.

Fig: Source (Odell - Case)

- In cases where restoration is required, removal of caries should follow the MID approach which involves minimally invasive cavity preparation i.e. to remove the decomposed (infected) dentine and leave behind the demineralized (affected) dentin, and to restore the cleaned cavity. (MID article)

DISCLAIMER

THIS IS COPYRIGHTED CONTENT. Unauthorized use, including screenshots, copying, misuse, reuse, or resale of any content from this app, is strictly prohibited. Our app monitors and records all screenshots and recordings. Violators will face strict legal action.

THIS IS COPYRIGHTED CONTENT. Unauthorized use, including screenshots, copying, misuse, reuse, or resale of any content from this app, is strictly prohibited. Our app monitors and records all screenshots and recordings. Violators will face strict legal action.

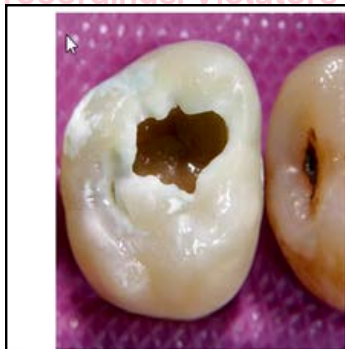DISCLAIMER
THIS IS COPYRIGHTED CONTENT. Unauthorized use, including screenshots, copying, misuse, reuse, or resale of any content from this app, is strictly prohibited. Our app monitors and records all screenshots and recordings. Violators will face strict legal action.

CARIES MANAGEMENT

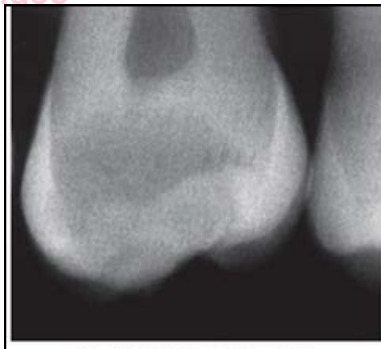- Ways to remove the carious dentine: Conventionally, carious dentine is removed with a large, slowly revolving carbon steel burs and hand excavators. Other alternatives include:

TABLE 9.1 Techniques for Excavation of Carious Dentine	
Technique	Mechanism/Advantages
Burs (carbon-steel, plastic)	Mechanical, rotary
Hand excavators	Mechanical, nonrotary
Air-abrasion (alumina/bioglass), ultrasonics, sono-abrasion, air polishing	Mechanical, nonrotary
Caridex, Carisolv gel, enzyme-based gels	Chemomechanical
Lasers	Ablative
Photoactive disinfection (PAD), ozone	Oxidative destruction and bacterial killing

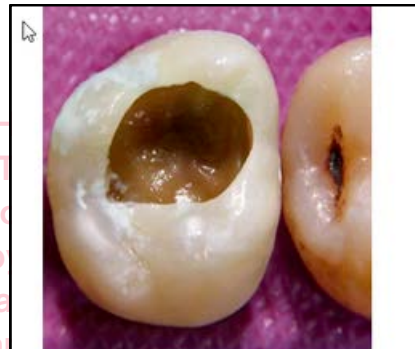
- Pictures of patient with a cavitated lesion and the progress throughout treatment (Step wise) is provided below:



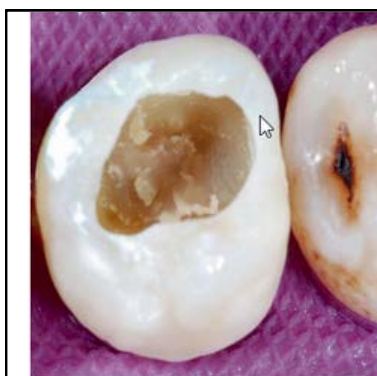• Fig. 9.1 The patient's maxillary right second molar on presentation.



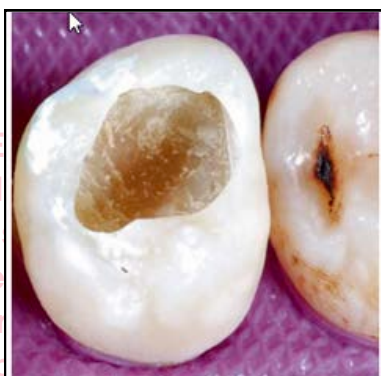• Fig. 9.2 Radiograph of the tooth.



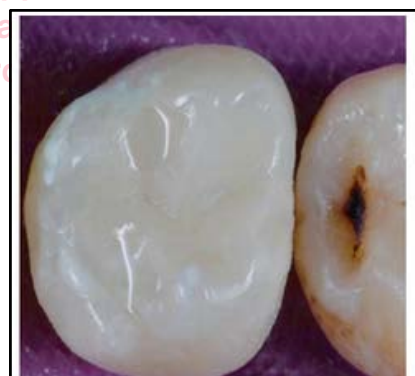• Fig. 9.3 The cavitated lesion after unsupported enamel removal.



• Fig. 9.5 Initial removal of grossly infected dentine.



• Fig. 9.6 Final caries excavation.



• Fig. 9.7 The final restoration.

Image: 9.1-9.7 (source Odell case)

DISCLAIMER

THIS IS COPYRIGHTED CONTENT. Unauthorized use, including screenshots, copying, misuse, reuse, or resale of any content from this app, is strictly prohibited. Our app monitors and records all screenshots and recordings. Violators will face strict legal action.

DISCLAIMER
THIS IS COPYRIGHTED CONTENT. Unauthorized use, including screenshots, copying, misuse, reuse, or resale of any content from this app, is strictly prohibited. Our app monitors and records all screenshots and recordings. Violators will face strict legal action.

THIS IS COPYRIGHTED CONTENT. Unauthorized use, including screenshots, copying, misuse, reuse, or resale of any content from this app, is strictly prohibited. Our app monitors and records all screenshots and recordings. Violators will face strict legal action.

DISCLAIMER

CARIES MANAGEMENT

MONITORING:

- Patients are recalled at regular intervals to monitor, caries activity, tooth brushing and oral hygiene competence and re application of fluorides, which is determined on the basis of caries risk status.
- The caries activity is monitored through the review of bitewing radiolucency. At recall appointments the radiolucency status of new bitewing is compared with older ones.
- A review of diet history from time to time will enable identification and discussion of different dietary trends.
- At each appointment the Plaque Distribution and Overall Plaque Index Score is recorded with record of bleeding and probing, this motivates the patient to improve and maintain a high standard of oral hygiene.
- Fluoride Exposure is the key for caries control (most important protective factor). So, at review appointments if there is absence of positive response to caries arrest, Fluoride exposure is increased. Both professional and home care regimes are adjusted as per the patient's risk.
- Recall Protocol for Adult permanent dentition, primary dentition and permanent or mixed dentition of child patients is different and given below.

Table 8. Recall protocol – schedule for monitoring caries activity and bitewing surveys

Recall Protocol		
Caries risk	Caries activity	Bitewing survey
Low	<ul style="list-style-type: none"> • 12 months following completion of treatment plan developed at first visit • then consider 18–24 month recalls 	<ul style="list-style-type: none"> • at first visit • then 12 months later • then every 18–24 months
Medium	<ul style="list-style-type: none"> • 6 months following completion of treatment plan developed at first visit • then 6-monthly until patient is classified as low risk 	<ul style="list-style-type: none"> • at first visit • then 6 monthly until patient becomes low risk
High	<ul style="list-style-type: none"> • 3 months following completion of treatment plan developed at first visit • then 3-monthly until <ul style="list-style-type: none"> ◦ home care goals have been achieved for: <ul style="list-style-type: none"> – oral hygiene – fluoride therapy ◦ lesion progression has arrested/reversed and patient is reclassified as medium/low risk 	<ul style="list-style-type: none"> • at first visit • then 6 monthly until patient is reclassified as low risk

Fig: Recall protocol for Adult permanent dentition. (Source -Evans article)

Table 9. Recall protocol for children and adolescents

Caries risk	Monitoring lesion activity and patient behaviour	Bitewing survey
Low	<ul style="list-style-type: none"> • 12 months after first visit • Note: Oral hygiene review and coaching at each visit 	<ul style="list-style-type: none"> • At first visit • Then every 12 months
At-risk ... where evidence is: ICDAS II codes > 1	<ul style="list-style-type: none"> • 3-monthly until lesion progression has arrested, i.e., evidence of (1) no extension of demineralization or (2) that GIC sealant remains intact • Note: Oral hygiene review and coaching at each visit 	<ul style="list-style-type: none"> • At first visit • Then every 6 months until patient is classified as low risk
At-risk ... where evidence is: Bitewing codes > C2 for primary teeth > C3 for permanent teeth	<ul style="list-style-type: none"> • 3-monthly for (1) F varnish and (2) oral hygiene monitoring until lesion progression has arrested and patient is reclassified as low risk • Note: Oral hygiene review and coaching at each visit 	<ul style="list-style-type: none"> • At first visit • Then every 6 months until patient is classified as low risk
At-risk ... where <i>only</i> evidence is: Sites with Plaque Index = 3	<ul style="list-style-type: none"> • One week following first visit to review and coach tooth brushing competence • Then one month later for same 	

Fig: Recall Protocol for primary dentition and child with mixed and permanent dentition (Evans Article)

DISCLAIMER

THIS IS COPYRIGHTED CONTENT. Unauthorized use, including screenshots, copying, misuse, reuse, or resale of any content from this app, is strictly prohibited. Our app monitors and records all screenshots and recordings. Violators will face strict legal action.

THIS IS COPYRIGHTED CONTENT. Unauthorized use, including screenshots, copying, misuse, reuse, or resale of any content from this app, is strictly prohibited. Our app monitors and records all screenshots and recordings. Violators will face strict legal action.

DISCLAIMER
THIS IS COPYRIGHTED CONTENT. Unauthorized use, including screenshots, copying, misuse, reuse, or resale of any content from this app, is strictly prohibited. Our app monitors and records all screenshots and recordings. Violators will face strict legal action.

RESTORATIVE MATERIALS

- In dental practice, restorative materials play a critical role in repairing and reconstructing damaged teeth. The selection of appropriate restorative materials, such as composites, amalgams, glass ionomers (GIC), SDF, RM-GIC improves both the appearance and functionality of teeth, contributing significantly to overall oral health.

COMPOSITES

(Source-Mount and Hume, Sturdevant)

Composition:

- The major components of a composite resin are as follows:
 - Organic phase:** most composite resins contain **-Bis-GMA dimethacrylate** some contain **urethane dimethacrylate**. Bis-GMA is highly viscous and shows polymerization shrinkage and water sorption. A diluent like TEGDMA is generally added to reduce the viscosity.
 - Inorganic phase: filler particles** are usually glasses containing aluminum, barium, strontium, zinc, zirconium or quartz. Alternate fillers can be silica
 - Interfacial phase - coupling agent:** It helps to bind the filler to the matrix. It acts as stress absorber allowing stresses in the resin to be transferred between filler particles via the weaker matrix
 - Miscellaneous phases:** Includes **accelerators** and **initiators**
- Filler contributes to the physical and mechanical properties of strength, stiffness, dimensional change, setting contraction, radiopacity and improved handling.
- Both the size and the size distribution of the filler particles play a part in the characteristics of each material. The smaller the filler particle size, the better the polishability.

Properties of Composite Resins:

- Setting time:** It depends on method of activation.
 - For chemically activated: 3-6 minutes from the start of mixing.
 - For light activated:
 - Curing time ranging from 3-40 seconds with minimum light intensity of 400 mW/cm² has been recommended for all composites.
 - The use of a higher intensity light will reduce the curing time and increase polymerization but it may also increase shrinkage and therefore microleakage.
 - Composite resin restorations should be built in increments no greater than 2 mm thick in order to obtain maximum, uniform polymerization.
 - Light curing tips must be held within 4 mm (3-4mm) of the surface of the restoration at all times for optimum effect.

DISCLAIMER

THIS IS COPYRIGHTED CONTENT. Unauthorized use, including screenshots, copying, misuse, reuse, or resale of any content from this app, is strictly prohibited. Our app monitors and records all screenshots and recordings. Violators will face strict legal action.

THIS IS COPYRIGHTED CONTENT. Unauthorized use, including screenshots, copying, misuse, reuse, or resale of any content from this app, is strictly prohibited. Our app monitors and records all screenshots and recordings. Violators will face strict legal action.

DISCLAIMER
THIS IS COPYRIGHTED CONTENT. Unauthorized use, including screenshots, copying, misuse, reuse, or resale of any content from this app, is strictly prohibited. Our app monitors and records all screenshots and recordings. Violators will face strict legal action.

RESTORATIVE MATERIALS

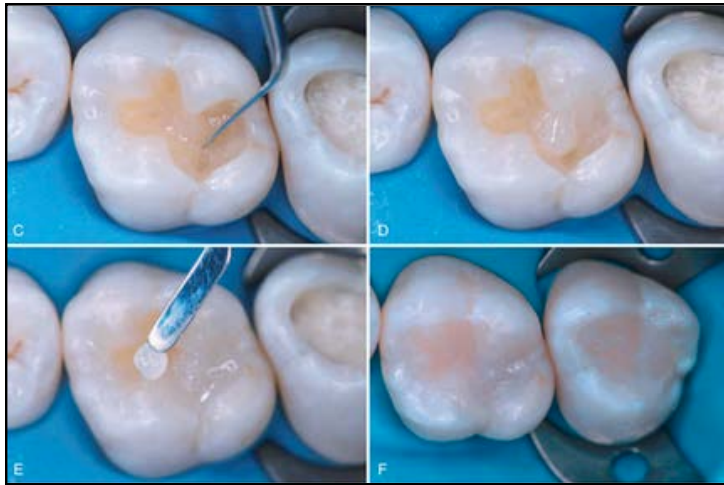


Fig: (C-F) Composite resin placed in small increments and light cured (Source-Sturdevant)

- **Thermal properties:**

- Ideally the thermal expansion of a restorative material should be similar to tooth structure to maintain the integrity of the interface between the restoration and the cavity wall.
- The coefficient of thermal expansion (CoTE) of a composite resin is higher than that of amalgam and approximately 3 times greater than tooth structure.
- This significant difference leads to more expansion and contraction leading to increased risk of marginal gaps and microleakage over time.
- This CoTE varies based on filler content. Composite resins with lower filler volume (microfilled) will therefore have a higher thermal expansion compared to a highly filled material.

- **Water sorption and solubility:**

- Composite resins absorb water and expand but the sorption process takes time and may not be sufficient to compensate for polymerization shrinkage.
- Water sorption tend to reduce physico-mechanical properties of composite resins including hardness and wear resistance
- Composite resins absorb water over time causing marginal staining.

- **Mechanical Properties:**

- The mechanical properties of composite resins vary with filler volume percent.
- Increased filler loading will increase hardness, stiffness, strength and fracture toughness.(better mechanical properties)
- The microfilled and flowable composites have less filler loading so should not be used in stress-bearing areas such as the occlusal surfaces of posterior teeth.
- However, the lower stiffness or modulus of elasticity of microfilled composite is an advantage in the restoration of non-carious cervical lesions (NCCLs) where it is desirable that the restoration is able to flex in response to cervical deformation during function or parafunction.

DISCLAIMER

THIS IS COPYRIGHTED CONTENT. Unauthorized use, including screenshots, copying, misuse, reuse, or resale of any content from this app, is strictly prohibited. Our app monitors and records all screenshots and recordings. Violators will face strict legal action.

DISCLAIMER
THIS IS COPYRIGHTED CONTENT. Unauthorized use, including screenshots, copying, misuse, reuse, or resale of any content from this app, is strictly prohibited. Our app monitors and records all screenshots and recordings. Violators will face strict legal action.

THIS IS COPYRIGHTED CONTENT. Unauthorized use, including screenshots, copying, misuse, reuse, or resale of any content from this app, is strictly prohibited. Our app monitors and records all screenshots and recordings. Violators will face strict legal action.

DISCLAIMER

RESTORATIVE MATERIALS

- **Wear:**
 - a) The wear resistance of microfill composites is generally better than macro filled or hybrid composite, but they appear to fail after prolonged fatigue.
- **Polymerization shrinkage:**
 - a) Polymerization shrinkage continues to be a problem with all resin-based restorative materials. Shrinkage will vary between 1-5% volumes.
 - b) It can be divided into pre gelation and post gelation phases:
 - c) During the pre-gel phase, the composite resin is able to flow and stress within the structure will be relieved.
 - d) After gelation, the flow ceases and cannot compensate for shrinkage stresses. This will result in significant stress in the surrounding tooth structure as well as the composite resin to tooth bond.
 - e) This can lead to postoperative sensitivity, tooth fracture, microleakage and secondary caries.
 - f) Various methods are suggested to reduce the effects of polymerization shrinkage.
 - Incremental placement of composite resin in to the cavity.
 - Placement of a glass-ionomer base to reduce the volume of composite required.
 - glass-ionomer liner to act as a shock absorber
 - The development of stronger bonding agents
 - The use of 'soft-start' 'pulse cure' or other modified methods of light curing.
- **Bonding of Composite to Enamel and Dentine:**
 - a) Bond to enamel:
 - Bonding of composite to enamel is completely micromechanical through acid etching and resin bonding.
 - The enamel margin should be etched with 37% phosphoric acid for 15 seconds then washed thoroughly to remove all etchant and debris.
 - b) Bond to dentine:
 - Bonding to dentine is through hybridization through acid etching, priming and adhesive.
 - Bonding of composite to dentine is less reliable than to enamel, mainly due to difference in composition of enamel and dentin.
 - Dentine contains approximately 12 times more water and twice the amount of organic material than enamel. Water competes with bonding agents for substrate surface and can also hydrolyze resin bonds.
 - Dentine bonding systems can be divided into three groups based on the mechanism of adhesion. The first group aims to modify the smear layer and incorporate it into the bonding process. A second group dissolves the smear layer while the Third group completely removes it. (*Note* - The smear layer is defined as any debris, calcific in nature, produced by reduction or instrumentation of dentine, enamel or cementum*)
 - The third group "Total Etch" technique is commonly used now and involves the use of three components acid etchant, primer and adhesive.

DISCLAIMER

THIS IS COPYRIGHTED CONTENT. Unauthorized use, including screenshots, copying, misuse, reuse, or resale of any content from this app, is strictly prohibited. Our app monitors and records all screenshots and recordings. Violators will face strict legal action.

DISCLAIMER

THIS IS COPYRIGHTED CONTENT. Unauthorized use, including screenshots, copying, misuse, reuse, or resale of any content from this app, is strictly prohibited. Our app monitors and records all screenshots and recordings. Violators will face strict legal action.

DISCLAIMER

THIS IS COPYRIGHTED CONTENT. Unauthorized use, including screenshots, copying, misuse, reuse, or resale of any content from this app, is strictly prohibited. Our app monitors and records all screenshots and recordings. Violators will face strict legal action.

RESTORATIVE MATERIALS

Classification of composite resins: (Source-Mount and Hume / Internet)

- **Based on Polymerization method:**

1. **Chemically cured composite resins** contain benzoyl peroxide as the initiator which is activated by a tertiary aromatic amine accelerator to produce free radicals for polymerization. Used in specific scenarios where light curing might not reach.
2. **Light activated composite resins** contain cam phorquinone and a tertiary amine as the photo initiators, pigments and UV absorbers. For photo cured resins, visible light of approximate wavelength 470 nm activates the photo initiator which produces free radicals for start of polymerization. They allow control over working time and are commonly used in clinical setting.
3. **Dual cure composite resins:** The process of chemical and light curing is both incorporated in the system. They offer flexibility of both the system.

- **Based on Filler Particle size and Morphology:**

- a) **Macro filled Composites**

- i) These contains large filler particles (10-100 μ)
- ii) They have high strength but result in rough surface and are prone to wear.

- b) **Micro filled Composites:**

- i) These have smaller filler particles (0.01-0.1 microns).
- ii) They allow smooth surface and better polishability.
- iii) Not as strong and generally used in anterior restorations.
- iv) Most preferred in cases of NCCLS(Non carious Cervical Lesions).

- c) **Hybrid Composites:**

- i) It contains a mix of macro and micro particles.
- ii) It offers a balance of strength and esthetics.
- iii) They offer better compatibility.

- d) **Nano filled composites:**

- i) They contain nanoparticles (1-100 nm)
- ii) It leads to better mechanical properties aesthetics and polishability.

Category	Particle size (μ)	Category	Particle size (μ)
Megafill	0.5	Minifill	0.1-1
Macrofill	10-100	Microfill	0.01-0.1
Midfill	1-10	Nanofill	0.005-0.01

After Bayne et.al.

Image- Bayne Classification of composites (Source-Mount and Hume)

DISCLAIMER

THIS IS COPYRIGHTED CONTENT. Unauthorized use, including screenshots, copying, misuse, reuse, or resale of any content from this app, is strictly prohibited. Our app monitors and records all screenshots and recordings. Violators will face strict legal action.

DISCLAIMER

THIS IS COPYRIGHTED CONTENT. Unauthorized use, including screenshots, copying, misuse, reuse, or resale of any content from this app, is strictly prohibited. Our app monitors and records all screenshots and recordings. Violators will face strict legal action.

DISCLAIMER

THIS IS COPYRIGHTED CONTENT. Unauthorized use, including screenshots, copying, misuse, reuse, or resale of any content from this app, is strictly prohibited. Our app monitors and records all screenshots and recordings. Violators will face strict legal action.

RESTORATIVE MATERIALS

- **Based on Viscosity:**

- a) **Flowable composites:**

- i) They have higher resin content and with reduction of filler content.
 - ii) Thus, reducing the viscosity of the materials offering better flow to poorly accessible areas.
 - iii) They have lower modulus of elasticity compared to densely packed composite resins and better wettability.
 - iv) They serve as an intermediate layer between the adhesive layer and the overlying resin to reduce contraction stress and consequently improve the seal of the restoration.
 - v) Flowable composites have higher polymerization shrinkage than other composites, mainly due to less filler content which increases the risk of microleakage.
 - vi) They offer better aesthetics as higher resin content provides more translucency.

- b) **Packable Composites/Condensable Composites:**

- i) They are characterized by higher filler content. This higher filler density provides increased strength and wear resistance, making them suitable for posterior restorations.
 - ii) There is Decrease in Coefficient of thermal expansion, so less change in dimension.
 - iii) Less resin content results in decreased translucency of the materials.
 - iv) Clinically, the material is less sticky and more viscous making it easier to establish proximal contact.

Indications and Contraindications of composite restorations: (Source-sturdevant)

- **The essential requirements for successful placement of composite restoration:**
 - i. For best bond presence of enamel around all the margins
 - ii. The cavity must be isolated from contamination so preferably use rubber dam.
 - iii. Cavity must be accessible to the activator light for adequate polymerization.

INDICATIONS:

- a) Class I, II, III, IV, V, and VI restorations.
- b) Foundations and core buildsups
- c) Sealants and preventive resin restorations (conservative composite restorations)
- d) Esthetic enhancement procedures: Partial veneers, Full veneers, Tooth contour modifications, Diastema closures.
- e) Temporary or provisional restorations.
- f) Periodontal splinting.
- g) Luting of indirect esthetic restorations (when used in flowable form, or when heated to increase flow)

DISCLAIMER

THIS IS COPYRIGHTED CONTENT. Unauthorized use, including screenshots, copying, misuse, reuse, or resale of any content from this app, is strictly prohibited. Our app monitors and records all screenshots and recordings. Violators will face strict legal action.

DISCLAIMER

THIS IS COPYRIGHTED CONTENT. Unauthorized use, including screenshots, copying, misuse, reuse, or resale of any content from this app, is strictly prohibited. Our app monitors and records all screenshots and recordings. Violators will face strict legal action.

DISCLAIMER

THIS IS COPYRIGHTED CONTENT. Unauthorized use, including screenshots, copying, misuse, reuse, or resale of any content from this app, is strictly prohibited. Our app monitors and records all screenshots and recordings. Violators will face strict legal action.

RESTORATIVE MATERIALS

CONTRAINDICATIONS:

- Inability to obtain adequate isolation
- Patients with excessive wear and bruxism.
- Extension of the restoration on root surface -It can lead to less than ideal marginal integrity.
- Operator factors: the operator must be committed to pursuing procedures, such as tooth isolation, that make bonded restorations successful.

Advantages and Disadvantages of composite resins: (Source-Sturdevant)

ADVANTAGES:

- Esthetics
- Conservative tooth preparation (less extension, minimum depth not necessary, mechanical retention usually not necessary)
- Low thermal conductivity,
- Universal use
- Adhesion to the tooth
- Repairability

DISADVANTAGES:

- May have poor marginal and internal cavity adaptation, usually occurring on root surfaces as a result of polymerization shrinkage stresses or improper insertion of the composite
- May exhibit marginal deterioration over time in areas where no marginal enamel is available for bonding.
- Are more difficult and time consuming to place, and more costly (compared with amalgam restorations) because bonding usually requires multiple steps
- Insertion is more difficult, establishing proximal contacts, axial contours, embrasures, and occlusal contacts may be more difficult; and finishing and polishing procedures are more difficult.
- They are more technique sensitive.
- May exhibit greater occlusal wear in areas of high occlusal stress or when all of the tooth's occlusal contacts are on the composite material.

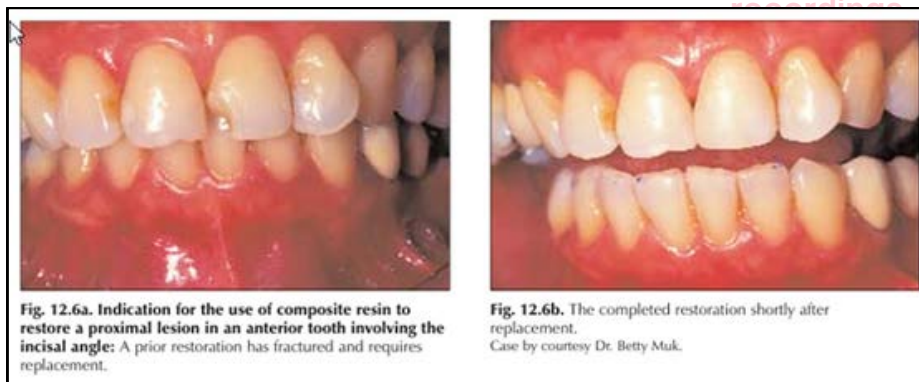


Fig. 12.6a. Indication for the use of composite resin to restore a proximal lesion in an anterior tooth involving the incisal angle: A prior restoration has fractured and requires replacement.

Fig. 12.6b. The completed restoration shortly after replacement.
Case by courtesy Dr. Betty Muk.

DISCLAIMER

THIS IS COPYRIGHTED CONTENT. Unauthorized use, including screenshots, copying, misuse, reuse, or resale of any content from this app, is strictly prohibited. Our app monitors and records all screenshots and recordings. Violators will face strict legal action.

DISCLAIMER
THIS IS COPYRIGHTED CONTENT. Unauthorized use, including screenshots, copying, misuse, reuse, or resale of any content from this app, is strictly prohibited. Our app monitors and records all screenshots and recordings. Violators will face strict legal action.

THIS IS COPYRIGHTED CONTENT. Unauthorized use, including screenshots, copying, misuse, reuse, or resale of any content from this app, is strictly prohibited. Our app monitors and records all screenshots and recordings. Violators will face strict legal action.

DISCLAIMER

RESTORATIVE MATERIALS

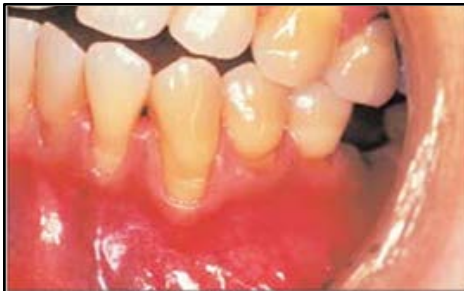

Fig. 12.7a. Indications for the placement of composite resins to restore labial cervical lesions on anterior teeth: There are multiple shallow cervical noncarious lesions on these anterior teeth requiring restoration with an aesthetic material.

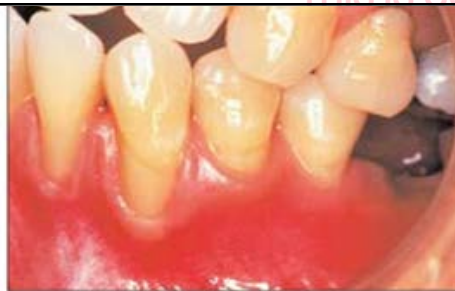

Fig. 12.7b. The lesions have been restored using composite resin with a dentine bonding agent.

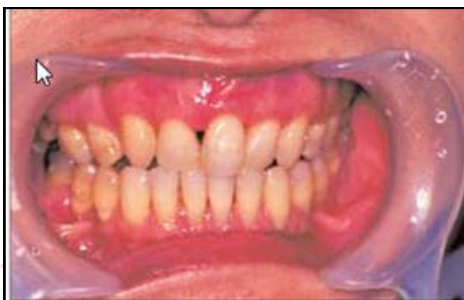

Fig. 12.9a. Modification of anterior teeth using composite resin: The maxillary right central incisor shows a size discrepancy in comparison with its matching neighbour. The lateral incisor is missing and the first premolars are discoloured.

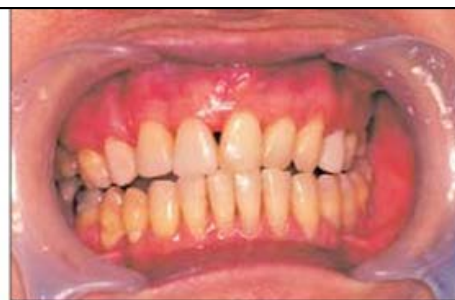

Fig. 12.9b. The size of the central incisor has been corrected, the canine has been reshaped to simulate a lateral incisor and the first bicuspid were veneered to mask discoloration.

Fig: Source-Mount and Hume

- **For Proximal Restorations the use of matrix system and wedging is important:** (Source-Sturdevant)
 - a) Class II composites are almost totally dependent on the contour and position of the matrix for establishing appropriate proximal contacts.
 - b) An ultrathin metal matrix band generally is preferred for the restoration of a Class II composite because it is thinner than a typical metal band and can be contoured better than a clear polyester matrix.
 - c) For restoring a two-surface tooth preparation (E.g. MO composite restoration), pre contoured sectional metallic matrix system are preferable.
 - d) When both proximal surfaces are involved (MOD restoration), a Tofflemire retainer with an ultrathin (0.025 mm or 0.001 inch) and burnishable matrix band is used.
 - e) Regardless of the type of matrix system used, the matrix material should extend at least 1 mm beyond the gingival margin (gingivally) and the area corresponding to the marginal ridge of the restoration (occlusally). The matrix should not extend further subgingivally or occlusally as it can interfere with the restorative procedure.

DISCLAIMER

THIS IS COPYRIGHTED CONTENT. Unauthorized use, including screenshots, copying, misuse, reuse, or resale of any content from this app, is strictly prohibited. Our app monitors and records all screenshots and recordings. Violators will face strict legal action.

DISCLAIMER

THIS IS COPYRIGHTED CONTENT. Unauthorized use, including screenshots, copying, misuse, reuse, or resale of any content from this app, is strictly prohibited. Our app monitors and records all screenshots and recordings. Violators will face strict legal action.

THIS IS COPYRIGHTED CONTENT. Unauthorized use, including screenshots, copying, misuse, reuse, or resale of any content from this app, is strictly prohibited. Our app monitors and records all screenshots and recordings. Violators will face strict legal action.

DISCLAIMER

RESTORATIVE MATERIALS

- A Triangular shaped wedge is needed at the gingival margin to
 - a) hold the matrix in position,
 - b) provide slight separation of the teeth,
 - c) Prevent a gingival overhang of the composite material.
- For posterior restorations, the wedge is placed from the larger to the smaller interproximal gingival embrasure, typically from a lingual approach, just apical to the gingival margin.

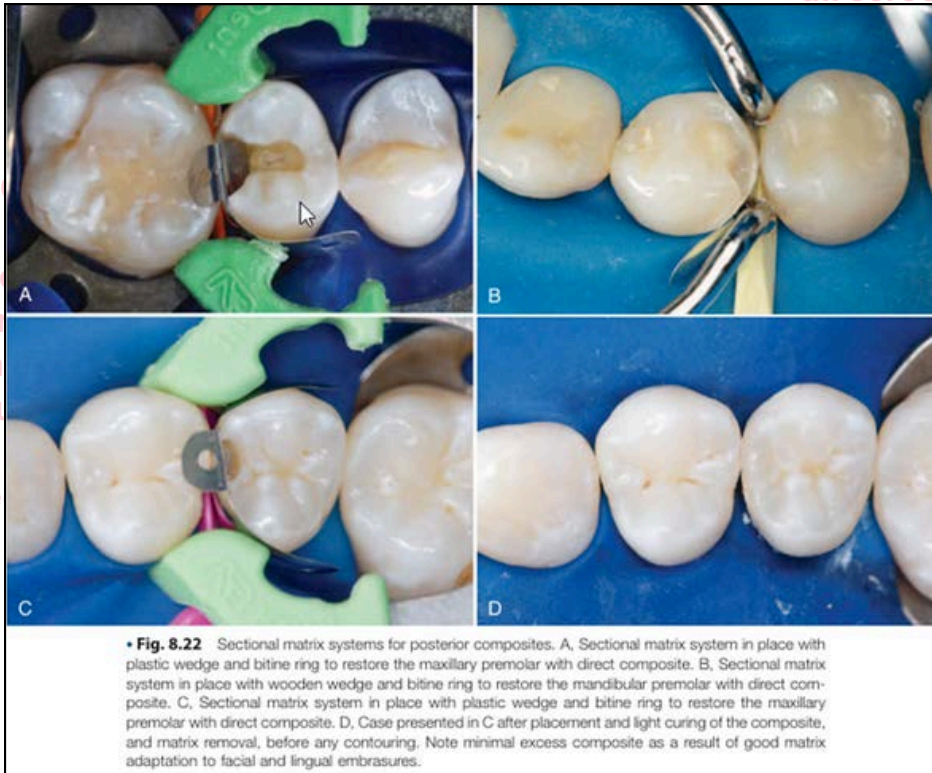

Fig: Source-Sturdevant

Note*- Composite resin is preferred restorative material in case of:

- radiation caries /Cases with dry mouth
- Sub gingival caries up to 0.5 mm
- Class V carious lesions
- Microfilled composites -in case of NCCLs

THIS IS COPYRIGHTED CONTENT. Unauthorized use, including screenshots, copying, misuse, reuse, or resale of any content from this app, is strictly prohibited. Our app monitors and records all screenshots and recordings. Violators will face strict legal action.

DISCLAIMER

THIS IS COPYRIGHTED CONTENT. Unauthorized use, including screenshots, copying, misuse, reuse, or resale of any content from this app, is strictly prohibited. Our app monitors and records all screenshots and recordings. Violators will face strict legal action.

DISCLAIMER
THIS IS COPYRIGHTED CONTENT. Unauthorized use, including screenshots, copying, misuse, reuse, or resale of any content from this app, is strictly prohibited. Our app monitors and records all screenshots and recordings. Violators will face strict legal action.

DISCLAIMER

THIS IS COPYRIGHTED CONTENT. Unauthorized use, including screenshots, copying, misuse, reuse, or resale of any content from this app, is strictly prohibited. Our app monitors and records all screenshots and recordings. Violators will face strict legal action.

RESTORATIVE MATERIALS

AMALGAM

- Amalgam is an alloy of one or more metals with mercury.
- Amalgam alloy is a silver-tin alloy to which varying amounts of copper (Cu) and small amounts of zinc (Zn) have been added.

Composition of amalgam:

(Source-Sturdevant 5th edition, Sturdevant 7th edition, Mount and Hume)

a) Copper Content of amalgam

- Low copper amalgam alloys have a total copper content less than 6%.
- High copper amalgam alloys have a total copper content greater than approximately 12%.

High copper amalgams have superior physical properties and clinical performance relative to the low copper amalgams mainly because of the absence of a tin/mercury (γ_2) reaction product and therefore reduced corrosion and creep.

b) Zinc component of amalgam

- Zinc Containing Alloys : Contains more than 0.01% zinc
- Zinc Free alloys: Those with less than 0.01% zinc
 - Amalgams that contain zinc appear to exhibit a lower rate of margin fracture under clinical loading but they exhibit an excessive delayed expansion if contaminated with moisture during placement.

c) Minor elements:

A number of elements, such as indium, palladium and platinum, may be included in the alloy in minor quantities. Although the proportion of these is usually less than 1%.

d) Gamma 2-phase content (γ_2):

- Amalgams may be described as γ_2 -containing or γ_2 free.
- Low copper amalgams contain the (Sn-Hg) reaction product which is called the γ_2 phase this reaction product is slow setting, weak and corrodes easily.
- Within several hours after amalgamation, all correctly manipulated high copper amalgams are γ_2 free.

e) Particle shape and type of amalgam:

- Lathe cut (or chip) refers to the irregularly shaped filings produced by cutting an ingot of alloy on a lathe. Prior to cutting, the ingot is homogenized to produce an alloy with a Ag-Sn phase (γ) as well as some regions of Cu_3Sn (ϵ)
- Spherical particles are produced by atomizing the alloy, whilst still liquid, into a stream of inert gas. They are usually not subjected to a homogenizing heat treatment and therefore contain Cu_3Sn (ϵ) finely dispersed in an Ag-Sn (γ) matrix.

DISCLAIMER

THIS IS COPYRIGHTED CONTENT. Unauthorized use, including screenshots, copying, misuse, reuse, or resale of any content from this app, is strictly prohibited. Our app monitors and records all screenshots and recordings. Violators will face strict legal action.

DISCLAIMER

THIS IS COPYRIGHTED CONTENT. Unauthorized use, including screenshots, copying, misuse, reuse, or resale of any content from this app, is strictly prohibited. Our app monitors and records all screenshots and recordings. Violators will face strict legal action.

THIS IS COPYRIGHTED CONTENT. Unauthorized use, including screenshots, copying, misuse, reuse, or resale of any content from this app, is strictly prohibited. Our app monitors and records all screenshots and recordings. Violators will face strict legal action.

DISCLAIMER

RESTORATIVE MATERIALS

f) Mercury content:

- Depending on the shape, size and composition of the alloy particles, the amount of mercury required to provide good amalgamation can vary from 40-53% by weight.
- Retention of excess mercury in the matrix will lead to loss of physical properties.
- Risk of mercury toxicity is higher when metallic mercury exists in liquid or vapor form, rather than bound in a set amalgam.
- As a vapor, metallic mercury can be inhaled and absorbed through the alveoli in the lungs at 80% efficiency.
- Inhalation is the major route of entry into the human body. Metallic mercury is poorly absorbed through the skin or via GI tract.
- In the dental office, the sources of mercury exposure related to amalgam include:
 - i. Amalgam raw materials being stored for use (usually as precapsulated packages)
 - ii. Mixed but unhardened amalgam during trituration, insertion, and intraoral hardening
 - iii. Amalgam scrap that has insufficient alloy to consume the mercury present completely;
 - iv. Amalgam undergoing finishing and polishing operations and
 - v. Amalgam restorations being removed. (most vapor generation)
- It is difficult, to contain liquid or gaseous mercury totally because it is very mobile, has a high diffusion rate, and penetrates through extremely fine spaces.

Properties of Amalgam:

- **Corrosion:** is defined as the electrochemical destruction of a metal by reaction with its environment.
 - i. Corrosion is the most important property of amalgam influencing the clinical longevity of the restoration.
 - ii. **Tarnishing** is a form of surface corrosion caused by oxidation of the Sn-Hg phase in low copper amalgams or the Cu-containing phases in high copper amalgams with the formation of a film of oxides, sulphides and hydroxides. Polarization may also take place with breakdown of the film and formation of a corrosion product leading to *pitting and roughening of the surface*.

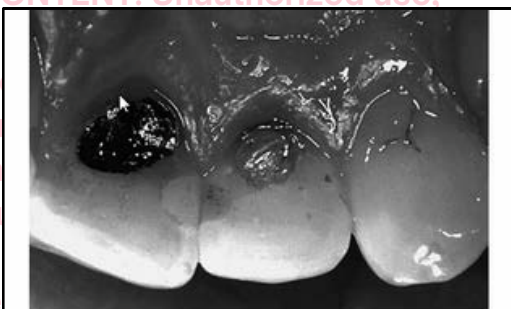


FIGURE 4-30 Clinical example of tarnished occlusal surface of amalgam restoration. (Courtesy of S.C. Bayne, School of Dentistry, University of North Carolina, Chapel Hill, NC.)

DISCLAIMER

THIS IS COPYRIGHTED CONTENT. Unauthorized use, including screenshots, copying, misuse, reuse, or resale of any content from this app, is strictly prohibited. Our app monitors and records all screenshots and recordings. Violators will face strict legal action.

DISCLAIMER

THIS IS COPYRIGHTED CONTENT. Unauthorized use, including screenshots, copying, misuse, reuse, or resale of any content from this app, is strictly prohibited. Our app monitors and records all screenshots and recordings. Violators will face strict legal action.

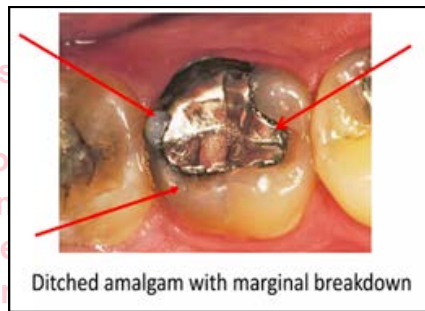
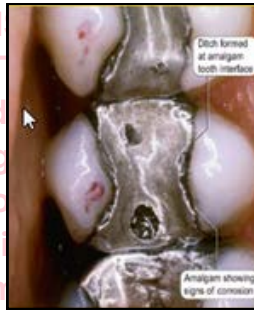THIS IS COPYRIGHTED CONTENT. Unauthorized use, including screenshots, copying, misuse, reuse, or resale of any content from this app, is strictly prohibited. Our app monitors and records all screenshots and recordings. Violators will face strict legal action.

DISCLAIMER

RESTORATIVE MATERIALS

iii. Crevice Corrosion: (Marginal ditching)

- It occurs in the gaps, cracks or crevices between amalgam and tooth structure.
- Inside the crevice, there is drop in oxygen level over time. This creates an oxygen concentration gradient between crevice (low oxygen) and open tooth surface (high oxygen).
- This difference in oxygen leads to electrochemical cell, where crevice acts as an anodic area (site of oxidation) and outer surface as a cathodic area.
- This imbalance leads to oxidation of metals (tin) within the crevice.
- The accumulation of oxidation products (tin oxides) inside the crevice can lead to expansion and dark staining.



iv. Corrosion Fatigue: This occurs particularly around the margins of restorations.

v. Galvanic Corrosion: Contact between dissimilar metals within an electrolyte may lead to galvanic corrosion.

• Creep:

- Creep is progressive permanent deformation of a set amalgam under load.
- Low copper amalgams show high creep values of greater than 2.5% which can be associated clinically with greater margin fracture.
- Alloys with low creep values typically demonstrate excellent marginal integrity over time.
- High copper amalgams display low creep values and are clinically successful alloys.

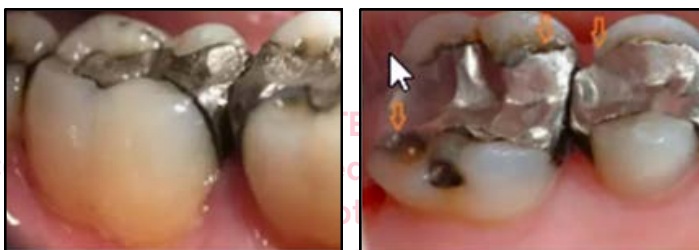

Fig: Showing Creep (Source-Internet)

DISCLAIMER

THIS IS COPYRIGHTED CONTENT. Unauthorized use, including screenshots, copying, misuse, reuse, or resale of any content from this app, is strictly prohibited. Our app monitors and records all screenshots and recordings. Violators will face strict legal action.

DISCLAIMER

THIS IS COPYRIGHTED CONTENT. Unauthorized use, including screenshots, copying, misuse, reuse, or resale of any content from this app, is strictly prohibited. Our app monitors and records all screenshots and recordings. Violators will face strict legal action.

THIS IS COPYRIGHTED CONTENT. Unauthorized use, including screenshots, copying, misuse, reuse, or resale of any content from this app, is strictly prohibited. Our app monitors and records all screenshots and recordings. Violators will face strict legal action.

DISCLAIMER

THIS IS COPYRIGHTED CONTENT. Unauthorized use, including screenshots, copying, misuse, reuse, or resale of any content from this app, is strictly prohibited. Our app monitors and records all screenshots and recordings. Violators will face strict legal action.

RESTORATIVE MATERIALS

- **Strength:**

- Amalgam has **high compressive strength** which makes it suitable for posterior restorations where it can withstand heavy biting forces during chewing.
- The **tensile strength** of amalgam is **lower** than the compressive strength which makes it prone to fracture when subjected to bending and pulling forces. Hence not ideal for thin unsupported areas such as edges and cusps.
- Amalgam has **limited flexural and shear strength** making it more brittle compared to composite resins.
- High copper amalgam eliminates the gamma 2 phase which significantly increases strength and reduces corrosion.

- **Dimensional Change:**

- Most amalgams exhibit a slight contraction on setting and this is of relatively minor clinical significance.
- Zinc containing amalgams, particularly low copper amalgams, may exhibit delayed expansion about 3-5 days after placement.
- Delayed expansion happens as a result of incorporation of water during clinical handling leading to an electrolytic reaction between the water and zinc.
- Hydrogen gas will be generated within the amalgam leading to expansion out of the cavity increased marginal leakage and pain.

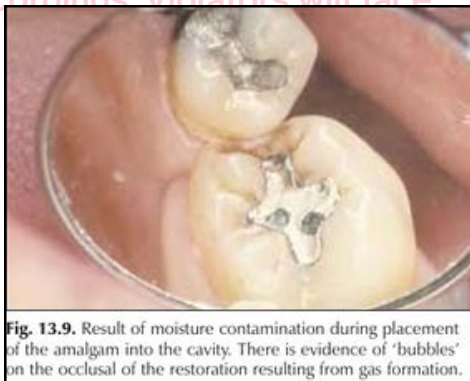


Fig. 13.9. Result of moisture contamination during placement of the amalgam into the cavity. There is evidence of 'bubbles' on the occlusal of the restoration resulting from gas formation.

Fig: Source (Mount and Hume)

Composition of amalgam:

(Source-Sturdevant 5th edition, Sturdevant 7th edition, Mount and Hume)

- **Trituration:**

- Trituration (or mixing) of the alloy with the mercury is carried out in a mechanical mixer (amalgamator) with the alloy and mercury in single use (ideally) or reusable capsules.
- The effectiveness of the mixing process will be influenced by the speed of the particular unit, the length and the direction of movement of the capsule in the machine, the presence of a pestle in the capsule and the length of time of mixing.
- A well-mixed amalgam should stay together when dropped but should be a little flattened and retain a wet gloss on the surface.

DISCLAIMER

THIS IS COPYRIGHTED CONTENT. Unauthorized use, including screenshots, copying, misuse, reuse, or resale of any content from this app, is strictly prohibited. Our app monitors and records all screenshots and recordings. Violators will face strict legal action.

DISCLAIMER

THIS IS COPYRIGHTED CONTENT. Unauthorized use, including screenshots, copying, misuse, reuse, or resale of any content from this app, is strictly prohibited. Our app monitors and records all screenshots and recordings. Violators will face strict legal action.

THIS IS COPYRIGHTED CONTENT. Unauthorized use, including screenshots, copying, misuse, reuse, or resale of any content from this app, is strictly prohibited. Our app monitors and records all screenshots and recordings. Violators will face strict legal action.

DISCLAIMER

RESTORATIVE MATERIALS

iv. Test for correct mix :

In Over trituration:

- Alloy will be hot
- Hard to remove from capsule
- Shiny wet and soft

In Under trituration:

- Alloy will be dry
- Will crumble

v. It is also better to slightly over triturate rather than under triturate an amalgam.

• Condensation:

- Condensation refers to the incremental placement of the amalgam into the prepared cavity and compression of each increment into the others to form a continuous homogeneous mass.
- It is done to adapt amalgam to the margins, walls and line angles of the cavity
- To minimize voids and layering between increments within the amalgam
- To remove excess mercury
- It is best carried out using hand instruments with a smooth flat surface. Smaller the diameter of the plugger the greater the pressure that can be applied.

• Pre-carve burnishing:

- After adequate condensation, a pre carve burnish is done using a large burnisher for 15 seconds.
- Use light force and move from the center of the restoration outwards across the margins.
- This will bring excess mercury to the surface, which must be removed.
- It also improves adaptation to the cavity margins.

• Carving:

- Carving should be done with very sharp instrument of appropriate shape (Carvers).
- While carving use the remaining enamel as a guide and take care to maintain marginal ridges and occlusal spillways.

• Post Carve Burnishing:

- After carving, check the occlusion, particularly in relation to lateral excursions and then carry out a brief final burnish.
- Use a small burnisher at a low load and burnish outwards across the margins to finally adapt the amalgam at the margin on both the occlusal and the proximal surfaces where access permits.

• Finishing:

- The amalgam restoration should be finished at a later appointment.
- It is done to refine the amalgam/tooth margin, adjust occlusal contacts, refine (but not deepen) occlusal anatomy, smooth the surface of the restoration to minimize plaque retention.

DISCLAIMER

THIS IS COPYRIGHTED CONTENT. Unauthorized use, including screenshots, copying, misuse, reuse, or resale of any content from this app, is strictly prohibited. Our app monitors and records all screenshots and recordings. Violators will face strict legal action.

DISCLAIMER

THIS IS COPYRIGHTED CONTENT. Unauthorized use, including screenshots, copying, misuse, reuse, or resale of any content from this app, is strictly prohibited. Our app monitors and records all screenshots and recordings. Violators will face strict legal action.

THIS IS COPYRIGHTED CONTENT. Unauthorized use, including screenshots, copying, misuse, reuse, or resale of any content from this app, is strictly prohibited. Our app monitors and records all screenshots and recordings. Violators will face strict legal action.

DISCLAIMER

RESTORATIVE MATERIALS

Advantages of Dental Amalgam:

- High Strength and Durability:** Amalgam is very strong in compression, making it suitable for restorations in posterior teeth where it can withstand heavy chewing forces.
- Cost-Effective:** Amalgam is generally less expensive than other restorative materials like composite or gold.
- Long-Lasting:** Amalgam restorations can last 10–15 years or more, often outlasting other materials, especially in large restorations.
- Ease of Placement:** Amalgam is less technique-sensitive than materials like composite, meaning it can be placed more easily in difficult-to-access areas and in situations where moisture control is challenging.
- Self-Sealing Property:** Amalgam has a natural ability to seal marginal gaps over time due to corrosion products, reducing microleakage. It is therefore highly resistant to recurrent caries.

Disadvantages of Dental Amalgam:

- Aesthetics:** Amalgam is silver-colored and does not match the natural color of teeth, making it less desirable for visible areas.
- Potential for Tooth Fracture:**
 - Amalgam's rigidity and lack of bonding with tooth structure can lead to tooth fracture, especially in teeth with large restorations and thin walls.
 - Bulk fracture of amalgam restorations is a common cause of failure during the first five years after restoration placed.

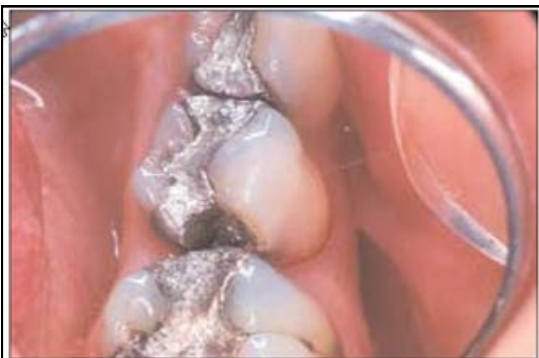

Fig. 13.14. Bulk fracture of an amalgam restoration. The main cause is the poor cavity design leaving a broad wedge of amalgam with no support.

- Research has found that fractures at the isthmus can be attributed to inadequate depth in the prepared cavity at this site.

DISCLAIMER

THIS IS COPYRIGHTED CONTENT. Unauthorized use, including screenshots, copying, misuse, reuse, or resale of any content from this app, is strictly prohibited. Our app monitors and records all screenshots and recordings. Violators will face strict legal action.

DISCLAIMER

THIS IS COPYRIGHTED CONTENT. Unauthorized use, including screenshots, copying, misuse, reuse, or resale of any content from this app, is strictly prohibited. Our app monitors and records all screenshots and recordings. Violators will face strict legal action.

THIS IS COPYRIGHTED CONTENT. Unauthorized use, including screenshots, copying, misuse, reuse, or resale of any content from this app, is strictly prohibited. Our app monitors and records all screenshots and recordings. Violators will face strict legal action.

DISCLAIMER

THIS IS COPYRIGHTED CONTENT. Unauthorized use, including screenshots, copying, misuse, reuse, or resale of any content from this app, is strictly prohibited. Our app monitors and records all screenshots and recordings. Violators will face strict legal action.

RESTORATIVE MATERIALS

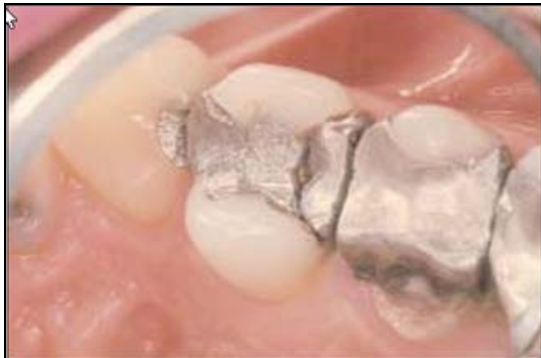

Fig. 13.15. The proximal box has fractured from this amalgam due likely to inadequate depth in the isthmus region.

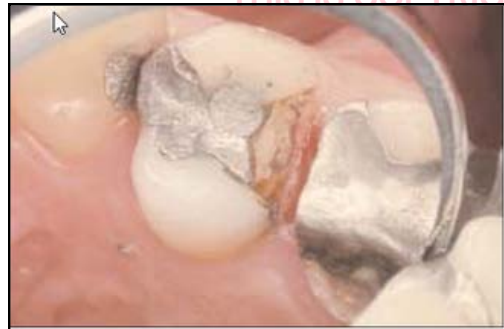

Fig. 13.16. The same restoration as shown in Figure 13.15 with cause of the failure now clear. The amalgam lacked bulk in the isthmus because of inadequate cavity depth.

- **Margin fracture** also referred to as margin breakdown, ditching and crevice formation is the result of an ongoing process of occlusal loading, deformation (creep), corrosion fatigue, fracture, formation of a crevice corrosion as well as further occlusal loading.

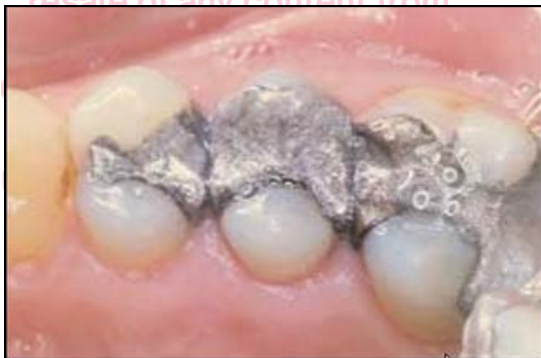

Fig. 13.13. A quadrant of old amalgam restorations showing chipped and ditched margins. The cause is unknown but cavity design is partly to blame.

c) Mercury Content: Amalgam contains mercury, which has raised health and environmental concerns. However, it is generally safe for dental use, though some patients may still prefer to avoid it.

d) Brittleness: Amalgam is more brittle than composite and can fracture in thin or unsupported areas.

e) Lack of Adhesion: Amalgam does not chemically bond to tooth structure, so the cavity preparation requires mechanical retention, which may lead to more removal of healthy tooth tissue.

DISCLAIMER

THIS IS COPYRIGHTED CONTENT. Unauthorized use, including screenshots, copying, misuse, reuse, or resale of any content from this app, is strictly prohibited. Our app monitors and records all screenshots and recordings. Violators will face strict legal action.

DISCLAIMER

THIS IS COPYRIGHTED CONTENT. Unauthorized use, including screenshots, copying, misuse, reuse, or resale of any content from this app, is strictly prohibited. Our app monitors and records all screenshots and recordings. Violators will face strict legal action.

THIS IS COPYRIGHTED CONTENT. Unauthorized use, including screenshots, copying, misuse, reuse, or resale of any content from this app, is strictly prohibited. Our app monitors and records all screenshots and recordings. Violators will face strict legal action.

DISCLAIMER

THIS IS COPYRIGHTED CONTENT. Unauthorized use, including screenshots, copying, misuse, reuse, or resale of any content from this app, is strictly prohibited. Our app monitors and records all screenshots and recordings. Violators will face strict legal action.

THIS IS COPYRIGHTED CONTENT. Unauthorized use, including screenshots, copying, misuse, reuse, or resale of any content from this app, is strictly prohibited. Our app monitors and records all screenshots and recordings. Violators will face strict legal action.

THIS IS COPYRIGHTED CONTENT. Unauthorized use, including screenshots, copying, misuse, reuse, or resale of any content from this app, is strictly prohibited. Our app monitors and records all screenshots and recordings. Violators will face strict legal action.

RESTORATIVE MATERIALS

Indications for Dental Amalgam:

- **Posterior Restorations:** Ideal for molars and premolars where aesthetics are less critical and high compressive strength is needed.
- **Large Cavities:** Suitable for large restorations, including class I and class II cavities, where amalgam's strength is beneficial.
- **High-Stress Areas:** Suitable for areas with heavy occlusal load or patients with bruxism.
- **Patients with Limited Finances:** Amalgam is a cost-effective option for patients seeking an economical choice.

Contraindications for Dental Amalgam:

- **Aesthetic Areas:** Not recommended for anterior teeth or visible areas where a tooth-colored restoration is preferred.
- **Allergy to Amalgam Components:** Contraindicated in patients with proven allergies to mercury or other metals in amalgam.
- **Small Cavities in Low-Stress Areas:** In small lesions or low-stress areas where less strength is required, composite or other adhesive restorations may be preferred.
- **Patients Concerned about Mercury Exposure:** For patients with concerns about mercury or specific health conditions where amalgam may be contraindicated (such as in some pregnant patients), alternative materials are preferred.
- **Extremely Large Cavities with Thin Tooth Structure:** In cases where very large portions of the tooth structure are lost, amalgam's brittleness may lead to fracture. Indirect restorations like crowns may be better options.

THIS IS COPYRIGHTED
CONTENT. Unauthorized use,
including screenshots,
copying, misuse, reuse, or
resale of any content from
this app, is strictly prohibited.
Our app monitors and records
all screenshots and
recordings. Violators will face
strict legal action.

DISCLAIMER

THIS IS COPYRIGHTED CONTENT. Unauthorized use, including screenshots, copying, misuse, reuse, or resale of any content from this app, is strictly prohibited. Our app monitors and records all screenshots and recordings. Violators will face strict legal action.

DISCLAIMER
THIS IS COPYRIGHTED CONTENT. Unauthorized use, including screenshots, copying, misuse, reuse, or resale of any content from this app, is strictly prohibited. Our app monitors and records all screenshots and recordings. Violators will face strict legal action.

DISCLAIMER

THIS IS COPYRIGHTED CONTENT. Unauthorized use, including screenshots, copying, misuse, reuse, or resale of any content from this app, is strictly prohibited. Our app monitors and records all screenshots and recordings. Violators will face strict legal action.

RESTORATIVE MATERIALS

GLASS IONOMER CEMENTS

(Source-Sturdevant 5th edition, Sturdevant 7th edition, Mount and Hume)

- Glass ionomer cement (GIC) is a type of dental restorative material which can chemically bond to both enamel and dentin.

Composition:

GIC is made from two primary components:

- Powder** - Typically contains a mix of:
 - **Calcium-aluminum-fluorosilicate glass** (provides the fluoride release, strength, and radiopacity).
 - **Barium** or other radiopaque fillers for visibility on X-rays.
- Liquid** - Typically contains:
 - **Polyacrylic acid** that reacts with the glass particles to form the cement.
 - **Water** (the medium for the acid-base reaction).

Properties of Glass Ionomer Cement:

- Chemical Bonding:**
 - **Bond to enamel and dentin:** One of the most distinctive features of GIC is its ability to bond chemically to tooth structure. This bonding is achieved through an acid-base reaction between the polyacrylic acid in the liquid and the glass particles in the powder.
- Fluoride Release:**
 - GIC releases fluoride ions over time, which can help in remineralizing adjacent tooth structures and preventing further decay. The fluoride release is greatest initially, but it continues at a reduced rate for several months.
- Biocompatibility:**
 - GIC is biocompatible with dental tissues, and there are minimal chances of adverse reactions when it is used appropriately. It does not irritate the pulp and is less likely to cause allergic reactions than other materials.
- Low Thermal Expansion:**
 - GIC has a coefficient of thermal expansion similar to that of natural tooth enamel. This makes it less likely to cause stress or damage to the tooth structure when exposed to temperature changes.
- Moderate Strength:**
 - The compressive strength of GIC is generally moderate, which makes it suitable for non-load-bearing areas in the mouth. However, it is not as strong as composite resins or amalgam, especially in high-stress areas like posterior teeth.
- Wear Resistance:**
 - GIC is more prone to wear compared to other restorative materials, such as composite resins and amalgam. However, it performs adequately in low-stress areas and as a temporary filling material.

DISCLAIMER

THIS IS COPYRIGHTED CONTENT. Unauthorized use, including screenshots, copying, misuse, reuse, or resale of any content from this app, is strictly prohibited. Our app monitors and records all screenshots and recordings. Violators will face strict legal action.

DISCLAIMER

THIS IS COPYRIGHTED CONTENT. Unauthorized use, including screenshots, copying, misuse, reuse, or resale of any content from this app, is strictly prohibited. Our app monitors and records all screenshots and recordings. Violators will face strict legal action.

DISCLAIMER

THIS IS COPYRIGHTED CONTENT. Unauthorized use, including screenshots, copying, misuse, reuse, or resale of any content from this app, is strictly prohibited. Our app monitors and records all screenshots and recordings. Violators will face strict legal action.

RESTORATIVE MATERIALS

vii. Cohesion and Adhesion:

- GIC has good initial adhesion to tooth structure, but its long-term bond strength may degrade in some cases, especially when exposed to moisture. The bond strength can be improved by using a bonding agent or conditioner.

xiii. Workability:

- Glass ionomer cements have a relatively short working time and set relatively quickly. They can be manipulated and placed directly into the cavity and will harden over time, with full strength achieved after several hours.

ix. Radiopacity:

- GIC is radiopaque, making it easy for clinicians to differentiate it from natural tooth structure and other materials.

x. Aesthetic Appearance:

- GIC is available in different shades, and its aesthetic properties are suitable for anterior restorations, although not as tooth-like as composite materials. It tends to have a duller finish and may discolor over time.

Classification of GIC (Based on Clinical Use):

GIC classification according to its clinical use
@Little Running Before Food Or Chocolate For Artistic Children

Type I	Luting
Type II	Restorative
Type III	Liner and Base
Type IV	Pits and Fissure sealants
Type V	Orthodontic cements
Type VI	Core build up material
Type VII	Fluoride releasing
Type VIII	GIC for ART
Type IX	Geriatric and Pediatric GIC

Image: Source-Internet

RESTORATIVE MATERIALS

Advantages of Glass Ionomer Cement:

- Fluoride release helps in preventing secondary caries.
- Chemical bond to tooth structure eliminates the need for bonding agents.
- Good biocompatibility with minimal irritation to pulp and surrounding tissues.
- Moisture tolerance during placement, making it easier to use in areas with moisture control challenges.
- Easy handling and can be placed directly into the cavity.

Disadvantages of Glass Ionomer Cement:

- The main limitation is a relatively low fracture resistance such that it cannot be used alone to withstand undue occlusal load.
- It is not suitable to rebuild marginal ridges or incisal corners.
- Lower mechanical strength compared to composites or amalgam.
- Wear resistance can be a concern, especially in areas subject to heavy occlusal forces.
- Aesthetic limitations as it doesn't match tooth color as well as composites and may discolor over time.
- As a water based material, it is subject to dehydration, particularly in the early stages after placement.
- In addition, it will dehydrate and disintegrate in the presence of a low salivary flow. For patients with Sjogrens Syndrome and similar salivary incompetence it is important to confine the use of glass ionomer as a dentine substitute and to laminate over it with another material to protect it.

SUMMARY
Glass-ionomer
Advantages
<ul style="list-style-type: none"> • Ion exchange adhesion to tooth structure • Ion exchange with tooth structure • Continuing fluoride reservoir • Acceptable aesthetics • Good wear factor on maturity • Low solubility on maturity
Disadvantages
<ul style="list-style-type: none"> • Low fracture resistance • Subject to dehydration in absence of saliva

SUMMARY
Three types of retention
<ul style="list-style-type: none"> • Chemical = glass-ionomer • Micromechanical = composite resin • Macromechanical = amalgam

Image: Source-Mount and Hume

DISCLAIMER

THIS IS COPYRIGHTED CONTENT. Unauthorized use, including screenshots, copying, misuse, reuse, or resale of any content from this app, is strictly prohibited. Our app monitors and records all screenshots and recordings. Violators will face strict legal action.

DISCLAIMER

THIS IS COPYRIGHTED CONTENT. Unauthorized use, including screenshots, copying, misuse, reuse, or resale of any content from this app, is strictly prohibited. Our app monitors and records all screenshots and recordings. Violators will face strict legal action.

DISCLAIMER

THIS IS COPYRIGHTED CONTENT. Unauthorized use, including screenshots, copying, misuse, reuse, or resale of any content from this app, is strictly prohibited. Our app monitors and records all screenshots and recordings. Violators will face strict legal action.

RESTORATIVE MATERIALS

RESIN MODIFIED GLASS IONOMER CEMENT

(Source- Sturdevant, Internet)

- Resin-Modified Glass Ionomer Cement (RMGIC) (e.g. Fuji Plus) is a hybrid material that combines the benefits of traditional glass ionomer cements (GIC) with the added advantages of resins to improve some of the limitations of conventional GIC.
- These cements have two setting reactions: the classic acid-base reaction and a chemical-cure resin reaction.

Composition of Resin-Modified Glass Ionomer Cement (RMGIC)

RMGIC consists of the following components:

i. Glass Powder:

Like conventional GIC, RMGIC contains a glass powder made of fluorosilicate or calcium-aluminosilicate glass that provides the material with its fluoride-releasing properties and radiopacity.

ii. Polyacid Liquid:

The liquid component is typically a polyacrylic acid or copolymer of polycarboxylic acid that enables the chemical bonding of the cement to tooth enamel and dentin.

iii. Resins:

The addition of methacrylate-based resins (such as Bis-GMA) improves the material's mechanical properties, including strength and wear resistance. These resins also allow the material to be light-cured (or in some cases, self-cured).

iv. Water:

The liquid contains water to facilitate the acid-base reaction with the glass particles, similar to traditional GICs.

Properties of Resin-Modified Glass Ionomer Cement (RMGIC)

i. Improved Mechanical Strength:

- RMGIC has higher compressive and flexural strength than conventional GICs due to the inclusion of resins, making it more suitable for posterior restorations and other areas that experience mechanical stress.
- Wear resistance is also improved compared to conventional GIC, making it more durable, particularly in molar areas.

ii. Fluoride Release:

- Like traditional GIC, RMGICs release fluoride ions over time, which helps to remineralize enamel and prevent recurrent decay.
- The fluoride release is typically lower than that of conventional GICs.

iii. Chemical Bonding:

- RMGIC retains the ability to chemically bond to enamel and dentin, providing an adhesive interface without the need for an additional bonding agent. This bond is stronger than that of conventional GICs due to the presence of resins.

DISCLAIMER

THIS IS COPYRIGHTED CONTENT. Unauthorized use, including screenshots, copying, misuse, reuse, or resale of any content from this app, is strictly prohibited. Our app monitors and records all screenshots and recordings. Violators will face strict legal action.

DISCLAIMER

THIS IS COPYRIGHTED CONTENT. Unauthorized use, including screenshots, copying, misuse, reuse, or resale of any content from this app, is strictly prohibited. Our app monitors and records all screenshots and recordings. Violators will face strict legal action.

THIS IS COPYRIGHTED CONTENT. Unauthorized use, including screenshots, copying, misuse, reuse, or resale of any content from this app, is strictly prohibited. Our app monitors and records all screenshots and recordings. Violators will face strict legal action.

DISCLAIMER

RESTORATIVE MATERIALS

iv. Aesthetic Properties:

- RMGICs offer improved aesthetic properties compared to conventional GIC. They are available in various shades that can closely match the natural tooth color, making them more suitable for anterior restorations.
- While not as esthetically versatile as composite resins, RMGICs are better in appearance than traditional GICs, which can have a more opaque, dull finish.

v. Light Cure Capability:

- Many RMGICs are light-curable. This provides better control over setting time compared to traditional GICs, which are typically self-cured.
- Some RMGICs also allow for dual curing, meaning they can be both light-cured and self-cured, providing additional flexibility in different clinical situations.

vi. Moisture Tolerance:

- While not as moisture-tolerant as conventional GIC, RMGICs still perform better than composite resins in environments with limited moisture control (e.g., areas of the mouth that are difficult to isolate). Hence, making it the choice of restorative material in case of Root caries.
- This makes RMGICs useful in situations where absolute dryness is difficult to achieve, such as in pediatric or geriatric patients.

vii. Thermal Insulation:

- RMGICs provide good thermal insulation due to their ability to act as a barrier between the dental pulp and hot or cold stimuli.

viii. Radiopacity

- RMGICs are radiopaque, meaning they show up on X-rays, allowing the clinician to easily monitor the integrity of the restoration.

Indications (Sturdevant -7th edition)

- Resin-modified glass ionomer restorative materials are indicated for root caries lesions due to their excellent adhesion to tooth structure and fluoride release.
- They are also recommended for repair of recurrent caries around existing indirect restorations. (Removal of the existing restoration is generally preferred in these situations, but is not always practical)
- RMGI restorative materials are the materials of choice for the restoration of NCCLs where esthetics is NOT of primary importance. RMGI materials have an excellent clinical history of retention with NCCLs, due to excellent adhesion and low elastic modulus, but the long-term esthetic result is compromised.

DISCLAIMER

THIS IS COPYRIGHTED CONTENT. Unauthorized use, including screenshots, copying, misuse, reuse, or resale of any content from this app, is strictly prohibited. Our app monitors and records all screenshots and recordings. Violators will face strict legal action.

DISCLAIMER

THIS IS COPYRIGHTED CONTENT. Unauthorized use, including screenshots, copying, misuse, reuse, or resale of any content from this app, is strictly prohibited. Our app monitors and records all screenshots and recordings. Violators will face strict legal action.

DISCLAIMER

THIS IS COPYRIGHTED CONTENT. Unauthorized use, including screenshots, copying, misuse, reuse, or resale of any content from this app, is strictly prohibited. Our app monitors and records all screenshots and recordings. Violators will face strict legal action.

RESTORATIVE MATERIALS

Contraindication

- Resin-modified glass ionomer restorative materials are contraindicated in stress bearing situations.

NOTE*

1) Composite resin is preferred restorative material in case of:

- radiation caries /Cases with dry mouth
- Sub gingival caries up to 0.5 mm
- Class V carious lesions

2) Micro-filled composites -in case of NCCLs

3) Resin Modified Glass ionomer Cement-

- Root caries
- Sub gingival caries extending more than 0.5mm.

4) GIC is never used as a permanent restorative material.

RESTORATIVE MATERIALS

SILVER DIAMINE FLUORIDE (SDF)

(Source-Articles on SDF, Sturdevant)

- Silver diamine fluoride (SDF) is a topical solution mostly used as a caries-arresting and anti-hypersensitivity agent. (Sturdevant)

Uses of SDF (Source-Articles on sdf as desensitizing agent and clinical use)

a) As a desensitizing agent:

- Use of SDF (38%) followed by potassium iodide is effective for blocking open dentinal tubules.
- Factors that contributed to reduction in dentine hypersensitivity:
 - i. Silver ions can precipitate proteins in dentinal tubules
 - ii. Fluoride ions can react with free calcium to form deposits of calcium fluoride that can block open dentinal tubules.
 - iii. Formation of silver iodide from reaction between SDF and potassium iodide contributes to further reduction in dentine tubule patency.
- Transient drawback with use of SDF is mild transient gingival erythema near the treated tooth.

b) Arrest carious lesion

(At concentration of 38%) It can be directly applied on the sound tooth surface for prevention and on carious lesion for arrestment. SDF does not stain sound enamel.

c) Manage dental caries in Young apprehensive children's.

d) For patients with special needs where SDF can be used without caries removal as SMART Technique. (Preferred over ART)

e) As a root canal disinfectant:

- At a concentration of 3.8 %.It is applied 3 times at 24 hours interval.(i.e. Recall each day apply sdf for 3 days)
- This will lead to 100% reduction in E.Faecialis after 60 min exposure.

Benefits of SDF:

- SDF shows antimicrobial activity against mono, dual and multi species cariogenic biofilm.
- Remineralizing effect by fluoride.
- Its application procedures are simple, not technique sensitive so very effective in young apprehensive patients, Uncooperative patients with special needs, Old patients.
- Low cost so affordable in many communities.
- There is no difference in removal of caries or no removal of caries prior to use of SDF.

DISCLAIMER

THIS IS COPYRIGHTED CONTENT. Unauthorized use, including screenshots, copying, misuse, reuse, or resale of any content from this app, is strictly prohibited. Our app monitors and records all screenshots and recordings. Violators will face strict legal action.

DISCLAIMER

THIS IS COPYRIGHTED CONTENT. Unauthorized use, including screenshots, copying, misuse, reuse, or resale of any content from this app, is strictly prohibited. Our app monitors and records all screenshots and recordings. Violators will face strict legal action.

DISCLAIMER

THIS IS COPYRIGHTED CONTENT. Unauthorized use, including screenshots, copying, misuse, reuse, or resale of any content from this app, is strictly prohibited. Our app monitors and records all screenshots and recordings. Violators will face strict legal action.

RESTORATIVE MATERIALS

Disadvantages of SDF:

- The inherent drawback of SDF is the caries lesion will be stained black after SDF application due to precipitation of silver.
- It can also transiently stain skin (for 7 days) and clothes (permanently).
- SDF solution has an unpleasant metallic taste.
- Transient gingival erythema for 1-2 days may occur.
- SDF is sensitive to light so must be stored in a dark/opaque container.
- Can cause fluorosis in young children so multiple application is avoided.

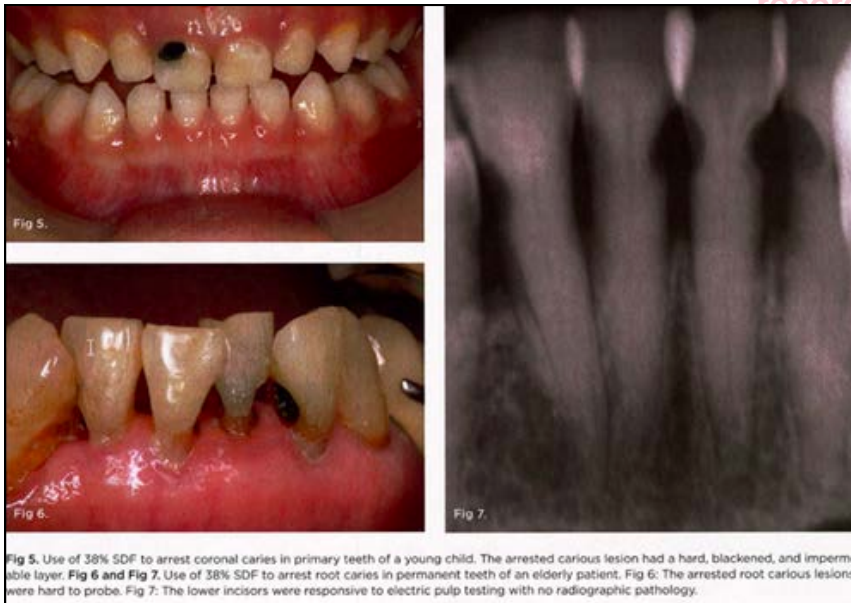

Image: (Source-Article on SDF)

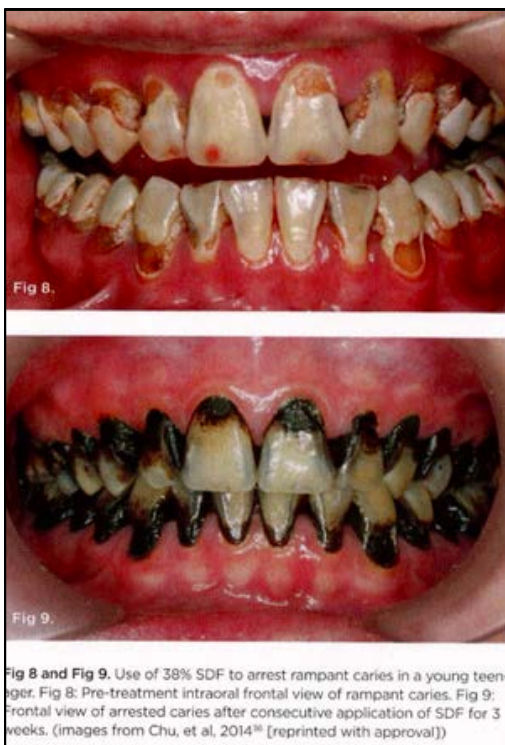

Image- Source (Articles)

DISCLAIMER

THIS IS COPYRIGHTED CONTENT. Unauthorized use, including screenshots, copying, misuse, reuse, or resale of any content from this app, is strictly prohibited. Our app monitors and records all screenshots and recordings. Violators will face strict legal action.

DISCLAIMER

THIS IS COPYRIGHTED CONTENT. Unauthorized use, including screenshots, copying, misuse, reuse, or resale of any content from this app, is strictly prohibited. Our app monitors and records all screenshots and recordings. Violators will face strict legal action.

THIS IS COPYRIGHTED CONTENT. Unauthorized use, including screenshots, copying, misuse, reuse, or resale of any content from this app, is strictly prohibited. Our app monitors and records all screenshots and recordings. Violators will face strict legal action.

THIS IS COPYRIGHTED CONTENT. Unauthorized use, including screenshots, copying, misuse, reuse, or resale of any content from this app, is strictly prohibited. Our app monitors and records all screenshots and recordings. Violators will face strict legal action.

THIS IS COPYRIGHTED CONTENT. Unauthorized use, including screenshots, copying, misuse, reuse, or resale of any content from this app, is strictly prohibited. Our app monitors and records all screenshots and recordings. Violators will face strict legal action.

DISCLAIMER

DRUG ABUSE/ RADIATION/ DRY MOUTH/ SJOGRENS/ CARIES

DRUG ABUSE

- Illicit drug use can have adverse effect on oral health. Many illicit drugs cause dry mouth and combined with a cariogenic diet and lack of oral hygiene can result in dental caries, oral candidiasis and other oral infections. (Source: TG)
- Most common drug abuse with dental implications is amphetamine (Methamphetamine). Opioid (Cocaine) is also commonly abused drug.
- If substance use disorder is identified it is important to investigate the use of other substances, because multiple drug use is common. (Source: TG)

METH MOUTH:

- Meth mouth is a term used to describe the mouth of a methamphetamine user with classical caries pattern. The drug is also referred to as Meth/speed/crank/ice/quartz/crystals.
- In less than 1 year of use meth users can go from having a healthy mouth to rampant decay and tooth loss.

Effect of Meth on oral tissues: (Source-Article on meth mouth)

- Dry mouth- Firstly meth reduces the salivary production, the dry mouth increases cravings for sugary carbonated food and drinks which damages the teeth and gums. Moreover the 'HIGH' from the drugs lasts several hours during which time the meth users will not brush or rinse their mouth to remove the plaque and sugary material leading to more severe extensive damage.
 - i) *Note -in meth mouth the sequence that follows is
 - ii) SSP-Saliva (poor salivary flow), Sugary drinks and food cravings, Poor oral hygiene
- Tooth decay: The very high sugar content in the diet of meth users along with ineffective oral hygiene leads to rampant tooth decay in cases of meth users.
- Effect on Periodontal tissues: Meth causes
 - a) Reduction in blood supply to the gums (Due to shrinkage of vessels)
 - b) Meth users are more susceptible to infection and gum disease as their immune system is weakened.
- Meth users tend to grind and clench their teeth due to nervousness or stress from the drug reactions which increases susceptibility to broken or cracked tooth.

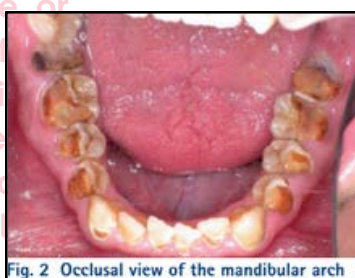
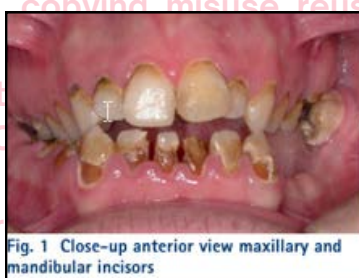
Image-Meth mouth (source-Article)

DISCLAIMER

THIS IS COPYRIGHTED CONTENT. Unauthorized use, including screenshots, copying, misuse, reuse, or resale of any content from this app, is strictly prohibited. Our app monitors and records all screenshots and recordings. Violators will face strict legal action.

DISCLAIMER

THIS IS COPYRIGHTED CONTENT. Unauthorized use, including screenshots, copying, misuse, reuse, or resale of any content from this app, is strictly prohibited. Our app monitors and records all screenshots and recordings. Violators will face strict legal action.

DISCLAIMER

THIS IS COPYRIGHTED CONTENT. Unauthorized use, including screenshots, copying, misuse, reuse, or resale of any content from this app, is strictly prohibited. Our app monitors and records all screenshots and recordings. Violators will face strict legal action.

DRUG ABUSE/ RADIATION/ DRY MOUTH/ SJOGRENS/ CARIES

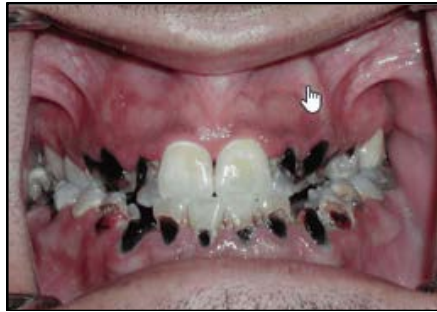

Image-Meth mouth (source-Internet)

Effects on General Health: In addition to oral implications it can cause increased HTN, increased respiration, Nausea and vomiting, hyperthermia, diarrhea, irregular heartbeat and even permanent heart damage.

Dental Management:

- The most important aspect of the management is to encourage the patient to stop abuse of methamphetamine. Pt counselling with information of the effects with continued use of drug must be done.
- Regular oral health instruction and education with determination of patient adherence and participation is the core of oral health management.
- Dental management should address pain and infection before aesthetic concerns.
- The approach on oral management should be multidisciplinary with the focus on prevention, promotion, restoring teeth and assessing salivary gland functions.
- In the event of early detection of illicit drug use by dentists (due to oral symptoms) it is the responsibility of the dentist to refer to a specialized addiction treatment center
- Patients need to be informed that consumption of carbonated food and drinks should be reduced immediately and to improve their oral hygiene.
- Patients need to be educated on maintaining oral hygiene i.e. brushing twice a day with fluoridated tooth paste and flossing regularly.
- Regular Professional fluoride application is recommended to reduce the dental caries progression. (5000ppm sodium fluoride).
- As meth users are presented with Xerostomia (measures to reduce dry mouth should be followed.)
- Use of SDF in arresting the carious lesions is also recommended.

It is important for the meth user to:

- Seek drug counselling and treatment for the addiction
- Maintain a proper home care program, as directed by a dental professional
- Help stimulate saliva flow by sipping water, chewing sugarfree gum and sucking on ice chips
- Schedule regular dental hygiene appointments for check-ups and cleanings to remove bacterial plaque buildup

Image - (source-Article)

DISCLAIMER

THIS IS COPYRIGHTED CONTENT. Unauthorized use, including screenshots, copying, misuse, reuse, or resale of any content from this app, is strictly prohibited. Our app monitors and records all screenshots and recordings. Violators will face strict legal action.

DISCLAIMER

THIS IS COPYRIGHTED CONTENT. Unauthorized use, including screenshots, copying, misuse, reuse, or resale of any content from this app, is strictly prohibited. Our app monitors and records all screenshots and recordings. Violators will face strict legal action.

THIS IS COPYRIGHTED CONTENT. Unauthorized use, including screenshots, copying, misuse, reuse, or resale of any content from this app, is strictly prohibited. Our app monitors and records all screenshots and recordings. Violators will face strict legal action.

DISCLAIMER

DRUG ABUSE/ RADIATION/ DRY MOUTH/ SJOGRENS/ CARIES

DRY MOUTH

- Dry mouth also known as Xerostomia is a relatively common condition, which can be subjective feeling of dryness with normal salivary flow (False Xerostomia) or objective reduction of salivary quantity and quality/ Salivary Gland Hypofunction SGH - where there is reduction of salivary output/flow. (True Xerostomia) (source-Odell and TG)

Etiology:

- The common causes of dry mouth includes:
 - a) Dehydration
 - b) Alcohol
 - c) Anxiety
 - d) Mouth breathing
 - e) Drugs (most common) - (source-Odell)
- Less common cause of dry mouth include: Disease such as Sjogrens syndrome.
- The drugs commonly associated with dry mouth includes:

Box 13. Drugs frequently associated with dry mouth [NB1]

• anticholinergic drugs
• antihistamines
• drugs to lower blood pressure
– angiotensin converting enzyme inhibitors
– angiotensin II receptor blockers
– alpha blockers
– beta blockers
– diuretics
• inhaled bronchodilators
– beta ₂ agonists (eg salbutamol)
– muscarinic antagonists (eg tiotropium)
• opioids
• psychotropic drugs
– antidepressants
– antipsychotics
– illicit drugs (eg marijuana, cocaine)
– psychostimulants (eg amfetamines)
• urinary antispasmodics

B1: Dry mouth is likely to be more severe if these drugs are used in combination.

Image - (source-TG)

DISCLAIMER

THIS IS COPYRIGHTED CONTENT. Unauthorized use, including screenshots, copying, misuse, reuse, or resale of any content from this app, is strictly prohibited. Our app monitors and records all screenshots and recordings. Violators will face strict legal action.

DISCLAIMER
THIS IS COPYRIGHTED CONTENT. Unauthorized use, including screenshots, copying, misuse, reuse, or resale of any content from this app, is strictly prohibited. Our app monitors and records all screenshots and recordings. Violators will face strict legal action.

DRUG ABUSE/ RADIATION/ DRY MOUTH/ SJOGRENS/ CARIES

TABLE 2: SOME MEDICINES CAUSING DRY MOUTH²⁻¹⁰

DRUG CLASS	EXAMPLES
Alcohol	
Antidepressants	Tricyclic antidepressants, some SSRIs (e.g. citalopram, escitalopram, fluoxetine, fluvoxamine, paroxetine), some SNRIs (e.g. duloxetine) and other antidepressants (e.g. mirtazapine).
Antihistamines (first generation with anticholinergic effects)	Brompheniramine, chlorpheniramine, cyclizine, cyproheptadine, dexchlorpheniramine, dimenhydrinate, diphenhydramine, pheniramine, promethazine, trimeprazine, triprolidine
Antipsychotic medicines (due to anticholinergic effects)	Amisulpride, aripiprazole, asenapine, chlorpromazine, clozapine, haloperidol, lurasidone, olanzapine, paliperidone, quetiapine, risperidone, ziprasidone
Benzodiazepines	Class effect, e.g. diazepam
Betablockers	e.g. atenolol
Caffeine	In coffee, also combined with paracetamol
Medicines with anticholinergic effects (plus first generation antihistamines)	Acidinium, amantadine, amitriptyline, atropine, belladonna alkaloids, benzhexol, benztrapine, biperiden, chlorpromazine, clomipramine, cyclopentolate, darifenacin, disopyramide, dothiepin, doxepin, glycopyrronium, homatropine, hyoscine (butylbromide or hydrobromide), imipramine, ipratropium, mianserin, nortriptyline, orphenadrine, oxybutynin, pericyazine, pizotifen, prochlorperazine, propantheline, solifenacin, tiotropium, tolterodine, tropicamide, umecclidinium
Methadone	Pharmacotherapy replacement programs. Dry mouth leading to significant salivary hypofunction and development of dental caries

- Dry mouth is also a debilitating side effect of head and neck radiotherapy with the degree of salivary flow reduction dependent on dose and region of radiation.
*Note-The full curative dose for most head and neck cancers is 60–65 grays (Gy; 1 Gy is the absorption of 1 joule of radiation energy per kilogram), but mild salivary gland damage can be detected after only 4 Gy, and severe permanent damage occurs with doses above 30 Gy to the glands.(Source-Odell)
- Dry mouth is more common in older people than other age groups.(article)
- Dehydration is a common cause in older people who may have a habitual low fluid intake, especially when institutionalized. It also accompanies cardiac or renal failure or use of diuretic drugs. (The combination of drugs and disease probably explains the apparent association of xerostomia with age.) (Source-Odell)

DISCLAIMER

THIS IS COPYRIGHTED CONTENT. Unauthorized use, including screenshots, copying, misuse, reuse, or resale of any content from this app, is strictly prohibited. Our app monitors and records all screenshots and recordings. Violators will face strict legal action.

DISCLAIMER
THIS IS COPYRIGHTED CONTENT. Unauthorized use, including screenshots, copying, misuse, reuse, or resale of any content from this app, is strictly prohibited. Our app monitors and records all screenshots and recordings. Violators will face strict legal action.

DRUG ABUSE/ RADIATION/ DRY MOUTH/ SJOGRENS/ CARIES

Effect on oral tissues:

Chronic dry mouth can lead to

- Tooth decay and erosion
- Periodontal disease
- Oral mucosal disease
- Oral candidiasis
- Difficulty with retention of dentures
- Difficulty with chewing and swallowing
- Altered sense of taste

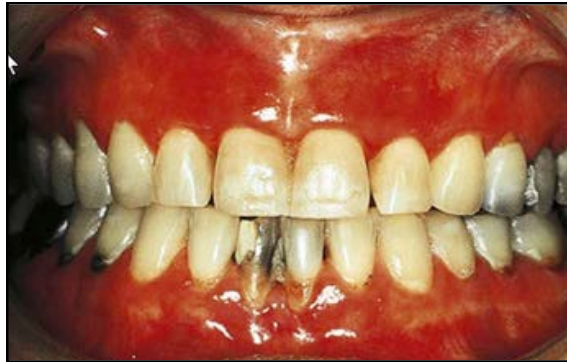

Image- Glazed and atrophic alveolar mucosa suggesting long standing xerostomia.(Source-Odell)

Investigations: (Source-articles)

- Measuring salivary flow with acceptable degree of reliability is challenging.
- The measure of Unstimulated Salivary flow rate(USFR)and Stimulated salivary flow rate (SFR) AKA whole saliva flow rate, should be done separately with USFR measured first.(For methods refer to caries risk assessment)

Management of Dry mouth:

- Firstly, review the patient's medications (if any) and in conjunction with prescriber stop any non-essential medications that can cause dry mouth.
- Ensuring adequate hydration: Drink at least 1.5 liters of water every day.
- Ensuring proper oral hygiene and avoiding consumption of caffeine cigarettes and alcoholic beverages
- Regular dental examination and review every 3-6 months
- Topical remineralising agents (Fluoride) to prevent tooth decay.
- Symptomatic relief which includes artificial salivary products like bicarbonate mouth wash, or, products that stimulate salivary flow such as throat lozenges or sugarless chewing gum.

Our app monitors and records all screenshots and recordings. Violators will face strict legal action.

DISCLAIMER

THIS IS COPYRIGHTED CONTENT. Unauthorized use, including screenshots, copying, misuse, reuse, or resale of any content from this app, is strictly prohibited. Our app monitors and records all screenshots and recordings. Violators will face strict legal action.

DISCLAIMER

THIS IS COPYRIGHTED CONTENT. Unauthorized use, including screenshots, copying, misuse, reuse, or resale of any content from this app, is strictly prohibited. Our app monitors and records all screenshots and recordings. Violators will face strict legal action.

THIS IS COPYRIGHTED CONTENT. Unauthorized use, including screenshots, copying, misuse, reuse, or resale of any content from this app, is strictly prohibited. Our app monitors and records all screenshots and recordings. Violators will face strict legal action.

DISCLAIMER

DRUG ABUSE/ RADIATION/ DRY MOUTH/ SJOGRENS/ CARIES

Box 14. Practical advice for patients with dry mouth

To manage your dry mouth:

- ensure you are adequately hydrated—drink at least 1.5 litres of tap water a day
- chew food thoroughly before swallowing because chewing stimulates saliva flow
- chew sugarless gum or suck sugarless sweets (avoid fruit flavours)
- avoid smoking cigarettes
- avoid acidic foods
- limit your caffeine and alcohol intake, especially in the evening
 - add milk to tea or coffee to reduce the drying effect
- avoid mouthwashes and other oral preparations that contain alcohol
- trial various over-the-counter dry mouth products or bicarbonate mouthwash
 - a bicarbonate mouthwash can be made by adding half a teaspoon of bicarbonate powder to a glass of warm water. Rinse with mouthwash on waking and at any time during the day.

To prevent oral and dental consequences of dry mouth:

- ensure you have good oral hygiene
- have regular dental examinations
- avoid acidic beverages (eg wine, fruit juices, soft drinks, sports drinks) or limit their consumption to meal times
- limit your sugar intake and avoid sugary snacks.

Image- Source: TG

*Pharmacological agents (Cholinergic drugs such as pilocarpine stimulates the salivary flow. (Odell)

THIS IS COPYRIGHTED CONTENT. Unauthorized use, including screenshots, copying, misuse, reuse, or resale of any content from this app, is strictly prohibited. Our app monitors and records all screenshots and recordings. Violators will face strict legal action.

DISCLAIMER

THIS IS COPYRIGHTED CONTENT. Unauthorized use, including screenshots, copying, misuse, reuse, or resale of any content from this app, is strictly prohibited. Our app monitors and records all screenshots and recordings. Violators will face strict legal action.

DISCLAIMER
THIS IS COPYRIGHTED CONTENT. Unauthorized use, including screenshots, copying, misuse, reuse, or resale of any content from this app, is strictly prohibited. Our app monitors and records all screenshots and recordings. Violators will face strict legal action.

THIS IS COPYRIGHTED CONTENT. Unauthorized use, including screenshots, copying, misuse, reuse, or resale of any content from this app, is strictly prohibited. Our app monitors and records all screenshots and recordings. Violators will face strict legal action.

THIS IS COPYRIGHTED CONTENT. Unauthorized use, including screenshots, copying, misuse, reuse, or resale of any content from this app, is strictly prohibited. Our app monitors and records all screenshots and recordings. Violators will face strict legal action.

DISCLAIMER

DRUG ABUSE/ RADIATION/ DRY MOUTH/ SJOGRENS/ CARIES

SJOGRENS SYNDROME

- Sjogrens syndrome is an autoimmune disease of unknown origin associated with inflammatory infiltration of the exocrine glands, particularly salivary gland and lacrimal glands leading to secretory gland dysfunction and usually sicca symptoms (sicca is a term used for dry eyes and dry mouth). (Source: Article)
- Sjogrens may be primary or secondary

PRIMARY SJORENS:

Symptoms include

- Dry eyes (keratoconjunctivitis sicca) — feeling of grittiness or burning in the eyes.
- Dry mouth (xerostomia) — difficulty swallowing or speaking, increased dental cavities.
- Fatigue, joint pain, and swelling (arthralgia, non-erosive arthritis)
- Raynaud's phenomenon

SECONDARY SJORENS:

- Secondary Sjogren's syndrome occurs in conjunction with another autoimmune disorder, most commonly **rheumatoid arthritis (RA)**, **systemic lupus erythematosus (SLE)**, or **Systemic sclerosis**. It shares the same symptoms as primary Sjogren's but is always linked to one of these other diseases.

Other features:

- Age of onset of the disease is 4th to 5th decade and with female predilection (9:1).
- Although it is a benign condition it can very rarely transform into lymphoid malignancy typically of B-cell origin.(10% or more) (source- odell case and article on dry mouth)

Diagnosis of Sjogrens syndrome:

- Diagnosis is strongly suggested with sicca symptoms.
- Along with positive ANA (Anti-nuclear antibodies) along with autoantibodies to Ro and La i.e. Anti-Ro antibodies and Anti La antibodies are both usually positive in Sjogrens syndrome.
- A raised ESR (Erythrocyte sedimentation rate), positive rheumatoid factor and anemia is also seen.

DISCLAIMER

THIS IS COPYRIGHTED CONTENT. Unauthorized use, including screenshots, copying, misuse, reuse, or resale of any content from this app, is strictly prohibited. Our app monitors and records all screenshots and recordings. Violators will face strict legal action.

DISCLAIMER

THIS IS COPYRIGHTED CONTENT. Unauthorized use, including screenshots, copying, misuse, reuse, or resale of any content from this app, is strictly prohibited. Our app monitors and records all screenshots and recordings. Violators will face strict legal action.

THIS IS COPYRIGHTED CONTENT. Unauthorized use, including screenshots, copying, misuse, reuse, or resale of any content from this app, is strictly prohibited. Our app monitors and records all screenshots and recordings. Violators will face strict legal action.

DISCLAIMER

DRUG ABUSE/ RADIATION/ DRY MOUTH/ SJOGRENS/ CARIES

Sample	Test	Relevance
Saliva	Whole salivary flow rate	See above; differentiates false from true xerostomia.
	Culture for candidal count	To exclude superimposed candidosis.
	Stimulated parotid flow	Accurate estimation of maximum possible parotid salivary flow.
Blood	Full blood picture	Mild anaemia is common in all autoimmune conditions and may require treatment.
	Erythrocyte sedimentation rate (ESR)	Relatively nonspecific, but raised in inflammatory conditions, and when there are raised immunoglobulins, especially IgG in Sjögren's syndrome, useful for monitoring their activity after treatment.
	Immunoglobulin (Ig) levels	Often raised in autoimmune disorders and may be markedly raised in primary Sjögren's syndrome.
	Autoantibody screen	Autoantibodies are a frequent finding in autoimmune disease. This appears to be a partly nonspecific effect, and many different autoantibodies may be seen. The exact combination in routine screening varies among centres but usually includes rheumatoid factor, antinuclear, antithyroid, antiparietal cell and antimitochondrial antibodies. Additional autoantibodies that may be seen in Sjögren's syndrome are anti-salivary gland duct antibody and ssA and ssB autoantibodies (anti-Ro and anti-La) directed against extractable nuclear antigens. None of these antibodies is individually helpful in diagnosis, but the presence of more than one is typical. They may aid in the diagnosis of connective tissue disease in secondary Sjögren's syndrome, and ssA and ssB may indicate patients at risk of specific complications. Anti-salivary gland duct antibody is not related to either the periductal infiltrates seen on biopsy or the pathogenesis of the disease.
Urine	Glucose	Occasionally useful to exclude unsuspected diabetes as a cause of dehydration.
Salivary gland	Ultrasonography	In established disease, ultrasonography almost always shows characteristic changes.
	Sialography	Ultrasonography has almost replaced sialography for in investigating Sjögren's syndrome. However, sialography is still useful if salivary stones or strictures are suspected because of additional swelling during eating.
	Other imaging techniques	Per technetate scintigraphy is a complex but useful test of secretion from individual glands. It is useful if sialography is not possible but involves a significant dose of radiation. Magnetic resonance imaging is useful to delineate the extent of salivary gland swelling, if present.
	Minor salivary gland biopsy	The histological appearances of salivary glands are characteristic in established disease. Biopsy of major glands is difficult, but the same changes may be seen in the minor glands of the lips and cheeks, provided a sufficient sample is removed (6-8 glands).
	Parotid gland biopsy	Biopsy of the tail of the parotid is possible without significant risk to the branches of the facial nerve. It provides an excellent sample and may be useful when other techniques have failed or when other conditions need to be excluded. It may also be helpful in the diagnosis of lymphoma in swollen parotid glands. Core biopsy taken under imaging guidance is performed more easily compared with an open biopsy, which is rarely undertaken unless indicated for clarifying whether another disease such as IgG4 disease or a lymphoma is present.
Eye	Schirmer test	This measures lacrimal secretion. Narrow filter paper strips are placed with one end under the lower eyelid and the length wetted is recorded after 5 minutes. In practice, the test is not very reproducible. (It is also uncomfortable and may cause corneal abrasions when the eye is very dry and, for this reason, is no longer recommended.) Ophthalmological examination is preferable, but the Schirmer test remains widely used.
	Ophthalmological examination	An ophthalmologist uses a slit lamp to detect conjunctival splits and Lissamine Green staining identifies dried tear secretion on the front of the eye. Although these changes are rarely helpful in diagnosis, examination and follow-up are required to prevent long-term complications of dry eyes.

Image: (Odell)

Management of Sjogrens:

- Symptomatic relief is recommended in cases of pts. With sjogrens.

DISCLAIMER

THIS IS COPYRIGHTED CONTENT. Unauthorized use, including screenshots, copying, misuse, reuse, or resale of any content from this app, is strictly prohibited. Our app monitors and records all screenshots and recordings. Violators will face strict legal action.

DISCLAIMER

THIS IS COPYRIGHTED CONTENT. Unauthorized use, including screenshots, copying, misuse, reuse, or resale of any content from this app, is strictly prohibited. Our app monitors and records all screenshots and recordings. Violators will face strict legal action.

THIS IS COPYRIGHTED CONTENT. Unauthorized use, including screenshots, copying, misuse, reuse, or resale of any content from this app, is strictly prohibited. Our app monitors and records all screenshots and recordings. Violators will face strict legal action.

DISCLAIMER

DRUG ABUSE/ RADIATION/ DRY MOUTH/ SJOGRENS/ CARIES

RADIATION TO HEAD AND NECK REGION

Source- Odell case, TG, Articles

- Radiotherapy (use of ionizing radiation to treat disease, usually x-rays to treat cancer) has many adverse effect to oral and general health of the patient.
- Radiotherapy to head and neck region also damages normal tissue as so many important and radiosensitive tissues lie in the head and neck region (particularly salivary glands, eye, spinal cord and thyroid gland).
- The full curative dose for most head and neck cancers is 60–65 grays (Gy), but mild salivary gland damage can be detected after only 4 Gy, and severe permanent damage occurs with doses above 30 Gy to the glands.

Methods of protection of important tissues:

- **Fractionation:** Delivering the total dose in small daily amounts or fractions, usually 2 Gy each weekday for 6 weeks which allows some recovery time between treatments, thus reducing toxicity to normal tissues.
- **Intensity modulated radiotherapy (IMRT):** This method uses multiple smaller 'beamlets' to converge on the cancer from different directions. The intensity and shape of the beams change at each fraction and are calculated to match the size of the tumor from each direction which guarantee the necessary high dose to the tumor while greatly reducing the dose to the sensitive normal surrounding tissues.

Adverse effects of radiation:

- Radiotherapy effects are divided into early, longer-term, and general effects.

TABLE 67.1	Adverse Effects of Radiotherapy To the Mouth and Adjacent Areas
Early	
<ul style="list-style-type: none"> • Xerostomia • Oral mucositis • Skin burns • Oral infections, particularly candidosis • Taste alteration 	
Longer-Term	
<ul style="list-style-type: none"> • Xerostomia • Trismus • Radiation caries • Loss of periodontal attachment • Osteoradionecrosis 	
General	
<ul style="list-style-type: none"> • Weight loss • Fatigue • Eating difficulty • Swallowing difficulty • Speech difficulty 	

Image-Source Odell

DISCLAIMER

THIS IS COPYRIGHTED CONTENT. Unauthorized use, including screenshots, copying, misuse, reuse, or resale of any content from this app, is strictly prohibited. Our app monitors and records all screenshots and recordings. Violators will face strict legal action.

DISCLAIMER

THIS IS COPYRIGHTED CONTENT. Unauthorized use, including screenshots, copying, misuse, reuse, or resale of any content from this app, is strictly prohibited. Our app monitors and records all screenshots and recordings. Violators will face strict legal action.

THIS IS COPYRIGHTED CONTENT. Unauthorized use, including screenshots, copying, misuse, reuse, or resale of any content from this app, is strictly prohibited. Our app monitors and records all screenshots and recordings. Violators will face strict legal action.

DISCLAIMER

DRUG ABUSE/ RADIATION/ DRY MOUTH/ SJOGRENS/ CARIES

RADIATION TO HEAD AND NECK REGION

Oral mucositis (inflammation of the mouth) affects all patients initially. Its features include erythema, ulceration, swelling and atrophy. It causes extreme soreness and can prevent eating as well.

Radiation Caries (Odell) is a type of dental decay that occurs as a complication of radiation therapy, particularly for patients undergoing treatment for cancers in the head and neck region. AKA radiation-induced dental caries. The risk of radiation caries increases in patients who receive high doses of radiation to the mouth, salivary glands, and surrounding tissues.

- When the salivary glands are impaired due to radiation, the quantity and quality of saliva are reduced, which creates a dry environment in the mouth. This increases the risk of tooth decay, as the natural protective mechanisms of saliva are diminished.

Characteristics of Radiation Caries:

- Radiation caries typically affects the cervical area of the teeth and progresses rapidly from there. This is because the reduced salivary flow makes it easier for plaque to accumulate, and the lack of buffering capacity in the mouth increases acid attacks on the enamel. The classic distribution of lesions occurs at incisal edges, cusp tips and cervical margin.
- Teeth may appear rough, pitted, and discolored, with areas of soft, chalky enamel. There may be increased sensitivity to hot, cold, and sweet foods or drinks.
- In radiation caries the whole dentine may be affected, but the enamel shell remains largely intact and pain is not generally reported. Caries may become very extensive and go unnoticed until teeth fracture.

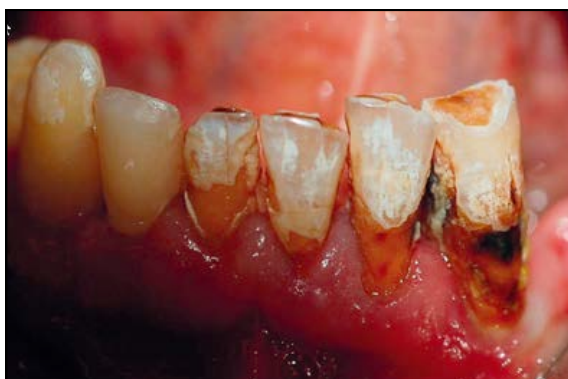

Image- Incisors with typical signs of radiation-induced caries (Source -Internet)

DISCLAIMER

THIS IS COPYRIGHTED CONTENT. Unauthorized use, including screenshots, copying, misuse, reuse, or resale of any content from this app, is strictly prohibited. Our app monitors and records all screenshots and recordings. Violators will face strict legal action.

DISCLAIMER

THIS IS COPYRIGHTED CONTENT. Unauthorized use, including screenshots, copying, misuse, reuse, or resale of any content from this app, is strictly prohibited. Our app monitors and records all screenshots and recordings. Violators will face strict legal action.

THIS IS COPYRIGHTED CONTENT. Unauthorized use, including screenshots, copying, misuse, reuse, or resale of any content from this app, is strictly prohibited. Our app monitors and records all screenshots and recordings. Violators will face strict legal action.

DISCLAIMER

DRUG ABUSE/ RADIATION/ DRY MOUTH/ SJOGRENS/ CARIES

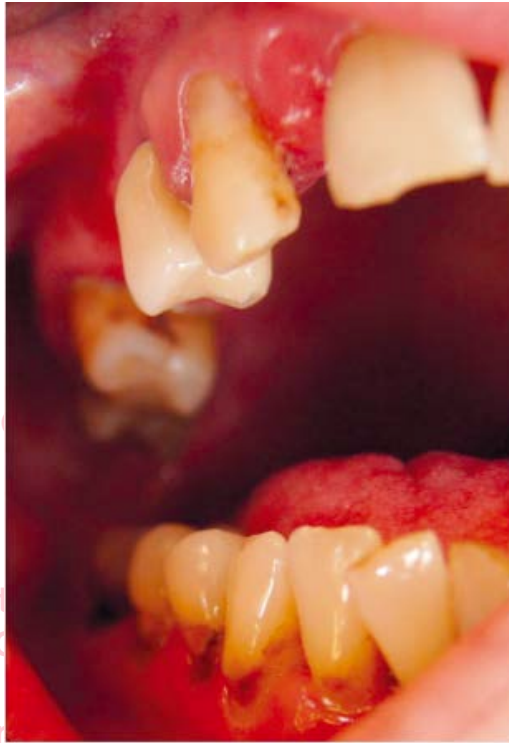

Image-Multiple caries in cervical region of irradiated patient (Source-Internet)

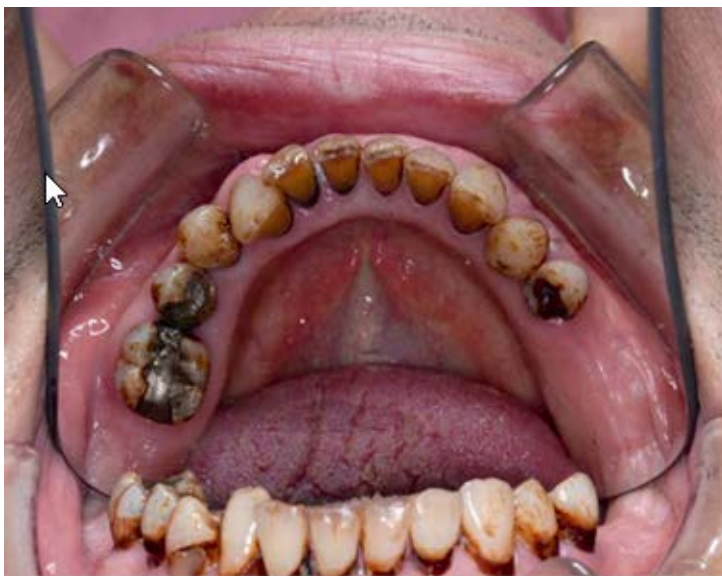

Image-Intraoral appearance of irradiated patient (Source-Odell)

THIS IS COPYRIGHTED CONTENT. Unauthorized use, including screenshots, copying, misuse, reuse, or resale of any content from this app, is strictly prohibited. Our app monitors and records all screenshots and recordings. Violators will face strict legal action.

THIS IS COPYRIGHTED CONTENT. Unauthorized use, including screenshots, copying, misuse, reuse, or resale of any content from this app, is strictly prohibited. Our app monitors and records all screenshots and recordings. Violators will face strict legal action.

resale of any content from this app, is strictly prohibited. Our app monitors and records all screenshots and recordings. Violators will face strict legal action.

DISCLAIMER

THIS IS COPYRIGHTED CONTENT. Unauthorized use, including screenshots, copying, misuse, reuse, or resale of any content from this app, is strictly prohibited. Our app monitors and records all screenshots and recordings. Violators will face strict legal action.

DISCLAIMER
THIS IS COPYRIGHTED CONTENT. Unauthorized use, including screenshots, copying, misuse, reuse, or resale of any content from this app, is strictly prohibited. Our app monitors and records all screenshots and recordings. Violators will face strict legal action.

DISCLAIMER

THIS IS COPYRIGHTED CONTENT. Unauthorized use, including screenshots, copying, misuse, reuse, or resale of any content from this app, is strictly prohibited. Our app monitors and records all screenshots and recordings. Violators will face strict legal action.

DRUG ABUSE/ RADIATION/ DRY MOUTH/ SJOGRENS/ CARIES

Factors Contributing to Radiation Caries:

- Reduced quantity and buffering capacity saliva caused by radiation effects on the salivary gland.
- Other contributory factors include high-sugar diet, reduced oral clearance of sugars, poor oral hygiene, often compounded by limited mouth opening, and a sore mouth. Changes in the oral flora may be a factor.

Osteoradionecrosis (Source-Odell and Articles) is one of more serious complication of radiotherapy. It is defined as clinical or radiographic presence of exposed and devitalized irradiated bone without healing for 1 month.

- It may present with pain, redness, swelling, altered sensation, discharge, skin fistula or a pathological fracture.
- ORN may arise spontaneously but develops most often after an extraction.
- ORN occurs mostly within 1 year of radiotherapy.

Factors affecting the incidence of ORNJ (Articles, TG and Odell)/

- **Dentoalveolar surgery:** Extraction sockets take time to heal, risk is increased when Dentoalveolar surgery is performed too close to commencement of radiotherapy or too soon after radiotherapy. If extractions are performed, allow adequate time for wound healing (10 days to 3 weeks) before starting radiotherapy.
Do not extract the tooth for patients who has already had radiotherapy without consulting with patient's multidisciplinary team.
- Studies have found periresective surgery increase the prevalence of ORNJ
- Continued tobacco use after radiotherapy due to its detrimental effects on wound healing, the vasoconstrictive properties and presence of chemicals in tobacco traumatize the oral mucosa and contaminate the surgical wounds.
- Diabetes mellitus type 2 increases the incidence of ORNJ as it has adverse effect on cardiovascular and immune system. It predisposes pt to peripheral vascular disease and microangiopathy causing impairment of blood supply which is detrimental to wound healing.
- Total radiation dose.

TABLE 67.2	Risk Factors for Osteoradionecrosis
Dental Factors	
<ul style="list-style-type: none"> • Extraction after radiotherapy, especially in mandibular molar area • Extraction before radiotherapy if within 10 days of start of radiotherapy • Denture trauma • Implant placement • Biopsy • Periodontal surgery 	
General Factors	
<ul style="list-style-type: none"> • >60 Gy radiotherapy, rare if <40 Gy • Combined chemotherapy with radiotherapy • Smoking • High alcohol intake 	

Image: Source-Odell

DISCLAIMER

THIS IS COPYRIGHTED CONTENT. Unauthorized use, including screenshots, copying, misuse, reuse, or resale of any content from this app, is strictly prohibited. Our app monitors and records all screenshots and recordings. Violators will face strict legal action.

DISCLAIMER
THIS IS COPYRIGHTED CONTENT. Unauthorized use, including screenshots, copying, misuse, reuse, or resale of any content from this app, is strictly prohibited. Our app monitors and records all screenshots and recordings. Violators will face strict legal action.

THIS IS COPYRIGHTED CONTENT. Unauthorized use, including screenshots, copying, misuse, reuse, or resale of any content from this app, is strictly prohibited. Our app monitors and records all screenshots and recordings. Violators will face strict legal action.

DISCLAIMER

DRUG ABUSE/ RADIATION/ DRY MOUTH/ SJOGRENS/ CARIES

Teeth that should be extracted before radiotherapy to prevent risk of ORNJ by further extraction in future are:

- Teeth that are infected, unrestorable or have pockets of greater than 5 mm depth should be extracted.
- Partially erupted third molars.
- Teeth that are likely to become inaccessible after cancer treatment.
- Other teeth must be assessed, taking several factors into account: the position of the tooth, volume of radiation to the area, strategic importance of the tooth and patient choice and compliance
- Extraction of the second and third molars may often be recommended in cases of tonsillar or tongue base cancer, where a high radiation dose is given to the tooth-bearing area.

Management of ORN:

- ORN is very resistant to treatment. Antibiotics do not penetrate well to the site of infection, and healing is compromised by the reduced vascularity. Patients with suspected ORN should be referred to a specialist oral surgeon.
- Management may be conservative, but sometimes surgery and bone grafting may be needed.
- Encourage regular dental review.

**Note-Use of fluoridated products is also recommended in patients with radiotherapy to head and neck. Neutral fluorides are better tolerated than acidulated products.*

THIS IS COPYRIGHTED
CONTENT. Unauthorized use,
including screenshots,
copying, misuse, reuse, or
resale of any content from
this app, is strictly prohibited.
Our app monitors and records
all screenshots and
recordings. Violators will face
strict legal action.

DISCLAIMER

THIS IS COPYRIGHTED CONTENT. Unauthorized use, including screenshots, copying, misuse, reuse, or resale of any content from this app, is strictly prohibited. Our app monitors and records all screenshots and recordings. Violators will face strict legal action.

DISCLAIMER

THIS IS COPYRIGHTED CONTENT. Unauthorized use, including screenshots, copying, misuse, reuse, or resale of any content from this app, is strictly prohibited. Our app monitors and records all screenshots and recordings. Violators will face strict legal action.

THIS IS COPYRIGHTED CONTENT. Unauthorized use, including screenshots, copying, misuse, reuse, or resale of any content from this app, is strictly prohibited. Our app monitors and records all screenshots and recordings. Violators will face strict legal action.

DISCLAIMER

DRUG ABUSE/ RADIATION/ DRY MOUTH/ SJOGRENS/ CARIES

CARIES AND FLUORIDE

Source- TG and Articles

Dental caries is most prevalent oral disease in Australian Children and Adults.

- Like Frequency of sugar consumption and plaque are the key etiological factor for dental caries, likewise use of fluoride has been the cornerstone for caries prevention.

FLUORIDE: (TG+Articles)

Water fluoridation is one of the most effective public health interventions.

- The level of fluoride in water should be within the range of 0.6 -1.1mg/L.
- People who consume bottled water, should be encouraged to drink labelled drinking water with 1mg/L of fluoride.
- Water fluoridation at current Australian levels is not associated with cognitive dysfunction, lowered IQ, cancer, hip fracture and downs syndrome.
- In Australia, dental fluorosis have declined over time and those reported are very mild or mild.

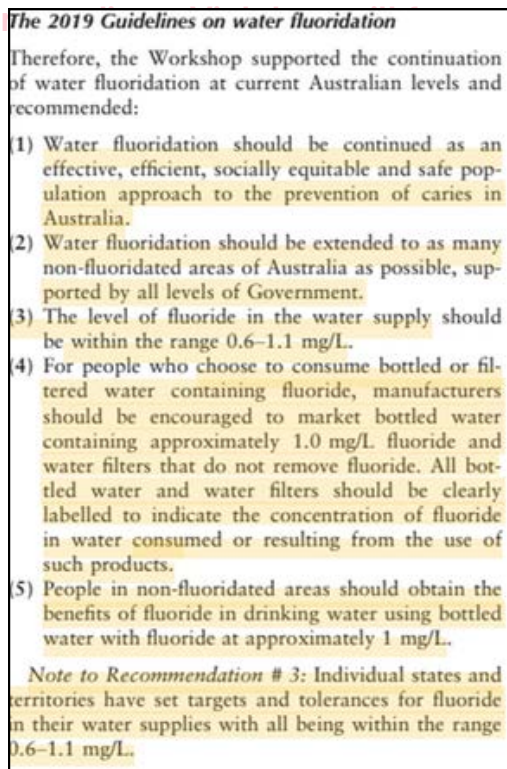


Image: Source- Fluoride article

DISCLAIMER

THIS IS COPYRIGHTED CONTENT. Unauthorized use, including screenshots, copying, misuse, reuse, or resale of any content from this app, is strictly prohibited. Our app monitors and records all screenshots and recordings. Violators will face strict legal action.

DISCLAIMER
THIS IS COPYRIGHTED CONTENT. Unauthorized use, including screenshots, copying, misuse, reuse, or resale of any content from this app, is strictly prohibited. Our app monitors and records all screenshots and recordings. Violators will face strict legal action.

DISCLAIMER

THIS IS COPYRIGHTED CONTENT. Unauthorized use, including screenshots, copying, misuse, reuse, or resale of any content from this app, is strictly prohibited. Our app monitors and records all screenshots and recordings. Violators will face strict legal action.

DRUG ABUSE/ RADIATION/ DRY MOUTH/ SJOGRENS/ CARIES

Use of Fluoridated toothpaste

1. The efficacy of tooth brushing with fluoridated toothpaste is widely established.
 2. Fluoride promotes enamel remineralization through the formation of fluoride containing apatites. (Flurohydrooxyapatite, fluorapatite) which are resistant to further acid challenge than normal hydroxyapatite.
 3. After brushing the teeth, remove excess toothpaste by spitting (do not swallow), Do not rinse the mouth after using fluoride toothpaste to increase uptake.
- Fluoride recommendation for patients without elevated risk

Table 7. Recommended concentration of fluoride toothpaste according to age and risk of dental caries [NB1]

Toothpaste for people not at elevated risk of dental caries

child younger than 18 months	twice-daily brushing without toothpaste
child 18 months to younger than 6 years	500 to 550 ppm (0.5 to 0.55 mg/g) fluoride twice daily, pea-sized amount [NB2]
child 6 years to adolescent	1000 to 1500 ppm (1 to 1.5 mg/g) fluoride twice daily
adolescent or adult	1000 to 1500 ppm (1 to 1.5 mg/g) fluoride twice daily

- Fluoride recommendation for patients with elevated risk

Toothpaste for people at elevated risk of dental caries [NB3]

child younger than 18 months	twice-daily brushing with toothpaste may be recommended [NB2]
child 18 months to younger than 6 years	1000 ppm (1 mg/g) fluoride twice daily [NB2] OR more frequent use of 500 to 550 ppm (0.5 to 0.55 mg/g) fluoride [NB2]
child 6 years to adolescent	more frequent use of 1000 to 1500 ppm (1 to 1.5 mg/g) fluoride [NB2]
adolescent or adult	5000 ppm (5 mg/g) fluoride twice daily OR more frequent use of 1000 to 1500 ppm (1 to 1.5 mg/g) fluoride

ppm = parts per million

NB1: Spit out fluoride products to minimise ingestion; do not rinse the mouth after use to allow increased uptake of fluoride from the saliva.

NB2: Advise parents of the risk of fluorosis and the need to supervise toothbrushing.

NB3: Toothpaste use may be varied as needed, based on the dentist's clinical judgment.

Image: Source - TG

DISCLAIMER

THIS IS COPYRIGHTED CONTENT. Unauthorized use, including screenshots, copying, misuse, reuse, or resale of any content from this app, is strictly prohibited. Our app monitors and records all screenshots and recordings. Violators will face strict legal action.

DISCLAIMER

THIS IS COPYRIGHTED CONTENT. Unauthorized use, including screenshots, copying, misuse, reuse, or resale of any content from this app, is strictly prohibited. Our app monitors and records all screenshots and recordings. Violators will face strict legal action.

THIS IS COPYRIGHTED CONTENT. Unauthorized use, including screenshots, copying, misuse, reuse, or resale of any content from this app, is strictly prohibited. Our app monitors and records all screenshots and recordings. Violators will face strict legal action.

DRUG ABUSE/ RADIATION/ DRY MOUTH/ SJOGRENS/ CARIES

- **Fluoride supplements** in the form of drops or tablets to be chewed or swallowed should not be used

The 2019 Guidelines on fluoride supplements

(11) Fluoride supplements in the form of drops or tablets to be chewed and/or swallowed, should not be used.

- **Fluoride Mouth rinses:** The concentration of fluoride mouth rinses to be used is 220 mg/L daily or 900 mg/L weekly.

Formulation	Usual directions for use
neutral fluoride mouthwash 220 ppm (0.22 mg/mL)	Use in adults and children 6 years or older daily. Patients should rinse in the mouth for 1 minute at a time of day when toothpaste is not used [NB2].
neutral fluoride mouthwash 900 ppm (0.9 mg/mL)	Use in adults and children 6 years or older weekly or more frequently if indicated. Patients should rinse in the mouth for 1 minute at a time of day when toothpaste is not used [NB2].

The 2019 Guideline on fluoride mouth rinses

- (12) Children below the age of 6 years should not use fluoride mouth rinse.
- (13) Fluoride mouth rinse might be used by people aged 6 years or more who have an elevated risk of developing caries. Fluoride mouth rinse should be used at a time of day when toothpaste is not used, and it should not be a substitute for brushing with fluoridated toothpaste. After rinsing, mouth rinse should be spat out, not swallowed.

THIS IS COPYRIGHTED CONTENT. Unauthorized use, including screenshots, copying, misuse, reuse, or resale of any content from this app, is strictly prohibited. Our app monitors and records all screenshots and recordings. Violators will face strict legal action.

DISCLAIMER

THIS IS COPYRIGHTED CONTENT. Unauthorized use, including screenshots, copying, misuse, reuse, or resale of any content from this app, is strictly prohibited. Our app monitors and records all screenshots and recordings. Violators will face strict legal action.

DISCLAIMER
THIS IS COPYRIGHTED CONTENT. Unauthorized use, including screenshots, copying, misuse, reuse, or resale of any content from this app, is strictly prohibited. Our app monitors and records all screenshots and recordings. Violators will face strict legal action.

THIS IS COPYRIGHTED CONTENT. Unauthorized use, including screenshots, copying, misuse, reuse, or resale of any content from this app, is strictly prohibited. Our app monitors and records all screenshots and recordings. Violators will face strict legal action.

DISCLAIMER

DRUG ABUSE/ RADIATION/ DRY MOUTH/ SJOGRENS/ CARIES

- Professionally applied fluoride products:

Fluoride Varnishes: Fluoride varnish contains 22.6mg/mL of fluoride ion suspended in an alcohol and resin base.

The most common available product is DURAPHAT.

It is applied by dental professionals directly onto the dried tooth surface.

It should be avoided in patients allergic to band aid adhesives due to cross reactivity between resin components.

fluoride varnish 22 600 ppm (2.6 mg/mL)	Use in adults and children 1 year or older usually twice a year depending on dental caries risk. Applied by a dental practitioner to all at-risk dental surfaces.
--	--

Fluoride gels: they contain high concentration of fluoride up to 12.3mg/g.

They are applied by dental professionals using trays that retain the material on tooth for several minutes.

They are contraindicated in children less than 10 years of age because large amount of fluoride can be ingested.

acidulated phosphate fluoride gel or foam 12 300 ppm (12.3 mg/g)	Use in adults and children 10 years or older usually twice a year depending on dental caries risk. Applied by a dental practitioner for up to 4 minutes using trays—evacuate excess [NB2]. Acidulated phosphate fluoride is preferred to neutral fluoride products because it has better enamel uptake; however, avoid acidulated gels and foams in patients with ceramic crowns and bridgework, direct restorations containing glass particles, or poor salivary flow (eg patients undergoing head or neck irradiation).
neutral fluoride gel or foam 5000 to 9000 ppm (5 to 9 mg/g)	Use in adults and children (age restriction variable) usually twice a year depending on dental caries risk. Can be used for patients with ceramic crowns and bridgework, direct restorations containing glass particles, or poor salivary flow (eg patients undergoing head or neck irradiation). Applied by a dental practitioner for up to 4 minutes using trays—evacuate excess [NB2]. Adults can use neutral fluoride gel or foam at home, according to recommended instructions.

DRUG ABUSE/ RADIATION/ DRY MOUTH/ SJOGRENS/ CARIES

- Professionally applied fluoride products:

Silver diamine fluoride:

38% SDF is used to arrest carious lesions

silver fluoride formulations	Use in adults and children (age restriction variable) usually twice a year or as recommended by a dentist. Applied by a dental practitioner to arrest carious lesions, but can stain teeth black.
------------------------------	--

The 2019 Guideline on silver diamine fluoride

(16) Silver diamine fluoride or silver fluoride might be used for people with caries in situations where traditional treatment approaches to caries management might not be possible.

Fluoride+CPP-ACP:

CPP ACP and fluoride are best used in cases of orthodemineralisation where it can reverse the tooth decay in the early stages (non-cavitated).

CPP ACP products should be avoided in patients with milk allergies.

Formulation	Usual directions for use
fluoride+CPP-ACP 900 ppm+10% cream	Use in adults and children for noncavitated white spot lesions twice daily after brushing with usual fluoride toothpaste. Patients should apply the cream to the teeth, hold in the mouth for 3 to 5 minutes, spit out excess and avoid rinsing the mouth [NB2].
fluoride+CPP-ACP 22 600 ppm (22.6 mg/mL)+2% varnish	Use in adults and children for noncavitated white spot lesions usually twice a year depending on dental caries risk. Applied by a dental practitioner to all at-risk dental surfaces.

CPP-ACP = casein phosphopeptide-amorphous calcium phosphate
 NB1: Treatment choice is based on clinical judgment and requires a complete assessment of the patient (eg age, other medications, disease risk).
 NB2: Spit out fluoride products to minimise ingestion; do not rinse the mouth after use to allow increased uptake of fluoride from the saliva.

DISCLAIMER

THIS IS COPYRIGHTED CONTENT. Unauthorized use, including screenshots, copying, misuse, reuse, or resale of any content from this app, is strictly prohibited. Our app monitors and records all screenshots and recordings. Violators will face strict legal action.

DISCLAIMER
THIS IS COPYRIGHTED CONTENT. Unauthorized use, including screenshots, copying, misuse, reuse, or resale of any content from this app, is strictly prohibited. Our app monitors and records all screenshots and recordings. Violators will face strict legal action.

DISCLAIMER

THIS IS COPYRIGHTED CONTENT. Unauthorized use, including screenshots, copying, misuse, reuse, or resale of any content from this app, is strictly prohibited. Our app monitors and records all screenshots and recordings. Violators will face strict legal action.

DRUG ABUSE/ RADIATION/ DRY MOUTH/ SJOGRENS/ CARIES

- Professionally applied fluoride products:

Fluoride levels in carious products.

Fluoride levels in various dental products				
Form of fluoride (F)	Conversion factors	Typical products	Per cent F	ppm F
Fluoride gel: acidulated phosphate fluoride		1.23% F	1.23% F	12,300
Fluoride varnish: sodium fluoride	2.2 mg NaF = 1 mg F ⁻	5% NaF	2.26% F	22,600
Mouthrinse: sodium fluoride	2.2 mg NaF = 1 mg F ⁻	0.2% NaF	0.09% F	900
Adult toothpaste monofluorophosphate (MFP)	7.6 mg MFP = 1 mg F ⁻	0.76% MFP	0.1% F	1,000
Junior toothpaste monofluorophosphate	7.6 mg MFP = 1 mg F ⁻	0.304% MFP	0.04% F	400

An example showing calculation of the amount ingested by a child brushing with an adult toothpaste and swallowing 20% is illustrated by the following two equations:
 % F in the compound ingested (0.1%) x quantity used in the treatment (0.25gm) = F dose (0.25 mg)
 F dose (0.25 mg) x amount actually swallowed (20%) = mg F ingested (0.05 mg)
 Emergency recommendations for fluoride overdose are presented in Table 2.

this app, is strictly prohibited.

- For application of fluoride based on caries risk (refer to hot notes of caries risk)

Summary of recommendations for professional fluoride application			
	12 months to <10 years	10 to 18 years	18+ years
Low risk	—	—	—
Moderate risk	Varnish at 6 monthly intervals	Varnish or gel at 6 monthly intervals	—
High risk	Varnish at 6 monthly intervals	Varnish or gel 6 monthly intervals	Varnish or gel at 3-6 monthly intervals

Image: Source - Article

THIS IS COPYRIGHTED
CONTENT. Unauthorized use,
including screenshots,
copying, misuse, reuse, or
resale of any content from
this app, is strictly prohibited.
Our app monitors and records
all screenshots and
recordings. Violators will face
strict legal action.

DISCLAIMER

THIS IS COPYRIGHTED CONTENT. Unauthorized use, including screenshots, copying, misuse, reuse, or resale of any content from this app, is strictly prohibited. Our app monitors and records all screenshots and recordings. Violators will face strict legal action.

DISCLAIMER
THIS IS COPYRIGHTED CONTENT. Unauthorized use, including screenshots, copying, misuse, reuse, or resale of any content from this app, is strictly prohibited. Our app monitors and records all screenshots and recordings. Violators will face strict legal action.

THIS IS COPYRIGHTED CONTENT. Unauthorized use, including screenshots, copying, misuse, reuse, or resale of any content from this app, is strictly prohibited. Our app monitors and records all screenshots and recordings. Violators will face strict legal action.

DISCLAIMER