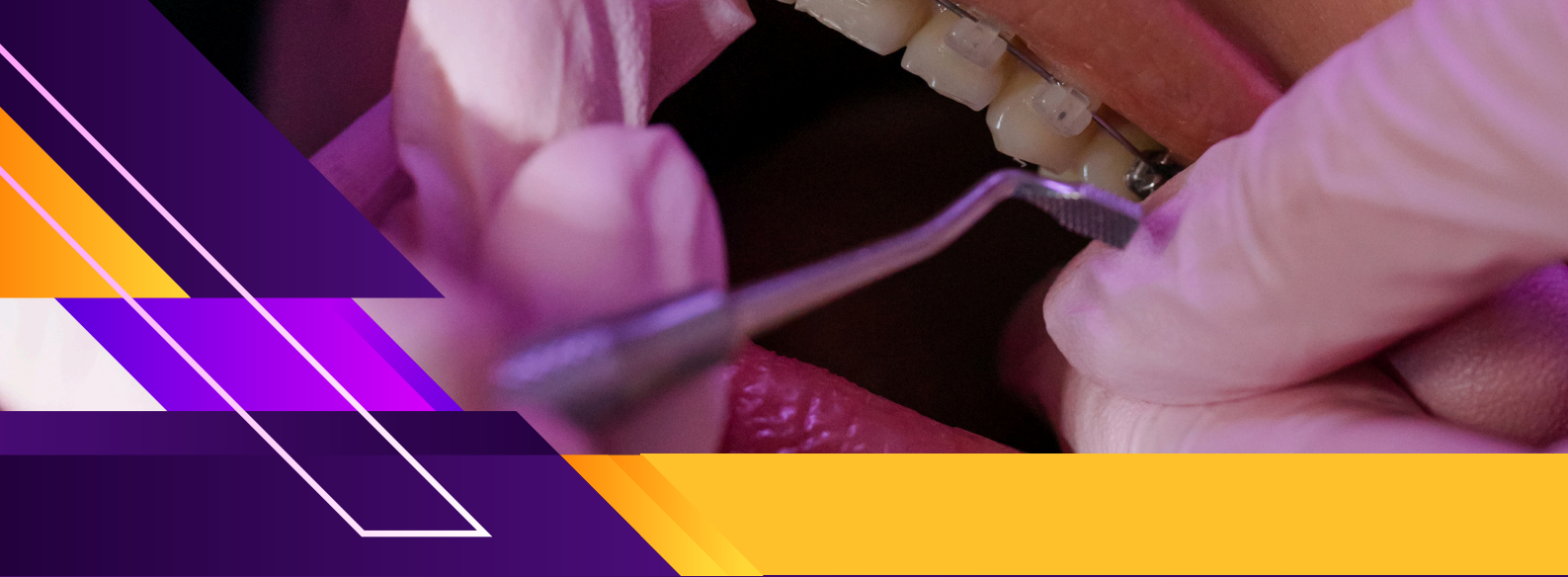



WINSPERT

WINSPERT

# P.O.W.E.R

PREPARATION OF ADC WITH WINSPERT EXPERT REVIEW

# NOTES

By Dr. Jigyasa Sharma



# OPERATIVE

## SBQ 1

A PATIENT IS 62 YEARS OLD. SHE HAS MANY ROOTS CARIES AND IT SAID SHE HAS INCIPIENT CARIES ON THE FRONT BUT IT IS NOT CAVITATED BUT IT IS VISIBLE WHEN IT IS WET. LIVES IN A PLACE WHICH HAS RETICULATED FLUORIDE TAP WATER. PATIENT DOESN'T LIKE DRINKING TAP WATER, DOESN'T LIKE THE TASTE OF IT, DRINKS BOTTLED WATER ONLY, DRYNESS OF MOUTH REPORTED, SJOGREN'S MENTIONED, VERY MUCOUS SALIVA, LOW SALIVARY FLOW RATE, SHE BRUSHES WITH FL TOOTHPASTE, TWO TIMES IN A DAY. COMPLAINS OF GENERALISED SENSITIVITY.

### I. What is the cause of her root caries/caries?

- A. Poor oral hygiene
- B. Low salivary flow
- C. Poor diet
- D. Less fluoride

### II. What do you advise regarding water?

- A. Drink bottled water only
- B. Drink bottled water that contains fluoride
- C. Add bicarbonate to bottled water
- D. Drink bottled water which has 'mineral' labelled on it
- E. Ask patient to drink tap water only

### III. What is the best management for her caries?

- A. Give sodium bicarbonate mouthwash and 1500 FL toothpaste
- B. Give ccp acp cream (only some centres gave this) and 5000 ppm FL toothpaste
- C. Give saliva substitute and 900 ppm fluoride toothpaste
- D. Mouth wash

### IV. Which toothpaste to recommend for her sensitivity?

- A. Strontium toothpaste
- B. Normal toothpaste
- C. Mouthwash containing triclosan
- D. Mouthwash containing arginine
- E. Fluoride toothpaste

# OPERATIVE

## P.O.W.E.R NOTES SBQ 1

### IN HER CASE THE RISK FACTORS OF GETTING CARIES:

1. Sjogren's syndrome → Dry mouth → Caries → Sensitive teeth
2. Doesn't like to drink tap water (tap water has fluoride) ....but she brushes teeth twice with fluoridated tooth paste.

### INCIPIENT CARIES VS HYPOPLASTIC/HYPO MINERALISED ENAMEL

INCIPIENT CARIES	HYPOPLASTIC/ HYPO MINERALISED ENAMEL
Doesn't appear at the time of tooth eruption	Appears at the time of tooth eruption
It is due to caries	It is due to defect in the enamel formation
White patches close to the gingival margins due to plaque accumulation	White or brown enamel defects, can be seen as pitted enamel in severe cases
Visible when the tooth surface is dried. But when caries has progressed halfway into the enamel it can be seen in wet tooth surface too.	It can be seen in both wet and dried situations.

- According to ICDAS classification incipient lesions and non cavitated lesions are not restored instead they are remineralised with the help of fluoride toothpaste, varnish, gel, cpp-acp.

- I. Since she brushes twice daily, she maintains good oh.  
Her dry mouth condition is a risk factor for caries.  
In the question it's not mentioned about her diet.  
She uses a fluoridated tooth paste though she doesn't drink tap water.  
Therefore, cause for caries in this case is poor salivary flow.
- II. Tap water has fluoride and tank water doesn't. As the patient doesn't like to drink tap water, we can't force her to do so. So, we can encourage the patient to have bottled water which has fluoride with it.

# OPERATIVE

## P.O.W.E.R NOTES SBQ 1

- III. (*reference TG page no. 67 table 7*): in high caries risk it's advised to recommend 5000ppm tooth paste. And cpp-acp will release  $\text{Ca}^{2+}$  and phosphate ions to remineralise the initial lesions. If the patient doesn't have milk protein allergy, its good advice cpp-acp along with F toothpaste.

And also, In case of xerostomia, hyposalivation and orthodontic demineralisation "fluoride alone" can't remineralise enamel. Fluoride with cpp-acp will be helpful in these circumstances.

Sodium bicarbonate mouth was is given in the management of dry mouth (*reference TG page no. 123*) but in this question it's asking about the caries management not the dry mouth management. And also, since she's using a fluoride tooth paste no point of prescribing a same concentration toothpaste. Need to prescribe a high concentration.

- IV. In case of sensitive teeth, it's always good to recommend a desensitising agent. If a patient with caries, sensitivity is due caries, so, it's good to choose a desensitising agent which has fluoride with it. (eg: sodium monofluoro phosphate) but in this question this answer is not given. She already uses a fluoride tooth paste so it's better to change it to a desensitizing agent for a short period of time until her sensitivity issue gets resolved.

Best desensitizing agents in descending order:

Arginine /  $\text{CaCO}_3$  <  $\text{KNO}_3$  (mostly available) < stannous F < NaF/NaCl/Na-monofluorophosphate/stronthium Cl



# OPERATIVE

## SBQ 2

LADY WORKS IN A FACTORY AND HAS MANY CERVICAL CARIES (RIGHT SIDE INTRA ORAL PIC WAS GIVEN, UPPER AND LOWER TEETH CERVICAL CARIES INCIPIENT). SHE EATS SNACKS AND SOFT DRINKS IN HER FREE TIME FROM WORK, EATS TAKEAWAY FOOD ALWAYS AND DOESN'T LIKE TO COOK AT HOME, AND SMOKES 10 CIGARETTES. HISTORY OF PERIODONTITIS. SHE IS WORRIED ABOUT LOSING HER TEETH.

**I. She tried to quit smoking a few years back and was unsuccessful, and doesn't want to quit again. How will you help her quit smoking? Or how will you manage her?**

- A. Tell her to record her emotions the next time she thinks of losing her teeth
- B. Record it in your notes to assess her willingness to quit in the next appointment and put her on recall Record her behaviour in her notes and review her willingness in next review appointment (mention in the records to inquire her willingness to quit in next session)
- C. Ask her the what her real intention should be for quitting
- D. Tell her she can call your clinic anytime she decides to quit again give her the number and give her clinics number
- E. Reassure/Assure her that "yes 80 percent people who try quitting fail when they try first"
- F. Tell her if she doesn't quit smoking, she can lose her teeth and give her no of Quitline.

**II. In subsequent appointments you notice she is not changing her eating habits. How will you motivate her about eating habits? (In my station it said you notice/get to know that her eating habits are not healthy, how will you motivate her eating habits)**

- A. Talk to her about how she can manage her diet after discussing her diet diary
- B. Showing her the clinical pictures, you have taken of her carious teeth and explain how it's affecting her teeth
- C. Show her regret over something which she has already lost in her mouth

**III. What is the reason for her cervical caries?**

- A. No balance b/w fast food and home food
- B. Frequency of carbs intake
- C. Eating sweet food and having sweet drinks together.
- D. Smoking

**IV. How will you check her white lesion?**

- A. Using sharp scaler tip
- B. Use a sharp tip with pressure over the edges of the lesion.
- C. Use ball end probe by passing it over the lesion gently
- D. Use Briault probe

# OPERATIVE

## SBQ 2

**V. How would you manage dentinal sensitivity in her case?**

- A. Strontium salt toothpaste
- B. Sodium monofluorophosphate toothpaste
- C. Oxalate salt toothpaste
- D. Sodium bicarbonate
- E. Potassium phosphate

## P.O.W.E.R NOTES SBQ 2

- I. When it comes to quit smoking always try to encourage and reassure the patient. Always try to appreciate if the patient has tried quitting smoking once. And give a positive response. Never make the patient disappointed by giving a negative response.
- II. Never discourage a patient. Always try to give a positive response. When it comes to dietary habits it's always good to maintain a diet chart and do modifications after discussing with the patient.
- III. Frequency matters more than the quantity of food. Snacking and drinking soft drinks in between the main meals makes the situation worse compared to having sweets/soft drinks along with the mealtime.
- IV. During inspection never use a sharp probe as it can damage the tooth structure and may lead to cavitation. Always use a blunt probe with a gentle force.
- IV. In this patient dentinal sensitivity is due to dental caries. Therefore, when we choose a toothpaste, it's always good to choose a desensitising agent which contains fluoride. Eg- sodium monofluorophosphate toothpaste. Otherwise in case of sensitive teeth due to cervical abrasions/attrition/erosion can be treated with potassium phosphate.

# OPERATIVE

## SBQ 3

VERMA, 29 YEARS, SMOKES, DRINKS A LOT OF ALCOHOL WITH FRIENDS OVER THE WEEKENDS, IS VERY STRESSED IN A HIGH POSITION IN HER JOB, DRINKS LOT OF COFFEE AND SUGARY SNACKS IN EVERY BREAK, CAN'T SLEEP PROPERLY, HAS HEADACHES, WAKES UP FEELING TIRED, STARTED TAKING ANTIDEPRESSANTS/ ANTIANXIETY RECENTLY, COMPLAINS OF DRY MOUTH, HAS A POOR ORAL HYGIENE. INTRAORAL PICTURE GIVEN OF UPPER ARCH CLICKED FROM LOWER ANGLE. INCISAL EDGE LOOKS EVENLY WORN AND ALSO SMOOTH WORN DENTITION ON PALATAL/ BUCCAL TOOTH SURFACES NOT VERY CLEAR (DID SHE COMPLAIN OF SENSITIVITY? OR SCARED ABOUT HER ORAL CONDITION OR TEETH GETTING WORSE? RAISED AMALGAM MARGINS ON UPPER MOLARS WERE NOTICED BY SOME STUDENTS.)

### I. What is the reason for her condition?

- A. Erosion
- B. Abrasion
- C. Attrition
- D. Bruxism
- E. Toothbrushing

### II. What will you do for the above problem?

- A. Give her occlusal splint
- B. Ask her to reduce the dose of her medication
- C. Ask her to limit her alcohol and coffee
- D. Ask her to reduce the frequency of brushing
- E. Reduce frequency sugary foods

### III. What is the cause of her dry mouth?

- A. Medication- antidepressants
- B. Stress
- C. High caffeine intake
- D. Poor oral hygiene
- E. Insufficient intake of water

### IV. You did oral examination and find multiple caries. What will you give her?

- A. All fluoride options(concentrations were wrong except one)
- B. Single annual application of Fluoride varnish
- C. 5000PPM Fluoride dentifrice

### V. What will you do for the management of her dry mouth?

- A. Frequent sips of water
- B. Sugarless chewing gum
- C. Limit both alcohol and caffeine
- D. Ask her to reduce her medication

# OPERATIVE

## P.O.W.E.R NOTES SBQ 3

- I. According to the aetiology both erosion and attrition answers are correct. Erosion happens due to alcohol and coffee intake. Attrition happens due to stress. The only clinical feature to pick one answer out of these two is, raised amalgam margins which happens only due to erosion. Smooth worn outs are seen in both erosion and attrition.
- II. Occlusion splint can be given in case of attrition.  
We are not medical practitioners to reduce her dose of medications.  
Therefore, we can ask the patient to limit her alcohol and coffee intake which are the etiological factors for erosion.
- III. Causes of Dry Mouth: *(reference TG page no. 121, 122)*  
(A), (B), (C), (E) .. all these answers are correct. But among these (A) is the best. Because antidepressants have a direct anticholinergic effect on salivary glands which leads to stop secretions.
- IV. Since she has multiple caries, she's at a high caries risk. In high risk patient's 5000ppm toothpaste is suggested. *(reference: TG page no. 67 table 7)*
- IV. (A), (B), (C) are all correct. When all the answers are correct, you must follow the sequence given in the TG. *(reference: TG page no. 124 Box 14).*

# OPERATIVE

## SBQ 4

30 YEARS OLD, CAME FOR TREATMENT. WANTS BLEACHING FOR HIS TEETH. HAD PAIN WITH 36, 36 & 37 HAD OPEN CONTACTS AND AN OVERHANG RESTORATION, WANTS TO GET 36 TREATED AND HAS EROSION, DRINKS A LOT OF ACIDIC DRINKS(COCA COLA).HAD NEVER VISITED A DENTIST IN 3-5 YEARS, POOR ORAL HYGIENE.

---

### I. What will be the aetiology of the lesions?

- A. Coca cola
- B. Poor oral hygiene
- C. Erosion

### II. IOPA given and you diagnose that it is irreversible pulpitis. You want to do an RCT of it. But patient refuses Rubber Dam. What will you do? (IOPA given)

- A. Refer to endo
- B. Give alternate options like extraction
- C. Respect his decision make him sign a waiver
- D. Refuse to treat

### III. Patient wants to get bleaching regardless. What will you tell him?

- A. Need to stabilize his condition first
- B. Do tooth whitening, and make her sign waiver

### IV. What is the problem related to her chief complaint (36 overhang restoration & open contact)

- A. Overhanging restoration.
- B. Periapical area involvement
- C. Secondary caries

### V. Which restoration will you replace?

*(Open contacts & overhanging restorations in both the teeth 35 & 36, there was very initial signs of vertical bone loss mesial to 36)*

- A. Only 36
- B. 35 & 36
- C. 35 only



# OPERATIVE

## P.O.W.E.R NOTES SBQ 4

- I. In the question it's mentioned about erosive lesions. The history denotes that the patient drinks a lot of acidic drinks (coca cola). Acidic drinks lead to erosion.
- II.
  - RCT must not be performed without a rubber dam.
  - Because there's a high risk that the patient may aspirate files without a rubber dam.
  - It helps to maintain a sterile area without saliva and blood contamination.
  - It helps to prevent sodium hypochlorite accidents.

\*If a patient refuses rubber dam you can offer these options:

- a) Refer to an endodontist if the tooth is restorable.
- b) Give alternate options like extraction if the tooth is not restorable.

*\*You must see the picture and the IOPA to decide the restorability of the tooth.*

- III. Before performing a bleaching treatment, you must stabilise his conditions.  
If erosions are present you need to control it with habit intervention and then temporisation.  
If caries is detected, you must temporise them.  
Because bleaching may lead to further damage if the dentine is exposed to the oral cavity and lead to more sensitivity and teeth may undergo with pulpitis.  
After 2 weeks time of bleaching we can proceed ahead with the permanent restorations. This waiting time period is to stabilize the colour after a bleaching treatment.
- IV. Overhanging restorations alone will not give secondary caries unless there are marginal discrepancies.  
Overhanging restorations will lead to periodontal complications.  
Irreversible pulpitis results from caries, which is spreading to the pulp, so secondary caries is the direct course for pain.
- V. Both 35 and 36 are having overhanging restorations. Therefore, need to restore both. If only one tooth has overhanging restoration, then replace only that.

# OPERATIVE

## SBQ 5

**GAP B/W TEETH & OPEN CONTACTS: BITEWING GIVEN. MULTIPLE COMPOSITE RESTORATIONS, ALL IN GOOD CONDITION. GAP BETWEEN 36 37 CLEARLY SEEN. PATIENT COMPLAINS THAT SHE FEELS SORE IN THE 36 37 REGIONS SPECIALLY AFTER SHE EATS MEAT.**

### I. What is the cause of her soreness?

- A. Food impaction between 36 37
- B. Bone loss
- C. Secondary Caries
- D. Leakage
- E. Subgingival calculus

### II. What is the problem in the fillings?

- A. Open contact between 36 37
- B. Leakage
- C. Overhang

### III. IOPA given You are restoring 36 MO In order to gain proper contact with 35 what will you do?

- A. Using siqveland matrix and high viscosity packable composite.
- B. Use pre burnish tofflemire band
- C. Use clear matrix with light reflecting wedge
- D. Use Sectional matrix system with small increments
- E. Pack composite in big increments

### IV. Same iopa as above in iopa 37 had enamel caries on one of the proximal surface and other proximal surface has filling.what will indicate that 37 needs filling?(gap)

- A. Cavitation
- B. Sensitivity
- C. Pain

# OPERATIVE

## P.O.W.E.R NOTES SBQ 5

- I. Patient complains of pain after she eats meat, which means the pain is due to food impaction between 36 and 37 because of the gap between them.

**Open contact** → **Food impaction** → **Vertical bone loss (infra-bony pockets)**

Leads to localise periodontal bone loss. Bone loss is the diagnose and the cause/aetiology for it is food impaction.

There are no overhanging restorations, no calculi, restorations are in good condition so no secondary caries.

- II. Gap/open contact between 36 and 37 is the main problem for the food to get impacted in this area. No proper proximal contact will create problems. There are no overhanging restorations.

**Open contact** → **Food impaction** → **Vertical bone loss (infra-bony pockets)**

- III. Reason for the open contact:

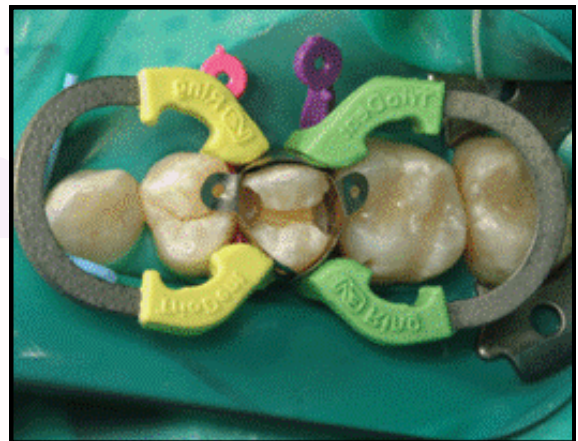When you don't use a wedge, you can't compensate the thickness of the matrix band.

Successful contacts are achieved with the "**sectional matrix system**" with small increments.

When the word "**system**" is given it denotes the combination of tofflemire, band and wedge. All the 3 items should be present.

### Reference:

*It is widely accepted that proximal contacts are very important features in healthy teeth. A lack of proximal contacts contributes to food impaction, secondary caries, tooth movement and periodontal complications. These studies supported use of the sectional matrix with separating ring in order to achieve tight contacts. the sectional matrix with separation ring seems to be the most reliable device for restoring proximal contacts in posterior teeth.*



- IV. Sensitivity will be treated with desensitising agents. Doesn't required filling.

Pain is an indicator for pulp involvement (irreversible pulpitis) or reversible pulpitis.

Irreversible pulpitis needs RCT, reversible pulpitis -Rx differs according to the situation.

According to ICDAS classification only cavitation required restoration. Cavitation is the 1st indicator.

# OPERATIVE

## SBQ 6

THE PATIENT PRESENTED TO YOUR CLINIC COMPLAINING THAT HE DOESN'T LIKE THE LOOK OF HIS OLD AMALGAM FILLINGS (PICTURE GIVEN MOLAR WITH AMALGAM CREEP AND NO SYMPTOMS) AND HE WANTS TO REPLACE IT WITH TOOTH COLOURED FILLING DUE TO AESTHETIC REASONS. YOU EXPLAINED TO THE PATIENT THAT IT'S BETTER TO RETAIN THE OLD AMALGAM FILLING SINCE IT'S STILL SOUND. BUT DESPITE YOU INFORMED HIM OF THE ADVERSE EFFECT OF REMOVING ALL THE AMALGAM, HE STILL INSISTS ON REPLACING IT. HOW DO YOU DEAL WITH IT?

### I. What is the risk of removing old amalgams

- A. Generation of Amalgam vapour
- B. Risk of teeth becoming non vital
- C. Tooth fracture

### II. IOPA of amalgam restorations given.

Lower 4, 5, 6 teeth were given and only 6 had overhanging restoration. Which one needs to be replaced?

- A. 5 only
- B. 6 only
- C. 5 and 6 both
- D. 4,5, 6 all

### III. The patient insists on replacing all the amalgams due to aesthetics complaints even after you explained all the risks. How would you manage this?

- A. Accept the patient's request with informed consent, documenting that you explained the adverse effects
- B. Refer the patient to another practitioner for a 2nd opinion.
- C. Accept the patient's request after he signs for a waiver
- D. Refuse to do the treatment.

### IV. What has caused the gap between the teeth?

- A. No wedge
- B. Wedge placed too gingivally
- C. Use of sectional matrix
- D. Use of Tofflemire system.

# OPERATIVE

## P.O.W.E.R NOTES SBQ 6

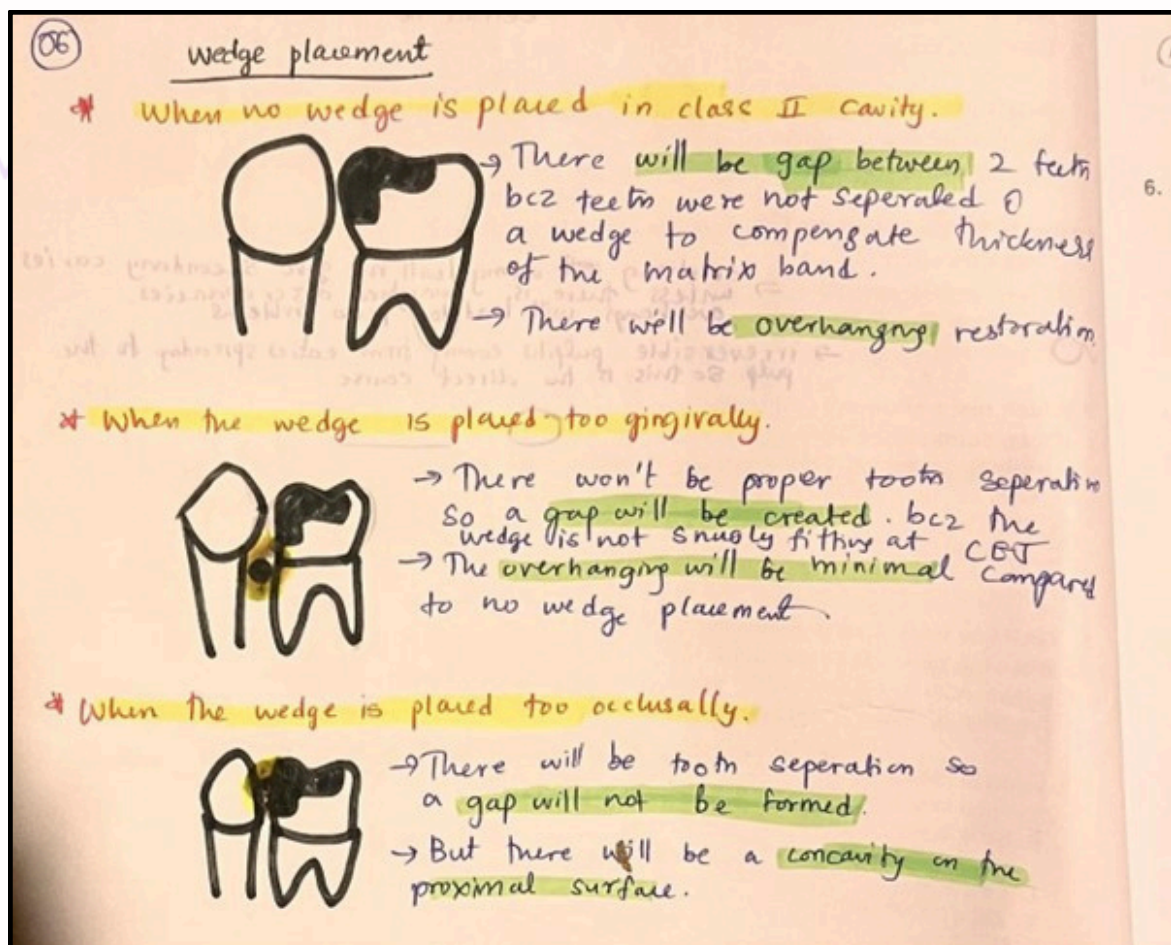
- I. Two main risk factors of removing old amalgams:
  - a) Health hazard- generation of amalgam vapour which can damage brain and other organs. This is the main risk factor.
  - b) Weakening of the tooth structure.
- II. Based on the history, radiographs and pictures the answer may get changed. Only the teeth which have overhanging should be replaced. Only 6 has overhanging.
- III. If the patient is concerned about aesthetics you can replace amalgam restorations, but don't remove the amalgam restorations unless they have been informed, explained and taken the consent.

### Reference: ADA policies

*Dental amalgam restorations should not be removed and replaced with alternative restorative materials for nonspecific or perceived health complaints unless the patient has been fully informed of the implication of this decision.*

### IV. Gap between the teeth/open contacts is due to: Not using a wedge

**\*when you don't use a wedge, you can't compensate the thickness of the matrix band.**





# OPERATIVE

## SBQ 7

**QUESTION ABOUT A HUGE AMALGAM RESTORATION. CLINICAL PICTURE OF SWOLLEN GUMS COVERING THE DO PORTION OF THE FULLY ERUPTED TOOTH 48. PATIENT IS 20 YEARS OLD AND CAME TO YOUR CLINIC COMPLAINING OF PAIN ON HIS LOWER RIGHT LAST MOLAR.**

**I. What is your proposed treatment for amalgam restored tooth?**

- A. Composite
- B. Gic core and full crown.
- C. Pin amalgam restorations
- D. Ceramic onlay
- E. Full crown.

**II. What is the medium term (mid to long term in some centres) prognosis of this tooth? The crack isn't involving the pulp.**

- A. Good
- B. Excellent
- C. Poor
- D. Fair

**III. What determines the prognosis of this tooth?**

- A. Cracks
- B. Amount of tooth structure remaining
- C. Vitality of the tooth
- D. Duration of placement of restoration

**IV. What mouthwash to be prescribed?**

- A. 0.2% or 0.12% Chlorhexidine gluconate
- B. Hydrogen peroxide
- C. Saline water

**V. Patient will come back after 2 weeks for extraction of 48. What is your interim management?**

- A. Prescribe analgesic regimen ibuprofen and paracetamol
- B. Advice to rinse with warm salt solution at home.
- C. Localised Debridement and 1% Hydrogen peroxide irrigation
- D. Apply locally the iodine with a cotton pellet.

# OPERATIVE

## P.O.W.E.R NOTES SBQ 7

- I. There's a lack of information in this question as there's no picture given. This needs a picture to choose the proper answer. Swollen gums (pericoronitis) present with another tooth -48. Amalgam filling is present in some other tooth.
- If it's a minor cavity and if you can see the retentive features, then we can use composite.
  - If it is a large restoration as mentioned in the history, in which it's proximal contacts are lost (walls are lost), it's better to choose a full crown.
  - If it's severely broken, then a crown with a core build up is required. Crown with a composite build up would be a good Rx option in this case.

### When to give an onlay?

*When the tooth structure/the walls are all in contact in 360 degree up to the middle 3rd or occlusally.*

### When to give core build up + crown?

*When 1 or more walls are broken below the middle 3rd and proper ferrule is available.*

### When to do crown lengthening+ core build up+ crown?

*When 1 or more walls are broken up to the CEJ or below CEJ crown lengthening is done to create a ferrule to retain the crown.*

- II. When you remove the amalgam filling you can see a crack. That's why you recommend a crown in this case. This crack is not involving the pulp therefore, you don't need to perform RCT.  
But still the prognosis is not GOOD or EXCELLENT, because the tooth is badly broken.  
Prognosis is not POOR, because you are not going for extraction.  
Tooth is moderately compromised with the remaining tooth structure. So, it has got a FAIR prognosis.
- III. The crack determines the prognosis.  
If the # line/crack is going below CEJ which means, it's a root # (VFR) so poor prognosis.  
Doesn't matter how much tooth structure is available, if the tooth has a crack.
- IV. According to TG both (A) and (C) are correct. Here we choose (A) because CHX is bactericidal and it's a pharmacological component.  
It's case of pericoronitis or infection before extraction both 0.2%/0.12% CHX or warm saline can be given. If both options are given, select CHX.  
In post extraction only warm saline is recommended. Because CHX is not given in open wounds.
- V. For interim management before extraction in pericoronitis CHX, POVIDONE IODINE, WARM SALINE (warm salt water) mouth wash can be given.  
CHX, POVIDONE IODINE mouth washes are superior to saline.  
Here application of POVIDONE IODINE with a cotton is given. That's why that answer is not selected.  
Analgesics are not needed for pericoronitis.

# OPERATIVE

## SBQ 8

TOOTH WAS BROKEN FROM BUCCAL & MESIAL SIDE. DISTAL WALL WAS INTACT. NO PAIN.  
IOPA GIVEN. IT WAS AMALGAM RESTORATION.  
IT FELL OUT ON TWO OCCASIONS.

I. The amalgam restoration fell out on 2 occasions. What would be the next management to avoid this issue?

- A. Crown lengthening with inlay
- B. Indirect ceramic inlay
- C. Composite restoration
- D. Pin amalgam
- E. RCT post followed by crown

II. Which investigation would you do?

- A. Pulp sensibility testing
- B. Percussion
- C. Pulp sensibility and cuspal loading
- D. Probing

## P.O.W.E.R NOTES SBQ 8

- I. If there was an answer given such as CROWN LENGTHENING +FULL CROWN, that will be the best answer. Because it's conservative rather than doing elective RCT+POST.

Crown lengthening will help to increase the ferrule effect in the missing wall at least 1.5-2mm, so the crown will retain. Without crown lengthening crown will not retain.

In this case 2 walls are lost. That means 50% of walls are not there. If 50% or more walls loss, you need this type of management.

**What's a prophylactic RCT?**

When more walls are broken and grossly destructed, it required post and core Rx. In this type of grossly destructed teeth, even though the pulp is not involved RCT is required to place a post.

- III. To check pulp vitality, we can do the pulp sensibility test. If it's non vital we can perform RCT.

Since it's a broken tooth we must do "cuspal loading" to check cracks.

Probing is usually done when u suspect a VRF.

# OPERATIVE

## SBQ 9

LADY WITH OVER CONTOURED, VERY WHITE RESTORATION. SHE IS NOT HAPPY WITH THE APPEARANCE OF ONE OF HER UPPER LEFT TEETH. (ON A RETAINED PRIMARY CANINE.) RETAINED DECIDUOUS 63. XRAY SHOWED IMPACTED 23.

### I. What is true regarding the impaction of Maxillary Canine?

- A. 20% impacted
- B. 12% impacted
- C. Max Canine more commonly impacted buccally
- D. Max Canine more commonly impacted palatally.
- E. % of the impacted maxillary canine cause resorption of the premolar.

### II. What treatment is unlikely to improve on the esthetics of c?

- A. Increasing the value of the tooth shade for composite veneer replacement?
- B. If you use multi layering technique of composite restoration you can improve the colour or shade)
- C. Reducing the buccal contours of the tooth.
- D. Change the veneer and improve on the size and shape of the tooth?

### III. Best x-ray for impacted canine (best x Ray to locate the position of impacted canine)

- A. CBCT
- B. MRI
- C. Another x-ray from different horizontal angulation
- D. Occlusal

### IV. For aesthetics, the patient requested direct veneer. What is not needed?

- A. Increase the Composite color value
- B. Wax up and die and putty
- C. Reduction of buccal contour

# OPERATIVE

## P.O.W.E.R NOTES SBQ 9

- I.
  - Maxillary canine gets impacted = 3%
  - Out of that 80% gets impacted palatally.
  - So maxillary canine more commonly gets impacted palatally than buccally.
  - Impacted maxillary canines lead to resorption of incisors.
- II. When a **value is high**, it means **the colour is very bright and opaque**.  
When **chroma is high**, it means **the colour is very dull**.  
When value is high, the chroma will be low. They oppose each other.
- III. Usually SLOB TECHNIQUE (same lingual opposite buccal) is preferred for impacted canines. Another XRAY from a different horizontal angulation.  
But in the question if they ask "THE BEST" Xray for impacted canine and if the CBCT option given, then you must select CBCT.
- IV.
  - In the question it is mentioned "VERY WHITE RESTORATION". This denotes the value is already high so what is not needed is ...increasing the colour value.
  - For direct veneers 1st need to get impressions then make cast, wax up and die and make putty impression. So, it will be easy to make contours in teeth. It can guide the direct veneers. Even the patient can get the direct idea about the restoration.
  - It's a tooth with an over contoured restoration so reduction is needed.



# OPERATIVE

## SBQ 10

### SERENA CASE (VERSION 1)

THERE WAS A STAINED DISCOLOURED RESTORATION ON PATIENT'S 13 AND 14 WITH CARIES APPEARING MENTIONED IN QUESTION THAT CARIES ARE EXTENDING 0.5 MM SUB GINGIVALLY. PATIENT WANTS AN AESTHETIC TREATMENT DONE ON THESE TEETH BECAUSE THEY ARE VISIBLE ON SMILING AND IT MAKES HER CONSCIOUS. THE PATIENT HAD IMPROVED HER OH AND DIET BUT IS STILL SMOKING. THE SBQ PREVIOUSLY MENTIONED THAT SHE ONLY WANTS A TREATMENT THAT IS NEITHER EXPENSIVE NOR TIME CONSUMING.

#### I. What will be your treatment?

- A. PFM crowns
- B. Ceramic crowns
- C. Bonded composite restoration
- D. GIC Fuji VII (brand names were used)
- E. Ceramic veneers

II. This was also slightly different from mmf. After 5 years she's all good. In this whole period you had given the required treatment and removed two teeth which were non saveable and given an RPD (immediate was not mentioned nor was mentioned when you gave her) now she came saying it's loose?

- A. Give her new acrylic rpd New co cr rpd
- B. Reline the rpd
- C. Implant

# OPERATIVE

## P.O.W.E.R NOTES SBQ 10

I. The most important points in this question:

**Extending 0.5mm sub gingivally**- if caries extending more than 0.5mm sub gingivally, it will violate the BW and crown lengthening is needed in such cases.

**Concerned about aesthetics but need neither expensive nor time consuming Rx**- in such cases RMGIC would be the best answer. RMGIC is better than GIC as it has reduced solubility in saliva and better retention. RMGIC is Fuji II. Therefore, composite is most suitable from the given.

- Type I - Luting cement used for cementation of crowns and bridges
- Type II - Restorative cement used for aesthetic fillings
- Type III - GIC used as liners and bases
- Type IV - GIC used as pit and fissure sealants
- Type V - GIC used for orthodontic cementation
- Type VI - GIC is used for core build-up in highly mutilated teeth
- Type VII - Fluoride releasing light-cured GIC
- Type VIII - GIC for atraumatic restorative treatment (ART)
- Type IX - GIC used for pediatric and older adult restorations

PFM and CERAMIC crowns, CERAMIC veneers are invasive treatment options which damage more tooth structure, and which is not required in minimal caries Rx.

II. If it was an immediate RPD there will be so much resorption after extraction, so only relining would not be enough. A new RPD should be constructed. Therefore, if it was an immediate RPD, the answer would be (A)  
Since she got a conventional RPD, answer would be (B).

# OPERATIVE

## SBQ 11

**EROSION CASE (DRINKS 5 GLASSES OF WINE DAILY, SMOKES 40 CIGARETTES, OBESE 128KGS, NOT A REGULAR ATTENDEE TO DENTIST) COMES TO SEE YOU WAITING FOR MY TEETH TO BE WORN OUT JUST LIKE ME AND NEED HELP?**

---

### I. Etiology of lesions?

- A. Alcohol
- B. Smoking
- C. Poor oral hygiene

**II. Dentist decided to increase the VDO by 4mm. Treatment with composite build up on anterior teeth was decided and the patient also consents to that. Has 14,15,16,24,25 missing. Picture given. How do you proceed with treatment?**

- A. Raise VDO with acrylic appliance with missing tooth for a period of at least two weeks
- B. Posterior Dahl appliance
- C. Anterior composites build-up with composite on few posterior teeth to aid other posteriors to re erupt
- D. Wait for 12 months to stabilize the risk factors reduction
- E. Replace all premolars and 16 with RPD and allow rest of posteriors to erupt.

# OPERATIVE

## P.O.W.E.R NOTES SBQ 11

- I. Erosion can be of 2 types. Extrinsic and intrinsic erosion.  
Alcohol, carbonated beverages leads to extrinsic erosion.  
Medical conditions such as GERD, Bulimia, Anorexia leads to intrinsic erosion.  
Smoking leads to periodontal destruction and poor OH leads to caries risk.

II. Missing teeth-

- 14,15,16,24,25

Teeth present in the posterior-

- 17,26,27
- 37,46,47 (*only 3 posterior contacts*)

Only 3 posterior contacts are left to increase VDO. Extrusion of these molars are required to increase VDO.

**OPTION A:**

Acrylic appliance with increased VDO on the missing teeth helps to extrude the posterior teeth. This RPD is not the definitive RPD and that's why it's given for short duration of 2 weeks time to check how much increased VDO can be achieved. Due to this short duration this answer is incorrect as much change won't be achieved in that short duration.

**OPTION B:**

Posterior Dhal appliance leads to anterior teeth extrusion. For this case anterior Dhal appliance is needed as it will help in the extrusion of posterior teeth.

**OPTION C:**

Among the given answers this is the best. But still it has a little mistake. Only 3 contacts are left to place composites over them and there's no any other posterior to extrude.

**OPTION D:**

When there's active erosion you can't do any restoration. So, it's better to wait to stabilise the risk factors reduction. But to wait 12 months is quite long. This answer would have been correct if it says 2 months.

**OPTION E:**

In this option it was not mentioned RPD with increased VDO. There's no point of having a RPD with same VDO. Then it would not be helpful in extrusion of posteriors.

# OPERATIVE

## SBQ 12

CENTRAL INCISORS 11 21 (IOPA) WAS GIVEN. THEY SAID THERE WAS INTERPROXIMAL DEMINERALISATION SPOTS BETWEEN THEM (ONLY MENTIONED IN THE QUESTION IN X-RAY IT WAS NOT VISIBLE, MAYBE DEMINERALISATION SEEN IN X-RAY AFTER 40% OF DEMINERALISATION OCCURS IN THE TEETH).

### I. How to treat it? Options were given?

- A. Fluoride varnish
- B. Fluoridated TP
- C. Restoration with rmgic

### II. What to check in a patient's history?

- A. Diet
- B. Fluoridated water
- C. Flossing

## P.O.W.E.R NOTES SBQ 12

- I. Early lesion/incipient caries can be arrested/remineralised with the help of fluoride treatment.

For the white spot lesions F varnish along with home care is the best.

- Low caries risk- 12 months review
- Moderate caries risk- 6 months review
- High caries risk- 3 months review

In the absence of hx of sugary drinks/snacks intake, excessive plaque, saliva contribution, we consider this case a low risk. Therefore, can apply varnish once a year.

According to ICDAS classification restoration is required in the presence of cavitation.

- III. In the patient hx we must check for the diet, salivary test, plaque index, OH maintenance, type of water, fluoride hx. Among all diet is the most important as it is a contributory factor for caries incidents. Therefore, maintaining a diet chart is very important.



# OPERATIVE

## SBQ 13

**BROKEN AMALGAM (OLD) CUSP LM BROKEN, THEY GIVE A PIC, SAYING THAT AFTER REMOVAL OF AMALGAM THE DENTIST SAW A GOOD REMAINING STRUCTURE, SOME CUSP SEEMED TO HAVE 1-2MM. WHAT IS THE BEST MANAGEMENT TO RESTORE? THERE WAS ONLY DISTAL, HALF BUCCAL N HALF LINGUAL WALLS REMAINING .. N ON MESIAL SIDE ITS MO WALL TILL 1-2MM BELOW MARGIN.**

- A. Resin composite
- B. Indirect resin composite
- C. Indirect resin composite w/ cusp coverage
- D. GIC core and Full Crown
- E. Post core and Full crown

## P.O.W.E.R NOTES SBQ 13

- I. **Mesial wall= MO involvement 1-12mm below the margin**

**Distal wall= completely present. No damage.**

**Buccal wall= ½ of the wall is present**

**Lingual wall= ½ of the wall is present**

- There's no 360degree complete ferrule as the mesial wall is broken below the gingival margin. When there's no 360degree ferrule, we must do crown lengthening. When 1 or more walls are broken up to the CEJ or below CEJ crown lengthening is done to create a ferrule to retain the crown.
- When more than 180degree walls are lost, even though ferrule present or not we need to give a post for good retention. In this case 3 walls are broken which is more than 180degree.
- If crown lengthening is not done at least post should be given to create a wall.
- How to build a core without a support to build it? without a ferrule can't build a proper core.

# OPERATIVE

## SBQ 14

12 YEARS OLD HE GETS HIS 6 MONTHS FLUORIDE TREATMENT BUT DOESN'T BRUSH WELL. HE PLAYS SPORTS? BUT DOESN'T LIKE SPORTS DRINKS AND DRINKS LESS WATER AS STAYS BUSY WHEN DOING SPORTS, EATS DRY FRUITS FOR ENERGY. HE HAS OCCLUSAL LESIONS ON HIS PRIMARY TEETH AND PERMANENT MOLARS HAS DEMINERALISED AREAS ON BUCCAL SURFACES.

### I. What is the most appropriate advice for him?

- A. Replace energy bars
- B. Replace sports drink with water?
- C. Ask him to drink sports drinks for energy
- D. Replace nuts with fruit juices.

### II. What is most appropriate advice for his Caries Management? (patient has high caries risk)

- A. Neutrafluor 5000 Tooth paste
- B. Fluoride varnishes every 6 months.
- C. Brush and floss in the morning
- D. Include 900 ppm mouthwash in his daily regimen

### III. How do you improve his water intake?

- A. Advice his mom to remind him of drinking when playing.
- B. Give him an expert opinion on the effects of hydration on Oral health.
- C. Tell him about the consequences of less water intake on his teeth and help him improve his water intake.
- D. Asked him to set a date when he would start drinking 2 liters of water everyday.

# OPERATIVE

## P.O.W.E.R NOTES SBQ 14

### I. Risk factors for caries:

Doesn't brush well

Less water intake → dryness in mouth → caries

Dry fruits for energy → tend to stick on the tooth surface and good source for bacteria

#### OPTION A:

in the hx it's not mentioned about the energy bars and also in the answer it's not mentioned to replace with what. Incomplete answer too.

#### OPTION B:

It's mentioned that he doesn't like to drink energy drinks but that doesn't mean that he doesn't drink energy drinks. Energy drinks has sugar and it's a risk factor for both caries and erosion. It's good to replace it.

#### OPTION C:

There are other good sources of energy rather than sports drinks.

#### OPTION D:

Fruit juice is high sugar source. It's good to eat the natural fruits rather than drinking juice. Nuts are better than fruit juice. Replacing nuts to fruit juice will worsen the condition as fruit juice is both cariogenic and erosive.

### III. OPTION A:

5000ppm toothpaste is recommended for adolescent and adults. We can prescribe it from 13yrs of age onwards. Still the patient is 12yrs old.

#### OPTION B:

He's already getting the Fluoride varnish treatment.

#### OPTION C:

It's recommended to brush twice daily. But this is the best answer among the given as in the hx it's mentioned that he doesn't brush well.

#### OPTION D:

According to TG 900ppm mouth wash is recommended once weekly.

### III. Since he's a child patient option (B), (C), (D) won't work for him. Mother can always pay attention and remind him during his practice.

# OPERATIVE

## SBQ 15

12 Y.O. PRIVATE SCHOOL BOY COMES FOR HIS 6 MONTHLY REVIEW. YOU'VE BEEN APPLYING VARNISH EVERY 6 MONTHS FOR 5 YEARS. HE PLAYS SPORTS, WEARS A MOUTH GUARD, DOES NOT DRINK MUCH WATER AND DOES NOT LIKE SPORTS DRINKS. ALMOST ALL HIS MEALS INCLUDE SUGAR, BUT HE TENDS TO SNACK ON CHEESE AND FRESH FRUITS. WHAT IS THE MAIN PREVENTIVE FACTOR THAT PROTECTS HIM FROM CARIES?

- A. Fluoride applications
- B. Non sugary snacks
- C. His good socio-economic condition
- D. The fact he doesn't like sport drinks
- E. Genetics

## P.O.W.E.R NOTES SBQ 15

CARIES RISK FACTORS	PREVENTIVE FACTORS
Excessive plaque	Good OH
High sugar intake	Reduced intake of sugar
Lack of fluoride	F applications and F toothpaste
Less salivary flow (medication, medical conditions can affect saliva)	Unstimulated flow=0.3-0.4ml/min Stimulate flow= 1-2ml/min
Less water intake	Good hydration 2-3 L/day

But when you compare the preventive factors fluoride application and reduced sugar intake, fluoride application is the most important as it strengthens the tooth. It has the highest predictability of protection of the teeth.

It's the every 6months interval fluoride application gives him most of the protection.

Causative factor = SUGAR comes number one  
Preventive factor= FLUORIDE comes number one

**\*STRONGEST PROTECTOR = FLUORIDE**

**\*STRONGEST ATTACKER= SUGAR**

# OPERATIVE

## SBQ 16

### HOW DO YOU ASSESS THAT THE EROSION IS ACTIVE?

- A. Fluoride applications
- B. Non sugary snacks
- C. His good socio-economic condition
- D. The fact he doesn't like sport drinks
- E. Genetics

## P.O.W.E.R NOTES SBQ 16

I.

ACTIVE EROSION



MAKE A STAIN ON THE TOOTH  
AND CHECK THE STAIN IN THE NEXT VISIT



IF IT DISAPPEARS THEN IT'S ACTIVE EROSION

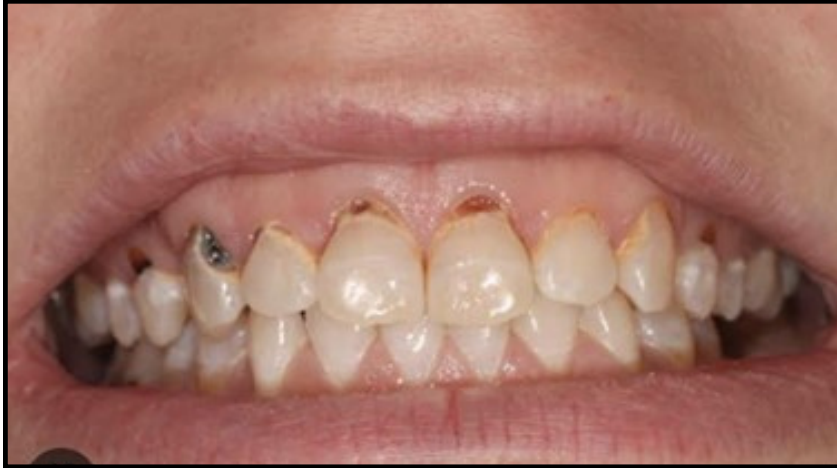In the absence of the option (D), the next best option is absence of lower lingual calculus.

Erosive wear index denotes how much destruction due to erosion has happened. It can be in relation to present or past erosion, but it doesn't indicate about the active erosion.

Lack of lustre means the dull appearance. But in erosion the tooth surface appears shiny. But shiny appearance of the tooth doesn't indicate active/inactive erosion.

Secondary dentin feels hard may be due to the occurrence of erosion. But it doesn't explain that it's active/inactive erosion.

# OPERATIVE

**SBQ 17**

**I. You are a dentist in a correction center. LA given- patient had palpitations for sometime and then went away . The reason?**

- A. Adrenaline effect
- B. Lignocaine effect
- C. NRT effect with La.
- D. Pt smuggling methamphetamine just before the appointment
- E. LA allergy

**II. Dentist visiting the prison for oral health checkup for inmates. A new inmate had come in a week ago. He has drug issues. Methamphetamine use. Pic given with cervical caries. Also a smoker( currently NRT patch as he is in the cell) - He just stopped because not allowed to smoke in prison, hence he is on nicotine patches. What effect does meth have in this particular presentation (cervical caries) ? Along with methamphetamine, what is most likely responsible for his dental condition. What was associated with methamphetamine? (There were cervical caries all over. Well demarcated black spots in cervical areas)**

- A. Bruxism
- B. Xerostomia I definitely didn't have this option- no, it wasn't an option
- C. Craving for sugary food/drinks
- D. Alcohol abuse

**III. Pt has minimal BOP - but has deep pockets. What is masking his Perio condition?**

- A. Reduced gingival blood supply
- B. Cigarette smoking
- C. Suppression of inflammation due to compromised immunity by methamphetamine
- D. Improved oral hygiene



# OPERATIVE

## SBQ 17

### IV. What are the most common side effects of Nicotine Replacement Therapy?

- A. Headache
- B. Ulcers
- C. Bradycardia
- D. Hypertension
- E. Obesity
- F. Craving for Sugary Drinks

### P.O.W.E.R NOTES SBQ 17

- I. Many patients feel “**adrenalin rush**” or “**vasovagal reaction**” when injected with lidocaine and epinephrine during wide awake surgery.

**Adrenaline rush symptoms:**

Nervousness, anxiety, tremors, shaky feelings, flushing, light headedness, tingling and heart racing.

**Vasovagal response:**

Nausea, a feeling of being unwell, faint, light headedness, pallor

NRT is not a contraindication for LA. So, no effect even though the patient is wearing NRT.

Methamphetamine smuggling just before the appointment would result in more systemic and more long-lasting effects. MA duration of action can be up to 24hrs. If the patient has used MA within last 24hrs the vasoconstrictor in LA could result in hypertension, MI, cardiovascular accidents.

LA allergy will result in urticaria, angioedema and anaphylaxis.

- II. **Dry mouth** and **craving for sugar** are the side effects of methamphetamine use which leads to dental caries.

There's a significant association between MA use and sugar soda consumption. In addition, sugar soda consumption is associated with more dental problems among MA users.

MA users crave beverages high in sugar while they are high mainly because they experience dry mouth. The bacteria that feed on the sugars in the mouth will secrete acids which can lead to more tooth destruction. With MA users tooth decay will start at the gum line and eventually spread.

Therefore, dry mouth comes first and craving for sugar comes second as the risk factors for caries risk in MA users.

MA users feel anxious, hyper or nervous. So, they will clench or grind their teeth. You may see severe wear patterns of their teeth. Sometimes even bite or chewing on soft food like smashed potato, will cause their teeth to break.

# OPERATIVE

## P.O.W.E.R NOTES SBQ 17

- III. **Gum Disease** – Methamphetamine users do not seek out regular dental treatment. Lack of oral health care can contribute to periodontal disease (destruction of the bone that supports the teeth). Teeth and gums need blood to stay healthy. Methamphetamines cause the vessels that supply blood to oral tissues to shrink in size. A reduction in blood flow will cause the tissues to break down. Over time the blood flow cannot recover, and the tissue will become necrotic.

Therefore, the best answer is (A) and the second best is (C).

IV. **Side effects of NRT**

- Nausea, vomiting, indigestion, and gastrointestinal disturbances
- Insomnia and sleep apnoea
- Headaches
- Oral ulcers
- Skin irritation
- Heart palpitations/chest pains
- Coughing
- Throat soreness
- Dry mouth
- Increase caries-risk profile
- Taste impairment
- Difficulty in speech in denture wearers
- Hyperkeratosis
- Localized mucosal irritation

So, both (A) AND (B) options are correct.

# OPERATIVE

## SBQ 18

### SERENA CASE (VERSION 2)

SHE HAS DARK DISCOLOURATION, LESS EXPENSIVE AND LESS TIME-CONSUMING TREATMENT. NOW SHE WANTS AESTHETICS AS THEY ARE VISIBLE WHILE SMILING AND HER ORAL CONDITION HAS IMPROVED AND SHE SMOKES LESS?

I. How will u restore her 0.5 mm subgingival caries on 13, 14 with many times restored teeth?

- A. GIC
- B. Polyacid modified resin composite
- C. Resin composite

II. Pt is diabetic. You have planned for extraction of 46,47 as patient doesn't want RCT But she is concerned about post op infection, What do u suggest to avoid post op infection in extraction area?

- A. Give her Amox 5 days
- B. Nystatin 7 days
- C. Metronidazole 5 days
- D. Rinse warm water saline three times a day after extraction
- E. Chlorhexidine

### P.O.W.E.R NOTES SBQ 18

- I. GIC can only be used as a PR in patients with dementia, mental incapacities, who can't stay longer in dental chair.  
Resin composite is expensive.  
Compomer/resin modified composite is cheaper than resin composite and will provide good aesthetics.  
If RMGIC is given then that would be the best answer.
- II. According to TG no AB or antifungal is given after extraction.  
CHX is not used after extraction or in open wounds.  
Warm saline rinse is recommended after extraction according to TG. It's not done soon after extraction and it's recommended after 24hr of extraction.

# OPERATIVE

## SBQ 19

**BITEWING RADIOGRAPHS GIVEN FOR ALL SEXTANTS. QUESTION ASKED ABOUT A TOOTH 27, HAS BIG FILLING AND CAN SEE CARIES IN THE DISTAL OF THE TOOTH. PT REPORTS PAIN ON DRINKING HOT TEA DRINK, GETTING WORSE, AND IS KEEPING HIM UP AT NIGHT. (CANALS LOOKED OBLITERATED TO ME IN THE X RAY)**

**I. You decided to do a sensitivity test which the following is correct (precise, adequate)?**

- A. Heat test
- B. Cold test with CO<sub>2</sub>
- C. Tetrachloroethane
- D. EPT

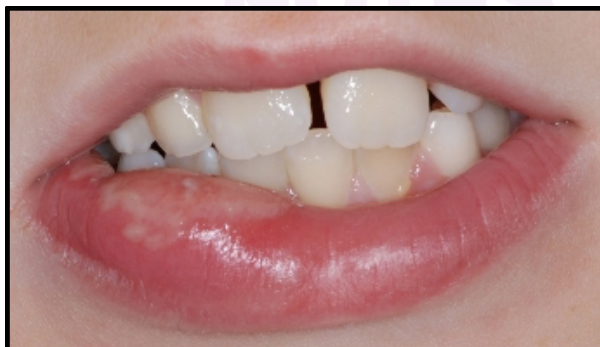**II. What is the variation you expect in treating the tooth 27?**

- A. 2 canals in palatal root
- B. 2 canals in MB with one foramen
- C. 2 canals in MB with 2 foramen
- D. 2 canals in DB with one foramen
- E. 2 canals in DB with 2 foramen

**III. What is the maximum cartridge of 2.2 ml of Lignocaine 2% (1:80000) that you can give to the child 25kg?(in my centre said 48 kg)**

- A. 1 cartridge
- B. 2 cartridges
- C. 3 cartridges
- D. 4 cartridges
- E. 5 cartridges

**IV. The child comes with the lesion in her lip the next day? The cause for that is:**



- A. Patient bite his lip while still numb
- B. Dentist accidentally hurt patient
- C. Allergic reaction to LA

# OPERATIVE

## P.O.W.E.R NOTES SBQ 19

- I. Patient has pain on drinking hot tea. Therefore, no need to do heat test.  
Among sensibility tests cold tests are the best and among them tetrachloroethene is the best. Second best is dry ice/CO<sub>2</sub> snow.
- II. Single MB canal= 60%  
2MB canals= 40%
  - 2MB canals in 1 foramen
  - 2MB canals in 2 foramens
- III. Max amount of LA that can be given for 1kg body weight= 7mg  
Max amount of LA that can be given for 25kg body weight= 7x25mg  
Lidocaine 2% = 20mg/ml  
Maximum dose of LA in (ml) that can be given to the patient =  $\frac{7 \times 25}{20} = 8.75\text{ml}$
- IV. The lesion appears keratotic and inflamed. This usually happens when patient bites the lip as the area is num and patient can't feel it.  
If the dentist hurts the patient it should have appeared on the time of the appointment.  
Allergic reaction to LA is very rare and appears as urticaria, angioedema, anaphylaxis.

# OPERATIVE

## SBQ 20

**PATIENT HAVING A STAIN IN BETWEEN 11 AND 21. (FULL CONTACT BETWEEN TEETH) (NO GAP)**

**I. You decided to do a sensitivity test which the following is correct (precise, adequate)?**

- A. Incipient caries
- B. Caries

**II. What additional measure to give apart from fluoride toothpaste**

- A. Interdental brushes
- B. Floss

**III. What will help you with identifying what's the stage of the periodontal condition?**

- A. His alcohol intake
- B. His smoking habit
- C. His clinical attachment loss
- D. His hba1c percentage

## P.O.W.E.R NOTES SBQ 20

- I. If it's a white stain, then answer would be (A)  
If it's a dark colour stain, then the answer would be (B)  
Answer depends on the given picture.
- II. In case of caries OH, brushing techniques, fluoride tooth paste, F varnish/gel , floss is important.  
In tight contacts floss is helpful and in open contacts/gaps interdental brush is helpful.
- III. Smoking and diabetes (HbA1C percentage) are indicators which helps in grading.  
Attachment loss will be helpful in grading.  
Alcohol intake is not associated with periodontitis. It's associated with dry mouth and erosion.



# OPERATIVE

## SBQ 21

**I. Clinical picture showing lower molar with crack extending to the bifurcation. How to check the cracks /fracture, the crown has a ceramic crown.**

- A. Closed debridement
- B. Surgical flap to visualise confirm the crack/fracture
- C. Percussion test

**II. Patient has pain how will you investigate?**

- A. Probing
- B. Remove crowns and observe
- C. Take OPG

**III. The patient need extraction, tooth pain and swelling, and also she will have prosthetic joint surgery in a week time. You performed extraction. What antibiotic regime you provide?**

- A. No antibiotics as source of infection removed
- B. Amoxicillin 500mg 5days
- C. Phenoxy penicillin 500mg 5days
- D. Amox plus clav 875 + 125 mg

## P.O.W.E.R NOTES SBQ 21

- I. If a tooth is restored and you are suspecting a crack, you can inspect it visually. And if the crack is extending to the bifurcation area can be visually check by removing the crown/removal of the restoration and raising a flap. Close debridement is needed in the presence of deposits. Percussion test is done to see the periapical involvement.**
- II. It's natural to have pain in the presence of cracked tooth. Probing will be helpful in the presence of VRF. IOPA/OPG will not be helpful in investigating cracks. Removal of crowns/restoration and using the transillumination will be helpful in finding cracks.**
- III. Localised infection doesn't need therapeutic AB as the active dental Rx will remove the source of infection. Spreading infection will require therapeutic AB. Prosthetic joint surgery is not a requirement to give prophylactic AB. Prophylactic AB is given in endocarditis and few other cardiac conditions which is mentioned in TG. (reference page no: 194 box 24)**

# OPERATIVE

## SBQ 22

THERE WAS A CLINICAL PICTURE GIVEN WITH WHITE SPOTS ON UPPER ANTERIOR INCISORS, THESE SPOTS DISAPPEAR WHEN THE SURFACE WAS WET. SHE ALSO HAD WHITE SPOTS ON THE CERVICAL AREA WHICH WERE VISIBLE BOTH WET AND DRY SEEN AFTER PLAQUE REMOVAL. PT HAS A HISTORY OF FINANCIAL CONSTRICTIONS. SHE LOST HER FATHER. AND SHE HAS TO LOOK AFTER HER FAMILY. THE WHITE SPOTS APPEAR IN SUCH A WAY THAT ORTHODONTIC DEMINERALIZATION SPOTS. (SHAPE OF THE BRACKETS WERE VISIBLE IN THE GIVEN PICTURE), THE WHITE SPOTS WERE ONLY SEEN ON THE INCISORS. SHE HAD CHRONIC MIDDLE EAR INFECTIONS AND CHICKEN POX. (SPOTS LOOK SQUARISH LIKE YOU LL FIND AROUND THE BRACKETS) DENTIST NOTED WHITE SPOTS WERE VISIBLE ON THE MID BUCCAL AREA TOO. (IT WAS MENTIONED). THE DENTAL SURGEON 1ST THOUGHT IT WAS MOLAR INCISOR HYPOMINERALIZATION SPOTS. BUT LATER HE CONCLUDED THAT IT'S NOT MIH SPOTS, BECAUSE MOLARS WERE NOT INVOLVED.

**I. Dentist thinks these are MIH spots. How will you confirm this is not MIH?**

- A. Did you take ortho treatment before
- B. History of middle ear infection
- C. Did you have any infectious disease at your childhood
- D. History of chickenpox

**II. Dentist thinks it might be caries as well, how will you confirm this is not caries?**

- A. It was visible when both wet and dry
- B. Surface feels rough when probed with blunt probe

**III. Dentist thinks it might be ortho demineralisation spots, how will he confirm?**

- A. Spots were present at the location of orthodontic brackets

**IV. You used the blunt end probe around the white spots, and felt rough when you did so. What does it indicate?**

- A. Cavitation present
- B. Active lesion
- C. Remineralized
- D. Progressing towards arrested

**V. As a preventive measure, what will you recommend?**

- A. Restore with composite
- B. Restore with GIC
- C. Fluoride varnish every three months
- D. 1200 ppm toothpaste twice daily
- E. SDF application

**VI. What advice can you give to the patient to prevent caries in the future, (in the history it was given the patient has a very busy life schedule and se brushes only in the morning)**

- A. Pay more attention more on your oral hygiene

# OPERATIVE

## P.O.W.E.R NOTES SBQ 22

- I. Childhood infection can lead to disturbance in enamel matrix formation and later results in MIH. Options (B), (C), (D) can be excluded as all these 3 options are about childhood infections.  
Orthodontic Rx can result in orthodontic demineralisation spots in patients who don't maintain good OH.
- II. In the presence of caries, the surface feels rough when probed with a blunt probe.  
Incipient caries: Visible when the tooth surface is dried. But when caries has progressed halfway into the enamel it can be seen in wet tooth surface too.  
Hypoplastic/hypo mineralised enamel: It can be seen in both wet and dried situations.  
Both the given options are incorrect.  
The only information that rules out caries is history of orthodontic treatment.
- III. When the spots are located at the area where orthodontic brackets were placed and when the spots appear squarish in shape, it will confirm the orthodontic remineralisation spots.
- IV. • Active enamel lesions are whitish, chalky and feels rough.  
• Inactive enamel lesions appear shiny, glossy and smooth. As an example, arrested or progressing towards arrested or remineralized.  
• Cavitation means "a break under depression."
- V. Fluoride tooth paste with CPP-ACP is recommended for orthodontic demineralising spots. But that option is not given.  
There's no cavitation therefore, restoration is not required. Option (A), (B) and (E) are ruled out.  
1200ppm toothpaste won't be helpful in this case.  
So, varnish application is the best option.
- VI. In her situation oral hygiene is the matter as she brushes only once daily due to her busy life.  
Improving OH will prevent from further caries progression.

# OPERATIVE

## SBQ 23

**QUESTION RELATED TO AMALGAM RESTORATION THAT WE DID IN OUR CLASS. HER NATUROPATH SAID IT'S NOT GOOD FOR HER, THE PHOTO IS SHOWING MULTIPLE AMALGAM (TOOTH 17, 16 MOD, PREMOLARS).**

**I. To manage tooth 16 had a huge amalgam mod filling discoloured from distal side and had secondary caries**

- A. Replace half amalgam
- B. Remove and replace whole restoration
- C. Repair only buccal groove by composite
- D. Replace all the restorations with composite
- E. Replace only disto palatal part of restoration

**II. Her dietician says to remove all the amalgam fillings as she has allergy to nickel**

- A. Explain the no relation with amalgam
- B. Do as per the patient demand
- C. Ask suggestions from GP

## P.O.W.E.R NOTES SBQ 22

- I. In the presence of secondary caries, the complete restoration must be removed and replaced. If you don't remove the whole amalgam restoration, then you won't be able to remove all the secondary caries. Then it will lead to incomplete cleaning.
- II. Explain the patient that there's no association with the nickel allergy and amalgam restoration. PFM restorations can't be given in nickel allergy. Even after explaining if the patient still wants to get the amalgams replaced, then get the informed consent, make them understand the drawbacks and proceed ahead with replacement. When you replace them use rubber dam, high vac evacuation system by doing so you can prevent yourself, staff and the patient getting exposed to unnecessary amalgam vapour generation.

# OPERATIVE

## SBQ 24

### TRUCK DRIVER CASE

PAIN IN UPPER RIGHT BACK REGION. HE CAME TO THE EMERGENCY DEPARTMENT - DRANK COLA THE WHOLE DAY, SMOKED 5 CIGARETTES IN A DAY, DECAYED TEETH MENTIONED IN EXAM, NO PIC GIVEN. AND MENTIONED BOTH HIS PARENTS WEAR DENTURE, NO OTHER DIET HISTORY GIVEN AND NOTHING ABOUT ORAL HYGIENE

I. Other than oral hygiene instruction what other main component could be contributing to his high caries risk.

- A. Smoking
- B. Genetic predilection
- C. High sugar intake

### P.O.W.E.R NOTES SBQ 24

- I. Smoking is associated with periodontitis.  
Plaque and sugar intake are associated with high caries risk.  
Patients drinks cola.  
There's no genetic predilection for caries risk.

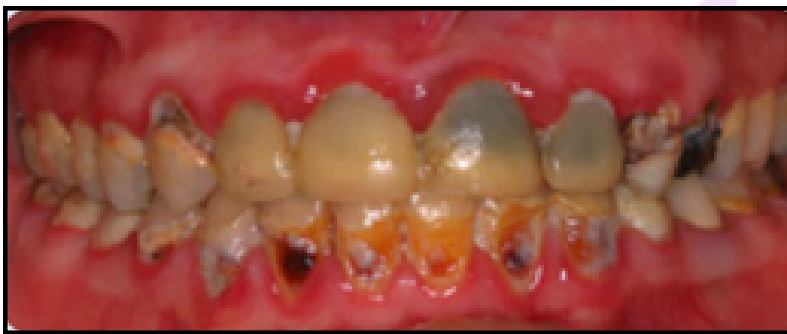# OPERATIVE

## SBQ 25

### **METHAMPHETAMINE USER CASE. QUIT ABOUT 6 MONTHS AGO**

A 20 YEAR OLD PATIENT WAS REFERRED TO YOU, ADMITTING HE WAS A METHAMPHETAMINE USER BUT HAD QUIT 6 MONTHS AGO. HE IS CONCERNED AND WOULD LIKE TO IMPROVE HIS ORAL HEALTH. PICTURE GIVEN: FULLY DENTATE PATIENT WITH PLAQUE ON ALL TEETH, GINGIVITIS, STAINS AND WHITE LESIONS ON CERVICAL SURFACES AS WELL AS TOOTH WEAR (ATTRITION/BRUXISM).

(SOMEWHAT SIMILAR PIC BUT HAD MORE CARIES CERVICALLY AND THAN IN THIS PIC AND PLAQUE)



I. What is the long term effect that he still would be having after quitting methamphetamine?

OR

What would be your (as a dentist) challenge to treat him?

- A. Obesity
- B. Paranoia
- C. Hypersomnia
- D. Hypoglycemia

II. Which local anesthetic agent can you use in this patient for an extraction?

- A. Local (dental) anesthesia with vasoconstrictor
- B. Local (dental) anesthesia without vasoconstrictor
- C. Local (dental) anesthesia double dose
- D. Local (dental) anesthesia reduced to half dose
- E. Topical local anesthesia (for some)

III. Where are the carious lesions usually found in these patients?

- A. Labial and buccal surfaces
- B. Incisal and buccal surfaces
- C. Cervical and approximal surfaces
- D. All tooth surfaces
- E. Occlusal and palatal surfaces



# OPERATIVE

## SBQ 25

### IV. What are the caries risk factors in this patient's case?

- A. Low frequency of dental visits
- B. Poor oral hygiene
- C. Long intoxication periods
- D. Consumption of sugary/carbonated drinks
- E. Lack of fluoride

### V. What are the other factors which caused caries other than poor oral hygiene and dry mouth?

- A. Low Frequency of dental visit
- B. Not using fluoride toothpaste
- C. Consumption of carbohydrate drinks
- D. Long intoxication period

## P.O.W.E.R NOTES SBQ 25

- I. The acute phase of MA withdrawal was characterised by increased sleeping and eating, a cluster of depression related symptoms and less severely, anxiety and craving related symptoms. Following the acute withdrawal phase most withdrawal symptoms remained stable and at low level for the remaining 2 weeks of abstinence.

Obesity and hypoglycaemia are not known withdrawal symptoms.

Paranoia and hypersomnia are known withdrawal symptoms.

**Paranoia-** *It's a rare mental health condition in which you believe that others are unfair, lying, or actively trying to harm you when there's no proof.*

**Hypersomnia-** *It's the inability to stay awake and alert during the day despite having more than an adequate amount of night-time sleep.*

**As a dentist paranoia is a challenge to treat him.**

The mental capacity to make consents, to understand information and to calmly take the treatment has been disturbed in paranoia.

- II. Methamphetamine smuggling just before the appointment would result in more systemic and more long-lasting effects. MA duration of action can be up to 24hrs. If the patient has used MA within last 24hrs the vasoconstrictor in LA could result in hypertension, MI, cardiovascular accidents.

In this case patient quit MA use 6months ago. Therefore, it's safe to use LA with vasoconstrictor.

# OPERATIVE

## P.O.W.E.R NOTES SBQ 25

- III. Cervical and the approximal surfaces are the carious lesions usually found in these patients. With MA users tooth decay will start at the gum line and eventually spread.

The dental effects of long-term methamphetamine use are often attributed to its effects on saliva. The reduction in saliva increases the likelihood of dental caries, enamel erosion, and periodontal disease.

A chronic dry mouth combined with high-sugar and carbonated drinks intake causes rampant caries that has a classical pattern known as "**Meth Mouth**".

- IV. Patient quit MA use 6months back. But this caries occurred when he was in MA use.

If dry mouth is given that would be the best option.

Second best answer is excessive consumption of carbonated drinks.

**Dry mouth** and **Craving for Sugar** are the side effects of methamphetamine use which leads to dental caries.

There's a significant association between MA use and sugar soda consumption. In addition, sugar soda consumption is associated with more dental problems among MA users.

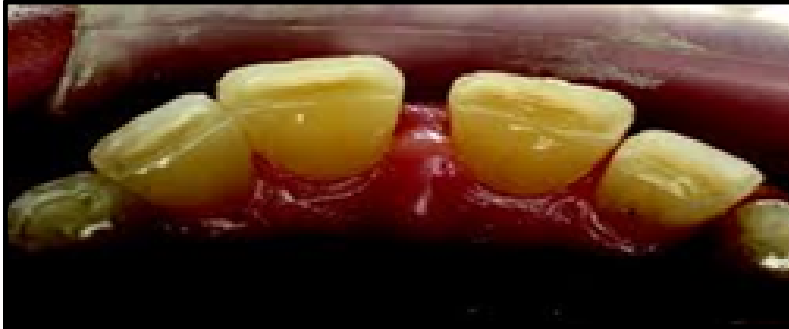MA users crave beverages high in sugar while they are high mainly because they experience dry mouth. The bacteria that fed on the sugars in the mouth will secrete acids which can lead to more tooth destruction.

- V. Explanation is the same as the above question.

# OPERATIVE

## SBQ 26

### EROSION CASE



#### I. How will you monitor the progression of erosion ?

- A. VDO decrease
- B. By taking impression with alginate and study models to compare
- C. Measuring using periodontal probe
- D. By Taking pictures

#### P.O.W.E.R NOTES SBQ 26

- I. It's difficult to monitor the VDO in each appointment. As it varies due to the posture, muscle fatigue and so many other reasons. So, it's difficult to measure and re-create the VDO at each and every appointment. Accurate physical evidence can be measured by taking impressions with alginate and study models. And it's 3D model. Picture are helpful but not as much as study model.

# OPERATIVE

## SBQ 27

### SECONDARY CARIES IN MOLAR WITH AMALGAM

A MALE PATIENT CAME TO YOUR CLINIC, CHIEF COMPLAINT WITH RESPECT TO TOOTH 27, PATIENT HAD PAIN (SECONDARY CARIES UNDER AMALGAM), HE WAS TAKING VITAMIN D SUPPLEMENTS, NO OTHER MEDICAL HISTORY WAS PRESENT. X-RAYS SHOWED ALMOST ALL MOLARS HAD AMALGAM, SEVERE WEAR AND ATTRITION WAS VISIBLE.

I. What will you ask the patient about/ regarding his concerns?

- A. Diabetes
- B. Frequency of sugar intake
- C. Psychological stress

### P.O.W.E.R NOTES SBQ 27

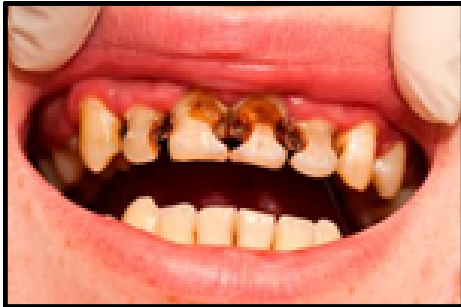
- I. His concern is pain due to secondary caries under amalgam. Therefore, pulpitis and secondary caries are his problems.  
Stress is a causative factor for attrition and severe wear.

# OPERATIVE

## SBQ 28

### DECAYED CANINE

PATIENT HAD GROSSLY DESTROYED CANINE. SHE FEELS SENSITIVITY TO COLD. WHAT IS DIFFICULT IN THIS CASE WITH RESPECT TO CANINE (CANINE HAD MESIAL CARIES EXTENDING BUCCALLY AND PALATALLY BUT HALF OF PALATAL AND FULL DISTAL TOOTH STRUCTURE WAS SOUND)



THE CARIES IN THIS PICTURE IS ON TOOTH 12 BUT IN THE EXAM IT WAS WITH CANINE, CANINE WAS SLIGHTLY OUT OF ARCH (DISTAL HALF OF PALATAL TOOTH STRUCTURE INTACT)

#### I. What difficulty will you face while restoring this tooth?

- A. Creating mesial contact with lateral incisor
- B. Canine guided occlusion.
- C. Achieving Marginal integrity

#### P.O.W.E.R NOTES SBQ 28

- I.
  - When the mesial part of the canine is missing due to proximal caries - this leads to difficulty in building up the proper contact with the lateral incisor. It's a one-point contact with the lateral incisor which is difficult to re-create.
  - When the canine is grossly destroyed- this leads to difficulty in maintaining the marginal integrity, so crown lengthening is required.
  - In the presence of palatal caries- its difficult to maintain canine guided occlusion as the lower teeth slides and glides on the palatal surface of the canine.

In this case there's mesial caries in the canine.

# OPERATIVE

## SBQ 29

(NEW)

A PATIENT COMES TO YOU, COMPOSITE RESTORATION WAS DONE FOR HIM 1 MONTH BACK . NOW AFTER A MONTH A PATIENT HAS COME BACK TO YOU AND SAYS THAT INITIALLY HE HAD SENSITIVITY AND PAIN FOR 2 TO 3 DAYS AFTER RESTORATION BUT SHE HAD NO PAIN AND SENSITIVITY SINCE THEN. NOW WHAT INVESTIGATION WILL YOU DO TODAY?

- A. Pulp sensitivity test
- B. Review after few weeks
- C. Remove restoration to see the reparative dentin formation
- D. Start root canal treatment
- E. Start pulpotomy
- F. Take IOPA

## P.O.W.E.R NOTES SBQ 29

- I. Immediate sensitivity in a composite restoration is due to polymerisation shrinkage. It's natural to have sensitivity for 2-3days. If sensitivity persists then it's due to the micro leakage. (due to the sever shrinkage) this will lead to reversible pulpitis.

So, review is important to check where it is still progressing or to where it has a marginal discrepancy. When you don't need to any investigation, review is the best thing to do.



# OPERATIVE

## SBQ 30

### CARIES ASSESSMENT

PATIENT HAS COME TO YOU FOR FOLLOW-UP AFTER 3 MONTHS OF FIRST VISIT .YOU DID A CLINICAL EXAMINATION AND THE PATIENT IS FULLY DENTATE, THIRD MOLARS HAVE ERUPTED.

#### I. What will be the next investigation to check for caries?

- A. Probe pit and fissures
- B. Opg
- C. Take bitewing

#### II. Which investigation/imaging to take?

- A. MRI
- B. Opg
- C. Cbct

### P.O.W.E.R NOTES SBQ 30

- I. We start doing the investigations with clinical examination. When you clinically find white spots, and proximal caries where you are not able to separate the contacts to check for the caries, then bi bitewing would be preferred.
- II. When no radiographs are done before, as the baseline investigation OPG is best among the given.

# ENDODONTICS

## SBQ 1

ONE X-RAY WAS GIVEN WHERE ON PREMOLAR RESTORATION WITH PINS WERE PRESENT. THERE WAS SOME HORIZONTAL FRACTURE NEAR THE MESIAL AREA ON THE X-RAY.(X-RAY WAS GIVEN AND COULD SEE THE HORIZONTAL FRACTURE AND ALSO IT HAD PINS AND LARGE RESTORATION) PATIENT COMPLAINS OF PAIN IN UPPER RIGHT AREA. PATIENT HAD SENSITIVITY, SINCE A LONG TIME BUT RECENTLY HAS PAIN WITH HOT FOODS. SHE SAYS A LARGE RESTORATION WAS DONE 10YRS AGO BY ANOTHER DENTIST AND NOW IT IS SO SORE THAT SHE CANNOT BITE ON IT.

### I. What test will you do to check pulp sensibility?

- A. Heat test
- B. Cold test with CO2 snow
- C. Cold test with ice stick
- D. Ethyl chloride spray
- E. Tooth sleuth ( not the exactly this name)

### II. You performed pulp testing and the pain lasted more than 10 mins. What is the pulpal riapical diagnosis?

- A. Acute apical periodontitis
- B. Acute apical abscess
- C. Chronic apical abscess
- D. Chronic apical periodontitis

### III. What is the cause of patient's complaint?

- A. Fracture along the mesio-distal
- B. Loss of marginal integrity/seal of the restoration
- C. Caries
- D. Tooth in traumatic bite
- E. Pin entered the pulp chamber

### IV. What decides the prognosis for this tooth?

- A. Amount of tooth structure left
- B. Possibility to put a post in one of the canals
- C. Restorability of the tooth
- D. Financial capacity of the patient

# ENDODONTICS

## P.O.W.E.R NOTES SBQ 1

### I. Sensibility Tests: Cold test, Heat test, EPT

Among these, cold test is the best.

Option (A):

Patient has pain with hot food therefore, this test should be done to confirm it.

Option (B), (C), (D):

All these 3 options are cold tests. Among these CO2 snow/dry ice is the best.

OPTION (E):

Tooth sloth is not a sensibility test.

### II. Sensitivity for hot/cold indicates pulpitis. Pain which last for more than 10mins is associated with irreversible pulpitis. The patient has pain on biting which means the inflammation has involved the PDL space. Therefore, the periapical condition is **acute apical periodontitis**.

If there's soft tissue involvement, then the answer would be **acute apical abscess**.

If there's a fistula with soft tissue involvement, then the answer would be **chronic apical abscess**.

When there's no abscess/no fistula but there's a periapical radiolucency, no pain then the answer would be chronic apical periodontitis.

For a diagnosis to be a abscess there should be soft tissue involvement or presence of fistula.

In the presence of soft tissue involvement

Acute periapical abscess  
(abscess+ pain+)

Chronic periapical abscess  
(fistula+ no/mild pain)

In the absence of soft tissue involvement

Acute apical periodontitis  
(pain+/no apical radiolucency)

Chronic apical periodontitis  
(pain may or may not/apical radiolucency)

# ENDODONTICS

## P.O.W.E.R NOTES SBQ 1

III.

RESTORATION WITH PINS



HORIZONTAL FRACTURE



FRACTURE LEAD TO ENTRANCE OF BACTERIA TO THE TOOTH



PULPITIS

IV. In case of RCT- the amount of the tooth structure left will decide the prognosis.  
In case of fracture- the restorability matters, if the crack is propagating below the CEJ or up to the furcation extraction may require. Therefore, the direction/orientation of the crack matters.

# ENDODONTICS

## SBQ 2

**A PATIENT HAD SEVERE PAIN 1-2 WEEKS AFTER THE RCT THAT SOME OTHER DENTIST DID. IOPA GIVEN. SHORT OBTURATION ON DISTAL CANAL OF LOWER MOLAR.**

---

**I. What is the reason for pain?**

- A. Bacteria left in the canal
- B. Short GP point
- C. Trauma from occlusion
- D. Leakage of irrigating material

**II. You are retreatting the tooth. What irrigation technique will you choose to safely irrigate?**

- A. Irrigate upto the apex to remove debris
- B. Static irrigation in apical region
- C. Positive pressure with plunger
- D. Bind the needle in apical one third (0.5 mm from apex)
- E. Side vented needle
- F. Irrigation via open ended needle at the apical third

**III. How will you obturate to prevent root fracture/ cracks in the root?**

- A. Lateral oblique movement of the spreader
- B. Pushing the spreader in apical direction away from walls of the roots
- C. Pre curve the spreader according to canal (Xray didn't show any curvature of roots or canals)
- D. Push the spreader against the walls
- E. Put the spreader 0.5 mm away from the anatomic apex

**IV. What will you check before final restoration?**

- A. Amount of remaining tooth structure
- B. Radiographic healing
- C. Biological width

# ENDODONTICS

## P.O.W.E.R NOTES SBQ 2

### I. Failure of RCT is see.

Short obturation alone will not give pain if the canal was cleaned thoroughly. Short obturation can give an idea that the BMP is not done well. And there is left remnant. Therefore, the bacteria left in the apical 1/3rd causing the pain.

### II. Side vented needle may offer safer irrigation than open ended needles in positive irrigation.

Negative pressure irrigation is superior to positive irrigation because it prevents the possibility of irrigant extrusion.

Endovac system uses the negative pressure to achieve safe irrigation of the apical canal.

Endovac is not given in the option, no negative pressure is given so answer is (E).

### III. Technique of obturation to prevent the root #/cracks in the root.

Pushing the spreader in apical direction away from the walls of the root.

#### **Reference:**

*Spreader is placed alongside the GP point and pushed apically with controlled force until it reaches the appropriate depth.*

*1mm from the end point of preparation.*

*The direction of force would be apically with no lateral rocking of the spreader to prevent root #.*

*In straight canals the spreader can be rotated at the same time as being pushed apically, this is contraindicated in curved canals.*

### IV. If these answers would have been there, then it's the best:

- **Restorability of the tooth**
- **Extension of the #/crack line**

Biological width is always consistent even in a healthy or in a tooth with periodontitis. So, no need to check BW. In case there's no proper ferrule crown lengthening should be done prior to placing a crown to avoid violence of BW.

# ENDODONTICS

## SBQ 3

**51 YEARS OLD COMPLAINS OF PAIN IN LOWER LEFT AREA, CAN'T BITE ON THE TOOTH 36 37, NO SENSITIVITY TO HOT LIQUIDS, MESIAL ROOT OF FIRST MOLAR LOOKS FUSED AND HAVE FILLINGS.**

---

### **I. How will you investigate?**

- A. Percussion
- B. Palpation
- C. Cold test
- D. Ept
- E. Hot test

### **II. Complication in doing RCT?**

- A. First molar
- B. Root resorption
- C. Tooth inclination
- D. Curved roots

### **III. You took an iopa, and see 36 has a deep caries almost reaching the pulpal floor and a lot of secondary dentine is formed reducing the level of pulp chamber floor. Which anatomic structure will help you determine the floor level so that you don't perforate it?**

- A. Cej
- B. Inclination of the tooth
- C. Mesiodistal width of tooth
- D. Buccolingual width of tooth



# ENDODONTICS

## P.O.W.E.R NOTES SBQ 3

- I. When a patient presents with pain and can't identify which tooth it is usually gives a provisional diagnosis of pulpitis as it's poorly localised. 2 teeth shows pain on biting reveals a early stage of PDL involvement.  
Patient doesn't have sensitivity to hot liquids therefore, cold test should be done as the sensibility test to identify the tooth.
- II. 1st check with the x-rays and pictures that are provided to you.  
Suppose you have all the findings,  
Root resorption is the biggest complication as it hampers the prognosis because apical seal is the predominant factor for success. If all were present, then the biggest challenge would be root resorption.  
2nd most difficult thing to handle is the curved roots as it's technique sensitive.  
3rd most difficult thing to handle is the tooth inclination as perforation can take place.
- III. CEJ is the most important anatomic land mark for determining the location of pulp chambers and the root canal orifices.

# ENDODONTICS

## SBQ 4

A PATIENT HAS PAIN ON BITING IN THE UPPER RIGHT AREA WHICH COMES ONLY SOMETIMES ON BITING ON SOME THINGS, NO OTHER COMPLAINT. RESTORATION WAS PLACED FEW WEEKS BACK. WANTS TO CHECK WHY IS IT HAPPENING. ACCESS OPENING PIC GIVEN LATER IN ONE OF THE QUESTIONS.

### I. How will you investigate?

- A. Percussion
- B. Palpation
- C. Sensibility
- D. CO2 test
- E. Ept
- F. Probing

### II. Clinical picture given of access opening. We can see multiple small cracks in the coronal portion not involving the pulp chamber (also it was mentioned in the question), sufficient tooth structure remaining. Question mentions no crack is going to the pulp chamber. What do you think will be the prognosis?

- A. Fair
- B. Excellent
- C. Poor
- D. Hopeless
- E. Good

### III. What is the complication in treating this tooth? (3 versions of iopa given). IOPA upper first molar normal roots normal inclination adjacent teeth present/ IOPA upper first molar severe inclination of the tooth /IOPA upper first molar resorption of half of root in one root

- A. Extreme inclination
- B. Rubber dam
- C. Open apex/ apical seal
- D. Root resorption
- E. The fact that it's a first molar

### IV. Which local anesthesia will you use for this tooth 16?

- A. Middle superior alveolar
- B. Infiltration buccally and palatally
- C. Greater palatine block
- D. Nasopalatine block

# ENDODONTICS

## P.O.W.E.R NOTES SBQ 4

- I. It's not the pain in the area but it's the pain on biting. Restoration was placed few weeks back so; the pain may be due to a high point. Percussion test should be done as pain on biting is present.
- II. Multiple cracks are seen so it can't be excellent.  
Sufficient tooth structure is remaining so it can be fair. Guarded prognosis.  
Poor and hopeless teeth need extraction.
- III. Answer get changed depending on the version.  
Version (A)- answer (E)  
Version (B)-answer (A) because extreme inclination will lead to perforation if not following the long axis of the tooth during access cavity preparation.  
Version (C) – answer (D) Root resorption is the biggest complication as it hampers the prognosis because apical seal is the predominant factor for success.
- IV. MSA is given to anesthetise the mesiobuccal root.  
Greater palatine alone will not work.  
Nasopalatine is not useful for 16.  
Infiltration both buccally and palatally will work.

# ENDODONTICS

## SBQ 5

**PATIENT HAD A CAVITY WHERE HE HAD SLIGHT PAIN A FEW WEEKS BEFORE BUT NOW IS OKAY, TOOTH IS TENDER TO PERCUSSION**

---

### **I. What investigation will you do to diagnose?**

- A. Cold test with CO2 snow
- B. Percussion
- C. Palpation
- D. Ept

### **II. What is pulp status?**

- A. Reversible pulpitis,
- B. Symptomatic irreversible pulpitis,
- C. Asymptomatic irreversible pulpitis
- D. Necrosis

### **III. What is periapical status?**

- A. Symptomatic apical periodontitis,
- B. Asymptomatic periapical periodontitis
- C. Acute periodontitis
- D. Chronic abscess

### **IV. What will be the treatment for the tooth?**

- A. RCT
- B. Filling
- C. Pulpotomy

### **V. What is the diagnosis?**

- A. Necrosis with acute apical periodontitis
- B. Necrosis with normal periapical tissue
- C. Necrosis with acute apical abscess
- D. Necrosis with chronic apical
- E. Periodontitis Necrosis with acute periodontitis

# ENDODONTICS

## P.O.W.E.R NOTES SBQ 5

- I. Patient had pain before but now there's no pain and but there's tenderness to percussion. Which means earlier there was a pulpal involvement but now it has progressed peri apically. Provisional diagnosis can be necrosis.  
As investigation percussion will not be helpful because it's already done according to the information give. Therefore, cold test can be done to check the vitality of the tooth.
- II. There's no pain involvement so it can't be pulpitis. So pulpal status would be necrosis.  
Symptomatic irreversible pulpitis will never turn into asymptomatic irreversible pulpitis. It can only involve the peri apically and cause necrosis.  
Asymptomatic irreversible pulpitis is pulp polyp.
- III. Pulpal condition has progressed peri apically. There's tenderness to percussion. So periapical condition is symptomatic apical periodontitis.
- IV. When both pulp chamber and radicular pulp are inflamed, RCT is the only treatment that can save the tooth. Restoration or pulpotomy won't be sufficient.
- V. According to the above explanations, the diagnosis is necrosis with acute apical periodontitis. It's combination of pulpal and periapical diagnosis.

# ENDODONTICS

## SBQ 6

### **PAIN ON BITING & ABSCESS CASE**

**PATIENT CAME WITH PAIN ON BITING. THERE WAS A PATIENT WITH ABSCESS. A 64-YEAR-OLD COMES TO YOUR CLINIC FOR AN EXTRACTION.**

**I. Which test would you perform to make a provisional diagnosis?**

- A. Cold test
- B. EPT
- C. Percussion test
- D. Probing

**II. You extracted her tooth but she is able to pay only 50 percent right now and couldn't pay the full amount. She calls you from home saying she is in pain after 24 hours. What will you do?**

- A. Don't treat till she pays the full amount
- B. Give her an appointment to come and see you in the clinic on emergency basis
- C. Ask her to pay the full amount first before doing any treatment
- D. Refer her to community clinic

**III. If you did not do the extraction for this patient the first time ( as she cant pay the full fee) what could have been the complication then?**

- A. Spreading infection ( it was given like ascending infection involving deep spaces)
- B. Abscess
- C. Tooth will continue to be carious.

**IV. After a few months she comes to you wanting an extraction of another tooth (infected tooth +no pain & wanting extraction). She has paid the full amount by now. But your area is now under ADA level-3 restrictions & is under the Hot Spot zone. How will you proceed? In the question it was mentioned that her X-ray was given (but there was no IOPA Attached) only the x-ray findings were written. Grossly carious lower first molar, caries extending to pulp with divergent roots and radiolucency around roots.**

- A. Use N95 mask and extract instead of surgical mask
- B. Do emergency access opening and expatriate the pulp to relieve her pain under a dental rubber dam and give temporary restoration.
- C. Refer to the hospital emergency dept.
- D. Refer to oral surgeon
- E. Prescribe Antibiotics.

# ENDODONTICS

## P.O.W.E.R NOTES SBQ 6

- I. In this case the patient has both pain on biting and abscess. Which means the pulpal condition has progressed peri apically and also, it's involving the soft tissue due to underlying infection. In the presence of the abscess sensibility test should be done to rule out necrosed pulp.  
If it's given only pain on biting, then you would have selected percussion test. Because only pain on biting can be due to restoration, high point, TFO, fracture/crack or food impaction.  
Both periodontal and periapical abscess have same clinical and radiographic features. Sensibility tests will be helpful to differentiate them. Periodontal abscess will give positive response to sensibility tests whereas periapical abscess will give negative response.
- II. According to TG any complication after extraction should be managed by the treating dentist.  
According to the professionalism cluster you can't deny taking care of her even though she paid half. So, the answer is B.
- III. Patient came with acute apical abscess with grossly decayed necrosed pulp on the 1st day.  
If the extraction is not performed on that day (A) could have happened. (B) and (C) are were already present at the time of arrival.



# ENDODONTICS

## SBQ 7

SCENARIO WHERE BOTH MOLARS 36 AND 37 WERE RCT TREATED, HAD RADIO LUCENCY NEAR THE BIFURCATION AND (TOOTH WASN'T BROKEN TILL GUM LEVEL. IT WAS GROSSLY CARIOUS BUT IN A RESTORABLE CONDITION). PREVIOUS DENTIST HAD DONE THE RCT AND THE PATIENT COMES TO YOU AFTER 1 YEAR. YOU TOOK AN IOPA. IN THE IOPA YOU CAN SEE SECONDARY CARIES WHICH HAVE REACHED THE BIFURCATION AND THE ROOTS ARE SHORT.

### I. How will you further investigate these teeth?

- A. Probing
- B. Sensibility
- C. Vitality test
- D. Percussion
- E. Mobility
- F. Use air from triplex syringe

### II. In the iopa you can see secondary caries which have reached the bifurcation or maybe it said roots and the roots are short. How will you manage?

- A. Extract
- B. Refer to endo for retreatment
- C. Crown lengthening
- D. Refer to prosthodontics
- E. Restoration with Resin Modified GIC

### III. Patient agrees to the treatment you suggested but he wants some time to think about the treatment options. So, for the meantime, how will you restore these temporarily? (i didn't have this question)

- A. Sealing with gic fuji vii
- B. Flowable composite
- C. Use preformed temp crowns as template
- D. Make him a temp crown temp crown with pro temp Composite strip crown

### IV. You inform the patient that this would have not happened if they timely got their final restorations done and that final restorations are very important. The patient said he was never told by the previous dentist about the crown and was upset that he was not informed. What would you advise?

- A. Offer to ask for his records from previous dentist after he signs record release form
- B. Ask him to talk to previous dentist and ask for the explanation
- C. Ask patient to complain about dentist
- D. Ask patient to take advice from Ahpra/ ADA
- E. Ask him to take to take legal advice

# ENDODONTICS

## SBQ 7

v. What will you ask the patient while taking history to know about the problem?

- A. Pain
- B. Swelling
- C. Since the time it broke
- D. How it broke

## P.O.W.E.R NOTES SBQ 7

- I. It's a RCT tooth so no need of doing the vitality/sensibility tests.  
There's no pain on biting to do the percussion test.  
Triplex syringe is not a test.  
Both probing and mobility are important, but clinical attachment loss is checked 1st and then mobility is checked. Probing is important to check the pockets, BOP, VRF.  
Can even do the cuspal loading to check the presence of any crack.
- II. It's a restorable tooth. Tooth doesn't have a crown so microleakage lead to secondary caries in bifurcation. Bicuspidation can be done and tooth can be treated as 2 separated teeth with 2 separate crowns. It's always good to refer if the tooth can be saved. If the treatment is beyond your expertise to handle then it's always good to refer. There's no emergency such as spread infection to address immediately.
- III. GIC fuji VII is flowable and can't use in this situation as it will not restore and protect the tooth from occlusal forces.  
Flowable composite will not save and protect the tooth from occlusal loads.  
Preformed temp crowns vs pro temp strip crown, pro temp strip crowns are the simplest and matching for tooth colour and used for permanent posterior.  
Preformed temp crowns will take more time to do adjustments as need to modify more for adaptation.  
Patient will get better marginal adaptation and operator chair side ease with pro temp strip crowns.
- IV. Don't get in between the situations where any complaints about the colleges and other dentists are present. Ethical management and the professionalism should be followed up. Since you don't have any access to the previous records and since you didn't go through their verbal discussion, tell the patient to ask from the previous dentist and clarify it with him/her. If still they are not happy then they by themselves can complain. Don't get involved in that. Don't advice the patient to take legal advice or follow AHPRA/ADA as the initial step.
- V. Pain is the greatest indicator of the RCT failure.

# ENDODONTICS

## SBQ 8

### PULPITIS CASE

---

- I. While removing the caries of a reversible pulpitis you realise that if you continue you could expose the pulp? What do you do?**
- A. Remove infected dentin and leave affected dentin and restore with a definitive restoration.
  - B. Similar option with temporary restoration
  - C. Restoration after complete removal of infected dentine and CAO<sub>2</sub>H plus Temporary Filling
  - D. Restoration after partial removal of infected dentine with CAO<sub>2</sub>H plus Temporary Filling
- II. While removing the caries, there was an exposure of the pulp. What would you do?**
- A. Partial Pulpotomy with Tricalcium silicate base
  - B. Pulpotomy with Tricalcium silicate.
  - C. Calcium Hydroxide
- III. How does composite restoration gets the resistance & retention to the tooth?**
- A. Preparing cavity walls with undercuts.
  - B. Slots & grooves
  - C. Enamel & Dentine bonding
  - D. Cavity preparation in relation to providing retentive features.
- IV. He has an injury on his forehead in which a part of skin peeled off and the blood was oozing. What kind of injury is it?**
- A. Abrasion
  - B. Bruising
  - C. Laceration
  - D. Puncture

# ENDODONTICS

## P.O.W.E.R NOTES SBQ 8

- I. Block off/cut off the bacteria from all the nutritional supply so the remaining bacteria will die. Seal is the deal. Pulp will heal. Keep observing.  
According to MID approach you can leave little amount of infected dentin.  
TF is now not recommended for IPC therefore, (C) and (D) are ruled out.
- II. Only partial pulpotomy is sufficient as it is a mild exposure and no further bleeding after the exposure.  
**MTA= calcium silicate**
- III. Composite restorations achieve resistance and retention through a combination of mechanical and chemical factors. Composites rely on bonding.

### CHEMICAL FACTORS

#### Bonding Agents:

- **Adhesive Systems:** Modern dental adhesives create a chemical bond between the tooth structure and the composite material. These systems involve a primer that penetrates into the etched surface and a bonding agent that chemically bonds to both the primer and the composite.

#### Hybrid Layer Formation:

- **Dentin Bonding:** The adhesive penetrates the demineralized dentin, forming a hybrid layer that consists of resin tags interlocked with the dentin matrix. This hybrid layer provides significant chemical and micro-mechanical retention.

- IV. Peeling and oozing of blood is associated with abrasion.

A skin abrasion is a superficial injury to the skin, usually caused by friction or scraping against a rough surface. Abrasions are often referred to as "scrapes" or "grazes" and typically do not penetrate deeper than the epidermis, the outermost layer of the skin.

# ENDODONTICS

## SBQ 9

**CASE OF RCT TREATED 46.IT WAS TREATED 2-3DAYS BACK & THE SEALER WAS INADEQUATELY PLACED. PATIENT HAD SEVERE PAIN. IOPA WAS ALSO GIVEN, IT WAS UNDERFILLED.**

### **I. Which are the diagnostic tests for this case?**

- A. Sensibility, palpation, percussion
- B. Selective cuspal cuspal loading test, Percussion, palpation, probing test
- C. Cuspal loading test
- D. Cuspsl loading test,probing test, sensibility test.

### **II. What is the reason for the pain?**

- A. Sealer material diffusing in to the bone
- B. Bacterial in periapical tissues
- C. Sealer binding insufficiently with dentine
- D. Underfilling of the canal

### **III. Why amalgam is better than composite?**

- A. Its marginal integration is much more reliable.
- B. Aesthetic reasons
- C. Retention form is better

### **IV. If there was a fracture in this RCT treated tooth, which diagnostic test would be most reliable?**

- A. Probing
- B. IOPA
- C. Sensibility testing
- D. Palpation

### **V. As the filling is short in apical third, What would be your next step in management?**

- A. Do immediate refilling
- B. Retrograde Sealer to be filled in this appointment
- C. To wait and observe until the signs arise.

# ENDODONTICS

## P.O.W.E.R NOTES SBQ 9

- I. Presence of pain after 2-3 days of a RCT is not normal. May indicate a flare up. Bacteria must have reached the periapical area and inflammation must be present.  
No point in doing sensibility tests in RCT teeth. So (A) and (D) are ruled out.  
To check for VRF/periapical infection probing, percussion, palpation and cuspal loading should be done.
- II. There may be underfilled canals with no pain. Because shaping and cleaning of canals have been done adequately up to the working length.  
If there is bacteria left over in the canal due to improper cleaning, that lead to pain.
- III. Amalgam has its corrosive property. Corrosive products will seal the margins. Therefore, its marginal integration is much more reliable.  
In composite there's polymerisation shrinkage and this will lead to micro leakage.
- IV. In case of VRF, IOPA will be helpful as there will be "J-shaped" radiolucency, but this may not always be recognised in the radiograph due to overlapping. So (B) is not always reliable.  
Probing with a narrow deep pocket is the most reliable technique for the VRF.  
Sensibility test is not helpful in RCT teeth.
- V. Retrograde is the periapical surgery. It's only done in the presence of a post. Because it's difficult to remove the post.  
There's pain and underlying infection going on, so wait and observe is not a good thing to do.  
Orthograde Rx/ immediate re-RCT is needed.

# ENDODONTICS

## SBQ 10

**PATIENT COMPLAINS OF SENSITIVITY ON COLD DRINKS, IT OCCURS ONLY WHEN HE DRINKS COLD DRINKS, YOU TAKE AN IOPA AND SEE DEEP CARIES.**

---

**I. What is the diagnosis based on the symptoms?**

- A. Reversible pulpitis
- B. Irreversible pulpitis
- C. Necrosis

**II. What is the reason for the pain?**

- A. From outside to inside incrementally
- B. Remove all at once

**III. (IOPA given) Lining present small amount of filling dislodged. What will the patient feel?**

- A. Sensitivity on cold
- B. Sensitivity on sweet
- C. No sensitivity
- D. Sens on hot
- E. Pain

**IV. While removing caries you realise that if you remove any further soft dentine, pulp will be exposed. What should be the management? (still caries is remaining, incomplete excavation then what will be the management?)**

- A. DPC
- B. Pulpotomy
- C. RCT
- D. IPC and direct restoration extraction



# ENDODONTICS

## P.O.W.E.R NOTES SBQ 10

- I. Because it's not spontaneous pain and comes only for cold drinks. And it's not mentioned how long it lasts. So, It's reversible pulpitis.
- II. Removing the infected dentin 1st and then removing the affected dentin, can leave the affected dentin behind. So should remove outside to inside incrementally.
- III. Liner is only present on the floor of the cavity. But the walls of the cavity is exposed to the oral environment. So dentinal tubules are protected only on the floor of the cavity. So, the patient may feel sensitivity. The most common sign is sensitivity to cold.
- IV. Still caries is remaining, incomplete excavation. Always best to do conservative Rx. You can leave the little amount of infected and proceed ahead with IPC and you can review the tooth. Tooth should be symptom free to leave infected pulp behind.

# ENDODONTICS

## SBQ 11

**A 10 WEEKS PREGNANT WOMAN CAME WITH DEEP CARIES AND SOME SYMPTOMS, CARIES ALMOST REACHING THE PULP, WILL NEED RCT. RCT WAS DONE AND PULP EXTIRPATED, TEMPORARY DRESSING GIVEN.**

**I. Which pregnancy period is safe for elective dental treatment?**

- A. Between 14 to 28 weeks
- B. Between 32 onwards
- C. Between 24 weeks to 9 weeks
- D. Between 10 weeks to 30 weeks

**II. Same patient didn't complete the treatment and came at 32 weeks in pain. Patient is 32 weeks pregnant. Which medication is safe to give?**

- A. Naproxen
- B. Celecoxib
- C. Paracetamol
- D. Ibuprofen

**III. Now she (32 weeks) comes for her regular scaling appointment. On the dental chair in a reclined position she started feeling dizziness, sweating, nausea. What is the most likely cause?**

- A. Vaso-vagal Syncope
- B. Supine hypotensive syndrome
- C. Pre-eclampsia

**IV. She came after giving birth and is breastfeeding. Which painkiller will you prescribe her?**

- A. Paracetamol
- B. Naproxen
- C. Celecoxib
- D. Oxycontin

**V. She asked about the future child and how to clean the child's teeth?**

- A. Brush with 500-550 ppm tooth paste pea sized at 18 months
- B. At 24 months brush with 1000 ppm smear of it
- C. Clean with 500-550 ppm FL toothpaste at 6 months of age

# ENDODONTICS

## P.O.W.E.R NOTES SBQ 11

- I. For elective dental treatment best is → 2nd trimester  
Emergency Rx can be done → 1st and 2nd trimester  
High chance of preterm labour → 3rd trimester
- II. Up to 32 weeks it's safe to give NSAIDs. Ibuprofen is the safest among NSAIDs. But after 32 weeks you can't give NSAIDs, only PCM is recommended.
- III. Supine hypotensive syndrome (SHS) is a condition that can occur when a pregnant woman lies flat on her back, particularly in the later stages of pregnancy. The weight of the uterus compresses the inferior vena cava, a large vein that carries blood from the lower part of the body to the heart. This compression can reduce blood flow to the heart, resulting in decreased cardiac output and a drop in blood pressure.

This can cause symptoms such as:

- Dizziness or lightheadedness
- Nausea
- Sweating
- Pallor (paleness)
- Rapid heartbeat (tachycardia)

In severe cases, it can lead to fainting (syncope). To prevent SHS, it is generally recommended that pregnant women, especially in the second and third trimesters, avoid lying flat on their backs and instead sleep or rest on their side, preferably the left side. This position helps to improve blood flow and reduce the risk of symptoms associated with SHS.

Pre-eclampsia is a pregnancy complication characterized by high blood pressure and signs of damage to other organs, most often the liver and kidneys. It typically occurs after 20 weeks of pregnancy in women whose blood pressure had previously been normal. If untreated, pre-eclampsia can lead to serious, even fatal, complications for both the mother and the baby.

- IV. If NSAID is required in breast feeding patient diclofenac or ibuprofen is preferred. In breast feeding only diclofenac, ibuprofen and PCM is preferred.  
(reference TG page no. 286 table 28)
- IV. Fluoride toothpaste is recommended after 18 months of age. From 18 months to 6 yrs of age, it's preferred to use 500-550ppm fluoridated toothpaste.  
(reference TG page no. 67 table 7)

# ENDODONTICS

## SBQ 12

MR. GOYAL 30 YEARS OLD, CAME FOR TREATMENT. WANTS BLEACHING FOR HIS TEETH. ALSO HAS PAIN WITH 36, ALSO HAS RESTORATION, WANTS TO GET 36 TREATED AND HAS EROSION, DRINKS A LOT OF COCA COLA, NEVER VISITED A DENTIST IN 3-5 YEARS, POOR ORAL HYGIENE.

**I. What will be the etiology of the lesions?**

- A. Coca cola
- B. Poor oral hygiene

**II. IOPA given and you diagnose that it is irreversible pulpitis. You want to do RCT. But the patient refuses Rubber Dam. What will you do? (IOPA given)**

- A. Refer to endo
- B. Give alternate options like extraction
- C. Respect his decision make him sign a waiver
- D. Refuse to treat

**III. Wants to get bleaching done regardless. What will you tell him?**

- A. Need to stabilize his condition first
- B. Do tooth whitening, and make her sign waiver

# ENDODONTICS

## P.O.W.E.R NOTES SBQ 12

- I. In the question it's mentioned about erosive lesions. The history denotes that the patient drinks a lot of acidic drinks (coca cola). Acidic drinks lead to erosion.
- II. RCT must not be performed without a rubber dam.

- Because there's a high risk that the patient may aspirate files without a rubber dam.
- It helps to maintain a sterile area without saliva and blood contamination.
- It helps to prevent sodium hypochlorite accidents.

*\*If a patient refuses rubber dam you can offer these options:*

- Refer to an endodontist if the tooth is restorable.
- Give alternate options like extraction if the tooth is not restorable.

*\*You must see the picture and the IOPA to decide the restorability of the tooth.*

- III. Before performing a bleaching treatment, you must stabilise his conditions.

If erosions are present you need to control it with habit intervention and then temporisation.

If caries is detected, you must temporise them.

Because bleaching may lead to further damage if the dentine is exposed to the oral cavity and lead to more sensitivity and teeth may undergo with pulpitis.

After 2 weeks time of bleaching we can proceed ahead with the permanent restorations. This waiting time period is to stabilize the colour after a bleaching treatment.

# ENDODONTICS

## SBQ 13

PHOTOS OF 25,26,27 GIVEN. THE PATIENT HAD RCT TREATED DONE ONE YEAR AGO. AND 26, 27 WERE BROKEN DOWN, NOW THE PATIENT WANTED TO RESTORE THEM. 26 MESIAL SUBGINGIVAL CAVITY EXTENSION, 27 MESIAL, PALATAL AND DISTAL SUBGINGIVAL CAVITY.

**I. What will you ask the patient while taking history to know about the problem?**

- A. Whether patient have pain
- B. How the teeth were broken
- C. Time since teeth broke
- D. Swelling

**II. Which of the following investigations will help with a diagnosis?**

- A. Probing
- B. Percussion
- C. Cold test
- D. X-RAY

**III. How do you restore 26 and 27 (the difficulty in this question for me is whether 26 needed crown lengthening, as only half of mesial side for 26 cavity is subgingival)**

- A. Core and crown for 26, Crown lengthening for 27
- B. Crown lengthening for 26 and 27
- C. Crown lengthening and post and core wrt 26,27 (i think this was the answer the tooth was having insufficient ferrule)
- D. Extraction

**IV. Previous dentist did not say about crown to patient after RCT**

- A. Advise patient to talk to previous dentist
- B. You request the previous dentist to transfer records of the patient
- C. You ask the patient to report the previous dentist to AHPRA

**V. Patient wants to think about the proposed treatment plan and come back, how would you temporize them?**

- A. Do a temporary crown with a prefabricated crown temp.
- B. GIC
- C. Flowable composite
- D. Do temporary with luxatemp

# ENDODONTICS

## P.O.W.E.R NOTES SBQ 13

- I. Presence of pain and swelling are signs of RCT failure. So among the given pain is the most important symptom to ask about.
- II. It's an RCT tooth so no need of doing the vitality/sensibility tests.  
Both probing and percussion are important, but XRAY is the most important investigation among all. Because with the help of the XRAY you would be able to see the extending of the obturation whether it's short or over obturated, is there any peri apical radiolucency or root resorption, is there any missed canal. So, with the help of the XRAY we can get a clear idea about RCT tooth.
- III. In this case,  
26-mesial wall has sub gingival cavity  
27-mesial, distal, palatal have subgingival cavity  
**When to give an onlay?**  
*When the tooth structure/the walls are all in contact in 360 degree up to the middle 3rd or occlusally.*  
**When to give core build up + crown?**  
*When 1 or more walls are broken below the middle 3rd and proper ferrule is available.*  
**When to do crown lengthening+ core build up+ crown?**  
*When 1 or more walls are broken up to the CEJ or below CEJ crown lengthening is done to create a ferrule to retain the crown.*  
Both 26 and 27 has subgingival cavities so need crown lengthening + post and core.
- IV. Don't get in between the situations where any complaints about the colleges and other dentists are present. Ethical management and the professionalism should be followed up. Since you don't have any access to the previous records and since you didn't go through their verbal discussion, tell the patient to ask from the previous dentist and clarify it with him/her. If still they are not happy then they by themselves can complain. Don't get involved in that. Don't advice the patient to take legal advice or follow AHPRA/ADA as the initial step.
- V. When comparing pre-fabricated temporary crowns and Luxatemp, there are several factors to consider, including material, application, durability, aesthetics, and cost.

### PRE-FABRICATED TEMPORARY CROWNS

#### **Material:**

- Typically made from materials like polycarbonate, composite resin, or acrylic.



# ENDODONTICS

## P.O.W.E.R NOTES SBQ 13

### Application:

- These crowns are pre-made in various sizes and shapes to fit different teeth.
- They can be adjusted and trimmed chairside to fit the patient's tooth.
- They are cemented onto the prepared tooth using temporary cement.

### Durability:

- Generally strong enough to last several weeks to a few months, depending on the material and patient's oral habits.

### Aesthetics:

- Pre-fabricated crowns might not perfectly match the patient's natural teeth in terms of color and shape.
- They are often less aesthetic compared to custom-made options.

### Cost:

- Usually less expensive than custom-made temporary crowns, including those made from Luxatemp.

## LUXATEMP

### Material:

- Luxatemp is a bisacrylic composite resin specifically designed for temporary crowns and bridges.

### Application:

- It is custom-made directly in the dental office. The dentist creates a mold or uses a matrix to shape the Luxatemp material around the prepared tooth.
- This allows for a more precise fit and better aesthetics.

### Durability:

- Luxatemp is known for its strength and durability, providing a reliable temporary solution.
- It can withstand normal biting and chewing forces.

### Aesthetics:

- Luxatemp provides a more natural-looking appearance compared to pre-fabricated crowns.
- It can be color-matched to the patient's natural teeth, offering better aesthetics.

### Cost:

- Typically more expensive than pre-fabricated crowns due to the custom fabrication process and higher material cost.

# ENDODONTICS

## P.O.W.E.R NOTES SBQ 13

### SUMMARY

#### Pre-Fabricated Temporary Crowns:

- Pros: *Quick application, lower cost.*
- Cons: *May not fit as well, less aesthetic.*

#### Luxatemp:

- Pros: *Custom fit, better aesthetics, durable.*
- Cons: *Higher cost, more time-consuming application.*

The choice between the two often depends on the specific needs of the patient, the dentist's preference, and budget considerations.

# ENDODONTICS

## SBQ 14

**QUESTION ON REVERSIBLE PULPITIS. FURTHER REMOVAL OF CARIES WILL CAUSE PULPAL EXPOSURE. WHAT WILL YOU DO? (MATURE TEETH)**

- A. Remove all from the margins, keep infected in the center and place GIC.
- B. REMOVE ALL infected dentin and give permanent restoration.
- C. Remove step wise, put temporary, recall in 3-6 months
- D. Remove infected, if exposed, do partial pulpotomy, fast setting caoh, GIC and composite.
- E. Remove infected, if exposed, do partial pulpotomy, calcium silicate and composite

## P.O.W.E.R NOTES SBQ 14

- I. According to MID article;  
GIC achieves chemical adhesion to tooth structure via an ion exchange mechanism, creating a stable acid resistance ion exchange layer interface, preventing micro leakage and bacterial contamination of pulp.

Leaving small amount of infected dentin in a cavity does not seem to result in caries progression, pulpitis or pulp death, provided the overlying restoration has a perfect seal.

Need to remove caries from the margins and can leave in the centre.  
Now TF is not used in IPC. So, option (C) is ruled out.

Removing "all infected" dentin can lead to pulpal exposure. So option (B) is ruled out.

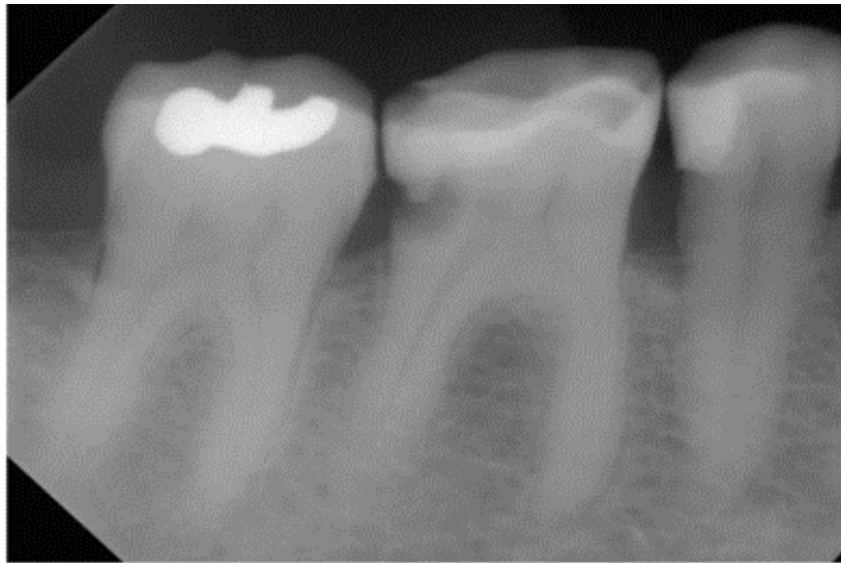Both option (D) AND (E) are correct. In (D) sandwich technique is used. In (E) MTA is used, which is superior to Ca(OH)<sub>2</sub>. So option (E) is better.

But among all option (A) is the best according to MID guidelines.

# ENDODONTICS

## SBQ 15

A YOUNG ADULT FEMALE, IOPA GIVEN (EXACT SAME PICTURE OF XRAY AS IN THE ADC SAMPLE QUESTION IN WEBSITE, LESION GIVEN ON DISTAL SIDE). PATIENT HAD PAIN ON HER LOWER LEFT HAND SIDE WHILE EATING COLD AND SWEET FOODS AND LITTLE DISCOMFORT IN THAT AREA, SPECIALLY PATIENT COMPLAINS ABOUT BAD TASTE COMING FROM LEFT POSTERIOR LOWER SITE. MEDICALLY FIT AND WELL.



I. Other than proximal cavitation seen in iopa, what else do you find significant connected to the chief complaint in x-ray?

- A. Periapical radiolucency on mesial root
- B. Mesial canal of 36 obliterated
- C. Root fracture
- D. Open contacts on mesial and distal of 36

II. What is the most appropriate material to fill this tooth?

- A. Resin composite
- B. Gic
- C. Amalgam because it has more marginal integrity
- D. Rmgic

III. What is the most appropriate test to confirm the diagnosis for this case?

- A. Percussion
- B. Hot GP point
- C. Co2 spray
- D. Probing test

# ENDODONTICS

## P.O.W.E.R NOTES SBQ 15

- I. Chief complaints are associated with the food impaction and pulpitis. Option (A), (B), (C) are not related. But option (D), open contacts lead to food impaction.
- II. Resin composites are best in class 2 restorations.  
GIC is not a permanent restoration.  
RMGIC is best in root caries. Root caries needs more chemical bonding than physical bonding.  
Amalgam is not preferred nowadays as it's aesthetically inferior though it has more marginal integrity. Composites binds well with enamel and dentin; good retention is seen with composites.
- III. It's a pulpitis case, so sensibility test will be helpful. Among sensibility test cold test is the best.

# ENDODONTICS

## SBQ 16

MAN WITH RCT TREATED TEETH A FEW MONTHS AGO WITH BARELY ANY CROWN STRUCTURE REMAINING (36 AND 36) WITH THE CORONAL PART SEALED WITH A PERMANENT FILLING MATERIAL. PATIENT HAS RETURNED AFTER SOME TIME TO HAVE CROWNS PUT. NO PAIN IN THE LAST FEW WEEKS.

### I. What will you ask the patient regarding these teeth?

- A. History of pain
- B. Medical history
- C. Dental history

### II. What is the most appropriate material to fill this tooth?

- A. Pulp sensibility
- B. IOPA
- C. OPG
- D. Percussion
- E. Probing

### III. What is the best way to restore these two teeth (not enough coronal structure at all)?

- A. Crown lengthening, Post and core build up and PFM
- B. Post and core and crown
- C. Pins and restoration

# ENDODONTICS

## P.O.W.E.R NOTES SBQ 16

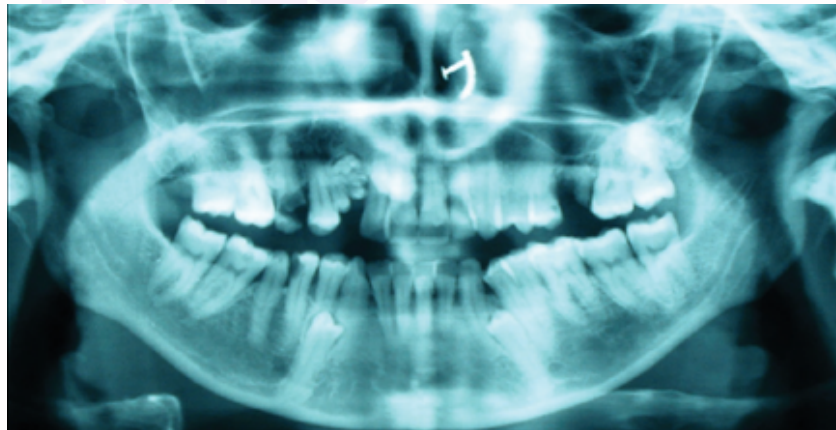
- I. Because if there was pain few months back and then subsided eventually, that means it require re-RCT. So, history of pain is more important.
- II. In a RCT tooth IOPA is the best investigation as it gives the status of RCT. Percussion and probing comes next. Pulp sensibility test is not useful in RCT tooth. OPG will not give a clear image compared to IOPA.
- III. If there's not enough coronal structure but if you still want to save the tooth, then must perform crown lengthening with post and core. Post will replace only the missing wall. Inadequate ferrule will be gained with crown lengthening. 1.5-2mm ferrule is needed in 360degree to prevent the dislodgment of the crown.



# ENDODONTICS

## SBQ 17

PATIENT NEEDED RCT ON AN UPPER 1ST MOLAR, (IOPA GIVEN, PATIENT'S MOLAR HAD ROOTS THAT WERE BENT IN THE MIDDLE THIRD PORTION, MIDDLE THIRD OF ROOTS WERE ALSO IMPOSED ON THE MAXILLARY SINUS) WHAT COMPLICATION WOULD MOST LIKELY TO OCCUR DURING RCT? (CALCIFIED CHAMBER AND THIN CANALS IOPA GIVEN)



- A. Pneumatization of sinus
- B. Difficulty in negotiating the canal
- C. Difficult to put rubber dam

## P.O.W.E.R NOTES SBQ 17

- I. In the presence of calcified chambers and thin canals in a maxillary molar tooth it's difficult to negotiate the canals. Maxillary molar tooth has difficult canal anatomy.

With the help of temporary endo build-up, it's not difficult to put a rubber dam.

# ENDODONTICS

## SBQ 18

**14 YEAR OLD COMES WITH MOTHER WITH HISTORY OF PULPITIS AND SYMPTOMS WERE OF IRREVERSIBLE PULPITIS AND SHE IS AGAINST X-RAY RADIATIONS WHAT WILL YOU SAY TO MOTHER.**

- A. Defer the treatment as we can't do treatment without x ray
- B. Give alternate options like extraction
- C. Do rct without x ray
- D. Educate patient on radiation

## P.O.W.E.R NOTES SBQ 18

- I. This is a professionalism question. For both extraction and RCT, IOPA is needed. And can't differ the treatment as the patient is in pain. So, you must educate the patient about the radiation.

# ENDODONTICS

## SBQ 19

DANNY IS A LABOURER, HE IS 30 YEARS OLD, WORKING ON A CONSTRUCTION SITE NEAR YOUR CLINIC, HE HAS PAIN IN TOOTH 11, HE SMOKES 5-10 CIGARETTES WHAT SYMPTOMS INDICATE HE HAS REVERSIBLE PULPITIS A MAN TOOTH PAIN EVERY NOW AND THEN WHEN DRINKING COLD WATER. HE LOVES DRINKING COLA AND HE CONSUMES LOT OF COKE ON HIS WORK

**I. You made the diagnosis of reversible pulpitis, how did you decide to make this as a diagnosis?**

- A. Initial onset of pain
- B. Transient nature of pain
- C. Sensitivity to cold

**II. You did the cold test n found that pulp is vital. How will u restore this tooth?**

- A. Give GIC lining and composite
- B. Calcium hydroxide lining and composite

**III. You found that patient had one more carious lesion on the distal of 45. How will u restore it?**

- A. Using sectional wedge system n incremental packing of composite

# ENDODONTICS

## P.O.W.E.R NOTES SBQ 19

- I. The transient nature of pain is only present in reversible pulpitis. Onset of pain on hot and cold is present in both reversible and irreversible pulpitis.
- II. In case of leaving infected dentin and restoring then we prefer sandwich technique (Ca(OH)<sub>2</sub> + GIC + composite) or GIC + composite. Because GIC can be used to line the infected dentin. But when Ca(OH)<sub>2</sub> and MTA are given these calcifying agents are also preferred choices.

### Reference:

*GIC achieves chemically adhesion to tooth structure via an ion exchange mechanism, creating a stable acid resistant "ion exchange layer" interface, preventing microleakage and bacterial contamination of pulp. Fluoride, calcium, phosphate, strontium ions are released from GIC and taken up by adjacent enamel and dentin, resulting in hyper mineralisation of sound and demineralised enamel and inhibition of caries progression.*

*But according to the MID article Ca(OH)<sub>2</sub> and MTA best in pulp therapy. Which means in reversible pulpitis these materials work best. Even among them MTA is superior.*

This is a case of reversible pulpitis so need to do IPC as there is no exposure yet. If both (A) and (B) options are given, we will be choosing option (B) as the pulp is still vital and you want to create reparative dentin as well.

If all the 3 options are given; Ca(OH)<sub>2</sub>, MTA and GIC. MTA is the best, Ca(OH)<sub>2</sub> is the 2nd best and last will be GIC. Setting Ca(OH)<sub>2</sub> will not interfere with the composite bonding.

### III. IN CLASS II RESTORATIONS:

Successful contacts are achieved with the "**sectional matrix system**" with small increments.

When the word "**system**" is given it denotes the combination of tofflemire, band and wedge. All the 3 items should be present.

### Reference:

*It is widely accepted that proximal contacts are very important features in healthy teeth. A lack of proximal contacts contributes to food impaction, secondary caries, tooth movement and periodontal complications. These studies supported use of the sectional matrix with separating ring in order to achieve tight contacts. the sectional matrix with separation ring seems to be the most reliable device for restoring proximal contacts in posterior teeth.*

# ENDODONTICS

## SBQ 20

### POST AND CORE CASE:

PICTURE WAS GIVEN. PT COMPLAINS OF PAIN IRT 11/21. WHILE ON EXAMINATION CROWS IRT 11/21 FELL OFF. MES LOT OF COKE ON HIS WORK

- 
- I. There were retraction cords around 11/21. There was pus draining sinus above 11. What will be the best investigation to do? (At this point they didn't give the radiograph.) Radiograph was given in the second question.
- A. GP inserting to the sinus and taking a radiograph
  - B. Percussion
  - C. Palpation
  - D. Probing
- II. After taking the radiograph you notice that it was rc treated. What can be the reason for the failed rct before 10 years, photo give 2 showing 11 post incomplete obturation, 21 Short rct in 11 was in x-ray
- A. Horizontal root fracture
  - B. Failure on RCT
  - C. Post too long
  - D. Post too angulated
  - E. Short obturation
- III. What will be essential for the success of the endodontic retreatment?
- A. Length of Post
  - B. Type of filing
  - C. Obturation method
  - D. Coronal seal

# ENDODONTICS

## P.O.W.E.R NOTES SBQ 20

- I. You can insert the GP to identify the source of infection specially when the pus draining sinus is lying between the 2 central incisors. So, you can find out from the where the infection is coming from.  
It's draining sinus so there's no pain, so percussion is not helpful. You will perform palpation and probing as well but option (A) comes first.
- II. There is short incomplete obturation so there's lack of periapical seal. If that was given as choice that would be the best answer. Lack of apical seal or left-over bacteria in the apical 3rd these two would be the best answers. Therefore option (E) is the best answer among the given.
- III. Length of the post will determine whether the tooth will sustain the restoration or not or whether it will fracture or not.  
Obturation method doesn't matter but the quality of the obturation matters.  
Coronal seal; as per the sequence of Walton picture the most important factor for the success is coronal seal. That's why immediately after a RCT permanent restoration is provided.

# ENDODONTICS

## SBQ 21

### **BEFORE AND AFTER IOPA WITH RESPECT TO LOWER MOLAR:**

A PATIENT CAME WITH PAIN ON THE LOWER LEFT HAND SIDE AND COMPLAINED OF A "FOUL SMELL" FROM THE LOWER LEFT PART OF THE MOUTH. 12 MONTHS AGO YOU HAD PLACED GIC CALCIUM HYDROXIDE WITH TEMPORARY FILLING, WHICH IS DISLODGED PARTLY NOW. RCT ATTEMPTED PULP, WAS DEBRIDED, AND HAD ASKED THE PATIENT TO COME BACK, BUT SHE DIDN'T DO IT BECAUSE SHE SAID SHE WAS TRAVELING. CHRONIC PERIAPICAL ABSCESS WAS PRESENT.

(OBSERVATIONS) TWO IOPA RADIOGRAPHS WERE GIVEN SIDE BY SIDE (PREVIOUS NO RADIO LUCENCY IN FURCATION, CAO H FILLING WAS VISIBLE AND NEW X - RAY HAD RADIO LUCENCY IN FURCATION)

OLD: RL IMAGE ON CORONAL ASPECT. COULD SEE HORIZONTAL BONE LOSS 1-2 MM INTERDENTALLY BETWEEN PREMOLAR AND MOLAR ALTHOUGH WAS VERY LESS

NEW: FURCATION INVOLVEMENT.

DIFFERENT IMAGE ON OCCLUSAL, AS IF THE RESTORATION HAD BEEN CHANGED AND THERE WAS A SLIGHT GAP WITH THE 37.

I. Upon examination, you can see that some caries has developed on the tooth. What is the reason for the change with respect to bone density that you can see in the radiograph?

- A. Aggressive periodontists
- B. Poor oral hygiene
- C. Chronic pulpitis
- D. Localized chronic infection
- E. Food impaction

II. Apart from x-ray, which step will you do next to arrive at the diagnosis?

- A. Periodontal probing
- B. Bite and release test
- C. Pulp sensibility test
- D. Palpation
- E. Transillumination



# ENDODONTICS

## P.O.W.E.R NOTES SBQ 21

- I. It's acute periapical re infection. Acute periodontal infection coming from an endodontic cause. Endo-perio lesion. In endodontics acute and chronic is symptomatic depiction.

Patient comes with pain so the presentation can't be chronic and it's an acute condition.

In the localised area long standing chronic infection is established. That is the reasons behind the pain present right now.

Change in the bone is seen the area of furcation. Food impaction can lead to vertical bone loss/infrabony pockets, not the furcation involvement, option (E) is ruled out.

Aggressive periodontitis is a destructive disease characterized by the following: the involvement of multiple teeth with a distinctive pattern of periodontal tissue loss; a high rate of disease progression; an early age of onset; and the absence of systemic diseases. So, option (A) is ruled out.

Pulp is already debrided so it can't be pulpitis. So, option (C) is ruled out.

- II. Pain in RCT tooth may be due to flare-up, cracked tooth or VRF.

In VRF pain is coming from the PDL. In cracked tooth, involvement of furcation is a chronic periapical condition. When pain on biting is present mostly it can be due to cracked tooth. From option A and B, option B is superior.

Both B and E options are for cracked tooth. B option is best as u can immediately identify with a tooth sloth due to the wedging effect and separation of the fragments. If B is not given E is the 2nd best, as the transillumination can reveal the cracks.

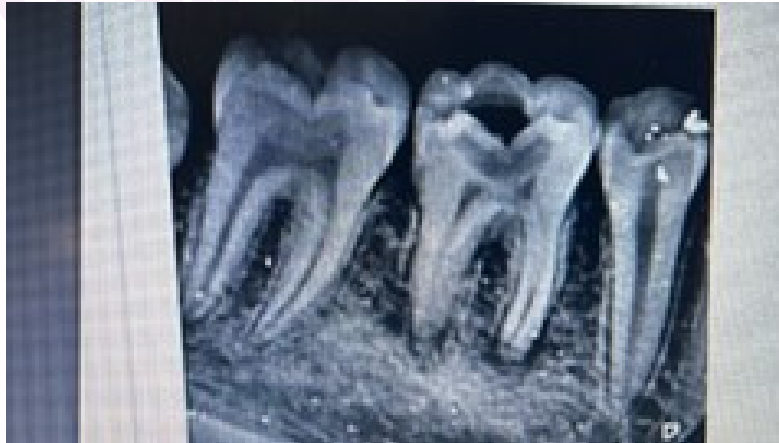Sensibility tests are not useful in RCT treated teeth.

Probing is done to identify VRF.

# ENDODONTICS

## SBQ 22

**JAMES MISSED AN APPOINTMENT AND PRESENTED TO YOU AFTER A FEW WEEKS WITH IRREVERSIBLE PULPITIS; SPONTANEOUS AND SEVERE PAIN.**



- 
- I. What is the best treatment you can do for James on this day?**
- A. Pulp extirpation
  - B. Emergency pulpotomy
  - C. Partial pulpotomy
  - D. Leader mix dressing after removal of 2 mm of pulp tissues
  - E. Zinc oxide dressing directly on pulp to relieve pain
- II. In a case where deep caries are present, if you remove the caries further then it would lead to pulp exposure. What will be the appropriate management for this case?**
- A. Spot application of caoh2 and composite restoration
  - B. Spot application of corticosteroid and antibiotic application
  - C. Caoh2 layer and composite restoration
  - D. Direct pulp capping and spot application of corticosteroid and antibiotic layer

# ENDODONTICS

## P.O.W.E.R NOTES SBQ 22

- I. Minimal emergency Rx for irreversible pulpitis → emergency pulpotomy  
Best Rx for irreversible pulpitis → pulp extirpation
- II. Corticosteroids are not used in IPC. So, options (B) and (D) are ruled out.  
Spot application is not adequate. So, option (A) is ruled out.  
Ca(OH)<sub>2</sub> and MTA are used as pulp capping agents.

# ENDODONTICS

## SBQ 23

### PULPITIS

PATIENT COMPLAINS OF ON AND OFF PAIN, COMPLAINING OF PAIN TO COLD FOR A FEW SECONDS. ON EXAMINATION SHE HAS A DECAY IN 46. YOU PERFORM COLD ICE STICK TEST FOR HER.

- 
- I. Which test are you going to perform next to confirm your diagnosis? (no x-ray option was given)
- A. Hot water test
  - B. Percussion
  - C. Probing
  - D. Palpation
- II. Patients complain of pain upon having anything cold, but subsides within a few seconds. Upon discussion with the patient you diagnose this as reversible pulpitis. How will you confirm your diagnosis of reversible pulpitis
- A. Transient of pain
  - B. X-ray
  - C. Cold stimulus

# ENDODONTICS

## P.O.W.E.R NOTES SBQ 23

- I. Heat test is done in the presence of pain to hot. So, option (A) is ruled out. Cold ice stick test is already performed for this patient. So, percussion test is done to see the periapical involvement. By percussion you can confirm whether there is a periapical involvement or not. If it's a sharp severe sort of pain, then the patient may not allow to do the percussion test. Probing will be helpful in RCT tooth to check the VRF.
- II. The transient nature of pain is only present in reversible pulpitis. Onset of pain on hot and cold is present in both reversible and irreversible pulpitis.  
X-RAY changes won't be seen in both reversible/irreversible pulpitis.

# ENDODONTICS

## SBQ 24

A HOLISTIC PATIENT COMES TO YOUR CLINIC WITH A CHIEF COMPLAINT OF PAIN. SHE DID NOT BELIEVE IN MAINSTREAM DENTISTRY. YOU CONDUCT THE EXAMINATION AND AFTER CONFIRMING DIAGNOSIS OF IRREVERSIBLE PULPITIS, YOU INFORM HER THAT RCT COULD BE REQUIRED SO YOU NEED TO TAKE A SMALL DOSE RADIOGRAPH BUT THE PATIENT REFUSES RADIOGRAPH.

### I. What will you do in this situation?

- A. Continue treatment without x-ray
- B. Extract without x-ray
- C. Use apex locator to do rct
- D. Explain patient that we can't continue treatment without x-ray

### II. You need to apply fluoride as a preventive regime but she refuses because she believes fluoride is toxic to health. How will you manage this patient?

- A. Respect patient's belief
- B. Explain evidence based positive aspects of fluoride
- C. Advice essential oil
- D. Discuss with her holistic doctor

# ENDODONTICS

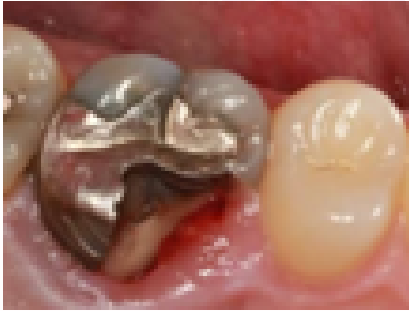## P.O.W.E.R NOTES SBQ 24

- I. Without an X-RAY it's difficult to perform RCT or extraction. So, you need to explain the patient about the importance of X-RAY.
- II. As a healthcare provider you must educate the patient about the importance of fluoride. Show evidenced based factors in related to fluoride.

# ENDODONTICS

## SBQ 25

A PATIENT GOT ROOT CANAL TREATMENT DONE WITH TOOTH 36. HE GOT THE TREATMENT DONE OVERSEAS BUT DIDN'T GET A CROWN FOR THE SAME.



I. Now the patient has come to you, root canal treatment is satisfactory. By looking at the clinical picture, What defines the treatment plan.

- A. Fracture line depth
- B. 360 degree ferrule
- C. Restorability

II. What investigation will you perform?

- A. Probing
- B. X-ray
- C. Sensitivity

III. What can be long term treatment in this case?

- A. PFM
- B. Crown lengthening, post & core and crown
- C. Post and core
- D. Extraction



# ENDODONTICS

## P.O.W.E.R NOTES SBQ 25

- I. Tooth seem to be restorable. Even though the tooth has 360degree ferrule but if the tooth has a fracture, then it can progress to root, then extraction is indicated. Therefor the direction of the crack/fracture matters when it's present. The direction/orientation of the crack/fracture determines the prognosis of the tooth.
- II. When we suspect a crack/VRF then the best test to diagnose is the X-RAY and second best is the probing. With the help of the X-RAY you would be able to appreciate the fractured fragments, how much the tooth is broken down.
- III. Suppose that the fracture is only up to the CEJ and not progressed up to the root, then you can still save this tooth. Even the fracture has progressed sub gingivally (fracture remains within the confines), still you can save the tooth by doing crown lengthening + post and core+ crown. But even crown lengthening has its limits, only up 1-2mm bone can be removed in crown lengthening, if the fracture is progressing more deeper than that then extraction is indicated. There's also a limit in sacrificing the supporting bone. You should not disrupt the crown: root ratio and the supporting bone.

Based on the picture/X-RAY the answer may get changed. It can be either B or D.

- III. You can't start doing re treatment or extraction when there's absence of signs and symptoms. Instead you must ask the patient when the treatment was done. As it will give you the estimate of whether this a long-standing radiolucency or not. As we usually wait for 1year for a long-standing radiolucency to get it healed and resolved. The radiolucency must be even before the tooth was RC treated. You can't talk to the previous dentist. So (D) is not the option as there can be language problems, time zone problems. According to ADA guideline you should not call doctors to confirm it. Best thig to do is to get the previous records. Then you can get to know on the day of the RCT whether the radiolucency was present or not. Because this could have also been a new radiolucency as well.

**REFERENCE:** *EMERGENCY OVERSEAS DENTALTREATMENT article, travelers should request a written report including radiographs on any emergency dental treatment received overseas to be passed on to their dentist on return from abroad.* (so, the traveler requests not the dentist, then you must manage based on your capacity)

Persistent radiographical changes present in the absence of signs and symptoms may require re treatment. If it's only few months, you can wait and observe. If the radiolucency still presents even after 1yr from RCT then re treatment is required.

If there's an option where asking the patient to request for the previous records and X-RAY, this would be best as you can get a clear idea about the tooth.

# ENDODONTICS

## SBQ 26

A 20 YEAR OLD BOY GOT RCT DONE OVERSEAS A FEW MONTHS BACK. NOW, THE PATIENT HAS COME TO YOU TO GET A CROWN FOR THE SAME TOOTH AND HAS NO SYMPTOMS, YOU JUST FIGURED OUT ON X-RAY RADIO LUCENCY AT APEX OF TOOTH 27. WHAT CAN YOU DO IN THE PATIENT'S BEST INTEREST?

- A. Retreat
- B. Extraction
- C. Ask when the treatment was done
- D. Talk to the previous dentist

# ENDODONTICS

## P.O.W.E.R NOTES SBQ 26

I.

II.

III.

# PROSTHO

## SBQ 1

PATIENT WHO HAS AN UPPER COMPLETE EDENTULOUS ARCH AND LOWER FEW TEETH, HE DOESN'T HAVE UPPER TEETH. AND HAS AN UPPER DENTURE. SAYS DENTURE ROCKING ALONG THE MIDLINE ON FUNCTION AND IS NOT RETENTIVE. 36 AND 46 MISSING AND 37 AND 47 HAVE TILTED IN ITS PLACE. DENTURE WAS DEFICIENT ON BORDER EXTENSIONS. (IN MY STATION IT ONLY SAID DEFICIENT DENTURE, "BORDER EXTENSION" PART WAS NOT THERE) PATIENT COMES AFTER 2-3 WEEKS AND IS NOT SATISFIED WITH DENTURE.

**I. Dentist took an impression of lower arch 10 weeks ago. What did it help him with?**

- A. Making custom tray
- B. To check the skeletal relationship maxilla and mandible
- C. To help with teeth setting and analyse the occlusion
- D. Check centric occlusion and centric relation (this option was not there in my station)

**II. The denture is rocking along the midline, what is the most likely reason?**

- A. Centric relation and centric occlusion not coinciding
- B. Interferences on lateral excursion/ not in laterally balanced occlusion Using
- C. Pressure indicating paste
- D. Pressure on Anterior incisors leading to tipping/ incorrect
- E. Improper curve of spee

**III. Why is denture not retentive? What will you check for that?**

- A. Denture insufficient on Peripheries
- B. Teeth are placed on the centre of the ridge
- C. Lack of soft tissue undercuts on upper ridge
- D. Deficient post dam area

**IV. You did all adjustments multiple visits for this patient and yet she is not happy with the denture. She has paid half and says won't pay till she is happy. What will you do?**

- A. Refer to a prosthodontist and pay her full refund
- B. Reline the denture for free
- C. Make brand new upper denture for free
- D. Refer to your known colleague who is an expert at dentures
- E. Do rebasing for free.

**V. What do you desire when setting teeth?**

- A. Bilaterally balanced occlusion
- B. Group function
- C. Canine Guidance
- D. Vertically balanced 2 dimensional occlusion

# PROSTHO

## P.O.W.E.R NOTES SBQ 1

Upper complete denture and few lower teeth signifies combination syndrome. In combination syndrome some teeth may be supra erupted and there may be excessive bone resorption in the opposed arch. So, it's difficult to bring teeth in occlusion and fabricate dentures.

There is denture rocking /dislodgment. Dislodgement happens either because of **lack of retention** or because of the **occlusal interference**.

If the denture is only **rocking in function means, there's no lack of retention**. Because lack of retention leads to rock the denture even not in function/at the rest mode.

If the **denture rocks in both function and rest, then it's due to lack of retention**.

There may be,

- an error with the impression
- tissue surface of the denture might be having the problem
- deficient post dam area
- flabby ridge
- denture insufficient on the periphery

So, **rocking in the function** is associated with occlusal interference and not associated with the periphery of the denture or the denture base.

- I. Lower impression is still needed to establish the occlusion. Lower arch impression is still needed when you are creating a denture for the upper arch to set the teeth and analyse occlusion. When lower teeth are present, lower teeth will act as a guide rather than the standard of the teeth setting.

It will also help to create a custom tray when you take the primary impression. It will also help to reconfirm the jaw relation and establish it on the articulator and check for the various relationships. But the most important factor that the mandibular impression will play in teeth setting.

The Skeletal relation of the maxilla and mandible is established either with the help of the jaw relation in the mouth. (centric relation, VD, horizontal relationship.)

# PROSTHO

- II. In edentulous patients we must create bilaterally balanced occlusion. Which means when working side teeth are in contact, even in non-working side of teeth also should come in contact. So that the non-working side doesn't tip. When anterior meet then the posteriors should also meet. So, it doesn't tip posteriorly. When posterior meet then the anterior should also meet. So, the anterior doesn't tip.

The denture doesn't rock anterior-posteriorly. If so the reason behind it is due to the centric occlusion is not coinciding with the centric relation. Because centric relation and centric occlusion is in the antero-posterior plane. So (A) is ruled out. Pressure indicating paste is easily ruled out as it's not an indicator. It might be needed to check where the problem is.

Pressure on the anterior teeth will lead to tip the posteriors. So, option (D) is ruled out.

Improper curve of spee - when the patient tries to protrude the mandible if the denture rocks posteriorly that's is because there's not enough curve of spee given. So the posteriors don't come in contact in protrusion.

Denture rocking can be of 2 types

1. Antero-posterior rocking
2. Lateral rocking (rocking along the midline)

Antero-posterior rocking happens:

- When centric occlusion and centric relation are not in contact
- Pressure on the anterior incisors leading to tipping
- Improper curve of spee

Lateral rocking (rocking along the midline):

- Interference on the lateral excursion

- III. There's an interference on the lateral excursion, but still you need to check the denture base. You should not only rely on soft tissues for retention. So (C) is ruled out.

Teeth placed on the centre of the ridges may lead to uneven forces on the ridges and uneven resorption. It's more important in distribution of forces and preservation of alveolar ridge. So, option (B) is ruled out.

Primary source of retention comes from denture extension and denture periphery. So, the answer should be (A) or (D). but (A) is superior to (D) because post dam is one of the peripheries.

# PROSTHO

IV. Even referral is a part of your treatment. You should not waste patient's time and your time. Should not lead the patient to frustration. So, refer to the prosthodontist and refund the money. As patient has wasted time and multiple visits for an incomplete work. Combination syndrome is out of scope for a general dentist.

Rebasing and rebasing the denture will not change the occlusion.

V. (B) and (C) are for the dentate patients. Bilaterally balance occlusion for the edentulous patients.

# PROSTHO

## SBQ 2

MALE PATIENT COMES TO GET HIS TREATMENT DONE AS PART OF WORK COMPENSATION COVER BECAUSE HE SLIPPED WHILE DOING DUTY ON WORK. HE HAS SEEN ANOTHER DENTIST TO MAKE AN INSURANCE CLAIM. CLINICAL PHOTO SHOWS PHOTO OF UPPER AND LOWER ANTERIORS, 12 NORMAL, REST OF DENTITION SEEM TO HAVE ATTRITION AND CHIPPED. HE WANTS YOU TO HAVE A LOOK. PATIENT SAYS MY TEETH CHIPPED OFF AND MY LOWER DENTURE GOT BROKEN AS A RESULT OF FALLING. YOU EXAMINE.

MEDICAL HISTORY WAS GIVEN (NOT SURE EITHER STRESS OR SOME HISTORY OF BRUXISM WAS THERE TOO) ALSO WANTS TO KNOW ABOUT BLEACHING HIS TEETH. (MENTIONED KEYWORDS CHIPPED AND BROKEN DOWN) YOU EXAMINE HIM AND REALIZE THAT MOST OF HIS DENTAL CONDITION IS NOT A RESULT OF INJURY. HIS LOWER FLEXIBLE ACRYLIC DENTURE IS BROKEN, THE OTHER DENTIST MADE A CLAIM FOR THE PATIENT SO HE ALSO GETS MONEY TO REPAIR HIS OTHER TEETH. (PICTURE OF THE DENTURES PROVIDED)

### I. What would be the ideal treatment for him?

- A. Repair the flexible denture
- B. New cobalt chrome RPD
- C. Make him a new acrylic denture Implant supported removable denture Implant
- D. Supported bridge

### II. Even though his dental condition is not a result of injury, another dentist is willing to cover it all under his work cover so that the company can pay and the patient can get a larger compensation for his dental treatment. He shows you a slip in which this is written. How do you handle that claim for the insurance in the situation?

- A. Do the same what the other dentist did to avoid reputation damage
- B. Report the dentist to Ada
- C. Report the dentist to Ahpra
- D. Contact the other dentist and inquire about the whole thing
- E. Report to work cover Australia
- F. Refuse to cover the work in insurance bill which was not due to the fall.

### III. The same patient was also interested in bleaching. But according to your findings and diagnosis, his dentition needs a lot of work to be done and he is not a suitable candidate for the above mentioned treatment because of current dental health. What advice will you give to the patient?

- A. Discuss with the patient that other treatment needs to be done before we proceed with bleaching.
- B. Refer to prosthodontist
- C. Go ahead with the treatment
- D. Refuse to do treatment



# PROSTHO

## IV. What should be the management of his worn down dentition?

- A. Refer to prosthodontist
- B. Add composites build up on anterior and oral rehabilitation
- C. Give him ceramic crowns
- D. Give him ceramic veneer

## V. Patient complains of sensitivity. What test would you conduct for your treatment?

- A. Probing
- B. IOPA
- C. Pulp sensitivity
- D. Percussion

### P.O.W.E.R NOTES SBQ 2

- I. For bruxers cobalt chrome denture is ideal compared to acrylic or flexible dentures to withstand the occlusal forces. Repairing a flexible denture is quite difficult and due to heavy bruxing forces it will be difficult for it to withstand forces. Denture implant supported bridge will be expensive.
- II. We don't know whether the provided document is legit or not. And, you don't need to contact the other dentist to know about this. You don't have to follow the same procedure what another dentist is doing. Follow the ethics.  
So, answer is (F).
- III. According to your findings and diagnosis the patient needs to get many dental treatments. Therefore, he's not a suitable candidate for the bleaching treatment because of the current dental health. Dentinal tubules should be sealed, and other required restorations should be completed as bleaching can lead to necrosis of the exposed teeth. So best option is (A).
- IV. Worn down dentition may require reorganised/confirmatory approach. And he wears an RPD. Now there's an opportunity to build up the vertical dimensions and build a new RPD and do full mouth rehabilitation. So, it's a complex situation to handle. It's good to refer complex cases (full mouth rehabilitation, implant placement, combination syndrome, crown lengthening) to the specialist.
- V. In case of sensitivity, it's always advised to use pulp sensibility test to identify the tooth and to check for the pulp vitality. Pulp sensibility test is an important test to perform before doing an RCT or before giving crowns.

# PROSTHO

## SBQ 3

**ANOTHER QUESTION WAS THE PATIENT THAT I THINK HAD COMBINATION SYNDROME AND WE ARE GOING TO CONSTRUCT A LOWER CHROME COBALT CLASS I PARTIAL DENTURE AND WAS ASKED IF:(POSTERIOIRS MISSING ON BOTH SIDES, PICTURE OF THE RIDGE GIVEN)**

### **I. What classification is this?**

- A. Kennedy Class I mucosa and tooth supported
- B. Kennedy class I mucosa supported
- C. Kennedy class ii mucosa and tooth supported
- D. Kennedy class ii mucosa supported

### **II. What type occlusion will u prefer in combination syndrome patient?**

- A. Bilaterally balanced occlusion
- B. Group function
- C. Canine guided
- D. Mutually protected occlusion

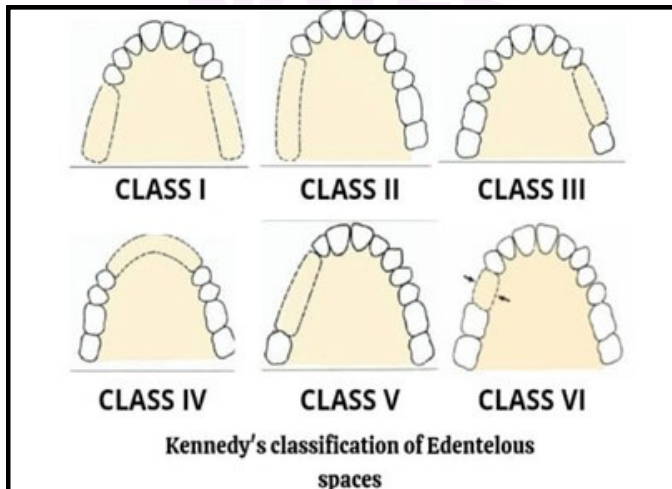
### **III. Overdenture case: what will be the advantage of overdenture over conventional complete dentures? What will you advise regarding the patient's perspective for aesthetic and functional purpose?**

- A. Preservation of alveolar ridge
- B. Patient compliance
- C. Patience psychological rescue of not losing teeth
- D. Maintain vdo

# PROSTHO

## P.O.W.E.R NOTES SBQ 3

- I. No RPD is completely mucosa supported because we use clasps for the abutments for the support. So, its tooth mucosa supported. CD are the completely mucosa supported. It's a class I Kennedy's situation as it's bilaterally distal extension.



- II. In combination syndrome maxilla is completely edentulous, in completely edentulous cases always bilateral balanced occlusion is given. Bilaterally balanced occlusion is a method of retention in function in edentulous cases. C, D, E options are used in replacing 1 or 2 teeth in case of FPD.
- III. Overdentures have several advantages over conventional complete dentures, primarily due to the retention of some natural teeth or the use of dental implants.

Here are some key advantages:

- Improved Retention and Stability
- Preservation of Bone
- Enhanced Chewing Efficiency
- Improved Comfort
- Better Aesthetics
- Proprioception
- Psychological Benefits

Among all preservation of alveolar ridge is the most important biological benefit.

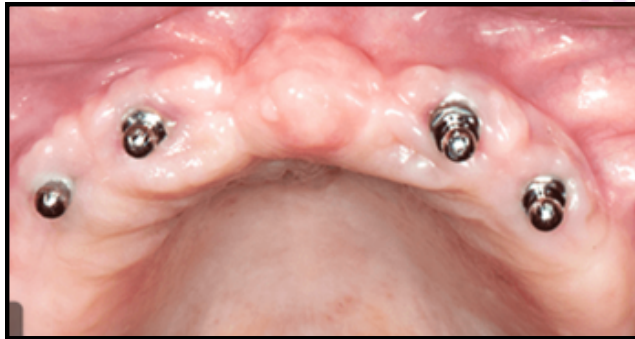# PROSTHO

## SBQ 4

**OVERDENTURE CASE. A 65 YEAR OLD FEMALE WHO IS NEW TO YOUR PRACTICE CAME BECAUSE SHE IS HAVING SOME DISCOMFORT WITH HER TOOTH RETAINED UPPER DENTURE. SHE IS OTHERWISE FIT AND WELL YOU HAVE CHECKED THE SOFT TISSUES AND DENTURES, UPPER DENTURE LOOKS GOOD WHILE IN REST.**

**I. Upper denture gets loose while in function, what is the likely cause?**

- A. There is flabby tissue on the tuberosity
- B. Problem in the occlusion check and re do it
- C. Compromised retained tooth



**II. Case where you were going to extract tooth 41. After IAN block injection, long buccal nerve block was also given using correct technique and LA quantity, the patient complains he can still feel pain around the area. How will you complement anesthesia?**

- A. Do another IAN injection on the LHS
- B. Do a mental nerve block
- C. Inject LA locally to 41 buccal and lingual

**III. Before you attempt extraction, what area is most important to check for numbness?**

- A. Half lips and tip of the tongue
- B. Lower lip and tongue
- C. Gingiva around the 41
- D. Tongue and floor of the mouth
- E. Does not cross the midline

# PROSTHO

## P.O.W.E.R NOTES SBQ 3

- I. Loose denture- either because of **lack of retention** or because of the **occlusal interference**.

If the denture is only **loose in function** means, there's **no lack of retention**. Because lack of retention leads to loose denture even not in function/at the rest mode.

If the **denture is loose in both function and rest**, then it's due to **lack of retention**. There may be,

- **an error with the impression**
- **tissue surface of the denture might be having the problem**
- **deficient post dam area**
- **flabby ridge**
- **denture insufficient on the periphery**

So, **loose denture in the function** is associated with **occlusal interference** and not associated with the periphery of the denture or the denture base.

- II. After giving all the anaesthesia (IAN, long buccal) if still the patient has pain, you should not repeat the same, instead you should give infiltration or intra-ligamentary anaesthesia (supplemental anaesthesia). Most effective supplemental anaesthesia is intra-ligamentary. Infiltration is drawn by a superficial vascularity. Into the PDL is far quicker. PDL intraligamentary is the best answer. That option is not given. So, among the given option (C) is the best.
- III. Lips and tongue will be anaesthetised 1st and gingiva get anaesthetised at last. So, you must wait until the gingiva get anaesthetised. You can't simply proceed extraction even though the lip and tongue are numb.

# PROSTHO

## SBQ 5

### ON PORCELAIN #MMF

ON EXAMINATION YOU FIND THE OBVIOUS SIGNS OF BRUXISM. WHAT IS YOUR MANAGEMENT, IF YOU WANT TO RETREAT THE RESTORATION AND DO NOT WANT THIS PROBLEM TO PROGRESS. CANINE WAS INCLUDED IN THE FPD GIVEN IN THE EXAM.

- A. Construct occlusal splint
- B. Give more favorable group function occlusion
- C. Give veneers
- D. Alter the bite to "canine protected" occlusion.

### P.O.W.E.R NOTES SBQ 5

- I. Canine guided/ canine protected occlusion will give more load on canines. So to prevent the load on the canine you will not give canine guided occlusion. Instead you give group function occlusion.

# PROSTHO

## SBQ 6

**WHAT IS MOST IMPORTANT RADIOLOGICAL CHARACTERISTIC OF CBCT/OPG (ONLY IN FEW CENTERS) IMAGING FOR IMPLANT?**

- A. Accuracy in linear measurement
- B. Superimposition of anatomic structures
- C. Breadth of the image
- D. High resolution

### P.O.W.E.R NOTES SBQ 6

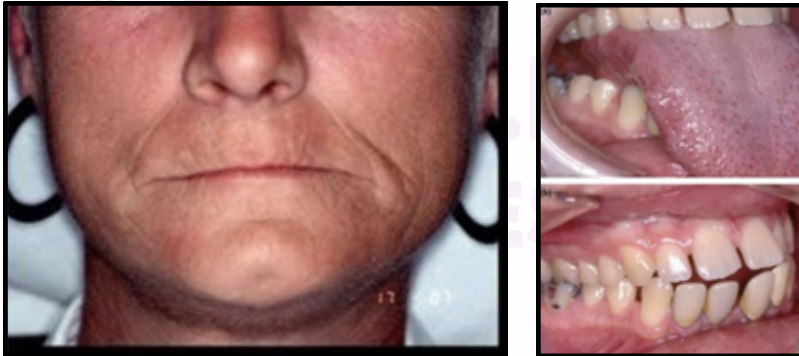- I. Breadth of the image and high resolution get covered under accuracy in linear measurement. Accuracy in linear measurements is one of the critical advantages of Cone Beam Computed Tomography (CBCT), particularly in dental and maxillofacial applications

#### CLINICAL APPLICATIONS:

- In dental implantology, accurate linear measurements are crucial for assessing the height, width, and density of the alveolar bone.
- In orthodontics, precise measurements are required for evaluating tooth positions, root alignment, and planning corrective procedures.
- In maxillofacial surgery, accurate measurements are essential for pre-surgical planning and postoperative assessment.

# PROSTHO

## SBQ 7



**DID NOT GET THIS PICTURE IN MY EXAM, PICTURE WAS DIFFERENT. QUESTION ALSO GAVE A SECTION (PT RIGHT POST) VIEW OF THE OPG. PHOTO WAS SIMILAR.**  
**ON THE OPG NO RESORPTION OR ANY COMPLICATIONS COULD BE SEEN.**

**I. You see a major complicating factor with constructing dentures in this patient. What do you think can cause aesthetic problems by looking at the photo? No major problems seen on clinical pic.**

- A. Tight Lower Lip
- B. Reverse smile line
- C. Prominent Mentalis
- D. Decreased VDO

**II. What group of muscles will have an effect on making an impression?**

- A. Orbicularis muscle
- B. Mentalis muscle
- C. Geniohyoid

**III. You are going to make a denture. What additional information is needed?**

- A. Photo and opg provide adequate information
- B. Ask the lab tech to do a occlusal analysis of the master cast
- C. An articulated study cast on semi -adjustable articulator for occlusal analysis
- D. Clinical assessment

**IV. How can you prolong setting time for Alginate imp without affecting its physical properties?**

- A. Add more powder than water
- B. Add more water then powder
- C. Decrease the water temperature
- D. Decrease spatulation speed

**V. Patient got burns after taking impressions which one material give burning.**

- A. Polyvinyl Siloxane compound material
- B. Alginate
- C. Zinc oxide eugenol



# PROSTHO

## P.O.W.E.R NOTES SBQ 7

- I. Lower lip seems to be tight and reverse smile line is seen. Though reduced VDO gives aesthetic problems, it is not challenging as it can be corrected. Prominent mentalis is challenging. It can give inverted/ protruded lip appearance. Even though you do changes in the denture you can't correct this. Prominent mentalis can lead to excessive protrusion of the lower lip.
- II. Mentalis muscle helps in tightening the labial vestibule and the labial vestibule is surrounded by the mentalis muscle.  
In case of hyperactive mentalis muscle situation, the lower lip seems to be very tight and the labial vestibular depth is uneven due to the excessive muscle force. If you try to get the impression in the hyperactive muscle situation, you won't be able to record the full extent of the vestibular depth. We need to relax the patient and make sure that the lower lip is loose while we are making the impression and border moulding as it goes deep into the labial vestibule. That's where the full retention comes from.
- III. Photos and OPG will not provide adequate information. Still you are at the information gathering stage so master casts and articulated study casts are not made yet. So, after photographs and OPG, clinical assessment is more important.
- IV. Anytime you control the water: powder ratio, it affects the physical property. So, option (A) and (B) are ruled out. Decreasing spatulation speed will lead to an incomplete mix/ non homogenous mixture and can lead to bubble formation and various discrepancy. Using cold water will be helpful in increasing the setting time.
- V. Option (A) and (B) are safe materials but eugenol causes mild irritation in certain patients.

# PROSTHO

## SBQ 8

### REGARDING RPD WHERE THEY SAID RPI IS A CHOICE OF CLASP

---

**I. Question was: how is given the indirect retention in this RPI system?**

- A. Distal occlusal rest on nearest abutment
- B. Mesial occlusal rest
- C. Lingual plate minor connector
- D. Reciprocal arm
- E. Mesial proximal plate

**II. In that same question it was asked that premolar 44 is used for clasp; it is periodontally weak gingival recession with class 2 mobility but still can be used . So what would be the preferred clasp which is less traumatic and more aesthetic?**

- A. Cast clasp suprabulge with  $\frac{1}{3}$  retentive area below the survey line
- B. Cast clasp infrabulge
- C. Wrought clasp with suprabulge
- D. Wrought clasp with infrabulge

# PROSTHO

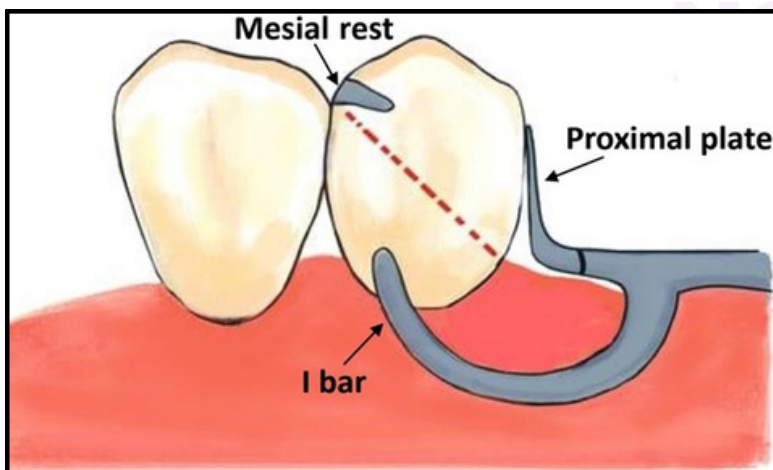
## P.O.W.E.R NOTES SBQ 8

### I. **RPI system**-Rest/ Proximal plate/ I-Bar

It consists of a mesial rest (R), proximal plate (P), and I-bar retentive arm (I). The proximal plate and mesial rest act as a reciprocating element to prevent lingual tooth migration as the I-bar moves over the tooth. It doesn't have a reciprocal arm.

Indirect retention comes from the **rest component**, either from the auxiliary rest or the mesial rest. That is part of the clasp assembly. Auxiliary rest is placed perpendicular to the most distal fulcrum line on the anterior teeth or on the rest of the part of the clasp.

**Proximal plate** is a component along with the I-bar and it act as the direct retention. It's also for the adaptation. Proximal plate act as a guiding area which guides the RPD into place. And it braces the tooth on the proximal area, that would be either for the guiding or for the direct retention.



### I. In a periodontally compromised tooth which clasp would be preferred?

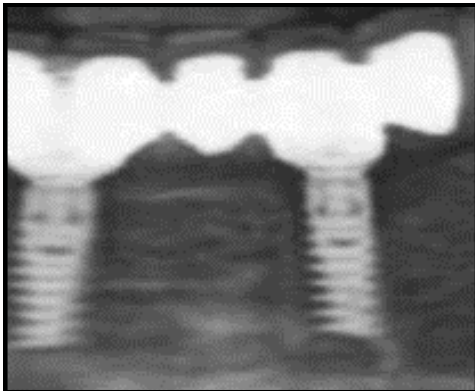
According to the evidence-based research, the placement of RPDs using **cast clasp** had a significantly greater stabilizing effect on the abutment teeth than use of **wrought wire clasps**. This finding indicates that directly applying a cast clasp to a retainer can stabilize mobile abutment teeth and increase their rigidity. So, option (C) and (D) are ruled out. And (D) answer is incorrect. Wrought clasp doesn't come as infra-bulge.

In **I-bar** limited amount of tooth get touched with the clasp assembly. Lesser the amount of clasp touches lesser the force acting on the tooth. In **circumferential clasp**, the whole retentive/reciprocal arm is touching the tooth surface. So, more force is applied on the tooth. Therefore, less traumatic and more aesthetic clasp among the given is cast clasp infra-bulge.

# PROSTHO

## SBQ 9

PATIENT COMPLAINS OF LOOSE PROSTHESIS IN THE LOWER ANTERIOR REGION. ON EXAMINATION YOU SEE A SWELLING IN THE 32 REGION. PATIENT BRUSHES TWICE DAILY WITH A FLUORIDE TOOTHPASTE AND FLOSSES HIS INTERDENTAL REGION ONCE DAILY BUT IS NOT ABLE TO CLEAN 32 REGION. (IMAGE OF A 5 UNIT IMPLANT SUPPORTED FPD GIVEN WITH A CANTILEVER ON 33 AND IMPLANTS AT POSITION 42 AND 32). FPD ON 41,42, 31, 32 ,33 (CANTILEVER). RADIOLUCENCY AROUND THE TOP PORTION OF IMPLANTS. CANTILEVER PART, 32, CLEARLY HAD AN OPEN CONTACT AND BONE LOSS AROUND 33 CANTILEVER AND 34 (SOUND TOOTH) AND 42 AREA WAS MASKED BY THE SWOLLEN GUMS. X-RAY: SHOWED PERI IMPLANTITIS AROUND BOTH IMPLANTS UPTO AT LEAST 1/3RD OF IMPLANTS . LOOSE ABUTMENT SCREWS WERE VISIBLE IN BOTH IMPLANTS WITH LOTS OF GAPS ON SIDES AND TOP PARTS.



### I. How should the patient maintain the hygiene under the prosthesis?

- A. Superfloss
- B. Unwaxed floss
- C. Circumferential floss method
- D. Water floss
- E. There's no current conclusive evidence about this matter

### II. The question asked about what hinders the access to maintaining oral hygiene around implant at 32?

- A. Open contact
- B. Food impaction
- C. Periodontitis
- D. Cantilever pontic 33
- E. Swollen gum

# PROSTHO

## III. What is the reason for the mobile bridge

- A. Peri-implant mucositis
- B. Peri-implantitis
- C. Loose abutment screw
- D. Loss of bone
- E. Occlusal overload in the front teeth
- F. No osseointegration
- G. Food Impaction

## IV. What method of mechanical debridement of the implant will be most effective?

- A. Plastic curette for manual debridement
- B. Metal curette
- C. Ultrasonic tip of metal.
- D. Ultrasonic tip of ceramic
- E. Metal brush scraper

## V. When performing SRP, what is the scientifically proven combination with Metronidazole effective in controlling bacterial growth?

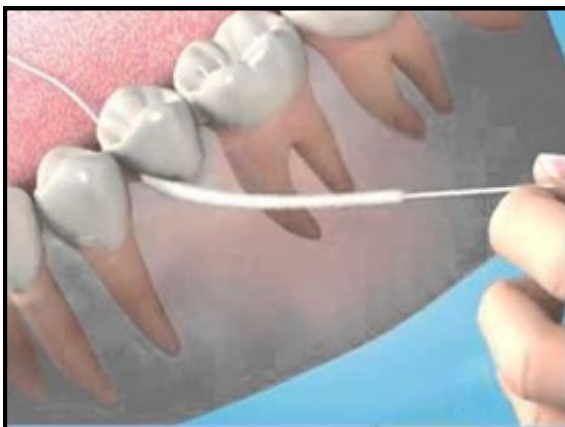- A. Amoxicillin
- B. Doxycycline
- C. Clindamycin

(Lat ceph was quite similar but with missing teeth no occlusion)

### P.O.W.E.R NOTES SBQ 9

- I. It's an implant retained FPD. Can see the swelling in the area of 32. 33 is a cantilever. There's radiolucency and bone loss around implants.

In implant retained FPDs, under the prosthesis a stiffer floss is recommended to maintain the OH. It's known as super floss. It's mostly indicated in FPDs.



# PROSTHO

## P.O.W.E.R NOTES SBQ 9

- II. Open contacts don't hinder as it gives access for maintaining OH.  
Food impaction will lead to bone loss problems in 32 which is present right now.  
There's no access problem with it.  
Patient can maintain OH in other pontics except for 33 cantilever pontic.  
Swelling is present on 32 which is due to physical hindrance to get in the area.
- III. Peri-implantitis is the diagnosis. The cause/ aetiology is the loose screws as all the detrimental forces are acting on it. Option (A) and (B) are ruled out.  
Occlusal load is fine as there's no bruxism or no edge to edge occlusion. It's the abutment that can't take up the load. Option (E) is ruled out.  
Loss of bone is not the reason of mobility. Loss of bone is the outcome. The bridge would have started getting loose even before the bone loss because of the loose screw. Patient is maintaining good oral hygiene so that it doesn't lead to bone loss. Option (D) ruled out.  
Osseointegration loss can happen due to 3 reasons; surgical problem during the placement of implants, poor OH maintenance, abutment problem with the screw loosening. Option (F) is ruled out.  
If loose screw is not given in the x-ray or in the history then what would be the reason for the mobile bridge? No osseointegration or no proper OH.
- IV. As a metal only titanium is recommended for mechanical debridement. This answer is not given. The second-best material is the plastic curettes.
- V. According to TG amoxicillin is given along with metronidazole.

# PROSTHO

## SBQ 10

### COMBINATION SYNDROME CASE:

- I. Pt had a very old denture, lower canine to canine present, there was a question about what is the best material and technique to take the **SECONDARY impression of the upper denture with a flabby ridge.**
- A. Pvs with custom made tray
  - B. Pvs with compound modified custom tray
  - C. 3d intraoral scan
  - D. Alginate with compound modified custom tray
  - E. ZoE in the denture
- II. Which muscle is to be taken care of while construction of the denture in the lower left lingual side?
- A. Mylohyoid
  - B. Superior constrictor
  - C. Medial pterygoid
  - D. Lateral pterygoid
- III. You constructed a lower cobalt chrome. Patient came with a complaint of loose denture on the left side after 2 weeks. What is the best way to correct this?
- A. Reline the distal saddle
  - B. Construct new rpd
  - C. Check occlusion and correct it
  - D. Adjust the clasp and denture base
- IV. Pt complains of loose upper denture, loose only during function. Lower canine to canine present with minimal calculus what is the cause of ill fitting denture ? ridge was firm and sound
- A. Due to canine interference on chewing
  - B. Resorbed anterior ridge



# PROSTHO

## P.O.W.E.R NOTES SBQ 10

- I. For loose flabby ridges PVS with compound modified custom made tray (because you do border moulding) and window technique is the best. Retention is better with PVS compared to 3D intra oral scan.
- II.
  - Lower lingual side of the mouth- mylohyoid muscle creates the floor of the mouth.
  - Superior constrictor muscle is the most posterior in the pharynx.
  - Medial and lateral pterygoid muscles are the condylar muscles.
- III.
  - After 2 weeks' time the denture is loose. So, u must check for the retentive components.
  - Resorption will not happen drastically in 2 weeks to make the denture loose. So relining is not indicated. Option (A) is ruled out.
  - Occlusion would have been the problem from day 1 or day 2. It is not loose on function. So, occlusion is not the problem. It's a loose denture on a side always. When looseness present always we must check for the retention. If looseness present only during the function, then the answer would be (C). option (C) is ruled out.
- IV. Denture is loose only during the function. So, there must be an occlusion interference. You can't give canine guided occlusion in combination syndrome. it will lead to canine interference on chewing. You can't give group function occlusion in combination syndrome. It should be bilaterally balance occlusion.



# PROSTHO

## SBQ 11

THERE WAS A PICTURE GIVEN IN WHICH IT SHOWED REDUCED INTER OCCLUSAL SPACE IN THE POSTERIORS AS THE LOWER RIGHT SIDE POSTER TEETH WERE MISSING. BUT THE UPPER RIGHT SIDE POSTERIOR TEETH WERE NOT SHOWING ANY EXTRUSION

- 
- I. With the first picture what can you see? (first picture was especially mentioned showing asymmetry of lips)
- A. Reverse smile line
  - B. Resorption of ridge
  - C. Reduced vdo
  - D. Hyperactive mentalis
  - E. Tight lower lip
- II. A second photograph provided: The whole upper right posterior segment was extruded including the bone and gingiva. Lower right edentulous ridge with reduced interocclusal distance. what is the reason for losing inter occlusal distance?
- A. Attrition of anterior teeth
  - B. Dento alveolar extrusion of whole maxillary segment with attachment loss
  - C. Postero-inferior collapse of maxilla (some had maxilla effected)
  - D. Hypertrophy of mandible (kind of visible in radiograph) (some has mandible affected)
- III. They also asked what was the best method to measure the re-established VDO?
- A. By reducing freeway space by 1 mm
  - B. Recording VDO in by various methods
  - C. By asking the patient to pronounce M and measure from the third molar distance.
  - D. Or by increasing the VDR more than freeway space.

# PROSTHO

## P.O.W.E.R NOTES SBQ 11

- I. According to the picture it's a protruded lip it's due to the hyperactive mentalis as mentioned above.
- II. Lower right-side posterior teeth were missing. So, it's Kennedy's class II. Upper right-side posterior teeth had reduced inter occlusal space. But there's no extrusion of the upper right-side posteriors. OPG was given and not showing any bone loss or extrusion of teeth. So, option (B) is ruled out.  
It's not the hypertrophy of mandible rather than atrophy due to excessive maxillary forces. So, option (D) is ruled out.
- III. We don't measure VDO by using only 1 method. VDO keeps changing. You will various methods to measure VDO to get a average value.

Reference: *ADA article -clinical considerations for increasing occlusal vertical dimension-page no 3.* "it has been suggested that in order to improve the accuracy of the recording procedure (VDO) more than 1method should be used.

# PROSTHO

## SBQ 12

**WHAT IS MOST IMPORTANT RADIOLOGICAL CHARACTERISTIC OF CBCT/OPG (ONLY IN FEW CENTERS) IMAGING FOR IMPLANT:**

---

- A. Accuracy in linear measurement
- B. Superimposition of anatomic structures
- C. Breadth of the image
- D. High resolution

## P.O.W.E.R NOTES SBQ 12

Repeated question SBQ 6

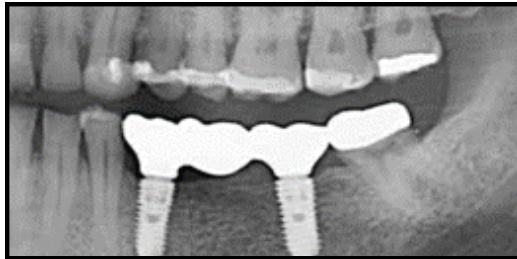
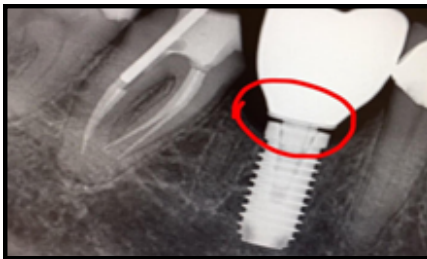
# PROSTHO

## SBQ 13

### ON IMPLANT (NEW QUESTION)

(PLASTIC CURETTAGE, SWELLING HINDRANCE, SUPERFLOSS SAME QUESTION AS YOURS. ONLY ONE QUESTION WAS DIFFERENT)

CANTILEVER BRIDGE FROM 42 TO 33, ABUTMENTS ARE 32,42. NOTHING IS GIVEN IN HISTORY ABOUT PAIN,BLEEDING, OR BONE LOSS. PATIENT WAS COMPLAINING ABOUT THE MOBILITY OF THE BRIDGE FOR 3 WEEKS, HE HAD DIFFICULTY CLEANING THE AREA. IMPLANTS WERE PLACED 3 YEARS AGO. BRIDGE WAS PLACED 9 MONTHS LATER.IN OPG IMPLANTS LOOK HEALTHY (IN SOME CENTERS THERE WAS CLEAR RADIO LUCENCY SURROUNDING THE CORONAL THIRD OF BOTH THE IMPLANTS), NO CALCULUS WAS VISIBLE.PATIENT HAS MEDICAL HISTORY OF DM. (IN SOME CENTERS YOU COULD SEE THE GAP BETWEEN THE BRIDGE AND IMPLANT AND NO RADIO LUCENCY AROUND IMPLANTS.



#### I. What is the reason for the mobility of the bridge?

- A. Lack of Osseointegration
- B. Loose abutment screws
- C. Peri implantitis
- D. Peri implant mucositis

#### II. You plan to refer the patient to a specialist. Which instruments will be used to curette implant

- A. Plastic curette
- B. Ultrasonic ceramic tip
- C. Metal scrubber
- D. Ultrasonic metallic tip

#### III. How does the adjunctive treatment help in the management?

- A. Influence the micro flora
- B. Alter host response to the bacteria
- C. Regenerate periodontal ligament

# PROSTHO

## P.O.W.E.R NOTES SBQ 13

- I. There's a gap between the abutment and the implant and no radiolucency around the bone. The answer would be loose abutment screws which are leading to the mobility of the bridge.  
If there's no loose abutment screw and in the presence of distinct radiolucency, then the answer would be lack of osseointegration.
- II. As a metal only titanium is recommended for mechanical debridement. This answer is not given. The second-best material is the plastic curettes.
- III. Adjunctive treatment is helpful in regeneration of PDL in dentate patients and not in implant patients. Adjunct treatment is helpful in implant patients by influencing the bacteria.  
Amoxicillin and metronidazole don't have regeneration capacity in both natural teeth and implants. Tetracycline has a regeneration capacity in natural tooth to create new PDL fibers.

# PROSTHO

## SBQ 14

### (NEW) - COMBINATION SYNDROME

LADY WEARING UPPER DENTURE FOR 17 YEARS AND LOWER 34-44 TEETH PRESENT. EXCESSIVE WORN OUT DENTURE TEETH INFORMATION GIVEN IN QUESTION.

- CLICKING IN JAW WHILE EATING FOOD
- REDUCED VDO AND SORENESS AROUND CORNER OF MOUTH
- DENTURE UNSTABLE UPON CHEWING
- RESORBED ANTERIOR MAXILLA WITH FLABBY RIDGE

(NO CLINICAL PICTURE WAS GIVEN)

#### I. What is the reason for soreness around the corner of mouth?

- A. Reduced VDO
- B. Reduced freeway space
- C. Vitamin deficiency

#### II. Muscle attached to the disc of the TMJ is pulled in front of the articular eminence it slides over. Which muscle is involved in clicking the tmj?

- A. Masseter
- B. Buccinator
- C. Medial pterygoid
- D. Temporalis
- E. Lateral pterygoid

#### III. Reason for denture instability upon chewing

- A. Excessive worn out teeth
- B. Reduced VDO
- C. Faulty post dam seal
- D. Anterior resorbed ridges
- E. Incorrect centric occlusion

#### IV. What can be done to stabilize the new denture?

- A. Make a functional lower rpd
- B. New denture with wear resistance teeth
- C. Make sure new denture have post dam seal

#### V. Best method for impression taking of an edentulous patient with maxillary anterior flabby ridge

- A. 3D impression technique
- B. Polyvinyl with compound modified custom made tray
- C. Alginate

# PROSTHO

## P.O.W.E.R NOTES SBQ 14

- Clicking in the jaw while eating food is associated with excessive worn out denture teeth. As a result, there will be reduced VDO. Reduced VDO results in angular cheilitis and soreness around the corner of mouth. TMJ problems/pain in the mandibular joint can happen with reduced VDO.
- Denture is unstable upon chewing is not because of occlusal interference. Because occlusal interference is not identified after 17years of denture use.
- Resorbed anterior maxilla with flabby ridge is a long- standing feature of combination syndrome, which leads to loose denture.

- I.
  - Soreness around the corner of mouth is due to reduced VDO and increased freeway space but not due to vitamin deficiency.
  - In dentate patients presenting history of angular cheilitis is due to vitamin deficiency.

II. Superior head of the lateral pterygoid muscle that is connected to the disc.

III. Incorrect centric occlusion will not show the results after 17years.

Flabby ridges from the combination syndrome will be seen from years of denture use.

Worn out teeth leads to reduced VDO and it doesn't cause instability of denture or rocking denture.

The post dam seal can get faulty now and can have gaps and leads to instability upon chewing. Lack of retention in the posterior and instability.

IV. Lower RPD is not a problem, wear resistance is not a problem as it's physiological wear that happened during 17years. So, no need of giving extra wear resistance teeth.

But now we have identified that the post dam seal is not good enough because the ridges will also be reduced naturally with physiological resorption.

Flabby ridges are present in the beginning of the combination syndrome/ before the denture is given. flabby ridges will not take place, when the combination syndrome patient wear denture. If you give denture in combination syndrome, then the patient will not develop flabby ridges.

When the patient remains edentulous for a long period of time and the lower natural teeth remain unopposed for a long period of time, that will result in upper anterior ridge resorption and the tissue overlying it will become flabby. When you give denture, it will not resorb excessively, only physiological resorption takes place.

When giving a new denture if the flabby ridge is not recorded with window/flowable technique, it will result in denture instability.

Overall looseness, generalised physiological resorption happens specially in the post dam area.

(reference: denture trouble shooting guide)

# PROSTHO

## P.O.W.E.R NOTES SBQ 14

- V. Patient will still have flabby ridge even if you are giving a new denture, if you are not surgically removing it. So, you need to use the window technique with PVS flowable with compound modified border moulded custom tray. ZOE will be used for the rest of the palate, anteriorly flowable.

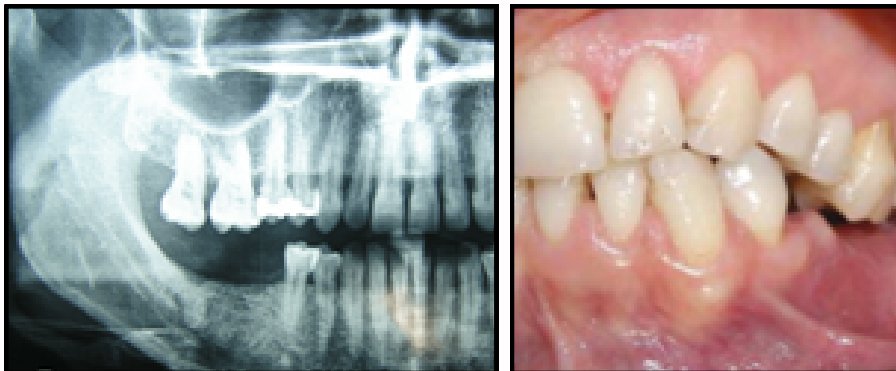


# PROSTHO

## SBQ 15

### DENTURE PATIENT

LADY PATIENT COMES TO YOU, YOU OBSERVE HYPERACTIVE MENTALIS MUSCLE, 2 CLINICAL PICTURES GIVEN - ONE FROM FRONT (EXTRA-ORAL), OTHER ONE INTRAORAL RIGHT SIDE CROPPED PIC - YOU COULD SEE EXTRUSION OF UPPER RIGHT DENTOALVEOLAR, NO LOWER TEETH PRESENT. CROPPED OPG OF RIGHT SIDE GIVEN.



(2ND PIC - COULD CLEARLY SEE DENTOALVEOLAR EXTRUSION WITHOUT ATTACHMENT LOSS)

I. After clinically checking teeth in maximum intercuspation (intra-oral pic was given) and radiographic assessment, what additional information or investigation will help to make a lower denture

- A. Clinical assessment and OPG provides all the required information.
- B. Ask the lab tech to do an occlusal analysis of the master cast
- C. An articulated study cast on semi-adjustable articulator for occlusal analysis

# PROSTHO

## P.O.W.E.R NOTES SBQ 15

- I.
- It's a complex case. Only by doing the clinical assessment and OPG will not provide all the required information.
  - Occlusal analysis should be done by the dentist and not by the lab technician.
  - The best way to do is the occlusal analysis on a articulated study casts.

# PEDO+ORTHO

## SBQ 1

**ADULT CERVICAL RESORPTION WITH CHILDHOOD ORTHODONTIC TREATMENT:** LADY 61 HAD ORTHO TREATMENT AS A CHILD. SHE HAS A RETAINER FIXED IN 11 21 TO MAINTAIN DIASTEMA CLOSURE DUE TO ANODONTIA. SHE HAS BEEN EXPERIENCING WEIRD FEELINGS SINCE A FEW DAYS IN THE FRONT TEETH, A VERY REGULAR ATTENDEE OF YOURS. IOPA GIVEN SOME SORT OF RESORPTION WITH 21 LOOKS LIKE AN EXTERNAL CERVICAL BUT NOT CLEAR. YOU DID THE EXAM, ALL LOOKS GOOD. NO SENSIBILITY TEST PROBLEM, NO PROBING PROBLEM. IOPA SHOWED DIFFERENT APEX LEVELS FOR BOTH INCISORS BUT ALSO THERE WAS A RADIOLUCENCY CLOSELY ASSOCIATED WITH PULP OF 21 INTERNALLY (IT WAS CONFUSING). THE TOOTH WAS VITAL ON SENSIBILITY TESTING.

### I. What is the defect in her teeth?

- A. Apical root resorption
- B. Internal resorption
- C. External invasive cervical resorption
- D. External replacement resorption
- E. Orthodontic root resorption

### II. What is the cause for her problem?

- A. Past Orthodontic treatment
- B. Past trauma
- C. Perio disease
- D. External bleaching
- E. Plaque/bad oral hygiene

**III. Patient said her Florine, daughter who is 14 now got the same thing when she got her tooth avulsed at age of 7-8 years old and then it was replaced and then she got this resorption. She had researched a lot about it and is convinced that its same with her. The patient was concerned if it was due to same reason as her daughter. How will you explain her how her resorption is different from her daughters?**

- A. Its progression need presence of orthodontic forces/treatment /it resolves as soon as forces stop
- B. It starts at the beginning of orthodontic treatment and resolves in later stages of treatment
- C. It starts at the beginning of orthodontic treatment and Repairs in later stages of treatment
- D. The resorption is related to the amount of force applied
- E. The resorption is related to the amount of time for the orthodontic treatment

# PEDO+ORTHO

## SBQ 1

**IV. You are treating this same patient and in your treatment, you used trichloroacetic acid (tca). When you remove the rubber dam you see it has caused a burn on palate. What will be your immediate step to treat/do?**

- A. Distilled Water
- B. Vaseline
- C. Saline
- D. Corticosteroid cream
- E. Sodium bicarbonate solution

**V. What could have been done for the daughter at that time?**

- A. Use of flexible nylon splint and starting rct within 7 days
- B. Use rigid splint and do recall within 3-4 days
- C. Use flexible splint for two weeks and start the root canal within 10 days(mature)
- D. Use flexible splint for two weeks and start the root canal treatment once the signs start to appear.(Immature)
- E. Use rigid splint for 4 weeks

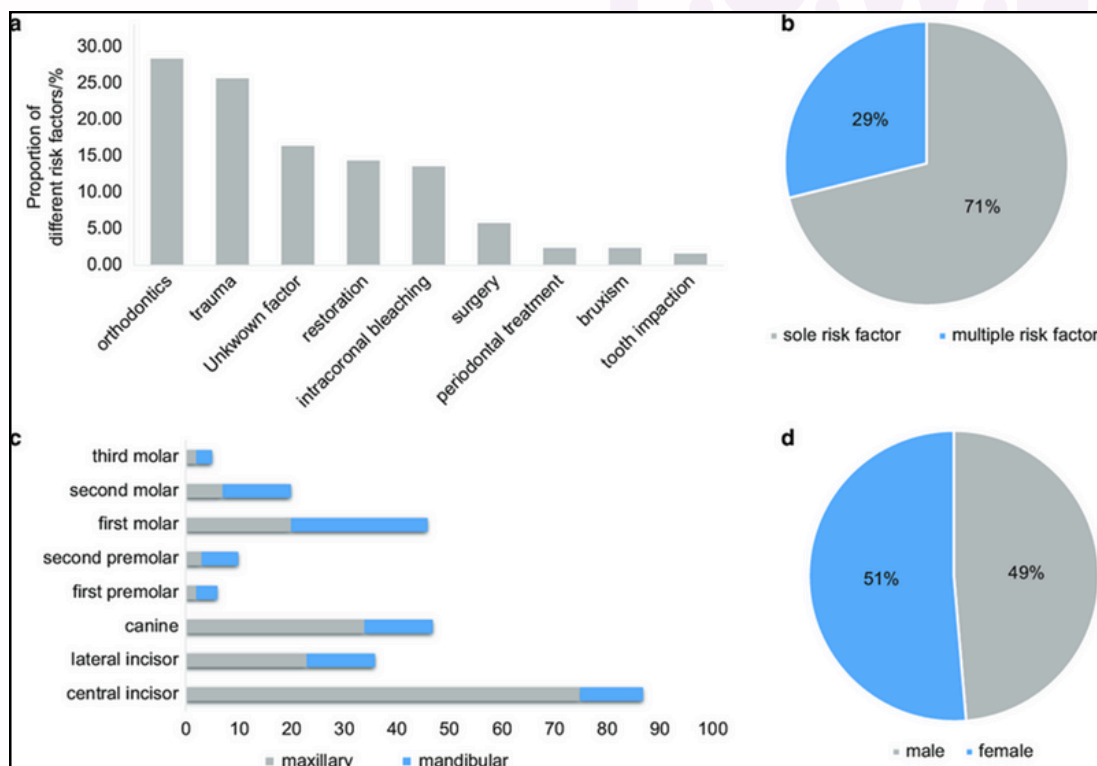
# PEDO+ORTHO

## P.O.W.E.R NOTES SBQ 1

External cervical resorption is a type of pathological root resorption that is often asymptomatic. It leads to progressive loss of dental hard tissues while the pulp usually remains vital. External cervical resorption (ECR) refers to a pathological state in which resorption tissues penetrate into the dentin at the cervical aspect of the root.

Inflammatory apical resorption happens during the orthodontic treatment and it will not take place after the treatment. Once the braces are off the apical resorption stops. Even in the optimal orthodontic force apical resorption can happen. In excessive orthodontic force, apical resorption is excessive which leads to tooth mobility.

ECR doesn't happen immediately after ortho treatment. Systematic reviews pointed to a positive correlation between the amount of the force exerted on the teeth. Besides, extending the time of acting force also increased the severity of root resorption. Mostly excessive force will induce ECR.



- I. Retainer fixed in 11, 21- mild orthodontic force is applied on the teeth for a long time period. This can lead to ECR. So, answer is (C)

Different apex levels for incisors- it's normal to have apical root resorption in a ortho patient. Orthodontic root resorption is nothing but apical root resorption. So, option (A) and (E) are ruled out.

There's no ankylosis happening due to external trauma. So, option (D) is ruled out.

# PEDO+ORTHO

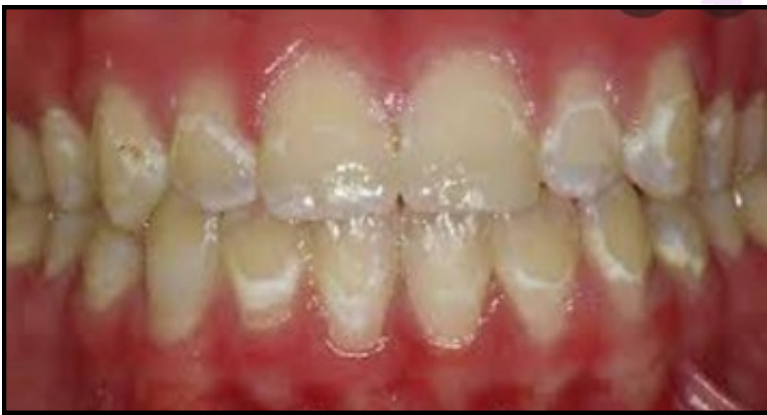## P.O.W.E.R NOTES SBQ 1

- II. Ortho treatment is given as the past dental history. So, the predominant cause is (A) only.
- III. ECR doesn't require presence of ortho forces. So, option (A) is incorrect.  
Options (B) and (C) are related to apical root resorption.  
Option (D) is true for both apical root resorption and ECR. So, option (D) is selected.  
Time factor is not related to ECR. It's related to apical root resorption. So, option (E) is ruled out.
- IV. TCA is an acid. so to neutralise it you need to have a base.  $\text{NaHCO}_3$  is the base. When you use TCA in the clinic you must have  $\text{NaHCO}_3$  solution.
- IV. • Daughter is 7-8yrs of age. Rigid and nylon splints are not used in immature teeth/mixed dentition because during the eruption of teeth forces can act and dislodge the splint.  
• Nylon (fishing line) splints are not recommended for children when there are only a few permanent teeth for stabilization of the traumatised tooth.  
• Flexible splint can be used in immature. RCT is done within 10 days in case of mature teeth. In case of immature teeth RCT is done once signs starts to appear. Otherwise you wait for apexogenesis to take place.

# PEDO+ORTHO

## SBQ 2

PATIENT COMES WITH COMPLAINTS OF WHITE STAINS ON TEETH WHICH HE DISLIKES A LOT. PHOTO GIVEN WITH INCIPENT LESIONS IN THE CERVICAL AREA. ORTHO TREATMENT BUT THE ORTHODONTIST TOOK OFF THE BRACES BECAUSE HE THOUGHT THE PATIENT IS NOT KEEPING UP THE GOOD ORAL HYGIENE. NOW HE DOES A LOT OF TOOTH BRUSHING BUT THESE WHITE STAINS ARE NOT GOING AWAY. HE DRINKS 2L COLA DAILY. ORTHODONTIST ALSO GIVE HIM REMOVABLE RETAINERS WHICH HE'S NOT WEARING. HE IS ALLERGIC TO PENICILLIN AND DAIRY PRODUCTS LIKE CHEESE, MILK, AND BANANAS.



### I. What is the cause of white lesions?

- A. Plaque deposits (retained plaque deposits)
- B. Acidic drinks
- C. Excessive tooth brushing
- D. Ortho treatment

### II. When prescribing preventative treatment for this patient, what should be kept in mind?

- A. Allergy to dairy
- B. Allergy to penicillin
- C. Frequency of brushing
- D. Frequency of sugary drinks

### III. What treatment will you give for this patient?

- A. 5000 ppm toothpaste twice daily
- B. 10 % Cpp acp and 900 ppm fl gel
- C. 900ppm Fluoride mouthwash weekly
- D. 22600 ppm varnish every month

### III. What treatment will you give for this patient?

- A. 5000 ppm toothpaste twice daily
- B. 10 % Cpp acp and 900 ppm fl gel
- C. 900ppm Fluoride mouthwash weekly
- D. 22600 ppm varnish every month

# PEDO+ORTHO

## SBQ 2

**IV. Considering this patient not wearing the removable retainer for bite correction. What is the major drawback of a removable retainer? (Question says retainers not aligners)**

- A. Patients compliance issue.
- B. Plaque control
- C. Movements in different planes
- D. Tipping forces (this option was not there in my station n it mentioned removable appliance)

**V. What are the white lesions on the cervical area?**

- A. Incipient caries
- B. Demineralisation
- C. Hypoplasia
- D. Hypomineralisation

## P.O.W.E.R NOTES SBQ 2

- I. The diagnosis is orthodontic demineralisation. The aetiology/ cause for both incipient caries and orthodontic demineralisation spots is plaque. Patient is not keeping good oral hygiene.
- II. The treatment for orthodontic demineralisation spots is CPP-ACP+ fluoride combination.  
A recent systemic review showed that CPP-ACP with fluoride incorporate in to it was superior to fluoride alone for arresting and reversing early occlusal carious lesions. CPP-ACP will increase the Ca uptake.  
In the patients who are allergic to dairy products, CPP-ACP can't be given. Therefore, fluoride alone is recommended in these patients. So, his allergic condition to CPP-ACP should be kept in mind.
- III. CPP-ACP can't be given due to his allergic condition. So, Option (B) is ruled out.  
22600ppm varnish is used 4-5 times annually. So, option (D) is ruled out.  
900ppm fluoride mouth wash weekly will not give required remineralisation. So, option (C) is ruled out.
- IV. Plaque control is better with removable compared to fixed. So, option (B) is ruled out.  
There are no movement desired or tipping forces desired from a removable retainer. So, option (C) and (D) are ruled out.  
Patient is not wearing the removable retainer, so patient compliance is the drawback.
- V. According to the given history patient had underwent ortho treatment. Therefore, these lesions are orthodontic demineralisation spots.



# PEDO+ORTHO

## SBQ 3

6-7 YEARS OLD GIRL COMES WITH FATHER. CLINICAL PICTURE OF PAINLESS PEDUNCULATED MASS ON PALATAL SURFACE ADJACENT TO 21. PARENTS ARE CONCERNED ABOUT IT INTERFERING WITH THE OCCLUSION OF THEIR CHILD. PIC GIVEN: GINGIVAL OVERGROWTH LINGUAL TO 21 WHICH HAS PUSHED 21 OUT LABIALLY DUE TO OVERGROWTH, NO HISTORY OF TRAUMA OR NO PULPAL ABNORMALITIES. LOWER CENTRAL INCISOR IS INDENTED INTO THE GROWTH. THERE WAS A PICTURE OF A SMALL LIGHT PINK COLOURED LOBULATED GROWTH WITHOUT ANY INFLAMMATION AND BLEEDING. ON THE PALATAL SIDE OF 21, 21 WAS LABIALLY DISPLACED (IT MENTIONED THAT IT IS A PEDUNCULATED MASS WHICH HAD INDENTATION FROM LL1) (IT DIDN'T LOOK LIKE A PYOGENIC GRANULOMA BUT A FIBROUS EPULIS).

- I. You did a biopsy while waiting for the result. you have provisional diagnosis of pyogenic granuloma. On what basis do you diagnose it as pyogenic granuloma?
  - A. Familial and hereditary condition
  - B. As it is pedunculated and painless growth
  - C. Form of actinomyces infection
  - D. Pus coming out of the lesion
- II. You want to take an IOPA of 21 to check the status inside. but the child is having a hard time or biting the film. What will you do?
  - A. Postponed the x-ray till you have the biopsy result
  - B. Ask the parents to put a lead apron on them & hold the film
  - C. Ask the DA to hold the film with the lead apron wearing
  - D. You hold the film with lead apron wearing
- III. PA is given with immature roots of 11, 21. (looks normal without any pathology) what is significant can you see from the PA?
  - A. Root of 21 is dilacerated
  - B. Radiolucent areas near the apices of the permanent incisors are the nasal cavity (looks like this is the best answer)
  - C. Roots do not correspond to the patient's age
  - D. Open apices compatible with the age
  - E. Infection
  - F. Dentigerous cyst
- IV. You come up with a diagnosis of pyogenic granuloma as it is confirmed with biopsy results. What is the cause of it?
  - A. Chronic trauma
  - B. Bacteria
  - C. Virus
  - D. Genetic or hereditary

# PEDO+ORTHO

## SBQ 3

V. You did a biopsy while waiting for the result. you have provisional diagnosis of pyogenic granuloma. On what basis do you diagnose is as pyogenic granuloma?

- A. Pulpitis
- B. Familial adenomatoid polyposis
- C. Some infection by lactobacillus
- D. Infection by actinomyces/ staph or strep
- E. Chronic minor trauma

## P.O.W.E.R NOTES SBQ 3

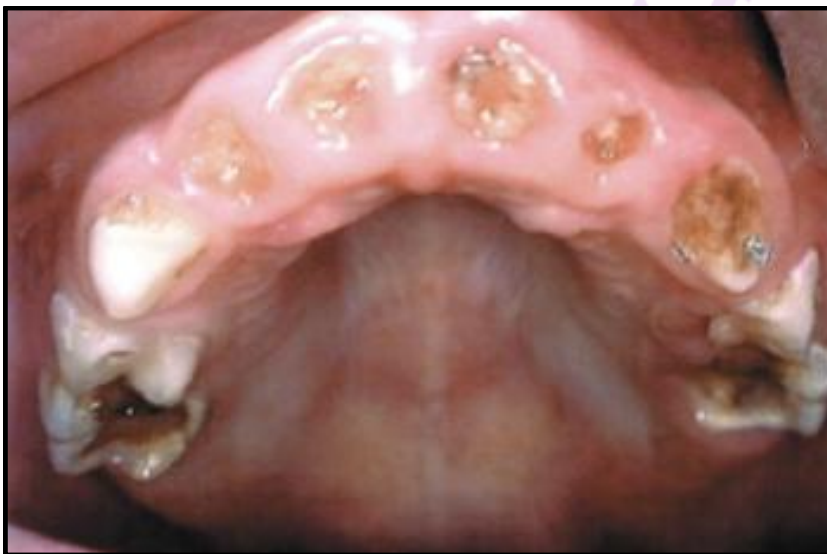- I. Fibrous epulis is a histological variant of pyogenic granuloma. There's no fibrous tissue rather than an inflammatory component.  
Pyogenic granuloma is not associated with a familial history. It's not an infection or not associated with pus drainage. But it's a pedunculated and a painless overgrowth.
- II. If the child is having a hard time on biting the film, somebody should help him. You will not postpone the x-ray as the next time the child will do the same. X-ray is needed to confirm the diagnosis and plan the treatment. The legal guardian/parent should help the child to hold the film. You don't expose your self or staff for excessive radiation. Because if you were to hold the film for every patient then the exposure for you is increased. For the parent it's just a one time exposure.
- III. There were nasal cavities seen along with the apices. If the film was placed deeper, you would be able to appreciate the nasal cavities. So, the answer could be (B)  
It can also be the open apices compatible with the age. So, the answer could be (D).  
(B) or (D) are more likely findings. Two different radiographs were given is different stations.
- IV. Chronic minor trauma either due to plaque, restoration, chronic irritation is associated with pyogenic granuloma.
- V. Same as above. Pyogenic granuloma is not associated with infection, familial history. So, the answer is (E).

# PEDO+ORTHO

## SBQ 4

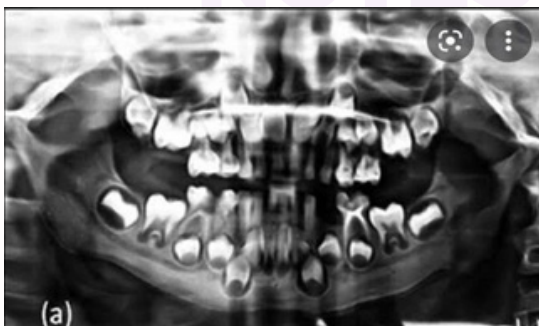
PRESCHOOL GIRL COMES WITH FATHER & FATHER IS COMPLAINING THAT SHE HAS NO TEETH AT THE FRONT. HAS PAIN WHILE EATING. INTRAORAL PICTURES GIVEN FOR BOTH THE ARCHES & OPG ALSO GIVEN, ALL INCISORS GROSSLY DECAYED AND XRAY GIVEN WITH SOME MOLARS DECAYED AS WELL. (PERMANENT MOLARS WERE OUT OF BONE BUT WITH IN THE MUCOSA IN XRAY. CLINICALLY NO BULGE IN SOFT TISSUE)

CLINICAL PICTURE: SHOWED CARIOUS TEETH IN ANTERIORS & HAD SINUS TRACT OPENINGS IN THE ANTERIORS IN BETWEEN 21 & 23 & SOME REMEMBERED IT WAS EVEN IN THE POSTERIORS)



I. As per clinical pictures & the radiographic given what is the expected age of this patient?

(OPG findings: First molars not erupted but reached alveolar bone already.)



- A. 3-4 y
- B. 4-5 y
- C. 5-6 y
- D. 1-2 y
- E. 6-7 y
- F. 2-3 y

# PEDO+ORTHO

## SBQ 4

**II. The previous dentist had given fissure sealants & he was asked to come back in 6months. What could have been a most essential step which was missing to be done at that stage along with the sealant placement?**

- A. Fluoride toothpaste
- B. Categorising child to be in high caries risk & doing early intervention.
- C. Fluoride varnish application more than twice that year.

**III. While taking the radiograph the patient seems to be cooperative. But while being accompanied by the parent for being seated on the dental chair, the girl seems uncomfortable and wasn't willing to. She was also wearing a long sleeved dress on a hot sunny day. What does this presentation immediately suggests you?**

- A. Suspicion of child abuse
- B. Girl is very shy
- C. She was cold on sunny day
- D. Nothing noticeable as for this age, the behaviour is very common.
- E. Child neglect suspicion
- F. She had recent injury

**IV. What treatment would you do first in this case?**

- A. Restoration of lower primary molar first.
- B. Extract all non savable poorly prognostic teeth first.
- C. Managing diet.

**V. How do you restore 75/85 donot remember which one exactly.(badly broken down carious molar)**

- A. Calcium hydroxide with stainless steel crown
- B. GIC
- C. Composite build up

# PEDO+ORTHO

## P.O.W.E.R NOTES SBQ 4

- I. Molars are still within the soft tissues but out of the bone. So, it's about to erupt. It erupts at the age of 6yrs. Since it's not erupted yet the age is 5-6yrs.
- II. Anterior teeth can not be protected with sealants.  
When you do sealants in a high caries risk patient, fluoride varnish application is an adjunct to it. Smooth surfaces are protected by the application of sealants. Dentist categorised the patient as a high caries risk patient and did the early intervention by application of sealers, but he missed applying fluoride varnish.
- III. According to the history given it denotes that it's a child abuse scenario rather than child neglect. The child was uncomfortable when she was accompanied by the parent. She must be wearing long sleeve dress on a hot sunny day to cover up her body marks.

IV.

### CARIES MANAGEMENT

#### 1. EMERGENCY PHASE

(EXTRACT ALL THE NON-SAVABLE POORLY PROGNOSSED TEETH)



#### 2. MANAGE DIET



#### 3. STABILIZE THE SAVABLE TEETH WITH TF



#### 4. EDUCATE THE PATIENT/PARENT



#### 5. RESTORE WITH PERMANENT RESTORATIONS

- V. SS crowns are the best for the badly broken-down primary molars.

# PEDO+ORTHO

## SBQ 5

### QUESTION ABOUT SPACE MAINTAINER

43,44,45 HAS NOT YET ERUPTED, NO ENOUGH SPACE FOR 43 44 AND 45. 46 IS PRESENT IN ORAL CAVITY. OPG SHOWED 43,44,45 WERE PRESENT. YOU HAVE PLANNED TO EXTRACT 85. SHE HAD PREMATURE LOSS OF 83. THERE WAS A MIDLINE SHIFT (TOWARDS RIGHT TO LEFT)

#### I. What is the malocclusion as per the intraoral picture?

- A. Class II div 2
- B. Class II div 1
- C. Class I
- D. Class III

#### II. Previous Dentist has extracted a tooth. What would have been done at that time when she had lost the canine? (Whether the treatment is for midline shift or the arch perimeter? (Only 83 was lost)

- A. Molar distalization space maintainer from 42
- B. Band and loop space maintainer
- C. Extract 73
- D. Lingual arch from 32 to 42

#### III. In which direction was the midline shift?

- A. Towards right with space loss of 43 44 45
- B. Towards left with space loss of 83 84 85
- C. Towards right with space loss on 33 34 35
- D. Towards left space loss of 73 74 75

## P.O.W.E.R NOTES SBQ 5

#### I. Pictures/ radiograph is needed to answer this question.

- II. • Lingual arch is preferred in a bilateral canine loss. So, option is (D) is ruled out. (D) is done to prevent the collapse of permanent incisors lingually. If the chief complaint says that her permanent incisors are lingually collapsed, then lingula arch could have been given. It's mostly used in case of bilateral molar loss.
  - To prevent midline shift contra lateral extraction is performed.
  - Band and loop are for the molar situations.
  - Molar distalisation is not done for the incisors.

#### III. Midline shift happens towards the same side in which the canine is lost.

# PEDO+ORTHO

## SBQ 6

**CHILD COMES WITH THE MOTHER. ONE OF THE FRONT TEETH IS MISSING. 12 HAD DILACERATION.**

### I. What is the deciding factor to manage it?

- A. To extract impacted 12 or surgically expose to fix it with ortho
- B. The space or lack of in the mouth
- C. The dilaceration
- D. Position of impacted

### II. You suspect child abuse what would you do next?

- A. Send the parent outside and ask the child
- B. Take the history of the injuries from the parent
- C. Call the authority

## P.O.W.E.R NOTES SBQ 6

- I.
  - To extract or to surgically expose are the management option but they are not the deciding factors.
  - The lack of space is one of the factors but it's not the predominant factor.
  - Dilaceration is a finding and not a deciding factor. Dilaceration is a course of impaction. It can be treated by surgically or ortho traction or by extraction.
  - Position of impaction will decide whether you can surgically expose it and orthodontically bring it to its normal position or not. If it's too far palatally placed, you can't orthodontically correct it. Therefore, position of impaction is the deciding factor.

### II. Assess the child (history/ examination/ talk to the child)

You must see whether the history matches with the injuries or not. Because children do get injured in childhood more often. First you must take the history from the parent as children are poor historians. If the history doesn't match with the injuries, then you can take the history from the child.

If the injuries are seen within the safety triangle and the history doesn't correlate with the injuries, it will be a suspicious case. Then you may call the authorities or colleague.

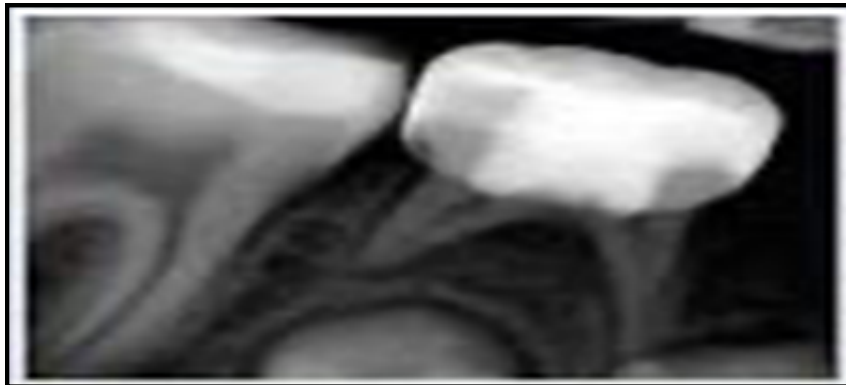
*(Reference: Odel case 36- skateboard accident flow chart)*



# PEDO+ORTHO

## SBQ 7

9 YEARS OLD ALI CAME WITH FATHER FOR A ROUTINE DENTAL CHECK UP. HIS FATHER SAID SOME TREATMENT WAS DONE BY THE PREVIOUS DENTIST BUT THEY DON'T REMEMBER AND DON'T HAVE ANY RECORDS ON HAND OR CONTACT OF THE PREVIOUS DENTIST. HE COMPLAINS OF NO PAIN NO DISCOMFORT. (MORE RESORPTION OF ROOTS / FURCATION INVOLVEMENT THAN THIS IMAGE, THERE WERE TWO BITEWINGS PROVIDED. RIGHT AND LEFT SIDE)



### I. What is TX done for 85?

- A. Pulpotomy with ss crown
- B. Only ss crown
- C. Pulpotomy with preformed resin crown SS D) crown with Hall technique

### II. Current TX for 4 (pulpotomy and crown) and 85 (caries close to pulp)

- A. Do nothing for 84 and gic for 85
- B. Do nothing for 84 and Pulpectomy for 85 C) Extract 84 and ssc for 85
- D. Extract 84 and pulpotomy and ssc for 85 E) Do nothing for 84 and ssc for 85
- F. Extraction of 84 and steel crown on 85
- G. Pulpectomy of 84 and steel crown on 85

### III. Child 9 years old child does not like to use adult toothpaste, doesn't like its taste, so using children's toothpaste, is at high caries risk. Brushes only when he likes. What should he be advised?

- A. Use children toothpaste twice in a day and 900 ppm mouthwash in daily routine
- B. Use 1500 ppm toothpaste twice plus 200 ppm mouthwash 5000 fluoride toothpaste
- C. Use adult toothpaste twice daily and
- D. Use children's toothpaste thrice in a day.



# PEDO+ORTHO

## SBQ 7

IV. 54/55 caries involving enamel and dentine on proximal wall involving the cusp (c4). What will be the treatment?

- A. Restore with gic
- B. Use ssc
- C. No treatment

V. Similar picture provided: lowest premolar. Father says he has seen this empty space since almost an year. (Empty space is there for a long time) Nothing is clearly visible below the cej (Very slight tip of erupting tooth visible just below bone on x ray) (no tip visible). What will you do immediately

- A. Radiograph to see location of premolar B) Refer to ortho.
- C. Do nothing
- D. Save space with space maintainer

## P.O.W.E.R NOTES SBQ 7

Resorption along with the furcation represents the physiological resorption. As there's no signs and symptoms or no exudate or no soft tissue involvement. physiological bone turnover is undergoing for eruption.

- I.
  - Restorative material is extending up to the pulpal floor. Therefore, pulp therapy is performed in this tooth and a crown was given. So, option (B) is ruled out.
  - Hall technique is done for the uncooperative patients without doing a restoration. So, option (D) is ruled out.
  - Resin crown is radiolucent. So, option (A) is ruled out.
- II. 84 is already treated. No signs and symptoms in relation to 84. So, options (C),(D), (F),(G) are ruled out.  
 GIC is not permanent restorative material. It's either SS crown, RMGIC, composite is used for primary teeth as a permanent restorative material. Among them the most preferred is the SS crown. Option (A) is ruled out.  
 In 85 the caries is closer to pulp but there's irreversible pulpitis associated with it. So, option (B) is ruled out.
- III. After 6yrs of age child can use a tooth paste with 1000-1500ppm according to TG. Adults tooth paste is not matching for her. There are children's tooth paste with 1500ppm. 900ppm mouth wash is for weekly use. 200ppm mouth wash is for daily use and can be used after 6yrs of age.
- IV. According to ICDAS, c4 requires restoration as it involves enamel and deeper dentin. GIC is not adequate. SSC is the best option.
- V. Tooth has not erupted in 1years time. To confirm the presence of premolar and its location radiograph is needed. For now, only the clinical picture is available. Depending of the radiograph you can refer the patient or can advice a space maintainer or do nothing if the tooth is almost erupting.

# PEDO+ORTHO

## SBQ 8

DWAYNE, A 6 YEAR CHILD PATIENT COMES WITH MOTHER IN SCHOOL HOURS WHO NOTICED A LARGE HOLE IN A TOOTH GROSSLY CARIOUS 85, NO PAIN. CHILD HAS TYPE 1 DIABETES.

### I. What investigation will you do?

- A. IOPA
- B. Percussion
- C. Sensibility test

### II. On IOPA furcation involvement seen. How will you treat 85?

- A. Extraction
- B. RCT
- C. Single sitting RCT
- D. Wait and observe

### III. What sequelae will happen if 85 is not treated?

- A. Spread of infection
- B. Ectopic eruption of permanent
- C. Periapical abscess
- D. Necrosis
- E. Ankylosis

### IV. Needs exo, he pushes your arm away every time when you attempt to put the forceps on the tooth, how do you handle this? (Version- this was the second time child was behaving like this)

- A. Reassure him and ask mother to hold his hands (exact language) Mother restrains arms of child
- B. Reassure him and ask the nurse to hold his hand /The nurse restrains arms of child
- C. Don't do extraction today and reschedule
- D. Reschedule and do extraction under sedation
- E. Reassure him and continue with the extraction
- F. Refer to specialist

### V. Which local anaesthesia will you give for the child?

- A. 2 percent Lignocaine with 1:80000 adrenaline
- B. Prilocaine with felypressin

### VI. Which local anaesthesia will you give for the child?

- A. Infection
- B. Healing
- C. Bleeding
- D. His age

# PEDO+ORTHO

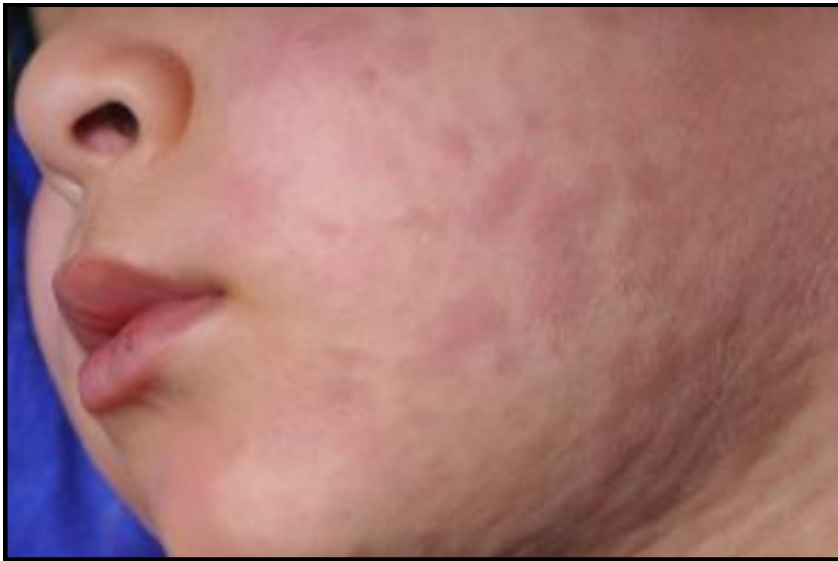## P.O.W.E.R NOTES SBQ 8

- I. Child with DM1 has a grossly decayed tooth and no pain. percussion or pulp sensibility will not give the definitive results. IOPA will be helpful to get a clear idea. And also, 6yrs old child is a poor historian. So, IOPA will be the best.
- II. No point in doing RCT as there's furcation involvement in the primary tooth. There's poor prognosis. In case if the orthodontist wants to save the tooth for another 1yr then we could do RCT though the furcation is involved.
- III. The infection continues to spread if it is not treated. It can either become a periapical abscess or spreading infection. Among (A) and (c), best is (A).
- IV. No physical constraint is indicated as it leads to trauma to the patient. So, (A) and (B) gets ruled out. In an uncooperative child as a dentist you can recommend nitrous oxide sedation. But he's a diabetic patient. When doing under nitrous oxide sedation patient must not eat anything few hours before the surgery as there is a risk of getting hypoglycaemia in a 6yrs old diabetic patient. Slightly more management and more care are needed for this patient. So, specialist referral is required as the child is diabetic.  
If this patient is not diabetic, option (D) would have been the answer if the option was corrected as under "conscious sedation". But still conscious sedation is done by specialist. Can't be given by a general dentist. So, this option will be incorrect. For child patients BDZ are given under specialist set up and N2O can be given under general setup.
- V. In diabetes there's no contraindication in giving lignocaine with adrenaline. We use prilocaine with felypressin when lignocaine with adrenaline is contraindicated. In uncontrolled DM adrenaline and elective procedures are contraindicated. Adrenaline increase the sugar levels.
- VI. Infection and poor healing are associated with DM. Infection can be managed with AB. For healing we must rely on body alone. That can be a major challenge that we must observe.

# PEDO+ORTHO

## SBQ 9

4 YEAR OLD , MOTHER CALLED AT PRACTICE THAT HER SON IS NOT EATING WELL (POSSIBLE TOOTH ISSUE), AS HE IS HAVING MEASLES, (PIC WAS GIVEN WITH TYPICAL RASH ALL OVER THE FACE, SWELLING OVER THE CHEEKS AND RASHES TYPICALLY AROUND LIPS) SHE IS GIVING HIM ICE CREAM BUT THE TOOTH AT THE BACK HURTS ON EATING ICE CREAM. SHE DOESN'T BELIEVE IN VACCINATION AS THINKS IT MAY AFFECT HIS GENERAL HEALTH AND CAUSE AUTISM.



- I. What is the most appropriate treatment at this time? You suspect acute pulpitis.
  - A. Manage with pain killers until the patient is no longer infectious
  - B. Refer to Pediatric specialist
  - C. Refer him to emergency department of hospital
  - D. Book an appointment for today and see the child.
- II. Then he developed swelling 24 hours later, you know it's an abscess and you decided not to delay the treatment, which is the most appropriate method to treat him ?
  - A. Using standard precautions
  - B. Using disposable instruments, single use items as much as possible
  - C. Last patient of day
  - D. Using P2/ N95 mask
- III. His mum says she did not vaccinate him as she believes the Measles vaccine can cause autism. How can you discuss this matter with her?
  - A. Tell her to discuss pros and cons of vaccine with her trusted family doctor
  - B. Tell her that evidence based studies have refuted the connection between the measles vaccine and autism
  - C. Tell her to discuss with the trusted family members
  - D. Tell her that she can get the information from trusted websites.

# PEDO+ORTHO

## P.O.W.E.R NOTES SBQ 9

I. Measles is a transmissible infection through the respiratory route. It's a viral infection which can spread through the droplets.

According to the ICG, patient should be deferred until they are no longer infectious. Eg: measles, mumps, TB. And should be managed with analgesics. So, option (A) is correct.

II. But where the treatment cannot be deferred (e.g: facial swelling), transmission-based precaution must be used for the provision of dental treatment. These are described as below;

- To be seen the last patient of the day
- Immunise against the current status of influenza
- Suitable antimicrobial pre- procedure mouth rinse
- Wear surgical masks that are adapted well to the face. Use of surgical respirators is optional.
- For restorative dentistry use a dental dam and high velocity evacuation to reduce the formation of aerosols. For other procedures, use techniques that minimise the production of splashes of fluids and generation of aerosols.
- Undertake the surface cleaning process twice.

Both options (C) and (D) are correct but (D) is optional according to ICG. So answer is (C).

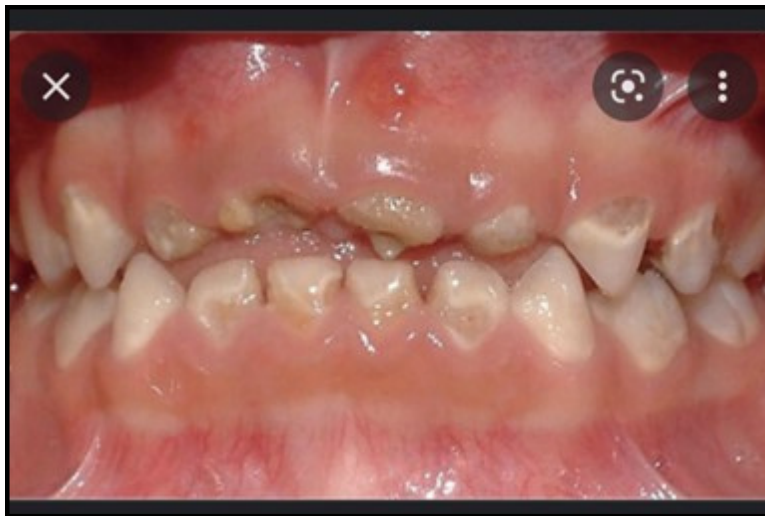III. Dentist can give opinion on dental related problems. But when it's related to vaccination you advise them to get the opinion from the family doctor/GP.

# PEDO+ORTHO

## SBQ 10

A 4-5 YEAR OLD CHILD WITH RAMPANT CARIES ( MULTIPLE INTRAORAL PHOTOS GIVEN SHOWING ALMOST ALL UPPER PRIMARY ANTERIOR RETAINED ROOTS, 54 & 64 GROSSLY CARIOUS, BUCCAL TO 54 AND 61 WITH ABSCESS/SINUS) (74,75 WITH RESTORABLE CARIES). IOPA FOR EACH QUADRANT WERE PROVIDED AS WELL. PATIENT COMPLAINED OF PAIN FROM DRINKING AND EATING ON BOTH SIDES.

WHAT WOULD BE THE DEFINITE TREATMENT? SINUS WAS PRESENT WITH RESPECT TO INCISOR AND MOLAR BOTH.



- A. Extraction of all incisors with hopeless prognosis
- B. Extraction of 54 and 64
- C. Pulpotomy and SCC for 74

# PEDO+ORTHO

## P.O.W.E.R NOTES SBQ 10

I.

### CARIES MANAGEMENT

#### 1. EMERGENCY PHASE

(EXTRACT ALL THE NON-SAVABLE POORLY PROGNOSSED TEETH)



#### 2. MANAGE DIET



#### 3. STABILIZE THE SAVABLE TEETH WITH TF



#### 4. EDUCATE THE PATIENT/PARENT



#### 5. RESTORE WITH PERMANENT RESTORATIONS

Rampant caries starts with max. incisors, then spreading to the max. posteriors. Mandibular anterior are the last to be affected because they have an immune environment due to the presence of salivary glands.



# PEDO+ORTHO

## SBQ 11

**PATIENT NEEDED EXTRACTION, PATIENT WAS ALLERGIC TO NICKEL.(43 KG 12 YEAR OLD CHILD).WHAT ANAESTHETIC TO GIVE?**

- A. 13.2 ml lignocaine with adrenaline
- B. 13.2 ml lignocaine with epinephrine
- C. 13.2 ml prilocaine with felypressin
- D. 13.2 m articaine

## P.O.W.E.R NOTES SBQ 11

- I. All the options have the same value. So, no need to calculate. Patient is allergic to nickel but it's not a contraindication to lignocaine with adrenaline.  
PFM crowns are contraindicated in Nickle allergy.



# PEDO+ORTHO

## SBQ 12

**AMARI 12 YEARS OLD (BOY) BASKETBALL TRAUMA, PATIENT WAS AGITATED AND CONFUSE, BOY FELL DOWN WHY, PT LOOKED UNWELL. YOU ASK "WHEN DID YOU GET THE INJURY?" TOOTH WAS MOBILE AND PAINFUL, BLEEDING IN SULCUS.**

**I. What is the clinical significance of asking when did the injury happen.**

- A. Indicate the prognosis of the treatment
- B. Requirement for emergency referral.
- C. Time suggests what treatment to provide
- D. To check if tetanus is up to date.
- E. What environment it happened

**II. Patient felt nauseous after the incident. There was dry blood crusting in the nose. What is the first question you ask the parents?**

- A. Any loss of consciousness
- B. Is the tooth mobile
- C. How did he fall down
- D. X-ray to see the fracture in the lip and gingiva

**III. Mouth guards to prevent sports injury based on the nature of their sports  
Child plays Rugby. Which mouthguard IS RECOMMENDED FOR 14-15 year old.**

- A. Stock
- B. Custom with bilaminar
- C. Custom with tri laminar,
- D. Custom made laminar
- E. Boil and bite

**IV. Mouth guard replacement should be done (for 14 and 15-year-old boys)**

- A. When discolored
- B. Every year
- C. When they start another contact sport
- D. Only when dental treatment is done.

**V. When asked about basket ball player did not wear mouth guard, he says he only wears on competition and not on practice matches. So what do you decide?**

- A. Provide mouth guards free of cost to players
- B. Provide mouth guards at cheaper price
- C. Advise coach regarding the benefit of using (arrange meeting with coaches to advise)
- D. Explain the Cost-benefit analysis of using mouth guards to players (by attending official club meetings)

# PEDO+ORTHO

## P.O.W.E.R NOTES SBQ 12

- I. Importance of asking “when did you get the injury?” for this there is two main reasons. One is dental and the other is the medical. The most important is the medical reason, that is to rule out the brain injury. So, you must refer the patient to the hospital for the neurological assessment.
- II. Concussion can lead to nausea. Dry blood crusting in the nose indicates internal injury. Clinical symptom of brain injury is the loss of consciousness. So, that should be asked first.

BILAMINAR MOUTH GUARD	TRILAMINAR MOUTH GUARD
Age- 14yrs onwards for permanent teeth	Age- up to 13yrs for mixed dentition.
Medium impact sports	High impact sports. E.g. Rugby, hockey, AFL, karate, squash, kickboxing.

- III. Stock mouth guards are not recommended in Australia.
- IV. Examine your mouth guard regularly for signs of deterioration and replace if it is split or if the resilience, fit or bite have changed.  
Have your mouth guard check for signs of wear, deterioration or reduction in its fit as part of your routine dental review, or at least annually by your dental practitioner.
- V. Giving the mouth guard at a cheaper price won't motivate them to wear it. Advising and explaining the benefits of the mouth guard should be done by the dentist rather than by the coach.

# PEDO+ORTHO

## SBQ 13

**I. We notice they are drinking sports drinks before inserting their mouthguards when training, and games to keep their hydration and replace electrolytes.**

**What should your advice them to do:**

- A. Drink sport drinks before putting on the mouth guard
- B. When the mouth guard is already on
- C. Substitute sports drinks for water
- D. Sugar free sports drinks

**II. It was said the players use mouthguards immediately after having sport drinks and they ask consequences of that on their dentition.**

- A. Erosion
- B. Caries
- C. Hypocalcification

**III. What would you suggest instead for SNACK for the mid game break**

- A. Caramel Muesli Bar
- B. Yogurt Based Smoothie
- C. Orange Wedges
- D. Apple Slices
- E. Dark Chocolate

# PEDO+ORTHO

## P.O.W.E.R NOTES SBQ 13

- I.
  - Sports drinks are needed for hydration, for energy, as nutrition and as electrolytes. So, (C) and (D) are ruled out.
  - It is found that the ph. is lower before putting the mouth guard and trap the electrolytes underneath the mouth guard and leads to more damage.
  - When you drink over the mouth guard the tooth surface gets protected and the ph. is not reduced. So, it good to drink the energy drinks after wearing the mouth guard.
- II. It increases their dental caries risk and erosion risk. Sports drinks have sugar so, the caries risk comes first.
- III. Caramel muesli bar is cariogenic because it contains sugar and it is sticky. Yogurt based smoothies have added sugars. Orange wedges are acidic fruits. Apple is a fibrous fruit and has a natural detergent effect on teeth as well. Dark chocolate has less sugar but not as low as apples.

**Cariogenic foods include:** sweet pastries, chips, cookies, crackers, white bread, sweetened cereals, cakes, confectionary, sweetened muesli bars, dried fruits, ice cream, flavoured milk, sweet yoghurt, beer and any sugary beverages

**Low cariogenic foods include:** white bread with chocolate and sweet spreads and whole grains, whole wheat bread, tortillas, wholemeal pasta, cooked starchy vegetables (such as corn, potatoes, yams, peas, carrots, beans), acidic fruits (such as mango and berries), soup and meat or cheese sandwiches.

**Cario-static foods include:** red meat, pork, fish, chicken, eggs, raw high-fibre vegetables (such as celery, broccoli, lettuce, spinach, cucumber and kale), nuts, popcorn and non-acidic artificial sweeteners.

**The top anti-cariogenic foods/drinks** of this type are plain milk and cheese (such as Swiss and aged Cheddar). Chewing non-citric Xylitol gum

# PEDO+ORTHO

## SBQ 14

A 4 YEAR OLD CHILD ARRIVES IN MELBOURNE, ANXIOUS BUT COOPERATIVE, HIDING BEHIND HIS MOM, HISTORY OF ASTHMA, OCCASIONAL USE OF SHORT ACTING INHALER, USING DAILY CORTICOSTEROIDS FOR ECZEMA, MOM IS WORRIED ABOUT HIS DIET, LIVING IN A NOT FLUORIDATED WATER AREA, ALLERGY TO NUTS, SESAME AND MILK AND ADHESIVE BANDAGES.

**I. Which one is most/least cariogenic? (in my centre it was asked most cariogenic)**

- A. Caramel bar something twice a day
- B. Orange juice 4 times a day (fruit juice)
- C. Rice milk 4 times a day
- D. Fresh fruit 2 times
- E. Plain popcorn twice a day

**II. Mother asks for happy gas, son 4-year-old with underweight and caries. Every time you ask the boy if he's in pain he hides behind his mum's leg, very apprehensive. Mother discloses she is under anxiety and depression, psychological treatment. What questions would you ask to consider her requests, or what should be considered before giving nitrous oxide to the child?**

- A. Any recent severe asthma episodes, as nitrous oxide can exacerbate asthma
- B. Eczema as nitrous oxide can worsen the condition
- C. Putting mask on the child(child willing to wear the mask)
- D. The child is in 15th percentile of weight

**III. What is the preventive treatment for this patient?**

- A. CPP-ACP
- B. 1400 ppm adult strength toothpaste
- C. 500 ppm child strength toothpaste
- D. 1000 ppm child tooth paste

**IV. What would you not recommend for this child (kid allergic to adhesive in rubber band aids)**

- A. Avoid Fluoride gel
- B. Avoid fluoride varnish
- C. Avoid CPP-ACP
- D. Avoid Fluoride mouthwash
- E. Avoid High Flouride toothpaste

# PEDO+ORTHO

## P.O.W.E.R NOTES SBQ 14

I. Caramel muesli bar is the most cariogenic because it contains sugar and it is sticky. Rice milk still has carbohydrate/sugars. Juices contain sugar. Fresh fruits still have sugars. Plain popcorn is neutral. So, least cariogenic is plain popcorn.

II. N2O helps in relieving asthma

### ABSOLUTE CONTRAINDICATION FOR N2O:

- COPD
- Psychiatric pt
- Not able to wear the mask
- Bleomycin medication used in cancer
- Air cavities in the body
- Previous hx of middle ear surgery
- Pneumothorax
- Bowel obstruction
- Presence of alveolar bullae
- Malnourished pt
- Altered B12 metabolism

### RELATIVE CONTRAINDICATION FOR N2O

- Claustrophobia
- Nasal obstruction
- Uncooperative behaviour
- If you are using electro surgery or laser surgery

III. Child is at a high caries risk. In high caries risk age 18months to 6yrs, 500ppm tooth paste more frequently or 1000ppm tooth paste twice daily is recommended.

IV. Patient is allergic to adhesives in rubber band aids. so, fluoride varnish should be avoided.

# PEDO+ORTHO

## SBQ 15

**A 9-YEAR-OLD HAD UNDERGONE TRAUMA AFTER A BASKETBALL GAME. COMPLICATED CROWN # ON 11 PIN POINT EXPOSURE HORIZONTAL ROOT # ON 21 - XRAY GIVEN! AND PICTURE GIVEN**

### I. What would be the treatment?

- A. Partial pulpotomy on 11 and flexible splint on 21 for 4 weeks
- B. Dpc on 11, flexible splint on 21 for 2 weeks
- C. Pulpectomy on 11 and splinting on 21 for 2 weeks

### II. Which has the poorest prognosis in root fracture?

- A. Cervical
- B. Middle
- C. Apical

## P.O.W.E.R NOTES SBQ 15

- I. In case of pinpoint exposure or in complicated crown # in immature permanent teeth- pulp capping or partial pulpotomy is indicated.  
Horizontal root #- flexible splint for 4weeks.  
DPC in 11 is ideal but splint for 2weeks is incorrect. So, option (B) is ruled out. And option (A) is correct.
- II. Apical root # has the best prognosis and cervical root # has the worst prognosis.

# PEDO+ORTHO

## SBQ 16

A LADY BROUGHT HER 4 YR OLD CHILD FOR CARIES TREATMENT WITH PAIN FOR TWO DAYS. HE IS BEHIND HIS AGE GROUP CHILDREN IN DEVELOPMENT U ASK HIM WHAT'S HIS PROBLEM AND HE MOVED HIS HEAD TO DENY ANY PROBLEM . LESS WEIGHT , IN 20 TH PERCENTILE OF WEIGHT AS PER AGE MOTHER HAS A FAMILY HISTORY OF DEPRESSION AND ANXIETY .

**I. Child shows Frankel 3 behaviour, nothing to refuse about. Which condition will make it difficult to handle him?**

- A. His mental development
- B. Age
- C. Underweight
- D. His mother's psychological situation

**II. 85 is carious n painig continuously for 2 days,waking him up at night, what it is?**

- A. Reversible pulpitis
- B. Irreversible pulpitis
- C. Hypersensitivity
- D. Degeneration

**III. How will you treat him?**

- A. Dpc
- B. lpc
- C. Pulpotomy
- D. Pulpectomy

**IV. How will you restore him after treatment?**

- A. RMGIC
- B. Composite resin
- C. POLYACID modified resin
- D. Ssc

**V. What is the first thing u do while treating this boy**

- A. Tell show do
- B. Voice control
- C. All other options were behavior management (option was - Protective stabilization)
- D. Home
- E. Ask tell do



# PEDO+ORTHO

## P.O.W.E.R NOTES SBQ 16

I.

Table 1. Frankl Scale		
Rating 1	Definitely negative	Refusal of treatment; crying forcefully, fearful, or any other evidence of extreme negativism
Rating 2	Negative	Reluctance to accept treatment; uncooperative; some evidence of negative attitude but not pronounced, i.e., sudden withdrawal
Rating 3	Positive	Acceptance of treatment; at time of cautious; willingness to comply with the dentist, at time with reservation, but patient follows the dentist's directions cooperatively
Rating 4	Definitely positive	Good rapport with dentist; interested in the dental procedures; laughing and enjoying the situation
Survey Instrument		

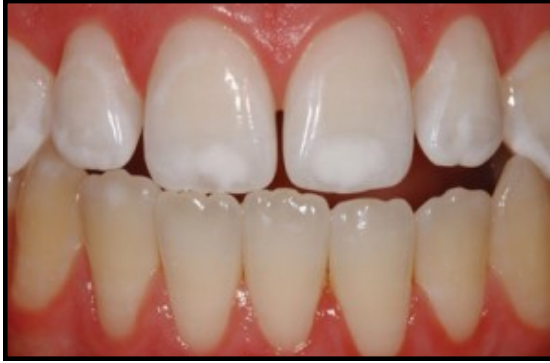He's mentally behind his age group. Frankel 3 is positive behaviour.

- II. Continuous, spontaneous pain is associated with irreversible pulpitis.
- III. Irreversible pulpitis is treated with pulpectomy in primary teeth.
- IV. Multiple surfaces are involved with dental caries. SS crown is the best in this situation to give strength to the grossly destructed teeth.
- V. Frankel 3 is not much involved with negative behaviour. So, voice control is not needed. Hand over mouth technique is not used now. No protective stabilizers/no constraints are used. So, tell-show-do is the best.

# PEDO+ORTHO

## SBQ 17

A GIRL 16 YRS OLD CM LIVING IN A NON-FLUORIDATION AREA, HAD ORTHO T/T IN THE PAST. PIC GIVEN YELLOW N WHITE LESIONS. NOT ABLE TO MAINTAIN GOOD ORAL HYGIENE DURING ORTHO T/T.



### I. How will u t/t her most conservatively

- A. Microabrasion wid 18% hcl n later pumice n something (resin infiltration)
- B. Intra oral sandblasting followed with unfilled resin infiltration and resin composite
- C. Daily home bleaching 10% + cpp acp (it was carbamide 10% + cpp acp)
- D. Composite restoration removing defective enamel first
- E. Covering complete buccal surface with resin composite

### II. Action of saliva to help reduce the risk of caries:

- A. Neutralize the acid of the food
- B. Remineralisation of enamel
- C. Attacks bacteria acids
- D. Lubricates mucosa and tongue
- E. Enamel more resistant to acid dissolution

### III. You don't think it might be incipient caries. What May be the reason to exclude the caries

- A. Carious lesion in ortho treatment looked like white lesion
- B. She has no pain or sensitivity
- C. The white spot is beneath the location where Ortho brackets were placed

# PEDO+ORTHO

## P.O.W.E.R NOTES SBQ 17

- I. Yellowish discolouration can be treated with bleaching technique. White colour spots are orthodontics demineralisation spots and can be treated with CPP-ACP. It's the most conservative method. Sand blasting, micro abrasion and composite restorations are not required.
- II. Saliva helps in remineralization by releasing Ca and other ions. It neutralizes the acid in food will not help in reducing caries. But by neutralizing the acid in the plaque will help in reducing caries. So, option (A) is ruled out.

**SALIVA HAS GOT 2 MAIN FUNCTIONS:**

1. Neutralise/buffer the acid in the plaque and remineralise the enamel by giving saturating Ca ions. And caries prevention.
2. Increased pH gives  $\text{Ca}^{2+}$ , phosphate ions. This leads to calculi formation and remineralisation.

It has got antibacterial properties as saliva has got enzymes.

- III. Incipient caries and orthodontic spots appear very similar but can be differentiate with the given history and the location. Incipient caries are usually located at the gingival margin and the orthodontic demineralising spots are located where the brackets used to be.

# PEDO+ORTHO

## SBQ 18

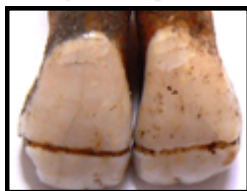BOY WITH RHEUMATIC HEART DISEASES, STAIN IN HIS ANTERIOR UPPER TEETH, BROWN HORIZONTAL LINE CERVICAL THIRD ON 22,21,11,12, SOME ARRESTED CARIES, SOME ACTIVE CARIES ON ANTERIORS. WHAT COULD BE THE REASON(WHITE BROWNISH STAIN) RHEUMATIC FEVER, ABP HE WAS STAYING IN A NON FLUORIDATED AREA HE IS NOW 12 YEARS HE CAME TO LIVE WITH HIS AUNT RECENTLY WHO IS ON PENICILLIN MONTHLY FOR RHEUMATIC FEVER CARIES ON 11,21,12,22.

### I. Reason for his black stain?

- A. Arrested caries
- B. Incipient
- C. Rampant and active caries
- D. Arrested and rampant caries
- E. Beginning of arresting of caries (picture had partial brown and white appearance)

### II. Possible reason for the horizontal line on the gingival third 12,11,21,22 (There was a horizontal line in cervical third)?

- A. Tetracycline
- B. Lots of sugary drink consumption
- C. Trauma in this early life
- D. Disturbances of enamel development at 1 year old
- E. During the development of permanent teeth defect in amelogenesis
- F. Fluorosis



### III. You also think this might be fluorosis. What makes you think that this child might have fluorosis

- A. Ingestion of adult fluoride toothpaste
- B. Fluoride tablet supplementation as a child
- C. Fluoride mouthrinse

### IV. You decide to do fillings on 11,12,21,22 (it specified using of cotton rolls).

What is correct about ABP he was 40 kgs

- A. No abp needed
- B. Amox 2 g orally 60 mins before
- C. 50 mg/kg body weight of Amox 60 mins before
- D. Ampicillin 2g iv 60 mins
- E. Ampicillin 2g Im 30 mins

# PEDO+ORTHO

## P.O.W.E.R NOTES SBQ 18

- I. Rampant and active caries are yellowish in colour. Incipient caries appears white in colour. Arrested caries is black in colour.
- II. Caries can't be a straight line. There's depression along with the line. So, it's hypoplasia. If there's no depression, then it could be hypo mineralisation. Tetracycline stains give a shadow like staining on the teeth. And there should be a history of tetracycline use. Trauma in the childhood will give a localised hypoplastic spot. This incisal area develops at the age of 1yr. and that incisal area is involved in this case. Fluorosis will appear as flecks rather than demarcation seen here. So (D) is the best answer among the given.
- III. Other than the hypo mineralisation due to the developmental disturbance's fluorosis can give brown/white spots. Patient lived in a non-fluoridated area when he was very young. So, he must not have been taken mouth rinses. Ingestion of fluoride toothpaste is rare. And it must have reported. Fluoride tablet supplementation has banded in Australia few years ago. Child is 12yrs now. So, he might have a hx of fluoride tablet supplementation.
- IV. His medical condition may require AB prophylaxis. But for restorations AB prophylaxis is not required. If it's an extraction AB prophylaxis is needed.

# PEDO+ORTHO

## SBQ 19

PATIENT HAS UNDERGONE ORTHO TREATMENT AS WELL SHE'S 16 YEARS OLD, SHE IS HAPPY WITH ORTHO ALIGNMENT BUT NOT HAPPY WITH THE STAINS, HYPOPLASTIC SPOTS, AS A BABY SHE SUFFERED A CHRONIC EAR INFECTION AND AT 11 YEARS OF AGE SHE SUFFERED CHICKEN POX

### I. What is your differential diagnosis

- A. Enamel Hypomineralisation
- B. Enamel hypomineralization
- C. Incipient caries
- D. Tetracycline stains
- E. Chronological hypoplasia

### II. You come for a provisional diagnosis of molar incisor Hypoplasia What makes you think that the reason for MIH is?

- A. Her history of chronic ear infection as a baby
- B. Her chickenpox history
- C. Nutritional disturbance during childhood.

### III. What treatment would you do she is concerned about her aesthetics

- A. Composite restoration on labial defects
- B. Resin Composite on whole labial surface
- C. Porcelain veneers
- D. All ceramic crowns
- E. RMGIC

# PEDO+ORTHO

## P.O.W.E.R NOTES SBQ 19

- I. Orthodontic Rx can give orthodontic demineralisation spots which are white in colour, they are not hypoplastic spots.  
There will be depressions and enamel protein matrix disturbances in hypoplastic spots, and it will take place during enamel formation. It's a formative and developmental defect. It happens only in certain teeth and not in all teeth. So, the differential diagnosis is chronological hypoplasia.
- II. At the 11yrs of age anterior teeth are already formed. So, chicken pox is not associated with teeth formation. But the patient suffered with an ear infection when she was a baby, front teeth will be developing at that age. So, chronic ear infection is linked with the hypoplastic defects. So, the differential diagnosis is chronological hypoplasia.
- III. Patient is concerned about the aesthetics. She's still 16yrs old. So, porcelain veneers and ceramic crowns are ruled out.

Technique	Advantages	Disadvantages
Full resin composite veneers	No destruction of tooth tissue, reversible and generally well tolerated even by anxious children. Excellent aesthetic result possible and easy to maintain.	Discolour with time. Tendency to fracture if placed at/over the incisal edge.
Enamel microabrasion	Minimal destruction of enamel, if carefully performed. Technique well tolerated.	Unpredictable. Teeth may rarely suffer postoperative sensitivity. Accidental exposure of dentine is possible where enamel is thin.
Localized resin composite restoration	Enamel destruction limited to defect, and full thickness need not be removed if opaque resin composite shades are used. Good aesthetic result possible.	Irreversible. Weakens tooth structure and large areas of dentine may be uncovered. Colour change and marginal discoloration with time.
Porcelain veneers	Good appearance.	Contraindicated in this age group because gingival contour not mature and stable tooth position not yet established.
Full-crown restoration	Good appearance.	Inappropriate until late second decade because immature pulp horns may be exposed. Gingival contour not mature and stable tooth position not yet established.

### FULL RESIN COMPOSITE VENEERS:

- No destruction of the tooth tissue
- Excellent aesthetic results

### RESIN COMPOSITE RESTORATIONS:

- Enamel destruction limited to defect
- Good aesthetic results

Therefore, composite veneers are better than composite restorations.



# PEDO+ORTHO

## SBQ 20

**TRAUMA CASE , LOOKED LIKE A ROOT FRACTURE**

**IOPA WAS GIVEN, IF U ARE NOT HAPPY WITH THE GIVEN IOPA**

### I. What is the best radiograph to give the diagnosis

- A. CBCT
- B. Two IOPA in a different angle
- C. OPG
- D. Occlusal

### II. Who is the best to treat this case

- A. Endodontist
- B. Orthodontist
- C. Periodontist
- D. Oral surgeon

### III. Question about malocclusion (83 lost and midline shift)

**OPG and pictures given. Which class of malocclusion this is**

- A. Class 1 with lower midline shift
- B. Class 2 div 1 with lower midline shift
- C. Class 2 div 2 with lower midline shift
- D. Class 3 with lower midline shift

### IV. What would be the best treatment that could have been done to avoid the midline shift

- A. Elective Extraction of 73
- B. Band and loop appliance
- C. Lingual arch involving all anterior teeth



# PEDO+ORTHO

## P.O.W.E.R NOTES SBQ 20

### I. RECOMMENDED RADIOGRAPHS IN “ROOT FRACTURE”

- One parallel periapical radiograph
- Two additional radiographs of the tooth taken with different / horizontal angulation
- Occlusal radiograph
- Root # may be undetected without additional images

In case where the above radiographs provide insufficient information for the treatment planning CBCT can be considered to determine the location, extent and direction of the #.

- II. Endodontist will be the best to treat in the presence of a root #. The coronal portion of the root need treatment.
- III. Pictures are required to answer this question.
- IV. When there's primary canine is missing in one side it leads midline shift. To avoid this balancing extraction should be done.

# PEDO+ORTHO

## SBQ 21

BOY 4 YO, MOTHER CAME BECAUSE SHE DOESN'T LIKE THE LOOK OF HIS UPPER FRONT TEETH 52 AND 62 THIRD CERVICAL WITH ACTIVE CARIOUS. HE HAS ASTHMA AND ECZEMA AND IS HAVING DRUGS FOR BOTH, LIVES IN UN FLUORIDATED AREA MOTHER SAID SHE BRUSHES HIM MANUALLY WITH A MANUAL TOOTHBRUSH AND TOOTHPASTE WITH NO FLUORIDE. HAS ASTHMA.

### I. What recommendation you give?

- A. Use electric tb with her normal toothpaste
- B. 500 ppm children's toothpaste twice daily
- C. 1000 ppm children's toothpaste twice daily
- D. 1500 ppm adult toothpaste twice daily
- E. 5000 ppm adult toothpaste twice daily

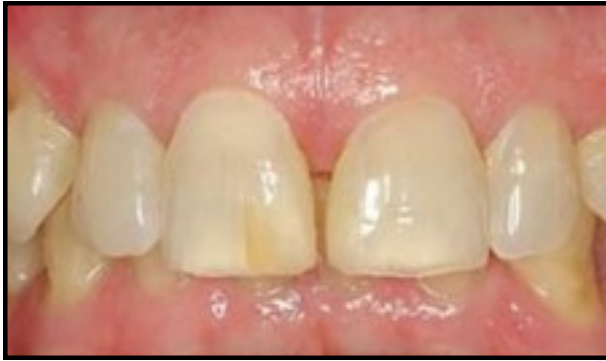### P.O.W.E.R NOTES SBQ 21

- I. Patient lives in a un fluoridated area. Brushes with a toothpaste with no fluoride. Patient is a high caries risk. 500ppm will not work for high caries risk patient. Patient is 4yrs. So, adult toothpaste is not recommended. So, child toothpaste with a high fluoride concentration can be prescribed.

# PEDO+ORTHO

## SBQ 22

CHILD 14 YO FROM A REMOTE COMMUNITY, JUST MOVED TO LIVE IN THE CITY. NO CARIES OR GINGIVAL INFLAMMATION. PICTURE OF THE ANTERIOR GIVEN, 12 TO 21 LOOKED FLAT AND SHARP FROM ANTERIOR. (BOTH CENTRALS HAD TRANSLUCENT INCISAL EDGE AND SHARP)



SAID THAT HE TAKES SALBUTAMOL INHALER (OCCASIONALLY) AND A STEROID PREVENTER FOR ASTHMA. HE COMPLAINS OF FEELING THAT HER UPPER FRONT TEETH ARE SHARP. CAN SEE MILD EROSION OF THE LABIAL OF INCISORS. PLAYS SOCCER AND CYCLES. VEGETARIAN. ON EXAMINATION, MINIMAL/NO PLAQUE, NO INFLAMMATION, NO CARIES. HE PLAYS SPORTS AND CYCLING. MENTIONED THAT HE DOESN'T DRINK MUCH WATER. HE FORGETS.

I. Based on the examination and social history, you suspect (provisional diagnosed) erosion What is the likely cause of erosion?

- A. Sports drinks
- B. Sweetened confectionary
- C. Vegetarianism
- D. Reflux
- E. Salbutamol

II. You discuss the cause of erosion with pt and advice management (here dentist made dx of erosion. Then how to manage)

- A. Talk to GP about changing the inhaler meds
- B. Limit sugar intake ( no caries mentioned)
- C. Advice to add meat on his diet
- D. Advice pt to not brush after drinking sports drink. (mouthwash 1000 ppm after sports)
- E. See GP for suspect of acid reflux issue (no history and mentioned only front teeth)

# PEDO+ORTHO

## P.O.W.E.R NOTES SBQ 22

- I. There's erosion on the buccal surface of the teeth. Sharpness and the translucency are due to the erosive wear. He uses salbutamol inhaler and steroid preventor for asthma. In the history it's not given that the patient drinks sports drinks. If it's given in the hx then sports drinks would be the predominant cause for erosion. When he's not drinking sports drinks or not even drinking water, the other acidic exposure that he's going through is salbutamol and asthma related drugs.

Asthmatic medication can place the patient at risk of dental erosion by reducing salivary protection against extrinsic or intrinsic acids. Asthmatic individuals are one of the higher risk groups suffering from dental erosion.

- II. When a sports person drinks sports drinks, we do not ask him to stop using sports drinks. Instead we ask them to alternate or rinse with water to wash it off/ neutralise / buffer the acidic environment.

If the patient has a hx of taking sports drinks, then it will be our main concern. Sports drinks have sugar, so it has relatively high risk for both caries and erosion. This child doesn't have caries but has erosion. But sports drinks have a potential to cause both. Because it is not sticky, erosions more likely.

Since the patient uses salbutamol inhaler which causes erosion, always good talk with the GP regarding changing the medication. And advice the patient to use the spacer while using the inhaler.

# PEDO+ORTHO

## SBQ 23

**YOUNG BOY - DOESN'T BRUSH PROPERLY - DOESN'T FLOSS - HYGIENE SATISFACTORY - BEEN APPLYING F VARNISH FOR 6 YEARS NOW, EVERY 6 MONTHS - SPORTS PLAYER, BUT DOESN'T LIKE SPORTS DRINKS - EATS SUGAR IN EVERY MEAL, BUT IN BETWEEN MEAL SNACK IS CHEESE AND FRUIT. NOT MUCH CARIES, JUST ENAMEL DEMINERALIZATION IN ONE TOOTH (16)**

### **I. You do caries risk assessment, what is important in his low caries risk?**

- A. The fact that he is a regular Fluoride varnish attendee
- B. He doesn't snack in between on cariogenic foods
- C. He doesn't drink sports drink

### **II. The best way to improve his oral health?**

- A. Decrease sugar DURING meals
- B. Fluoride application
- C. Sport drinks

## **P.O.W.E.R NOTES SBQ 23**

- I. Fibrous fruits are non-cariogenic. Acidic fruits are low cariogenic. Fruit is never a highly cariogenic.**

**Amongst the diet and fluoride application, fluoride application has a caries reducing property.**

**Amount of free sugars / frequency of free sugars has increased caries risk.**

**Fluoride exposure, hard cheese, sugar free chewing gum, xylitol, milk, dietary fibre, whole fresh fruit have decreased caries risk.**

**Eliminating sugar will reduce the caries risk. But when both sugar intake and fluoride are given, fluoride will prevent more than eliminating sugar.**

- II. He's not taking sports drinks. He's already taking fluoride treatment. So, the best way to improve his oral health is decrease sugar during meals.**

# PEDO+ORTHO

## SBQ 24

**A GIRL - AGE 13 - COMES WITH MOM - WANTS TONGUE PIERCING - DOESN'T BRUSH PROPERLY - HAS SEEN HER SCHOOL ELDER FRIENDS GET PIERCINGS FROM TATTOO PLACES - SO SHE ALSO WANTS ONE - BUT AFRAID THEY ARE NOT CLEAN. MOM RECENTLY DIVORCED, AND MOM IS A BUSY LAWYER - DAUGHTER SAYS TO DENTIST "I KEEP WORRYING ABOUT A LOT OF THINGS RECENTLY"**

**I. What is the most important barrier that you will need to overcome to improve the child's oral health?**

- A. Teenage behavior
- B. Lack of mothers support
- C. His oral hygiene practices

**II. Mum is very apprehensive or unhappy about tongue piercing. A Lot of kids have got infections from tongue piercings. What will be your advice to the child?**

- A. Refer to oral surgeon to manage complications
- B. Ask mother to check if the tattooist is using sterilized instruments
- C. Get piercing at older age ( when adult)
- D. Discourage her in getting piercing

## P.O.W.E.R NOTES SBQ 24

**I. Teenagers are capable in doing oral hygiene practice alone. So, having a divorced mother is not a barrier to maintain her oral hygiene. Child doesn't brush properly and that's the barrier that you need to overcome. So, you need to educate and motivate the patient.**

**II. Reference:**

*Intra oral and peri oral piercing are invasive procedures that carry significant local and systemic health risks. Complications include infections, swelling bleeding nerve damage, chipped teeth, gum recession, alteration to speech and swallowing or inhalation of lost or damaged piercings.*

*Other irreversible body modifications of the oral cavity including of the natural dentition should not be performed and dental practitioners should discourage individuals from having body modification in their oral cavity.*

**So, according to the guidelines, discourage her in getting piercing.**

# PEDO+ORTHO

## SBQ 25

PATIENT 12 YEARS OLD, CAME WITH 75 AND 85 WITH VARIOUS LESIONS. NO PERMANENT SUCCESSORS PRESENT SO YOU WANT TO TRY TO PRESERVE THEM AS LONG AS POSSIBLE. UPON XRAY YOU SEE 75 HAS A SMALL RADIO LUCENCY IN THE FURCATION, WHAT'S THE BEST TREATMENT FOR THIS TOOTH?

- A. Pulpotomy
- B. Pulpectomy
- C. Extraction
- D. Ipc

## P.O.W.E.R NOTES SBQ 25

- I. Once the furcation is involved in the primary teeth the best option is to extract them. But in the given hx it's mentioned that no permanent successors present so you want to preserve them as long as possible, in this case you may need to perform pulpectomy.

# PEDO+ORTHO

## SBQ 26

12-YEAR-OLD GIRL IS LEAVING ABROAD SOON, AND CAME FOR A GENERAL CHECK-UP. YOU DID TREATMENT WHEN SHE WAS YOUNG, PRIMARY TEETH THAT WERE ALL OKAY BUT SHE RETURNS AFTER A FEW YEARS, ANTERIORS ARE HYPOMINERALIZED. WHAT IS THE REASON FOR LESIONS (IMAGE SHOWING ANTERIORS - HORIZONTAL WHITE HYPOPLASTIC BANDS)

- A. Amelogenesis imperfecta
- B. Dentinogenesis imperfecta
- C. Dentin dysplasia
- D. Chronological hypoplasia

## P.O.W.E.R NOTES SBQ 26

- I. In amelogenesis imperfecta, dentinogenesis imperfecta and dentine dysplasia both primary and permanent teeth are affected. In the history it is mentioned that the primary teeth are ok. So, (A), (B), (C) are ruled out. Chronological dysplasia can happen due to childhood disturbances and nutritional disturbances.



# PEDO+ORTHO

## SBQ 27

**PATIENT'S PARENTS WERE WORRIED ABOUT THE RADIATION FROM BITEWING.**

### I. How will you reassure them?

- A. By telling them it's just a small exposure
- B. By telling it will not radiate to any of his body parts
- C. Bitewing radiograph is essential otherwise we cannot continue the treatment
- D. Continue without x-ray
- E. Tell them study shows that it doesn't cause cancer

### II. Safest material for internal bleaching?

- A. Sodium perborate
- B. Carbamide peroxide 10%
- C. Hydrogen peroxide 30%
- D. H<sub>2</sub>O<sub>2</sub> 3%

## P.O.W.E.R NOTES SBQ 27

- I. X-rays have the potential to cause cancer. X-ray causes cancer with exposure quantity. So, (E) is ruled out.

If the x-ray is needed for the diagnosis and treatment planning, we can't continue the procedures without x-ray. So, option (D) is ruled out.

It's not the professional management of patient's and parent's concern. So, option (C) is ruled out.

By telling them it will not radiate to any other body parts It will not prevent the secondary radiation. So, option (B) is ruled out.

- II. Hydrogen peroxide 30% is a chairside material. Carbamide peroxide 10% which release peroxide 3% is used for home bleaching. Sodium perborate is used for non-vital bleaching (walking bleaching).

# PEDO+ORTHO

## SBQ 28

**I. 12yrs old boy marginal ridge carries.no pain.**

- A. Ssc and pulpotomy
- B. Gic
- C. Composite
- D. SDF
- E. No treatment

**II. Don't remember the complete question. But it was about extracting 12 on a child patient and doing what for rehabilitation.**

- A. Extract 12 and wait for 13 to erupt into its place
- B. Extract and give an immediate cast cobalt denture
- C. Extract and give implant in the empty space

## P.O.W.E.R NOTES SBQ 28

- I.
  - Marginal ridge is the cumulation of proximal and occlusal surfaces. It's a complex area.
  - GIC is not used as a permanent restorative material in primary or in permanent teeth.
  - Pulpotomy/ SDF is not required in marginal ridge caries. SDF is used to arrest the caries but it causes severe discolouration.
  - You will not leave a carious tooth with cavity without any treatment.
- II. Ideal treatment is to extract 12 and give acrylic denture for the space maintenance. 13 will not erupt in the place of 12, therefore, orthodontic bodily movement is needed. Implants are not given at the age of 12yrs. And can be given after 18yrs.

# PEDO+ORTHO

## SBQ 29

**I. Picture with brown-black cervical lesion and have brown line defect in cervical third. What is this lesion in the picture?**

- A. Incipient caries
- B. Progressing arrested caries
- C. Abrasion
- D. Disturbance in amelogenesis in early age
- E. Fluorosis

**II. Cervical lesions best long term material to fill on the front teeth, Photo the caries is very near the cervical areas, and class 4 caries.**

- A. Compomer
- B. Gic
- C. Amalgam
- D. Polyacid resin modified composite
- E. Zinc polycarboxylate cement

# PEDO+ORTHO

## P.O.W.E.R NOTES SBQ 29

- I. Incipient caries appears white. Arrested caries appears brown black. Amelogenesis imperfecta and fluorosis usually affect generally not in a single tooth. Abrasion is the non-carious, mechanical wear of tooth from interaction with objects other than tooth-tooth contact.
- II. In anterior teeth you concern about the aesthetics so, options (B), (C), (E) are ruled out. RMGIC has better retention in cervical area than compomer as it chemically bonds without a bonding agent.

CHARACTERISTIC	COMPOMERS	RMGICs Resin-Modified Glass Ionomer Cements)
Composition	Resin matrix with glass filler particles	Glass ionomer core with resin component
Setting Mechanism	Primarily light-cured with some acid-base reaction	Dual-setting: light-curing followed by acid-base reaction
Fluoride Release	Moderate, diminishes over time	Higher, sustained release
Physical Properties	Better aesthetics (translucency, color match), higher wear resistance	Lower wear resistance, more opaque
Bonding to Tooth Structure	Requires bonding agent, less moisture tolerance	Chemically bonds without bonding agent, better moisture tolerance
Clinical Applications	Anterior/posterior restorations, paediatric dentistry	Non-load bearing areas, high-caries-risk patients
Handling	Easier to sculpt and achieve fine details	Slightly challenging but improved compared to traditional glass ionomers
Aesthetic Properties	High, suitable for visible areas	Adequate for non-aesthetic areas

# PEDO+ORTHO

## SBQ 30

**PATIENT 12 YEAR OLD COMES TO YOU WITH MOTHER, SHE HAD AN ORTHO TREATMENT FROM AN OVERSEAS DENTIST BUT THE DENTIST DID NOT INFORM THE PATIENT REGARDING HIS MISSING PREMOLAR AND ANKYLOSED DECIDUOUS MOLAR. SHE HAS A GAP. SHE WANTS TO COMPLAIN.**

### **I. What should you professionally advise her?**

- A. Leave as he is an overseas dentist
- B. Write to the local authority body where treatment done
- C. Write to the treating dentist
- D. Put in social media about that dentist
- E. Write letter to newspaper about

### **II. What is the common source of fluorosis for children in non-fluoridated area?**

- A. Swallowing adult toothpaste 1000- 1500mg
- B. Daily sodium fluoride tablet 1mg daily

### **III. Patient couldn't quit smoking for the past 10 years. But in the last month he quit smoking and vapes an electronic cigarette only. What advice which has scientific evidence you should provide?**

- A. E cigarette has chemical compound that induce cancer
- B. E cigarette is best nrt you should continue
- C. E cigarette has proved to help in quitting smoking.
- D. If you have any symptoms contact the medical doctor.

### **IV. Pt had a history of smoking for 5 years. When you told her I'm ready to give help if she wishes to quit smoking ,she replied I'm not an addict i can quit even now.. you diagnosed her attitude prevents her from quitting smoking. what is the evidence based strategy you should provide?**

- A. Reassure her that health benefits of quit smoking accrue at any age (same words)
- B. Acknowledge her and explain positives of quit smoking(same words)
- C. Tell the fact that if she doesnt quit smoking can cause serious health problems..
- D. Give quit smoking pamphlet and contact details

### **V. How to use cpp-acp?**

- A. Place it finger apply to teeth spread using tongue.
- B. Use with mouthwash
- C. Use pea size on finger , apply on teeth for 3 min , and spit out .
- D. Use tooth brush to apply
- E. Use tray to apply

# PEDO+ORTHO

## SBQ 30

VI. You have to work with technician in order to make new partial denture, Which of these item you may not task the laboratory in order to maintain your professionalism?

- A. Frame design
- B. Final polishing material
- C. Ridge Contour
- D. Clasp selection
- E. Treatment plan

## P.O.W.E.R NOTES SBQ 30

I. Patient wants to complain about an overseas dentist as they are disappointed with the treatment. You should not involve in the middle of the situation rather you should encourage the patient to communicate with the overseas dentist.

### THE PROTOCOL THAT WE FOLLOW:

1. Recommend them to discuss with their dentist; if the patient doesn't want to talk to their previous dentist then,
2. Request dental records and discuss findings; if the patient is still not happy,
3. Give details of the organisations to complain; AHPRA and ACCC

II. Swallowing the adult toothpaste is an incorrect option, so answer is (B).

III. All e-cigarettes, even those that don't contain nicotine, can contain dangerous substances in the liquid and the aerosol. These can include number of known cancer-causing agents. Such as:  
Formaldehyde, acetone, acetaldehyde, heavy metals like nickel, tin, lead

### Direct health risks of vaping:

- Irritation of the mouth and airways
- Persistent coughing
- Nausea and vomiting
- Chest pain and palpitations
- Poisoning and seizures from inhaling too much nicotine or ingestion of e-liquid
- Burns or injury caused by e-cigarette overheating or exploding
- Nicotine dependence
- Respiratory problems and permanent lung damage
- Harm to developing adolescent brain
- DNA damage

*E-cigarettes don't produce the tar found in the conventional cigarettes which is the main cause of lung cancer. However, many scientists are concerned that vaping could increase the risk of lung disease, heart disease and cancer.*

# PEDO+ORTHO

## P.O.W.E.R NOTES SBQ 30

IV. Patient is not acknowledging that he's addicted to smoking. Her attitude is preventing her from quitting. You can't threaten and scare the patient. It's always good to explain the health benefits of quitting rather than saying the side effects of smoking.

V. **Reference TG:**

Table 8. Examples of topical fluoride applications for patients at elevated risk of dental caries [NB1] (cont.)	
Formulation	Usual directions for use
fluoride+CPP-ACP 900 ppm+10% cream	Use in adults and children for noncavitated white spot lesions twice daily after brushing with usual fluoride toothpaste.  Patients should apply the cream to the teeth, hold in the mouth for 3 to 5 minutes, spit out excess and avoid rinsing the mouth [NB2].

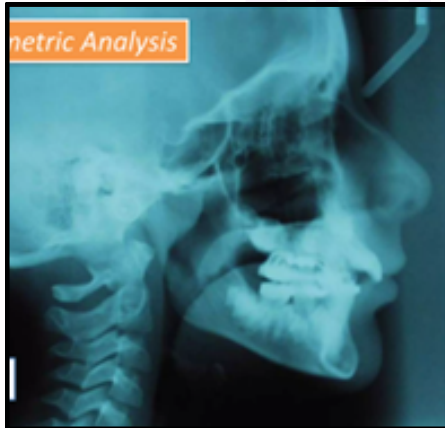VI. As a dentist you won't discuss or take their help in treatment planning. But you can discuss about the frame design, final polishing material, ridge contour, clasp selection with the technician.



# PEDO+ORTHO

## SBQ 31

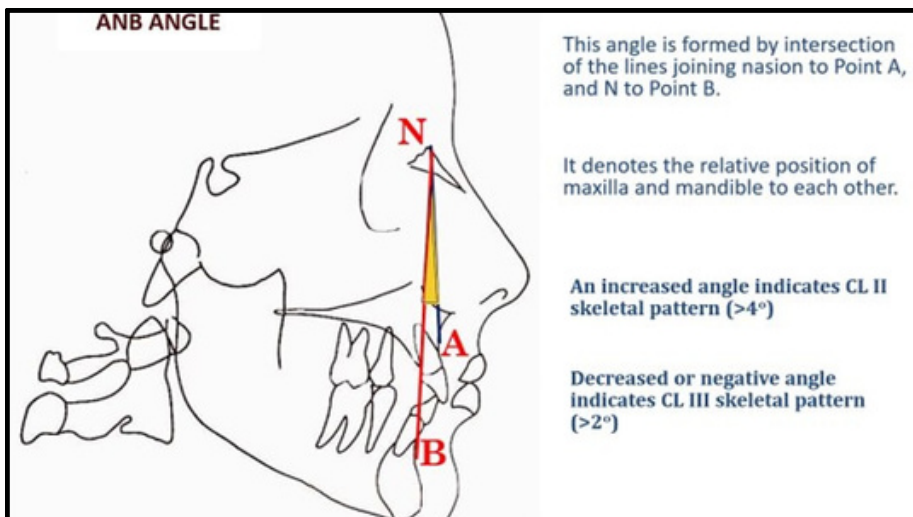
CHILD WAS ABOUT 11 YEARS OLD. LATERAL CEPHALOGRAM OF A CHILD GIVEN ASKING WHICH SKELETAL MALOCCLUSION IS THIS.( MOLAR RELATIONSHIP WAS NOT CLEAR - 1ST MOLAR WERE RETAINED).CENTRAL INCISORS: 11 WAS EDGE TO EDGE IN THE PICTURE, 21 WAS NORMAL .WHAT IS THE SKELETAL RELATIONSHIP?



- A. Class 2 div 2
- B. Class 1
- C. Class 3
- D. Cannot determine malocclusion pattern by only lateral cephalogram
- E. Class 2 div 1

## P.O.W.E.R NOTES SBQ 31

Look at the point nasion, A and point B. It's greater than 4degree. There's incisor inclination and overjet. So, it's class 2 div 1. If the incisors are retroclined, then it's class 2 div 2.





# PEDO+ORTHO

## SBQ 32

12 YEAR OLD MARYAM KNOCKED OUT HER FRONT TOOTH. MOTHER IS A RELATIVE OF YOU. YOU KNOW MOTHER IS VERY LOUSY (MOTHER IS VERY VOCAL ABOUT HER DAUGHTER IN FAMILY GATHERINGS, CAME TO YOU AFTER 6 HRS AND TOOTH WAS WRAPPED IN PLASTIC PLACED NEXT TO ICE IN THE LUNCHBOX. CHILD CALLED THE MOTHER AFTER A FEW HOURS ABOUT WHAT TO DO WITH THE KNOCKED TOOTH. SHE INSTRUCTED TO WRAP IT IN PLASTIC. THEY CAME TO YOUR CLINIC WITH THE KNOCKED TOOTH. SHE HAD CLASS 2 MALOCCLUSION

### I. What is the viability of periodontal ligament?

- A. Non-viable
- B. Might be viable but less functional
- C. Highly viable
- D. Viable compromised
- E. Viable uncompromised

### II. Your cousin is very upset and unhappy when you explained her the complications that can occur. She thinks the tooth will be back to normal and is not ready to accept otherwise. She wants the tooth to be fixed. How will you manage this?

- A. Advise her that you will refer her to a paedodontist right after fixing the avulsed tooth
- B. Reassure her that you are in the best position to manage this
- C. Ask her to trust you because you're a qualified professional beyond being her cousin
- D. Ask her to reconsider the matter and explain to her that she can call you any time for support and advise

### III. To prevent further injury while playing football what would be your best advice to the child?

- A. To use custom mouth guard while playing football
- B. Correct class 2 malocclusion
- C. Stabilise maxilla

### IV. What to tell Maryam regarding tooth avulsion if happens next time?

- A. Rinse in cold water for ten minutes and bag it
- B. Hold the tooth from the yellow part
- C. If can't visit immediately, put it in milk
- D. Keep it in the buccal vestibule

### IV. What is the best medium to be used for avulsion.

- A. Milk
- B. Water
- C. No medium
- D. Saliva and keep the tooth in box

# PEDO+ORTHO

## SBQ 32

### VI. What can complicate the situation of this avulsed tooth

- A. Inflammatory resorption
- B. Ankylosis
- C. Grey or yellow discoloration
- D. Pulp canal obliteration

### P.O.W.E.R NOTES SBQ 32

- I. **The PDL cells are most likely viable.** The tooth has been replanted immediately or within a very short period (about 15min) at the place of the accident.

**The PDL cells may be viable but compromised.** The tooth has been kept in a storage medium (e.g: milk, HBSS, saliva or saline) and the total extra oral time has been <60min.

**The PDL cells are likely to be non-viable.** The total extra oral dry time has been more than 60min, regardless of the tooth have been stored in a medium or not.

- II. Tooth will not have a favourable outcome after more than 6hrs of extra oral time. But you must fix the avulsed tooth and refer the patient to the specialist. You can replant the tooth, but the prognosis will be poor.

- III. Even though class 2 injuries lead to frequent injuries, 12yrs is not the age to correct the malocclusion orthodontically. Therefore, mouth guards are mandatory to prevent from sports injuries with or without the correction of malocclusions.

- IV. In avulsion it's always good to meet the dentist immediately. But if it's not possible tooth should be kept in a storage medium (e.g.: milk, HBSS, saliva or saline).

- V. Milk is the best storage medium. Even better than HBSS.

**Milk > HBSS > saliva > saline**

- VI. Inflammatory response will lead to immediate exfoliation, mobility, loosening. Ankylosis can lead to infra occlusion and unfavourable tooth but it can maintain the space. Mobility is the worst outcome.

# PEDO+ORTHO

## SBQ 33

ETHAN 8 YEARS OLD AVULSION 11 AND 52. FATHER BROUGHT THE CHILD AFTER HE FELL ON FACE IN A RUGBY MATCH IN SCHOOL. CHILD WAS CLASS 2 DIV 1, THE TOOTH HASN'T BEEN FOUND YET AND THE COACH IS STILL LOOKING FOR IT. CHILD LOOKS CONFUSED AND NAUSEOUS. YOU ARE WAITING FOR THE TOOTH TO ARRIVE.

### I. What should you do first?

- A. Check tetanus status
- B. Check brain concussion symptoms
- C. Check dental status
- D. Radiograph the inferior lip

### II. Which tooth PRECLUDES reimplantation?

- A. Deciduous tooth can't reimplant
- B. Closed apex permanent
- C. Open apex permanent teeth after 60 minutes
- D. Tooth which has been manipulated from root

### III. What to tell the kid to prevent this from happening

- A. Wear a custom-made mouthguard
- B. Correct his malocclusion
- C. Be more careful while playing
- D. Change the sport

### IV. What will you suggest further if such types of injuries happen?

- A. Put it in milk
- B. Put it in water
- C. Hold it from yellow part of tooth

## P.O.W.E.R NOTES SBQ 33

I. When the patient has neurological signs patient should be medically checked 1st rather than looking for the dental concerns. In the hx nausea and concussion are given.

II. Deciduous teeth are not re implanted.

Patient should be advised to wear the mouth guard to prevent from getting dental trauma from sports injuries.

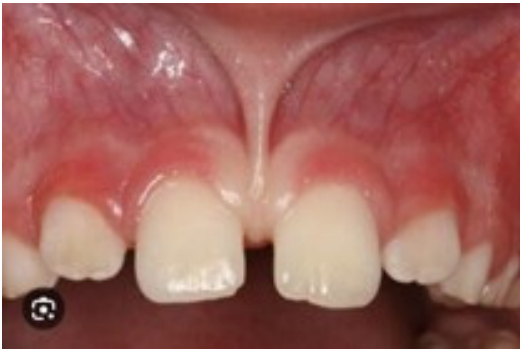Milk is the best storage medium. Even better than HBSS.

Milk > HBSS > saliva > saline

# PEDO+ORTHO

## SBQ 34

IN A RURAL AREA, JASON HE'S 10 YEARS OLD CASE AND PRINCIPAL DENTIST VISITING FORTNIGHTLY. ANOTHER DENTIST SAYS THAT THE ONLY WAY TO CLOSE THE DIASTEMA BETWEEN 11 AND 21 IS BY DOING FRENECTOMY AND THE PARENTS WITH THE CHILD COME TO YOUR PRACTICE AND THEY DON'T WISH FOR THAT PROCEDURE. CANINES AND UPPER 2ND PMS HAVE NOT ERUPTED YET. PARENTS DO NOT WANT TO GET FRENECTOMY DONE AND WANT ALTERNATIVE TREATMENTS. WHAT RECOMMENDATION YOU WILL GIVE THEM?



- A. Have to do the frenectomy, to close the diastema and then do ortho
- B. Do nothing and wait for the permanent canines to erupt
- C. If the frenectomy is done now the scar will not impede the ortho treatment.
- D. Start ortho treatment, lets the canines erupt and then do frenectomy

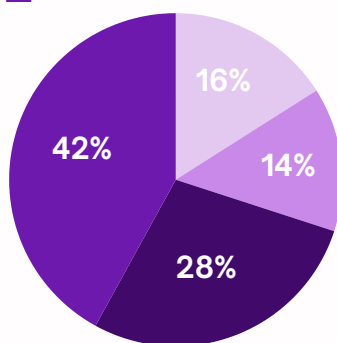
# PEDO+ORTHO

## P.O.W.E.R NOTES SBQ 34

- There are multiple things to concern in this case. Patient's age is 10yrs. Still there's time for canines to erupt and close this gap between the front teeth naturally. Some potential of closing is still there. There's a waiting period of starting the ortho treatment till the canine erupts. You must wait till the age of 12-13yrs.
- Blanch test and radiographic assessment are done to check for the abnormal frenum. Radiographic assessment – IOPA is taken to see the alveolar notch/depression.
- Frenectomy as a part of orthodontic treatment, can aid in diastema closure.
- When frenectomy is done before or after diastema closure in the presence of abnormal frenum has a better long- term stability.
- Abnormal labial frenum is also considered to be a potential cause of median diastema and has demonstrated a potential for relapse after closure with orthodontic treatment.
- Midline bony clefts can be associated with an abnormal frenum as its fibrous tissue insert into the notch in the alveolar bone. This inter-crestal bony cleft may keep the teeth apart and interrupt the formation of the transeptal fibres.
- Orthodontic relapse of median diastema was twice as great in patients with abnormal frenum compared with those with normal frenum attachment, and the risk of relapse reduced by performing frenectomy.
- Permanent retention without frenectomy can control orthodontic relapse but this can lead to cervical resorption. That's why majority advice to proceed with frenectomy.

### TIMING OF FRENECTOMY IN RELATION TO ORTHODONTIC SPACE CLOSURE

- Before starting orthodontic Rx
- Timings doesn't matter
- Just before diastema closure
- After diastema closure



It's suggested that frenum resist mesial pressure, **frenectomy before orthodontic closure should lead to faster tooth movement.**

**The rationale for closure of median diastema prior to frenectomy is to improve the stability of the space closure by consolidating the teeth with scar tissues forming around the surgical site.** They also believe that with early frenectomy, old scar tissue may impede orthodontic space closure.

I. Patient is still 10yrs and orthodontic Rx is not recommended at this age. So frenectomy is not required to do right now. So, option (B) is the right answer.

# PEDO+ORTHO

## SBQ 35

ORTHO MIDLINE DIASTEMA BETWEEN 11 AND 21. DIASTEMA MORE THAN 2MM SEEN IN PHOTOGRAPHS NOT MENTIONED IN WRITTEN. AGE OF CHILD 10 YEARS LABIAL FRENUM PRESENT CAUSING BLANCHING OF GINGIVA BETWEEN CENTRALS. IT DOESN'T HAVE PERMANENT PREMOLARS AND CANINES HAVE ERUPTED. FINANCIAL CONSTRAINTS. THEY HAD SEEN A PREVIOUS DENTIST AND HE TOLD ME CORRECTION OF DIASTEMA IS NOT POSSIBLE WITHOUT FRENECTOMY.

**I. Parents not wishing for frenectomy. Come to you now for a checkup again. What is the best investigation?**

- A. IOPA in upper central incisors
- B. Standard occlusal
- C. MRI of soft tissues - it means for thick frenum
- D. Cephalogram probing
- E. Occlusal view

**II. A combined treatment of frenectomy and Ortho treatment was decided. Why would you consider doing frenectomy IMMEDIATELY before ortho treatment?**

- A. Reduces scar tissue between centrals
- B. It closes the diastema faster( make move central incisors easier )
- C. If we don't do frenectomy it will hinder ortho treatment
- D. To allow better interproximal cleaning while using fixed ortho

**III. Parents are worried about the procedure and financial constraints. looking at the picture you prefer to do frenectomy. What alternatives can you suggest?**

- A. Monitor eruption of canine and then reassess the need of frenectomy at that stage
- B. Normal for the age
- C. Not normal, it will not close later on its own
- D. It will get close on its own as she grows
- E. Refer to ortho (not in all centres)

**IV. What is hindrance for diastema closure?**

- A. Having thick labial frenum
- B. Age of the child not suitable for the ortho treatment

**V. Who will Give the consent, child is 12 years old?**

- A. Child
- B. Both parents
- C. Child and mother
- D. Child and dentist
- E. No consent

# PEDO+ORTHO

## P.O.W.E.R NOTES SBQ 35

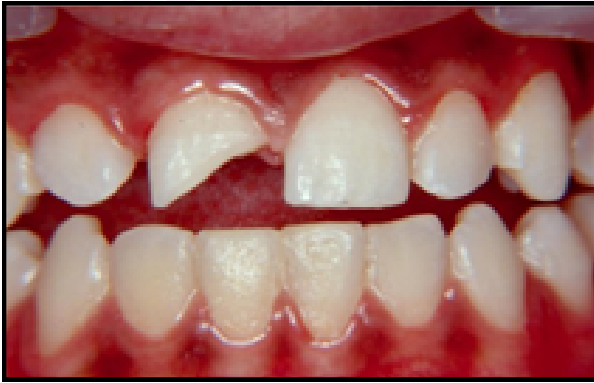
- I. Blanching of gingiva – presence of abnormal frenum, patient is 12yrs old and canine have erupted. Before the eruption of canine 2mm gap is normal and 4mm gap is abnormal. After the eruption of canine 2mm is abnormal.  
Other than the blanch test IOPA is don't to see the alveolar notch.
- II. We have to choose an answer to support “doing frenectomy before the treatment.” So according to the reference given above; It's suggested that frenum resist mesial pressure, frenectomy before orthodontic closure should lead to faster tooth movement.
- III. Canines are already erupted. So, the median diastema can't get closed by its own. Option (A), (B), (D) get ruled out. Frenectomy is needed. So, you have to refer the patient to the orthodontist. If option (E) is not given then the next best option is (C).
- IV. There's a hindrance of diastema closure because of the thickness of the labial frenum. That's why the natural diastema closure is not happening.
- V. Child is still 12yrs old. So, the consent is given by the parents.  
14-16yrs both the child and parent can give the consent.



# PEDO+ORTHO

## SBQ 36

A 9 YEAR OLD BOY FELL DOWN WHILE PLAYING AND SUDDENLY HAD A HEADACHE AND FELT DIZZY. ALSO, 11/ 21 WAS FRACTURED.



**I. What should be done immediately?**

- A. Arrange to take him to the emergency department.
- B. Ask his father to take him to his medical practitioner.
- C. Not an issue, take him to the dentist
- D. Start required dental treatment
- E. Send the Patient home

**II. A 9 year old boy fell while playing. There is fracture in respect to 11 and there is pinpoint exposure of pulp. What kind of fracture is it?**

- A. Complicated crown fracture
- B. Uncomplicated crown fracture
- C. Complicated crown root fracture
- D. Crown infarction

**III. You took a radiograph by paralleling technique in the midline of 11, 21. What is the other appropriate radiograph you need to take next?**

- A. Opg
- B. Paralleling technique in 12 in center
- C. Paralleling technique in respect to 53 center
- D. Vertical shift the tube
- E. Lateral cephalogram

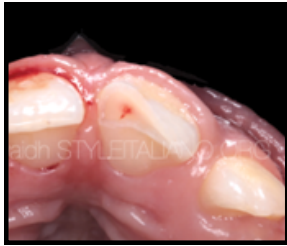


# PEDO+ORTHO

## SBQ 36

**IV. What would you recommend as the Best immediate treatment for this patient?**

(only 1 tooth was involved either 11 or 21. Pinpoint pulp exposure pic was given almost like this one)



- A. Dpc with mta
- B. Composite restoration
- C. Pulpectomy
- D. Extraction

**V. Cyclist had a trauma. His friends bring him to you. You gave him a mirror and he sees a blood like pin - point appearance on the fractured anterior tooth. What is your treatment?**

- A. Dpc
- B. Pulptomy
- C. Ipc
- D. Pulpectomy

**V. The tooth wasn't mobile but the patient feels he can't bite because he feels as if it was hitting the incisal edge lower teeth. What kind of injury can it be?**

- A. Palatal Luxation
- B. Extrusion
- C. Labial Luxation

# PEDO+ORTHO

## P.O.W.E.R NOTES SBQ 36

- I. According to the history the patient has headache and dizziness. It's an emergency so, the patient should be sent to the emergency department.
- II. There's a pinpoint exposure of pulp. Therefore, the pulp is involved. It's a complicated crown fracture.
- III. Since maxillary central incisors are the most frequently affected teeth, the radiographs listed below are recommended to thoroughly examine the injured area:
  - One parallel periapical radiograph aimed through the midline to show the two maxillary central incisors.
  - One parallel periapical radiograph aimed at the maxillary right lateral incisors.
  - One parallel periapical radiograph aimed at the maxillary left lateral incisors.
  - One maxillary occlusal radiograph
  - One parallel periapical radiograph of the lower incisors centred on the two mandibular centrals.
- IV. Patient is 9yrs old. Mostly the roots are matured. In mature teeth partial pulpotomy is recommended for pinpoint exposure. That answer is not given, DPC is indicated for immature permanent teeth with pinpoint pulp exposure. In this question we believe that it's still an immature permanent.
- V. As mentioned above based on the age, maturity of roots according to the given radiographs you need to choose whether it's DPC or pulpotomy.
  - immature permanent with pinpoint exposure- DPC
  - mature permanent with pinpoint exposure- pulpotomy
- VI. If the traumatised tooth is not mobile but if it's hitting the incisal edge of the lower incisors, it is due to palatal luxation. Extrusive luxations are mobile. Extrusion takes place in the vertical plane whereas the palatal/labial luxation takes place in the antero-posterior plane.

# PEDO+ORTHO

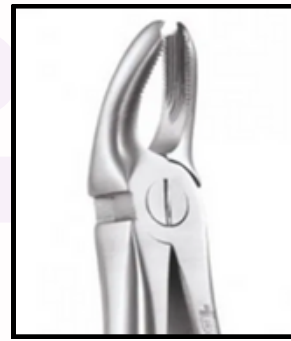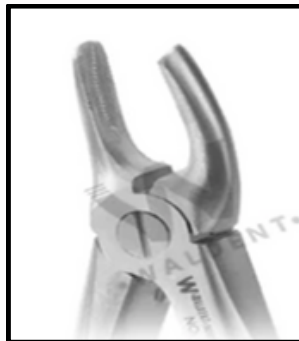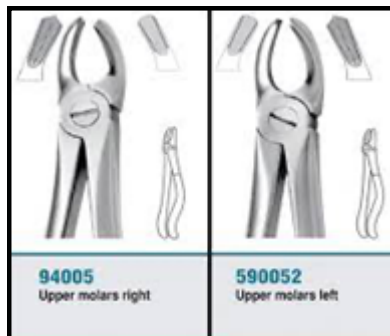## SBQ 37

### PRIMARY TEETH (MOD)

I. Picture of primary teeth occlusal view was given but it was cropped and rotated sideways, which are visible on the photograph (all were primary teeth only).

- A. 55 54 53 52
- B. 65 64 63 22
- C. 33 34 35 32
- D. 75 74 73 72

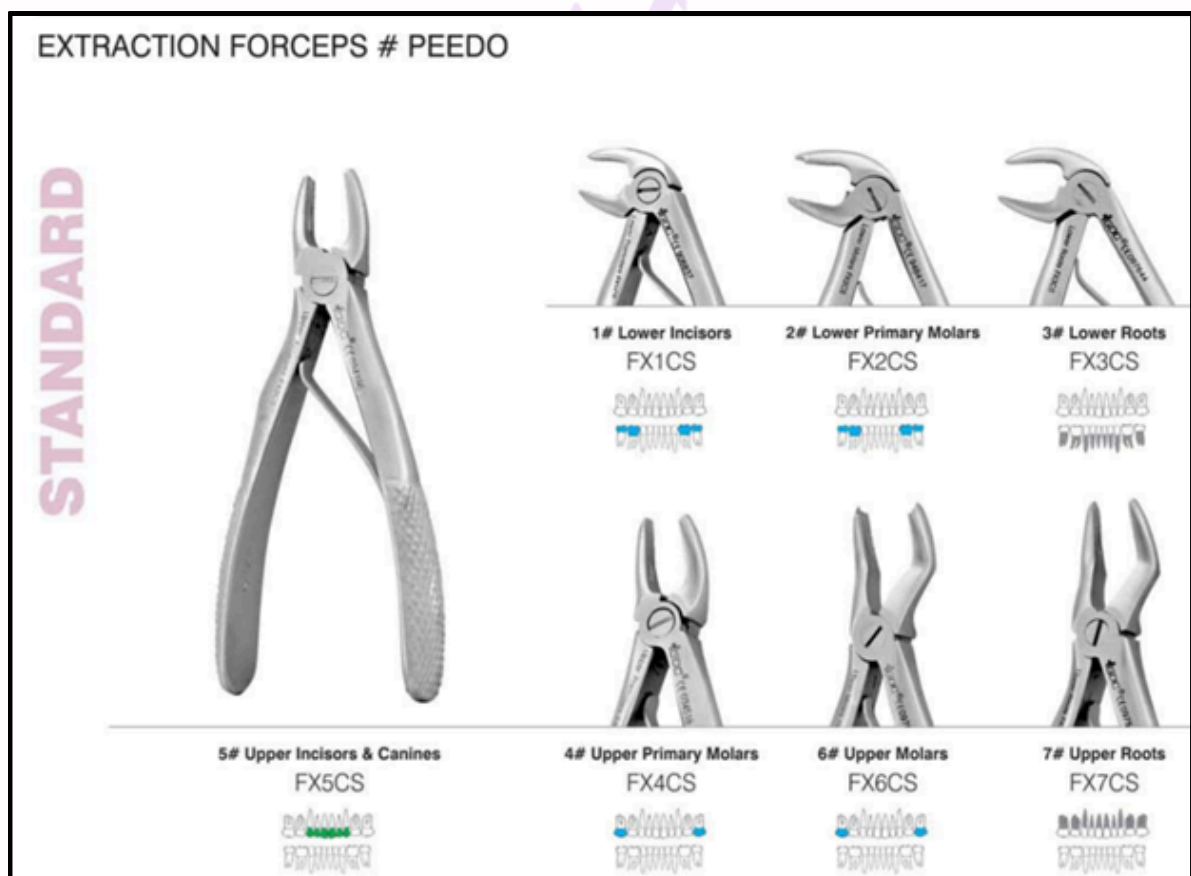
II. A small picture of two upper left and right and two lower extraction forceps was given. which one using for extracting 55



# PEDO+ORTHO

## P.O.W.E.R NOTES SBQ 37

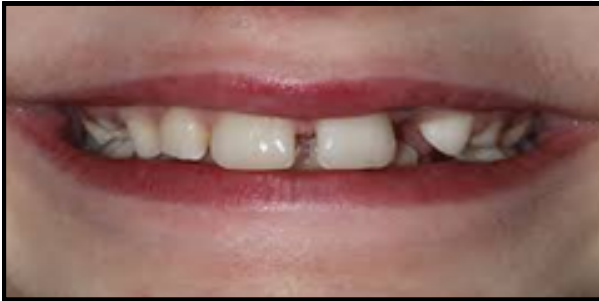- I. In the question it's mentioned about the primary teeth. So, options (B) and (C) get ruled out. If the occlusal view shows upper teeth answer would be (A) whereas if the occlusal view shows lower teeth answer would be (D).
- II. Both the beaks are pointed in the upper primary molar forceps as there's no right and left forceps.  
Upper molars forceps are pointed and bent. Upper premolar forceps are flat end and bent. Upper incisor forceps are straight and flat end. Upper root forceps are tapered.



# PEDO+ORTHO

## SBQ 38

**DEEP BITE CASE 10 YEARS OLD. ONE LATERAL INCISOR IS MISSING**



**I. How to correct the deep bite?**

**OR**

**What is the treatment for the deep bite?**

- A. Treatment with fixed ortho
- B. Use bite plane to intrude lower incisors
- C. Use Invisalign aligners for the alignment
- D. You will give removable appliance

# PEDO+ORTHO

## P.O.W.E.R NOTES SBQ 38

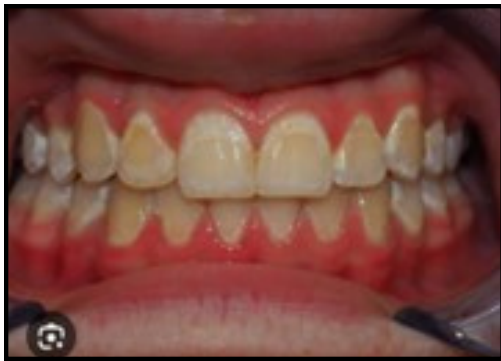- I. • Deep bite is not corrected at the mixed dentition period as it can be self corrected.
- The overbite is greater after eruption of the prominent incisors and decreases with the eruption of the posterior teeth. If the skeletal bases are class I with normal incisor angulation, it's better to wait and watch till the eruption of the posterior teeth which results in resolution of deep bite.
  - For this reason intrusion as a part of early treatment is seldom required. It's often better to differ this treatment until the early permanent dentition.
  - Early childhood is the best time to treat complex deep bite.
  - Deep bites with anterior vertical maxillary excess showing gummy lines can be intercepted by high pull headgears.
  - So, option (A) is ruled out.
  - In deep bite cases bite plane is used to intrude the upper incisors not the lower incisors. And also not preferably at her age. So, option (B) is ruled out.
  - In non skeletal deep bites, a utility arch that incorporates molar and incisor teeth can be used during the mixed dentition to intrude, tip or reposition both molar and incisors.
  - With invisaligns stable results were obtained. Evaluating the effectiveness, safety and acceptability of aligners during primary and mixed dentition phases indicates comparable efficacies to traditional fixed appliances, with potential advantages in terms of treatment duration and patient comfort. Clear aligners playing a significant role in meeting the needs of the growing patients.
  - With aligner we can do minor corrections. There's no option saying no treatment, wait and observe. Between (C) and (D), option (C) has got the better aesthetics and easy maintenance of OH. With the removable appliances plaque retention is more due to the presence of wire components and it has got full coverage areas.

# PEDO+ORTHO

## SBQ 39

### DEMINERALIZATION CASE

A LADY PATIENT CAME WITH THE CHIEF COMPLAINT OF WHITE DISCOLORATION IN HER FRONT TEETH. PATIENT HAD ORTHO TREATMENT IN THE PAST. THEY HAVE MENTIONED THAT ON BITEWING RADIOGRAPHS INTERPROXIMAL CARIES WERE EXTENDING INTO ENAMEL. SHE DRINKS A LOT OF COCA COLA. (HISTORY VARIATION - THE ORTHODONTIST TOOK OUT HER BRACES BECAUSE SHE DID NOT MAINTAIN GOOD ORAL HYGIENE)



#### I. What other investigation will help you for the diagnosis?

- A. Caries detecting dyes
- B. Caries risk assessment
- C. Caries detection using Briault probe

#### II. Which factor led to this situation?

- A. Plaque retention
- B. Ortho treatment
- C. Sugar/sugary drinks

#### III. How will you monitor these lesions in terms of the patient's chief complaint?

- A. 3 monthly bitewing review
- B. Topical fluoride application
- C. Do a 3 monthly review

# PEDO+ORTHO

## P.O.W.E.R NOTES SBQ 39

- I. Even with the history of ortho Rx, if the patient has interproximal caries according to the bitewing, caries is the diagnosis. Orthodontic demineralisation doesn't involve the interproximal area. Bitewing shows the interproximal extension. And, patient has risk factors of cola intake and poor OH.  
Caries detecting die is useful in extended carious lesion to see the extension of the cavity. Superficial, incipient, active caries to arrested, inactive caries can be differentiated with a blunt probe.  
"Briault" probe is a sharp probe. If it was blunt probe (C) would be the best answer.
- II. Plaque retention and sugar intake both are important risk factors. Based on the given history you must select one of these. If both sugar and plaque are mentioned, then you will choose plaque. If both are present in the absence of poor OH, then you will choose sugar intake.
- III. In high caries risk we get bitewings in every 6months and review the patient every 3 months time.

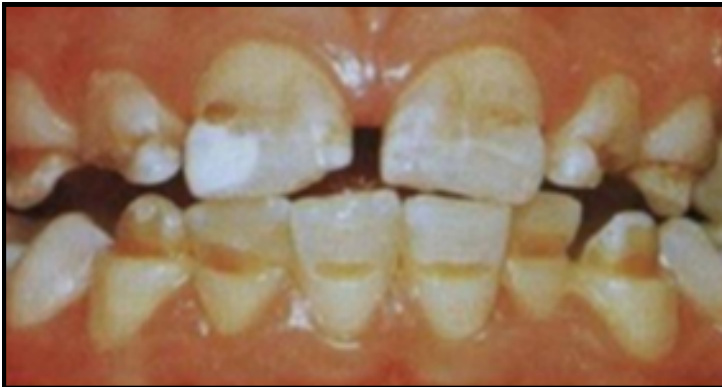

# PEDO+ORTHO

## SBQ 40

### ENAMEL HYPOMINERALIZATION

A 13 YEAR OLD PATIENT CAME BACK AFTER FEW YEARS TO YOU WITH HYPOPLASTIC SPOTS ON FRONT TEETH, IN THE PREVIOUS APPOINTMENT A FEW YEARS BACK AS A 5 YEAR OLD CHILD HE DIDN'T HAVE ANY SUCH LESIONS, EXCEPT FOR PREMOLARS ALL OTHER TEETH INCLUDING MOLARS HAD WHITE DISCOLORATION AND HYPOPLASTIC SPOTS.  
(HYPOMINERALISATION)



#### I. How will you restore or protect the molars from breakdown?

- A. SSC after tooth reduction
- B. Composite build up/restoration
- C. Gic restoration
- D. Resin modified GIC

#### II. What will be the treatment for anterior teeth?

- A. Porcelain veneer
- B. Micro abrasion with fluoride application
- C. Composite restoration
- D. Bleaching

(no composite veneer option was given)

# PEDO+ORTHO

## P.O.W.E.R NOTES SBQ 40

In this case hypoplastic spots are to chronological / molar-incisor hypoplasia rather than amelogenesis imperfecta, because primary teeth were not involved.

- I. Ss-crown are done for the primary teeth not for the permanent. So, to protect the permanent molars we can do composite build-ups. PFM crowns are not indicated at the age of 13yrs. RMGIC doesn't have rigidity compared to composite to take up masticatory loads on molars.
- II. Bleaching is not helpful in hypoplastic spots. Porcelain veneers are not indicated in 13yrs old child as the gingival contours develop at the age of 18yrs. Micro abrasion with fluoride application will not be helpful in deep pits. Composite restoration is the best among the given.

Technique	Advantages	Disadvantages
Full resin composite veneers	No destruction of tooth tissue, reversible and generally well tolerated even by anxious children. Excellent aesthetic result possible and easy to maintain.	Discolour with time. Tendency to fracture if placed at/over the incisal edge.
Enamel microabrasion	Minimal destruction of enamel, if carefully performed. Technique well tolerated.	Unpredictable. Teeth may rarely suffer postoperative sensitivity. Accidental exposure of dentine is possible where enamel is thin.
Localized resin composite restoration	Enamel destruction limited to defect, and full thickness need not be removed if opaque resin composite shades are used. Good aesthetic result possible.	Irreversible. Weakens tooth structure and large areas of dentine may be uncovered. Colour change and marginal discoloration with time.
Porcelain veneers	Good appearance.	Contraindicated in this age group because gingival contour not mature and stable tooth position not yet established.
Full-crown restoration	Good appearance.	Inappropriate until late second decade because immature pulp horns may be exposed. Gingival contour not mature and stable tooth position not yet established.

# PERIODONTICS

## SBQ 1

PATIENT IS ABOUT 50 YEARS OLD, WITH CHRONIC PERIODONTITIS, BAD ORAL HYGIENE, GREAT AMOUNT OF PLAQUE, GREAT LOSS OF ATTACHMENT, MOBILE TEETH, SMOKER (SMOKING MORE THAN 20 CIGARETTES A DAY) AND HEAVY DRINKER. HE WANTS TO EXTRACT MOBILE TEETH AND RECEIVE A DENTURE TO REPLACE THEM. OPG & INTRA ORAL PIC GIVEN WITH FOLLOWING FINDINGS:

EXCESSIVE CALCULUS DEPOSITS, EXCESSIVE RIDGE DEFECTS, MULTIPLE MISSING TEETH MOSTLY IN UPPER LEFT QUADRANT, FLARED AND DRIFTED UPPER ANTERIOR TEETH, AT LEAST GRADE 2 FURCATION INVOLVEMENT IN ALL MOLARS AND GRADE 3 IN SOME LOWER MOLARS, WHILE GRADE 4 FURCATION OF UPPER RIGHT MOLARS. ROOT STUMPS IN 15. HE WAS A POOR PATIENT (FINANCES WERE MENTIONED). HE WANTED TREATMENT IN THE LIMIT OF EXPENSE. TEETH PRESENT ARE:

UPPER-17 16 15 14 13 12 XX 22 23 24 25

LOWER- 47 46 45 44 43 42 XX 32 33 34 X 36 37 38(HEAVIER DEPOSITS THAN IMAGE PROVIDED)

I. How will you classify the periodontal disease of this patient?

- A. Stage 3 grade B
- B. Stage 3 grade C
- C. Stage 4 grade B
- D. Stage 4 grade C

II. You decide to extract the following teeth 15 16 17 25 47 38. You did initial scaling and the chart was given with all the details and then asked what's the classification now? What will be the classification now? Perio charting provided with excessive pocket depths and CAL.

- A. Stage 3 grade b
- B. Stage 4 grade b
- C. Stage 3 grade c
- D. Stage 2 grade c
- E. Stage 4 grade c

III. What is the Kennedy classification of this patient after extractions ?

- A. Upper Class 1 mod 1 & lower class 2 mod 1
- B. Upper Class 2 mod 2 & lower class 2 mod 2
- C. Upper class 1 mod 2 & lower class 1 mod 2
- D. Upper class 1 mod 1 & lower class 2 mod 2
- E. Class II mod I upper; Class III lower mod 2
- F. Class II mod I upper & Class III lower mod I

# PERIODONTICS

## SBQ 1

**IV. Patient doesn't want to stop smoking and doesn't want to proceed with periodontal treatment. He just wants extraction and replacement of mobile teeth. What will you do?**

- A. Proceed with extraction and give prosthesis with everything documented in your notes
- B. Proceed with extractions and give prosthesis with a patient's signature to write off a waiver Refuse treatment until he quit smoking
- C. Refuse treatment until periodontal situation is solved
- D. Refuse treatment until smoking cessation and periodontal treatment is done

**V. You performed scaling root planning. What will you inform the patient before discharging him? (perio management)**

- A. Sensitivity
- B. Pain
- C. Bleeding

# PERIODONTICS

## P.O.W.E.R NOTES SBQ 1

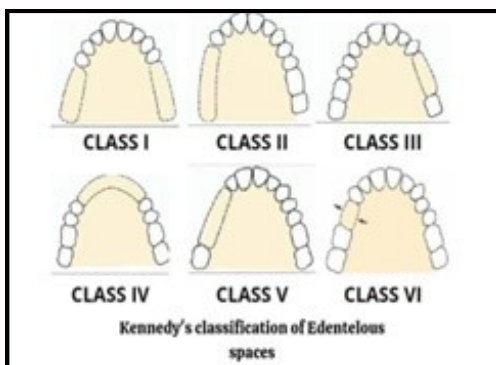
### I. FEATURES OF STAGE IV

- Masticatory dysfunction
- Secondary occlusal trauma (tooth mobility degree >2)
- Severe ridge defect
- Bite collapse, drifting, flaring
- Less than 20 remaining teeth
- Multiple attachment loss and furcation involvement

So, based on the remaining bone, drifting and flaring you can decide the staging. According to the given history patient comes under stage IV and grade C as the patient smokes 20 cigarettes per day.

II. If the smoking is not reduced the grading won't change. Even if we perform Rx, stage will not change.

III.



IV. Without periodontal stabilisation we can't give a prosthesis as the prosthesis will become more plaque retentive site and it will worsen the patient's condition. Without smoking cessation, we can't proceed ahead with periodontal Rx or another Rx s.

V. Smoking will remain at a great risk for them. It's a stage 4 grade 3 case. Even after treatment you may not know about the OH maintenance. So in the future if more teeth are needed to be added, then acrylic dentures would be ideal in this case as adding teeth is easier with acrylic.

VI. Because of shrinkage of gingiva and slight exposure of the cementum/ dentine patient may feel sensitivity after the scaling.

# PERIODONTICS

## SBQ 2

PATIENT WITH GINGIVITIS HAS NOT BEEN TO A DENTIST FOR 3 YEARS. WE COULD SEE THE ENLARGEMENT AND LOTS OF PLAQUE. THE PATIENT HAD GENERALISED SWELLING (MENTIONED IN THE QUESTION) AND PAIN SINCE FEW (DAYS/WEEKS/MONTHS?). WAS DIAGNOSED WITH EPILEPSY 6 MONTHS BACK AND TAKING DILANTIN SINCE 3 MONTHS (I HAD IT SAYING DILATION FOR 6 MONTHS).PATIENT WAS ALSO ON SSRIS, ESCITALOPRAM 10MG FOR MILD ANXIETY & DEPRESSION. RECENTLY NOTICED GUMS STARTED BLEEDING WHEN SHE CHEWS OR BRUSHES. SPONTANEOUS BLEEDING,(CANNOT REMEMBER WHETHER WE HAD "SPONTANEOUS" WORD BUT IT WAS MENTIONED THAT HAD BLOOD STAINS ON PILLOW) THERE WAS BLOOD ON HER PILLOW. (DIDN'T MENTION ABOUT FEVER OR LYMPHADENOPATHY) (HAD A PICTURE WITH VISIBLE PLAQUE DEPOSITS AND GENERALISED HYPERPLASIA)

### I. What's the cause for her spontaneous bleeding?

- A. Acute myelogenous leukaemia
- B. Drug induced gingivitis
- C. Anug
- D. Acute periodontal disease
- E. SSRIs(Escitalopram)

### II. What will you give her to use at home for two weeks?

- A. 0.12% Chlorhexidine
- B. 1.5 % H<sub>2</sub>O<sub>2</sub>
- C. Salt water
- D. Essential oil m/w

### III. Which drug causes gingival enlargement?

- A. Mao inhibitors
- B. Phenobarbitone
- C. Tetracycline

### IV. Dentist wants to know about her condition and also wants to keep baseline records. What investigation does he need to do?

- A. Opg
- B. Left and right bitewings
- C. Periapicals
- D. OPG & Periapicals

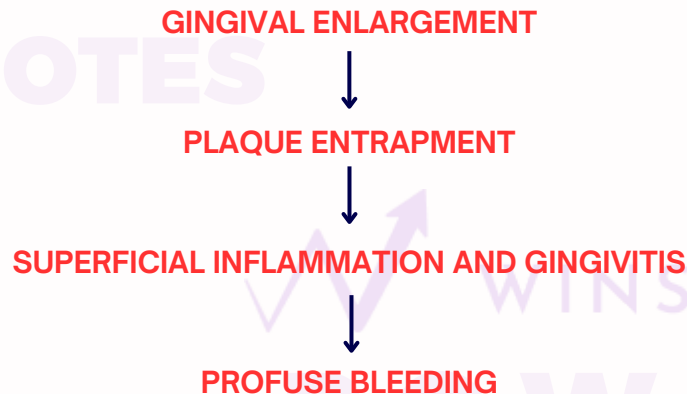
### V. Dentist wants to scale sextant two which has deep pockets. What should he use?

- A. Sickel Scaler
- B. Gracey 1 and 2
- C. Gracey 13 and 14
- D. Gracey 15 and 16
- E. Columbia curettes

# PERIODONTICS

## P.O.W.E.R NOTES SBQ 2

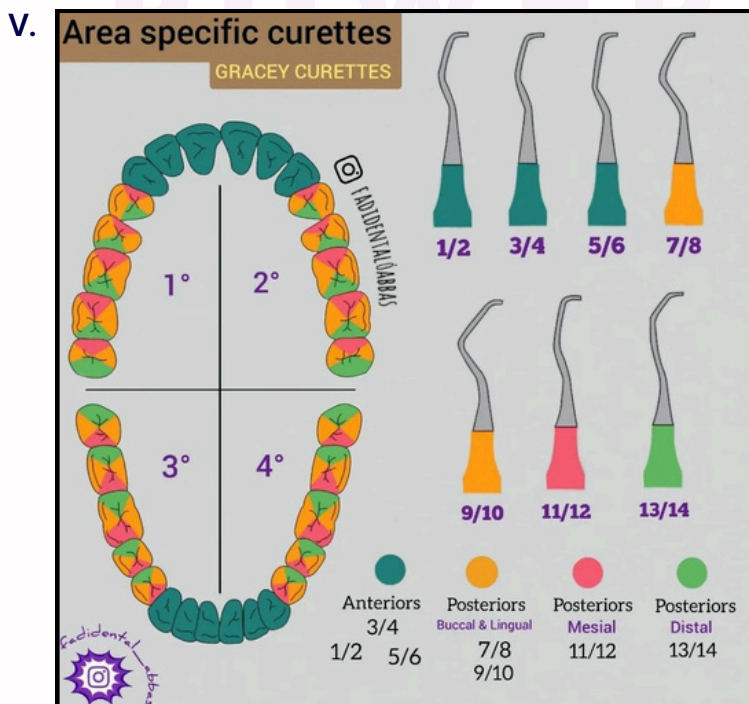
- I. Dilantin is known to cause gingival enlargement. SSRI are not causing gingival enlargement.



There's no fever, no lymphadenopathy, no fatigue. Therefore, it's not linked with leukemia.

Based on the signs and symptoms (B) would be the cause.

- II. Among the given CHX is the best for gingivitis. It's given only for 2 weeks as longer use can cause discolouration and taste alteration.
- III. Barbiturates cause gingival enlargement.
- IV. This is gingivitis and not periodontitis. So, we don't require periapical radiographs and bitewings. Only OPG is enough as there's no bone involvement, no attachment loss or no mobility.





# PERIODONTICS

## SBQ 3

**PERIODONTAL SCREENING READING GIVEN TO A PREGNANT PATIENT WHO IS 10 WEEKS PREGNANT. DURING THE BASIC PERIODONTAL EXAMINATION (BPE), SHE SAYS THAT SHE IS DRINKING A LOT OF SUGARY DRINKS, SHE TRIES TO QUIT BUT SHE COULD NOT QUIT AT THIS POINT OF TIME. THERE WAS INFLAMMATION OF MARGINAL GINGIVA AND ROLLED MARGIN. THEY MENTIONED THE DIAGNOSIS AS MILD TO MODERATE MARGINAL GINGIVAL INFLAMMATION WITH THE BPE**

**BPE SCORES:**

**2 1 2**

**1 2 1**

### **I. Based on the readings above, what will be the treatment for her?**

- A. Do not do any perio assessment and just give oral hygiene instruction
- B. Do not do any perio assessment and just give scaling and ohi
- C. Complete periodontal assessment and give oral hygiene instructions
- D. Do a complete periodontal assessment and do scaling for her and give ohi
- E. Do a complete periodontal assessment and do scaling and root planing and ohi

### **II. How will you protect her teeth from sugary drinks?**

- A. Ask her to drink the sugar free drink with a straw, immediately Gargle with tap water and ask her to use fluoride toothpaste 5000 ppm twice a day
- B. Ask her drink with the straw and immediately brush with fluoride 1250 ppm toothpaste
- C. Drink sugar free cola with straw, during meals, and gargle with water after the meal, brush 1 hour after with 1450 ppm fluoride toothpaste
- D. Drink cola with straw during meal, gargle with water after the meal, brush 1 hour after with 1450 ppm fluoride toothpaste

### **III. Clinical signs of gingivitis are:**

- A. Inflammation of interdental papilla
- B. Rolled margins
- C. Attached gingiva inflammation
- D. Calculus

### **IV. She asked about the future child and how to clean the child's teeth?**

- A. Brush with 500-550 ppm toothpaste pea sized at 18 months At 24 months brush with 1000 ppm smear of it
- B. Clean with 500-550 ppm FL toothpaste at 6 months of interval.

### **V. If the dentist were to do a health promotion event. What advice should be in particular to pregnant patients? (Language was similar)**

- A. Pregnancy will cause dental caries
- B. Meet your dentist to avoid gum disease
- C. Get the treatment for Periodontal disease (language was a bit different, but it meant this)
- D. Pregnancy always causes gingivitis



# PERIODONTICS

## P.O.W.E.R NOTES SBQ 3

I.

Probing depth	Observation	BPE Score
Black band completely visible	No probing depths >3.5 mm, no calculus/overhangs, no bleeding after probing	0
Black band completely visible	No probing depths >3.5 mm, no calculus/overhangs, but bleeding after probing	1
Black band completely visible	No probing depths >3.5 mm, but supra- or sub-gingival calculus/overhangs present	2
Black band partially visible	Probing depth(s) of 3.5 – 5.5 mm present	3
Black band entirely within the pocket	Probing depth(s) of 6 mm or more present	4
N/A	Furcation involvement	*

BPE Score	Guidance on Further Assessment and Treatment
0	Periodontal treatment is not required
1	Plaque and gingivitis charting and oral hygiene demonstration.
2	As for code 1 plus remove supra-gingival plaque, calculus and stain, and if necessary sub-gingival plaque and calculus, using an appropriate method.
3	As for code 2 plus full periodontal examination of all teeth and root surface instrumentation where necessary (N.B. Where code 3 is observed in only one sextant, carry out full periodontal examination and root surface instrumentation of affected teeth in that sextant only).
4	As for code 2 plus full periodontal examination of all teeth and root surface instrumentation where necessary (more time is required for root surface instrumentation than for score 3). Assess the need for more complex treatment and consider referral to a specialist.
*	Treatment need will depend on the BPE scores of 0 to 4 for that sextant. Assess the need for more complex treatment and consider referral to a specialist.

# NOTES

# PERIODONTICS

## P.O.W.E.R NOTES SBQ 3

- II. When we compare (A) and (C), (C) is better as it's mentioned to drink cola during the meal.  
In option (B) it's mentioned to brush immediately which is not good.  
In option (D) the sugar free option is not given.
- III. In gingivitis interdental papilla gets involved before the marginal gingiva.
- IV. According to TG 500-550ppm toothpaste can be used from 18 months to 6 yrs old.
- V. Prevention is better than cure. In health promotion we should promote prevention.  
Therefore option (B) is better than (C).

# PERIODONTICS

## SBQ 4

### IMPLANT QUESTION

OPG GIVEN. ON OPG, 25-POST AND CORE WITH 25. IMPLANT ABUTMENT 46. NO CROWN. SHE DIDN'T HAVE MONEY TO COMPLETE TREATMENT THEN. NOW SHE WANTS TO COMPLETE IT. 47 MESIALLY TILTED. PATIENT COMPLAINS OF PAIN ON BITING ON UPPER LEFT REGION AND MOBILITY SINCE THE LAST FEW DAYS. OVERALL HISTORY OF GENERALISED PERIODONTITIS? SMOKING? MEDICAL HISTORY OF OSTEOPOROSIS & TAKING ORAL BISPHOSPHONATES.

I. You examine 25 probing depth on mid buccal-8mm, you find mobility slightly greater than physiological mobility. What is the probable diagnosis?

- A. Irreversible pulpitis
- B. Acute apical periodontitis
- C. Vertical root fracture
- D. Periodontal abscess

II. The patient decided she wants to go with extraction since the tooth is very heavily restored. What will be the most common (High risk) complication which you should inform the patient about? Tooth was heavily restored and the mesial part was completely decayed, even below CEJ)

- A. Infection
- B. Maxillary sinus
- C. Root fracture
- D. Tuberosity fracture

III. She wants to get an implant in its place. What would complicate implant?

- A. Infection
- B. History of past & current periodontitis
- C. Smoking
- D. Osteoporosis
- E. Occlusal trauma

IV. You examine it and it shows slight redness and swelling around the implant and maybe some bleeding on palpation. Probing 6mm distally and 4mm mesially? Looking at the OPG there did not seem any much bone loss, no mobility mentioned in the question.

What is the probable diagnosis for the implant?

- A. Periimplantitis
- B. Peri Implant gingivitis
- C. Peri implant periodontitis
- D. Peri implant mucositis

# PERIODONTICS

## SBQ 4

**V. She wants to get her implant prosthesis. What will you tell regarding implant prosthesis?**

- A. Can't restore implant
- B. Take out old and put new implant
- C. Ortho uprighting may be required.
- D. Implants are contraindication to osteoporosis.
- E. Implant can be given but a complex treatment might be required.

**VI. How much space required for two implants of 3.5 mm?**

- A. 14mm
- B. 17mm
- C. 9mm
- D. 13mm

# PERIODONTICS

## P.O.W.E.R NOTES SBQ 4

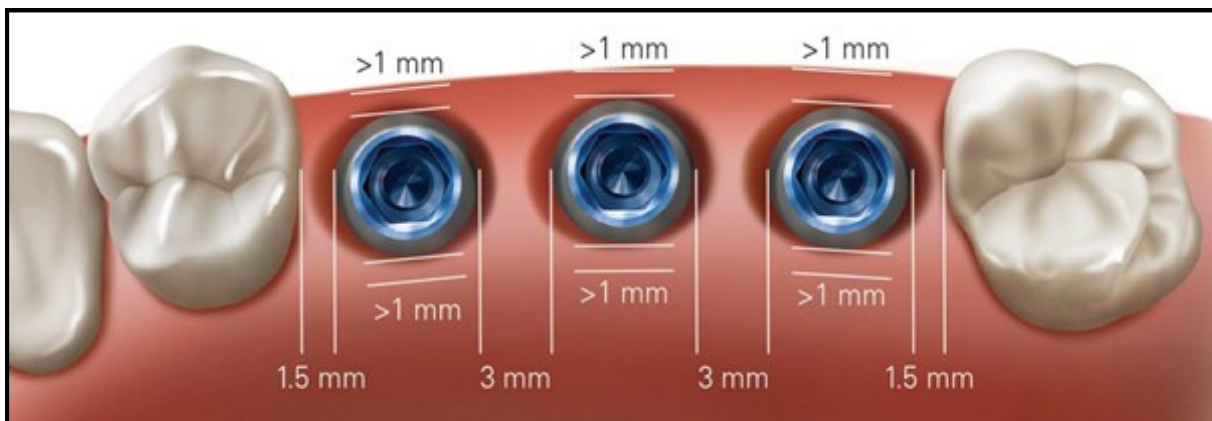
- I. A narrow, vertical deep mid buccal probing depth confined to the one surface of the tooth with mobility and slight pain on biting in a post treated tooth gives the diagnosis of VRF.
- II. It's a heavily restored, post core treated tooth with a VRF and has a high risk of root fracture. Bone preservation during exodontia is the most important factor. Infection is less likely due to aseptic techniques. Maxillary sinus communication is not a risk or complication that we need to inform the patient about. Premolar is not associated with the tuberosity fracture.
- III. Once the causative factor for the infection is removed, there won't be infection afterwards. Smoking and osteoporosis are not absolute complications. Traumatic occlusion from the opposing tooth can be corrected. Past history of periodontitis would not be a complication as the now the disease is under control. But the current periodontitis will hamper the implant osseointegration. Plaque retention and poor OH is the greatest risk factor for implants. With the drug planning, implants can be given for patients with osteoporosis and who are on bisphosphonates. Even for smokers' implants can be given with controlling smoking.

### ABSOLUTE CONTRAINDICATION FOR IMPLANTS:

- Plaque and poor OH
- Terminally ill patients

- IV. Even though it's mentioned about 6mm of probing depth, there's no bone loss and no mobility. Only soft tissue involvement. There's no baseline record of more than 2mm of bone loss annually. Up to 2mm of bone loss is normal. Therefore, the diagnosis is peri implant mucositis. Option (B) and (C) are incorrect terms.
- V. There's no space for crown placement as the adjacent tooth is mesially tilted. Therefore, orthodontic up righting is required before crown placement. If option (C) is not given, next best option is (E).

VI.



# PERIODONTICS

## SBQ 5

PATIENT HAD POOR ORAL HYGIENE AND POOR PERIODONTAL HEALTH. 37 (MOST DISTAL TOOTH) (IT WAS MESIALLY TILTED WITH AN APPARENT UNDERCUT LOCATED MESIALLY AND FLAT SURFACE DISTALLY) AFTER EXTRACTION OF 34, 35 AND 38 (36 ALREADY MISSING) ON OPG?

I. Which clasp would be given on 37 (most distal tooth) (it was mesially tilted with an apparent undercut located mesially and flat surface distally) after extraction of 34, 35 and 38 (36 already missing) on opg?

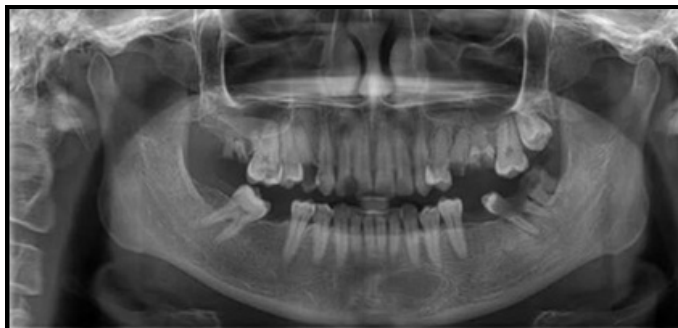- A. Ring clasp
- B. Roach clasp
- C. C clasp
- D. I Bar
- E. Infrabulge clasp

II. In the OPG Findings:

25 was root stumps which were rct treated (in some centres 26 also as root stumps), you decide to extract 38 now.

What would you explain the patient about future extractions, what would be the risk (not complication) of the future extractions?

(Almost similar OPG except 37 was tilted but no caries)



- A. Root Fracture
- B. Oroantral communication
- C. Bleeding
- D. Fracture of zygomatic buttress
- E. It's lying in close proximity to the distal tooth.

III. There is an associated pimple with 25, its asymptomatic & no tenderness on percussion, what would be the diagnosis with 25, the pimple would come and go. What would be the diagnosis?

- A. Chronic periapical abscess
- B. Acute periapical abscess
- C. Acute periapical periodontitis
- D. Chronic periapical periodontitis



# PERIODONTICS

## SBQ 5

### IV. What could be the possible reason for this condition?

- A. Attachment loss predominantly
- B. Due to root stumps
- C. RCT failure

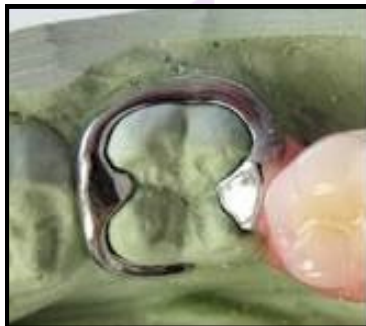## P.O.W.E.R NOTES SBQ 5

I. There's a mesial edentulous space for 37 and it's mesially tilted. Undercut of 37 lies mesially adjacent to the edentulous space.

Options (B), (D) and (E) are similar types and these are not indicated for a tilted tooth. C- clasp is also not indicated for a tilted tooth. Ring clasp is suitable for a tilted tooth.

### RING CLASP:

- Encircles nearly the abutment tooth
- Usually used with mesially and lingually tilted mandibular molars (with a ML undercut) or mesially and buccally tilted maxillary molars (with a MB undercut).
- The undercut is on the same side as the rest seat. (i.e adjacent to the edentulous span)



II. Root stumps should be removed in the next appointment. Root fracture is the complication associated with it, which you must explain the patient.

III. Associated pimple with 25 denotes a soft tissue involvement, therefore, it's an abscess. It's asymptomatic and non-tender. So, it's an acute condition. Diagnosis is chronic periapical abscess.

IV. It's an RCT tooth associated with a periapical abscess. It happens due to RCT failure.

# PERIODONTICS

## SBQ 6

**IN A PATIENT WITH SEVERE PERIODONTITIS AND HB1AC 7 PERCENT. WHAT DOES DIABETES HAVE ON PERIODONTAL DISEASE?**

- A. Minimal as long as diabetes is well controlled
- B. Minimal with periodontal care.
- C. Significant as periodontal condition will decline
- D. Significant coz of diabetes medications in long

## P.O.W.E.R NOTES SBQ 6

- I. Hba1c is 7, which means grade C. so, the periodontal condition is significant. Medication doesn't have an effect on periodontitis, but the blood glucose level has. So, option (C) is correct.



# PERIODONTICS

## SBQ 7

THE DENTIST DECIDES TO DIVIDE TREATMENT WITH ORAL HYGIENIST/THERAPIST WORKING IN YOUR CLINIC, HOW TREATMENT CAN BE DIVIDED?

- A. Dentist retains full responsibility of overall treatment
- B. Oht take full responsibility of treatment
- C. Dentist only put oral hygiene responsibility on oht
- D. Dentist take full responsibility of counselling or instruction or rx done by oht
- E. Dentist shares the work responsibility for that specific period and is not responsible for the decisions made by hygienist
- F. Dentist takes full responsibility and instruct to the oral hygienist for the management

## P.O.W.E.R NOTES SBQ 7

### I. DELEGATION

Delegation involves one practitioner asking another person or member or staff to provide care on behalf of the delegating practitioner while the practitioner retains overall responsibility for the care of the patient or client.

#### GOOD PRACTICE INVOLVES:

- Taking reasonable steps to ensure that any person to whom a practitioner delegates, refers or handover has the qualifications and/ or experience and/ or knowledge and/ or skills to provide the care required.
- The delegating practitioner remains responsible for the overall management of the patient or client and for the decision to delegate.

# PERIODONTICS

## SBQ 8

### OPG GIVEN

**36 BONE LOSS ALL AROUND ROOTS INVOLVING FURCATION AREA (IT WAS MOBILE) 36 AND 37 HAS MILD POCKET 46 BONE LOSS AROUND ONE ROOT AND FURCATION. DISTAL ROOT FINE, 47, 35 MISSING.**

#### I. How to identify the tooth with questionable to hopeless prognosis

- A. Grade 3 mobility
- B. Furcation grade 3
- C. Furcation grade 3 and vertical bone Loss 3mm
- D. Pocket depth 7 mm

#### II. You would like to assess the stage of progression of disease for this patient. How to assess, without previous record or x-ray.

- A. Check the clinical attachment loss
- B. Bleeding on probing
- C. Plaque index
- D. Radiographic bone loss

#### III. BPE scoring was given

**4\* 3\* 3\***

**4\* 3\* 4\***

**(\*furcation involvement)**

- A. Localized periodontitis
- B. Generalized perio
- C. 6 point probing of all the teeth in all quadrant
- D. Mobility

#### IV. Clinical attachment lost- gingival recession- 3 and pocket 4

- A. 4
- B. 3
- C. 7

# PERIODONTICS

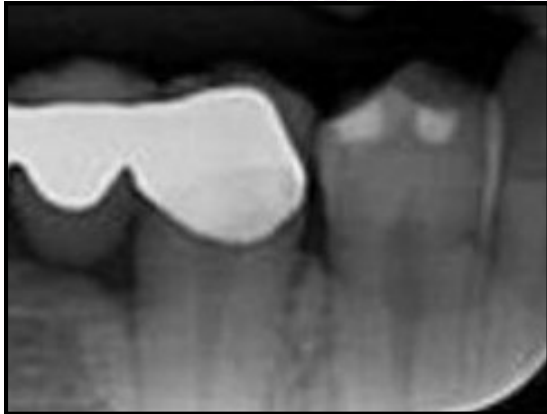
## P.O.W.E.R NOTES SBQ 8

- I. Hopeless prognosis: something that goes for extraction immediately.  
Good prognosis: you can save the tooth.  
Questionable prognosis: you can treat the tooth but you are not sure whether it's saveable or not.  
Questionable to hopeless prognosis: you can do the treatment and may be able to save the tooth but at the same time there's a risk that the tooth may require extraction.  
Grade 3 mobility – hopeless prognosis  
Pocket depth 7mm- fair prognosis (re attachment can be achieved with graft techniques)  
Furcation grade 3- questionable prognosis  
Furcation grade 3 and vertical one loss 3mm- questionable prognosis but going towards hopeless.
- II. Either you need the bone loss or the attachment loss to get to know the staging.
- III. BPE score **0-2**: periodontal chart is not required.  
BPE score **3-4**: periodontal chart is required.  
In periodontal chart 6-point probing depth of all teeth, bleeding, furcation involvement, recession and mobility is recorded.
- IV. CAL= **probing dept + gingival recession**

# PERIODONTICS

## SBQ 9

LADY WITH UNSUPPORTED PFM BRIDGE. TREATMENT WAS SIMILAR TO THAT ONE, NOT THE SAME:, ALSO THE SAID THAT THE PROBE WAS NOT DEEPER THAN A SHADED PART. IT HAS A CANTILEVERS BRIDGE IRT 43 44 45 (RADIOPAQUE AREA OF BONE IT WAS DENSE IN CERVICAL 1/3 AREA) (VISIBLE IN THE IOPA AROUND 43, 44).



I. What is the reason for the radiopaque dense area of bone ?

- A. Calculus
- B. Paget's disease
- C. Condensing osteitis

II. Best fulcrum line to probe disto labial of tooth 21 (which fulcrum is to probe the area of disto labial wrt 11)

- A. Chin
- B. Upper arch
- C. Lower arch
- D. Finger on finger
- E. Zygoma

III. What would you ask the patient to know more about the case?

- A. Last visit to the dentist for scaling

IV. Clinical attachment loss asked?

- A. Gingival recession 3mm
- B. Pocket depth 4mm
- C. 7mm

# PERIODONTICS

## P.O.W.E.R NOTES SBQ 9

I. Condensing osteitis is seen in the apical level. Can't be Paget's bone disease.

### II. DESCRIPTION OF THE VARIOUS INTRA ORAL FINGER RESTS:

Conventional rest: here, finger rest is established on the tooth surface immediately adjacent to the working area.

Cross arch rest: in this case finger rest is established on the tooth surface on the other side of the same arch.

Opposite arch: finger rest is established on the tooth surface of the opposite arch, for an example while working on the maxillary arch, finger rest is established on the mandibular arch.

Finger on finger rest: it's established on the thumb or index finger of the non-operating hand.

III. Since the patient has a cantilever bridge and calculus deposits it's good to know when was the last FMS was done.

IV. CAL= probing dept + gingival recession

# PERIODONTICS

## SBQ 10

**PATIENT COMPLAINS OF BAD TASTE IN THE LOWER LEFT AREA? WHICH TEST WILL HELP YOU TO DIAGNOSE HER CONDITION?**

---

- A. Bite wing and IOPA
  - B. Sensibility test
  - C. Percussion
- Ps: \*Probing wasn't an option.

## P.O.W.E.R NOTES SBQ 10

- I. If probing was given as an option that would be the best answer as it helps to determine the presence of the periodontal pockets. Periodontal pockets lead to food impaction and bad breath/ bad taste.  
Bitewing and IOPA will be helpful to see the bone loss.

# PERIODONTICS

## SBQ 11

**PATIENT WITH PERIODONTITIS THAT USES WHICH OTHER HYGIENE TOOL HE WAS MISSING TO USE? OPEN SPACES BETWEEN TEETH.**

- A. Water Floss
- B. Pikster
- C. Electric toothbrush
- D. Mouthwash AND interdental toothbrushes
- E. Interdental toothpicks

## P.O.W.E.R NOTES SBQ 11

- I. For interdental cleaning interdental brushes and dental floss are used. Interdental brush is used for the open spaces between the teeth whereas dental floss is used for the tight contacts.  
Regular dental floss is superior to the water floss.  
According to TG mouth wash is not recommended on daily basis.  
“**Pickster**” is a brand name for interdental brushes which can be used in the open space between the teeth.

# PERIODONTICS

## SBQ 12

WHILE PROBING THE BLACK BAND IS TOTALLY VISIBLE, AND PATIENT HAS OVERHANGING FILLINGS, BOP, WHICH BPE SCORE WOULD INDICATE THIS?

- A. 1
- B. 2
- C. 3
- D. \*

## P.O.W.E.R NOTES SBQ 12

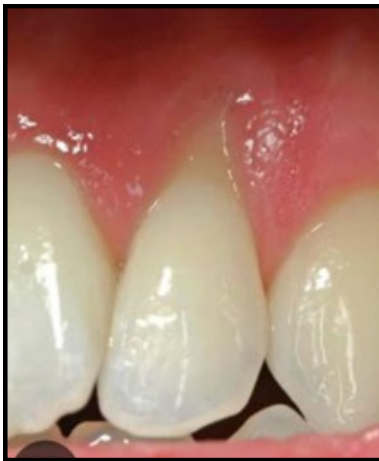I. Black band is completely visible in 0,1,2 BPE scores. Calculus and over hanging restorations are present in BPE score 2.



# PERIODONTICS

## SBQ 13

LADY WHO COMPLAINTS OF PRESSURE IN HER TEETH AROUND 23 (SHE FEELS HER TEETH 'JAMMED') IT IS SO INTENSE THAT SHE USES RUBBER AND TOOTHPICK OR ANYTHING AVAILABLE TO REMOVE THE FOOD STUCK TO RELIEVE THE PRESSURE SHE BRUSHES TWICE DAILY SHE ALSO FLOSSES INTERDENTAL BRUSHES ALSO SHE USES. SHE SAID EVEN WHEN SHE WAS TALKING TO SOMEONE, SHE WILL LEAVE AND FIND ANYTHING SHE CAN FIND, EVEN A TWIG FROM THE STREET TO CLEAN HER TEETH. (EVEN A TWIG TO PUT INTERDENTALLY SO SHE CAN RELIEVE THE PRESSURE) SHE IS REALLY STRESSED BECAUSE HER BUSINESS GOT AFFECTED BY COVID, SAID SHE HAS HAD TO FIRE 10 OF HER EMPLOYEES DUE TO HER COMPANY BEING IN A FINANCIAL CRISIS. SHE IS ON BANKRUPTCY.



I. On examination YOU found trauma for gingiva around 23 picture was given.

What is the diagnosis

- A. Necrotizing gingivitis
- B. Traumatic injury
- C. Stillman's cleft
- D. Dehiscence

II. What is the reason

- A. Stillman cleft
- B. Trauma
- C. Stress
- D. Poor oral hygiene
- E. Inflammation

III. The lady also had generalized mild gingivitis with shiny attached gingiva.

Reason for gingivitis May be

- A. Mechanical injury caused gingivitis
- B. Plaque induced gingivitis.
- C. Generalized Perio
- D. Gingivitis due to bacterial condition
- E. Viral infection

# PERIODONTICS

## SBQ 13

### IV. WHAT IS THE CAUSE OF PRESSURE" (exact wording)

- A. Dissection
- B. Trauma
- C. Recession

### V. What mouthwash would you prescribe to her to help her while she is waiting for a specialist appointment.

- A. Antibacterial gel
- B. Analgesic
- C. Topical anesthetic mouthwash
- D. Moisturizing gel
- E. Anti inflammatory mouthwash
- F. Essential oil

# PERIODONTICS

## P.O.W.E.R NOTES SBQ 13

- I. Tooth pick can lead to gingival trauma, recession and bone loss. So, we don't recommend to use it.

**STILLMAN'S CLEFT:** It's a mucogingival triangular shape defect. Predominantly seen on the buccal surface of the root. It can be related to occlusal trauma which is associated either with marginal gingivitis or periodontitis. It can be found as depression or a define fissure extending up to 5-6mm of length. Other cause can be traumatic tooth brushing, incorrect use of interdental floss.

Patient has been using flossing and interdental cleaning agent excessively. So, there's a relationship between the traumatic tooth brushing and gingival recession.

**FENESTRATION AND DEHISCENCE:** A fenestration is an isolated area in which the root of a tooth has bone resorption and it is only covered by periosteum and gingival tissues, but maintains an intact marginal ridge. But when the bone resorption involves the marginal ridge, it is called a dehiscence.

- II. Aetiology for stillman's cleft is trauma. Poor OH will lead to dehiscence. Dehiscence is a "U" shaped depression, starting from the marginal bone.
- III. When there's mild gingivitis in the absence of plaque and calculus, with the presence of shiny attached gingiva. This is due to excessive abrasion of gingiva as a result of mechanical injury.
- IV. Patient feels pressure on her teeth and this pressure is due to the trauma because she continuously traumatises the gingiva by vigorously using interdental cleaning. Recession is the outcome of it.
- V. Question specifically ask for a mouth wash. So, option (A), (D) get ruled out. She doesn't have pain. She has pressure on the gums. Therefore, analgesics and anaesthetics are not required. Option (B) and (C) get ruled out. There's an inflammation of the area due to the mild gingivitis. So, anti-inflammatory mouth wash is suitable.

# PERIODONTICS

## SBQ 14

**LADY, CAME FOR NORMAL PERIODONTAL EXAMINATION - FIND OUT UPPER TOOTH (28) - GRADE 2 MOBILITY - NO PAIN, BUT SUPPURATION ON PROBING - COMES TO YOU SAYING, RECENTLY TOOK HOME PREGNANCY TEST, BEFORE WEEK AND POSITIVE.**

### **I. How to manage?**

- A. Take radiograph and extract now
- B. Extract without taking radiograph
- C. Defer radiograph and extraction till 2nd trimester
- D. Defer radiograph and extraction till 3rd trimester

### **II. There was a question from some other scenario saying what is the earliest time for LA injection in pregnant female?**

- A. 1st trimester
- B. 2nd trimester
- C. 3rd trimester
- D. 4th trimester

### **III. Following question - she comes back to you - 14 weeks pregnant - for tooth cleaning - but sensitivity present - so what LA will you give**

- A. Lignocaine 2% with adrenaline
- B. Articaine with adrenaline
- C. 3% Prilocaine with felypressin

### **IV. She asks about the baby's oral health, when to bring the baby to the dentist - you say, bring on his first birthday! What will you check up on that stage**

- A. Oral brushing habits
- B. Fluoride varnish
- C. Solid food
- D. Epstein pearl
- E. Oral hygiene

### **V. If she comes with a baby who is 10 months old and he has his two lower incisors what would you recommend...she said the child does lots of breastfeeding at night, breastfeeding and what is the best preventative measure for the child?**

- A. Brush teeth with low fluoride toothpaste
- B. Use wipe to clean teeth after breastfeeding
- C. Use fluoridated water

# PERIODONTICS

## P.O.W.E.R NOTES SBQ 14

- I. In the 1st trimester of pregnancy elective dental treatments are not done. And the patient doesn't have any pain. But can perform scaling as there's suppuration present on probing.
- II. For LA, there's no contraindication. You can give LA in 1st trimester as well. So, if you are planning to perform FMS in this case you can give LA if required.
- III. There's no contraindication for lignocaine with adrenaline in pregnancy.
- IV. At the age of 1yr we check for the OH and the eruption status of teeth.
- V. According to TG, fluoridated toothpaste is recommended at the age of 18months. According to WHO recommendation fluoridated water is not given up to the age of 10months.

# PERIODONTICS

## SBQ 15

OLD MAN WITH EXPOSED ROOTS, JUST WANT TO CLEAN HIS TEETH, COMPLAINING SENSITIVITY WHAT DO U PRESCRIBE TO HIM IN CONJUNCTION WITH INTERDENTAL BRUSHES.

- A. Fluoride varnish monthly
- B. Toothpaste with potassium nitrate
- C. Fluoride mouthwash

## P.O.W.E.R NOTES SBQ 15

- I. Amongst the given potassium nitrate is the desensitising agent. Fluoride varnish is recommended to use in 6 months intervals.

# PERIODONTICS

## SBQ 16

YOU WANT TO DO THE SCALING OF THE LOWER ANTERIORS. PATIENT IS FEELING PAIN WHILE DOING THE SCALING. WHAT WOULD YOU GIVE ? (SUBGINGIVAL SCALING)

- A. Lignocaine gel
- B. Lignocaine block
- C. Lignocaine infiltration

## P.O.W.E.R NOTES SBQ 16

I. No need to give a block for scaling. Anaesthetic gel is given prior to injecting.

# PERIODONTICS

## SBQ 17

MRS HONG WORKS IN A RESTAURANT AND WORKS TILL NIGHT. MRS AND MR HONG RECENTLY RETURNED FROM TRIP TO VIETNAM TO VISIT HER FATHER-IN-LAW. THEY HAD FINANCIAL PROBLEM SAVING FOR NEW HOUSE. WORKS HEAVILY SHE DISCONTINUED HER EDUCATION ON 6TH STANDARD. SHE FEELS ABOUT HER DENTAL HYGIENE STATUS.

- 
- I. What factors would have led to high caries risk in the patient?
- A. Socio economic, educational, professional
  - B. Educational, marital status, professional
  - C. Socio economic, marital status, professional
  - D. Socio economic, educational, marital status , cultural linguistic background
- II. Mrs. Hong has 2 front crowns, missing teeth, and the crowns are loose. what investigation to do with Based on given conditions and from photo of Mrs. Hong anterior gum with crowns of 11 21, She wants to replace her crowns.
- A. Probing, bone sounding, smile analysis
  - B. Probing, iopa, remove crown
  - C. Probing, vitality test
  - D. Vitality test, bone sounding, smile analysis
- III. Continued from the previous question. What advice you should give her if she is diagnosed with xerostomia?
- A. Xylitol gum, frequent drinking of water, oral hygiene instruction
  - B. Diet analysis, frequent drinking of water, ohi
  - C. Salivary substitute, ohi



# PERIODONTICS

## P.O.W.E.R NOTES SBQ 17

- I. Marital status has no effect on high caries risk. So, options (B), (C), (D) get ruled out.
- II. **Bone sounding** is done to address the crest of the level of the bone which would dictate whether there is violation of BW or not. That's important to know when you are giving a new crown to re-establish the margins.

**Smile analysis** is also needed when you are giving new crown and in the presence of missing teeth.

**Probing** is done to check for the attachment loss and VRF.

**Vitality test** may be required when you are giving crowns again.

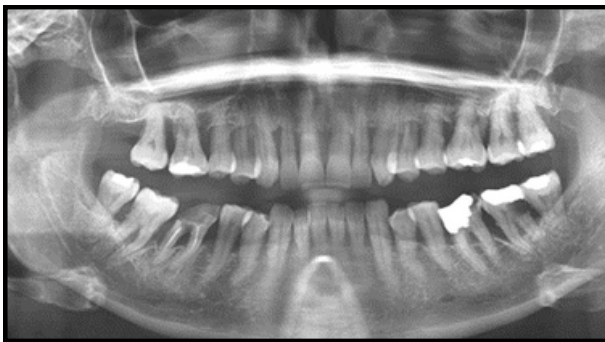Most importantly **probing, IOPA, crown removal** will show the remaining attachment, crown: root ratio, remaining tooth structure, whether there is fracture or not

- III. Dry mouth management according to TG; frequent drinking of water and xylitol gum come first.

# PERIODONTICS

## SBQ 18

A 64 YR OLD LADY. SHE IS SOCIAL IN CULTURAL GATHERINGS AND IS CONSIDERED A SAMOAN ELDER. SHE IS DIABETIC BUT SAYS HER DIABETES IS WELL UNDER CONTROL AS SHE IS ON A CONTROLLED DIET. PLAQUE DEPOSITS, GENERALISED PERIODONTITIS. USED TO SMOKE 10 CIGARETTES BUT QUIT NOW, CLINICAL ATTACHMENT LOSS MORE THAN 6MM. HASN'T BEEN TO THE PHYSICIAN AND DENTIST, BONE LOSS TILL APICAL THIRD IN FEW MOLARS. OPG - ALL FIRST MOLARS HAD BONE LOSS WITH FURCATION INVOLVEMENT. PREMOLARS HAS 50 PERCENT BONE LOSS UPPER N LOWER, SUBGINGIVAL CALCULUS PRESENT



**I. You believe that her diabetes is not as controlled as she thinks it is. What is the best test to check for diabetes?**

- A. Haemoglobin a1c
- B. Glucose tolerance test
- C. Fasting glucose
- D. Random glucose
- E. Glucose Screening

**II. Perio classification asked after describing her Periodontitis staging and grading features in question.**

- A. Stage 3 grade C unstable
- B. Stage 4 grade B unstable
- C. Stage 3 grade B stable
- D. Stage 4 grade C stable
- E. Stage 4 grade C unstable

**III. Which indicates rate of progression?**

- A. %bone loss by age
- B. Clinical attachment loss analysis
- C. Plaque index

**IV. Which clinical finding describes stage of periodontitis?**

- A. Radiographic attachment loss
- B. Bleeding on probing
- C. Overhanging restoration
- D. Deep bite forces
- E. Smoking

# PERIODONTICS

## SBQ 18

### V. Bpe 112/212 indicates?

- A. Bleeding on probing and calculus
- B. Gingival inflammation
- C. Pockets in all quadrants

### IV. 1/1/1

1/2/1 CPITN index scores what it indicates on intraoral findings?

- A. Gingival bleeding in all sextant
- B. Gingival bleeding and calculus detected in one sextant
- C. Gingival bleeding and calculus in all sextant
- D. Gingival bleeding and calculus detected

### VI. The best antibiotic combination with Metronidazole for prescribing after Scaling and root planing, which is scientifically proven to reduce pocket depths?

- A. Amoxicillin
- B. Clindamycin
- C. Azithromycin
- D. Doxycycline

## P.O.W.E.R NOTES SBQ 18

- I. The best way to estimate and evaluate her DM condition is hba1c. nothing else will tell the chronic overall management and the blood sugar level of the last 3months.
- II. Bone loss is seen up to the middle and apical 3rd. but there's no flaring, no drifting of teeth, no ridge defects because teeth have not been lost yet. Therefore, this is stage 3 situation.

In this case hba1c level and smoking hx is not given. So, to know about the grading u must use the formula = % bone loss/ age

More than 50%/64= which means patient falls in grade C. (only in the area of premolar region it shows 50% bone loss.)

There are plaque deposits and patient hasn't got any treatment yet. Before the treatment when the disease is in the active state, it is unstable. After getting treatment if still bleeding on probing present, if still plaque and calculi present, then it will be unstable. After getting the treatment if there's no BOP and reduced PD, then it will be stable.

# PERIODONTICS

## P.O.W.E.R NOTES SBQ 18

### Staging and Grading Periodontitis



The 2017 World Workshop on the Classification of Periodontal and Peri-Implant Diseases and Conditions resulted in a new classification of periodontitis characterized by a multidimensional staging and grading system. The charts below provide an overview. Please visit [perio.org/2017wwdc](http://perio.org/2017wwdc) for the complete suite of reviews, case definition papers, and consensus reports.

#### PERIODONTITIS: STAGING

Staging intends to classify the severity and extent of a patient's disease based on the measurable amount of destroyed and/or damaged tissue as a result of periodontitis and to assess the specific factors that may attribute to the complexity of long-term case management.

Initial stage should be determined using clinical attachment loss (CAL). If CAL is not available, radiographic bone loss (RBL) should be used. Tooth loss due to periodontitis may modify stage definition. One or more complexity factors may shift the stage to a higher level. See [perio.org/2017wwdc](http://perio.org/2017wwdc) for additional information.

	Periodontitis	Stage I	Stage II	Stage III	Stage IV
Severity	Interdental CAL (at site of greatest loss)	1 – 2 mm	3 – 4 mm	≥5 mm	≥5 mm
	RBL	Coronal third (<15%)	Coronal third (15% - 33%)	Extending to middle third of root and beyond	Extending to middle third of root and beyond
	Tooth loss (due to periodontitis)	No tooth loss		≤4 teeth	≥5 teeth
Complexity	Local	<ul style="list-style-type: none"> <li>Max. probing depth ≤4 mm</li> <li>Mostly horizontal bone loss</li> </ul>	<ul style="list-style-type: none"> <li>Max. probing depth ≤5 mm</li> <li>Mostly horizontal bone loss</li> </ul>	In addition to Stage II complexity: <ul style="list-style-type: none"> <li>Probing depths ≥6 mm</li> <li>Vertical bone loss ≥3 mm</li> <li>Furcation involvement Class II or III</li> <li>Moderate ridge defects</li> </ul>	In addition to Stage III complexity: <ul style="list-style-type: none"> <li>Need for complex rehabilitation due to:               <ul style="list-style-type: none"> <li>Masticatory dysfunction</li> <li>Secondary occlusal trauma (tooth mobility degree ≥2)</li> <li>Severe ridge defects</li> <li>Bite collapse, drifting, flaring</li> </ul> </li> <li>&lt; 20 remaining teeth (10 opposing pairs)</li> </ul>
Extent and distribution	Add to stage as descriptor	For each stage, describe extent as: <ul style="list-style-type: none"> <li>Localized (&lt;30% of teeth involved);</li> <li>Generalized; or</li> <li>Molar/incisor pattern</li> </ul>			

#### PERIODONTITIS: GRADING

Adapted from: see [perio.org/2017wwdc](http://perio.org/2017wwdc) for additional information

Grading aims to indicate the rate of periodontitis progression, responsiveness to standard therapy, and potential impact on systemic health. Clinicians should initially assume grade B disease and seek specific evidence to shift to grade A or C.

	Progression		Grade A: Slow Rate	Grade B: Moderate Rate	Grade C: Rapid Rate
Primary criteria Whenever available, direct evidence should be used	Direct evidence of progression	Radiographic bone loss or CAL	No loss over 5 years	<2mm over 5 years	≥2mm over 5 years
	Indirect evidence of progression	% bone loss ÷ age	≤.24	.25-1.0	≥ 1.1
		Case phenotype	Heavy biofilm deposits with low levels of destruction	Destruction commensurate with biofilm deposits	Destruction exceeds expectations given biofilm deposits; specific clinical patterns suggestive of periods of rapid progression and/or early onset disease
Grade modifiers	Risk factors	Smoking	Non-smoker	≤9 cigarettes/day	10+ cigarettes/day
		Diabetes	Normal glycemic/no diagnosis of diabetes	HbA1c ≤6.99% in patients with diabetes	HbA1c ≥7.0 in patients with diabetes

# PERIODONTICS

## P.O.W.E.R NOTES SBQ 18

III. Rate is the speed. It denotes whether it is rapid or slow. Speed of progression is the grade. Grade indicators are smoking, DM and %bone loss as per the age. Clinical attachment loss is the severity, that would be the staging criteria.

IV. **BOP** and **PD** can determine the stability. Presence of BOP and increased PD determines the presence of active/ unstable disease.

**Smoking** is a grade factor.

**Deep bite forces** are neither the grading nor staging factors.

**Overhanging restoration** describes the BPE score.

**Attachment loss** criteria is for staging.

V.

Probing depth	Observation	BPE Score
Black band completely visible	No probing depths >3.5 mm, no calculus/ overhangs, no bleeding after probing	0
Black band completely visible	No probing depths >3.5 mm, no calculus/ overhangs, but bleeding after probing	1
Black band completely visible	No probing depths >3.5 mm, but supra- or sub-gingival calculus/overhangs present	2
Black band partially visible	Probing depth(s) of 3.5 – 5.5 mm present	3
Black band entirely within the pocket	Probing depth(s) of 6 mm or more present	4
N/A	Furcation involvement	*

VI.1 denotes bleeding and 2 denotes the presence of calculus. So, calculus is detected only in one sextant.

VII. Metronidazole acts on the gram negative. Usually amoxicillin is given in combination with metronidazole. Clindamycin is broad spectrum and given as a single drug. Azithromycin acts on the gram negative. Doxycycline is used in periodontitis but not in combination with metronidazole. It's given as a single drug.

# PERIODONTICS

## SBQ 19

### IMPLANT

I. You decided to extract a first molar for a patient and now plan to replace it with an implant. While placing the implant, you should be careful regarding which nerve?

- A. Mylohyoid nerve
- B. IAN
- C. Mental
- D. Long buccal
- E. Lingual nerve

II. Why are you considering CBCT

- A. Lingual bone contour/concavity
- B. Bone width

### P.O.W.E.R NOTES SBQ 19

I. IAN is most commonly injured nerve (64.4%), followed by the lingual nerve (28.8%) during mandibular implant placement in the molar region. If it was a premolar situation mental nerve would be the answer.

II. Bone width can be measured by the bone sounding.

CBCT scans help in the planning of oral implants, they enable measurement of the distance between the alveolar crest and mandibular canal to avoid impingement of inferior alveolar nerve, avoid perforation of mandibular posterior lingual undercut, and assess the density and quality of bone.



# PERIODONTICS

## SBQ 20

**WHICH LOCAL CRITERIA WILL HELP WITH THE STABILITY OF THE IMPLANT AND WILL FURTHER HELP IN THE TREATMENT PLANNING FOR THIS PATIENT?  
OR  
WHICH LOCAL CRITERIA WILL YOU CHECK BEFORE PLACING AN IMPLANT IN THE PATIENT?**

---

- A. Plaque index
- B. Bleeding on probing
- C. Take study model cast
- D. Cbct
- E. Opg

## P.O.W.E.R NOTES SBQ 20

- I. Suppose that patient didn't brush one day before the dental appointment, then the plaque index will be high. But there won't be established gingivitis.

In the presence of BOP in the area where you are planning to place implants, it's an immediate sign that you need to postpone the surgery until the tissues healed and arrest BOP. BOP indicate active gingivitis.

(B), (C), (D) are not local factors.

# ORAL SURGERY

## SBQ 1

75 YEARS OLD, HAD HEPATITIS-B HISTORY AS A CHILD. HE HAD A STROKE 2 YEARS BACK AND WAS TAKING WARFARIN FOR IT BUT THE GP CHANGED IT TO DABIGATRAN RECENTLY. HAS HYPERTENSION, TAKING MEDICATION FOR IT, HAS ATRIAL FIBRILLATION.

### I. What is the best test to check warfarin?

- A. INR
- B. Prothrombin test
- C. Ptt
- D. Bt

### II. If you have to do extraction. What will you consider?

- A. Give ab prophylaxis
- B. Speak to GP and ask about liver function test (it mentioned for drug clearance)
- C. Reduce the dose of dabigatran
- D. Assume dabigatran will cause minimal bleeding and go ahead with local hemostatic measures

### III. When will you check inr?

- A. On the day of the procedure
- B. 36 hours before the procedure
- C. 48 hours before the procedure
- D. 72 hours before the procedure

### IV. Opg given 27 no 26 25. Isolated molar.

What will be the major risk in extracting 27 (complication for extraction)?

- A. Oaf (x-ray showed communication with the antrum)
- B. Tuberosity fracture
- C. Fracture of roots

### V. A patient on renal dialysis has end stage kidney disease. Goes for dialysis 3 times a week. You have to do an extraction. What is the best way to manage him? (asa)

- A. Treat on the day of dialysis
- B. Refer to a specialist for the dental treatment
- C. Treat her on non dialysis days
- D. Give painkillers



# ORAL SURGERY

## P.O.W.E.R NOTES SBQ 1

- I. The international normalised ratio (INR) blood test tells you how long it takes for your blood to clot. It is used to test clotting times in people taking warfarin.
- II. Patient is on one anticoagulant. So, we can proceed ahead with extraction in the absence of patient related factors. But in this there's a patient related factor (hx of hepatitis is present. This can prolong bleeding)
- III. We check INR within 24hrs. among the given (A) is the best.
- IV. 27 is an isolated, standalone maxillary molar which is more prone to get ankylosed. Therefore, there's a high risk of tuberosity fracture.
- V. According to TG, end stage kidney disease is a severe immune compromised situation. These patients are handled by the specialist and multidisciplinary team.

# ORAL SURGERY

## SBQ 2

A 65 YEARS OLD PATIENT HAS A PROBLEM AT 15 AND WANTS AN EXTRACTION. THE LADY HAD HYPERTENSION 155/95 BP, A STROKE 9 YEARS BACK, SMOKED 10 CIGARETTES IN A DAY, HAS EMPHYSEMA, PACEMAKER PRESENT. PATIENT TOLD THE DOCTOR THAT SHE NEEDS ANTIBIOTIC PROPHYLAXIS. THE PATIENT WAS VERY ANXIOUS.

### I. In which case surgical antibiotic prophylaxis is required?

- A. Dry socket
- B. Root fracture
- C. Sinus perforation
- D. Spread of infection
- E. Adjacent filling may fall out

### II. In which classification does this patient fall?

- A. ASA2
- B. ASA1
- C. ASA3
- D. ASA4
- E. ASA5

### III. Iopa/opg given what will be the most likely complication with the extraction in this case?

- A. Dry socket
- B. Root fracture
- C. Sinus perforation
- D. Spread of infection
- E. Adjacent filling may fall out

### IV. By mistake during extraction, you displaced the opposing amalgam restoration as your forceps slipped. What will you do?

- A. Inform the patient, replace the restoration and ask him to pay
- B. Inform the patient, replace the restoration and you do it for free
- C. You don't tell the patient now to prevent additional stress and tell him in next appointment
- D. Inform the patient in that appointment and restore and ask him to pay
- E. Replace the restoration and do not tell the patient

### V. Patient requested for sedation as she is scared of needles and we have planned the nitrous oxide sedation. The patient came the next morning and had already taken diazepam 10gm. What will you do now?

- A. Lower the dose of nitrous oxide
- B. Do not administer nitrous
- C. Lower the dose of la and normal nitrous oxide sedation
- D. Go ahead with planned treatment and give her nitrous oxide
- E. Go ahead with treatment but give nitrous only till the injection of la

# ORAL SURGERY

## P.O.W.E.R NOTES SBQ 2

- I. None of the given options require ABP. Cyanotic heart defects require ABP. Valvular conditions don't require ABP. Patent ductus arteriosus is an acyanoitic condition, but it also gives some cyanosis.
- II. Due to uncontrolled HTN and smoking, this patient is falling under ASA class III.
- ASA I- healthy
  - ASA II- mild and controlled
  - ASA III- uncontrolled and may require specialist referral
  - ASA IV- referral to hospital
  - ASA V- requires operation
- III.
- Need the x-ray for marking the answer.
  - If it's a grossly broken max. molar, there's a risk of root #.
  - If there's an adjacent filling in relation to the extracting tooth, then option (E).
  - Sinus perforation can't be seen with the 2-dimentional. Radiograph doesn't review. We don't inform about sinus perforation before the treatment. When you identify a communication has occurred, you must correct it immediately and inform the patient. It's not the clinician's fault as the sinus line can't be seen with the 2-dimentional as it's a soft tissue lining and sometimes the root can overlap.
  - Spread of infection is not a complication with the aseptic techniques.
  - Dry socket is seen commonly in the mandible.
- IV. Must inform the patient what has happened and shouldn't charge from the patient as it's a mistake happened by the dentist.
- V. Both N2O and diazepam can't be given at the same time.

# ORAL SURGERY

## SBQ 3

### INFRAORBITAL SPACE INFECTION

PT HAD FEVER 39.5, INFRAORBITAL SWELLING, OEDEMA AND TOOTH INVOLVED WAS MOBILE

---

#### I. Which tooth is likely to cause this infection?

- A. Canine
- B. Lateral incisor
- C. Central incisor
- D. First premolar
- E. Second molar

#### II. How to diagnose?

- A. Ept
- B. Cold test
- C. Heat test
- D. Percussion

#### III. The infection has spread to which facial space?

- A. Canine space
- B. Maxillary space
- C. Buccal space
- D. Labial space
- E. Palatal space

#### IV. What treatment can be done?

- A. Refer to hospital
- B. Extraction and drainage
- C. Extraction and antibiotics
- D. Rct and antibiotics
- E. Drainage through intraoral incision

#### V. Patient has a headache, can't open his eyes, nausea and drooping of eye.

##### What is happening?

- A. Maxillary sinusitis
- B. Cavernous sinus thrombosis
- C. Migraine

# ORAL SURGERY

## P.O.W.E.R NOTES SBQ 3

- I. Canine has got the longest root, so, canine is mostly involved with infraorbital space infections. Also known as canine space infection.
- II. Cold test is the best vitality test. Infection comes from the necrosed pulp tissue. Percussion is an indicator of the inflammation within the periapical PDL. When there's a space infection, you need to identify the infected pulp. Percussion can become positive even with the traumatic occlusion. Percussion may become negative in this case as it's not a localised infection and it's a spreading infection and pus accumulation is beyond the PDL now. Percussion test reveals PLD inflammation due to traumatic bite, high point, food impaction.
- III. Involvement of the maxillary incisors and canines may result in a **canine space** infection, which manifests as dramatic swelling of the upper lip, canine fossa, and, frequently, the periorbital tissues.
- IV. Patient has high grade fever. It's a spreading infection with severe systemic features. Therefore, need to refer to the hospital as IV AB and extraction is immediately needed.
- V. Cavernous sinus thrombosis is the most common complication of infraorbital space infection.  
Cellulitis and respiratory space involvement are the most common complications of submandibular space infection.

# ORAL SURGERY

## SBQ 4

**A MALE PT IN HIS 30'S REPORTED TO YOU REGARDING A COMPLAINT OF CLICKING OF HIS TMJ. CEREBRAL PALSY CASE.**

**I. What is the best investigation to examine and diagnose his joint problem?**

- A. Ultrasound
- B. Cbct
- C. Opg, Lat oblique.
- D. MRI

**II. While examining, you notice a trismus. What is the minimum requirement for mouth opening in order to diagnose that it's not trismus? (Measuring mouth opening (trismus) mentioned limited mouth opening)**

- A. Fits 2 fingers of the practitioner
- B. Fits 3 fingers of the practitioners Fits 2
- C. Fingers of the patient
- D. Fits 3 fingers of the patent
- E. The mandible something

**III. 3rd molar needs extraction which xray modality would be the best for treatment planning?**

- A. Cbct
- B. Mri
- C. Ct scan
- D. Oral pantomogram

**IV. Which splint?**

- A. Mandibular repositioning splint (joint problems)
- B. Michigan splint (for TMD stabilisation & bruxism)
- C. Michigan and mandibular advancement splint
- D. Morning repositioning splint
- E. Mandibular advancement splint

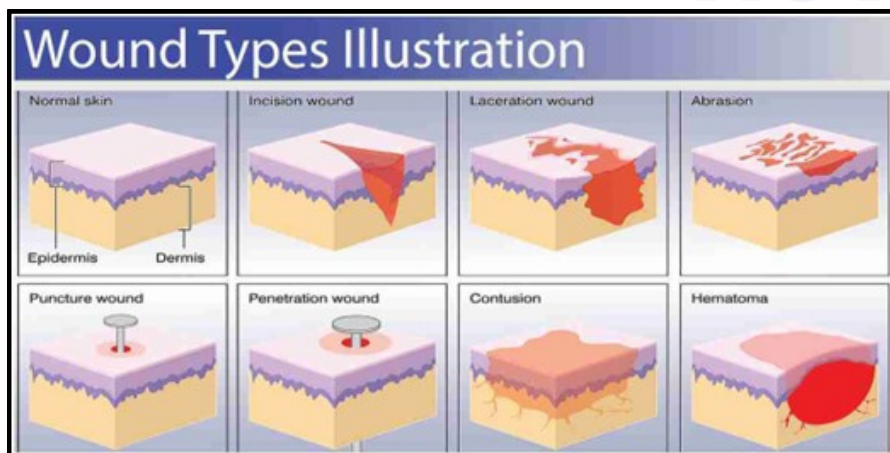
**V. He has an injury on his forehead in which a part of skin peeled off and the blood was oozing. What kind of injury is it?**

- A. Abrasion
- B. Bruising
- C. Laceration
- D. Puncture

# ORAL SURGERY

## P.O.W.E.R NOTES SBQ 4

- I. Patient has clicking which means the disk is involved. We don't do soft tissue examination when the disk gets involved. MRI is the best to investigate this.
- II. **"Three Finger test"**: ask the patient to insert three fingers into the mouth. If all three fingers fit between the central incisors, mouth opening is considered functional. If less than three fingers can be inserted, restriction is likely.
- III. Nerve involvement is needed to study in 3RD molar extraction. Therefore, CBCT is the best for the treatment planning.
- IV.
  - Joint problems involve disc and condyle. So, you need to reposition them. You need to create more space between the joint capsule then the symptoms will be relieved. **Mandibular reposition splint** is used to treat these problems.
  - **Michigan splint** is used in MPDS/ bruxism.
  - **Mandibular advancement split** is used in sleep apnoea.
- V. **Abrasion**- oozing of blood due to capillary bleeding.  
**Bruising** – discoloration of skin but there's no bleeding.  
**Laceration and puncture** - profuse bleeding



# ORAL SURGERY

## SBQ 5

### ICG NEW CASE

YOU BOUGHT AN OLD PRACTICE FROM A SENIOR DENTIST, YOU HAD TO CHANGE ONE ROOM (THE ROOM WAS REPROCESSING OR STERILISATION RELATED) COMPLETELY. STAFF IS VERY EXPERIENCED BUT YOU NEED TO UPDATE THEM WITH NEW INFECTION CONTROL PROTOCOLS). YOUR NEWLY APPOINTED DA IS TRAINED AND SAYS SHE'S AWARE OF ALL THE INFECTION CONTROL PROTOCOLS

**I. Your DA says, it is easier for her to soak the contaminated instruments in the hand wash basin in your surgery so that she can collect all the instruments. The materials on the instruments will not dry. What is the basic rule of infection control your DA is unaware of here?**

- A. Keep the instruments covered in a wet paper towel so that the debris shouldn't dry..
- B. You cannot wash your hands and instruments in the same basin
- C. Chair side wiping of the instruments after the procedure.
- D. We need to use a container with a lid to transport the instruments to the processing room.

**II. The mouth mirror & college tweezers being Semi critical instruments needed a full cycle of sterilisation?**

- A. Chemical disinfection
- B. Thermal disinfection
- C. Chemical and thermal
- D. Sterilisation but does not require BCI
- E. Sterilisation but requires BCI

**III. Your DA was suggesting you skip the ultrasonic cleaning step as she was sure the other sterlisation procedures were done optimally. What is the one best explanation you can give to your DA which would make a complete sense in the favour of using ultrasonic cleaning?**

- A. Washing instruments by hands can cause injury
- B. Ultrasonic cleaners remove organic masses which get stuck to instruments which prevents steam penetration.
- C. Ultrasonic is more efficient than manual cleaning.
- D. The data can be stored & monitored efficiently by use of ultrasonics.

**IV. After you open the instruments what would you tell your DA to do with the empty pouches with BCI?**

- A. You throw them.
- B. You note it down in the patients hard copy under the date & throw the pouches.
- C. Entering in the steri-manual(something similar)



# ORAL SURGERY

## SBQ 5

V. He bought a new autoclave & DA has a question, the printers was printing all the parameters. Is it necessary to do any other performance tests, isn't it enough that the data print coming from the data recorder enough?

- A. Leak rate test weekly and helix test daily
- B. Leak rate test daily bowie dick test weekly
- C. Do spore test weekly & put routine chemical indicators.
- D. Spore test daily & some thing related to indicators.

## P.O.W.E.R NOTES SBQ 5

### I. According to ICG:

Ideally there should be several sinks, one separate basin for hand washing that is fitted with elbow operated or sensor operated taps, and at least one sink for rinsing or manually cleaning contaminated instruments, that has hot and cold-water taps. Hand washing must only occur in the dedicated separated basin for hand washing, and not in the sinks used for instrument reprocessing.

### II. Semi critical instruments require sterilisation but don't require BCI.

III. Manual or mechanical cleaning should be done before sterilisation. There are 2 types of mechanical cleaning. They are instrument washer and ultrasonic cleaning. Ultrasonic cleaners are the best as they remove organic masses, with manual cleaning it's not done.

IV. BCI should be noted in the patient's records. Once it's done the packages can be discarded. Clinician is responsible for this.

V. Test with **chemical indicator** is done with each load.

**Helix test**- is done daily

**Steam penetration test- Bowie Dick test**- is done daily

**Air leak test** – daily for machines without automatic air leak detection, weekly for machines with automatic air leak detection

**Spore test**- is done annually

# ORAL SURGERY

## SBQ 6

A PATIENT COMES TO YOU AFTER A BASKETBALL ACCIDENT. A PLAYER KNOCKED ON ANOTHER PLAYERS ARM(SOMETHING SIMILAR).THIS PATIENT HAS SUFFERED DENTAL INJURY WHERE IN HIS ANTERIOR TOOTH WAS INVOLVED. HE WENT TO HOSPITAL ER & COMES BACK TO YOU FOR DENTAL VISIT. PICTURE GIVEN WITH UPPER ANTERIORS. WE COULD SEE THE SULCULAR BLEEDING IN RELATION TO THE CENTRAL INCISOR. THE TOOTH WAS SHOWING MORE THAN NORMAL MOBILITY. THE TOOTH WASN'T DISLOCATED.

### I. What type of injury is it?

- A. Subluxation
- B. Alveolar fracture
- C. Concussion
- D. Root Fracture.
- E. Extrusion

### II. You did the sensibility test but after 4weeks and it is still negative. What would be the explanation for this?

- A. Start RCT if the signs arise
- B. The status of the pulp cannot be determined by pulp sensibility testing alone
- C. Pulp necrosis

### III. How does chlorhexidine work?

- A. It is bacteriocidal & also acts in established plaque
- B. Its adsorbs onto the surfaces and works for longer time.

### IV. How do you create awareness in athletes wearing mouth guards. The patient tells that all the players in the club wear mouthguards only during competition and not during practice matches.

- A. Engage with he coaches & educate them about benefits of using mouth guard.
- B. Participate in the official club meeting and create awareness about cost versus benefits of mouth guards.
- C. Give discount on mouth guards.
- D. Issue free mouth guards for all the players

### V. When pt comes for review at 4 weeks after subluxation injury of mature lateral incisor, what signs of tooth tells u that it is going to be necrotic?

- A. Pulp sensibility negative still at 4 weeks
- B. On xray it shows canal obliteration
- C. Tooth discoloration improves
- D. NO periapical sign
- E. Still mobile

# ORAL SURGERY

## P.O.W.E.R NOTES SBQ 6

- I. Dental subluxation is a traumatic injury to the periodontal tissue in which the tooth has increased mobility (i.e., is loosened) but has not been displaced.
- II. It's normal to have negative sensibility test after trauma. Sensibility test is not indicating the exact status of pulp after a trauma.
- III. CHX works on the new forming plaque. It can absorb on to the surfaces and has a substantivity effect.
- IV. Players need to wear mouth guards during practice matches. Dentist's advise has more legit effect.
- V.
  - Pulp test is not a reliable factor at 4 weeks' time.
  - On x-ray canal obliteration is a good sign of healing because dentin gets deposited.
  - Improvement in the tooth discoloration is a good sign.
  - No periapical sign is a good sign.
  - Mobility and non-healing PDL are a bad sign. It can be a sign of external inflammatory resorption.

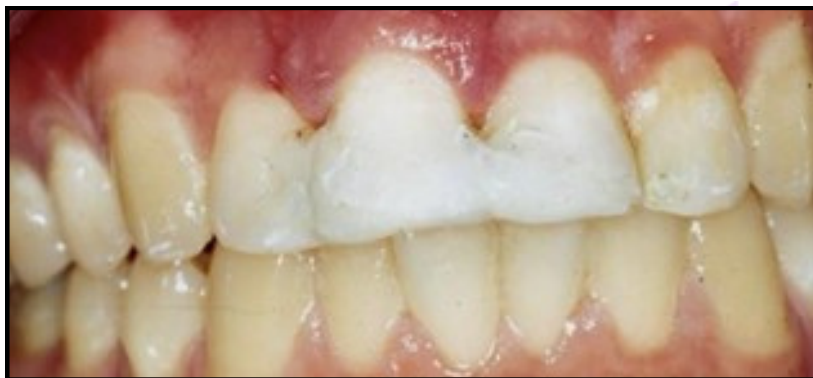# ORAL SURGERY

## SBQ 7

A 12YRS OLD BOY HAD AN ACCIDENT OF 21. HE WAS TREATED IN THE ORAL AND EMERGENCY DEPARTMENT. THEY HAVE DONE THE REIMPLANTATION & STABILISED IT WITH A RIGID SPLINT ON 11,21. MOTHER BROUGHT HIM FOR A DENTAL VISIT AFTER COMING FROM ER.

(IT WAS AFTER 24 HOURS)

MOTHER NOTICED THAT THE 21 WAS PLACED A LITTLE BIT LONGER THAT 11. (PA IS GIVEN WITH 21 STILL A LITTLE BIT EXTRUDED) MOTHER WASHED IT WITH WATER FOR 15 MINUTES AND THEN PLACED IT IN MILK.



### I. What would you do?

- A. Immediate surgical repositioning of the 21 and change the splint to flexible
- B. Digitally apply pressure to repositioned the 21 and replace it with the flexible splint
- C. Wait until it repositions by itself & observe
- D. Reposition 21 and maintain the rigid splint

### II. What will you tell the mother regarding the home care of this child?

- A. Chlorhexidine 0.2% mouthwash for 2weeks
- B. Hypochloride mouthwash
- C. Sodium bicarbonate mouthwash
- D. Hydrogen peroxide mouthwash.

### III. What would be the management of this case?

- A. Commence RCT within 10days. (In one centre within 2weeks)
- B. Wait until there is a signs of discolouration.
- C. Observe until the child complains of any symptoms
- D. Change to flexible and commence RCT within 2 weeks.

### IV. What would be the factor which would interfere with the prognosis of the tooth?

- A. As the tooth was washed in the water for 15 minutes before placing it in milk.
- B. As it was placed in the milk
- C. Type of Injury
- D. Time lapse between the accident and the tooth placement in the socket

# ORAL SURGERY

## SBQ 7

**V. The doctor had prescribed him doxycycline. What was the reason for him to choose this antibiotic?**

- A. It can be given to children of all ages and has no side effects.
- B. It has anti inflammatory, antibacterial & antiresorptive properties.
- C. It is usually well tolerated with all the children.
- D. Because of its potent antibacterial properties
- E. Because it is good for prevention of Tetanus.

## P.O.W.E.R NOTES SBQ 7

- I. The tooth was already positioned in the socket, if there's any mal positioning you can correct it by using slight digital pressure. Should not take the tooth out and reposition. Avulsion needs passive flexible splint.
- II. CHX is best for the gingival sulcular healing.
- III. For mature apex RCT is done within 2weeks time in avulsed teeth.  
In immature teeth, RCT is indicated in the presence of change in any signs/symptoms.
- IV. Immediate reimplantation should have been done within 15 mins. PDL could have been viable if it was reimplanted within 15mins. Mother did 2 mistakes in this case. She used water to wash the tooth and extra oral time was more than 15mins. Even though she placed the tooth in milk afterwards, the viability of the tooth was compromised due to osmolality.
- V. Doxycycline has anti-inflammatory, anti-bacterial, anti-resorptive activity. It's not given for children younger than 8yrs old.

# ORAL SURGERY

## SBQ 8

**TMJ RHEUMATOID ARTHRITIS CASE: PATIENT IS 33 YEARS OLD. HAD SUFFERED A BLOW TO LEFT JAW DURING HER CHILDHOOD WHILE PLAYING SPORTS. WHEN OPENING HER MOUTH SHE HAD PAIN & DEVIATION ON THE LEFT SIDE OF HER TMJ. PAIN WAS RADIATING TO EAR. SHE WAS HAVING DIFFICULTY CHEWING ON LEFT SIDE & HENCE GOT ACCUSTOMED TO EATING ON THE RIGHT SIDE. RECENTLY SHE HAS NOTED THAT HER JAW GETS MOMENTARILY LOCKED FOR WHILE YAWNING FOR 30 SECOND. (TMJ CLOSED MOMENTARILY) ..SIGNS OF BRUXISM & ATTRITION IN THE LOWER.**

**I. What question from her history is most relevant to lead you to potential diagnosis?**

- A. History of Autoimmune/degenerative disorders in the family.
- B. Anxiety/depression
- C. Post traumatic Stress disorder(PTSD)
- D. Osteoporosis
- E. Stress

**II. They gave 4 Radiographic views of the TMJ**

- A. One was normal tmj view
- B. One with rheumatoid arthritis wear condyle
- C. One with disc
- D. One looks normal as well.

**III. Which splint to give?**

- A. Michigan splint
- B. Mand advancement splint
- D. No splint
- F. Morning repositioning splint

**IV. What is the condition the patient is suffering?**

- A. Disc derangement with delayed reduction
- B. Disc derangement without reduction
- C. Disc derangement with immediate
- D. Reduction
- E. Disc derangement with open/close reduction

**V. Best investigation for TMJ?**

- A. MRI
- B. CBCT
- C. OPG
- D. CT Scan

# ORAL SURGERY

## P.O.W.E.R NOTES SBQ 8

- I. Patient has a hx of trauma in the childhood and at the present she suffers from TMD. Childhood injury is linked with the TMD.

**Association between the PTSD and TMD.**

Stress is believed to be coming from various kinds of triggers. Childhood sports injury can be a serious type of injury that can have an impact even in growing years and can develop PTSD. It can develop though out the life and can develop TMD. Stress leads to parafunction habits and bruxism.

- II. Patient is suffering from a disc disorder. There's internal disc displacement with delayed reduction.

So, the radiograph will give the image of the disc which is ahead of condyle.

- III. **Mandibular reposition splint** is used to treat disc problems.

**Michigan splint** is used in MPDS/ bruxism.

**Mandibular advancement** split is used in sleep apnoea.

- IV. **Wilkes Classification of Internal Derangement**

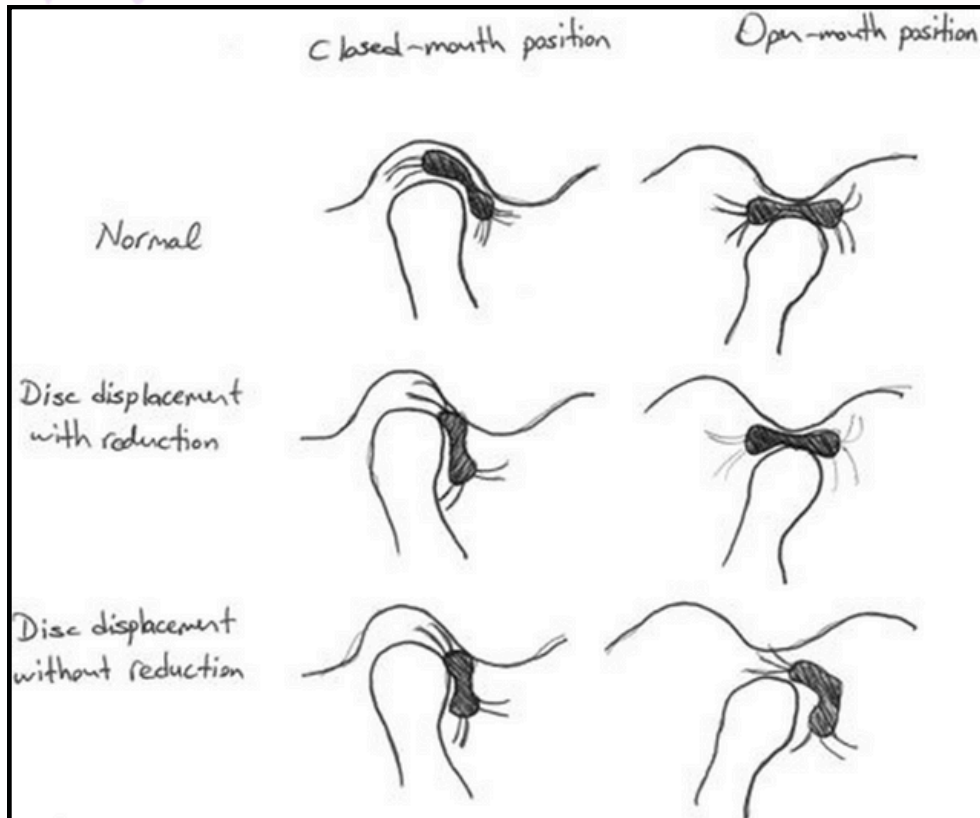
<b>Stage I</b>	Early reducing disk displacement No pain or limitation, early opening click
<b>Stage II</b>	Late reducing disk displacement One or more episodes of pain, mid to late opening click, transient catch & lock
<b>Stage III</b>	Nonreducing disk displacement: acute/subacute Multiple painful episodes, locking, restricted mobility
<b>Stage IV</b>	Nonreducing disk displacement: chronic Increasing functional disturbance
<b>Stage V</b>	Nonreducing disk displacement: chronic with osteoarthritis, crepitus, scraping, grating, grinding symptoms; pain, restricted motion, difficult function



# ORAL SURGERY

## P.O.W.E.R NOTES SBQ 8

IV.



V. When we want to see the disc derangement, the soft tissue analysis MRI is the best as it shows the articular eminence, disc and the condyle.



# ORAL SURGERY

## SBQ 9

64 YEAR OLD PATIENT CAME WITH PAIN ON BITING AND HAS A PERIAPICAL ABSCESS. SHE COMES TO YOUR CLINIC FOR AN EXTRACTION. PATIENT IS IN PAIN. YOU PLANNED A RCT TREATMENT, SHE HAD POSTPONED HER APPOINTMENT. NOW SHE GIVES YOU A CALL SAYING SHE IS HAVING SEVERE PAIN, BUT YOUR AREA IS IN LEVEL 3 RESTRICTIONS.

**I. You extract her tooth but she is able to pay only 50 percent right now and couldn't pay the full amount. She calls you from home saying she is in pain after 24 hours. What will you do?**

- A. Don't treat till she pays the full amount
- B. Give her an appointment to come and see you in the clinic on emergency basis
- C. Ask her to pay the full amount first before doing any treatment
- D. Refer her to community clinic

**II. After a few months she comes to you wanting an extraction for another tooth, complains of some pain. She has paid full amount by now. But your area is now under ADA level-3 restrictions. And it is in the hot spot zone. How will you proceed?**

- A. Use N95 mask and extract instead of surgical mask
- B. Do emergency access opening and expatriate the pulp to relieve pain use rubber dam and give temp restoration
- C. Refer to the hospital emergency dept.
- D. Refer to oral surgeon
- E. Prescribe Painkillers and antibiotics

**III. What will be the complication of extraction?**

- A. Infection
- B. Root fracture

**IV. The patient did not want a rubber dam .What will we advise her?**

- A. Respect her feelings and do not apply Rubber Dam
- B. Tell her we can't continue treatment without Rubber Dam and offer alternative such as extraction
- C. Refer to endodontist
- D. Refuse treatment

**V. What would you do to her. She says she wants extraction.**

- A. Refer to hospital
- B. Extirpate the pulp under dental dam to relieve her pain
- C. Do extraction

# ORAL SURGERY

## P.O.W.E.R NOTES SBQ 9

Let's treat this patient as a normal patient and not as a covid positive patient.

- I. According to TG, after an extraction any complication should be treated by the treating dental surgeon. Cost is not coming as a 1st factor in the emergency management.
- II. Infection is not a common complication if you are following the aseptic techniques. Root fracture is a common complication in a grossly destructed tooth.
- III. Should explain the patient that treatment can't be done without the rubber dam and the only option which is left is extraction without using the rubber dam. After saying this if the patient disagrees to extract the tooth, patient should be referred to the specialist.
- IV. Patient agreed to the alternative treatment plan we mentioned. So, you can proceed with extraction.

# ORAL SURGERY

## SBQ 10

62 YEARS OLD LADY. SHE HAS A COMPLEX MEDICAL HISTORY & TAKING LOTS OF MEDICATIONS HAS A HIP JOINT REPLACEMENT. COMES TO YOUR PRACTICE FOR EXTRACTION. SHE SAYS SHE HAS ALWAYS BEEN GIVEN ANTIBIOTIC COVERAGE & HENCE MARKED THE NEED FOR ANTIBIOTIC COVERAGE.

### I. In which case antibiotic prophylaxis is required?

- A. Ventricular septal defect
- B. Mitral valve prolapse
- C. Hip replacement
- D. Patent ductus arteriosus
- E. Mitral valve prolapse

### II. For which procedures do you need antibiotic prophylaxis?

- A. Procedures that might cause infection
- B. Deep invasive procedures
- C. Severe infected (didn't have this option)
- D. All dental procedures.
- E. Procedures causing inflammation

### III. Patient complains of pain on biting, which investigation would be most helpful?

- A. Percussion test
- B. Probing test
- C. Radiographs
- D. Vitality test
- E. Selective cuspal loading

### IV. Antibiotic regime for Infective endocarditis.

- A. Clindamycin 600mg Oral one hour before the procedure
- B. Amoxicillin for 5days
- C. Tetracycline for 5days
- D. Amoxicillin but regime wasn't correct.

# ORAL SURGERY

## P.O.W.E.R NOTES SBQ 10

- I. According to TG, AB prophylaxis is not indicated in the hx of hip replacement.  
None of the given options require AB prophylaxis. Although patent ductus arteriosus is an acyanotic defect, some cyanotic features are seen. Therefore, among the given it's chosen.
- II. Deep invasive procedures, where there's a chance of contamination involving the deeper circulation require ABP.
- III. No pain on hot and cold, no spontaneous pain indicated that there's no pulpal involvement. When only pain on biting present, percussion test is helpful to localise the pain and identify the tooth.
- IV. Options (B) and (C) are therapeutic doses. Clindamycin 600mg or amoxicillin 2g given 1hr before as ABP.

# ORAL SURGERY

## SBQ 11

YOU ARE SEEING A PATIENT WITH SCHIZOPHRENIA, EPILEPSY AND NEEDLE PHOBIA. PATIENT SEEMS AGITATED. HE HAS MENTAL INCAPABILITY (INTELLECTUAL INSTABILITY). IT IS DIFFICULT TO OBTAIN ANY INFORMATION FROM THE PATIENT REGARDING THEIR HISTORY AND MEDICATION. SO YOU ASK HELP FOR HIS CARER DURING THE APPOINTMENT TO GET THE PATIENT'S MEDICATION LIST IN THE NEXT APPOINTMENT. PATIENT IS TAKING ANTIDEPRESSANTS, ANTIPSYCHOTICS.

**I. You judge the patient is not capable of giving consent for the treatment . Who should provide consent?**

- A. Carer
- B. Legal guardian
- C. Family member
- D. Next to kin

**II. Patient is needle phobic and asks for nitrous oxide minimal sedation. What would you say?**

- A. N2O is best indicated under these circumstances
- B. You can use n20 but inform the patient that you still need the needle for the LA
- C. Prefer to perform the treatment under GA

**III. You have to extract 11 and 27 (or 26) the patient presents all the rest of his dentition. What would be the best treatment to manage the edentulous space?**

- A. Implant
- B. Acrylic rpd
- C. Croco rpd
- D. No replacement.

**IV. The daughter called afterwards and advised that due to financial issues. What will you do?**

- A. Explain Daughter the health impact of not continuing with Planned Rx Plan
- B. Report Abuse
- C. Suggest Payment plan
- D. Refer the patient to the community dental clinic.

# ORAL SURGERY

## P.O.W.E.R NOTES SBQ 11

- I. Schizophrenia patient has incapacity to give medical consent. Legal guardian comes first in giving consent.

### SUBSTITUTION DECISION MAKERS:

- Spouse
- Son or daughter
- Father or mother
- Brother or sister
- Grandfather or grandmother
- Grandson or granddaughter
- Uncle or aunt
- Nephew or niece

- II. N20 can't eliminate the need of local anaesthesia. Patients with mental incapacities and psychotic disorders best to get the treatment done by a specialist.

- III. Dentures are difficult to maintain for a psychotic patient. Because the patient is incapacitated to maintain his OH. Implants are not contraindicated in psychiatric disorders. Among the given options implants would serve him best. As the patient doesn't have to remember taking off and putting in, no replacement can lead to food impaction, tilting of teeth and periodontal problems.

- IV. You can make the treatment plan easy by introducing them a payment plan.

# ORAL SURGERY

## SBQ 12

IT WAS A WHOLE CASE ABOUT ICG. THE MANAGER WANTS TO UNDERTAKE A VERIFICATION OF THE INFECTION CONTROL OF THE CLINIC AND VALIDATION PROCESSES.

---

**I. What is the ideal temperature and time to validation of cycle B of the autoclave?**

- A. 121C for 3 minutes
- B. 121C for 5 minutes
- C. 121C for 2 minutes
- D. 134C for 3 minutes
- E. 6134C for 5 minutes

**II. One staff member got the full vaccines and immunisation for HBV. What will prove that she is immune? (There were crazy values.)**

- A. 0.1 - 0.5
- B. 50-150
- C. 5-15
- D. 500 - 1500
- E. 1500 to 5000
- F. 5000-15000

**III. What process do you need to do to check if there is steam penetration through a big porous load?**

- A. Vacuum test
- B. Helix test
- C. Bowie Dick test
- D. Leakage test
- E. Cycle B

**IV. How do you validate ultrasonic cleaners?**

- A. Pencil test
- B. Leak rate test
- C. Degassing test
- D. Foil test
- E. Strip test

**V. Dentist has slight irritation from hand washing. How will you help your DA take out the instrument?**

- A. Another person was there as a witness
- B. Sharps injury was through clothing or glove
- C. Depth of penetrating injury
- D. Whether the instrument was solid or hollow object
- E. If the object had blood or saliva on it

# ORAL SURGERY

## P.O.W.E.R NOTES SBQ 12

- I. According to ICG it's, **134-137 C for 3min.**
- II. Anything less than 10 is not immune. 10-100 is immune but it's low immunity so, need a booster dose. Anything above 100 is immune.
- III. **HELIX test**- for hollow load  
**BOWIE DICK** – for porous load.
- IV. Foil test and pencil test are indicated for ultrasonic cleaners. Foil test is the universal test.
- V.

REMOVE GLOVES



ABHR



TAKE INSTRUMENT



ABHR



WEAR NEW GLOVES



# PERIODONTICS

## SBQ 13

**INCIDENCE OF SHARP INJURY. WHAT WOULD BE OF LEAST CONCERN WHEN WRITING THE INJURY REPORT IN RECORDS?**

- A. Another person was there as a witness
- B. Sharps injury was through clothing or glove
- C. Depth of penetrating injury
- D. Whether the instrument was solid or hollow object
- E. If the object had blood or saliva on it

## P.O.W.E.R NOTES SBQ 13

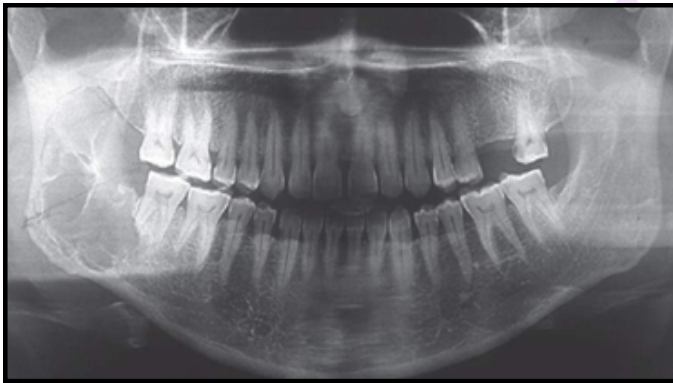- I. All the given options are relevant except for the witness.

*Ref: blood and body fluid exposure protocol*

# ORAL SURGERY

## SBQ 14

BRIAN 30YR OLD MAN, HAS HAD DISCOMFORT IN HIS LOWER RIGHT BACK REGION FOR 3 MONTHS. THE DISCOMFORT INCREASED IN THE PAST 1 WEEK. OPG GIVEN WITH RADIO LUCENCY IN MANDIBULAR ANGLE ALL THE WAY UP TO CORONOID PROCESS. IT IS A MULTILOCULAR RADIO LUCENCY (48 IS DISPLACED THE RADIO LUCENCY STARTS WHERE THE TOOTH IS. (CAN ONLY SEE THE CROWN OF 48, 47 ROOT RESORPTION ON DISTAL ROOT, 48 IS PUSHED DOWN TO MANDIBLE EDGE). THERE WAS ANOTHER SMALL RADIO LUCENCY ATTACHED TO THE ROOT OF FULLY ERUPTED 38 IN THE SAME OPG. CORTICAL EXPANSION WAS SEEN AT THE LOWER CORTEX OF THE MANDIBLE.



### I. What is this lesion most likely?

- A. OKC
- B. Ameloblastoma
- C. Dentigerous cyst

### II. Which further investigation will you require to help diagnosing this lesion?

- A. Lateral oblique
- B. CBCT
- C. CT SCAN
- D. MRI

### III. What could be the further complication if the lesion persists in relation to 47?

- A. Displacement of 47
- B. External resorption of 47 roots (was visible on the opg)
- C. Pocket formation with 47
- D. Occlusal plane displacement

### IV. What is the most conservative treatment for this lesion?

- A. Enucleation and resection
- B. Enucleation with extraction
- C. Cryosurgery
- D. Resection
- E. Enucleation and curettage

# ORAL SURGERY

## SBQ 14

V. There was another small radiolucency attached to the root of fully erupted 38 in the same case OPG and it was asked, what is the appropriate investigation for that?

- A. Perform pulp sensibility test
- B. Do Rct
- C. Extract
- D. Observe
- E. Biopsy

## P.O.W.E.R NOTES SBQ 14

- I. **Ameloblastoma**- cortical expansion and extending towards ramus.  
**OKC**- extending towards anteriorly and no cortical expansion  
**Dentigerous cyst**- not multilocular. Is associated with a crown of an impacted tooth, not the apex of the tooth.
- II. OPG is already taken. CBCT is the next best investigation in ameloblastoma. Since it's a soft tissue tumour MRI can give overexaggerated extent of the tumour. So, can end up doing more surgical removal than required.
- III. Resorption has already occurred. Displacement of 47 can happen after resorption.
- IV. • In this question it's mentioned "conservative treatment" therefore it's enucleation and curettage. In patients younger than 18yrs, we do conservative treatment.
  - Ideal treatment for ameloblastoma is surgical resection.
  - Enucleation and curettage will show 60% of recurrence.
  - Surgical resection will show 10% of recurrence
- V. • Need to do the pulp sensibility test 1st, whether it's vital or non-vital. If it's non vital, then it would be coming from the infected pulp. If it's vital, then you would have to extract the tooth and send for the biopsy. Because radiolucency in the mandibular posterior region associated with a vital tooth could be a malignancy, a metastatic presentation.
  - If it was a diffuse radiolucency attached with the tooth in the mandible and not attached to the root, you can suspect of a malignancy. Then a biopsy would be required. Here it's a radiolucency which is attached to the root may be due to the non-vital tooth.

# ORAL SURGERY

## SBQ 15

A MALE PT 38YR OLD WHO HAS WORKED IN THE MILITARY (OR STILL WORKING MAYBE) COMES TO YOU FOR CONSULTATION REGARDING HIS 3RD MOLARS. HE IS ASYMPTOMATIC. YOU TOOK AN OPG TO FIND A RADIOLOUCENT AREA EXTENDING FROM 34 TO 36.

**I. What is the most likely diagnosis? (It was a R/L that could have been confused with submandibular fossa if the option was given)**

- A. Traumatic cyst
- B. Dentigerous cyst
- C. Odontogenic keratocyst
- D. 1 more option no stafne no submand fossa given

**II. What is the structure arrows are pointing to? Lamina dure**

- A. External oblique ridge
- B. Internal oblique ridge
- C. Mylohyoid ridge

**III. What is the arrow indicating? Dark rim between enamel and dentine**

- A. Difference in the thickness of substances
- B. Artifact
- C. Error
- D. Contrast

**IV. What is the lucency under the cej indicating?**

- A. Cervical burnout
- B. Root caries
- C. Resorptiom

**V. What is the error in bitewing?**

- A. Conecut
- B. Incorrect placement
- C. Incorrect angulation
- D. Patient not biting properly

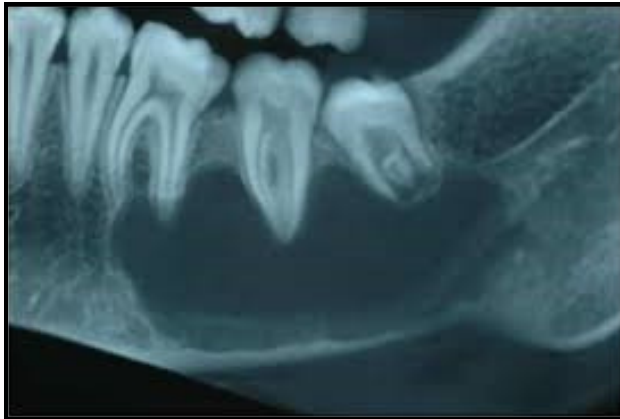**VI. Bitewing given. Multiple caries present. In the main sbq history mentioned that 36 has caries. Apart from caries in 37, which other tooth is carious?**

- A. Mesial of 14
- B. Distal of 15

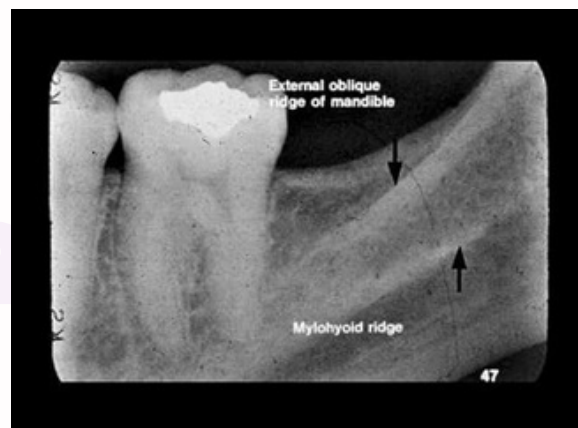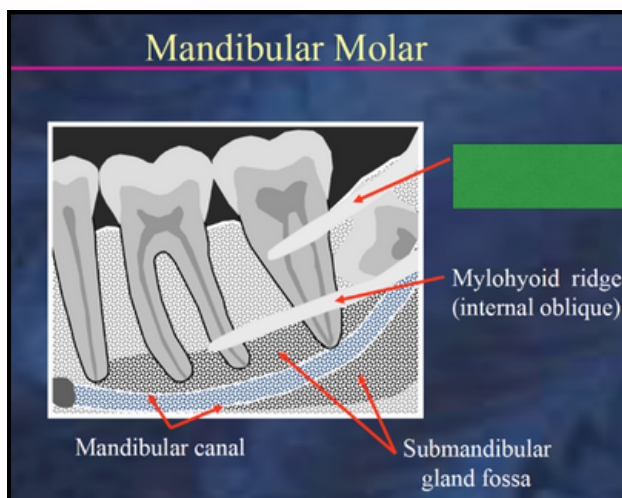
# ORAL SURGERY

## P.O.W.E.R NOTES SBQ 15

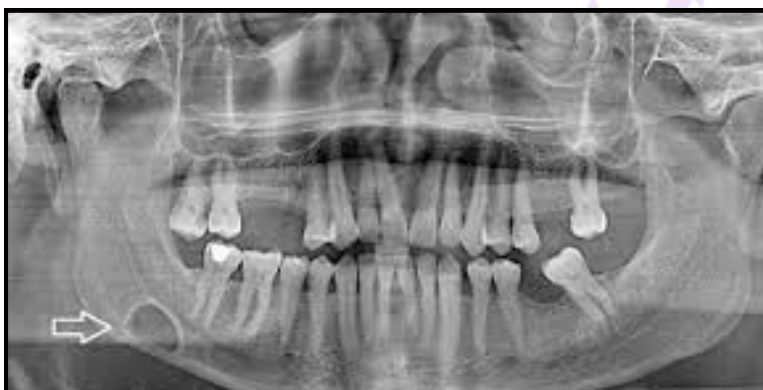- I. Radiolucency is seen in a scalloping fashion among the roots. Patient has worked in the army. So probably traumatic injury might have happened. So the diagnosis is traumatic cyst.



- II. Internal ridge is also known as mylohyoid ridge.



## STAFINE BONE CAVITY

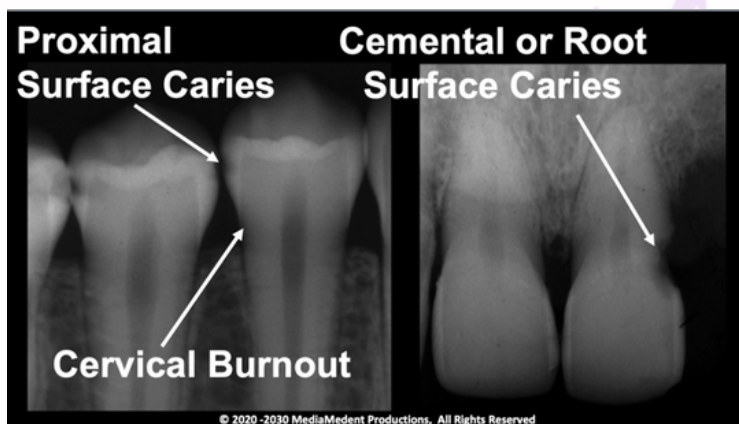


# ORAL SURGERY

## P.O.W.E.R NOTES SBQ 15

III. In a radiograph, the dark rim between the enamel and dentin is typically the result of the differing radiopacity of these two tissues. Enamel is more radiopaque (appears lighter) than dentin because it is denser and contains more mineral content.

IV. If the radiolucency is under the crest or parallel to the crest of the bone is a “cervical burn out”. Can be seen on all the teeth. It appears as a black shadow. If the radiolucency is above the crest of the bone indicate attachment loss and exposed bone. It appears circular in shape. Proximal caries is triangular in shape.



V. Answering this question requires a bitewing radiograph.

# ORAL SURGERY

## SBQ 16

**SCENARIO OF DENS INVAGINATUS. 8-9 YEARS OLD MAYBE PATIENT HAD FEVER AND INFRAORBITAL SWELLING. TEMP 38. X-RAY GIVEN**

**I. You took an iopa. What is the diagnosis for 12?**

- A. Dens invaginatus
- B. Open apex
- C. Internal resorption
- D. Vertical root fracture

**II. What should be the immediate treatment?**

- A. Extraction and drainage
- B. Drainage through intraoral incision and antibiotics
- C. Drainage through skin
- D. Antibiotics and recall
- E. Extraction And Antibiotics
- F. Refer to hospital emergency

**III. Mother is concerned. What will replace the tooth if it goes for extraction?**

- A. Make a temporary rpd for 12 Cantilever
- B. Resin bonded bridge with 11 Implant
- C. Fixed bridge with 11,13
- D. Tell her 13 will come in its place Refer to orthodontist
- E. Leave it as it is

**IV. Mother is asking what will happen if we go for rct? What will you advise her regarding the outcome of rct on 12?**

- A. Will need multiple dressings for root closure before final restoration
- B. Rct can be done but such tooth has poor prognosis
- C. Rct is not possible

**V. You see the opposite 22 has similar clinical appearance but no radiolucency seen with it. What will you do?**

- A. Pit and fissures sealant
- B. Rct
- C. Explore and filling Pulpotomy



# ORAL SURGERY

## P.O.W.E.R NOTES SBQ 16

- I. Dens invaginatus, also known as dens in dente, is a dental anomaly resulting from an invagination (infolding) of the enamel organ into the dental papilla during tooth development. This condition leads to the formation of a tooth within a tooth  
Location: This anomaly most commonly affects the maxillary lateral incisors but can occur in any tooth.

Location: This anomaly most commonly affects the maxillary lateral incisors but can occur in any tooth.

### Clinical Implications:

- Teeth with dens invaginatus are more susceptible to dental caries and pulp infections because the invaginated area can create an entry point for bacteria.
- The condition can lead to pulpitis or periapical periodontitis if not treated appropriately.

**Treatment:** The treatment depends on the type and severity of the invagination and may include:

- Preventive measures such as sealing the invagination to prevent bacterial entry.
- Endodontic treatment (root canal therapy) if the pulp is involved.
- In severe cases, extraction might be necessary if the tooth is not restorable.
- Early diagnosis and appropriate management are crucial to prevent complications associated with dens invaginatus.

- II. Hospital referral is done in case of spreading infection with sever and systemic features.
- III. To decide whether we need to maintain this space, to decide whether we need to move canine or not, we need to refer the patient to the orthodontist.
- IV. If RCT is needed to attempt in dens invaginatus tooth, it should be done by a specialist. But these teeth have poor prognosis.
- V. In these teeth prophylactic RCT is not done as they have complicated pulp anatomy. Instead, preventive measures such as sealing the invagination to prevent bacterial entry is the best thing to do.



# ORAL SURGERY

## SBQ 17

### COVID RESTRICTIONS LEVEL 1 QUESTION

**DEFER NON-URGENT TREATMENT FOR PEOPLE WHO DO MEET EPIDEMIOLOGICAL OR CLINICAL SYMPTOM CRITERIA FOR COVID-19 RISK. URGENT DENTAL TREATMENT FOR PEOPLE WHO DO MEET EPIDEMIOLOGICAL OR CLINICAL SYMPTOM CRITERIA FOR COVID-19 RISK OR CONFIRMED AS A COVID-19 CASE, PROVIDED AS PER ADA MANAGING COVID-19 GUIDELINES**

#### I. Which is the recommended mouthwash

- A. 1% hydrogen peroxide
- B. Chlorhexidine 0.2%
- C. 0.2% povidone iodine
- D. Essential oil

#### II. Who should use the mouthwash

- A. Pre & post procedural mouth rinse by Staff & Patient
- B. Pre-operative mouth rinse by patient and staff
- C. Pre- operative mouth rinse by patient and postoperative rinse by Staff
- D. Pre procedural Patient only

#### III. Patient has swelling but and has been exposed to covid and waiting for test results, she insist you to do check up on her, What would be the management?

- A. Give her appt ("at the end of the day" not given in our center) and clean everything using standard precaution.
- B. Refer her to the local community hospital (emergency department?)
- C. Telephone appt
- D. Defer until test result arrive

#### IV. The patient had to take analgesics. Which one to give? No medical history/ condition, has mild toothache.

- A. PCM and Ibuprofen separately
- B. PCM and Ibuprofen together
- C. PCM and celecoxib combination together
- D. PCM and celecoxib separately

#### V. Other pt has to get treatment generating aerosol, which can't be deferred, what else would you do in addition to the covid precautions?

- A. Use p2 or n95 masks for the dentist and staff
- B. 15 min fallow time after pt completes
- C. Clean everything after pt finishes treatment with Tga approved disinfectant active against covid-19 only once.
- D. Use disposable instruments and double sterilization of the other instruments.
- E. Use level 3 SURGICAL mask FOR aerosol generating procedure

## OUT OF SYLLABUS

# ORAL SURGERY

## SBQ 18

### IMPLANT

**I. Which local criteria will help with stability of the implant with further help in Treatment planning for this patient. Would you check before giving the implant to the patient?**

- A. Plaque index
- B. Take study model cast
- C. CBCT
- D. OPG

**II. You palpate the alveolar ridge area wrt14 and buccal cortical plate was the cortical plate collapsed so what will do?**

- A. Bone graft before placing implant
- B. Bone graft does not require before placing implant
- C. We can't place implant because the poor bone quality
- D. Place implant with lingual tilt with angulated abutment
- E. Place an implant with angled abutment
- F. Bone graft after implant placement

**III. Which further radiographic investigation u will go ahead / What have you gone to the Pt about the maxillary 14 region to place an implant?**

- A. Large intertrabecular space
- B. Improper bone quality
- C. Maxillary sinus nearby
- D. Pneumatization of sinus
- E. Porous bone something

**IV. What is the important history we have to consider in this patient?**

- A. Previous History of Bone graft rejection
- B. History of bone disease
- C. Smoking
- D. History of metabolic disease

**V. What feature is most desirable in the investigation you would like to order further?**

- A. Ability to measure linear measurements accurately
- B. High resolution
- C. Superimposition of anatomical structures
- D. Level of sinus
- E. 2d image
- F. Breadth image

**VI. Best exam to do a implant**

- A. Opg
- B. Cbct
- C. Periapical

# ORAL SURGERY

## P.O.W.E.R NOTES SBQ 18

- I. The implant disease risk assessment was introduced as a guide to identify the risk of developing implant disease. 8 parameters were suggested to be included in assessing the risk of peri-implant disease in a patient.

They include:

- History of periodontitis
- Bleeding on probing
- Number of teeth/implants with probing depth of 5mm or more
- Bone loss/ age of the patient
- Periodontitis susceptibility
- Compliance with supportive care
- Distance of the restorative margin to the bone crest
- Prosthesis related factor

If both plaque index and BOP are given as options, BOP comes 1st.

- II. Buccal cortical plate was collapsed, so, there's an anatomical restriction for engaging both the anatomical plates with implants. Solution for that would be either **adding a bone graft or changing the direction of the implant placement** towards where there is more bone present to engage the cortical plates. So, among these 2 options placing bone graft **before implants placement** is the best. If option (A) is not given (D) is the 2nd best option.

The use of angled abutments facilitates paralleling, nonaligned implants, thereby making prosthesis fabrication easier. The abutments can also aid the clinician in avoiding anatomical structures when placing implants. In addition, use of angled abutments can reduce treatment time, fees and the need to perform guided tissue regeneration procedures.

- III. There's poor bone quality in the maxillary premolar region.

**Reference:**

*The bone height between the floor of the maxillary sinus and the alveolar crest is routinely analysed in oral implantology when posterior maxillary implants are contemplated. An increase of sinus volume or sinus pneumatization after a loss of a posterior tooth/ teeth often necessitates vertical bone augmentation with a sinus lift procedure if implants are considered in this area. The bone of this region is also known to have compromised bone quality (type 3 and 4) that can increase an implant failure rate.*

- IV. We are planning to place a graft in this patient, so, previous hx of bone graft rejection is important to ask. In the presence of positive hx there's a high chance of failure in this procedure.

Smoking is not an absolute contraindication for implants.

# ORAL SURGERY

## P.O.W.E.R NOTES SBQ 18

V. CBCT provides accurate linear measurements, which are essential for diagnosing and planning treatments, especially in orthodontics, implantology, and reconstructive surgery. The precision depends on the voxel size, image resolution, and the quality of the CBCT machine.

VI. **Comparison with Other Imaging Techniques:** CBCT provides more accurate 3D measurements compared to traditional 2D imaging techniques like panoramic radiographs or cephalograms.

# ORAL SURGERY

## SBQ 19

WHILE PLACING AN IMPLANT WRT 36 WHICH ANATOMICAL STRUCTURE (THICK RADIOPAQUE LINE RUNNING ALONG D ROOTS OTHER THAN SUB MANDIBULAR FOSSA RELEVANT DURING THE INVESTIGATION)

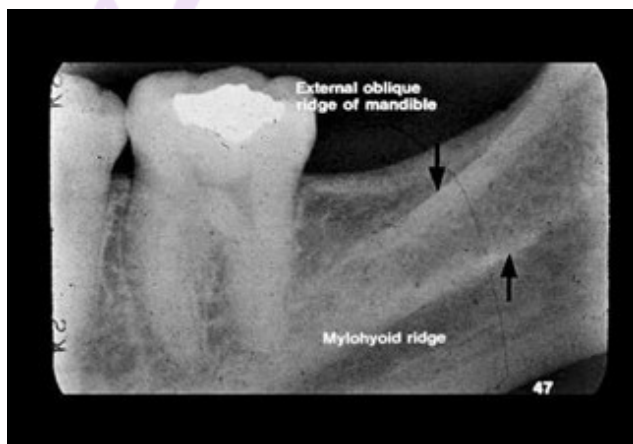- A. Mylohyoid ridge
- B. Inferior alveolar canal
- C. Lingual nerve
- D. External oblique ridge

### P.O.W.E.R NOTES SBQ 19

- I. Among the given inferior alveolar canal and lingual nerve are radiolucent structures.

In the question it's asking for the radiopaque structures. External oblique ridge is a radiopaque structure that runs over the CEJ. Mylohyoid ridge is a radiopaque structure that runs over the roots.

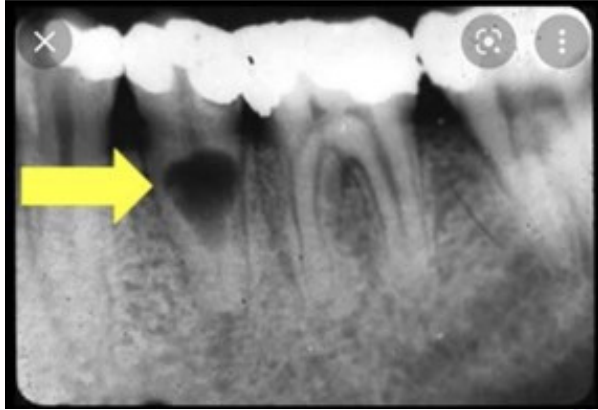
Submandibular fossa is a radiolucency diffusely present near the inferior alveolar canal.



# ORAL SURGERY

## SBQ 20

### INDIGENOUS MAN

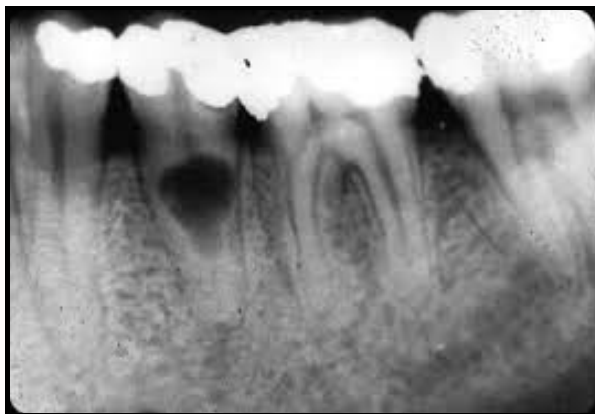


I. What is the lesion you see above?

- A. Internal root resorption
- B. External inflammatory root resorption
- C. Cervical root resorption

### P.O.W.E.R NOTES SBQ 20

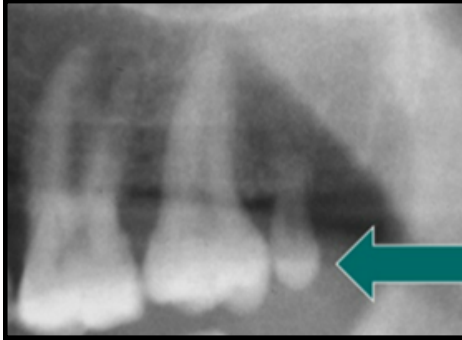
- **Radiolucent Area:** A distinct, well-defined radiolucent (dark) area within the root canal space, often round or oval in shape.
- **Uniform Enlargement:** The radiolucent area typically shows a uniform enlargement, indicating the resorptive process within the canal.
- **Root Canal Continuity:** The outer surface of the root appears intact, distinguishing internal resorption from external root resorption where the outer surface is involved.



# ORAL SURGERY

## SBQ 21

OPG OF 26 27 AND 28 (SMALL MICRODONT) GIVEN. THE PATIENT WANTS TO UNDERGO EXTRACTION OF THE TOOTH, PT HAD A HISTORY THAT LA NEVER WORK PROPERLY ON HIM.



I. You want to give palatal and buccal infiltrations to anesthetize tooth 28, Where would you give the palatal infiltration? What is the best direction (or location) how you infiltrate palatally?

- A. Parallel to long axis of 27
- B. Parallel to long axis of 28
- C. Distal to 27
- D. Distal to 28
- E. In between of 27 & 28

II. After infiltration while you attempt to extract the teeth, the patient complains of pain. How further will you anesthetize?

- A. Intraligamentary injection mesial to 28
- B. Intraligamentary injection distal to 28
- C. Intrapulpal injection to 28
- D. Intra osseous injection



# ORAL SURGERY

## P.O.W.E.R NOTES SBQ 21

### I. Reference:

#### INFILTRATION ANAESTHETIC TECHNIQUES

##### Buccal anaesthesia

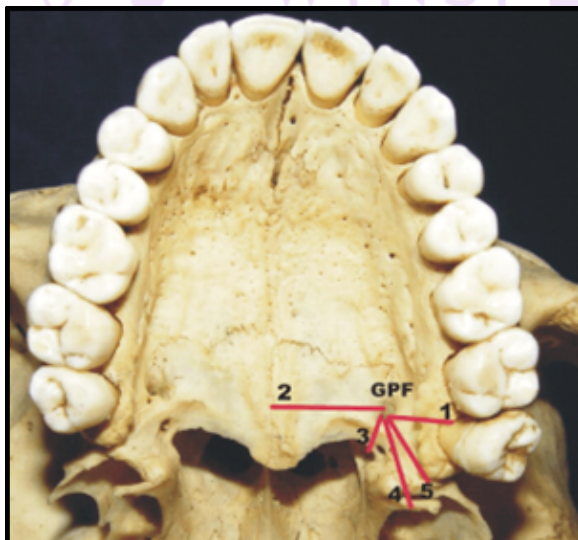
- **Injection for the maxillary 3rd molars**  
Made opposite to the maxillary 2nd molar tooth to avoid injury to the pterygoid plexus of veins.
- **Upper centrals**  
Inject a few drops to the apical area of the other central incisor

##### Palatal anaesthesia

- **Injection for the maxillary 3rd molar**  
Should be at the palatal root of the maxillary second molar to avoid anaesthesia of the lesser palatine nerves which supply the soft palate and may lead to gag reflection.

##### Greater palatine nerve

It's located on either side of the roof of the mouth between the 2nd and 3rd maxillary molars, approximately 1cm medial to the palatogingival margin.



- II. It's safer to inject mesial to 28 than distal. Intraligamentary is the most effective supplemental anaesthesia.



# ORAL SURGERY

## SBQ 22

**PATIENT WITH UPPER DENTURE AND EPULIS FISSURATUM CASE. REPEATED QUESTION SAME AS IN THE MEGA MASTER FILE, STEPS TO TREAT IT AND MANAGEMENT.**

---

- A. Refer to oral surgeon and excision with laser, remake the cd
- B. Excision, biopsy and shorten the borders
- C. Excision, shorten the border and reline
- D. New cd

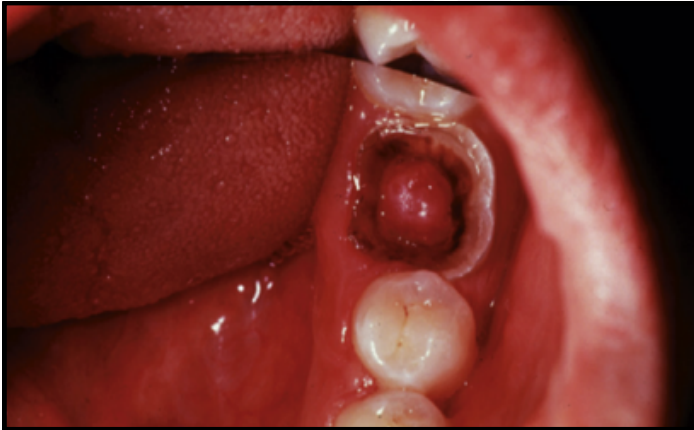
## P.O.W.E.R NOTES SBQ 22

Epulis fissuratum is caused by the over extended borders of the denture. So, we must shorten the borders. Even though it's a non-malignant condition we send for the biopsy for the confirmation.

# ORAL SURGERY

## SBQ 23

ABORIGINAL PT WITH RHEUMATIC HEART DISEASE, 35 YEARS OLD LIVES IN A REMOTE COMMUNITY, COMES WITH HIS SON WHO IS 14YO. PT IS IN PAIN. PT SPEAKS LITTLE ENGLISH AND SON IS TRANSLATING AND REPORTS HIS DAD IS FIT AND WELL APART FROM THE TOOTHACHE AND THAT HE HAS NEVER BEEN TO THE DENTIST.



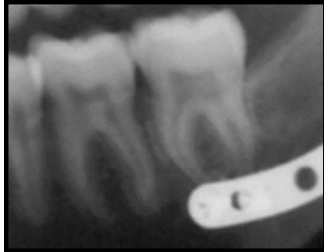**SIMILAR BUT IN 2ND MOLAR**

- I. 37 with pulp polyp with picture. You made a provisional diagnosis of pulp polyp. How would you proceed to confirm the nature of the tissue?
- A. Extract the tooth then send it to the pathology lab
  - B. Remove the tissue growth and then send to the pathology and start Root canal treatment
  - C. Do nothing
  - D. Refer him to the public system and wait for an oral surgeon to see him
- II. What to take in consideration when using the son as a translator? Or its like Why do you consider his son can't be considered as a translator for him ?
- A. Organising a translator will require booking and delay treatment
  - B. It is difficult to arrange translator for an aboriginal remote area
  - C. The son is 14 yrs old and considered a minor mature
  - D. Family members do not always explain the treatment properly
  - E. The situation is an emergency

# ORAL SURGERY

## SBQ 23

III. IOPA X-ray given of the patient's lower posterior molar region asked what is the radiopacity in exam caused by (tricky question as hx mention pt has never been to the dentist). Aboriginal man (looked like titanium plate over the region of the 3rd lower molar and the pulp polyp was in the 2nd molar)



*X-ray similar to this*

- A. Artifact
- B. Titanium plate
- C. Patient movement
- D. Jewellery
- E. X-ray holder

IV. You decided on the extraction of this tooth. What other investigation do you have?

- A. Clindamycin 2g iv 60min before
- B. Amox 2g iv 60 min before
- C. Amox 3g
- D. Amox 500 mg oral one hour before the procedure

# ORAL SURGERY

## P.O.W.E.R NOTES SBQ 23

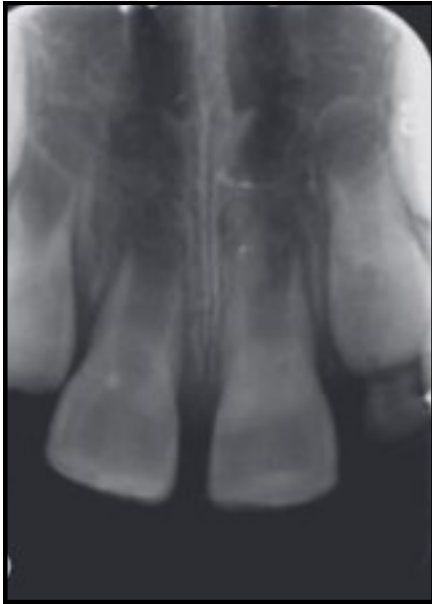Any patient with rheumatic heart disease requires ABP.

- I. Any abnormal growth in the mouth / body should be removed and sent for the pathological examination. And can save the tooth by doing RCT. If the tooth is non restorable or if the patient cannot afford the treatment cost, extraction is indicated.
- II. According to the COC guidelines, a family member is not considered as a translator, as they don't explain the treatment properly. You should arrange another translator.
- III. Radiopaque metallic plate which is used in fracture reduction is given in the IOPA. Patient says that he has never been to the dentist, but the fracture could have been managed in a hospital set up and he may have forgotten about it.
- IV. The degree of fracture displacement and the relationship of the fracture line to the periodontium are evaluated using OPG. Pulp sensibility test won't be helpful as it's a case of chronic irreversible pulpitis. As the base line investigation CBCT is not required initially.
- V. Amoxicillin when given as a prophylactic AB, it's given 2g, 60min before.  
Clindamycin when given as a prophylactic AB, it's given 600mg, 60min before.

# ORAL SURGERY

## SBQ 24

EXACTLY SAME PICTURE IN EXAM WHAT'S THE RADIOLOGUCENCY ALONG THE APEX IN THE PERIAPICAL BELOW:



- A. Normal apex for patient age
- B. External root resorption
- C. Nasal cavities
- D. Open apex

## P.O.W.E.R NOTES SBQ 24

According to the IOPA there's an extending radiolucency from the apices of the roots suggestive of nasal cavity.

# ORAL SURGERY

## SBQ 25

**SURVEY X-RAY AFTER ALL 3RD MOLARS HAVE ERUPTED**

---

- A. Bitewing
- B. Periapical
- C. Opg

## P.O.W.E.R NOTES SBQ 26

OPG is the survey x-ray that shows all the 3rd molars.

# ORAL SURGERY

## SBQ 26

### PREGNANT LADY

PATIENT SEES THE DENTIST THAT SHE GOT HOME PREGNANCY TEST WHICH SHOWED POSITIVE, THEN COMPLAINS MOBILE TEETH IN THE LOWER JAW

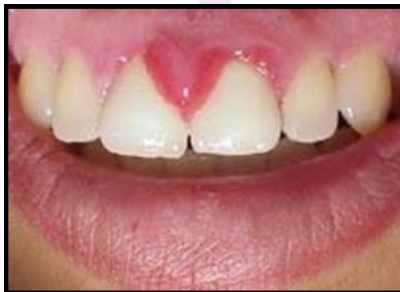I. Dentist wants to extract her tooth what precautions will u take during radiograph

- A. Take the x-ray and continue with treatment plan
- B. Recall her second trimester and take the x-ray

II. A lady came to see you for a clean, 20 weeks pregnant she complains of sore gums, while doing the cleaning, she complains that it is uncomfortable and you decide to give her an anaesthesia to help with the pain. Which anaesthesia will you choose/What is the most appropriate LA to use?

- A. Lignocaine 10% GEL
- B. Prilocaine 3% with felypressin
- C. Lignocaine 2% with adrenaline 1:80000
- D. Articaine 4% with adrenaline
- E. Lidocaine plain

III. Few weeks later she comes back to see you 30 weeks pregnant, she wants you to check her gums. What is your management for this presentation?



- A. Clean and biopsy pathology ( not there in my station)
- B. Tell her don't need to do anything
- C. Only clean( in my station this was not there)
- D. Do nothing and asked her to cm bck after delivery
- E. Local debridement and ohi
- F. 0.12% chx mouthwash

# ORAL SURGERY

## P.O.W.E.R NOTES SBQ 26

I. However, most procedures to be performed in dentistry are important in the 1st trimester and the 3rd trimester, in terms of the stresses to which the mother and the baby will be exposed. Effective dental treatment in the 1st trimester should be avoided. This period is a very sensitive period because it's the stage of organogenesis. Unnecessary interventions can lead to abortions. However, in case where there is pain or if no intervention will cause more harm, the teeth must be urgently treated. Under these circumstances, tooth extraction and canal treatment can be performed.

x-rays are not contraindicated in pregnancy.

II. Lignocaine with adrenaline is not contraindicated during pregnancy.

III. In case of pregnancy epulis we will not excise it, instead we will perform FMS and give OHI.



# ORAL SURGERY

## SBQ 27

PATIENT WEIGHS 80 KGS. TOOTH #36 WITH PERIODONTAL INVOLVEMENT AND RADIOLUCENCY ALL AROUND THE ROOTS. YOU INJECT 1.8ML OF LIGNOCAINE USING THE CORRECT TECHNIQUE FOR THE IAN BLOCK, WAIT FOR 5 MINUTES BUT THE PATIENT STILL FEELS PAIN. YOU ATTEMPT TO INJECT A SECOND CARTRIDGE AND IT WORKS. WHAT IS THE MOST LIKELY REASON FOR THE FAIL OF THE FIRST INJECTION?

- I. One question ask about block fail reason and the other for infiltration fail reason (Totally 6.3 ml of LA was injected) Not enough anaesthesia. Picture shows there was an gingival swelling in the buccal vestibule wrt 36\37
- A. Anatomical variation of the mandibular canal
  - B. Not enough wait time i.e 5 mins
  - C. Incorrect operator technique
- II. Now you gave buccal infiltration twice and the patient still feels pain. What is the reason for failure?
- A. Low pH of the area
  - B. Anatomy
  - C. Not enough amount of LA given

## P.O.W.E.R NOTES SBQ 27

- I. The technique was good enough and the waiting time after LA was good enough. According to the Walton it's given that the failure rate of the mandibular nerve block is due to anatomical variation in the mandibular canal.
- II. Buccal infiltration would fail due to the ph of the tissue/ excessive inflammation. Same happens with the maxillary infiltrations and blocks.

# ORAL SURGERY

## SBQ 28

ADULT PATIENT. WITH UNCOMPLICATED CROWN FRACTURE PALATALLY JUST BELOW THE GINGIVA CASE, APEX COMPLETE. PATIENT WITH INCISAL MESIAL AND SUBGINGIVAL FRACTURE, NORMAL PULP SENSIBILITY TEST, NO PULP EXPOSURE BUT THE PINK COLOR OF THE PULP CAN BE SEEN THROUGH DENTINE( VERY CLOSE TO PULP). PT COMPLAINS OF SLIGHT SENSITIVITY. ALMOST HALF OF THE TOOTH WAS LOST. ALSO THIS TOOTH SHOWS MOBILITY BUT NO DISPLACEMENT. (PICTURE WAS GIVEN FROM BUCCAL VIEW WRT 11 WHERE THE FRACTURED 2/3RD CLINICAL CROWN)

### I. What is going to be your immediate management today:

- A. Complete root canal treatment with restoration
- B. CaOH and gic restoration
- C. Pulpotomy with calcium hydroxide with restoration
- D. GIC restoration

### II. What is the most appropriate treatment for this tooth? Asked about the long term treatment.

- A. Post and core,crown by rct
- B. Core and crown
- C. Give Veneers

## P.O.W.E.R NOTES SBQ 28

- I. Uncomplicated crown fracture in a permanent mature tooth- indirect pulp capping with  $\text{Ca(OH)}_2$  and GIC is indicated. Pulp capping is done because pink colour of the pulp is seen through the dentine.
- II. Half of the tooth structure is lost so veneers are not indicated.  
RCT or post is not required as the pulp is vital. And also prophylactic RCT is not needed as there's enough tooth structure to withstand core and crown.

# ORAL SURGERY

## SBQ 29

PATIENT HAS ALVEOLAR OSTEITIS, SOCKET WAS IRRIGATED WITH CHLORHEXIDINE AND ALVOGYL WAS PLACED. WHAT ALLERGY WOULD MOST LIKELY OCCUR? OR WHAT ALLERGY WOULD YOU CHECK.

- A. Allergy to milk proteins
- B. Allergy to egg proteins
- C. Allergy to iodine
- D. Allergy to chlorhexidine

## P.O.W.E.R NOTES SBQ 29

CHX can cause anaphylaxis when used in open wounds. Dry socket (alveolar osteitis) is not an open wound.

Alvogyl is contraindicated in those who are allergic to iodine.

Alvogyl is not to be used on the patients having a hx of allergic reactions to procaine type anaesthetics or sensitivity to iodine or iodine compounds.

# ORAL SURGERY

## SBQ 30

OPG GIVEN AND POINTED ARROWS TOWARDS 1ST QUADRANT. (TWO VARIATIONS ON OPG- COMPOUND ODONTOMA / RETAINED ROOTS)

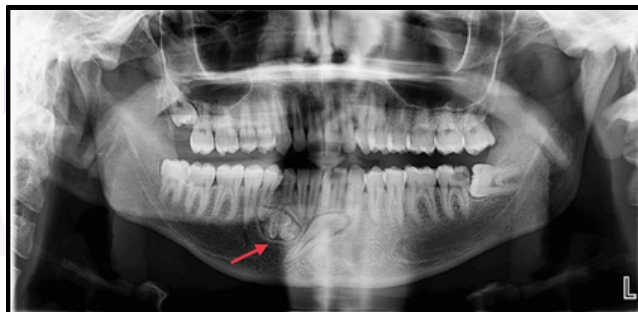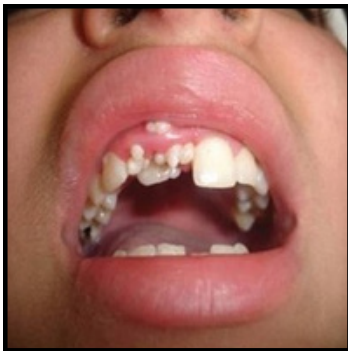- A. Cementoma
- B. Compound odontoma
- C. Ghost image
- D. Supernumerario
- E. Retained roots

### P.O.W.E.R NOTES SBQ 30

#### Compound odontoma:

it consists of well-organized, tooth-like structures that resemble small, abnormal teeth or denticles. Compound odontomas typically contain enamel, dentin, cementum, and sometimes pulp, arranged in an orderly pattern.

**Radiographic Appearance:** On X-rays, they appear as a collection of tooth-like structures within a radiolucent (dark) area, surrounded by a well-defined radiopaque (light) border.



# ORAL SURGERY

## SBQ 31

CHILD WITH TYPE-1 DIABETES AND CARIES NO PAIN AND NEEDS LA. PREVIOUS DENTISTS SAID THAT THE ANAESTHESIA WAS NOT WORKING AT ALL. "INADEQUATE ANAESTHESIA/ DIFFICULT ANAESTHESIA. WHAT IS THE BEST LA?

- A. 2% lignocaine with 1:80000 adrenaline
- B. Prilocaine with felypressin
- C. Articaine without adrenaline
- D. Mepivacaine 3%

## P.O.W.E.R NOTES SBQ 31

Lignocaine with adrenalin is not contraindicated in diabetic patients.

# ORAL SURGERY

## SBQ 32

ICG

**I. Min requirement for checking steam sterilization by which indicator -**

- A. Class 1
- B. Class 2
- C. Class 3
- D. Class 4
- E. Class 5 and 6

**II. Why do we need to bag / pouch extraction forceps prior to sterilization?**

- A. To avoid perforation injuries (In the staff)
- B. To keep it sterile at the time of procedure
- C. To prolong life of instrument
- D. To check the sterilization status by changing color on pouch
- E. To check if the bag changed color

**III. You were about to start a procedure on a patient, and waiting for an instrument, your DA who was discarding old instruments and suddenly the DA injured. You record the sharp injury, send both patient and the DA for blood test. So you go to the Sterilization chamber to unload, but you see all the pouches are still damp/wet Why the instrument are still wet after sterilization?**

- A. Overload chamber?
- B. Paper faced down
- C. Water reservoir full
- D. Door seal not good

**IV. And you find your instrument - Class 1 indicator not changed color. In which condition does Class 1 indicator change color? OTHER VARIATION What does the class 1 indicator tell**

- A. Pouch put in heat or steam
- B. Pouch put in 134 degrees
- C. Pouch put in 137 degrees
- D. Pouch steamed for 3 mins
- E. Pouch put in dry heat

**V. Precautions taken to restrict legionella (asked in 3 out of 4 papers)**

- A. Retraction cord
- B. Silver ion in water lines
- C. 30 sec flushing
- D. H<sub>2</sub>O<sub>2</sub> in water line
- E. Check biofilm concentration in units

# ORAL SURGERY

## SBQ 32

**VI. Pt said he read that there was a lady who got pre term labour after getting treated by dentist due to legionella infections How will you reassure the patient?**

- A. By showing him your staffs Attendance
- B. By showing your clinics annual health report
- C. By telling we put silver ions tab in bottle everyday
- D. Tell patient that you disinfect the waterline daily
- E. By showing him your monthly Dental unit water line (DUWL) check report

**VII. When would you open the pouch?**

- A. Just before the procedure
- B. When patient reports to your desk
- C. Two hours after sterilization procedure
- D. When you are setting up the instruments for the procedure.

**VIII. What is the first advice you provide**

- A. Wash with soap and water
- B. Squeeze and allow bleeding for 2 to 3 minutes
- C. Apply pressure
- D. Use alcohol gel hand rub

**IX. Why should extraction forceps be packaged individually?**

- A. Sterile till point of use
- B. So the steam can penetrate inside the bag sterilize
- C. We protect the sharp part and injuries sharp?
- D. To keep it clean while it is kept in storage
- E. So that the sharp beaks of forcep doesn't cause any injury

# ORAL SURGERY

## P.O.W.E.R NOTES SBQ 32

- I. Class 4 chemical indicator is the minimum that must be included inside every package of a wrapped load when the reprocessing conditions have not (or not yet) been verified by a full qualification process. Class 5 and 6 indicates high accuracy.
- II. Extraction forceps is a critical instrument. Critical instruments are put in pouches to keep it sterile at the time of the procedure.
- III. When the pouches are overloaded and kept over the other, the steam gets trapped between each other.  
If the door seal is not good the colour indicator would not change.
- IV. Class 1 indicator will change colours only to heat/ high temperature and it will not change the colour for steam.
- V. Biofilm levels in the dental equipment can be minimised by using a range of measures, including ozonation, electrochemical activation, and chemical dosing of water (e.g. with hydrogen peroxide, oxygen compounds, hypochlorites, chloramines, iodine, silver ions, or nanoparticle silver).

### According to the Australian Drinking Water Guidelines:

The number of bacteria in water used as a coolant/ irrigant for non-surgical dental procedures should be less than 200 CFU/ml since this is a widely used international limit for safe water for medical application.

All the given options are correct by option (E) is the most important among them.

- VI. Evidence is most important in reassuring a patient. So, the monthly DUWL check report should be offered to the patient.
- VII. Critical instrument pouches are opened just before the procedure.
- VIII. In case of sharp injury, let the blood flow and wash the area with soap.  
Don't squeeze, don't apply pressure, don't use alcohol in that area.
- IX. Extraction forceps are critical instruments which should be packed individually and should be sterile at the point of use.



# ORAL SURGERY

## SBQ 33

### QUESTION ABOUT LA

IT WAS EXTRACTION OF FIRST MOLAR WITH DIVERGENT ROOTS. THE DENTIST WAS GOING TO SECTION THE TOOTH AND KNEW IT WAS GOING TO BE COMPLICATED. YOU WANT TO ACHIEVE A LONGER AND DEEPER ANAESTHESIA.

#### I. Which LA would you prefer

- A. Articaine with adrenaline
- B. Mepivacaine with adrenaline
- C. Lignocaine
- D. Mepivacaine

#### II. X Ray given with radiopacity around the coronal thirds of the molar and premolar. Mentioned that we diagnosed it as Exostoses. What could be the likely cause for this radiopacity in the coronal third of 43,44 (instead of cause, the exact word was REASON)

- A. Bruxism (exact wording - Heavy Bruxer)
- B. History of bone disease
- C. Localized pocket
- D. Calculus
- E. Lack of interdental cleaning

### P.O.W.E.R NOTES SBQ 33

- I. When adrenaline or felypressin is not added to LA, it will be short acting. Therefore, options (C) and (D) are ruled out.

When adrenaline or felypressin is added to LA, it will be intermediate acting.

Articaine, bupivacaine, ropivacaine are long acting. But articaine has a risk of prolonged or permanent anaesthesia. So, it's used only for infiltration and it's not used for regional blocks. Bupivacaine is not used in children younger than 12yrs old.

In the question it's mentioned only 1st molar and not mentioned whether it's lower or upper. So, we believe in this case a block anaesthesia is required. So, among the given options, (B) is the best.

- II. Hyper deposition of the cortical bone is known as exostosis. It's not a pathological condition. In case if a patient with exostosis requires a denture, we may need to remove the excess bone as it has an impact on the denture retention.

The likely cause of radiopacity in this area / exostosis is due to the bruxism.

#### Reference:

*Aetiology is not established, but it has been suggested that the bony overgrowth can be because of abnormally increased masticatory forces to the teeth.*

# ORAL SURGERY

## SBQ 34

**DIFFERENT CASES - YOU PLAN EXTRACTION - LOOKS SIMPLE - SO YOU PUT UP A FINANCIAL PLAN FOR A NORMAL FORCEPS EXTRACTION AND START THE PROCEDURE. MID WAY BETWEEN THE PROCEDURE - COMPLICATION OCCURS - ROOT FRACTURE - SO YOU HAD TO RAISE FLAP AND SURGICAL EXTRACTION DONE.**

### **I. How would you manage the patient**

- A. Stop extraction midway, explain the patient - about increase cost for surgical extraction and then proceed
- B. Finish the extraction surgically, after the procedure - explain the patient
- C. Its your mistake, so reduce the charges for patient
- D. Get only the planned finance, nothing extra as its a complication during extraction

### **II. For this procedure you require anaesthesia. Which anaesthetic agent will you choose?**

- A. Mepivacaine with adrenaline
- B. Articaine with adrenaline
- C. Lignocaine with adrenaline

### **III. While u reflect the flap how the flap should be, "Based on the flap techniques":**

- A. With a wider base
- B. With a narrow base
- C. Reflecting upto the attached gingiva
- D. Partial thickness flap

### **IV. In what situation will you leave the root stump:**

- A. Deep and vital
- B. Deep and non vital
- C. Superficial
- D. Less than 5 mm size of root stump
- E. Bleeding is uncontrollable

# ORAL SURGERY

## P.O.W.E.R NOTES SBQ 34

### I. Reference:

*Dental fees may be based on either an itemised schedule of treatment or on the time taken to complete the dental procedure. Accordingly, the dentist may only be able to estimate a range of fees based on the expected time to undertake the procedure and the anticipated complexity of the procedure. Similarly, if the planned procedure is changed during the procedure due to for unseen circumstances, this may also result in a change to the final fee charged by the dentist. Any such change should be advised at an appropriate time.*

II. It's good to use an intermediate acting LA. Both (A) and (C) are intermediate acting. Lignocaine with adrenaline is the gold standard.

III. The flap should be wider on the base and narrow on the top up to the mucogingival junction. It should be full thickness as you want the bone to be exposed. The blood circulation will be maintained.

### IV. Reference:

***What happens if a root tip fracture?***

*1st consider leaving it there if it is vital, less than 5mm and in proximity to a vital structure such as nerve. If you can remove it through a small bony window thus maintaining alveolar bone height.*

# ORAL SURGERY

## SBQ 35

**PATIENT - 48 EXTRACTION DONE - PAIN, FOUL TASTE/SMELL - YOU GIVE LA - PATIENT SETTLES DOWN - RELIEVED - AFTER 5 MINS, YOU IRRIGATE WITH SALINE, REMOVE SOME SMALL NECROTIC BONE FRAGMENTS - PLACE ALVOGYL SUDDENLY THE PATIENT GETS AGITATED, FLUSHING ON FACE, CHEEKS AND FOREARMS. AMBULANCE ALREADY CALLED APART FROM ANAPHYLAXIS.**

### **I. Which of the below could have a similar clinical presentation?**

- A. Panic attack
- B. Shingles
- C. Impetigo
- D. Increase of core body temperature
- E. Cellulitis

### **II. Oral mucosa starts to get swollen suddenly. What's your first management**

- A. Tell nurse to call 000 ambulance
- B. Remove alvogyl
- C. Place patient in supine position
- D. Assist to make him stand
- E. Put pressure and ice packs

### **III. You administer adrenaline from an auto-injector in his antero lateral thigh (which was available in your clinic) Why was the antero lateral thigh chosen?**

- A. Rapid plasma concentration increases
- B. Not invading privacy
- C. Less painful site
- D. Not any major blood vessels in that area
- E. Best site for subcutaneous injections

### **IV. Now the patient develops stridor, what is your management?**

- A. Administer another adrenaline injection
- B. Administer steroids
- C. Administer oxygen
- D. Administer oral anti histamines

### **V. Finally, its anaphylaxis, probably due to?**

- A. Lidocaine
- B. Adrenaline
- C. Lodoform
- D. Saline
- E. Nitrile gloves

# ORAL SURGERY

## P.O.W.E.R NOTES SBQ 35

I. **Shingles** is a viral disease. **Impetigo** is a bacterial disease. **Hyperthermia** is not associated with anaphylaxis. **Cellulitis** is the facial swelling due to spreading infection. **Panic attack** is an autonomic nervous situation that mimics anaphylaxis.

II. Management of anaphylaxis:

- Stop the treatment
- Remove or stop administration of the allergen
- Lie the patient flat
- Give IM injection of adrenalin
- Call 000
- Start supplemental O<sub>2</sub> and airway support if needed
- Be prepared to start CPR
- Repeat adrenalin every 5mins until the patient responds or assistance arrives

III. There's no major nerves or blood vessels running in anterolateral thigh region. So, it's safe to give IM injection in this area.

IV. Stridor is the noisy breathing. Which indicates that the patient is struggling to breathe. O<sub>2</sub> should be administered. Adrenaline is already given and repeated in every 5mins time.

V. Patient developed anaphylaxis immediately after administering alvogyl. Iodine present in alvogyl is the causative agent.

# ORAL SURGERY

## SBQ 36

A PT WHO IS MISSING UPPER 5 WANTS TO DO REPLACE IT WITH IMPLANT. HE HAS HYPERTENSION. (130/80 ; 140/90) AND HE IS TAKING ANGIOTENSIN CONVERTING ENZYME INHIBITOR.. ALSO TAKING CLOPIDOGREL. PREVIOUSLY GOT HIS TOOTH EXTRACTED AND HE HAD HX OF BLEEDING.

**I. When assessing his risk of bleeding what in the medical hx may increase the risk of bleeding other than clopidogrel:**

- A. Concomitant use of ACEI
- B. Hx of bleeding
- C. (his diabetes?)
- D. His blood pressure

**II. Which of the below is "THE BEST" artificial sugar substitute?**

- A. Sorbitol
- B. Xylitol
- C. Stevia
- D. Sucralose

**III. What is the reason that xylitol is not being used widespread**

- A. Too expensive
- B. Stomach flatulence
- C. Is contraindicated in Crohn's disease
- D. Inflammatory bowel disease
- E. Gastric ulcer
- F. It has half the calories than sugar

# ORAL SURGERY

## P.O.W.E.R NOTES SBQ 36

I. Patient related factors for increased bleeding: **"BOLDSHKAB"**

- B**- bleeding disorders
- O**- old age and frailty
- L**- liver disease and unstable INR
- D**- drugs that predispose to bleeding including NSAIDs
- S**- prior stroke
- H**- hypertension
- K**- kidney dysfunction
- A**- alcohol consumption
- B**- hx of bleeding

According to the question, patient's BP is under control. Patient has a hx of bleeding other than clopidogrel.

II. Stevia, xylitol, sorbitol are natural sugar substitutes. Only sucralose is the artificial sugar substitute among the given.

III. Xylitol has laxative effect which causes diarrhea. It's not using widespread due to stomach flatulence. It's too expensive too.

# ORAL SURGERY

## SBQ 37

MALE PATIENT AROUND 70YRS OLD. PATIENT WAS BREATHING HEAVILY, TELLING HIS CHEST WAS ACHING. PATIENT IN THE DENTAL CHAIR AND STILL WISHES TO GET EXTRACTION DONE BY MENTIONING HE IS FINE.

I. What can be the reason for his recent condition?

- A. Angina
- B. Allergic reaction

II. There was a case on diabetic pt taking sglt-2. Also pt who is taking medication for DM. His doctor recently changed his medication from metformin to sglt 2. What can be the risk factors that u must consider managing this patient.

- A. Diabetic nephropathy
- B. Hypoglycemia

## P.O.W.E.R NOTES SBQ 36

I. Chest pain in an old patient with difficulty in breathing suggestive of a cardiac condition.

II. Patient's taking SGLT2 are at a higher risk of developing diabetic ketoacidosis. Presenting signs would be nausea, stomach pain, abdominal toxicity.

**Reference:** TG page 179

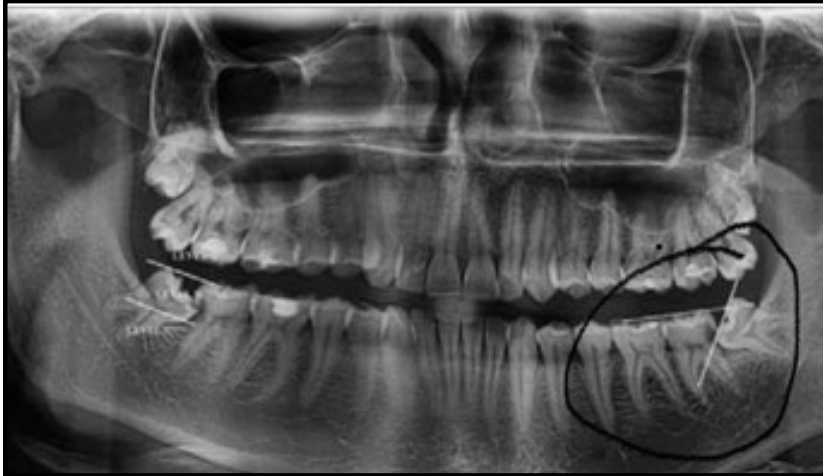SGLT2 inhibitors have been associated with the development of DKA in patients with type 1 and type 2 diabetes. The risk of DKA is increased in patients taking SGLT2 inhibitors who:

- Have been fasting or having a very restricted dietary intake
- Have undergone a surgical procedure
- Are dehydrated
- Have an active infection

SGLT2 inhibitors may need to be stopped before a dental procedure, consult the medical practitioner.



# ORAL SURGERY

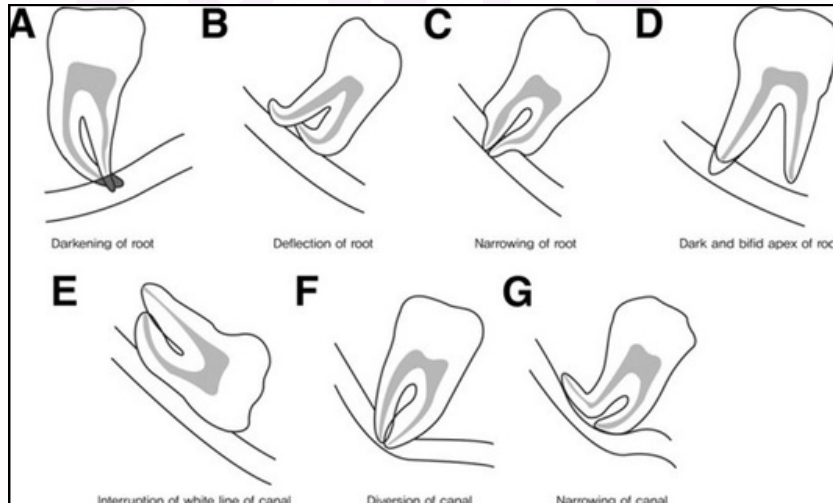
**SBQ 38****SIMILAR OPG**

- I. There OPG gave questions relating to the lower nerve (inferior alveolar nerve) 38 near the IAN and also 48. The opg both sides u could also see proximity/interruptions nerve canal of the 48 and 38. What factor will determine that you will need to refer this patient to the specialist?
- A. Proximity of inferior alveolar nerve to 38
  - B. On the right mandibular radiolucency across the mandible
  - C. The position of 38 will complicate the extraction of 37
  - D. The proximity of IAN to the root end of 37
- II. What can you see from the x rays that can determine that patient has bruxism,
- A. Thin enamel of lower posteriors when compared to other teeth
  - B. Pulp stones
  - C. Lower 3rd molar enamel is normal(no opposing 3rd molar maxilla)

# ORAL SURGERY

## P.O.W.E.R NOTES SBQ 38

- I. According to the OPG the IAN runs closer to the 3rd molar, there's an interruption of the canal.



Radiographic sign	Criteria for positive sign
Diversion of the canal	Change in direction of inferior alveolar canal when it comes on contact with root of third molar
Interruption of white line of canal	Disappearance of one or both cortical white line of inferior alveolar canal
Narrowing of the canal	Reduction in diameter of the inferior alveolar canal when it meets roots of third molar
Darkening of root	Increased radiolucency because of overlapping of the canal and roots of third molar
Deflection of root	Abrupt deviation of third molar roots when it reaches the canal
Narrowing of the root	Abrupt narrowing of the third molar root when it overlaps with the inferior alveolar canal
Dark and bifid apex of the root	Double shadow of periodontal membrane when roots cross the inferior alveolar canal

- II. Masseter hypertrophy can't be seen in x-rays. Attrition is a clinical feature that can be seen due to bruxism. Attrition can be identified in a x-ray due to the presence of the thin enamel.

# ORAL SURGERY

## SBQ 39

68 YEAR OLD PATIENT, HAS COME FOR EXTRACTION 26,17 AND 13 GRADE 3 MOBILE .RADIO FINDINGS OF 26 LIKE CURVED ROOT OR HYPERCEMENTOSIS. PATIENT HAS THREE TEETH LEFT IN THE UPPER JAW 26 ,17,13 AND WANTED TO GET THEM EXTRACTED. ALL THESE TEETH WERE GRADE 3 MOBILE ON EXAMINATION. YOU DECIDE TO REMOVE IT BY SURGICAL EXTRACTION. WHILE REMOVING A TOOTH U FRACTURE THE ROOT TIP, PT GETS ANGRY.

I. Question on denosumab. He was about to start denosumab next week. What should you ask before extraction (safest time zone)

- A. When did the dose started
- B. When is the next dose

II. On providing denture for denosumab patient what should you inform the patient to report immediately?

- A. Calculus deposits on dentist
- B. Soreness under denture
- C. Stains in denture

# ORAL SURGERY

## P.O.W.E.R NOTES SBQ 39

### I. **Reference** : TG PG 170

Patient who is on denosumab is associated with any of the risk factors mentioned below is at a high risk of developing MRONJ.

- Immune compromised
- Diabetes
- Anaemia
- Hyperthyroidism
- Renal dialysis
- Glucocorticoid therapy
- Tobacco use
- Periodontal disease
- Denture use
- Local suppuration

Patient is about to start the denosumab in the next week.

Denosumab is a reversible antiresorptive administered every 6 months for osteoporosis. If it's possible to delay a bone invasive dental procedure in a patient taking denosumab for osteoporosis, ideally schedule the procedure just before the next dose of denosumab. It's never appropriate to interrupt or delay the dose of denosumab. Withdrawal of denosumab has been associated with an increased risk of spontaneous vertebral fractures.

II. Poorly fitting dentures, inflammation/ soreness under the denture puts the patient at a higher risk to develop MRONJ.

# ORAL SURGERY

## SBQ 40

**ON PERFORMING EXTRACTION OF THE MAXILLARY FIRST MOLAR YOU FIND BLUE LINING WHICH BLOWS ON EXPIRATION.**

**I. What is the factor which decides which surgeon to refer the patient to an oral surgeon?**

- A. Size of the opening
- B. Ask patient to blow nose with closed nostrils.
- C. Air passes through communication while he breathes.
- D. Surrounding soft tissue available for its closure.

**II. What do you advise the patient for healing?**

- A. Antibiotics
- B. Do not blow the nose
- C. Sneeze with mouth closed
- D. Saltwater rinse after 24 hours

**III. You conclude on doing surgical extraction (buccal bone removal). What is the important aspect of flap design?**

- A. Base wide and narrow apex.
- B. Within the attached gingiva.
- C. Bevelled margins
- D. Use a split thickness flap design.

**IV. Patient was worried about post op complications. What will you advise the patient that is crucial to an uneventful healing?**

- A. Resorbable suture
- B. Blood Clot retention
- C. Warm saline rinses
- D. Antihistamines
- E. Antibiotics

**V. Patient comes with trismus after few days of extraction, what is the cause of this?**

- A. Internal derangement of jaw.
- B. Traumatic extraction

# ORAL SURGERY

## P.O.W.E.R NOTES SBQ 40

- I. Blue lining which blows on expiration is the sinus lining. There's an oroantral communication.

**Oroantral communication (OAC)** is an opening between the oral cavity and the maxillary sinus, often occurring after the extraction of upper posterior teeth. If this communication does not heal properly, it can develop into an **oroantral fistula (OAF)**, a persistent pathological connection.

Epithelial lining is formed in this communication and form the oroantral fistula.

Check for the presence of oroantral communication by holding the patient's nose and getting them to blow, listen for any passage of air or bubbles. If the tooth is intact and the **communication is small** compress the socket and suture closed. Tell the patient to not to blow their nose or create a negative pressure.

If the **communication is large, more than 4mm** or a piece of tooth is missing, promptly refer to an oral and maxillofacial surgeon. A two-layer mucoperiosteal flap with a buccal fat pad graft is useful for large communications.

Size of the opening will decide that it can be done by general dentist or an oral and maxillofacial surgeon.

- II. To keep the integrity of suture and the flap is most important.

**Advice the patient to:**

Don't blow the nose, otherwise the pressure can break the sutures and integrity of the communication. It's the most important thing to do.

Sneeze while the mouth is open, so, the negative pressure will not be created.

Saltwater gargle

Use of antibiotics and anti-inflammatory in case of persistent infection and sinusitis, oroantral fistula formation.

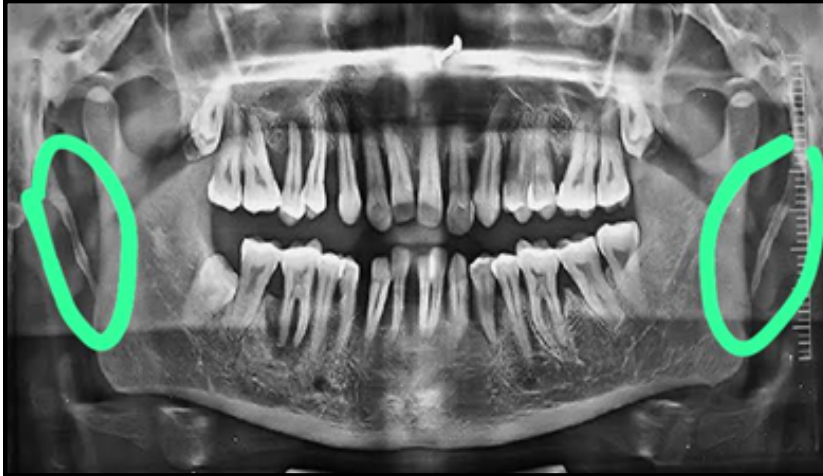- III. Incision should be made beyond the mucogingival junction to make it movable. Base should be wider, and the apex should be narrower.

- IV. Compression is done to preserve the blood clot. Clot formation is the 1st step of healing.

- V. IM injection during LA can lead to trauma to the muscle which lead to internal bleeding and hematoma formation. This results in trismus. LA should be given within the tissue space, not in the muscle or vessel.

Specialist referral is needed in the presence of trismus after extraction.

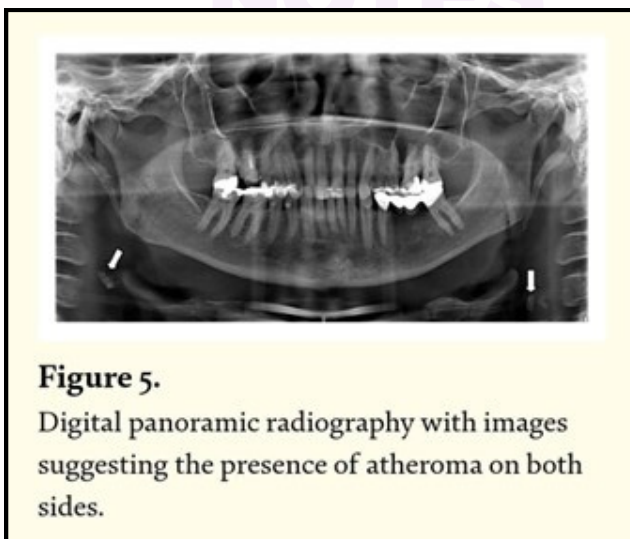
# ORAL SURGERY

**SBQ 41****SAME OPG**

I. Asked about this calcified ligament which cause her difficult during swallowing.

- A. Stylo Cricoid
- B. Stylomandibular
- C. Stylohyoid
- D. 4 stylopharyngeus

II. OPG - you are very concerned about white structure in the opg and you decided to send it to her GP. What condition in the below makes the patient worse if confirmed? There were radiopaque dots near the angle of mandible on both sides and they had encircled that.pt is taking clopidogrel. Calcification on both sides of OPG. Phlebolith, but not in the cervical spine. In relation to her medical condition what makes the condition worst if confirmed.



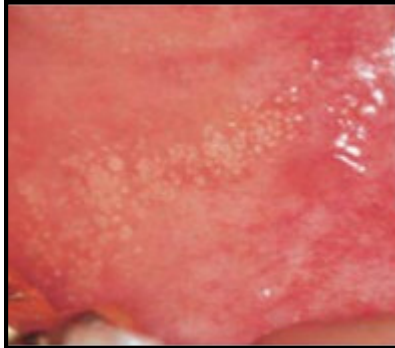**Figure 5.**

Digital panoramic radiography with images suggesting the presence of atheroma on both sides.

- A. Stroke
- B. Thyroid goitre
- C. Hypercalcemia
- D. Renal stones

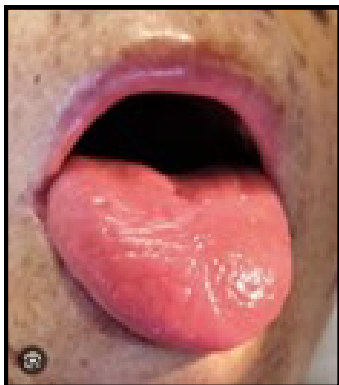

# ORAL SURGERY

**SBQ 41**

**III. SAME PHOTO - Question - you have diagnosed this as Fordyce spots. What is management?**

- A. Biopsy
- B. Corticosteroid
- C. NSAID
- D. No treatment



**IV. Patient has burning sensation in the tongue, has been to the doctor and iron levels are normal, beefy tongue appearance. Due to lack of which vitamin tongue becomes atrophic.**

- A. Vit A
- B. Vit K
- C. Vit C
- D. Vit B12



# ORAL SURGERY

## P.O.W.E.R NOTES SBQ 41

- I. Bilateral radiopacities behind the ramus are the calcified ligaments. They are stylohyoid ligaments. They run from styloid process to the hyoid bone. Facial pain when turning the head, dysphagia, foreign body sensation, pain on extending tongue, change in voice, sensation of hypersalivation, tinnitus or otalgia can be present and in these cases the term “Eagle syndrome” is used.
- II. There’s a calcification close to the vertebra. These are atheroma in the carotid artery. It’s a high-risk condition. It can dislodge and can reach the cranial blood vessels and can lead to ischemic stroke.
- III. Fordyce’s granules/ spots are the ectopic sebaceous glands and they don’t require any treatment.
- IV. Beefy red enlarged tongue is associated with vitamin deficiency. Iron and vitamin B12 deficiency are associated with glossitis. In the question it’s mentioned that the iron levels are normal.

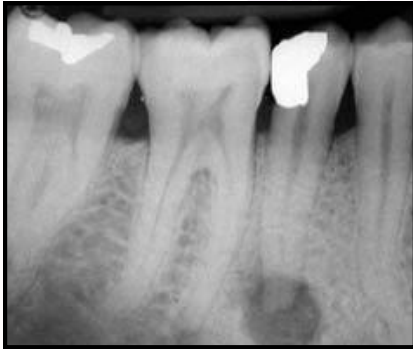**Pernicious anaemia, one of the causes of vitamin B12 deficiency, is an autoimmune condition that prevents your body from absorbing vitamin B12. Left untreated, pernicious anaemia can cause serious medical issues, including irreversible damage to your nervous system.**

Pernicious anaemia related enlarged tongue and glossitis is associated with vitamin B12 deficiency.

# ORAL SURGERY

## SBQ 42

PATIENT COMES TO YOUR PRACTICE WITH DIFFUSE SWELLING, AND PAIN IN MANDIBULAR POSTERIOR REGION SINCE 3 DAYS. ON RADIOGRAPH YOU FIND SWELLING EXTENDS FROM PREMOLAR REGION TO RAMUS. HE WAS HAVING SPACE INFECTION IRT 38 AND YOU ARE SUSPECTING IT TO BE LUDWIG'S ANGINA.



### I. What is the radiological diagnosis?

- A. Acute periapical rarefying osteitis
- B. Fibrous Healing
- C. Chronic apical periodontitis
- D. Overactive granuloma
- E. Advanced stage of Radicular cyst

### II. How will you confirm its Ludwig's?

- A. Raised temperature
- B. Raised floor of mouth
- C. Tender lymph nodes

### III. What is the antibiotic regime following extraction?

- A. No antibiotics as source of infection removed
- B. Amoxicillin 500mg for 5 days
- C. Amox+clav 875+125 mg for 5 days

# ORAL SURGERY

## P.O.W.E.R NOTES SBQ 42

- I. Granuloma/ abscess/ radicular cyst are **histological diagnosis** which require biopsy.  
Among the given acute rarefying osteitis is the **radiological diagnosis**.  
There's no draining sinus and it's painful so, option (C) is ruled out.  
Space infection is not a radiographic finding and it's a clinical finding.
- II. Any infection can cause raised temperature and tender lymph nodes. Raised floor of the mouth will determine that it's Ludwig's angina.
- III. Patient requires therapeutic IV dose of AB. Once the patient can swallow you can switch to oral AB.

# ORAL SURGERY

## SBQ 43

**ABORIGINAL PERSON AGE 17, WITH SEVERE PAIN IN HIS BACK TOOTH VISITS UR CLINIC. TOOTH DOESN'T REMEMBER. HE LIVES IN NON-FLUORIDATED AREAS AND REMOTE AREAS AND HAS POOR EATING HABITS. OPG GIVEN AND 38 WAS MESIOANGULAR IMPACTED, ROOTS NOT COMPLETED.**

**I. Why 3rd molar has to be removed in his case as preventive measure to prevent in opg.crowding was seen?**

- A. 3rd molar can cause crowding in anterior teeth
- B. Position of 38 molar can cause caries on 37 (could see that the 38 was mesioangular and was pressing on the 37 tooth)

**II. Removal of 3rd molars decision in 17 yr old person? (All for third molars impacted with no root formation .Lower left molar seems to be buccally placed and she has a fixed lingual retainer in lower anterior and all premolars present)**

- A. Monitor until age of 20, as bone grows it'll gain space for eruption
- B. Advise her to extract her 3rd molar as it will impact her ortho treatment.
- C. Wait until adult and extract
- D. Less complicated to extract third molars early
- E. Provide coronectomy

**III. You see that you can't extract the teeth and you refer to specialist but pt has financial constraints and he wants you to take all the third molars out**

- A. You take out the upper ones and send to specialist for the lower ones
- B. You say that you can't do the extraction
- C. Send to the local hospital so that the patient can get into the waiting list.

# ORAL SURGERY

## P.O.W.E.R NOTES SBQ 43

- I. • The present study does not provide enough evidence to incriminate 3rd molars as being the only or even major etiological factor in the late lower dental arch crowding.
- At the same time a cost/benefit analysis should be carried out to justify the prophylactic removal of 3rd molars, which should only be indicated with the purpose of preventing cases that involve pathological processes, such as root resorption or caries in second molars, cysts and pericoronitis.
  - Dentists and patients must take into account that surgical complications after 3rd molar removal are common. Severe pain, swelling, bleeding, alveolar osteitis, abscesses, dehiscence, sequestra, paraesthesia, hematoma and trismus are the complications that can take place.

Therefore option (B) is better compared to option (A).

II. As a general rule ages 18-24 is considered ideal for 3rd molar extraction.

### Why age is a consideration in wisdom tooth extraction?

Oral surgeons usually prefer to perform the procedure when about 2/3 of the 3rd molar roots have developed. Most patients reach this stage by age 18yrs, and delaying tooth extraction until then can make for an easy experience. When the tooth roots are fully erupted, 3rd molar removal is more difficult, and patients may have a great risk of complications.

According to new researches as mentioned above, all the 3rd molars don't need to undergo extraction unless they are associated with a pathology. 3rd molar eruption will not impact the ortho treatment. Bone will grow and there may be space for 3rd molars to erupt, therefore, better to monitor.

III. If all the 3rd molars are erupted, then the answer would be (A). If all the 3rd molars are impacted then the answer would be (C). OPG is required to decide this.

# ORAL SURGERY

## SBQ 44

### ORAL SURGERY

---

**I. Patient with liver cirrhosis which L.a can be given?**

- A. Mepivacaine
- B. Articaine
- C. Lignocaine
- D. Citanest

**II. You are injecting block but you're unable to achieve successful anaesthesia.**

**You also had two positive aspirations and you're worried that the patient has received toxic levels of L.A. The patient feels unwell. how to know systemic toxic dose of anaesthesia what will be early sign of LA toxicity**

- A. Excitability
- B. Hyperventilation
- C. Hypotension
- D. Palpitation
- E. 5, wheezing

**III. What is the best anaesthetic for a "long procedure" to extract 16 with a flap? I don't remember but I think the patient didn't have any systemic problems or allergies.**

- A. Articaine with adrenaline
- B. Lidocaine with adrenaline
- C. Prilocaine with felypressin
- D. Mepi with adrenaline

**IV. First immediate sign of heart attack?**

- A. Noisy breathing
- B. Skin pallor
- C. Tingling in tips and lips
- D. Slurred speech

# ORAL SURGERY

## P.O.W.E.R NOTES SBQ 44

I. Articaine is the safest LA for patients with liver and kidney disease. Plain mepivacaine, prilocaine with felypressin or maximum of 2 cartridges of lidocaine with adrenaline are the best indications for cardiovascular patients.

II. CNS signs appear 1st before the CVS signs. 1st the excitability (restlessness and anxiety) take place.

### Reference: TG

the clinical presentation of systemic toxicity is variable and can include neurological, psychiatric, cardiovascular and respiratory effects, allergic reactions and rarely methemoglobinemia. Minor **CNS effects** (e.g. restlessness, anxiety, tinnitus, dizziness, blurred vision, tremors, CNS depression, drowsiness are early indications of systemic toxicity. However, CVS effects may occur before CNS effects if a long acting LA is used (particularly bupivacaine). Serious systemic effects include seizures and CV toxicity.

Hyperventilation, hypotension, palpitation, wheezing are CVS and respiratory signs.

III. It's a long procedure which requires a flap; therefore, block anaesthesia is required. Articaine is given only as infiltration. So, option (A) is ruled out. Patient doesn't have any allergy or contraindication to lignocaine. So, option (C) is ruled out. Both options (B) and (D) are intermediate LA. Lidocaine is widely used. So, option (B) is selected.

IV. CARDINAL SYMPTOMS OF HEART ATTACK ARE:

- Chest pain
- Pain in the shoulder or back
- Radiating pain or numbness in the arm
- Dyspnea
- Fatigue

# ORAL SURGERY

## SBQ 45

### FROM INFECTION CONTROL

**I. Hep b. In this scenario pt clearly said to the dentist that he is infected with hep.B 10 months ago and he is homosexual before starting the procedure. So, the DA asks the dentist what preventive measures should we take for handling this pt. So what might have the dentist said to the DA.**

- A. Use disposable gloves
- B. See him as first patient of the day
- C. Use 2 cycles for sterilisation
- D. Use N95 mask
- E. Don't treat the patient and delay the appointment
- F. Treat patient with regular sterilisation

**II. Dentist met with an penetrating injury from the forceps with the above mentioned Hep. b pt. After an injury while cleaning immunity level 98mIU/ml. What should the dentist do now?**

- A. Get a booster dose
- B. Immunization again
- C. Get the medical advice asap
- D. Within 48-72 hrs single human immunoglobulin dose
- E. No precaution you are already immunised

**III. Dentist is worried and emotional while explaining this scenario to the patient about a sharp injury and you're uncomfortable regarding blood borne infections. You are contemplating of the recent incident What Should be his next step to manage the patient/ or to avoid this situation in future (two versions)**

- A. Avoid infected hep B patients in future
- B. Refer infected patients to a colleague
- C. Undergo a sharps injury refresher training before your next appointment
- D. Do palliative care today and ask him to come back for the rest of the treatment later

**IV. How to tell if a person is not immunised, I think the question was more. How to check that the HBv is still and active infection**

- A. HBS ag
- B. Hbs antibody(Hb S)
- C. HBC antigen
- D. HBC antibody
- E. IgM



# ORAL SURGERY

## P.O.W.E.R NOTES SBQ 45

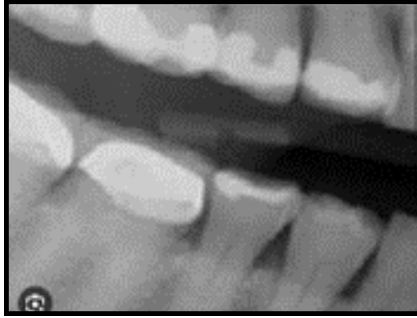
- I. In case of hepatitis B, standard precautions are taken. Therefore, patients are treated with regular sterilisation.
- II. Booster dose is given when the immunity level is below 10. Nothing is required when the immunity level is above 10. In this case patient's immunity level is 98IU/ml. so, he's well immunised. Therefore, no immunisation or booster dose is required.
- III. Dentist is worried about the needle injury. So, it's good to proceed ahead with the treatment in the next appointment and do the palliative care today.  
You can avoid this situation by undergoing a training related to sharps before the next appointment.
- IV. Indicator for hepatitis B immunity= hepatitis B antibody  
Indicator for patient is actively infected= hepatitis b antigen (HBe and HBs); when both HBe and HBs are given, HBe is chosen as it is transmissible and actively replicating.

# ORAL SURGERY

## SBQ 46

### BITEWING ERROR

I. It showed lower molar mid root on distal side and upper occlusal 1/3rd on mesial side two edges with black area lower root not visible x ray looked angled (a bit vertically sloping downwards distally)



- A. Sensor displaced vertically by tongue
  - B. Sensor pushed palatally
  - C. Patient gagged while taking
  - D. Sensor contacted patient's palate on biting
  - E. Patient did not bite the bite block correctly
- II. Patient with gagging, pic of occlusion given roots stumps in front lower enough teeth present upper only three in occlusion need to take posterior and anterior teeth how to take a radiograph
- A. Use extraoral radiograph
  - B. Slide the sensor along the palate
  - C. Take canine first and molars later
  - D. Give him antiemetic and then take radiograph
- III. You manage to take the radiograph of that patient, and then 2 radiographs were given.

# ORAL SURGERY

## P.O.W.E.R NOTES SBQ 46

- I. Patient has not been bitten on the bite block completely, so, there's a gap between the upper and the lower teeth and the upper teeth are not visible completely.
- II. When the patient has gag reflex you should not start with the pharmacological management 1st.  
Gag reflex can be controlled by smaller exposures such as managing the anterior 1st and posteriors later.  
Extra oral radiographs are not clear enough and there's too much of exposure to radiation.

# ORAL SURGERY

## SBQ 47

CHILD WITH UNERUPTED PREMOLAR AND FACIAL SWELLING CASE. NO OBVIOUS CARIES OR TRAUMA HAS FACIAL SWELLING AND BUCCAL SINUS AND THEY ARE GOING OVERSEAS IN ONE WEEK, X-RAY GIVEN 12YR OLD OPEN APEX. THERE WAS NO PAIN IN PAST AND NOT NOW. MOTHER WAS WORRIED WHY THIS IS HAPPENING. SWELLING WAS HARD AND FIRM.

### I. What will you tell her that is likely diagnosis?

- A. Systemic condition
- B. Cellulitis
- C. Abscess
- D. Induration
- E. It's unusual to have a radiolucency for a vital tooth.

### II. What will be the immediate management?

- A. Extraction
- B. Pulp debridement
- C. Analgesics only
- D. Drainage and antibiotic

### III. What will be the final management?

- A. Extraction
- B. Refer to endo
- C. Refer to oral surgeon
- D. Close the apex with mta and do the rct
- E. Close the apex with caoh and do the rct

# ORAL SURGERY

## P.O.W.E.R NOTES SBQ 47

In the main question it's given as "It's an **unerupted** premolar associated with radiolucency". But we are answering the below questions by thinking it's an **erupted tooth**. Because the given answers are not matching if the tooth is unerupted.

If it's an unerupted premolar associated with radiolucency, it can't be associated with systemic disease. The likely diagnosis can be dentigerous cyst.

If it's an erupted premolar associated with radiolucency, then it can be associated with Langerhans cell histiocytosis.

- I. Usually swelling associated with an odontogenic infection and draining sinus will not be hard and firm. The likely diagnosis is; It's unusual to have a radiolucency in a vital tooth. (no caries / no trauma)
- II. There's big radiolucency associated with the premolar. Sometimes may not be able to save the tooth. But it may require pulp debridement and take some of the exudate out. Since it has open apex, apexification may require.
- III. We are referring the patient to the oral surgeon as there's no odontogenic cause associated with the swelling, whether the tooth is erupted or un erupted.

# ORAL SURGERY

## SBQ 48

LADY IN HER 50S CAME TO YOUR CLINIC AND REPORTED THAT SHE HAD INJURED HER UPPER FRONT TWO TEETH. (11,21) 3 DAYS AGO WHILE SHE WAS CLEANING HER HOME. ON EXAMINATION YOU FOUND THAT HER TOOTH 21 IS GRADE 1 MOBILE AND HAD 1 MM GINGIVAL RECESSION ON CERVICAL REGION OF THE TOOTH AND YOU ASK HER WHETHER SHE KNEW ABOUT IT, PATIENT SAYS SHE KNEW ABOUT GUM LOOKING LIKE THIS SINCE 1 YEAR BUT SHE'S NOT BOTHERED ABOUT IT

**I. You did a vitality test of the teeth and found no response. What is the reason for no response?**

- A. Recent trauma renders temporary loss of sensations
- B. You decide to do splinting
- C. Nylon splint for 2weeks

**II. One case with an X-ray after trauma but you are not satisfied with the X-ray. Pt came after trauma happened 2 days ago while cleaning the house. Just a little loose.**

**III. What X-ray will give you the most info lopa given very light, 11 was crown fracture, 21 was fractured on root horizontal fracture?**

- A. lopa in different angulation
- B. Occlusal
- C. Cbct
- D. Mri

**IV. What is the most appropriate specialist to refer?**

- A. Endo
- B. Perio
- C. Oral surgeon
- D. Orthodontist

**V. The patient has come after 2 weeks for splint removal. What will you check in the X-ray on that appointment?**

- A. Vitality of tooth
- B. Signs of inflammatory root resorption
- C. Ankylosis
- D. Revascularisation

**VI. What is the diagnosis of 11?**

- A. Complicated Crown fracture on 11
- B. Luxation on 11
- C. Uncomplicated crown fracture
- D. Crown and root fracture irt 11

**VII. What is the diagnosis of 21?**

- A. Horizontal root fracture

# ORAL SURGERY

## P.O.W.E.R NOTES SBQ 48

- I. There's a temporary loss of sensation. The main factors that interfere with the effectiveness of sensibility tests in newly traumatized teeth are subjectivity of the patient's response, alteration of the pain threshold, changes in the supporting dental tissues, and especially transient paraesthesia, which may persist up to 6 months after the traumatic injury.
- II. IOPA in different angle would be helpful to identify root fracture.
- III. There's a horizontal root fracture. So, need to check whether both fragments have vitality or not. Sometimes you might have to do the RCT till the fracture line. Therefore, need to refer to the endodontist.
- IV. All the clinical and radiographical evaluation is done in each appointment according to the trauma guideline. Vitality can't be checked with the help of the x-ray. Option (A) is ruled out. In 2 weeks', time ankylosis will not take place. Option (C) is ruled out. Revascularisation will not show with a x-ray. Signs of root resorption may appear in 2 weeks' time.
- V. Given history is not enough to mark whether it's complicated/ uncomplicated crown #. Therefore, answer can be (A) or (C).
- VI. In the question it's clearly given that there's a horizontal root # involving 21.

# ORAL SURGERY

**SBQ 49****AIRWAY OBSTRUCTION**

**I. You were doing prophylaxis and the proph cup came off and fell (across the back of the patient's tongue) What is the next step to take?**

- A. Call an ambulance
- B. Give abdominal thrust
- C. Put into recovery position
- D. Give up to 5 back blows
- E. Cricothyrotomy

**II. Emergency number in Australia?**

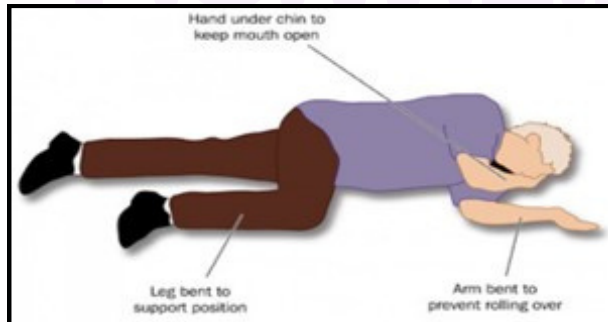
- A. 000, 999
- B. 000, 112
- C. 000, 911
- D. 911, 112



# ORAL SURGERY

## P.O.W.E.R NOTES SBQ 48

- I. According to TG, it's not the recovery position, it should be upright position. So, option (C) is ruled out. Below image demonstrates the recovery position.



### Box 48. Management of an inhaled or swallowed object [NB1]

In the event that an object appears to have fallen down the oropharynx:

- Stop dental treatment.
- Check whether the object is present in the patient's mouth or clothes and, if so, remove it.
- If the object is not found, put the patient into an upright position.
- Although the majority of ingested foreign bodies will pass through the gastrointestinal tract without incident, refer the patient for further medical assessment and management. If the patient is stable and asymptomatic, it may be appropriate to complete dental treatment before doing so.

If the patient is conscious with signs of airway obstruction (see Table 26; p.257):

- Call 000.
- Reassure the patient and encourage them to relax, breathe deeply and try to dislodge the object by coughing.
- If coughing is ineffective, give up to 5 back blows between the shoulder blades using the heel of the hand (checking for effectiveness between each blow).
- If back blows are unsuccessful, give up to 5 chest thrusts delivered at the same compression point as for CPR (checking for effectiveness between each chest thrust).
- Continue to alternate between back blows and chest thrusts until the obstruction is relieved or assistance arrives.

If the patient with airway obstruction becomes unconscious:

- Call 000.
- Inspect the back of the throat for the foreign object and remove it if possible.
- Start CPR (for 'Basic life support flow chart', see Figure 8; p.235).
- Clinicians with appropriate expertise and equipment should consider performing cricothyroidotomy.
- Abdominal thrusts, such as those described in the Heimlich manoeuvre, can cause internal organ damage so are not recommended.

CPR = cardiopulmonary resuscitation

NB1: A flow chart for the management of choking can be downloaded from the Australian Resuscitation Council website <[resus.org.au/guidelines/flowcharts-3/](http://resus.org.au/guidelines/flowcharts-3/)>.

emergencies in dental

Back blows, chest thrusts and cricothyroidotomy are done after calling 000.

- II. 000 is Australia's main emergency service number. You should call 000 if you need urgent help from police, fire or ambulance services. Telstra answers calls to the emergency service numbers 000 and 112 and transfers the call, and information about your location, to the emergency service you request.

# ORAL SURGERY

## SBQ 50

### ICG NEW QUESTIONS

**I. How much time does ADA guidelines recommend that you should have your blood tested after a sharp incident with a needle?**

- A. Within 24 hours
- B. One week
- C. Two weeks
- D. 4-6 weeks

**II. Where should the sharps bin be located?**

- A. In the sterilization room
- B. Near to the point of use
- C. Above/near the hand washing sink
- D. In overhead cupboard
- E. Above/near the dustbin

**III. How will you discard needle and syringe after use to avoid sharp injury**

- A. Hold the syringe assembly with one hand and close the syringe with the other hand
- B. Hold the syringe assembly with a hand and close the syringe cap with the other hand
- C. Leave the syringe assembly on the bracket table and cover the needle with a gauze
- D. Hold the syringe in one hand and Remove with a needle holder with other hand
- E. Keep the syringe with a needle in a contaminated area on the bench top

**IV. According to spaulding classification ,which is the semi critical item**

- A. Mouth Mirror
- B. Stainless steel matrix band
- C. Shade guide
- D. Extraction forceps
- E. Eye wear

# ORAL SURGERY

## P.O.W.E.R NOTES SBQ 50

- I. The test should be completed as soon as possible after the injury (ideally same day and definitely within 24hrs) bearing in mind the window period of the tests.
- II. Sharp bin should be wall mounted. It should never be in overhead cupboard. It should never be near the hand washing sink.

### Reference: ICG

Disposal of sharps is always best done at the point of use (i.e. into a sharp bin located in the operatory or treatment room).

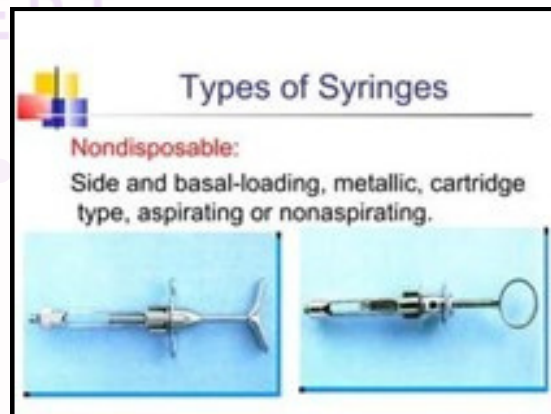
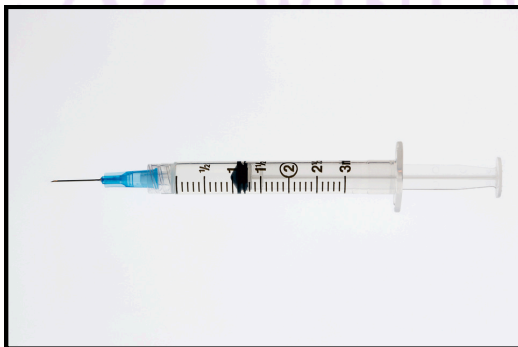It should be wall mounted at the height of 1100-1300mm from the floor to enable access from the sitting position, or a minimum of 1300mm if access is required from the standing position, so as to allow staff to be able to see into the opening of the container.

### III. Reference: ICG

Needles must not be re-sheathed unless using an approved recapping device or single-handed technique. Contaminated needles must never be bent or broken by hand or removed from disposable syringe.

In the question it's asked how to discard "needle and syringe" so, the answer would be (B). this is applicable for the disposable syringe.

In the question if it's asked how to discard "needle" so, the answer would be (D). this is applicable for the non-disposable syringe.



- IV. Stainless steel matrix band is a single use item which is discarded after use.

Shade guide and eye wear are non-critical instruments.

Extraction forceps is a critical instrument.

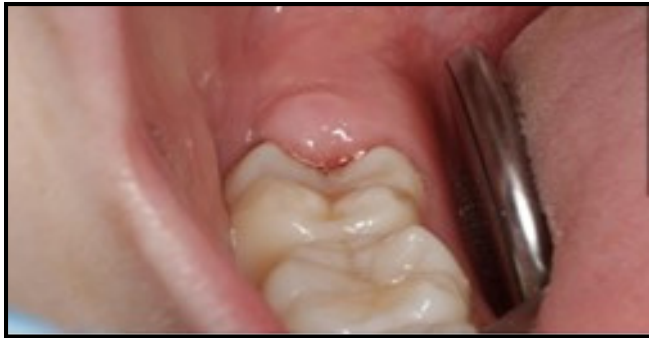Mouth mirror is a semi critical instrument.

# ORAL SURGERY

## SBQ 51

### PERICORONITIS

A TEENAGE GIRL COMES TO YOU WITH A COMPLAINT OF A REPEAT EPISODE OF PERICORONITIS. IOPA WAS GIVEN ,A QUESTION WAS ASKED REGARDING THE 3RD MOLAR (CLINICAL PICTURE WAS GIVEN IN SOME CENTERS) . IT WAS IMPACTED AGAINST THE SECOND MOLAR WITH SWOLLEN OPERCULUM IN RESPECT TO 48 AND THE SAME APPEARANCE ON THE 3RD QUADRANT AS WELL.



#### I. Which investigation will you perform 1st?

- A. Bitewing
- B. IOPA
- C. Opg
- D. Cbct
- E. MRI

#### II. Where should the sharps bin be located?

- A. Salt water gargle
- B. Chlorhexidine mouthwash
- C. Ibuprofen
- D. Operculectomy
- E. Debridement and irrigation with 1% peroxide
- F. Povidone iodine

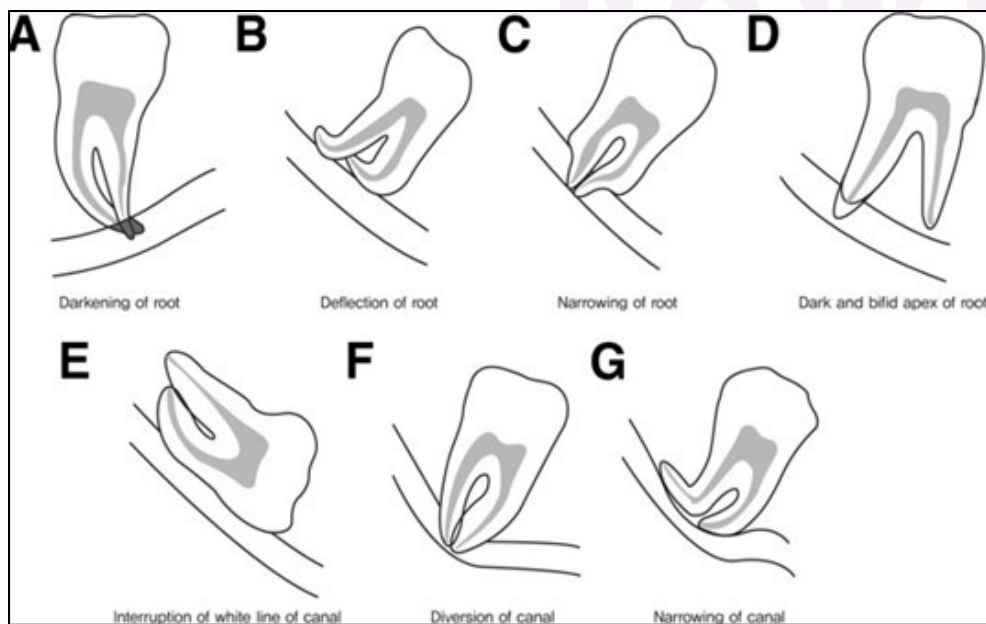
#### III. What will be the most difficult factor faced during the extraction of the third molar?

- A. IAN is just touching the roots of tooth
- B. There is interruption in the continuity of the lamina dura of the IAN
- C. There is darkening of roots of tooth
- D. There is narrowing of the bony wall of the canal

# ORAL SURGERY

## P.O.W.E.R NOTES SBQ 51

- I. Repeated episodes of pericoronitis in related to 3rd molar requires extraction. OPG is the gold standard investigation which is required in surgical removal of 3rd molar tooth. CBCT is only require din complicated extractions and that would be recommended by the oral and maxillofacial surgeon and not by the general dentist.
- II. The most common sign of a close relationship between 3d molar and mandibular canal have been consistently reported as the interruption of the white line followed by darkening of the roots.
- III. Option (A) is incomplete, the temperature matters. It should be warm saline. According to TG, CHX can be give up to 2 weeks.
- IV. The most difficult factor is the interruption of the white line of the canal. Keep in mind the pneumatic ID. (I=interruption D= darkening of the roots)



# ORAL SURGERY

## SBQ 52

### ON IV BISPHOSPHONATES

MISS RUTHERFORD CAME TO YOUR CLINIC, HER GENERAL PHYSICIAN IS SOON GOING TO START IV BISPHOSPHONATES ON COMING FRIDAY. ON OPG, 36 IS RCT TREATED WHICH IS INCOMPLETE, MESIAL ROOT APPEARED BULBOUS, INFECTION IS PRESENT AT PERIAPICAL AREA. OTHER TEETH SEEMS TO HAVE NO PROBLEMS SHE CAME TO YOU FOR AN OVERALL DENTAL CHECK UP BEFORE SHE STARTS HER IV BISPHOSPHONATE THERAPY.

**I. What is the best advice you would include in the management before she goes for her next dose?**

- A. Switch to oral from IV bisphosphonates
- B. Stop the iv bisphosphonates
- C. Drug holiday
- D. Continue taking the same regime.
- E. Do only restorative work, tell GP to continue with treatment.
- F. Delay the bisphosphonate therapy for one week.

**II. From the x-ray, what local factor is going to make the extraction most difficult for you? (all this factors are seen in X-ray)**

- A. Brittleness of RCT treated 36
- B. Close proximity of ML root of 35
- C. Change in the density of the bone

**III. Regarding the consent of extraction of 36. What is the most important factor to be considered for extraction?**

- A. Make sure patients understands the whole procedure
- B. Give patient the brochure to read
- C. Important to sign the written consent
- D. It's legal procedure
- E. You explain details of steps of the procedure to the patient.



# ORAL SURGERY

## P.O.W.E.R NOTES SBQ 52

I. There's an underlying infection in relation to 36 which requires extraction. Patient is going to receive IV bisphosphonates.

According to the flow chart given in TG, this patient is at a lower risk. If the tooth has an abscess, then the patient is at a higher risk.

According to TG it's advised to extract just before starting bisphosphonate treatment or immediately after bisphosphonate treatment.

### Reference: TG

- If possible, any necessary dental treatment should be completed before or shortly after starting antiresorptive therapy for osteoporosis (e.g. within 6months) the risk of MRONJ of the jaw in patients with osteoporosis remain low in the early stage of the treatment.
- It's never appropriate to interrupt or delay the dose of denosumab; withdrawal of denosumab has been associated with an increased risk of spontaneous vertebral fractures.
- There is no evidence that drug holidays reduce the risk of MRONJ.

II. In case of brittleness of RCT, we can split the tooth and manage.

In case of hypercementosis, lot of bone must be sacrificed. More complicated procedure.

III. You can explain all the steps to the patient, but the informed consent can be taken only if the patient understands the procedure well. If the patient doesn't have the mental capacity to understand there's no point in explaining all the steps to that patient.

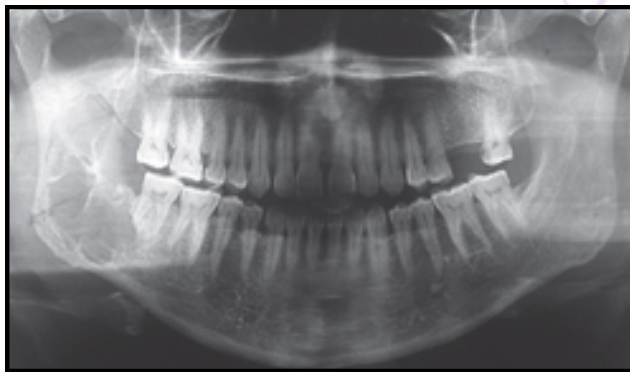
# ORAL SURGERY

## SBQ 53

### JAW LESION

OPG GIVEN. MULTIOCLULAR RADIOLUCENCY EXTENDING TO THE RAMUS AND 48 WAS CLOSE TO THE LESION BUT NOT FROM THE CEJ OF THE 48. (48 - ROOTS WERE NOT FORMED AND WERE LYING CLOSE TO THE LOWER BORDER OF MANDIBLE 47 SHOWING SOME ROOT RESORPTION. THE PATIENT FELT DISCOMFORT BEFORE BUT NOW IT HAS BEEN ACHING FOR A FEW DAYS. (PIC 1 - LOOK AT POSITION OF 47 - IN EXAM 47 WAS DISPLACED OCCLUSALLY SLIGHT AS COMPARED TO PLANE OF 46 AND ALSO ROOT RESORPTION WAS SEEN WITH BOTH 47 AND 46)

RADIOLUCENT LESION WAS LIKE ONE SHOWN IN THIS PIC AND 3RD MOLAR WAS PLACED MORE TOWARDS LOWER BORDER OF MANDIBLE)



I. What is the lesion on the right side which has 3rd molar impacted, multilocular radiolucency?

- A. Metastatic tumor
- B. Radicular cyst
- C. Odontogenic keratocystic tumor
- D. Hemangioma
- E. Myxoma

II. What is the complication caused by the lesion with respect to 47?

OR

(What could be complicating adjacent teeth due to radiolucency)

- A. Root resorption on 47
- B. Distal pocket formation with 47
- C. Displacement of 47

III. What is the most conservative treatment for this lesion?

- A. Extraction of 48 and enucleation
- B. Resection
- C. Cryosurgery
- D. Enucleation



# ORAL SURGERY

## P.O.W.E.R NOTES SBQ 53

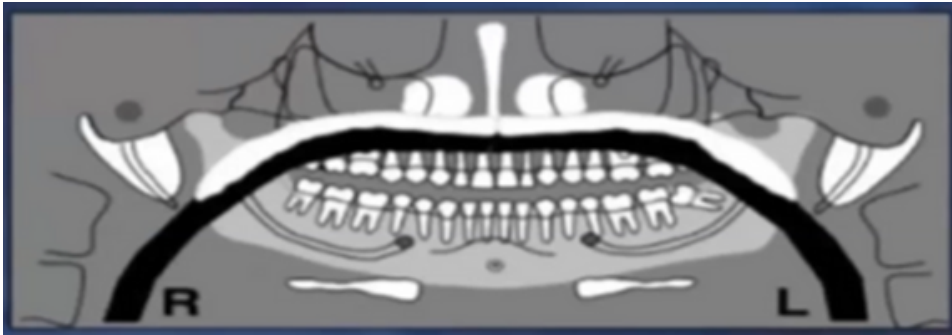- I. • **Metastatic lesions** don't have multilocular radiolucency. They are presented with diffuse radiolucency in the mandible. But not associated with impacted teeth.
- **Radicular cyst** is associated in the periapical area of the infected root.
  - **OKC** is seen as a multilocular radiolucency associated with impacted teeth.
  - **Hemangioma** is not associated with impacted teeth.
  - **Myxoma** is not associated with impacted teeth.
- II. There are 2 variants of this question.
- If it's asked what the complication is caused by the lesion; then the answer would be **root resorption**.
- If it's asked what could be the complicating the adjacent teeth; then the answer would be **displacement of 47**, as root resorption is already mentioned in the question.
- III. Cystic lesion doesn't require resection. Resection is a tumour related procedure. Resection is done in ameloblastoma.
- For OKC extraction along with enucleation is required. Enucleation alone is not adequate. OKC has the highest recurrence rate among all the cysts.

# ORAL SURGERY

## SBQ 54

### OPG ERROR

OPG GIVEN IN WHICH THERE WAS A RADIOLUCENT BAND OVER THE APICAL PART OF THE ROOTS OF UPPER ANTERIOR TEETH. WHAT WILL YOU TELL THE PATIENT TO PREVENT THIS?



- A. Ask the patient to keep the tongue still
- B. Ask the patient to keep the tongue in contact with the palate
- C. Place the chin downwards

### P.O.W.E.R NOTES SBQ 54

Palatoglossal space is appearing as the radiolucent band in this OPG. It's a radiographic error. We can prevent it by asking the patient to keep the tongue in contact with the palate.