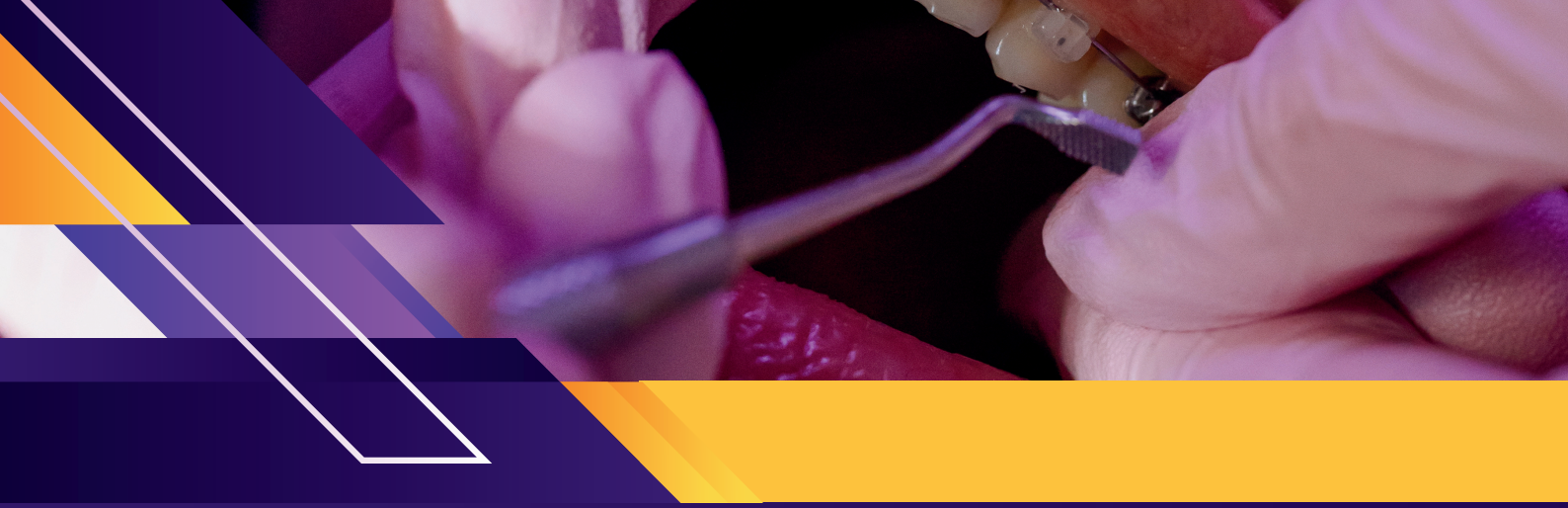



WINSPERT

# PEDODONTICS Part 2

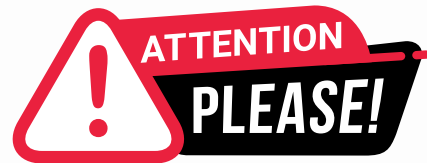# H.O.T

HIGH-PRIORITY ORGANISED THEORY

# NOTES

By Dr. Jigyasa Sharma





Dear Students,

We'd like to remind you about the importance of respecting the integrity of the resources provided in our app.

Please be aware that **WINSPERT HOT NOTES ARE COPYRIGHTED CONTENT. Unauthorized use, including screenshots, copying, misuse, reuse, or resale of any content from this app, is strictly prohibited.**

**Our app monitors and records all screenshots and recordings. Violators will face strict legal action.**

We're committed to providing you with the best tools for your success, and we appreciate your cooperation in maintaining a fair and secure learning environment.

Thank you for your understanding and continued dedication.

Best regards,  
WINSPERT TEAM

# PEDODONTICS

## H.O.T TOPICS

7. Trauma Guidelines
8. Primary Teeth Restorations
9. Behaviour Management
10. Child Abuse Management
11. Sports Drinks & Mouthguards
12. Childhood Systemic Diseases and Infectious Diseases

# TRAUMA GUIDELINES

(Sources IADT trauma guidelines 1, 2 and 3 (Fractures and location in permanent teeth, Trauma in primary teeth and Avulsion) and Therapeutic Guidelines)

- Trauma involving the dento-alveolar region is a frequent occurrence which can result in the fracture and displacement of teeth, crushing, and/or fracturing of bone, and soft tissue injuries including contusions, abrasions, and lacerations.
- The combination of two different types of injuries occurring concurrently to the same tooth will be more detrimental than a single injury, creating a negative synergistic effect. For example,
  - a) Concurrent crown fractures significantly increase the risk of pulp necrosis and infection in teeth with concussion or subluxation injuries and mature root development.
  - b) Similarly, crown fractures with or without pulp exposure significantly increase the risk of pulp necrosis and infection in teeth with lateral luxation.

## Classification Of TDIs:

- A) Fractures and Luxation injury of both primary and permanent teeth
- B) Avulsion on Primary and permanent teeth

### 1) Radiographic examination in Traumatic Dental Injuries (TDIs)

- Radiographs are necessary to make a thorough diagnosis of dental injuries.
- Tooth root and bone fractures, for instance, may occur without any clinical signs or symptoms and are frequently undetected when only one radiographic view is used.
- Several conventional two-dimensional imaging projections and angulations are recommended.
- There needs to be a strong likelihood that a radiograph will provide the information that will positively influence the selection of the treatment provided.
- Initial radiographs are important as they provide a baseline for future comparisons at follow-up examinations.
- The use of film holders is highly recommended to allow standardization and reproducible radiographs.
- Since maxillary central incisors are the most frequently affected teeth, the following radiographs are recommended to thoroughly examine the injured area. This series of radiograph is provided as an example and if other teeth are injured, then the series can be modified to focus on the relevant teeth.
  - i. One parallel periapical radiograph aimed through the midline to show the two maxillary central incisors.
  - ii. One parallel periapical radiograph aimed at the maxillary right lateral incisors (should also show the right canine and central incisor).
  - iii. One parallel periapical radiograph aimed at the maxillary left lateral incisor (should also show the left canine and central incisor).
  - iv. One maxillary occlusal radiograph.
  - v. At least one parallel periapical radiograph of the lower incisors centered on the two mandibular centrals.

## DISCLAIMER

THIS IS COPYRIGHTED CONTENT. Unauthorized use, including screenshots, copying, misuse, reuse, or resale of any content from this app, is strictly prohibited. Our app monitors and records all screenshots and recordings. Violators will face strict legal action.

DISCLAIMER  
THIS IS COPYRIGHTED CONTENT. Unauthorized use, including screenshots, copying, misuse, reuse, or resale of any content from this app, is strictly prohibited. Our app monitors and records all screenshots and recordings. Violators will face strict legal action.



# TRAUMA GUIDELINES

## 1) Radiographic examination in Traumatic Dental Injuries (TDIs)

- However, other radiographs may be indicated if there are obvious injuries of the mandibular teeth (e.g., similar periapical radiographs as above, mandibular occlusal radiograph).
- Cone beam computerized tomography (CBCT) provides enhanced visualization of TDIs, particularly root fractures, crown/ root fractures, and lateral luxation.
- CBCT helps to determine the location, extent, and direction of a fracture. In these specific injuries, 3D imaging can be useful and should be considered, if available.
- A guiding principle when considering exposing a patient to ionizing radiations (e.g., either 2D or 3D radiographs) is whether the image is likely to change the management of the injury.

## 2) Photographic Documentation

- The use of clinical photographs is strongly recommended for the initial documentation of the injury and for follow-up examinations.
- Photographic documentation allows monitoring of soft tissue healing, assessment of tooth discoloration, the re-eruption of an intruded tooth, and the development of infra-positioning of an ankylosed tooth.
- In addition, photographs provide medico-legal documentation that could be used in litigation cases.

## 3) Evaluation of Pulp Status:

- It is an important consideration that is used in cases of TDIs to determine the condition of the pulp.
- The evaluation can be done with sensibility tests like (cold test or electric pulp test), which assesses neural activity of the pulp and not vascular supply and this may not be completely reliable.
- The temporary loss of sensibility is a frequent finding during post-traumatic pulp healing, especially after luxation injuries.
- Thus, the lack of a response to pulp sensibility testing is not conclusive for pulp necrosis in traumatized teeth.
- Despite this limitation, pulp sensibility testing should be performed initially and at each follow-up appointment in order to determine if changes occur over time
- Pulp sensibility testing should be done as soon as practical to establish a baseline for future comparison testing and follow up. Initial testing is also a good predictor for the long-term prognosis of the pulp.

### 5.2 | Vitality tests

The use of pulse oximetry, which measures actual blood flow rather than the neural response, has been shown to be a reliable non-invasive and accurate way of confirming the presence of a blood supply (vitality) in the pulp.<sup>14,21</sup> The current use of pulse oximetry is limited due to the lack of sensors specifically designed to fit dental dimensions and the lack of power to penetrate through hard dental tissues.

Laser and ultrasound Doppler flowmetry are promising technologies to monitor pulp vitality.

### DISCLAIMER

THIS IS COPYRIGHTED CONTENT. Unauthorized use, including screenshots, copying, misuse, reuse, or resale of any content from this app, is strictly prohibited. Our app monitors and records all screenshots and recordings. Violators will face strict legal action.

### DISCLAIMER

THIS IS COPYRIGHTED CONTENT. Unauthorized use, including screenshots, copying, misuse, reuse, or resale of any content from this app, is strictly prohibited. Our app monitors and records all screenshots and recordings. Violators will face strict legal action.

THIS IS COPYRIGHTED CONTENT. Unauthorized use, including screenshots, copying, misuse, reuse, or resale of any content from this app, is strictly prohibited. Our app monitors and records all screenshots and recordings. Violators will face strict legal action.

### DISCLAIMER

# TRAUMA GUIDELINES


## Classification:

### A) Fractures of primary and permanent teeth.

It can be further divided into:


#### 1) Enamel Infraction:

##### a) For permanent teeth:


Enamel infraction	Clinical findings	Imaging, radiographic assessment, and findings	Treatment	Follow up	Favorable outcomes	Unfavorable outcomes
 <p>An incomplete fracture (crack or crazing) of the enamel, without loss of tooth structure</p>	<ul style="list-style-type: none"> <li>No sensitivity to percussion or palpation</li> <li>Evaluate the tooth for a possible associated luxation injury or root fracture, especially if tenderness is observed</li> <li>Normal mobility</li> <li>Pulp sensibility tests usually positive</li> </ul>	<ul style="list-style-type: none"> <li>No radiographic abnormalities</li> <li>Recommended radiographs:               <ul style="list-style-type: none"> <li>One parallel periapical radiograph</li> <li>Additional radiographs are indicated if signs or symptoms of other potential injuries are present</li> </ul> </li> </ul>	<ul style="list-style-type: none"> <li>In case of severe infractions, etching and sealing with bonding resin should be considered to prevent discoloration and bacterial contamination of the infractions.</li> <li>Otherwise, no treatment is necessary</li> </ul>	<ul style="list-style-type: none"> <li>No follow up is needed if it is certain that the tooth suffered an infraction injury only</li> <li>If there is an associated injury such as a luxation injury, that injury-specific follow-up regimen prevails</li> </ul>	<ul style="list-style-type: none"> <li>Asymptomatic</li> <li>Positive response to pulp sensibility testing</li> <li>Continued root development in immature teeth</li> </ul>	<ul style="list-style-type: none"> <li>Symptomatic</li> <li>Pulp necrosis and infection</li> <li>Apical periodontitis</li> <li>Lack of further root development in immature teeth</li> </ul>

#### 2) Uncomplicated Crown Fracture involving Enamel only:

##### a) For primary teeth:


Enamel fracture	Radiographic recommendations	Treatment	Follow up	Favorable and unfavorable outcomes include some, but not necessarily all, of the following	
				Favorable outcomes	Unfavorable outcomes
 <p>Clinical findings: Fracture involves enamel only</p>	<ul style="list-style-type: none"> <li>No radiographs recommended</li> </ul>	<ul style="list-style-type: none"> <li>Smooth any sharp edges.</li> <li>Parent/patient education:               <ul style="list-style-type: none"> <li>Exercise care when eating not to further traumatize the injured tooth while encouraging a return to normal function as soon as possible.</li> <li>Encourage gingival healing and prevent plaque accumulation by parents cleaning the affected area with a soft brush or cotton swab combined with an alcohol-free 0.1 to 0.2% chlorhexidine gluconate mouth rinse applied topically twice a day for 1 wk</li> </ul> </li> </ul>	<ul style="list-style-type: none"> <li>No clinical or radiographic follow up recommended</li> </ul>	<ul style="list-style-type: none"> <li>Asymptomatic</li> <li>Pulp healing with:               <ul style="list-style-type: none"> <li>Normal color of the remaining crown</li> <li>No signs of pulp necrosis and infection</li> <li>Continued root development in immature teeth</li> </ul> </li> </ul>	<ul style="list-style-type: none"> <li>Symptomatic</li> <li>Crown discoloration</li> <li>Signs of pulp necrosis and infection—such as:               <ul style="list-style-type: none"> <li>Sinus tract, gingival swelling, abscess, or increased mobility</li> <li>Persistent dark gray discoloration with one or more other signs of infection</li> <li>Radiographic signs of pulp necrosis and infection</li> </ul> </li> <li>No further root development of immature teeth</li> </ul>

##### b) For permanent teeth:

Uncomplicated crown fracture (enamel-only fracture)	Clinical findings	Imaging, radiographic assessment, and findings	Treatment	Follow up	Favorable outcomes	Unfavorable outcomes
 <p>A coronal fracture involving enamel only, with loss of tooth structure</p>	<ul style="list-style-type: none"> <li>Loss of enamel</li> <li>No visible sign of exposed dentin</li> <li>Evaluate the tooth for a possible associated luxation injury or root fracture, especially if tenderness is present</li> <li>Normal mobility</li> <li>Pulp sensibility tests usually positive</li> </ul>	<ul style="list-style-type: none"> <li>Enamel loss is visible</li> <li>Missing fragments should be accounted for:               <ul style="list-style-type: none"> <li>If fragment is missing and there are soft tissue injuries, radiographs of the lip and/or cheek are indicated to search for tooth fragments and/or foreign materials</li> </ul> </li> <li>Recommended radiographs:               <ul style="list-style-type: none"> <li>One parallel periapical radiograph</li> <li>Additional radiographs are indicated if signs or symptoms of other potential injuries are present</li> </ul> </li> </ul>	<ul style="list-style-type: none"> <li>If the tooth fragment is available, it can be bonded back on to the tooth</li> <li>Alternatively, depending on the extent and location of the fracture, the tooth edges can be smoothed, or a composite resin restoration placed</li> </ul>	<ul style="list-style-type: none"> <li>Clinical and radiographic evaluations are necessary:               <ul style="list-style-type: none"> <li>after 6-8 wk</li> <li>after 1 y</li> </ul> </li> <li>If there is an associated luxation or root fracture, or the suspicion of an associated luxation injury, the luxation follow-up regimen prevails and should be used. Longer follow ups will be needed</li> </ul>	<ul style="list-style-type: none"> <li>Asymptomatic</li> <li>Positive response to pulp sensibility testing</li> <li>Good quality restoration</li> <li>Continued root development in immature teeth</li> </ul>	<ul style="list-style-type: none"> <li>Symptomatic</li> <li>Pulp necrosis and infection</li> <li>Apical periodontitis</li> <li>Loss of restoration</li> <li>Breakdown of the restoration</li> <li>Lack of further root development in immature teeth</li> </ul>

#### 3) Uncomplicated Crown Fracture involving Enamel and Dentin

##### a) For primary teeth:

Enamel-dentin fracture (with no pulp exposure)	Radiographic recommendations	Treatment	Follow up	Favorable and unfavorable outcomes include some, but not necessarily all, of the following	
				Favorable outcome	Unfavorable outcome
 <p>Clinical findings: Fracture involves enamel and dentin. The pulp is not exposed</p> <ul style="list-style-type: none"> <li>The location of missing tooth fragments should be explored during the trauma history and examination, especially when the accident was not witnessed by an adult or there was a loss of consciousness</li> <li>Note: While fragments are most often lost out of the mouth, there is a risk that they can be embedded in the soft tissues, ingested, or aspirated</li> </ul>	<ul style="list-style-type: none"> <li>Baseline radiograph optional</li> <li>Take a radiograph of the soft tissues if the fractured fragment is suspected to be embedded in the lips, cheeks, or tongue</li> </ul>	<ul style="list-style-type: none"> <li>Cover all exposed dentin with glass ionomer or composite</li> <li>Lost tooth structure can be restored using composite immediately or at a later appointment</li> <li>Parent/patient education:               <ul style="list-style-type: none"> <li>Exercise care when eating not to further traumatize the injured tooth while encouraging a return to normal function as soon as possible</li> <li>Encourage gingival healing and prevent plaque accumulation by parents cleaning the affected area with a soft brush or cotton swab combined with an alcohol-free 0.1 to 0.2% chlorhexidine gluconate mouth rinse applied topically twice a day for 1 wk</li> </ul> </li> </ul>	<ul style="list-style-type: none"> <li>Clinical examination after 6-8 wk</li> <li>Radiographic follow up indicated only when clinical findings are suggestive of pathosis (eg, signs of pulp necrosis and infection)</li> <li>Parents should watch for any unfavorable outcomes. If seen, the child needs to return to the clinic as soon as possible. When unfavorable outcomes are identified, treatment is often required</li> <li>The follow-up treatment, which frequently requires the expertise of a child-oriented team, is outside the scope of these guidelines</li> </ul>	<ul style="list-style-type: none"> <li>Asymptomatic</li> <li>Pulp healing with:               <ul style="list-style-type: none"> <li>Normal color of the remaining crown</li> <li>No signs of pulp necrosis and infection</li> <li>Continued root development in immature teeth</li> </ul> </li> </ul>	<ul style="list-style-type: none"> <li>Symptomatic</li> <li>Crown discoloration</li> <li>Signs of pulp necrosis and infection—such as:               <ul style="list-style-type: none"> <li>Sinus tract, gingival swelling, abscess, or increased mobility</li> <li>Persistent dark gray discoloration with one or more other signs of root canal infection</li> <li>Radiographic signs of pulp necrosis and infection</li> </ul> </li> <li>No further root development of immature teeth</li> </ul>

## DISCLAIMER

THIS IS COPYRIGHTED CONTENT. Unauthorized use, including screenshots, copying, misuse, reuse, or resale of any content from this app, is strictly prohibited. Our app monitors and records all screenshots and recordings. Violators will face strict legal action.

DISCLAIMER  
THIS IS COPYRIGHTED CONTENT. Unauthorized use, including screenshots, copying, misuse, reuse, or resale of any content from this app, is strictly prohibited. Our app monitors and records all screenshots and recordings. Violators will face strict legal action.

THIS IS COPYRIGHTED CONTENT. Unauthorized use, including screenshots, copying, misuse, reuse, or resale of any content from this app, is strictly prohibited. Our app monitors and records all screenshots and recordings. Violators will face strict legal action.

DISCLAIMER

# TRAUMA GUIDELINES


## Classification:

### A) Fractures of primary and permanent teeth.

It can be further divided into:

### 3) Uncomplicated Crown Fracture involving Enamel and Dentin

#### b) For permanent teeth:

Uncomplicated crown fracture (enamel-dentin fracture)	Clinical findings	Imaging, radiographic assessment, and findings	Treatment	Follow up	Favorable outcomes	Unfavorable outcomes
 <p>A fracture confined to enamel and dentin without pulp exposure</p>	<ul style="list-style-type: none"> <li>Normal mobility</li> <li>Pulp sensibility tests usually positive</li> <li>No sensitivity to percussion or palpation</li> <li>Evaluate the tooth for a possible associated luxation injury or root fracture, especially if tenderness is present</li> </ul>	<ul style="list-style-type: none"> <li>Enamel-dentin loss is visible.</li> <li>Missing fragments should be accounted for: <ul style="list-style-type: none"> <li>If fragment is missing and there are soft tissue injuries, radiographs of the lip and/or cheek are indicated to search for tooth fragments and/or foreign materials</li> </ul> </li> <li>Recommended radiographs: <ul style="list-style-type: none"> <li>One parallel periapical radiograph</li> <li>Additional radiographs are indicated if signs or symptoms of other potential injuries are present</li> </ul> </li> </ul>	<ul style="list-style-type: none"> <li>If the tooth fragment is available and intact, it can be bonded back on to the tooth. The fragment should be rehydrated by soaking in water or saline for 20 min before bonding</li> <li>Cover the exposed dentin with glass-ionomer or use a bonding agent and composite resin</li> <li>If the exposed dentin is within 0.5 mm of the pulp (pink but no bleeding), place a calcium hydroxide lining and cover with a material such as glass-ionomer</li> </ul>	<p>Clinical and radiographic evaluations are necessary:</p> <ul style="list-style-type: none"> <li>after 6-8 wk</li> <li>after 1 y</li> <li>If there is an associated luxation, root fracture or the suspicion of an associated luxation injury, the luxation follow-up regimen prevails and should be used. Longer follow ups will be needed</li> </ul>	<ul style="list-style-type: none"> <li>Asymptomatic</li> <li>Positive response to pulp sensibility testing</li> <li>Good quality restoration</li> <li>Continued root development in immature teeth</li> </ul>	<ul style="list-style-type: none"> <li>Symptomatic</li> <li>Pulp necrosis and infection</li> <li>Apical periodontitis</li> <li>Lack of further root development in immature teeth</li> <li>Loss of restoration</li> <li>Breakdown of the restoration</li> </ul>

### 4) Complicated Crown Fractures:

#### a) For primary teeth:

Complicated crown fracture (i.e. with exposed pulp)	Radiographic recommendations	Treatment	Follow up	Favorable and unfavorable outcomes include some, but not necessarily all, of the following	
				Favorable outcome	Unfavorable outcome
 <p>Clinical findings: Fracture involves enamel and dentin plus the pulp is exposed. The location of missing tooth fragments should be explored during the trauma history and examination, especially when the accident was not witnessed by an adult or there was a loss of consciousness Note: While fragments are most often lost out of the mouth, there is a risk that they can be embedded in the soft tissues, ingested, or aspirated</p>	<ul style="list-style-type: none"> <li>A periapical radiograph (using a size 0 sensor/film and the paralleling technique) or an occlusal radiograph (with a size 2 sensor/film) should be taken at the time of initial presentation for diagnostic purposes and to establish a baseline</li> <li>Take a radiograph of the soft tissues if the fractured fragment is suspected to be embedded in the lips, cheeks, or tongue</li> </ul>	<ul style="list-style-type: none"> <li>Preserve the pulp by partial pulpotomy. Local anesthesia will be required. A non-setting calcium hydroxide paste should be applied over the pulp and cover this with a glass ionomer cement and then a composite resin. Cervical pulpotomy is indicated for teeth with large pulp exposures. The evidence for using other biomaterials such as non-staining calcium silicate-based cements is emerging. Clinicians should focus on appropriate case selection rather than the material used</li> <li>Treatment depends on the child's maturity and ability to tolerate procedures. Therefore, discuss different treatment options (including pulpotomy) with the parents. Each option is invasive and has the potential to cause long-term dental anxiety. Treatment is best performed by a child-oriented team with experience and expertise in the management of pediatric dental injuries. Often no treatment may be the most appropriate option in the emergency situation, but only when there is the potential for rapid referral (within several days) to the child-oriented team</li> <li>Parent/patient education: <ul style="list-style-type: none"> <li>Exercise care when eating not to further traumatize the injured tooth while encouraging a return to normal function as soon as possible.</li> <li>To encourage gingival healing and prevent plaque accumulation, parents should clean the affected area with a soft brush or cotton swab combined with an alcohol-free 0.1 to 0.2% chlorhexidine gluconate mouth rinse applied topically twice a day for 1 wk</li> </ul> </li> </ul>	<ul style="list-style-type: none"> <li>Clinical examination after: <ul style="list-style-type: none"> <li>1 wk</li> <li>6-8 wk</li> <li>1 y</li> </ul> </li> <li>Radiographic follow up at 1 y following pulpotomy or root canal treatment. Other radiographs are only indicated where clinical findings are suggestive of pathosis (eg. an unfavorable outcome)</li> <li>Parents should watch for any unfavorable outcomes. If seen, the child needs to return to the clinic as soon as possible. Where unfavorable outcomes are identified, treatment is often required.</li> <li>The follow-up treatment, which frequently requires the expertise of a child-oriented team, is outside the scope of these guidelines</li> </ul>	<ul style="list-style-type: none"> <li>Asymptomatic</li> <li>Pulp healing with: <ul style="list-style-type: none"> <li>Normal color of the remaining crown</li> <li>No signs of pulp necrosis and infection</li> <li>Continued root development in immature teeth</li> </ul> </li> </ul>	<ul style="list-style-type: none"> <li>Symptomatic</li> <li>Crown discoloration</li> <li>Signs of pulp necrosis and infection—such as: <ul style="list-style-type: none"> <li>Sinus tract, gingival swelling, abscess, or increased mobility</li> <li>Persistent dark gray discoloration with one or more signs of root canal infection</li> <li>Radiographic signs of pulp necrosis and infection</li> </ul> </li> <li>No further root development of immature teeth</li> </ul>

## DISCLAIMER

THIS IS COPYRIGHTED CONTENT. Unauthorized use, including screenshots, copying, misuse, reuse, or resale of any content from this app, is strictly prohibited. Our app monitors and records all screenshots and recordings. Violators will face strict legal action.

## DISCLAIMER

THIS IS COPYRIGHTED CONTENT. Unauthorized use, including screenshots, copying, misuse, reuse, or resale of any content from this app, is strictly prohibited. Our app monitors and records all screenshots and recordings. Violators will face strict legal action.

THIS IS COPYRIGHTED CONTENT. Unauthorized use, including screenshots, copying, misuse, reuse, or resale of any content from this app, is strictly prohibited. Our app monitors and records all screenshots and recordings. Violators will face strict legal action.

## DISCLAIMER



# TRAUMA GUIDELINES


## Classification:

### A) Fractures of primary and permanent teeth.

It can be further divided into:


### 4) Complicated Crown Fractures:

#### b) For permanent teeth:

Complicated crown fracture (enamel-dentin fracture with pulp exposure)	Clinical findings	Imaging, radiographic assessment, and findings	Treatment	Follow up	Favorable outcomes	Unfavorable outcomes
 <p>A fracture confined to enamel and dentin with pulp exposure</p>	<ul style="list-style-type: none"> <li>Normal mobility</li> <li>No sensitivity to percussion or palpation.</li> <li>Evaluate the tooth for a possible associated luxation injury or root fracture, especially if tenderness is present</li> <li>Exposed pulp is sensitive to stimuli (eg. air, cold, sweets)</li> </ul>	<ul style="list-style-type: none"> <li>Enamel-dentin loss is visible</li> <li>Missing fragments should be accounted for: <ul style="list-style-type: none"> <li>If fragment is missing and there are soft tissue injuries, radiographs of the lip and/or cheek are indicated to search for tooth fragments and/or foreign debris</li> </ul> </li> <li>Recommended radiographs: <ul style="list-style-type: none"> <li>One parallel periapical radiograph</li> <li>Additional radiographs are indicated if signs or symptoms of other potential injuries are present</li> </ul> </li> </ul>	<ul style="list-style-type: none"> <li>In patients where teeth have immature roots and open apices, it is very important to preserve the pulp. Partial pulpotomy or pulp capping are recommended in order to promote further root development</li> <li>Conservative pulp treatment (eg. partial pulpotomy) is also the preferred treatment in teeth with completed root development</li> <li>Non-setting calcium hydroxide or non-staining calcium silicate cements are suitable materials to be placed on the pulp wound</li> <li>If a post is required for crown retention in a mature tooth with complete root formation, root canal treatment is the preferred treatment</li> <li>If the tooth fragment is available, it can be bonded back on to the tooth after rehydration and the exposed pulp is treated</li> <li>In the absence of an intact crown fragment for bonding, cover the exposed dentin with glass-ionomer or use a bonding agent and composite resin</li> </ul>	<ul style="list-style-type: none"> <li>Clinical and radiographic evaluations are necessary: <ul style="list-style-type: none"> <li>after 6-8 wk</li> <li>after 3 mo</li> <li>after 6 mo</li> <li>after 1 y</li> </ul> </li> <li>If there is an associated luxation, root fracture or the suspicion of an associated luxation injury, the luxation follow-up regimen prevails and should be used. Longer follow ups will be needed</li> </ul>	<ul style="list-style-type: none"> <li>Asymptomatic</li> <li>Positive response to pulp sensibility testing</li> <li>Good quality restoration</li> <li>Continued root development in immature teeth</li> </ul>	<ul style="list-style-type: none"> <li>Symptomatic</li> <li>Discoloration</li> <li>Pulp necrosis and infection</li> <li>Apical periodontitis</li> <li>Lack of further root development in immature teeth</li> <li>Loss of restoration</li> <li>Breakdown of the restoration</li> </ul>

### 5) Crown-Root fractures:

#### a) For primary teeth:

Crown-root fracture	Radiographic recommendations	Treatment	Follow up	Favorable and unfavorable outcomes include some, but not necessarily all, of the following	
				Favorable outcome	Unfavorable outcome
 <p>Clinical findings: Fracture involves enamel, dentin, and root; the pulp may or may not be exposed (ie, complicated or uncomplicated)</p> <p>Additional findings may include loose, but still attached, fragments of tooth</p>	<ul style="list-style-type: none"> <li>A periapical radiograph (using a size 0 sensor/film and the paralleling technique) or an occlusal radiograph (with a size 2 sensor/film) should be taken at the time of initial presentation for diagnostic purposes and to establish a baseline</li> </ul>	<ul style="list-style-type: none"> <li>Often no treatment may be the most appropriate option in the emergency situation, but only when there is the potential for rapid referral (within several days) to a child-oriented team</li> <li>If treatment is considered at the emergency appointment, local anesthesia will be required</li> <li>Remove the loose fragment and determine if the crown can be restored</li> <li><b>Option A:</b> <ul style="list-style-type: none"> <li>If restorable and no pulp exposed, cover the exposed dentine with glass ionomer</li> <li>If restorable and the pulp is exposed, perform a pulpotomy (see crown fracture with exposed pulp) or root canal treatment, depending on the stage of root development and the level of the fracture.</li> </ul> </li> <li><b>Option B:</b> <ul style="list-style-type: none"> <li>If unrestorable, extract all loose fragments taking care not to damage the permanent successor tooth and leave any firm root fragment in situ, or extract the entire tooth</li> </ul> </li> <li>Treatment depends on the child's maturity and ability to tolerate the procedure. Therefore, discuss treatment options (including extraction) with the parents. Each option is invasive and has the potential to cause long-term dental anxiety. Treatment is best performed by a child-oriented team with experience and expertise in the management of pediatric dental injuries</li> <li>Parent/patient education: <ul style="list-style-type: none"> <li>Exercise care when eating not to further traumatize the injured tooth while encouraging a return to normal function as soon as possible</li> <li>To encourage gingival healing and prevent plaque accumulation, parents should clean the affected area with a soft brush or cotton swab combined with an alcohol-free 0.1% to 0.2% chlorhexidine gluconate mouth rinse applied topically twice a day for 1 wk</li> </ul> </li> </ul>	<ul style="list-style-type: none"> <li>Where tooth is retained, clinical examination after: <ul style="list-style-type: none"> <li>1 wk</li> <li>6-8 wk</li> <li>1 y</li> </ul> </li> <li>Radiographic follow up after 1 y following pulpotomy or root canal treatment. Other radiographs only indicated where clinical findings are suggestive of pathosis (eg. an unfavorable outcome)</li> <li>Parents should watch for any unfavorable outcomes. If seen, the child needs to return to the clinic as soon as possible. Where unfavorable outcomes are identified, treatment is often required</li> <li>The follow-up treatment, which frequently requires the expertise of a child-oriented team, is outside the scope of these guidelines</li> </ul>	<ul style="list-style-type: none"> <li>Asymptomatic</li> <li>Pulp healing with: <ul style="list-style-type: none"> <li>Normal color of the remaining crown</li> <li>No signs of pulp necrosis and infection</li> <li>Continued root development in immature teeth</li> </ul> </li> </ul>	<ul style="list-style-type: none"> <li>Symptomatic</li> <li>Crown discoloration</li> <li>Signs of pulp necrosis and infection—such as: <ul style="list-style-type: none"> <li>Sinus tract, gingival swelling, abscess, or increased mobility</li> <li>Persistent dark gray discoloration with one or more signs of root canal infection</li> <li>Radiographic signs of pulp necrosis and infection</li> </ul> </li> <li>No further root development of immature teeth</li> </ul>

## DISCLAIMER

THIS IS COPYRIGHTED CONTENT. Unauthorized use, including screenshots, copying, misuse, reuse, or resale of any content from this app, is strictly prohibited. Our app monitors and records all screenshots and recordings. Violators will face strict legal action.

THIS IS COPYRIGHTED CONTENT. Unauthorized use, including screenshots, copying, misuse, reuse, or resale of any content from this app, is strictly prohibited. Our app monitors and records all screenshots and recordings. Violators will face strict legal action.

DISCLAIMER

THIS IS COPYRIGHTED CONTENT. Unauthorized use, including screenshots, copying, misuse, reuse, or resale of any content from this app, is strictly prohibited. Our app monitors and records all screenshots and recordings. Violators will face strict legal action.

# TRAUMA GUIDELINES

## Classification:


### A) Fractures of primary and permanent teeth.

It can be further divided into:

#### 5) Crown-Root fractures:


##### b) For permanent teeth:

##### i. Uncomplicated Crown root fractures:

Uncomplicated crown-root fracture (crown-root fracture without pulp exposure)	Clinical findings	Imaging, radiographic assessment, and findings	Treatment	Follow up	Favorable outcomes	Unfavorable outcomes
 <p>A fracture involving enamel, dentin and cementum (Note: Crown-root fractures typically extend below the gingival margin)</p>	<ul style="list-style-type: none"> <li>Pulp sensibility tests usually positive</li> <li>Tender to percussion.</li> <li>Coronal, or mesial or distal, fragment is usually present and mobile</li> <li>The extent of the fracture (sub- or supra-alveolar) should be evaluated</li> </ul>	<ul style="list-style-type: none"> <li>Apical extension of fracture usually not visible</li> <li>Missing fragments should be accounted for: <ul style="list-style-type: none"> <li>If fragment is missing and there are soft tissue injuries, radiographs of the lip and/or cheek are indicated to search for tooth fragments or foreign debris</li> </ul> </li> <li>Recommended radiographs: <ul style="list-style-type: none"> <li>One parallel periapical radiograph</li> <li>Two additional radiographs of the tooth taken with different vertical and/or horizontal angulations</li> <li>Occlusal radiograph</li> </ul> </li> <li>CBCT can be considered for better visualization of the fracture path, its extent, and its relationship to the marginal bone; also, useful to evaluate the crown-root ratio and to help determine treatment options</li> </ul>	<ul style="list-style-type: none"> <li>Until a treatment plan is finalized, temporary stabilization of the loose fragment to the adjacent tooth/teeth or to the non-mobile fragment should be attempted</li> <li>If the pulp is not exposed, removal of the coronal or mobile fragment and subsequent restoration should be considered</li> <li>Cover the exposed dentin with glass-ionomer or use a bonding agent and composite resin</li> </ul> <p>Future Treatment Options:</p> <ul style="list-style-type: none"> <li>The treatment plan is dependent, in part, on the patient's age and anticipated co-operation. Options include: <ul style="list-style-type: none"> <li>Orthodontic extrusion of the apical or non-mobile fragment, followed by restoration (may also need periodontal re-contouring surgery after extrusion)</li> <li>Surgical extrusion</li> <li>Root canal treatment and restoration if the pulp becomes necrotic and infected</li> <li>Root submergence</li> <li>Intentional replantation with or without rotation of the root</li> <li>Extraction</li> <li>Autotransplantation</li> </ul> </li> </ul>	<p>Clinical and radiographic evaluations are necessary:</p> <ul style="list-style-type: none"> <li>after 1 wk</li> <li>after 6-8 wk</li> <li>after 3 mo</li> <li>after 6 mo</li> <li>after 1 y</li> <li>then yearly for at least 5 ys</li> </ul>	<ul style="list-style-type: none"> <li>Asymptomatic</li> <li>Positive response to pulp sensibility testing</li> <li>Continued root development in immature teeth</li> <li>Good quality restoration</li> </ul>	<ul style="list-style-type: none"> <li>Symptomatic</li> <li>Discoloration</li> <li>Pulp necrosis and infection</li> <li>Apical periodontitis</li> <li>Lack of further root development in immature teeth</li> <li>Loss of restoration</li> <li>Breakdown of the restoration</li> <li>Marginal bone loss and periodontal inflammation</li> </ul>

strict legal action.

##### ii. Complicated Crown root fractures:

Complicated crown-root fracture (crown-root fracture with pulp exposure)	Clinical findings	Imaging, radiographic assessment, and findings	Treatment	Follow up	Favorable outcomes	Unfavorable outcomes
 <p>A fracture involving enamel, dentin, cementum and the pulp (Note: Crown-root fractures typically extend below the gingival margin)</p>	<ul style="list-style-type: none"> <li>Pulp sensibility tests usually positive</li> <li>Tender to percussion.</li> <li>Coronal, or mesial or distal, fragment is usually present and mobile</li> <li>The extent of the fracture (sub- or supra-alveolar) should be evaluated</li> </ul>	<ul style="list-style-type: none"> <li>Apical extension of fracture usually not visible</li> <li>Missing fragments should be accounted for: <ul style="list-style-type: none"> <li>If fragment is missing and there are soft tissue injuries, radiographs of the lip and/or cheek are indicated to search for tooth fragments or foreign debris</li> </ul> </li> <li>Recommended radiographs: <ul style="list-style-type: none"> <li>One parallel periapical radiograph</li> <li>Two additional radiographs of the tooth taken with different vertical and/or horizontal angulations</li> <li>Occlusal radiograph</li> </ul> </li> <li>CBCT can be considered for better visualization of the fracture path, its extent, and its relationship to the marginal bone; also useful to evaluate the crown-root ratio and to help determine treatment options</li> </ul>	<ul style="list-style-type: none"> <li>Until a treatment plan is finalized, temporary stabilization of the loose fragment to the adjacent tooth/teeth or to the non-mobile fragment should be attempted</li> <li>In immature teeth with incomplete root formation, it is advantageous to preserve the pulp by performing a partial pulpotomy. Rubber dam isolation is challenging but should be tried. <ul style="list-style-type: none"> <li>Non-setting calcium hydroxide or non-staining calcium silicate cements are suitable materials to be placed on the pulp wound</li> </ul> </li> <li>In mature teeth with complete root formation, removal of the pulp is usually indicated <ul style="list-style-type: none"> <li>Cover the exposed dentin with glass-ionomer or use a bonding agent and composite resin</li> </ul> </li> </ul> <p>Future Treatment Options:</p> <ul style="list-style-type: none"> <li>The treatment plan is dependent, in part, on the patient's age and anticipated co-operation. Options include: <ul style="list-style-type: none"> <li>Completion of root canal treatment and restoration</li> <li>Orthodontic extrusion of the apical segment (may also need periodontal re-contouring surgery after extrusion)</li> <li>Surgical extrusion</li> <li>Root submergence</li> <li>Intentional replantation with or without rotation of the root</li> <li>Extraction</li> <li>Autotransplantation</li> </ul> </li> </ul>	<p>Clinical and radiographic evaluations are necessary:</p> <ul style="list-style-type: none"> <li>after 1 wk</li> <li>after 6-8 wk</li> <li>after 3 mo</li> <li>after 6 mo</li> <li>after 1 y</li> <li>then yearly for at least 5 y</li> </ul>	<ul style="list-style-type: none"> <li>Asymptomatic</li> <li>Continued root development in immature teeth</li> <li>Good quality restoration</li> </ul>	<ul style="list-style-type: none"> <li>Symptomatic</li> <li>Pulp necrosis and infection</li> <li>Apical periodontitis</li> <li>Lack of further root development in immature teeth</li> <li>Loss of restoration</li> <li>Breakdown of the restoration</li> <li>Marginal bone loss and periodontal inflammation</li> </ul>

## DISCLAIMER

THIS IS COPYRIGHTED CONTENT. Unauthorized use, including screenshots, copying, misuse, reuse, or resale of any content from this app, is strictly prohibited. Our app monitors and records all screenshots and recordings. Violators will face strict legal action.

DISCLAIMER  
THIS IS COPYRIGHTED CONTENT. Unauthorized use, including screenshots, copying, misuse, reuse, or resale of any content from this app, is strictly prohibited. Our app monitors and records all screenshots and recordings. Violators will face strict legal action.

THIS IS COPYRIGHTED CONTENT. Unauthorized use, including screenshots, copying, misuse, reuse, or resale of any content from this app, is strictly prohibited. Our app monitors and records all screenshots and recordings. Violators will face strict legal action.

DISCLAIMER



# TRAUMA GUIDELINES


## Classification:

### A) Fractures of primary and permanent teeth.

It can be further divided into:

#### 6) Root fractures:

##### a) For primary teeth:

Root fracture	Radiographic recommendations and findings	Treatment	Follow up	Favorable and unfavorable outcomes include some, but not necessarily all, of the following	
				Favorable outcome	Unfavorable outcome
 <p>Clinical findings: Depends on the location of fracture</p> <ul style="list-style-type: none"> <li>The coronal fragment may be mobile and may be displaced</li> <li>Occlusal interference may be present</li> </ul>	<ul style="list-style-type: none"> <li>A periapical (size 0 sensor/film, paralleling technique) or occlusal radiograph (size 2 sensor/film) should be taken at the time of initial presentation for diagnostic purposes and to establish a baseline</li> <li>The fracture is usually located mid-root or in the apical third</li> </ul>	<ul style="list-style-type: none"> <li>If the coronal fragment is not displaced, no treatment is required</li> <li>If the coronal fragment is displaced and is not excessively mobile, leave the coronal fragment to spontaneously reposition even if there is some occlusal interference</li> <li>If the coronal fragment is displaced, excessively mobile and interfering with occlusion, two options are available, both of which require local anesthesia</li> <li><b>Option A:</b> <ul style="list-style-type: none"> <li>Extract only the loose coronal fragment. The apical fragment should be left in place to be resorbed</li> </ul> </li> <li><b>Option B:</b> <ul style="list-style-type: none"> <li>Gently reposition the loose coronal fragment. If the fragment is unstable in its new position, stabilize the fragment with a flexible splint attached to the adjacent uninjured teeth. Leave the splint in place for 4 wk</li> </ul> </li> <li>The treatment depends on the child's maturity and ability to tolerate the procedure. Therefore, discuss treatment options with the parents. Each option is invasive and has the potential to cause long-term dental anxiety. Treatment is best performed by a child-oriented team with experience and expertise in the management of pediatric dental injuries. Often no treatment may be the most appropriate option in the emergency scenario, but only when there is the potential for rapid referral (within several days) to the child-oriented team</li> <li>Parent/patient education:           <ul style="list-style-type: none"> <li>Exercise care when eating not to further traumatize the injured tooth while encouraging a return to normal function as soon as possible</li> <li>To encourage gingival healing and prevent plaque accumulation, parents should clean the affected area with a soft brush or cotton swab combined with an alcohol-free 0.1%-0.2% chlorhexidine gluconate mouth rinse applied topically twice a day for 1 wk</li> </ul> </li> </ul>	<ul style="list-style-type: none"> <li>Where no displacement of coronal fragment, clinical examination after:           <ul style="list-style-type: none"> <li>1 wk</li> <li>6-8 wk</li> <li>1 y and where there are clinical concerns that an unfavorable outcome is likely.</li> </ul> </li> <li>Then continue clinical follow up each year until eruption of permanent teeth</li> <li>If coronal fragment has been repositioned and splinted, clinical examination after:           <ul style="list-style-type: none"> <li>1 wk</li> <li>4 wk for splint removal</li> <li>8 wk</li> <li>1 y</li> </ul> </li> <li>If coronal fragment has been extracted, clinical examination after 1 y</li> <li>Where there are concerns that an unfavorable outcome is likely, then continue clinical follow up each year until eruption of permanent teeth</li> <li>Radiographic follow up only indicated where clinical findings are suggestive of pathosis (eg, an unfavorable outcome)</li> <li>Parents should be informed to watch for any unfavorable outcomes and the need to return to the clinic as soon as possible. Where unfavorable outcomes are identified, treatment is often required.</li> <li>The follow-up treatment, which frequently requires the expertise of a child-oriented team, is outside the scope of these guidelines</li> </ul>	<ul style="list-style-type: none"> <li>Asymptomatic</li> <li>Pulp healing with:           <ul style="list-style-type: none"> <li>Normal color of the crown or transient red/gray or yellow discoloration and pulp canal obliteration</li> <li>No signs of pulp necrosis and infection</li> <li>Continued root development in immature teeth</li> </ul> </li> <li>Realignment of the root-fractured tooth</li> <li>No mobility</li> <li>Resorption of the apical fragment</li> </ul>	<ul style="list-style-type: none"> <li>Symptomatic</li> <li>Signs of pulp necrosis and infection—such as:           <ul style="list-style-type: none"> <li>Sinus tract, gingival swelling, abscess, or increased mobility</li> <li>Persistent dark gray discoloration with one or more signs of root canal infection</li> <li>Radiographic signs of pulp necrosis and infection</li> <li>Radiographic signs of infection-related (inflammatory) resorption</li> </ul> </li> <li>No further root development of immature teeth</li> <li>No improvement in the position of the root-fractured tooth</li> </ul>

##### b) For permanent teeth:

Root fracture	Clinical findings	Imaging, radiographic assessment, and findings	Treatment	Follow up	Favorable outcomes	Unfavorable outcomes
 <p>A fracture of the root involving dentin, pulp and cementum. The fracture may be horizontal, oblique or a combination of both.</p>	<ul style="list-style-type: none"> <li>The coronal segment may be mobile and may be displaced</li> <li>The tooth may be tender to percussion</li> <li>Bleeding from the gingival sulcus may be seen</li> <li>Pulp sensibility testing may be negative initially, indicating transient or permanent neural damage</li> </ul>	<ul style="list-style-type: none"> <li>The fracture may be located at any level of the root</li> <li>Recommended radiographs:           <ul style="list-style-type: none"> <li>One parallel periapical radiograph</li> <li>Two additional radiographs of the tooth taken with different vertical and/or horizontal angulations</li> <li>Occlusal radiograph</li> </ul> </li> <li>Root fractures may be undetected without additional imaging</li> <li>In cases where the above radiographs provide insufficient information for treatment planning, CBCT can be considered to determine the location, extent and direction of the fracture</li> </ul>	<ul style="list-style-type: none"> <li>If displaced, the coronal fragment should be repositioned as soon as possible.</li> <li>Check repositioning radiographically</li> <li>Stabilize the mobile coronal segment with a passive and flexible splint for 4 wk. If the fracture is located cervically, stabilization for a longer period of time (up to 4 mo) may be needed</li> <li>Cervical fractures have the potential to heal. Thus, the coronal fragment, especially if not mobile, should not be removed at the emergency visit</li> <li>No endodontic treatment should be started at the emergency visit</li> <li>It is advisable to monitor healing of the fracture for at least one year. Pulp status should also be monitored</li> <li>Pulp necrosis and infection may develop later. It usually occurs in the coronal fragment only. Hence, endodontic treatment of the coronal segment only will be indicated. As root fracture lines are frequently oblique, determination of root canal length may be challenging. An apexification approach may be needed. The apical segment rarely undergoes pathological changes that require treatment</li> <li>In mature teeth where the cervical fracture line is located above the alveolar crest and the coronal fragment is very mobile, removal of the coronal fragment, followed by root canal treatment and restoration with a post-retained crown will likely be required. Additional procedures such as orthodontic extrusion of the apical segment, crown lengthening surgery, surgical extrusion or even extraction may be required as future treatment options (similar to those for crown-root fractures outlined above).</li> </ul>	<p>Clinical and radiographic evaluations are necessary:</p> <ul style="list-style-type: none"> <li>after 4 wk S*</li> <li>after 6-8 wk</li> <li>after 4 mo S**</li> <li>after 6 mo</li> <li>after 1 y</li> <li>then yearly for at least 5 y</li> </ul>	<ul style="list-style-type: none"> <li>Positive response to pulp sensibility testing; however, a false negative response is possible for several months. Endodontic treatment should not be started solely on the basis of no response to pulp sensibility testing</li> <li>Signs of repair between the fractured segments</li> <li>Normal or slightly more than physiological mobility of the coronal fragment</li> </ul>	<ul style="list-style-type: none"> <li>Symptomatic</li> <li>Extrusion and/or excessive mobility of the coronal segment</li> <li>Radiolucency at the fracture line</li> <li>Pulp necrosis and infection with inflammation in the fracture line</li> </ul>

Note: S\* = splint removal (for mid-root and apical third fractures); S\*\* = splint removal (for cervical third fractures).

## DISCLAIMER

THIS IS COPYRIGHTED CONTENT. Unauthorized use, including screenshots, copying, misuse, reuse, or resale of any content from this app, is strictly prohibited. Our app monitors and records all screenshots and recordings. Violators will face strict legal action.

## DISCLAIMER

THIS IS COPYRIGHTED CONTENT. Unauthorized use, including screenshots, copying, misuse, reuse, or resale of any content from this app, is strictly prohibited. Our app monitors and records all screenshots and recordings. Violators will face strict legal action.

THIS IS COPYRIGHTED CONTENT. Unauthorized use, including screenshots, copying, misuse, reuse, or resale of any content from this app, is strictly prohibited. Our app monitors and records all screenshots and recordings. Violators will face strict legal action.

## DISCLAIMER

# TRAUMA GUIDELINES


## Classification:

### A) Fractures of primary and permanent teeth.


It can be further divided into:

#### 7) Alveolar Fractures:

##### a) For primary teeth:

Alveolar fracture	Radiographic recommendations and findings	Treatment	Follow up	Favorable and unfavorable outcomes include some, but not necessarily all, of the following	
				Favorable outcome	Unfavorable outcome
 <p>Clinical findings: The fracture involves the alveolar bone (labial and palatal/lingual) and may extend to the adjacent bone.</p> <ul style="list-style-type: none"> <li>Mobility and dislocation of the segment with several teeth moving together are common findings.</li> <li>Occlusal interference is usually present.</li> </ul>	<ul style="list-style-type: none"> <li>A periapical (size 0 sensor/film, paralleling technique) or occlusal radiograph (size 2 sensor/film) should be taken at the time of initial presentation for diagnostic purposes and to establish a baseline.</li> <li>A lateral radiograph may give information about the relationship between the maxillary and mandibular dentitions and if the segment is displaced in a labial direction.</li> <li>Fracture lines may be located at any level, from the marginal bone to the root apex or beyond, and they may involve the primary teeth and/or their permanent successors.</li> <li>Further imaging may be needed to visualize the extent of the fracture(s) but only where it is likely to change the treatment provided.</li> </ul>	<ul style="list-style-type: none"> <li>Reposition (under local anesthesia) any displaced segment which is mobile and/or causing occlusal interference.</li> <li>Stabilize with a flexible splint to the adjacent uninjured teeth for 4 wk.</li> <li>Treatment should be performed by a child-oriented team with experience and expertise in the management of pediatric dental injuries.</li> <li>Parent/patient education: <ul style="list-style-type: none"> <li>Exercise care when eating not to further traumatize the injured teeth while encouraging a return to normal function as soon as possible.</li> <li>To encourage gingival healing and prevent plaque accumulation, parents should clean the affected area with a soft brush or cotton swab combined with an alcohol-free 0.1%-0.2% chlorhexidine gluconate mouth rinse applied topically twice a day for 1 wk.</li> </ul> </li> </ul>	<ul style="list-style-type: none"> <li>Clinical examination after: <ul style="list-style-type: none"> <li>1 wk</li> <li>4 wk for splint removal</li> <li>8 wk</li> <li>1 y</li> </ul> </li> <li>Further follow up at 6 y of age is indicated to monitor eruption of the permanent teeth.</li> <li>Radiographic follow up at 4 w and 1 y to assess impact on the primary tooth and the permanent tooth germs in the line of the alveolar fracture. This radiograph may indicate a more frequent follow-up regimen is needed. Other radiographs are indicated only where clinical findings are suggestive of pathosis (eg, an unfavorable outcome).</li> <li>If the fracture line is located at the level of the primary root apex, an abscess can develop. A periapical radiolucency can be seen on the radiograph.</li> <li>Parents should be informed to watch for any unfavorable outcomes and the need to return to the clinic as soon as possible. Where unfavorable outcomes are identified, treatment is often required.</li> <li>The follow-up treatment, which frequently requires the expertise of a child-oriented team, is outside the scope of these guidelines.</li> </ul>	<ul style="list-style-type: none"> <li>Asymptomatic</li> <li>Pulp healing with: <ul style="list-style-type: none"> <li>Normal crown color or transient red/gray or yellow discoloration and pulp canal obliteration</li> <li>No signs of pulp necrosis and infection</li> <li>Continued root development in immature teeth</li> </ul> </li> <li>Periodontal healing</li> <li>Realignment of the alveolar segment with the original occlusion restored</li> <li>No disturbance to the development and/or eruption of the permanent successor</li> </ul>	<ul style="list-style-type: none"> <li>Symptomatic</li> <li>Signs of pulp necrosis and infection—such as: <ul style="list-style-type: none"> <li>Sinus tract, gingival swelling, abscess, or increased mobility</li> <li>Persistent dark gray discoloration plus one or more signs of root canal infection</li> </ul> </li> <li>Radiographic signs of pulp necrosis and infection including infection-related (inflammatory) resorption</li> <li>No further root development in immature teeth</li> <li>Limited or no improvement in the position of the displaced segment and the original occlusion is not re-established</li> <li>Negative impact on the development and/or eruption of the permanent successor</li> </ul>

##### b) For permanent teeth:

Alveolar fracture	Clinical Findings	Imaging, radiographic assessment, and findings	Treatment	Follow Up	Favorable outcomes	Unfavorable outcomes
 <p>The fracture involves the alveolar bone and may extend to adjacent bones.</p>	<ul style="list-style-type: none"> <li>The alveolar fracture is complete and extends all the way from the buccal to the lingual bone in the maxilla and from the buccal to the lingual bony surface in the mandible.</li> <li>Segment mobility and displacement with several teeth moving together are common findings.</li> <li>Occlusal disturbances due to displacement and misalignment of the fractured alveolar segment are often seen.</li> <li>Teeth in the fractured segment may not respond to pulp sensibility testing.</li> </ul>	<ul style="list-style-type: none"> <li>Fracture lines may be located at any level, from the marginal bone to the root apex.</li> <li>Recommended radiographs: <ul style="list-style-type: none"> <li>One parallel periapical radiograph</li> <li>Two additional radiographs of the tooth taken with different vertical and/or horizontal angulations</li> </ul> </li> <li>In cases where the above radiographs provide insufficient information for treatment planning, a panoramic radiograph and/or CBCT can be considered to determine the location, extent and direction of the fracture.</li> </ul>	<ul style="list-style-type: none"> <li>Reposition any displaced segment</li> <li>Stabilize the segment by splinting the teeth with a passive and flexible splint for 4 wk</li> <li>Suture gingival lacerations if present</li> <li>Root canal treatment is contraindicated at the emergency visit</li> <li>Monitor the pulp condition of all teeth involved, both initially and at follow ups, to determine if or when endodontic treatment becomes necessary</li> </ul>	<p>Clinical and radiographic evaluations are necessary:</p> <ul style="list-style-type: none"> <li>after 4 wk S*</li> <li>after 6-8 wk</li> <li>after 4 mo</li> <li>after 6 mo</li> <li>after 1 y</li> <li>then yearly for at least 5 y</li> </ul> <p>Bone and soft tissue healing must also be monitored</p>	<ul style="list-style-type: none"> <li>Positive response to pulp sensibility testing (a false negative response is possible for several months)</li> <li>No signs of pulp necrosis and infection</li> <li>Soft tissue healing</li> <li>Radiographic signs of bone repair</li> <li>Slight tenderness of the bone to palpation may remain at the fracture line and/or on mastication for several months</li> </ul>	<ul style="list-style-type: none"> <li>Symptomatic</li> <li>Pulp necrosis and infection</li> <li>Apical periodontitis</li> <li>Inadequate soft tissue healing</li> <li>Non-healing of the bone fracture</li> <li>External inflammatory (infection-related) resorption</li> </ul>

Note: S\* = splint removal.

## DISCLAIMER

THIS IS COPYRIGHTED CONTENT. Unauthorized use, including screenshots, copying, misuse, reuse, or resale of any content from this app, is strictly prohibited. Our app monitors and records all screenshots and recordings. Violators will face strict legal action.

DISCLAIMER  
THIS IS COPYRIGHTED CONTENT. Unauthorized use, including screenshots, copying, misuse, reuse, or resale of any content from this app, is strictly prohibited. Our app monitors and records all screenshots and recordings. Violators will face strict legal action.

THIS IS COPYRIGHTED CONTENT. Unauthorized use, including screenshots, copying, misuse, reuse, or resale of any content from this app, is strictly prohibited. Our app monitors and records all screenshots and recordings. Violators will face strict legal action.

DISCLAIMER



# TRAUMA GUIDELINES


## Classification:

### B) Luxative Injuries:


It can be further divided into:

#### 1) Concussion:

##### a) For primary teeth:


Concussion	Radiographic recommendations	Treatment	Follow up	Favorable and unfavorable outcomes include some, but not necessarily all, of the following	
				Favorable outcome	Unfavorable outcome
 <p>Clinical findings: The tooth is tender to touch but it has not been displaced</p> <ul style="list-style-type: none"> <li>It has normal mobility and no sulcular bleeding</li> </ul>	<ul style="list-style-type: none"> <li>No baseline radiograph recommended</li> </ul>	<ul style="list-style-type: none"> <li>No treatment is needed.</li> <li>Observation</li> <li>Parent/patient education: <ul style="list-style-type: none"> <li>Exercise care when eating not to further traumatize the injured tooth while encouraging a return to normal function as soon as possible</li> <li>To encourage gingival healing and prevent plaque accumulation, parents should clean the affected area with a soft brush or cotton swab combined with an alcohol-free 0.1%-0.2% chlorhexidine gluconate mouth rinse applied topically twice a day for 1 wk</li> </ul> </li> </ul>	<ul style="list-style-type: none"> <li>Clinical examination after: <ul style="list-style-type: none"> <li>1 wk</li> <li>6-8 wk</li> </ul> </li> <li>Radiographic follow up only indicated where clinical findings are suggestive of pathosis (eg, an unfavorable outcome)</li> <li>Parents should be informed to watch for any unfavorable outcomes and the need to return to the clinic as soon as possible. Where unfavorable outcomes are identified, treatment is often required</li> <li>The follow-up treatment, which frequently requires the expertise of a child-oriented team, is outside the scope of these guidelines</li> </ul>	<ul style="list-style-type: none"> <li>Asymptomatic</li> <li>Pulp healing with: <ul style="list-style-type: none"> <li>Normal color of the crown or transient red/gray or yellow discoloration and pulp canal obliteration</li> <li>No signs of pulp necrosis and infection</li> </ul> </li> <li>Continued root development in immature teeth</li> <li>No disturbance to the development and/or eruption of the permanent successor</li> </ul>	<ul style="list-style-type: none"> <li>Symptomatic</li> <li>Signs of pulp necrosis and infection—such as: <ul style="list-style-type: none"> <li>Sinus tract, gingival swelling, abscess, or increased mobility</li> <li>Persistent dark gray discoloration plus one or more other signs of root canal infection</li> </ul> </li> <li>Radiographic signs of pulp necrosis and infection</li> <li>No further root development of immature teeth</li> <li>Negative impact on the development and/or eruption of the permanent successor</li> </ul>

##### b) For permanent teeth:

Concussion	Clinical findings	Imaging, radiographic assessment, and findings	Treatment	Follow up	Favorable outcome	Unfavorable outcome
	<ul style="list-style-type: none"> <li>Normal mobility</li> <li>The tooth is tender to percussion and touch</li> <li>The tooth will likely respond to pulp sensibility testing</li> </ul>	<ul style="list-style-type: none"> <li>No radiographic abnormalities</li> <li>Recommended radiographs: <ul style="list-style-type: none"> <li>One parallel periapical radiograph</li> <li>Additional radiographs are indicated if signs or symptoms of other potential injuries are present</li> </ul> </li> </ul>	<ul style="list-style-type: none"> <li>No treatment is needed.</li> <li>Monitor pulp condition for at least one year, but preferably longer</li> </ul>	<p>Clinical and radiographic evaluations are necessary:</p> <ul style="list-style-type: none"> <li>after 4 wk</li> <li>after 1 y</li> </ul>	<ul style="list-style-type: none"> <li>Asymptomatic</li> <li>Positive response to pulp sensibility testing; however, a false negative response is possible for several months. Endodontic treatment should not be started solely on the basis of no response to pulp sensibility testing</li> <li>Continued root development in immature teeth</li> </ul>	<ul style="list-style-type: none"> <li>Symptomatic</li> <li>Pulp necrosis and infection</li> <li>Apical periodontitis</li> <li>No further root development in immature teeth</li> </ul>

#### 2) Subluxation:

##### a) For primary teeth:

Subluxation	Radiographic recommendations and findings	Treatment	Follow up	Favorable and unfavorable outcomes include some, but not necessarily all, of the following	
				Favorable outcome	Unfavorable outcome
 <p>Clinical findings: The tooth is tender to touch and it has increased mobility, but it has not been displaced</p> <ul style="list-style-type: none"> <li>Bleeding from gingival crevice may be noted</li> </ul>	<ul style="list-style-type: none"> <li>A periapical (size 0 sensor/film, paralleling technique) or occlusal radiograph (size 2 sensor/film) should be taken at the time of initial presentation for diagnostic purposes and to establish a baseline</li> <li>Normal to slightly widened periodontal ligament space will be visible</li> </ul>	<ul style="list-style-type: none"> <li>No treatment is needed.</li> <li>Observation</li> <li>Parent/patient education: <ul style="list-style-type: none"> <li>Exercise care when eating not to further traumatize the injured teeth while encouraging a return to normal function as soon as possible</li> <li>To encourage gingival healing. Parents should clean the affected area with a soft brush or cotton swab combined with an alcohol-free 0.1%-0.2% chlorhexidine gluconate mouth rinse applied topically twice a day for 1 wk</li> </ul> </li> </ul>	<ul style="list-style-type: none"> <li>Clinical examination after: <ul style="list-style-type: none"> <li>1 wk</li> <li>6-8 wk</li> </ul> </li> <li>Where there are concerns that an unfavorable outcome is likely, then continue clinical follow up each year until eruption of the permanent teeth</li> <li>Radiographic follow up only indicated where clinical findings are suggestive of pathosis (eg, an unfavorable outcome)</li> <li>Parents should be informed to watch for any unfavorable outcomes and the need to return to the clinic as soon as possible. Where unfavorable outcomes are identified, treatment is often required</li> <li>The follow-up treatment, which frequently requires the expertise of a child-oriented team, is outside the scope of these guidelines</li> </ul>	<ul style="list-style-type: none"> <li>Asymptomatic</li> <li>Pulp healing with: <ul style="list-style-type: none"> <li>Normal color of the crown or transient red/gray or yellow discoloration and pulp canal obliteration</li> <li>No signs of pulp necrosis and infection</li> </ul> </li> <li>Continued root development in immature teeth</li> <li>No disturbance to the development and/or eruption of the permanent successor</li> </ul>	<ul style="list-style-type: none"> <li>Symptomatic</li> <li>Signs of pulp necrosis and infection—such as: <ul style="list-style-type: none"> <li>Sinus tract, gingival swelling, abscess, or increased mobility</li> <li>Persistent dark gray discoloration plus one or more signs of root canal infection</li> </ul> </li> <li>Radiographic signs of pulp necrosis and infection</li> <li>No further root development of immature teeth</li> <li>Negative impact on the development and/or eruption of the permanent successor</li> </ul>

## DISCLAIMER

THIS IS COPYRIGHTED CONTENT. Unauthorized use, including screenshots, copying, misuse, reuse, or resale of any content from this app, is strictly prohibited. Our app monitors and records all screenshots and recordings. Violators will face strict legal action.

DISCLAIMER  
THIS IS COPYRIGHTED CONTENT. Unauthorized use, including screenshots, copying, misuse, reuse, or resale of any content from this app, is strictly prohibited. Our app monitors and records all screenshots and recordings. Violators will face strict legal action.

THIS IS COPYRIGHTED CONTENT. Unauthorized use, including screenshots, copying, misuse, reuse, or resale of any content from this app, is strictly prohibited. Our app monitors and records all screenshots and recordings. Violators will face strict legal action.

# TRAUMA GUIDELINES


## Classification:

### B) Luxative Injuries:

It can be further divided into:


#### 2) Subluxation:

##### b) For permanent teeth:

Subluxation	Clinical findings	Imaging, radiographic assessment, and findings	Treatment	Follow up	Favorable Outcome	Unfavorable outcome
 <p>An injury to the tooth-supporting structures with abnormal loosening, but without displacement of the tooth</p>	<ul style="list-style-type: none"> <li>The tooth is tender to touch or light tapping</li> <li>Tooth has increased mobility but is not displaced</li> <li>Bleeding from the gingival crevice may be present</li> <li>The tooth may not respond to pulp sensibility testing initially indicating transient pulp damage</li> </ul>	<ul style="list-style-type: none"> <li>Radiographic appearance is usually normal</li> <li>Recommended radiographs:               <ul style="list-style-type: none"> <li>One parallel periapical radiograph</li> <li>Two additional radiographs of the tooth taken with different vertical and/or horizontal angulations</li> <li>Occlusal radiograph</li> </ul> </li> </ul>	<ul style="list-style-type: none"> <li>Normally no treatment is needed</li> <li>A passive and flexible splint to stabilize the tooth for up to 2 wk may be used but only if there is excessive mobility or tenderness when biting on the tooth</li> <li>Monitor the pulp condition for at least one year, but preferably longer</li> </ul>	Clinical and radiographic evaluations are necessary: <ul style="list-style-type: none"> <li>after 2 wk 5'</li> <li>after 12 wk</li> <li>after 6 mo</li> <li>after 1 yr</li> </ul>	<ul style="list-style-type: none"> <li>Asymptomatic</li> <li>Positive response to pulp sensibility testing; however, a false negative response is possible for several months. Endodontic treatment should not be started solely on the basis of no response to pulp sensibility testing</li> <li>Continued root development in immature teeth</li> <li>Intact lamina dura</li> </ul>	<ul style="list-style-type: none"> <li>Symptomatic</li> <li>Pulp necrosis and infection</li> <li>Apical periodontitis</li> <li>No further root development in immature teeth</li> <li>External inflammatory (infection-related) resorption – if this type of resorption develops, root canal treatment should be initiated immediately, with the use of calcium hydroxide as an intra-canal medicament. Alternatively, corticosteroid/antibiotic medicament can be used initially, which is then followed by calcium hydroxide</li> </ul>

#### 3) Extrusion (Extrusive Luxation)

##### a) For primary teeth:

Extrusive luxation	Radiographic recommendations and findings	Treatment	Follow up	Favorable and unfavorable outcomes include some, but not necessarily all, of the following:	
				Favorable outcome	Unfavorable outcome
 <p>Clinical findings: Partial displacement of the tooth out of its socket</p> <ul style="list-style-type: none"> <li>The tooth appears elongated and can be excessively mobile.</li> <li>Occlusal interference may be present</li> </ul>	<ul style="list-style-type: none"> <li>A periapical (size 0 sensor/film, paralleling technique) or occlusal radiograph (size 2 sensor/film) should be taken at the time of initial presentation for diagnostic purposes and to establish a baseline</li> <li>Slight increase to substantially widened periodontal ligament space apically</li> </ul>	<ul style="list-style-type: none"> <li>Treatment decisions are based on the degree of displacement, mobility, interference with the occlusion, root formation, and the ability of the child to tolerate the emergency situation</li> <li>If the tooth is not interfering with the occlusion—let the tooth spontaneously reposition itself</li> <li>If the tooth is excessively mobile or extruded &gt; 3 mm, then extract under local anesthesia</li> <li>Treatment should be performed by a child-oriented team with experience and expertise in the management of pediatric dental injuries. Extractions have the potential to cause long-term dental anxiety</li> <li>Parent/patient education:               <ul style="list-style-type: none"> <li>Exercise care when eating not to further traumatize the injured tooth while encouraging a return to normal function as soon as possible.</li> <li>To encourage gingival healing and prevent plaque accumulation, parents should clean the affected area with a soft brush or cotton swab combined with an alcohol-free 0.1%-0.2% chlorhexidine gluconate mouth rinse applied topically twice a day for 1 wk</li> </ul> </li> </ul>	<ul style="list-style-type: none"> <li>Clinical examination after:               <ul style="list-style-type: none"> <li>- 1 wk</li> <li>- 6-8 wk</li> <li>- 1 y</li> </ul> </li> <li>Where there are concerns that an unfavorable outcome is likely, then continue clinical follow up each year until eruption of the permanent teeth</li> <li>Radiographic follow up only indicated where clinical findings are suggestive of pathosis (eg, an unfavorable outcome)</li> <li>Parents should be informed to watch for any unfavorable outcomes and the need to return to the clinic as soon as possible. Where unfavorable outcomes are identified, treatment is often required</li> <li>The follow-up treatment, which frequently requires the expertise of a child-oriented team, is outside the scope of these guidelines</li> </ul>	<ul style="list-style-type: none"> <li>Asymptomatic</li> <li>Pulp healing with:               <ul style="list-style-type: none"> <li>- Normal color of the crown or transient red/gray or yellow discoloration and pulp canal obliteration</li> <li>- No signs of pulp necrosis and infection</li> </ul> </li> <li>Continued root development in immature teeth</li> <li>Realignment of the extruded tooth</li> <li>No interference with the occlusion</li> <li>No disturbance to the development and/or eruption of the permanent successor</li> </ul>	<ul style="list-style-type: none"> <li>Symptomatic</li> <li>Signs of pulp necrosis and infection—such as:               <ul style="list-style-type: none"> <li>- Sinus tract, gingival swelling, abscess, or increased mobility</li> <li>- Persistent dark gray discoloration plus one or more signs of root canal infection</li> </ul> </li> <li>Radiographic signs of pulp necrosis and infection</li> <li>No further root development of immature teeth</li> <li>No improvement in the position of the extruded tooth</li> <li>Negative impact on the development and/or eruption of the permanent successor</li> </ul>

## DISCLAIMER

THIS IS COPYRIGHTED CONTENT. Unauthorized use, including screenshots, copying, misuse, reuse, or resale of any content from this app, is strictly prohibited. Our app monitors and records all screenshots and recordings. Violators will face strict legal action.

DISCLAIMER  
THIS IS COPYRIGHTED CONTENT. Unauthorized use, including screenshots, copying, misuse, reuse, or resale of any content from this app, is strictly prohibited. Our app monitors and records all screenshots and recordings. Violators will face strict legal action.

THIS IS COPYRIGHTED CONTENT. Unauthorized use, including screenshots, copying, misuse, reuse, or resale of any content from this app, is strictly prohibited. Our app monitors and records all screenshots and recordings. Violators will face strict legal action.

DISCLAIMER



# TRAUMA GUIDELINES

## Classification:


### B) Luxative Injuries:

It can be further divided into:

#### 3) Extrusion (Extrusive Luxation)

##### b) For permanent teeth:


**TABLE 11** Permanent teeth: treatment guidelines for extrusive luxation injuries of the teeth

Extrusive luxation	Clinical findings	Imaging, radiographic assessment, and findings	Treatment	Follow up	Favorable outcome	Unfavorable outcome
 <p>Displacement of the tooth out of its socket in an incisal/axial direction</p>	<ul style="list-style-type: none"> <li>The tooth appears elongated</li> <li>The tooth has increased mobility</li> <li>The tooth will appear elongated incisally</li> <li>Likely to have no response to pulp sensibility tests</li> </ul>	<ul style="list-style-type: none"> <li>Increased periodontal ligament space both apically and laterally</li> <li>Tooth will not be seated in its socket and will appear elongated incisally</li> <li>Recommended radiographs:               <ul style="list-style-type: none"> <li>One parallel periapical radiograph</li> <li>Two additional radiographs of the tooth taken with different vertical and/or horizontal angulations</li> <li>Occlusal radiograph</li> </ul> </li> </ul>	<ul style="list-style-type: none"> <li>Reposition the tooth by gently pushing it back into the tooth socket under local anesthesia</li> <li>Stabilize the tooth for 2 wk using a passive and flexible splint. If breakdown/fracture of the marginal bone, splint for an additional 4 wk</li> <li>Monitor the pulp condition with pulp sensibility tests</li> <li>If the pulp becomes necrotic and infected, endodontic treatment appropriate to the tooth's stage of root development is indicated</li> </ul>	<p>Clinical and radiographic evaluations are necessary:</p> <ul style="list-style-type: none"> <li>after 2 wk S*</li> <li>after 4 wk</li> <li>after 8 wk</li> <li>after 12 wk</li> <li>after 6 mo</li> <li>after 1 y</li> <li>then yearly for at least 5 y</li> </ul> <p>Patients (and parents, where relevant) should be informed to watch for any unfavorable outcomes and the need to return to clinic if they observe any</p> <p>Where unfavorable outcomes are identified, treatment is often required. This is outside the scope of these guidelines. Referral to a dentist with the relevant expertise, training and experience is advised</p>	<ul style="list-style-type: none"> <li>Asymptomatic</li> <li>Clinical and radiographic signs of normal or healed periodontium</li> <li>Positive response to pulp sensibility testing; however, a false negative response is possible for several months. Endodontic treatment should not be started solely on the basis of no response to pulp sensibility testing</li> <li>No marginal bone loss</li> <li>Continued root development in immature teeth</li> </ul>	<ul style="list-style-type: none"> <li>Symptomatic</li> <li>Pulp necrosis and infection</li> <li>Apical periodontitis</li> <li>Breakdown of marginal bone</li> <li>External inflammatory (infection-related) resorption - if this type of resorption develops, root canal treatment should be initiated immediately, with the use of calcium hydroxide as an intracanal medicament. Alternatively, corticosteroid/antibiotic medicament can be used initially, which is then followed by calcium hydroxide</li> </ul>

Note: S\* = splint removal.

#### 4) Lateral Luxation:

##### a) For primary teeth:

Lateral luxation	Radiographic recommendations and findings	Treatment	Follow up	Favorable and unfavorable outcomes include some, but not necessarily all, of the following	
 <p>Clinical findings: The tooth is displaced, usually in a palatal/lingual or labial direction</p> <ul style="list-style-type: none"> <li>The tooth will be immobile</li> <li>Occlusal interference may be present</li> </ul>	<ul style="list-style-type: none"> <li>A periapical (size 0 sensor/film, paralleling technique) or occlusal radiograph (size 2 sensor/film) should be taken at the time of initial presentation for diagnostic purposes and to establish a baseline</li> <li>Increased periodontal ligament space apically (most clearly seen on an occlusal radiograph, especially if tooth is displaced labially)</li> </ul>	<ul style="list-style-type: none"> <li>If there is minimal or no occlusal interference, the tooth should be allowed to spontaneously reposition itself</li> <li>Spontaneous repositioning usually occurs within 6 mo</li> <li>In situations of severe displacement, two options are available, both of which require local anesthesia:               <ul style="list-style-type: none"> <li><b>Option A:</b> <ul style="list-style-type: none"> <li>Extraction when there is a risk of ingestion or aspiration of the tooth</li> </ul> </li> <li><b>Option B:</b> <ul style="list-style-type: none"> <li>Gently reposition the tooth</li> <li>If unstable in its new position, splint for 4 wk using a flexible splint attached to the adjacent uninjured teeth</li> </ul> </li> </ul> </li> <li>Treatment should be performed by a child-oriented team with experience and expertise in the management of pediatric dental injuries. Extractions have the potential to cause long-term dental anxiety</li> <li>Parent/patient education:               <ul style="list-style-type: none"> <li>Exercise care when eating not to further traumatize the injured teeth while encouraging a return to normal function as soon as possible</li> <li>To encourage gingival healing and prevent plaque accumulation, parents should clean the affected area with a soft brush or cotton swab combined with an alcohol-free chlorhexidine gluconate 0.1%-0.2% mouth rinse applied topically twice a day for 1 wk</li> </ul> </li> </ul>	<p>Clinical examination after:</p> <ul style="list-style-type: none"> <li>1 wk</li> <li>6-8 wk</li> <li>6 mo</li> <li>1 y</li> </ul> <p>If repositioned and splinted, review after:</p> <ul style="list-style-type: none"> <li>1 wk</li> <li>4 wk for splint removal</li> <li>8 wk</li> <li>6 mo</li> <li>1 y</li> </ul> <p>Where there are concerns that an unfavorable outcome is likely, then continue clinical follow up each year until eruption of the permanent teeth</p> <p>Radiographic follow up only indicated where clinical findings are suggestive of pathosis (eg, an unfavorable outcome)</p> <p>Parents should be informed to watch for any unfavorable outcomes and the need to return to the clinic as soon as possible. Where unfavorable outcomes are identified, treatment is often required</p> <p>The follow-up treatment, which frequently requires the expertise of a child-oriented team, is outside the scope of these guidelines</p>	<ul style="list-style-type: none"> <li>Asymptomatic</li> <li>Pulp healing with:               <ul style="list-style-type: none"> <li>Normal color of the crown or transient red/gray or yellow discoloration and pulp canal obliteration</li> <li>No signs of pulp necrosis and infection</li> </ul> </li> <li>Continued root development in immature teeth</li> <li>Periodontal healing</li> <li>Realignment of the laterally luxated tooth</li> <li>Normal occlusion</li> <li>No disturbance to the development and/or eruption of the permanent successor</li> </ul>	<ul style="list-style-type: none"> <li>Symptomatic</li> <li>Signs of pulp necrosis and infection—such as:               <ul style="list-style-type: none"> <li>Sinus tract, gingival swelling, abscess, or increased mobility</li> <li>Persistent dark gray discoloration plus one or more signs of root canal infection</li> </ul> </li> <li>Radiographic signs of pulp necrosis and infection</li> <li>Ankylosis</li> <li>No further root development of immature teeth</li> <li>No improvement in position of the laterally luxated tooth</li> <li>Negative impact on the development and/or eruption of the permanent successor</li> </ul>

## DISCLAIMER

THIS IS COPYRIGHTED CONTENT. Unauthorized use, including screenshots, copying, misuse, reuse, or resale of any content from this app, is strictly prohibited. Our app monitors and records all screenshots and recordings. Violators will face strict legal action.

**DISCLAIMER**  
THIS IS COPYRIGHTED CONTENT. Unauthorized use, including screenshots, copying, misuse, reuse, or resale of any content from this app, is strictly prohibited. Our app monitors and records all screenshots and recordings. Violators will face strict legal action.

THIS IS COPYRIGHTED CONTENT. Unauthorized use, including screenshots, copying, misuse, reuse, or resale of any content from this app, is strictly prohibited. Our app monitors and records all screenshots and recordings. Violators will face strict legal action.

DISCLAIMER



# TRAUMA GUIDELINES


## Classification:

### B) Luxative Injuries:

It can be further divided into:



#### 4) Lateral Luxation:

##### b) For permanent teeth:

Lateral luxation	Clinical findings	Imaging, radiographic assessment, and findings	Treatment	Follow up	Favorable Outcome	Unfavorable outcome
 Displacement of the tooth in any lateral direction, usually associated with a fracture or compression of the alveolar socket wall or facial cortical bone	<ul style="list-style-type: none"> <li>The tooth is displaced, usually in a palatal/lingual or labial direction</li> <li>There is usually an associated fracture of the alveolar bone</li> <li>The tooth is frequently immobile as the apex of the root is "locked" in by the bone fracture</li> <li>Percussion will give a high metallic (ankylosis) sound</li> <li>Likely to have no response to pulp sensibility tests</li> </ul>	<ul style="list-style-type: none"> <li>A widened periodontal ligament space which is best seen on radiographs taken with horizontal angle shifts or occlusal exposures</li> <li>Recommended radiographs:               <ul style="list-style-type: none"> <li>One parallel periapical radiograph</li> <li>Two additional radiographs of the tooth taken with different vertical and/or horizontal angulations</li> <li>Occlusal radiograph</li> </ul> </li> </ul>	<ul style="list-style-type: none"> <li>Reposition the tooth digitally by disengaging it from its locked position and gently reposition it into its original location under local anesthesia.               <ul style="list-style-type: none"> <li>Method: Palpate the gingiva to feel the apex of the tooth. Use one finger to push downwards over the apical end of the tooth, then use another finger or thumb to push the tooth back into its socket</li> </ul> </li> <li>Stabilize the tooth for 4 wk using a passive and flexible splint. If breakdown/fracture of the marginal bone or alveolar socket wall, additional splinting may be required</li> <li>Monitor the pulp condition with pulp sensibility tests at the follow-up appointments</li> <li>At about 2 wk post-injury, make an endodontic evaluation:               <ul style="list-style-type: none"> <li>Teeth with incomplete root formation:                   <ul style="list-style-type: none"> <li>Spontaneous revascularization may occur.</li> <li>If the pulp becomes necrotic and there are signs of inflammatory (infection-related) external resorption, root canal treatment should be started as soon as possible.</li> <li>Endodontic procedures suitable for immature teeth should be used</li> </ul> </li> <li>Teeth with complete root formation:                   <ul style="list-style-type: none"> <li>The pulp will likely become necrotic.</li> <li>Root canal treatment should be started, using a corticosteroid-antibiotic or calcium hydroxide as an intra-canal medicament to prevent the development of inflammatory (infection-related) external resorption</li> </ul> </li> </ul> </li> </ul>	<ul style="list-style-type: none"> <li>Clinical and radiographic evaluations are necessary:               <ul style="list-style-type: none"> <li>after 2 wk</li> <li>after 4 wk 5"</li> <li>after 8 wk</li> <li>after 12 wk</li> <li>after 6 mo</li> <li>after 1 y</li> <li>then yearly for at least 5 y</li> </ul> </li> <li>Patients (and parents, where relevant) should be informed to watch for any unfavorable outcomes and the need to return to clinic if they observe any</li> <li>Where unfavorable outcomes are identified, treatment is often required. This is outside the scope of these guidelines. Referral to a dentist with the relevant expertise, training and experience is advised</li> </ul>	<ul style="list-style-type: none"> <li>Asymptomatic</li> <li>Clinical and radiographic signs of normal or healed periodontium</li> <li>Positive response to pulp sensibility testing; however, a false negative response is possible for several months. Endodontic treatment should not be started solely on the basis of no response to pulp sensibility testing</li> <li>Marginal bone height corresponds to that seen radiographically after repositioning</li> <li>Continued root development in immature teeth</li> </ul>	<ul style="list-style-type: none"> <li>Symptomatic</li> <li>Breakdown of marginal bone</li> <li>Pulp necrosis and infection</li> <li>Apical periodontitis</li> <li>Ankylosis</li> <li>External replacement resorption</li> <li>External inflammatory (infection-related) resorption</li> <li>External inflammatory (infection-related) resorption - if this type of resorption develops, root canal treatment should be initiated immediately, with the use of calcium hydroxide as an intra-canal medicament. Alternatively, corticosteroid/antibiotic medicament can be used initially, which is then followed by calcium hydroxide</li> </ul>

#### 5) Intrusive Luxation (Intrusion)

##### a) For primary teeth:

Intrusive luxation	Radiographic recommendations and findings	Treatment	Follow up	Favorable and unfavorable outcomes include some, but not necessarily all, of the following	
  Clinical findings: The tooth is usually displaced through the labial bone plate, or it can impinge on the permanent tooth bud • The tooth has almost or completely disappeared into the socket and can be palpated labially	<ul style="list-style-type: none"> <li>A periapical (size 0 sensor/film, paralleling technique) or occlusal radiograph (size 2 sensor/film) should be taken at the time of initial presentation for diagnostic purposes and to establish a baseline</li> <li>When the apex is displaced toward or through the labial bone plate, the apical tip can be seen and the image of the tooth will appear shorter (foreshortened) than the contralateral tooth</li> <li>When the apex is displaced toward the permanent tooth germ, the apical tip cannot be visualized and the image of the tooth will appear elongated</li> </ul>	<ul style="list-style-type: none"> <li>The tooth should be allowed to spontaneously reposition itself, irrespective of the direction of displacement</li> <li>Spontaneous improvement in the position of the intruded tooth usually occurs within 6 mo</li> <li>In some cases, it can take up to 1 y</li> <li>A rapid referral (within a couple of days) to a child-oriented team that has experience and expertise in the management of pediatric dental injuries should be arranged</li> <li>Parent/patient education:               <ul style="list-style-type: none"> <li>Exercise care with eating not to further traumatize the injured tooth while encouraging a return to normal function as soon as possible</li> <li>To encourage gingival healing and prevent plaque accumulation, parents should clean the affected area with a soft brush or cotton swab combined with an alcohol-free 0.1%-0.2% chlorhexidine gluconate mouth rinse applied topically twice a day for 1 wk</li> </ul> </li> </ul>	<ul style="list-style-type: none"> <li>Clinical examination after:               <ul style="list-style-type: none"> <li>1 wk</li> <li>6-8 wk</li> <li>6 mo</li> <li>1 y</li> </ul> </li> <li>Further follow up at 6 y of age is indicated for severe intrusion to monitor eruption of the permanent tooth</li> <li>Radiographic follow up only indicated where clinical findings are suggestive of pathosis (eg, an unfavorable outcome)</li> <li>Parents should be informed to watch for any unfavorable outcomes and the need to return to the clinic as soon as possible. Where unfavorable outcomes are identified, treatment is often required</li> <li>The follow-up treatment, which frequently requires the expertise of a child-oriented team, is outside the scope of these guidelines</li> </ul>	<ul style="list-style-type: none"> <li>Asymptomatic</li> <li>Pulp healing with:               <ul style="list-style-type: none"> <li>Normal color of the crown or transient red/gray or yellow discoloration and pulp canal obliteration</li> <li>No signs of pulp necrosis and infection</li> </ul> </li> <li>Continued root development in immature teeth</li> <li>Periodontal healing</li> <li>Re-eruption/realignment of the intruded tooth</li> <li>No disturbance to the development and/or eruption of the permanent successor</li> </ul>	<ul style="list-style-type: none"> <li>Symptomatic</li> <li>Signs of pulp necrosis and infection—such as:               <ul style="list-style-type: none"> <li>Sinus tract, gingival swelling, abscess, or increased mobility</li> <li>Persistent dark gray discoloration with one or more signs of infection</li> </ul> </li> <li>Radiographic signs of pulp necrosis and infection</li> <li>No further root development of immature teeth</li> <li>Ankylosis</li> <li>Negative impact on the development and/or eruption of the permanent successor</li> </ul>

## DISCLAIMER

THIS IS COPYRIGHTED CONTENT. Unauthorized use, including screenshots, copying, misuse, reuse, or resale of any content from this app, is strictly prohibited. Our app monitors and records all screenshots and recordings. Violators will face strict legal action.

DISCLAIMER  
THIS IS COPYRIGHTED CONTENT. Unauthorized use, including screenshots, copying, misuse, reuse, or resale of any content from this app, is strictly prohibited. Our app monitors and records all screenshots and recordings. Violators will face strict legal action.

THIS IS COPYRIGHTED CONTENT. Unauthorized use, including screenshots, copying, misuse, reuse, or resale of any content from this app, is strictly prohibited. Our app monitors and records all screenshots and recordings. Violators will face strict legal action.

# TRAUMA GUIDELINES

## Classification:

### B) Luxative Injuries:

It can be further divided into:

#### 5) Intrusive Luxation (Intrusion)

##### b) For permanent teeth:

Intrusive luxation	Clinical findings	assessment, and findings	Treatment	Follow up	Favorable outcome	Unfavorable
 <p>Displacement of the tooth in an apical direction into the alveolar bone</p>	<ul style="list-style-type: none"> <li>The tooth is displaced axially into the alveolar bone</li> <li>The tooth is immobile</li> <li>Percussion will give a high metallic (ankylotic) sound</li> <li>Likely to have no response to pulp sensibility tests</li> </ul>	<ul style="list-style-type: none"> <li>The periodontal ligament space may not be visible for all or part of the root (especially apically)</li> <li>The cemento-enamel junction is located more apically in the intruded tooth than in adjacent non-injured teeth</li> <li>Recommended radiographs: <ul style="list-style-type: none"> <li>One parallel periapical radiograph</li> <li>Two additional radiographs of the tooth taken with different vertical and/or horizontal angulations</li> <li>Occlusal radiograph</li> </ul> </li> </ul>	<p>Teeth with incomplete root formation (immature teeth):</p> <ul style="list-style-type: none"> <li>Allow re-eruption without intervention (spontaneous repositioning) for all intruded teeth independent of the degree of intrusion</li> <li>If no re-eruption within 4 wk, initiate orthodontic repositioning</li> <li>Monitor the pulp condition</li> <li>In teeth with incomplete root formation spontaneous pulp revascularization may occur. However, if it is noted that the pulp becomes necrotic and infected or that there are signs of inflammatory (infection-related) external resorption at follow-up appointments, root canal treatment is indicated and should be started as soon as possible when the position of the tooth allows. Endodontic procedures suitable for immature teeth should be used.</li> <li>Parents must be informed about the necessity of follow-up visits</li> </ul> <p>Teeth with complete root formation (mature teeth):</p> <ul style="list-style-type: none"> <li>Allow re-eruption without intervention if the tooth is intruded less than 3 mm. If no re-eruption within 8 wk, reposition surgically and splint for 4 wk with a passive and flexible splint. Alternatively, reposition orthodontically before ankylosis develops</li> <li>If the tooth is intruded 3-7 mm, reposition surgically (preferably) or orthodontically</li> <li>If the tooth is intruded beyond 7mm, reposition surgically</li> <li>In teeth with complete root formation, the pulp almost always becomes necrotic. Root canal treatment should be started at 2 wk or as soon as the position of the tooth allows, using a corticosteroid-antibiotic or calcium hydroxide as an intra-canal medication. The purpose of this treatment is to prevent the development of inflammatory (infection-related) external resorption</li> </ul>	<p>Clinical and radiographic evaluations are necessary:</p> <ul style="list-style-type: none"> <li>after 2 wk</li> <li>after 4 wk 5*</li> <li>after 8 wk</li> <li>after 12 wk</li> <li>after 6 mo</li> <li>after 1 y</li> <li>then yearly for at least 5 y</li> </ul> <p>Patients (and parents, where relevant) should be informed to watch for any unfavorable outcomes and the need to return to clinic if they observe any</p> <ul style="list-style-type: none"> <li>Where unfavorable outcomes are identified, treatment is often required. This is outside the scope of these guidelines. Referral to a dentist with the relevant expertise, training and experience is advised</li> </ul>	<ul style="list-style-type: none"> <li>Asymptomatic</li> <li>Tooth in place or is re-erupting</li> <li>Intact lamina dura</li> <li>Positive response to pulp sensibility testing; however, a false negative response is possible for several months. Endodontic treatment should not be started solely on the basis of no response to pulp sensibility testing</li> <li>No signs of root resorption</li> <li>Continued root development in immature teeth</li> </ul>	<ul style="list-style-type: none"> <li>Symptomatic</li> <li>Tooth locked in place/ ankylotic tone to percussion</li> <li>Pulp necrosis and infection</li> <li>Apical periodontitis</li> <li>Ankylosis</li> <li>External replacement resorption</li> <li>External inflammatory (infection-related) resorption - if this type of resorption develops, root canal treatment should be initiated immediately, with the use of calcium hydroxide as an intra-canal medicament. Alternatively, corticosteroid/antibiotic medicament can be used initially, which is then followed by calcium hydroxide</li> </ul>

THIS IS COPYRIGHTED CONTENT. Unauthorized use, including screenshots, copying, misuse, reuse, or resale of any content from this app, is strictly prohibited.

**DISCLAIMER**  
THIS IS COPYRIGHTED CONTENT. Unauthorized use, including screenshots, copying, misuse, reuse, or resale of any content from this app, is strictly prohibited. Our app monitors and records all screenshots and recordings. Violators will face strict legal action.

CONTENT. Unauthorized use, including screenshots, copying, misuse, reuse, or resale of any content from this app, is strictly prohibited. Our app monitors and records all screenshots and recordings. Violators will face strict legal action.

THIS IS COPYRIGHTED CONTENT. Unauthorized use, including screenshots, copying, misuse, reuse, or resale of any content from this app, is strictly prohibited. Our app monitors and records all screenshots and recordings. Violators will face strict legal action.

#### DISCLAIMER

THIS IS COPYRIGHTED CONTENT. Unauthorized use, including screenshots, copying, misuse, reuse, or resale of any content from this app, is strictly prohibited. Our app monitors and records all screenshots and recordings. Violators will face strict legal action.


# TRAUMA GUIDELINES

## Classification:

### C) Avulsion

It is the complete removal of teeth from its socket.

#### 1) Avulsion primary teeth:

Avulsion	Radiographic recommendations and findings	Treatment	Follow up	Favorable and unfavorable outcomes include some, but not necessarily all, of the following	
				Favorable outcome	Unfavorable outcome
 <p>Clinical findings: The tooth is completely out of the socket</p> <ul style="list-style-type: none"> <li>The location of the missing tooth should be explored during the trauma history and examination, especially when the accident was not witnessed by an adult or there was a loss of consciousness.</li> <li>While avulsed teeth are most often lost out of the mouth, there is a risk that they can be embedded in soft tissues of the lip, cheek, or tongue, pushed into the nose, ingested or aspirated.</li> <li>If the avulsed tooth is not found, the child should be referred for medical evaluation to an emergency room for further examination, especially where there are respiratory symptoms</li> </ul>	<ul style="list-style-type: none"> <li>A periapical (size 0 sensor/film, paralleling technique) or occlusal radiograph (size 2 sensor/film) is essential where the primary tooth is not brought into the clinic to ensure that the missing tooth has not been intruded</li> <li>The radiograph will also provide a baseline for assessment of the developing permanent tooth and to determine whether it has been displaced</li> </ul>	<ul style="list-style-type: none"> <li>Avulsed primary teeth should not be replanted</li> <li>Parent/patient education: <ul style="list-style-type: none"> <li>Exercise care when eating not to further traumatize the injured soft tissues</li> <li>To encourage gingival healing and prevent plaque accumulation, parents should clean the affected area with a soft brush or cotton swab combined with an alcohol-free 0.1%-0.2% chlorhexidine gluconate mouth rinse applied topically twice a day for 1 wk</li> </ul> </li> </ul>	<ul style="list-style-type: none"> <li>Clinical examination after: <ul style="list-style-type: none"> <li>6-8 wk</li> <li>Further follow up at 6 y of age is indicated to monitor eruption of the permanent tooth</li> </ul> </li> <li>Radiographic follow up only indicated where clinical findings are suggestive of pathosis (eg, an unfavorable outcome)</li> <li>Parents should be informed to watch for any unfavorable outcomes and the need to return to the clinic as soon as possible. Where unfavorable outcomes are identified, treatment is often required</li> <li>The follow-up treatment, which frequently requires the expertise of a child-oriented team, is outside the scope of these guidelines</li> </ul>	<ul style="list-style-type: none"> <li>No signs of disturbance to development and/or eruption of the permanent successor</li> </ul>	<ul style="list-style-type: none"> <li>Negative impact on the development and/or eruption of the permanent successor</li> </ul>

#### 2) Avulsion of Permanent Teeth:

- Avulsion of permanent teeth is seen in 0.5%–16% of all dental injuries.
- Numerous studies have shown that this injury is one of the most serious dental injuries, and the prognosis is very much dependent on the actions taken at the place of accident and promptly following the avulsion.
- Replantation is, in most situations, the treatment of choice but cannot always be carried out immediately.
- Appropriate emergency management and a treatment plan are important for a good prognosis.
- There are also individual situations when replantation is not indicated (e.g., severe caries or periodontal disease, an uncooperative patient, severe cognitive impairment requiring sedation, severe medical conditions such as immunosuppression, and severe cardiac conditions) which must be dealt with individually.
- Dentists should be prepared to give appropriate advice to the public about first aid for avulsed teeth.
- An avulsed permanent tooth is one of the few real emergency situations in dentistry.
- In addition to increasing the public awareness by mass media campaigns or other means of communication, parents, guardians and teachers should receive information on how to proceed following these severe and unexpected injuries.

#### DISCLAIMER

THIS IS COPYRIGHTED CONTENT. Unauthorized use, including screenshots, copying, misuse, reuse, or resale of any content from this app, is strictly prohibited. Our app monitors and records all screenshots and recordings. Violators will face strict legal action.

**DISCLAIMER**  
THIS IS COPYRIGHTED CONTENT. Unauthorized use, including screenshots, copying, misuse, reuse, or resale of any content from this app, is strictly prohibited. Our app monitors and records all screenshots and recordings. Violators will face strict legal action.

THIS IS COPYRIGHTED CONTENT. Unauthorized use, including screenshots, copying, misuse, reuse, or resale of any content from this app, is strictly prohibited. Our app monitors and records all screenshots and recordings. Violators will face strict legal action.

DISCLAIMER



# TRAUMA GUIDELINES

## Classification:

### C) Avulsion

#### 2) Avulsion of Permanent Teeth:

- Also, instructions may be given by telephone to people at the emergency site.
- Immediate replantation of the avulsed tooth is the best treatment at the place of the accident. If for some reason this cannot be carried out, there are alternatives such as using different types of storage media.
- If a tooth is avulsed, make sure it is a permanent tooth (primary teeth should not be replanted) and follow these recommended instructions:
  - i. Keep the patient calm.
  - ii. Find the tooth and pick it up by the crown (the white part). Avoid touching the root. Attempt to place it back immediately into the jaw.
  - iii. If the tooth is dirty, rinse it gently in milk, saline or in the patient's saliva and replant or return it to its original position in the jaw.
  - iv. It is important to encourage the patient/guardian/teacher/other person to replant the tooth immediately at the emergency site.
  - v. Once the tooth has been returned to its original position in the jaw, the patient should bite on gauze, a handkerchief or a napkin to hold it in place.
  - vi. If replantation at the accident site is not possible, or for other reasons when replantation of the avulsed tooth is not feasible (e.g., an unconscious patient), place the tooth, as soon as possible, in a storage or transport medium that is immediately available at the emergency site. This should be done quickly to avoid dehydration of the root surface, which starts to happen in a matter of a few minutes. In descending order of preference, milk, HBSS, saliva (after spitting into a glass for instance), or saline are suitable and convenient storage mediums. Although water is a poor medium, it is better
  - vii. than leaving the tooth to air-dry.  
The tooth can then be brought with the patient to the emergency clinic.
  - viii. See a dentist or dental professional immediately.

#### Treatment Guidelines for avulsed Permanent teeth:

- The choice of treatment is related to the maturity of the root (open or closed apex) and the condition of the periodontal ligament (PDL) cells.
- The condition of the PDL cells is dependent on the time out of the mouth and on the storage medium in which the avulsed tooth was kept.

#### DISCLAIMER

THIS IS COPYRIGHTED CONTENT. Unauthorized use, including screenshots, copying, misuse, reuse, or resale of any content from this app, is strictly prohibited. Our app monitors and records all screenshots and recordings. Violators will face strict legal action.

DISCLAIMER

THIS IS COPYRIGHTED CONTENT. Unauthorized use, including screenshots, copying, misuse, reuse, or resale of any content from this app, is strictly prohibited. Our app monitors and records all screenshots and recordings. Violators will face strict legal action.

THIS IS COPYRIGHTED CONTENT. Unauthorized use, including screenshots, copying, misuse, reuse, or resale of any content from this app, is strictly prohibited. Our app monitors and records all screenshots and recordings. Violators will face strict legal action.

DISCLAIMER

# TRAUMA GUIDELINES

## Treatment Guidelines for avulsed Permanent teeth:

- The choice of treatment is related to the maturity of the root (open or closed apex) and the condition of the periodontal ligament (PDL) cells.
- The condition of the PDL cells is dependent on the time out of the mouth and on the storage medium in which the avulsed tooth was kept.
  - i. The PDL cells are most likely viable when the tooth has been replanted immediately or within a very short time (about 15 minutes) at the place of accident.
  - ii. The PDL cells may be viable but compromised when the tooth has been kept in a storage medium (e.g., milk, HBSS (Save-a-Tooth or similar product), saliva, or saline, and the total extra-oral dry time has been less than 60 minutes. The PDL cells are likely to be non-viable when the total extra-oral dry time has been more than 60 minutes, regardless of the tooth having been stored in a medium or not.
  - iii. The PDL cells are most likely non-viable when the tooth has been kept in a storage medium (e.g., milk, HBSS (Save-a-Tooth or similar product), saliva, or saline, and the total extra-oral dry time has been less than 60 minutes.
- The best treatment for an avulsed tooth is immediate replantation at the site of the accident, which is usually not painful.
- While local anesthesia is not available when teeth are replanted at the site of injury, once the patient arrives at a dental or medical facility, pain control by means of local anesthesia is always recommended.

### a) Tooth With Closed apex (Mature teeth)

- The treatment guidelines depend on the time of reimplantation of the avulsed tooth:
  - i. When the tooth has been replanted at the site of injury or before the patient's arrival at the dental clinic:

1. Clean the injured area with water, saline, or chlorhexidine.
2. Verify the correct position of the replanted tooth both clinically and radiographically.
3. Leave the tooth/teeth in place (except where the tooth is malpositioned; the malpositioning needs to be corrected using slight digital pressure).
4. Administer local anesthesia, if necessary, and preferably with no vasoconstrictor.
5. If the tooth or teeth were replanted in the wrong socket or rotated, consider repositioning the tooth/teeth into the proper location up to 48 hours after the traumatic incident.
6. Stabilize the tooth for 2 weeks using a passive flexible splint such as wire of a diameter up to 0.016" or 0.4 mm<sup>32</sup> bonded to the tooth and adjacent teeth. Keep the composite and bonding agents away from the gingival tissues and proximal areas. Alternatively, nylon fishing line (0.13-0.25 mm) can be used to create a flexible splint, using composite to bond it to the teeth.

7. Suture gingival lacerations, if present.
8. Initiate root canal treatment within 2 weeks after replantation (refer to Endodontic Considerations).
9. Administer systemic antibiotics.<sup>34,35</sup> (see: "Antibiotics")
10. Check tetanus status.<sup>36</sup> (see: "Tetanus")
11. Provide post-operative instructions. (see: "Patient instructions")
12. Follow up. (see: "Follow-up procedures")

#### DISCLAIMER

THIS IS COPYRIGHTED CONTENT. Unauthorized use, including screenshots, copying, misuse, reuse, or resale of any content from this app, is strictly prohibited. Our app monitors and records all screenshots and recordings. Violators will face strict legal action.

#### DISCLAIMER

THIS IS COPYRIGHTED CONTENT. Unauthorized use, including screenshots, copying, misuse, reuse, or resale of any content from this app, is strictly prohibited. Our app monitors and records all screenshots and recordings. Violators will face strict legal action.

THIS IS COPYRIGHTED CONTENT. Unauthorized use, including screenshots, copying, misuse, reuse, or resale of any content from this app, is strictly prohibited. Our app monitors and records all screenshots and recordings. Violators will face strict legal action.

DISCLAIMER



# TRAUMA GUIDELINES

## ii. When the tooth has been kept in a physiologic storage medium or stored in non-physiologic conditions, with the extra-oral dry time less than 60 minutes

- |   |  |
|---|--|
| <ol style="list-style-type: none"> <li>1. If there is visible contamination, rinse the root surface with a stream of saline or osmolality-balanced media to remove gross debris.</li> <li>2. Check the avulsed tooth for surface debris. Remove any debris by gently agitating it in the storage medium. Alternatively, a stream of saline can be used to briefly rinse its surface.</li> <li>3. Put or leave the tooth in a storage medium while taking a history, examining the patient clinically and radiographically, and preparing the patient for the replantation.</li> <li>4. Administer local anesthesia, preferably without a vasoconstrictor.<sup>37</sup></li> <li>5. Irrigate the socket with sterile saline.</li> <li>6. Examine the alveolar socket. If there is a fracture of the socket wall, reposition the fractured fragment into its original position with a suitable instrument.</li> <li>7. Removal of the coagulum with a saline stream may allow better repositioning of the tooth.</li> <li>8. Replant the tooth slowly with slight digital pressure. Excessive force should not be used to replant the tooth back into its original position.</li> </ol> | <ol style="list-style-type: none"> <li>9. Verify the correct position of the replanted tooth both clinically and radiographically.</li> <li>10. Stabilize the tooth for 2 weeks using a passive, flexible wire of a diameter up to 0.016" or 0.4 mm.<sup>32</sup> Keep the composite and bonding agents away from the gingival tissues and proximal areas. Alternatively, nylon fishing line (0.13-0.25 mm) can be used to create a flexible splint, using composite to bond it to the teeth. Nylon (fishing line) splints are not recommended for children when there are only a few permanent teeth as stabilization of the traumatized tooth may not be guaranteed. In cases of associated alveolar or jawbone fracture, a more rigid splint is indicated and should be left in place for about 4 weeks.</li> <li>11. Suture gingival lacerations, if present.</li> <li>12. Initiate root canal treatment within 2 weeks after replantation (refer to "Endodontic Considerations").<sup>38,39</sup></li> <li>13. Administer systemic antibiotics.<sup>34,35</sup> (see: "Antibiotics")</li> <li>14. Check tetanus status.<sup>36</sup> (see: "Tetanus")</li> <li>15. Provide post-operative instructions. (see: "Post-operative instructions")</li> <li>16. Follow up. (see: "Follow-up procedures")</li> </ol> |
|---|--|

## iii. When extraoral dry time is more than 60 minutes:

- |   |  |
|---|--|
| <ol style="list-style-type: none"> <li>1. Remove loose debris and visible contamination by agitating the tooth in physiologic storage medium, or with gauze soaked in saline. Tooth may be left in storage medium while taking a history, examining the patient clinically and radiographically, and preparing the patient for the replantation.</li> <li>2. Administer local anesthesia, preferably without vasoconstrictor.</li> <li>3. Irrigate the socket with sterile saline.</li> <li>4. Examine the alveolar socket. Remove coagulum if necessary. If there is a fracture of the socket wall, reposition the fractured fragment with a suitable instrument.</li> <li>5. Replant the tooth slowly with slight digital pressure. The tooth should not be forced back to place.</li> <li>6. Verify the correct position of the replanted tooth both clinically and radiographically.</li> <li>7. Stabilize the tooth for 2 weeks<sup>40</sup> using a passive flexible wire of a diameter up to 0.016" or 0.4 mm.<sup>32</sup> Keep the composite and bonding agents away from the gingival tissues and proximal areas. Alternatively, nylon fishing line (0.13-0.25 mm) can be used to create a flexible splint, with composite to bond it to the teeth. A more rigid splint is indicated in cases of alveolar or jawbone fracture and should be left in place for about 4 weeks.</li> </ol> | <ol style="list-style-type: none"> <li>8. Suture gingival lacerations, if present.</li> <li>9. Root canal treatment should be carried out within 2 weeks (refer to Endodontic Considerations).</li> <li>10. Administer systemic antibiotics.<sup>34,35</sup> (see: "Antibiotics")</li> <li>11. Check tetanus status.<sup>36</sup> (see: "Tetanus")</li> <li>12. Provide post-operative instructions. (see: "Post-operative instructions")</li> <li>13. Follow up. (see: "Follow-up procedures")</li> </ol> |
|---|--|

- Delayed replantation has a poor long-term prognosis.
- The periodontal ligament becomes necrotic and is not expected to regenerate.
- The expected outcome is ankylosis-related (replacement) root resorption.
- The goal of replantation in these cases is to restore, at least temporarily, esthetics and function while

### DISCLAIMER

THIS IS COPYRIGHTED CONTENT. Unauthorized use, including screenshots, copying, misuse, reuse, or resale of any content from this app, is strictly prohibited. Our app monitors and records all screenshots and recordings. Violators will face strict legal action.

DISCLAIMER  
THIS IS COPYRIGHTED CONTENT. Unauthorized use, including screenshots, copying, misuse, reuse, or resale of any content from this app, is strictly prohibited. Our app monitors and records all screenshots and recordings. Violators will face strict legal action.

THIS IS COPYRIGHTED CONTENT. Unauthorized use, including screenshots, copying, misuse, reuse, or resale of any content from this app, is strictly prohibited. Our app monitors and records all screenshots and recordings. Violators will face strict legal action.

DISCLAIMER

# TRAUMA GUIDELINES

## b) Tooth With Closed apex (Mature teeth)

### i. When the tooth has been replanted before the patient's arrival at the clinic

- |  |  |
|--|--|
| <ol style="list-style-type: none"> <li>1. Clean the area with water, saline, or chlorhexidine.</li> <li>2. Verify the correct position of the replanted tooth both clinically and radiographically.</li> <li>3. Leave the tooth in the jaw (except where the tooth is malpositioned; the malpositioning needs to be corrected using slight digital pressure).</li> <li>4. Administer local anesthesia, if necessary, and preferably with no vasoconstrictor.</li> <li>5. If the tooth or teeth were replanted in the wrong socket or rotated, consider repositioning the tooth/teeth into the proper location for up to 48 hours after the trauma.</li> <li>6. Stabilize the tooth for 2 weeks using a passive and flexible wire of a diameter up to 0.016" or 0.4 mm.<sup>32</sup> Short immature teeth may require a longer splinting time.<sup>47</sup> Keep the composite and bonding agents away from the gingival tissues and proximal areas. Alternatively, nylon fishing line (0.13-0.25 mm) can be used to create a flexible splint, using composite to bond it to the teeth. In cases of associated alveolar or jawbone fracture, a more rigid splint is indicated and should be left in place for 4 weeks.</li> </ol> | <ol style="list-style-type: none"> <li>7. Suture gingival lacerations, if present.</li> <li>8. Pulp revascularization, which can lead to further root development, is the goal when replanting immature teeth in children. The risk of external infection-related (inflammatory) root resorption should be weighed against the chances of revascularization. Such resorption is very rapid in children. If spontaneous revascularization does not occur, apexification, pulp revitalization/revascularization,<sup>48,49</sup> or root canal treatment should be initiated as soon as pulp necrosis and infection is identified (refer to Endodontic Considerations).</li> <li>9. Administer systemic antibiotics.<sup>34,35</sup> (see: "Antibiotics")</li> <li>10. Check tetanus status.<sup>36</sup> (see: "Tetanus")</li> <li>11. Provide post-operative instructions. (see: "Post-operative instructions")</li> <li>12. Follow up. (see: "Follow-up procedures")</li> </ol> |
|--|--|

- In immature teeth with open apices, there is a potential for spontaneous healing to occur in the form of new connective tissue with a vascular supply.
- This allows continued root development and maturation.
- Hence, endodontic treatment should not be initiated unless there are definite signs of pulp necrosis and infection of the root canal system at follow-up appointments.

### ii. The tooth has been kept in a physiologic storage medium or stored in non-physiologic conditions, and the extra-oral time has been less than 60 minutes

- |  |   |
|--|---|
| <ol style="list-style-type: none"> <li>1. Check the avulsed tooth and remove debris from its surface by gently agitating it in the storage medium. Alternatively, a stream of sterile saline or a physiologic medium can be used to rinse its surface.</li> <li>2. Place or leave the tooth in a storage medium while taking the history, examining the patient clinically and radiographically and preparing the patient for the replantation.</li> <li>3. Administer local anesthesia, preferably vasoconstrictor.</li> <li>4. Irrigate the socket with sterile saline.</li> <li>5. Examine the alveolar socket. Remove coagulum, if necessary. If there is a fracture of the socket wall, reposition the fractured segment with a suitable instrument.</li> <li>6. Replant the tooth slowly with slight digital pressure.</li> <li>7. Verify the correct position of the replanted tooth both clinically and radiographically.</li> <li>8. Stabilize the tooth for 2 weeks using a passive and flexible wire of a diameter up to 0.016" or 0.4 mm.<sup>32</sup> Keep the composite and bonding agents away from the gingival tissues and proximal areas. Alternatively, nylon fishing line (0.13-0.25 mm) can be used to create a flexible splint, with composite to bond it to the teeth. In cases of associated alveolar or jawbone fracture, a more rigid splint is indicated and should be left for about 4 weeks.</li> </ol> | <ol style="list-style-type: none"> <li>9. Suture gingival lacerations, if present.</li> <li>10. Revascularization of the pulp space, which can lead to further root development, is the goal when replanting immature teeth in children. The risk of external infection-related (inflammatory) root resorption should be weighed against the chances of revascularization. Such resorption is very rapid in children. If spontaneous revascularization does not occur, apexification, pulp revitalization/revascularization,<sup>48,49</sup> or root canal treatment should be initiated as soon as pulp necrosis and infection is identified (refer to Endodontic Considerations).</li> <li>11. Administer systemic antibiotics.<sup>34,35</sup> (see: "Antibiotics")</li> <li>12. Check tetanus status.<sup>36</sup> (see: "Tetanus")</li> <li>13. Provide post-operative instructions. (see: "Post-operative instructions")</li> <li>14. Follow up. (see: "Follow-up procedures")</li> </ol> |
|--|---|

#### DISCLAIMER

THIS IS COPYRIGHTED CONTENT. Unauthorized use, including screenshots, copying, misuse, reuse, or resale of any content from this app, is strictly prohibited. Our app monitors and records all screenshots and recordings. Violators will face strict legal action.

#### DISCLAIMER

THIS IS COPYRIGHTED CONTENT. Unauthorized use, including screenshots, copying, misuse, reuse, or resale of any content from this app, is strictly prohibited. Our app monitors and records all screenshots and recordings. Violators will face strict legal action.

THIS IS COPYRIGHTED CONTENT. Unauthorized use, including screenshots, copying, misuse, reuse, or resale of any content from this app, is strictly prohibited. Our app monitors and records all screenshots and recordings. Violators will face strict legal action.

#### DISCLAIMER



# TRAUMA GUIDELINES

## b) Tooth With Closed apex (Mature teeth)

### iii. When Extra-oral time longer than 60 minutes:

- |   |  |
|---|--|
| <ol style="list-style-type: none"> <li>1. Check the avulsed tooth and remove debris from its surface by gently agitating it in the storage medium. Alternatively, a stream of saline can be used to rinse its surface.</li> <li>2. Place or leave the tooth in a storage medium while taking the history, examining the patient clinically and radiographically and preparing the patient for the replantation.</li> <li>3. Administer local anesthesia, preferably with no vasoconstrictor.</li> <li>4. Irrigate the socket with sterile saline.</li> <li>5. Examine the alveolar socket. If there is a fracture of the socket wall, reposition the fractured segment with a suitable instrument.</li> <li>6. Replant the tooth slowly with slight digital pressure.</li> <li>7. Verify the correct position of the replanted tooth both clinically and radiographically.</li> <li>8. Stabilize the tooth for 2 weeks using a passive and flexible wire of a diameter up to 0.016" or 0.4 mm.<sup>32</sup> Keep the composite and bonding agents away from the gingival tissues and proximal areas. Alternatively, nylon fishing line (0.13-0.25 mm) can be used to create a flexible splint, with composite to bond it to the teeth. In cases of associated alveolar or jawbone fracture, a more rigid splint is indicated and should be left for about 4 weeks.</li> </ol> | <ol style="list-style-type: none"> <li>9. Suture gingival lacerations, if present.</li> <li>10. Revascularization of the pulp space, which can lead to further root development and maturation, is the goal when replanting immature teeth in children. The risk of external infection-related (inflammatory) root resorption should be weighed against the chances of revascularization. Such resorption is very rapid in children. If spontaneous revascularization does not occur, apexification, pulp revitalization/revascularization, or root canal treatment should be initiated as soon as pulp necrosis and infection is identified (refer to Endodontic Considerations).</li> <li>11. Administer systemic antibiotics.<sup>34,35</sup> (see: "Antibiotics")</li> <li>12. Check tetanus status.<sup>36</sup> (see: "Tetanus")</li> <li>13. Provide post-operative instructions. (see: "Post-operative instructions")</li> <li>14. Follow up. (see: "Follow-up procedures")</li> </ol> |
|---|--|

- In cases of Immature tooth also, the most expected outcome is ankylosis-related (replacement) root resorption in cases of delayed reimplantation which has poor prognosis.

### Use of Antibiotics in Avulsion Cases:

- Antibiotic Therapy is recommended after replanting the tooth, however there is limited evidence to show that it reduces healing complication like inflammatory root resorption.
- Amoxicillin and penicillin are used.
- Doxycycline is preferred because of its clinical experience and also some evidence showing that it has antiresorptive property.

doxycycline orally, once daily for 7 days  
 adult: 100 mg  
 child 8 years or older and less than 26 kg: 50 mg  
 child 8 years or older and 26 to 35 kg: 75 mg  
 child 8 years or older and more than 35 kg: 100 mg

If doxycycline is contraindicated (eg children younger than 8 years); use:

amoxicillin 500 mg (child: 15 mg/kg up to 500 mg) orally, 8-hourly for 7 days.

Recommend the use of chlorhexidine mouthwash after replantation while the tooth is splinted; use:

- 1 chlorhexidine 0.2% mouthwash 10 mL rinsed in the mouth for 1 minute, 8- to 12-hourly\*

OR

- 1 chlorhexidine 0.12% mouthwash 15 mL rinsed in the mouth for 1 minute, 8- to 12-hourly.\*

### DISCLAIMER

THIS IS COPYRIGHTED CONTENT. Unauthorized use, including screenshots, copying, misuse, reuse, or resale of any content from this app, is strictly prohibited. Our app monitors and records all screenshots and recordings. Violators will face strict legal action.

### DISCLAIMER

THIS IS COPYRIGHTED CONTENT. Unauthorized use, including screenshots, copying, misuse, reuse, or resale of any content from this app, is strictly prohibited. Our app monitors and records all screenshots and recordings. Violators will face strict legal action.

THIS IS COPYRIGHTED CONTENT. Unauthorized use, including screenshots, copying, misuse, reuse, or resale of any content from this app, is strictly prohibited. Our app monitors and records all screenshots and recordings. Violators will face strict legal action.

### DISCLAIMER

# TRAUMA GUIDELINES

## Follow up Protocol For avulsed permanent teeth:

### a) For teeth with Open Apex (Immature teeth)

Replanted teeth with an open apex should be monitored clinically and radiographically:

- at 2 weeks (when the splint is removed),
- 1 month (4 weeks)
- 2month (8 weeks),
- 3 month (12 weeks)
- 6 months
- one year,
- and yearly thereafter for at least five years

### b) For teeth with Closed Apex (Mature teeth)

Replanted teeth should be monitored clinically and radiographically

- At 2 weeks (when the splint is removed),
- 4 weeks,
- 3 months,
- 6 months,
- one year,
- and yearly thereafter for at least five years.

THIS IS COPYRIGHTED CONTENT. Unauthorized use, including screenshots, copying, misuse, reuse, or resale of any content from this app, is strictly prohibited. Our app monitors and records all screenshots and recordings. Violators will face strict legal action.

**DISCLAIMER**  
THIS IS COPYRIGHTED CONTENT. Unauthorized use, including screenshots, copying, misuse, reuse, or resale of any content from this app, is strictly prohibited. Our app monitors and records all screenshots and recordings. Violators will face strict legal action.

THIS IS COPYRIGHTED CONTENT. Unauthorized use, including screenshots, copying, misuse, reuse, or resale of any content from this app, is strictly prohibited. Our app monitors and records all screenshots and recordings. Violators will face strict legal action.

THIS IS COPYRIGHTED CONTENT. Unauthorized use, including screenshots, copying, misuse, reuse, or resale of any content from this app, is strictly prohibited. Our app monitors and records all screenshots and recordings. Violators will face strict legal action.

#### DISCLAIMER

THIS IS COPYRIGHTED CONTENT. Unauthorized use, including screenshots, copying, misuse, reuse, or resale of any content from this app, is strictly prohibited. Our app monitors and records all screenshots and recordings. Violators will face strict legal action.

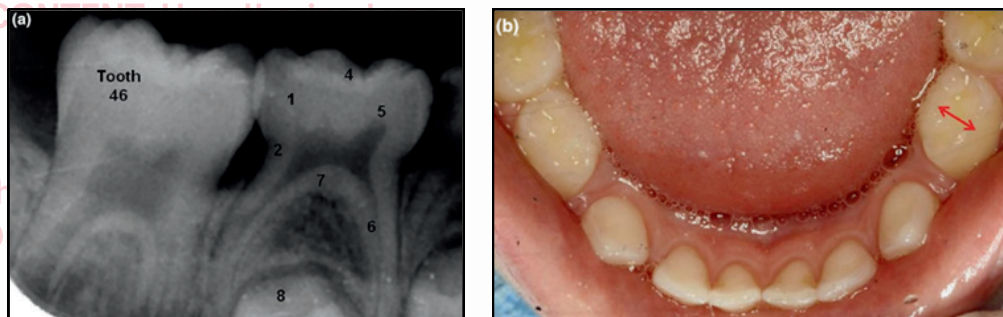
# PRIMARY TEETH RESTORATIONS

(Source- Article on Restorative treatment of primary teeth (ADJ), 2019)

- Dental caries affects a significant percentage of children worldwide, that can have potentially serious complications for child's dental and general well-being.
- Rehabilitation of Child's dentition can restore them to health and function.
- The restoration of Primary teeth can be technically difficult due to:
  - a) Their smaller size in comparison to permanent teeth.
  - b) The thinner enamel and high pulp horns in primary tooth is also associated with increased risk of caries progression into dentine.
  - c) This also increases the risk of pulp exposure during operative intervention.

## Difference between primary and permanent molars:

- Features of primary molars include:



1. Bulbous Crown (Fig. a)
2. Cervical Constriction (Fig. a)
3. Narrow occlusal table (as shown in 2<sup>nd</sup> photo not given in x-ray) (Fig. b)
4. Thin enamel (Fig. a)
5. Pulp horns (Fig. a)
6. Narrow root canals (Fig. a)
7. Thin and porous pulpal floor (Fig. a)
8. Developing permanent tooth. (Fig. a)

## Establishing Diagnosis:

- History, Examination and Special Tests (radiographs) are the key elements in establishing an accurate diagnosis.
- The clinician should question the child and his/her parents or carers regarding the symptoms of the carious tooth.
- Radiographs (most commonly bitewings) are essential aids to establishing correct diagnosis of primary molar caries without which the pulpal pathology is likely to be undiagnosed.
- Various studies also suggest that the extent and site of caries can also alert the clinician to the possibility of pulpal pathology.

## DISCLAIMER

THIS IS COPYRIGHTED CONTENT. Unauthorized use, including screenshots, copying, misuse, reuse, or resale of any content from this app, is strictly prohibited. Our app monitors and records all screenshots and recordings. Violators will face strict legal action.

DISCLAIMER  
THIS IS COPYRIGHTED CONTENT. Unauthorized use, including screenshots, copying, misuse, reuse, or resale of any content from this app, is strictly prohibited. Our app monitors and records all screenshots and recordings. Violators will face strict legal action.

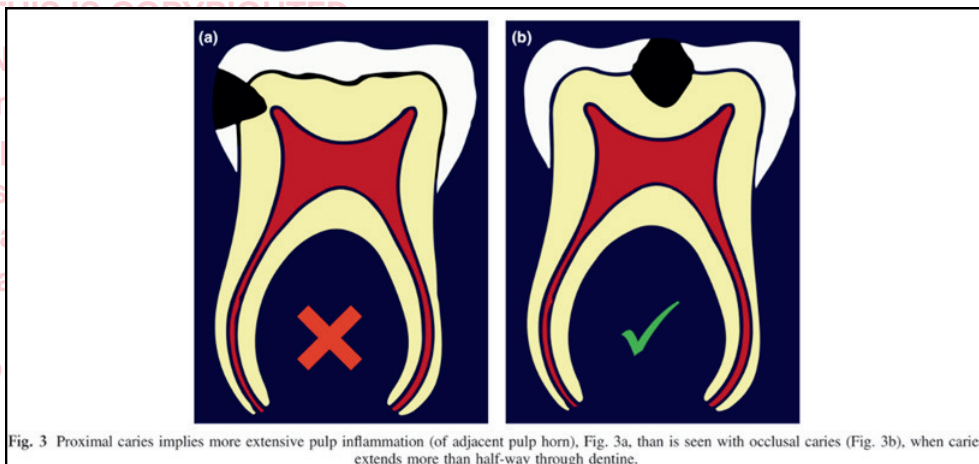
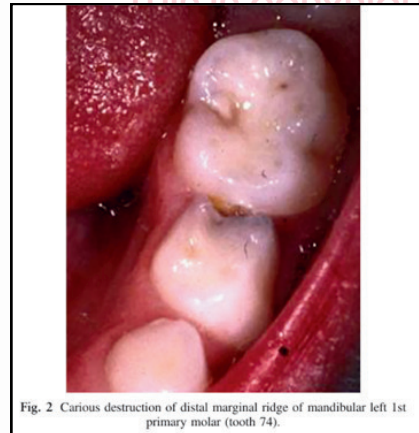
THIS IS COPYRIGHTED CONTENT. Unauthorized use, including screenshots, copying, misuse, reuse, or resale of any content from this app, is strictly prohibited. Our app monitors and records all screenshots and recordings. Violators will face strict legal action.

DISCLAIMER



# PRIMARY TEETH RESTORATIONS

studies, Duggal *et al.*, and later Kassa *et al.*, demonstrated that pulp inflammation in carious primary molars, where caries has caused occluso-proximal cavitation, precedes pulp exposure, and that in a primary molar with a broken-down marginal ridge, due to caries, the adjacent pulp horn is inflamed (Fig. 2). Kassa *et al.* demonstrated that a primary molar with proximal caries extending more than half-way into dentine exhibits more pulpal inflammation (of the adjacent pulp horn), than is seen in pulps of primary molars with only occlusal caries of the same extent (Fig. 3). The authors recommended that pulpotomy, and placement of a pre-formed crown be performed for such teeth (see later).



- After making a diagnosis and treatment plan, clinician must decide **how to restore a tooth and what materials to use.**

## Treatment Options:

- Restoration may be
  - a) Intra-coronal (a filling)
  - b) Extra-coronal (a Crown)

Appropriate restorative methods for primary teeth are: Intracoronal restoration (a "filling") using suitable materials; Extracoronal restoration ("pre-formed crown" – SSCs have the greatest evidence base); Indirect pulp cap + SSC; Pulpotomy + SSC; and, when irreversible pulpitis is diagnosed and the tooth is deemed restorable, Pulpectomy + SSC.

resale of any content from this app, is strictly prohibited. Our app monitors and records all screenshots and recordings. Violators will face strict legal action.

## DISCLAIMER

THIS IS COPYRIGHTED CONTENT. Unauthorized use, including screenshots, copying, misuse, reuse, or resale of any content from this app, is strictly prohibited. Our app monitors and records all screenshots and recordings. Violators will face strict legal action.

## DISCLAIMER

THIS IS COPYRIGHTED CONTENT. Unauthorized use, including screenshots, copying, misuse, reuse, or resale of any content from this app, is strictly prohibited. Our app monitors and records all screenshots and recordings. Violators will face strict legal action.

THIS IS COPYRIGHTED CONTENT. Unauthorized use, including screenshots, copying, misuse, reuse, or resale of any content from this app, is strictly prohibited. Our app monitors and records all screenshots and recordings. Violators will face strict legal action.

DISCLAIMER

# PRIMARY TEETH RESTORATIONS

- The decision for the type of restoration depends on various factors:
  - Caries risk
  - Extent of caries
  - Age of patient
  - Method of treatment (e.g., in office or under general anesthesia)
- Keys to successful restoration in carious primary molars are:

**Table 1. Keys to successful restoration of carious primary molars**

- |   |  |
|---|--|
| 1 | Accurate, ideally early, diagnosis                               |
| 2 | Teeth restored properly, with appropriate materials.             |
| 3 | Due consideration given to pulpal involvement.                   |
| 4 | Pulp therapy performed when indicated.                           |
| 5 | Pre-formed (usually stainless steel) crowns used when indicated. |
| 6 | Rubber dam isolation employed.                                   |

## Material Used for restoration of primary tooth:

- When choosing appropriate material for a given situation, the clinician should consider desirable factors mentioned below:

**Table 2. Desirable factors, to consider when choosing appropriate dental materials**

- |   |  |
|---|--|
| 1 | Ease of handling in practice                   |
| 2 | Adhesion to tooth structure (enamel & dentine) |
| 3 | Physical and chemical qualities                |
| 4 | Longevity of restorations                      |
| 5 | Anti-caries effect                             |
| 6 | Biologic properties of material                |
| 7 | Cost effectiveness                             |
| 8 | Aesthetics                                     |

- Amalgam is not used** for restoration in children.

Following the recommendations of the Minamata Convention on Mercury, Amalgam is no longer indicated for use in children (*viz.* European Union regulation 2017/852, Article 10).

## DISCLAIMER

THIS IS COPYRIGHTED CONTENT. Unauthorized use, including screenshots, copying, misuse, reuse, or resale of any content from this app, is strictly prohibited. Our app monitors and records all screenshots and recordings. Violators will face strict legal action.

## DISCLAIMER

THIS IS COPYRIGHTED CONTENT. Unauthorized use, including screenshots, copying, misuse, reuse, or resale of any content from this app, is strictly prohibited. Our app monitors and records all screenshots and recordings. Violators will face strict legal action.

## DISCLAIMER

THIS IS COPYRIGHTED CONTENT. Unauthorized use, including screenshots, copying, misuse, reuse, or resale of any content from this app, is strictly prohibited. Our app monitors and records all screenshots and recordings. Violators will face strict legal action.

# PRIMARY TEETH RESTORATIONS

- The various materials available in order of preference as well:
  - Pre formed (usually Stainless steel) Crown.**
  - Resin Modified Glass Ionomer (RMGIC)**
  - Compomer (Polyacid modified composite resin)**
  - Resin Based Composite**
  - Conventional Class ionomer (GIC)**

## Advantages and disadvantages of materials:

### a) Pre formed Crowns:

- The indication for use of preformed crowns are given below:

**Table 4. Indications for use of pre-formed crowns**

- |   |  |
|---|--|
| 1 | A carious primary molar with more than two surfaces requiring restoration                    |
| 2 | Where there is insufficient remaining tooth substance to retain an intra-coronal restoration |
| 3 | Following pulp therapy   |
| 4 | For restoration of teeth affected by severe erosion  |
| 5 | As abutments for crown & loop space maintainers  |
| 6 | For patients with certain disabilities, or high caries susceptibility                        |
| 7 | For pre-cooperative or anxious patients (the "Hall technique")                               |

- Pre formed crown can be divided into:

#### i. Pre formed (Stainless Steel) Crowns:

- They have many applications for use on primary molars
- Studies have concluded that "Crowns placed on primary molar teeth with carious lesion or following pulp treatment are likely to reduce the risk of major failure or pain in the long term compared to fillings."

#### ii. Aesthetic Pre formed Crowns:

- These can be **SSC (stainless steel Crown)** with composite veneer or **Zirconia Porcelain Crown.**

##### 1. SSC with composite veneer

- It is more bulky than conventional SSC and more teeth reduction is required when fitting them.
- The preparation and fitting technique are more demanding.
- Less adaptation is possible as only non-veneered areas of the crown can be crimped or contoured.
- Composite may wear or fracture from veneered crown particularly when opposing veneer crowns are in contact.

##### 1. Zirconia Porcelain Crown

- They have very good aesthetics and demonstrate good adaptation to gingival margins.

val margins. The preparation technique for these crowns, however, is demanding; more tooth reduction is required than for alternative crowns, and no adaptation of the crown is possible (the tooth is cut to fit crown). As noted by Seale and Randall,<sup>45</sup> there are no prospective clinical studies relating to Zirconia posterior crowns; therefore, no evidence-based recommendations for their use can be made.

## DISCLAIMER

THIS IS COPYRIGHTED CONTENT. Unauthorized use, including screenshots, copying, misuse, reuse, or resale of any content from this app, is strictly prohibited. Our app monitors and records all screenshots and recordings. Violators will face strict legal action.

DISCLAIMER  
THIS IS COPYRIGHTED CONTENT. Unauthorized use, including screenshots, copying, misuse, reuse, or resale of any content from this app, is strictly prohibited. Our app monitors and records all screenshots and recordings. Violators will face strict legal action.

THIS IS COPYRIGHTED CONTENT. Unauthorized use, including screenshots, copying, misuse, reuse, or resale of any content from this app, is strictly prohibited. Our app monitors and records all screenshots and recordings. Violators will face strict legal action.

DISCLAIMER



# PRIMARY TEETH RESTORATIONS

## HALLS TECHNIQUE With SSC:

- In Hall's technique, the clinician, places a stainless-steel crown on primary molar without local anesthesia, caries removal, or tooth preparation and seats it with finger pressure.
- Excess cement is wiped away, after which the child further seats the crown by biting on a cotton roll placed on the occlusal of the crown

Seale and Randall,<sup>45</sup> summarising their systematic literature review of SSCs noted, with regard to the Hall technique, that it is "supported by good quality evidence and appears to have validity as a technique for placement of SSCs."

- The Hall Crown technique can also be used to prevent caries of mesial surface of First permanent molar adjacent to distal surface caries on primary second molar.

molar. This implies that a carious lesion on the distal of a 2<sup>nd</sup> primary molar should be treated to prevent caries of the mesial surface of FPM. If restorative treatment is indicated for the 2<sup>nd</sup> primary molar (*i.e.*, the lesion has cavitated), intra-coronal restoration of the distal cavity of the 2<sup>nd</sup> primary molar, or traditional SSC placement on the 2<sup>nd</sup> primary molar risks iatrogenic damage to the mesial surface of FPM. Restoration of the 2<sup>nd</sup> primary molar using a Hall crown would obviate this risk. Should a Hall crown be placed, in this circumstance, while the FPM is still erupting, it is important to crimp and contour the distal margin of the crown to prevent impaction of the FPM (Fig. 6).

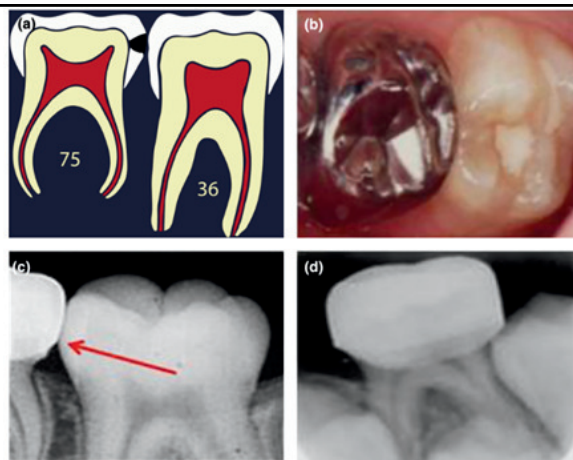


Fig. 6 Preventing mesial caries and preventing iatrogenic damage of 1st permanent molar by use of Hall crown technique. (a) The caries rate for the mesial surface of 1st permanent molar (FPM) is 15 × higher if the distal surface of the 2nd primary molar has developed enamel/enamel-dentin border caries, compared to a sound distal surface of the 2nd primary molar.(Mejare I, *et al.* Caries Res 2001; 35: 178–185). (b) Restoration of the 2nd primary molar with a Hall SSC avoids iatrogenic injury to the mesial surface of FPM. (c & d) Crimp & contour distal margin of Hall crown to prevent impaction of erupting FPM (Fig. 6d).

recordings. Violators will face strict legal action.

### DISCLAIMER

THIS IS COPYRIGHTED CONTENT. Unauthorized use, including screenshots, copying, misuse, reuse, or resale of any content from this app, is strictly prohibited. Our app monitors and records all screenshots and recordings. Violators will face strict legal action.

### DISCLAIMER

THIS IS COPYRIGHTED CONTENT. Unauthorized use, including screenshots, copying, misuse, reuse, or resale of any content from this app, is strictly prohibited. Our app monitors and records all screenshots and recordings. Violators will face strict legal action.

THIS IS COPYRIGHTED CONTENT. Unauthorized use, including screenshots, copying, misuse, reuse, or resale of any content from this app, is strictly prohibited. Our app monitors and records all screenshots and recordings. Violators will face strict legal action.

### DISCLAIMER

# PRIMARY TEETH RESTORATIONS

## b) Resin Modified Glass ionomer (RMGIC)

- RMGIC are glass ionomer cements into which small quantities of monomer are incorporated together with initiators involved in polymerization reaction.

RMGICs share the desirable properties of conventional GICs (adhesion to tooth substance, fluoride release, biocompatibility, and reasonably good aesthetics), while the addition of monomer, and initiators of polymerisation, confers on the materials higher fracture toughness, better wear-resistance, and higher resistance to moisture. With some RMGICs, it is possible to obtain initial photo-polymerisation of the material by exposure to visible light, while later curing of the material occurs via acid-base reaction.<sup>12,16</sup>

- Evidence supports the use of RMGIC for small to moderate size Class II restorations.

## c) Compomers (Polyacid modified resin composites)

- They are light cured restorative materials that has property in common with both GIC and hybrid composites.
- Acid etching is not required yet adhesion to enamel and dentin is made possible by means of conditioning/bonding agents. (e.g, Prime & Bond NT-Dentsply)
- Compomers can be recommended for Class II restoration in primary dentition, but are not recommended for restoration of pulpotomised and pulpectomised primary teeth.

advantages of compomers are: adhesion to tooth substance (by means of priming and bonding agents), better aesthetics than glass ionomers (though inferior to resin composites), the material can be light-cured, relatively high clinical success rates, and better mechanical properties than glass ionomers (lower fracture rates, and less wear). Disadvantages, however, include that placement of compomers is more time-consuming and technically demanding than placement of glass ionomer materials (though less demanding than resin composite placement), isolation with rubber dam is recommended, wear properties of compomers are inferior to those of resin composites, marginal discolouration is worse than for composites, and they are not recommended for restoration of primary molars that have had pulpotomy or pulpectomy.<sup>17,18</sup>

- Fluoride release of compomers is only approximate to 10 % that is released by GIC or RMGIC.
- The main reason for loss of compomers is loss of retention.

### DISCLAIMER

THIS IS COPYRIGHTED CONTENT. Unauthorized use, including screenshots, copying, misuse, reuse, or resale of any content from this app, is strictly prohibited. Our app monitors and records all screenshots and recordings. Violators will face strict legal action.

### DISCLAIMER

THIS IS COPYRIGHTED CONTENT. Unauthorized use, including screenshots, copying, misuse, reuse, or resale of any content from this app, is strictly prohibited. Our app monitors and records all screenshots and recordings. Violators will face strict legal action.

THIS IS COPYRIGHTED CONTENT. Unauthorized use, including screenshots, copying, misuse, reuse, or resale of any content from this app, is strictly prohibited. Our app monitors and records all screenshots and recordings. Violators will face strict legal action.

### DISCLAIMER



# PRIMARY TEETH RESTORATIONS

## d) Resin Based Composite:

- They are esthetic, not inherently adhesive but can be bonded to enamel with proprietary resins, following acid etching, washing, and drying of enamel. This is a time-consuming process when restoring primary molars.
- They are technique sensitive and ideally be placed using rubber dam isolation.
- They do not release fluoride and are relatively expensive materials.
- A major disadvantage is polymerization shrinkage which can lead to leaking restoration margins. This increases the potentiality of secondary caries.

age.<sup>26</sup> As resin-based composites are the most time-consuming and most technique-sensitive materials, and have potential for marginal leakage, they are generally unsuitable for class II intra-coronal restorations in primary teeth, particularly if the child is uncooperative, and/or at high caries risk.<sup>26,27</sup>

## e) Conventional Glass ionomer (GIC)

- They are derived from organic acids (usually aqueous polymeric acid) and a glass component (mostly fluoroaluminosilicate glass)
- These materials set by acid-base reaction, initiated by mixing the components.
- Major advantage is that it acts as a fluoride reservoir.

tage of GICs. Fluoride is used as a flux during the manufacture of the glass powder component of GICs. It gradually leaches from the set cement, within the first few months. The set GIC has the capacity, thereafter, to take up more fluoride from the oral environment, which is then gradually leached from the material, seemingly for the entire time the restoration remains *in situ*. The GIC restoration, therefore, acts as a fluoride reservoir.<sup>12</sup>

- However, it has poor compressive and tensile strength compared to other materials.
- Surface roughness, poor color stability and poor resistance to wear is also a problem.
- When used in Class II restorations in primary molars, conventional GICs have been shown to perform poorly.

### DISCLAIMER

THIS IS COPYRIGHTED CONTENT. Unauthorized use, including screenshots, copying, misuse, reuse, or resale of any content from this app, is strictly prohibited. Our app monitors and records all screenshots and recordings. Violators will face strict legal action.

### DISCLAIMER

THIS IS COPYRIGHTED CONTENT. Unauthorized use, including screenshots, copying, misuse, reuse, or resale of any content from this app, is strictly prohibited. Our app monitors and records all screenshots and recordings. Violators will face strict legal action.

THIS IS COPYRIGHTED CONTENT. Unauthorized use, including screenshots, copying, misuse, reuse, or resale of any content from this app, is strictly prohibited. Our app monitors and records all screenshots and recordings. Violators will face strict legal action.

### DISCLAIMER



# PRIMARY TEETH RESTORATIONS

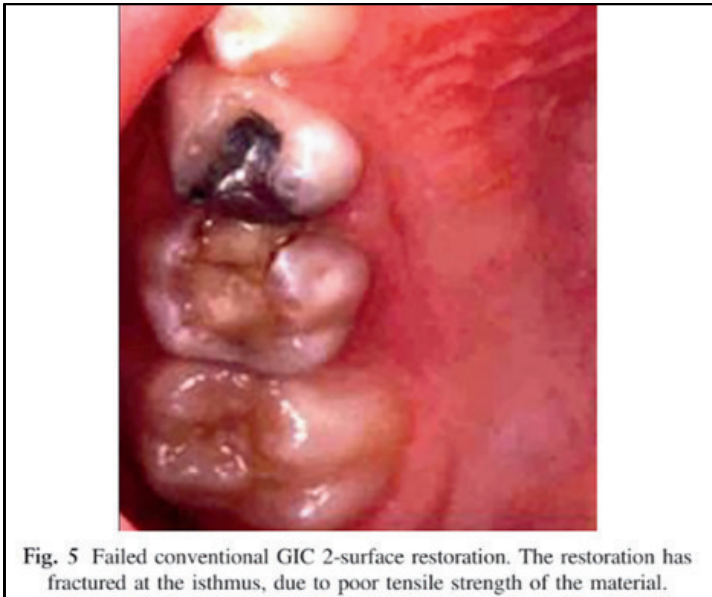


Fig. 5 Failed conventional GIC 2-surface restoration. The restoration has fractured at the isthmus, due to poor tensile strength of the material.

## Restoration of Primary Incisors:

- It is commonly achieved by the use of Composite Strip Crown technique or preformed crowns (Composite veneered SSC- or zirconia porcelain crowns)

lain crowns). Very little scientific evidence is available regarding the restoration of primary incisors. An evidence-based systematic literature review of anterior restorations for primary teeth, by Waggoner,<sup>73</sup> published 2006, revealed that failure rates for strip crowns ranged from 0 to 50%; while the failure rate for veneered anterior SSCs ranged 32–39%. Other authors have reported, from retrospective studies, the retention of anterior strip crowns on primary teeth to be 80% after 24–36 months.<sup>74,75</sup>

THIS IS COPYRIGHTED CONTENT. Unauthorized use, including screenshots, copying, misuse, reuse, or resale of any content from this app, is strictly prohibited. Our app monitors and records all screenshots and recordings. Violators will face strict legal action.

**DISCLAIMER**  
THIS IS COPYRIGHTED CONTENT. Unauthorized use, including screenshots, copying, misuse, reuse, or resale of any content from this app, is strictly prohibited. Our app monitors and records all screenshots and recordings. Violators will face strict legal action.

THIS IS COPYRIGHTED CONTENT. Unauthorized use, including screenshots, copying, misuse, reuse, or resale of any content from this app, is strictly prohibited. Our app monitors and records all screenshots and recordings. Violators will face strict legal action.

## DISCLAIMER

THIS IS COPYRIGHTED CONTENT. Unauthorized use, including screenshots, copying, misuse, reuse, or resale of any content from this app, is strictly prohibited. Our app monitors and records all screenshots and recordings. Violators will face strict legal action.

**DISCLAIMER**

THIS IS COPYRIGHTED CONTENT. Unauthorized use, including screenshots, copying, misuse, reuse, or resale of any content from this app, is strictly prohibited. Our app monitors and records all screenshots and recordings. Violators will face strict legal action.

# BEHAVIOR MANAGEMENT

(Source- Literature review on Contemporary behavior techniques in Clinical Pediatric Techniques)

- Behavior management is the cornerstone for the success of pediatric dentistry in managing children.
- The use of Behavior management techniques (BMTs) allows children to learn appropriate behavior and coping skills, reduce anxiety and facilitate the delivery of adequate oral health care.
- BMTs are based on the understanding of social, emotional and cognitive development of children to enable effective communication and establish social and behavioral guidelines during dental treatment.
- The utilization of behavioral management techniques has evolved with the change in children's, parents and society's expectations.
- Behavioral management should be flexible and individualized for each child.
- The choice of BMTs used will depend on the knowledge, training, expertise and philosophy of the dentist and his/her ability to deliver the chosen techniques.

Changes in education at the undergraduate and post-graduate level influence techniques used by contemporary dentists. For example, current programs teach aversive techniques with less of an emphasis on the use of pharmacological and communicative techniques.<sup>35,51</sup> Younger dentists are more likely to use modeling, TSD, contingent escape, and contingent reinforcement through rewards and praise than aversive techniques.<sup>9,51, 52</sup>

## Behavioral management Techniques:

- It includes:

### a) Non-pharmacological techniques:

- i. Tell Show Do (most effective and commonly used)
- ii. Non- verbal communication and Voice control
- iii. Behavior shaping and contingent reinforcement
- iv. Modeling
- v. Distraction
- vi. Changing control (Temporary Escape)
- vii. Systematic Desensitization
- viii. Protective Stabilization (Restraint)

### b) Pharmacological Techniques:

- i. Anxiolysis with nitrous oxides (minimal sedation)
- ii. Conscious sedation
- iii. General anesthesia

## DISCLAIMER

THIS IS COPYRIGHTED CONTENT. Unauthorized use, including screenshots, copying, misuse, reuse, or resale of any content from this app, is strictly prohibited. Our app monitors and records all screenshots and recordings. Violators will face strict legal action.

## DISCLAIMER

THIS IS COPYRIGHTED CONTENT. Unauthorized use, including screenshots, copying, misuse, reuse, or resale of any content from this app, is strictly prohibited. Our app monitors and records all screenshots and recordings. Violators will face strict legal action.

THIS IS COPYRIGHTED CONTENT. Unauthorized use, including screenshots, copying, misuse, reuse, or resale of any content from this app, is strictly prohibited. Our app monitors and records all screenshots and recordings. Violators will face strict legal action.

## DISCLAIMER

# BEHAVIOR MANAGEMENT

## c) Modern Alternative techniques:

- These are several alternative methods that includes child-centered care, magic tricks, hypnosis, memory reconstructing strategy and motivational interviewing.
- These techniques do not replace the old strategies but add to the armamentarium available to the pediatric dentist.
- E.g., With magic tricks, the child is shown a trick to reduce the level of anxiety and encourage them to have positive behavior in the dental environment.

## d) Old and rarely used techniques:

### i. Parental presence/ Absence

- It is a contingent reinforcement technique where the parent is removed from the operatory in response to undesired behavior as a punisher, and returned to the operatory in response to desired behavior.
- Routine removal of parents from the dental operatory is not favored by modern parents who often express the desire to know how the child is treated.

know how their child is treated. Parental presence allows a parent to be involved in their child's care, witness their child's behavior, observe the quality of dental care provided, and provide consent for changes in treatment and management of behavior.<sup>6</sup> A British study on

- Setting limits and boundaries for parental participation and encouragement of favorable parental involvement (i.e., sitting within the view of the patient and offering and appropriate and timely reassuring touch or phrase) is more effective.

### ii. Hand Over Mouth Exercise (HOME)

- This technique involves placing dentist's hand over mouth of a screaming child to gain their attention.
- It is accompanied by voice control and instructions on desired behavior should the child want the hand removed.
- It is dying technique. HOME is now actually taught as an example of unacceptable technique.

#### DISCLAIMER

THIS IS COPYRIGHTED CONTENT. Unauthorized use, including screenshots, copying, misuse, reuse, or resale of any content from this app, is strictly prohibited. Our app monitors and records all screenshots and recordings. Violators will face strict legal action.

#### DISCLAIMER

THIS IS COPYRIGHTED CONTENT. Unauthorized use, including screenshots, copying, misuse, reuse, or resale of any content from this app, is strictly prohibited. Our app monitors and records all screenshots and recordings. Violators will face strict legal action.

THIS IS COPYRIGHTED CONTENT. Unauthorized use, including screenshots, copying, misuse, reuse, or resale of any content from this app, is strictly prohibited. Our app monitors and records all screenshots and recordings. Violators will face strict legal action.

#### DISCLAIMER



# BEHAVIOR MANAGEMENT

## A) Non-Pharmacological:

### 1) Tell Show Do (TSD) Technique:

- TSD is a communication technique used universally by pediatric dentists combining communication with contingent reinforcement.
- It familiarizes the child with procedures and different aspects of dental environment in a manner that minimizes anxiety through familiarization with positive reinforcement and desensitization.
- It involves 3 phases:

#### a) The “tell” component:

- It is a simple explanation of the procedure in language appropriate to child’s cognitive level and understanding.

#### b) The “show” component:

- The procedure is demonstrated using tactile sensation and as many sensory modalities as possible.

#### c) The “do” component:

- The do phase should follow the show phase without any delay and should be accompanied with positive reinforcement of desired behavior.

### 2) Non-Verbal Communication and Voice Control:

- Children mostly on the preoperational stage (2-7 years Jean Piaget’s stages of cognitive development) are acutely responsive to nonverbal communication and voice control as they do not have sophisticated understanding of verbal language.
- A gentle touch on the shoulder can relax and reassure a patient more than verbal communications.
- Voice control is a modulation of tone, volume, pace and pitch of voice to control and guide behavior.
- Voice control can suppress disruptive and adverse behavior effectively within 2 seconds and last up to 2 minutes.
- Voice control is most effective when combined with non-verbal cues.

### 3) Behavior Shaping and contingent Reinforcement

- It involves the modification of behavior through the use of reinforcers, that strengthens the pattern of desired behaviors and limits undesirable behaviors.

#### • Reinforces can be:

a) **Social reinforcers:** It includes Praise, Non-verbal communication, positive voice modulation and approval from parents

b) **Non social reinforcers:** Tokens or rewards like stickers.

- To be most effective in behavior modifications reinforcers must be applied immediately and consistently after the desired behavior.

- Behavior that is not rewarded is less likely to be repeated.

- Punishment is the removal of something of value to the child in response to inappropriate behavior.

#### DISCLAIMER

THIS IS COPYRIGHTED CONTENT. Unauthorized use, including screenshots, copying, misuse, reuse, or resale of any content from this app, is strictly prohibited. Our app monitors and records all screenshots and recordings. Violators will face strict legal action.

DISCLAIMER

THIS IS COPYRIGHTED CONTENT. Unauthorized use, including screenshots, copying, misuse, reuse, or resale of any content from this app, is strictly prohibited. Our app monitors and records all screenshots and recordings. Violators will face strict legal action.

THIS IS COPYRIGHTED CONTENT. Unauthorized use, including screenshots, copying, misuse, reuse, or resale of any content from this app, is strictly prohibited. Our app monitors and records all screenshots and recordings. Violators will face strict legal action.

DISCLAIMER

# BEHAVIOR MANAGEMENT

## A) Non-Pharmacological:

### 3) Behavior Shaping and contingent Reinforcement

the child in response to inappropriate behavior. When used as a "time out" rather than a punishment, it can be effective, but requires communication with the child about why the action had occurred and what behavior will result in the return of the object of value.<sup>9,17</sup>

### 4) Modeling

- Modeling relies upon the theory that behaviors are learned from observing and imitating others.
- Most Effective in 4-9 years old children esp. when introducing them to new environment or new procedure.
- Most effective when models are of similar age or are perceived to have prestige or status to the child (brother or sisters)
- The model child should exhibit the desired behavior with minimal anxiety, and is rewarded with positive reinforcement.

### 5) Distraction:

- Distraction or deflection of a patient's attention away from potentially fear inducing stimulus or situations is an established and effective behavior management technique in pediatric dentistry.
- Methods of distractions include verbal distractions, cartoons, audio-visual glasses, magic tricks, music and eye movement desensitization reprocessing.

Limited evidence exists for the efficacy of distraction, depending on the modality of distraction utilized; however, regardless of the ability to prevent negative behavior, distraction has the potential for mental escape, making treatment and potentially negative experiences more pleasant for children.<sup>21</sup> Video eyeglasses have been reported to reduce physically disruptive behaviors significantly in children during restorative treatment and improve patient satisfaction compared with the use of plain glasses or nitrous oxide alone.<sup>24,25</sup> The use of distraction with video eyeglasses may also be considered a good adjunct or alternative to nitrous oxide sedation, with one study comparing the behavior between the two modalities showing no significant differences but an overall reduction in negative behavior with both modalities for restorative procedures.<sup>24</sup>

#### DISCLAIMER

THIS IS COPYRIGHTED CONTENT. Unauthorized use, including screenshots, copying, misuse, reuse, or resale of any content from this app, is strictly prohibited. Our app monitors and records all screenshots and recordings. Violators will face strict legal action.

#### DISCLAIMER

THIS IS COPYRIGHTED CONTENT. Unauthorized use, including screenshots, copying, misuse, reuse, or resale of any content from this app, is strictly prohibited. Our app monitors and records all screenshots and recordings. Violators will face strict legal action.

THIS IS COPYRIGHTED CONTENT. Unauthorized use, including screenshots, copying, misuse, reuse, or resale of any content from this app, is strictly prohibited. Our app monitors and records all screenshots and recordings. Violators will face strict legal action.

#### DISCLAIMER

# BEHAVIOR MANAGEMENT

## A) Non-Pharmacological:

### 6) Changing Control/ Temporary Escape

- Enhancing control or temporary escape allows the patient to have some degree of control over their situation.
- It also enhances their ability to communicate (like when the patient requires arrest, is in pain, or needs the dentist to stop)
- Most common method used for temporary escape is the use of “stop” signal, by raising the hand in stop sign motion.
- It incorporates an empathetic approach in organizing the need for escape and acknowledging the emotions and perspective of a child.

### 7) Systematic Desensitization:

- It aims to reduce anxiety through the gradual presentation of anxiety or fear inducing stimulus while the child is either in a relaxed state or in the presence of neutral or positive stimulus.
- It includes 4 steps:
  1. Identifying the problem and its history.
  2. Introducing relaxation techniques.
  3. Creating a ranked inventory of fear or anxiety inducing stimuli
  4. Exposing the patient to the stimulus from the inventory while practicing relaxation techniques.
- It is critical that the dentist does not progress to next stimulus unless behavior has improved and is either neutral or relaxed.

Systematic desensitization is highly beneficial for the patient; however, it is not always viewed as a cost-effective use of time and may require the use of a psychologist to teach relaxation techniques and address the origin of specific fears.

### 8) Protective Stabilization (Restraint)

- AAPD defines it as “the restriction of patient’s freedom of movement, with or without patient’s permission, to decrease risk of injury while allowing safe completion of treatment.
- The restriction of movement can involve:
  - a) Use of stabilization device: Pedi wrap and papoose Board
  - b) Another person
  - c) Combination of these two
- It is less acceptable to parents than other methods of BMTs, including sedation and GA (General anesthesia).

#### DISCLAIMER

THIS IS COPYRIGHTED CONTENT. Unauthorized use, including screenshots, copying, misuse, reuse, or resale of any content from this app, is strictly prohibited. Our app monitors and records all screenshots and recordings. Violators will face strict legal action.

#### DISCLAIMER

THIS IS COPYRIGHTED CONTENT. Unauthorized use, including screenshots, copying, misuse, reuse, or resale of any content from this app, is strictly prohibited. Our app monitors and records all screenshots and recordings. Violators will face strict legal action.

THIS IS COPYRIGHTED CONTENT. Unauthorized use, including screenshots, copying, misuse, reuse, or resale of any content from this app, is strictly prohibited. Our app monitors and records all screenshots and recordings. Violators will face strict legal action.

#### DISCLAIMER



# BEHAVIOR MANAGEMENT

## A) Non-Pharmacological:

### 8) Protective Stabilization (Restraint)

- It may be indicated for patients who require immediate/emergency treatment and are pre-cooperative or are unable to cooperate due to disability.
- Explicit Informed consent should be achieved prior to use of protective stabilization.
- It should never be used as a punishment.
- Precautions to be taken if using protective stabilization:

1. Carefully assess and review the medical history for conditions that may contribute to the restriction of respiration and a compromised airway, or those that can lead to bone fractures.
2. Avoid using in children with a history of psychological or physical trauma from a previous use of protective stabilization.
3. Stringently monitor the patient during stabilization, assessing for tightness, respiration, and circulation.
4. Abandon the use of protective stabilization if the patient becomes hysterical, distressed, or sustains physical trauma, or if a parent withdraws consent.

## B) Pharmacological Methods:

- The use of pharmacological method may be required for children who cannot overcome dental fear and anxiety, cannot be communicated with, are pre-cooperative and have special needs.
- **Nitrous oxide or Conscious sedation** may be used as an adjunct to non-pharmacological BMT to enhance patient communication, reduce anxiety and facilitate safe delivery of care

Sedation using nitrous oxide has been shown to reduce anxiety and fear in subsequent restorative appointments.<sup>34</sup> Following the removal of the hand-over-mouth technique from the AAPD guidelines, there has been a greater reliance on sedation and general anesthesia, with greater time devoted to the teaching of advanced pharmacological techniques in advanced dental education.<sup>35,36</sup> The decision to use pharmacological behavior management must involve consideration of alternative BMTs, the patient's dental needs, the quality of dental care that can be provided, the child's emotional and cognitive development, the child's general health, and the knowledge and experience of the clinician.<sup>4,8,33</sup>

### DISCLAIMER

THIS IS COPYRIGHTED CONTENT. Unauthorized use, including screenshots, copying, misuse, reuse, or resale of any content from this app, is strictly prohibited. Our app monitors and records all screenshots and recordings. Violators will face strict legal action.

### DISCLAIMER

THIS IS COPYRIGHTED CONTENT. Unauthorized use, including screenshots, copying, misuse, reuse, or resale of any content from this app, is strictly prohibited. Our app monitors and records all screenshots and recordings. Violators will face strict legal action.

THIS IS COPYRIGHTED CONTENT. Unauthorized use, including screenshots, copying, misuse, reuse, or resale of any content from this app, is strictly prohibited. Our app monitors and records all screenshots and recordings. Violators will face strict legal action.

DISCLAIMER

# BEHAVIOR MANAGEMENT

## Parental Acceptance of Techniques:

The type of dental treatment required will influence which techniques are acceptable for parents. For healthy, developmentally normal children, the use of communicative techniques is acceptable for all procedures. However, the use of protective stabilization for radiography, examination, or simple preventive procedures is not viewed as acceptable by parents.<sup>30,32</sup> Parents of children with developmental delays and autism spectrum disorders are, in general, much more accepting of more advanced or aversive techniques.<sup>47</sup> Informed consent, with an explanation of procedures, indications, contraindications, and alternative techniques, achieves greater acceptance by parents.<sup>31,48-50</sup>

resale of any content from this app, is strictly prohibited. Our app monitors and records all screenshots and recordings. Violators will face strict legal action.

THIS IS COPYRIGHTED CONTENT. Unauthorized use, including screenshots, copying, misuse, reuse, or resale of any content from this app, is strictly prohibited. Our app monitors and records all screenshots and recordings. Violators will face strict legal action.

### DISCLAIMER

THIS IS COPYRIGHTED CONTENT. Unauthorized use, including screenshots, copying, misuse, reuse, or resale of any content from this app, is strictly prohibited. Our app monitors and records all screenshots and recordings. Violators will face strict legal action.

THIS IS COPYRIGHTED CONTENT. Unauthorized use, including screenshots, copying, misuse, reuse, or resale of any content from this app, is strictly prohibited. Our app monitors and records all screenshots and recordings. Violators will face strict legal action.

**DISCLAIMER**  
THIS IS COPYRIGHTED CONTENT. Unauthorized use, including screenshots, copying, misuse, reuse, or resale of any content from this app, is strictly prohibited. Our app monitors and records all screenshots and recordings. Violators will face strict legal action.

**DISCLAIMER**

THIS IS COPYRIGHTED CONTENT. Unauthorized use, including screenshots, copying, misuse, reuse, or resale of any content from this app, is strictly prohibited. Our app monitors and records all screenshots and recordings. Violators will face strict legal action.

THIS IS COPYRIGHTED CONTENT. Unauthorized use, including screenshots, copying, misuse, reuse, or resale of any content from this app, is strictly prohibited. Our app monitors and records all screenshots and recordings. Violators will face strict legal action.

# CHILD ABUSE MANAGEMENT

(Source: Odell Case 36, Oral and Dental Aspects of Child Abuse and Neglect: Clinical Report (AAPD-September 24))

- It is common for dentists to be aware of or suspect that a patient attending their practice has experienced domestic violence/ abuse.
- Child abuse and neglect is a broad term covering any intentional and non-intentional behaviors by parents, caregivers, or other adults considered to be in a position of responsibility, trust or power that results in a child being harmed physically or emotionally (AIFS 2014; WHO 1999)

## Box 1: Defining child maltreatment

Child maltreatment includes physical, sexual and emotional abuse, and neglect inflicted upon a child by a person responsible for their care and wellbeing.

**Physical abuse** includes any non-accidental physical act inflicted upon a child that causes harm.

**Sexual abuse** includes any act that exposes the child to, or involves the child in, sexual processes beyond their understanding, or contrary to accepted community standards.

**Emotional abuse** includes any act that results in the child suffering significant emotional deprivation or trauma, including suffering caused by exposure to family and domestic violence.

**Neglect** includes any serious act or omission that, within the bounds of cultural tradition, constitutes a failure to provide conditions essential for the healthy physical and emotional development of a child (AIHW 2019a).

- **Child abuse is defined in four categories: physical abuse, emotional abuse, sexual abuse and neglect.**
- Abuse or neglect may be by inflicting harm or by failing to prevent harm.
- Effects of child abuse and neglect can be physical, emotional, and behavioral, and can last a lifetime
- Abuse can include physical and sexual abuse and may be evidenced by bite marks, dental neglect, and medical child abuse (MCA).
- Bullying and the human trafficking of children also occur and can have serious long-term effects.
- Abuse and neglect may be the presenting problem, noticed during a physical examination, or children or adolescents may disclose information about these experiences.
- It is important for pediatricians, dental professionals, and other physicians to be alert to and knowledgeable about signs and symptoms of child abuse and neglect and to know how to respond.
- Identifying and reporting suspected abuse can be challenging for pediatricians, dental professionals, and other physicians but has the potential to interrupt the cycle of abuse, secure the child's safety, and in some cases, save the child's life.

## DISCLAIMER

THIS IS COPYRIGHTED CONTENT. Unauthorized use, including screenshots, copying, misuse, reuse, or resale of any content from this app, is strictly prohibited. Our app monitors and records all screenshots and recordings. Violators will face strict legal action.

## DISCLAIMER

THIS IS COPYRIGHTED CONTENT. Unauthorized use, including screenshots, copying, misuse, reuse, or resale of any content from this app, is strictly prohibited. Our app monitors and records all screenshots and recordings. Violators will face strict legal action.

## DISCLAIMER

THIS IS COPYRIGHTED CONTENT. Unauthorized use, including screenshots, copying, misuse, reuse, or resale of any content from this app, is strictly prohibited. Our app monitors and records all screenshots and recordings. Violators will face strict legal action.



# CHILD ABUSE MANAGEMENT

## Physical Abuse

- In one study, 27.5% of abused infants had a previous minor but inflicted injury that had been recognized by a parent or physician but usually not reported to authorities.
- The majority of these “sentinel injuries” involved bruising to the face, forehead, or ear.
- The mnemonic TEN-4 (Torso, Ear, or Neck in children less than or equal to 4 years of age, and anywhere in an infant under 4 months of age) has been widely adopted to assist in identifying bruises concerning for abuse.
- An expanded mnemonic with improved sensitivity for identifying abusive bruise injuries has since been introduced: TEN-4-FACES (Torso, Ear, Neck, Frenulum, Angle of jaw, Cheeks, Eyelids, Subconjunctivae in children younger than 4 years, bruising anywhere in infants younger than 5 months, or patterned bruising).
- Because of their exposed location on the body and anatomic complexity, the head and face are more vulnerable to serious injury than are other body regions.
- Recent research has found that children younger than 4 years with orofacial (especially cheek, ear, jaw, and frenum) and torso bruising are at risk for having been physically abused and are at risk for future, more serious abuse.
- Physical abuse may result in contusions; burns or lacerations of the tongue, lips, buccal mucosa, palate (soft and hard), gingiva, alveolar mucosa, or frenum; fractured, displaced, or avulsed teeth or facial bone and jaw fractures
- Lacerations to the oral frena in premobile infants are often the result of physical abuse and are frequently associated with other findings of serious physical abuse.
- Trauma to the teeth may result in pulpal necrosis, leaving the teeth gray and discolored.
- Gags applied to the mouth may result in bruises, lichenification, or scarring at the corners of the mouth
- All findings in cases in which there is reasonable suspicion of abuse or neglect, regardless of mechanism, need to be reported for further investigation.
- Unintentional or accidental injuries to the mouth are common and may be distinguished from abuse by judging whether the history (including the timing and mechanism of the injury) is consistent with the characteristics of the injury and the child’s developmental capabilities.
- Multiple injuries, injuries in different stages of healing, or a discrepant history ought to arouse suspicion for abuse.

including screenshots, copying, misuse, reuse, or resale of any content from this app, is strictly prohibited. Our app monitors and records all screenshots and recordings. Violators will face strict legal action.

### DISCLAIMER

THIS IS COPYRIGHTED CONTENT. Unauthorized use, including screenshots, copying, misuse, reuse, or resale of any content from this app, is strictly prohibited. Our app monitors and records all screenshots and recordings. Violators will face strict legal action.

### DISCLAIMER

THIS IS COPYRIGHTED CONTENT. Unauthorized use, including screenshots, copying, misuse, reuse, or resale of any content from this app, is strictly prohibited. Our app monitors and records all screenshots and recordings. Violators will face strict legal action.

# CHILD ABUSE MANAGEMENT

## Sexual Abuse:

- The oral cavity is a frequent site of sexual abuse in children, and acquisition of sexually transmitted infections (STIs) via this route can occur.
- Testing for STIs within the oral cavity may be considered when:
  - i. The child gives a history of oral–genital contact
  - ii. The child has experienced penetration or has evidence of recent or healed penetrative injury to the genitals, anus, or oropharynx
  - iii. The child has been abused by a stranger
  - iv. The child has been abused by an assailant known to be infected with oral high risk for STIs
  - v. The child has a sibling, other relative, or household contact with an STI
  - vi. The child lives in an area with a high rate of STIs in the community
  - vii. The child has signs or symptoms of an STI (e.g., vaginal discharge, genital itching or odor, urinary symptoms, or genital lesions)
  - viii. The child or the parent of a prepubertal child requests STI testing
- The child is unable to verbalize details of the assault.

## Medical Child Abuse:

- MCA, also known as “Munchausen syndrome by proxy” and “caregiver fabricated-illness,” is a form of child maltreatment in which a caregiver subjects a child to unnecessary and potentially harmful medical care because of the caregiver’s exaggeration, falsification, or induction of an illness or medical condition.
- These children are subjected to unnecessary medical interventions, diagnostic tests, repeated examinations, surgeries, and medications.
- There is no typical presentation of MCA, although commonly, the fabricated illness involves multiple organ systems.
- Apnea, seizures, feeding problems, bleeding, and rashes are frequently reported symptom.
- Making a diagnosis of MCA can be difficult because of false information provided and/or induction of illness by the caregiver.
- Numerous medical professionals from various specialties and institutions are often involved in treating these patients.
- Diagnosing MCA may require a thorough review of all available medical records, which is often voluminous and can be time consuming, but is needed to discover concerning patterns and make the correct diagnosis.

## DISCLAIMER

THIS IS COPYRIGHTED CONTENT. Unauthorized use, including screenshots, copying, misuse, reuse, or resale of any content from this app, is strictly prohibited. Our app monitors and records all screenshots and recordings. Violators will face strict legal action.

DISCLAIMER  
THIS IS COPYRIGHTED CONTENT. Unauthorized use, including screenshots, copying, misuse, reuse, or resale of any content from this app, is strictly prohibited. Our app monitors and records all screenshots and recordings. Violators will face strict legal action.

DISCLAIMER

THIS IS COPYRIGHTED CONTENT. Unauthorized use, including screenshots, copying, misuse, reuse, or resale of any content from this app, is strictly prohibited. Our app monitors and records all screenshots and recordings. Violators will face strict legal action.

# CHILD ABUSE MANAGEMENT

## Bite Marks on Skin:

- Acute or healed bite marks on the skin may indicate abuse.
- Dentists trained as forensic odontologists can assist pediatricians, other dental professionals, and physicians in the detection and evaluation of bite marks related to physical and sexual abuse.
- Bite marks on the skin need to be suspected when ecchymoses, abrasions, or lacerations are found in an elliptical, horseshoe-shaped, or ovoid pattern.
- Frequently, bite marks are found on the cheeks, back, sides, arms, buttocks, and genitalia.
- Bites produced by dogs and other carnivorous animals tend to tear flesh, whereas human bites compress flesh and can cause abrasions, contusions, and lacerations, but rarely avulsions of tissue.
- An intercanine distance (i.e., the linear distance between the central point of the cuspid tips) measuring more than 3.0 cm is suspicious for an adult human bite.
- The pattern, size, contour, color, and evolution of a bite mark ideally can be evaluated by a forensic odontologist.
- If a specialist is unavailable, a child abuse pediatrician or pediatric dental professional experienced in identifying the patterns of child abuse injuries may examine and document the bite mark characteristics photographically with an identification tag and scale marker (e.g., ruler) in the photograph.

## Dental Neglect:

- Dental neglect, as defined by the American Academy of Pediatric Dentistry, is the “willful failure of parent or guardian, despite adequate access to care, to seek and follow through with treatment necessary to ensure a level of oral health essential for adequate function and freedom from pain and infection.”
- Dental neglect is the most frequent type of abuse seen by dentists and can be challenging to identify because it is chronic and insidious in nature.
- Some children who present for dental care have severe early childhood caries (formerly termed “infant bottle” or “nursing” caries).
- It is important to differentiate between caregivers with adequate knowledge but willful failure to seek care, from those caregivers with barriers to care or those without knowledge or awareness of their child’s need for dental care
- This will determine the need to report such cases to child protective services.
- Several factors are considered necessary for the diagnosis of neglect :
  - i. A child is harmed or at risk for harm because of lack of dental health care
  - ii. The recommended dental care offers significant net benefit to the child
  - iii. The anticipated benefit of the dental treatment is significantly greater than its morbidity, so parents would likely choose treatment over nontreatment
  - iv. Access to health/dental care is available but not used
  - v. The parent understands the dental advice given.

## DISCLAIMER

THIS IS COPYRIGHTED CONTENT. Unauthorized use, including screenshots, copying, misuse, reuse, or resale of any content from this app, is strictly prohibited. Our app monitors and records all screenshots and recordings. Violators will face strict legal action.

## DISCLAIMER

THIS IS COPYRIGHTED CONTENT. Unauthorized use, including screenshots, copying, misuse, reuse, or resale of any content from this app, is strictly prohibited. Our app monitors and records all screenshots and recordings. Violators will face strict legal action.

THIS IS COPYRIGHTED CONTENT. Unauthorized use, including screenshots, copying, misuse, reuse, or resale of any content from this app, is strictly prohibited. Our app monitors and records all screenshots and recordings. Violators will face strict legal action.

## DISCLAIMER



# CHILD ABUSE MANAGEMENT

## Dental Neglect:

- The point at which to consider a parent negligent and begin intervention occurs after the parent has been properly alerted by a pediatrician, dental professional, or other physician about the nature and extent of the child's condition, the specific treatment needed, and the mechanism of accessing that treatment.
- Pediatricians, dental professionals, and other physicians can make a reasonable effort to help caregivers understand the explanation of the dental disease and its implications, the risks and benefits of dental treatment, and the use of the appropriate analgesic and anesthetic during the procedure to ensure the child's comfort.
- Assistance can be provided to the family in finding financial aid, transportation, or public facilities for needed services.
- If, despite these efforts, the parent fails to obtain therapy, the case warrants reporting to the appropriate child protective services agency.
- Once dental problems have been explained to parents or carers, and appropriate and acceptable dental treatment has been offered to restore oral health, the following would be of concern:
  - a) Repeated missed appointments
  - b) Failure to complete planned treatment
  - c) Repeatedly returning in pain
  - d) Requiring repeated GA for dental extractions.
- Preschool children are particularly vulnerable.

## Risk Factors for Child abuse or Neglect

TABLE 36.1 Risk Factors for Child Abuse and Neglect		
Parental	Social	Child
Parents needing additional support to meet child's needs	Families living in adverse social environments	Children in need of additional help to safeguard their welfare
Young parents	Poverty	Babies and toddlers are most vulnerable
Single parents	Social isolation	Children with disabilities
Parents with learning difficulties	Poor housing	Older children, particularly girls, are more vulnerable to sexual abuse
Mental health problems	Family violence	Children with behavioural problems
Drug and alcohol abuse		Children looked after in foster care or residential care

Image: Odell Case 36

### DISCLAIMER

THIS IS COPYRIGHTED CONTENT. Unauthorized use, including screenshots, copying, misuse, reuse, or resale of any content from this app, is strictly prohibited. Our app monitors and records all screenshots and recordings. Violators will face strict legal action.

### DISCLAIMER

THIS IS COPYRIGHTED CONTENT. Unauthorized use, including screenshots, copying, misuse, reuse, or resale of any content from this app, is strictly prohibited. Our app monitors and records all screenshots and recordings. Violators will face strict legal action.

THIS IS COPYRIGHTED CONTENT. Unauthorized use, including screenshots, copying, misuse, reuse, or resale of any content from this app, is strictly prohibited. Our app monitors and records all screenshots and recordings. Violators will face strict legal action.

### DISCLAIMER

# CHILD ABUSE MANAGEMENT

## Recommendations:

- Pediatricians, dental professionals, and other physicians must report injuries that are concerning for abuse or neglect to child protective services in accordance with local or state legal requirements.
- In cases of sexual abuse that may involve the mouth, even without overt signs, pediatricians, dental professionals, and other physicians should know how to collect a history to elicit this information and to perform oral STI testing using appropriate tests to support forensic investigations. When sexual abuse is suspected or diagnosed in a child, the case needs to be reported to child protective services and/or law enforcement agencies for investigation. A multidisciplinary child abuse evaluation for the child and family is preferred when available
- Consultation with a child abuse pediatrician may be helpful when a pediatrician, dental professional, or other physician suspects MCA.
- Because ABFO guidelines no longer endorse positive identification of a suspect dentition to a bite mark, pediatricians, dental professionals, and other physicians should consult with a forensic odontologist, pediatric dentist experienced in forensic issues, or child abuse pediatrician for help in evaluating bite marks.
- Pediatricians, dental professionals, and other physicians are encouraged to consult with colleagues on challenging cases and collaborate with them to provide education and support toward improved identification of child maltreatment.

DISCLAIMER

THIS IS COPYRIGHTED CONTENT. Unauthorized use, including screenshots, copying, misuse, reuse, or resale of any content from this app, is strictly prohibited. Our app monitors and records all screenshots and recordings. Violators will face strict legal action.

THIS IS COPYRIGHTED CONTENT. Unauthorized use, including screenshots, copying, misuse, reuse, or resale of any content from this app, is strictly prohibited. Our app monitors and records all screenshots and recordings. Violators will face strict legal action.

DISCLAIMER

THIS IS COPYRIGHTED CONTENT. Unauthorized use, including screenshots, copying, misuse, reuse, or resale of any content from this app, is strictly prohibited. Our app monitors and records all screenshots and recordings. Violators will face strict legal action.

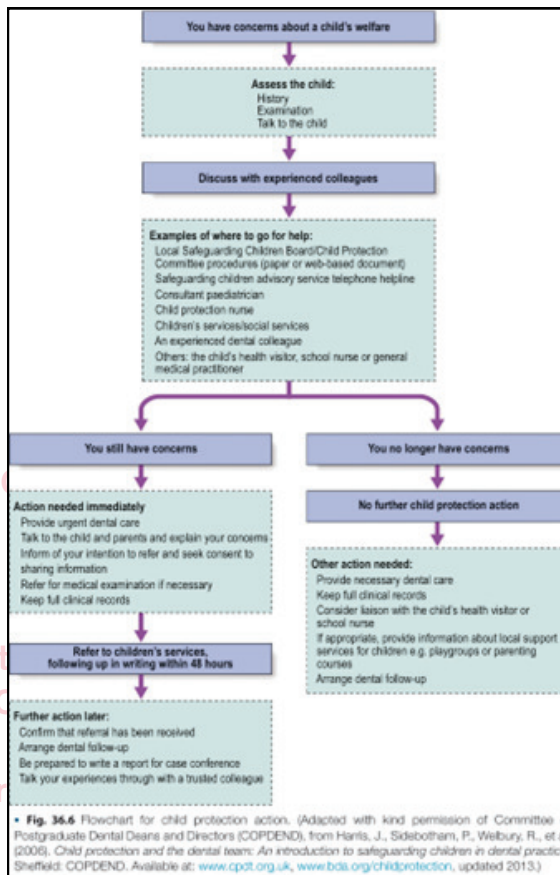
THIS IS COPYRIGHTED CONTENT. Unauthorized use, including screenshots, copying, misuse, reuse, or resale of any content from this app, is strictly prohibited. Our app monitors and records all screenshots and recordings. Violators will face strict legal action.

DISCLAIMER

THIS IS COPYRIGHTED CONTENT. Unauthorized use, including screenshots, copying, misuse, reuse, or resale of any content from this app, is strictly prohibited. Our app monitors and records all screenshots and recordings. Violators will face strict legal action.

# CHILD ABUSE MANAGEMENT

Child Protection Action that should be taken by the dentist: (\*Important\*)



THIS IS COPYRIGHTED CONTENT. Unauthorized use, including screenshots, copying, misuse, reuse, or resale of any content from this app, is strictly prohibited. Our app monitors and records all screenshots and recordings. Violators will face strict legal action.

**DISCLAIMER**  
THIS IS COPYRIGHTED CONTENT. Unauthorized use, including screenshots, copying, misuse, reuse, or resale of any content from this app, is strictly prohibited. Our app monitors and records all screenshots and recordings. Violators will face strict legal action.

THIS IS COPYRIGHTED CONTENT. Unauthorized use, including screenshots, copying, misuse, reuse, or resale of any content from this app, is strictly prohibited. Our app monitors and records all screenshots and recordings. Violators will face strict legal action.

THIS IS COPYRIGHTED CONTENT. Unauthorized use, including screenshots, copying, misuse, reuse, or resale of any content from this app, is strictly prohibited. Our app monitors and records all screenshots and recordings. Violators will face strict legal action.

**DISCLAIMER**

THIS IS COPYRIGHTED CONTENT. Unauthorized use, including screenshots, copying, misuse, reuse, or resale of any content from this app, is strictly prohibited. Our app monitors and records all screenshots and recordings. Violators will face strict legal action.

**DISCLAIMER**

THIS IS COPYRIGHTED CONTENT. Unauthorized use, including screenshots, copying, misuse, reuse, or resale of any content from this app, is strictly prohibited. Our app monitors and records all screenshots and recordings. Violators will face strict legal action.



# SPORTS DRINK AND MOUTHGUARDS

(Sources- Mouthguard and sport drinks on the tooth surface pH, Guidelines for fabrication, Use and maintenance of sports mouthguard (ADA), Play it safe mouthguard (fact sheet), Ada Policies)

- A mouthguard is a protective device worn in the upper jaw and sometimes the lower jaw to reduce injuries to the teeth, jaws and associated soft tissues.
- Provision of professionally fitted custom- made mouth guards for people involved in contact sports and recognition of the injury prone dentition are important in injury prevention.

Consideration should be given to wearing mouthguards in all sporting activities (including training) in which there is risk of trauma to the teeth and associated structures. Such activities include stick and ball sports, all football codes, contact martial arts and where close physical contact could reasonably be expected, e.g., water polo, basketball and netball.

- Dental injuries are relatively common in children and wearing a custom fitted mouth guards should commence as soon as the child starts to participate in organized contact sport.
- Custom fitted mouth guard should be considered as a part of children's sporting team uniform.

## General Design principles of mouth guards:

The general design principles for sports mouthguards are:

- For sports where high occlusal loads are to be expected, the mouthguard should enclose the maxillary teeth, preferably to the distal surface of the second molar.  
For these design requirements a mandibular model will be necessary to obtain an even occlusal contact.
- For standard club sports, enclosing the maxillary teeth to the distal surface of the first molar is usually sufficient.
- In the mixed dentition, the mouthguard should extend to the distal surface of the maxillary first molar.
- The approximate material thickness should be 2-3 mm on the labial aspect, 3 mm on the occlusal aspect and 2 mm on the palatal aspect.
- The labial flange should extend to within 2 mm of the vestibular reflection.
- The palatal flange should extend about 10 mm above the gingival margin.
- The edge of the labial flange should be rounded in cross-section.
- The edge of the palatal flange should be tapered in cross-section.
- On closing the mouth, there should be even contact between the mouthguard's occlusal surface and the lower teeth.
- For laminated mouthguards, improved impact force dispersion occurs when an airspace is created over the anterior teeth.<sup>8</sup>
- Mouthguards should not be designed and constructed with hard inserts sandwiched between laminations.<sup>77</sup>
- Mouthguards should be thoroughly inspected prior to being issued to ensure adequate thickness, resilience and minimum pressure on the soft tissues.

## DISCLAIMER

THIS IS COPYRIGHTED CONTENT. Unauthorized use, including screenshots, copying, misuse, reuse, or resale of any content from this app, is strictly prohibited. Our app monitors and records all screenshots and recordings. Violators will face strict legal action.

## DISCLAIMER

THIS IS COPYRIGHTED CONTENT. Unauthorized use, including screenshots, copying, misuse, reuse, or resale of any content from this app, is strictly prohibited. Our app monitors and records all screenshots and recordings. Violators will face strict legal action.

THIS IS COPYRIGHTED CONTENT. Unauthorized use, including screenshots, copying, misuse, reuse, or resale of any content from this app, is strictly prohibited. Our app monitors and records all screenshots and recordings. Violators will face strict legal action.

## DISCLAIMER

# SPORTS DRINK AND MOUTHGUARDS

There are different types of mouthguards:

## a) Custom made mouthguards

- Custom-made mouth guards are formed on the cast of upper jaw (wearer's) sometimes in conjunction with a cast of the lower jaw to obtain even occlusal contact.
- Custom-made mouth guards are the most acceptable.
- The Australian Dental association recommends custom fitted mouthguards for all Australians who participate in contact sport or sports with high risk of dental injury

## b) Bimaxillary mouthguards:

- These mouth guards are worn on upper and lower jaws with the passage for breathing in the anterior.
- These types of mouthguards could be considered for players in boxing, martial arts, and contact sports who desire a different type of protection.
- They require a period of adaptation in order to be tolerated.

## c) Laminated mouthguards

- They offer flexibility in design and construction.
- Ethyl vinyl acetate (EVA) of different hardness and thickness can be laminated together to provide increased protection.

## d) Mouth formed mouthguards

- It is also known as “**boil and bite**” mouthguards.
- They are available over the counter to be purchased from sports shop.
- It is softened in hot water and then formed in mouth by finger, tongue and biting pressure.

*Such mouthguards fit poorly, are difficult to wear, thin out dramatically, provide poor protection, are difficult to adapt to the mouth's anatomy, may be dislodged during use with a consequential risk of airway obstruction<sup>20</sup> and are therefore not recommended.*

*Mouth-formed “shell-liner” guards, which have a rigid outer layer and a soft thermoplastic inner layer, are also not recommended as the hard outer layer may amplify impact force and cause injury.<sup>20</sup>*

# SPORTS DRINK AND MOUTHGUARDS

There are different types of mouthguards:

## e) Stock mouthguards

- It is another variety of “off the shelf” mouthguards.
- These consists of a curved trough of plastics or rubber and are worn without adaptation or modification

without modification or adaptation. *Such mouthguards fit poorly, are difficult to wear, provide poor protection, may be dislodged during use with a consequential risk of airway obstruction<sup>20</sup> and are not recommended.*

For how long and how to maintain a mouthguard?

Patients fitted with sports mouthguards should be advised on the use and maintenance of their appliance. This advice should include:

- Wear only a professionally fitted, custom-made mouthguard with an even occlusal contact.
- Wear your mouthguard at training, practice and during the game.
- Rinse your mouthguard before and after use.
- Wash your mouthguard only with soap and in cold or lukewarm water.
- Clean the inner surface after wearing with a soft toothbrush.
- Do not let others use your mouthguard; it is custom-made and so can only be used by you.
- Store your mouthguard in a clean, rigid and ventilated plastic container.
- Keep your mouthguard away from sunlight and heat.
- Examine your mouthguard regularly for signs of deterioration, and replace if it is split or if the resilience, fit or bite have changed.
- Have your mouthguard checked for signs of wear, deterioration or reduction in fit as part of your routine dental review, or at least annually, by your dental practitioner.
- Contact your dental practitioner if your mouthguard becomes loose, too tight or causes you any discomfort.
- Do not expose your mouthguard to petroleum and petroleum products, cleaning agents, paints, adhesives and similar chemicals. It may be damaged and rendered ineffective, without the damage being visible to you.
- Consider regular replacement of mouthguards in children whose mouths are growing, and deciduous teeth are being lost and replaced by permanent teeth.

## DISCLAIMER

THIS IS COPYRIGHTED CONTENT. Unauthorized use, including screenshots, copying, misuse, reuse, or resale of any content from this app, is strictly prohibited. Our app monitors and records all screenshots and recordings. Violators will face strict legal action.

## DISCLAIMER

THIS IS COPYRIGHTED CONTENT. Unauthorized use, including screenshots, copying, misuse, reuse, or resale of any content from this app, is strictly prohibited. Our app monitors and records all screenshots and recordings. Violators will face strict legal action.

## DISCLAIMER

THIS IS COPYRIGHTED CONTENT. Unauthorized use, including screenshots, copying, misuse, reuse, or resale of any content from this app, is strictly prohibited. Our app monitors and records all screenshots and recordings. Violators will face strict legal action.



# SPORTS DRINK AND MOUTHGUARDS

## Custom made mouthguards types:

### Who Needs a Mouthguard?

Anyone who plays a sport or undertakes an activity where collision or contact to the face is a legitimate risk should wear a mouthguard. Sports such as rugby union and league, AFL, hockey and boxing are 'no brainers' because intentional collision and contact are a part of the game.

However, it is sports where accidental collision occurs that are often responsible for dental trauma, such as cricket, basketball, netball, touch football, and soccer. These sports are considered 'non-contact' and yet they also carry risk of accidental collision and contribute to the thousands of adults and children who are treated for dental trauma each year.

### a) Dual-laminated custom-made mouthguards:

- They can be Light or medium type.
- The medium type is designed for general use and sports with likely impacts from objects with a larger surface area such as: Boxing, Basketball, soccer, Judo, wrestling etc.
- The light type is for children up to 13 years of age and sports that require a mouthguard to protect the lower teeth from damage.

### b) Tri-laminated custom-made mouth guards:

- They are made from 3 layers
- They are best suited for stable adult teeth for sports such as senior rugby, hockey, AFL, ICE hockey, Karate, Squash, Kickboxing etc.

Different risk levels are associated with participation in particular sports. These can be categorised into four risk levels with oral protective measures appropriate to the risk:

- Sports during which the use of mouthguards is strongly recommended, including off-road bike riding, skateboarding, rock climbing, white-water rafting, trampolining, combat sports, football, basketball, squash and field hockey.
- Sports during which protective equipment for the head is worn, which may thus obviate the need for mouthguards, including full-face helmets in ice hockey and goalkeepers in field hockey cricket, roller-blading and cycling.
- Sports during which oral protective equipment is not normally worn but where mouthguard use could be justified under certain circumstances, including high diving, surf-boarding and skiing.
- Sports where mouthguard use would be impractical or not warranted due to low risk of injury, including swimming, athletics, aerobics and rowing.

Image: ADA polices

### DISCLAIMER

THIS IS COPYRIGHTED CONTENT. Unauthorized use, including screenshots, copying, misuse, reuse, or resale of any content from this app, is strictly prohibited. Our app monitors and records all screenshots and recordings. Violators will face strict legal action.

DISCLAIMER  
THIS IS COPYRIGHTED CONTENT. Unauthorized use, including screenshots, copying, misuse, reuse, or resale of any content from this app, is strictly prohibited. Our app monitors and records all screenshots and recordings. Violators will face strict legal action.

DISCLAIMER  
THIS IS COPYRIGHTED CONTENT. Unauthorized use, including screenshots, copying, misuse, reuse, or resale of any content from this app, is strictly prohibited. Our app monitors and records all screenshots and recordings. Violators will face strict legal action.

# SPORTS DRINK AND MOUTHGUARDS

## Sport Drinks and Mouth guards:

- Sports Drinks are essential for players playing sport esp. high impact sports.
- Intake of sports drink with high sugar content during sporting event is recommended for preventing dehydration as well as promoting energy intake.
- Sport drinks usually have acidic and erosive potential, so sensible use and modification of their properties is recommended.
- However, the erosive effect of sports drink on tooth surface is concerning.
- **Athlete who wears mouth guards often consume sports drink during exercise or competition before wearing mouthguard or with mouthguard already in place.**
- Studies have concluded that consuming sports drink over the mouthguard reduces the erosive potential of the drinks and prevents erosion and dental caries.
- They also concluded that if mouth guard is worn after consuming sports drink the risk of dental caries is significant due to entrapment of the sport drink beneath the mouth guard.

### Abstract

The influence of sports drinks and mouthguards on the pH level of tooth surface was examined. A custom-made mouthguard was fabricated for each subject. The pH level was measured by electric pH meter with sensitivity of 0.01 up to 30 min. Sports drinks (pH=3.75) containing 9.4% sugar were used in this study. Measurements were performed on a cohort of 23 female subjects without a mouthguard (control), wearing a mouthguard only (MG), wearing a mouthguard after 30ml sports drink intake (SD+MG), wearing a mouthguard during a 5-min jogging exercise (MG+EX) and wearing a mouthguard during jogging after sports drink intake (SD+MG+EX).

For 7 male subjects, the same measurements were performed while a sports drink was taken over the mouthguard (MG+SD, MD+EX+SD). MG showed statistically higher pH level than control ( $p<0.05$ ). SD+MG exhibited a significant decrease in pH level, and SD+MG+EX exhibited even below the critical level of pH 5.5 in some subjects. When sports drinks were taken over the mouthguard, no significant differences in pH level were observed among the different conditions. Within the limitations of this study, it was suggested that wearing a mouthguard during exercise is in itself not a possible risk factor for dental caries, while wearing a mouthguard after consuming sports drinks is.

- **A well fitted mouth guard do not allow sport drink to flow onto the tooth surface.**
- Oral hygiene should be strongly promoted among athletes when they use mouth guards. As dental plaque may accumulate on the tooth surface when athletes use mouth guards.
- Consuming water is also recommended during sporting events, but the intake of drinking water or sports drink with non-cariogenic sugar such as xylitol when using a mouth guard is more preferable.

### DISCLAIMER

THIS IS COPYRIGHTED CONTENT. Unauthorized use, including screenshots, copying, misuse, reuse, or resale of any content from this app, is strictly prohibited. Our app monitors and records all screenshots and recordings. Violators will face strict legal action.

### DISCLAIMER

THIS IS COPYRIGHTED CONTENT. Unauthorized use, including screenshots, copying, misuse, reuse, or resale of any content from this app, is strictly prohibited. Our app monitors and records all screenshots and recordings. Violators will face strict legal action.

THIS IS COPYRIGHTED CONTENT. Unauthorized use, including screenshots, copying, misuse, reuse, or resale of any content from this app, is strictly prohibited. Our app monitors and records all screenshots and recordings. Violators will face strict legal action.

### DISCLAIMER

# CHILDHOOD SYSTEMIC DISEASES AND INFECTIOUS DISEASES

Sources: (Cameron and therapeutic Guidelines)

- Although some disorders are confined to the mouth, oral lesions may be a sign of a systemic medical disorder.
- The majority of oral pathology seen in children is benign. However, it is essential to identify or eliminate more serious conditions.
- The presentation of pathology in children is often different from adult pathology and the subtleties of these differences are often important in diagnosis. In addition, many lesions change in form or extent with growth of the body.
- It is important to remember that one disease entity may have different presentations while one presentation, e.g., an ulcer, may be representative of many different diseases.

## 1) Odontogenic Infections:

- The basic signs and symptoms of oral infection should be familiar to all clinicians.
- **Acute infection** usually presents as an emergency:
  - a) A sick, upset child.
  - b) Raised temperature.
  - c) Red, swollen face.
  - d) Anxious and distressed parents.
- **Chronic infection** typically presents as an asymptomatic or indolent process:
  - a) A sinus may be present (usually labial or buccal).
  - b) Mobile tooth.
  - c) Halitosis
  - d) Discolored tooth
- The treatment of infection follows
  - a) Removal of the cause.
  - b) Local drainage and debridement.

## 2) Primary herpetic gingivostomatitis

- This is the most common cause of severe oral ulceration in children.
- It is caused by herpes simplex type 1 virus.
- This usually occurs after 6 months of age, often coincident with the eruption of the primary incisors.
- The peak incidence is between 12 and 18 months of age.
- Incubation time is 3–5 days with a prodromal 48-h history of irritability, pyrexia and malaise.
- The child is often unwell, has difficulty in eating and drinking and typically drools.
- Stomatitis is present, with the gingival tissues in particular becoming red and edematous.
- Intraepithelial vesicles appear and rapidly break down to form painful ulcers. Vesicles may form on any part of the oral mucosa, including the skin around the lips.

DISCLAIMER

THIS IS COPYRIGHTED CONTENT. Unauthorized use, including screenshots, copying, misuse, reuse, or resale of any content from this app, is strictly prohibited. Our app monitors and records all screenshots and recordings. Violators will face strict legal action.

THIS IS COPYRIGHTED CONTENT. Unauthorized use, including screenshots, copying, misuse, reuse, or resale of any content from this app, is strictly prohibited. Our app monitors and records all screenshots and recordings. Violators will face strict legal action.

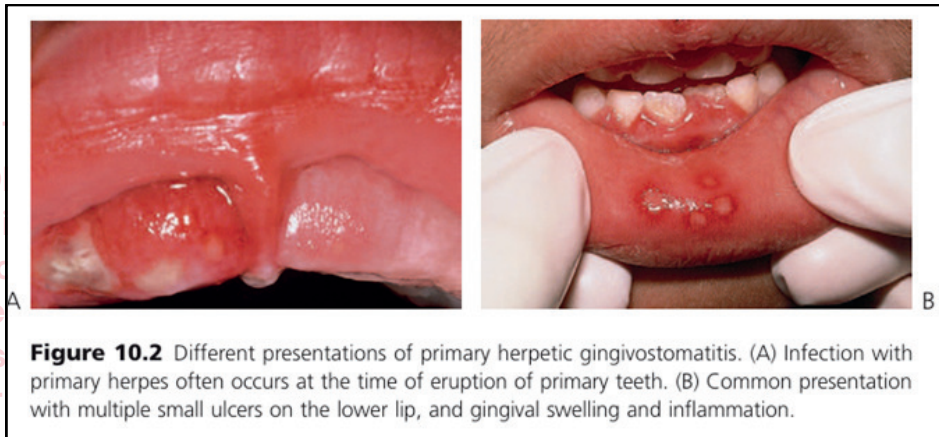
DISCLAIMER  
THIS IS COPYRIGHTED CONTENT. Unauthorized use, including screenshots, copying, misuse, reuse, or resale of any content from this app, is strictly prohibited. Our app monitors and records all screenshots and recordings. Violators will face strict legal action.



# CHILDHOOD SYSTEMIC DISEASES AND INFECTIOUS DISEASES

## 2) Primary herpetic gingivostomatitis

- Solitary ulcers are usually small (3 mm) and painful with an erythematous margin, but larger ulcers with irregular margins often result from the coalescence of individual lesions.
- The disease is self-limiting and the ulcers heal spontaneously without scarring, within 10–14 days.



- **Diagnosis is based on history and clinical examination.**

### Clinical Hint

An obviously ill child with puffy erythematous gingivae is most likely to have primary herpetic gingivostomatitis.

Primary oral mucocutaneous herpes simplex virus (HSV) infection (**herpetic gingivostomatitis**) often occurs in childhood with fever, painful intraoral lesions, systemic symptoms (eg malaise, lethargy) and cervical lymphadenopathy. Intraoral herpes simplex virus lesions begin as blisters and ulcerate rapidly—see Photo 15 (below). Healing occurs within several days in infants, but can take up to 2 weeks in older children. During this time, it may be difficult to eat and drink and hospital admission may be required. Herpetic gingivostomatitis is rare in adults, but can be severe and present with dehydration due to severe odynophagia.

While herpes simplex virus is the most common virus to cause mouth ulcers, other viruses (eg varicella zoster virus, coxsackie virus, cytomegalovirus) may be the cause. Intraoral herpes simplex virus lesions may resemble those seen in necrotising gingivitis (see p.73 for management of necrotising gingivitis); however, necrotising gingivitis is rare in children and is confined to the gingival tissues, while herpetic gingivostomatitis lesions are widespread and affect all soft tissues in the mouth.

Source: TG

### DISCLAIMER

THIS IS COPYRIGHTED CONTENT. Unauthorized use, including screenshots, copying, misuse, reuse, or resale of any content from this app, is strictly prohibited. Our app monitors and records all screenshots and recordings. Violators will face strict legal action.

### DISCLAIMER

THIS IS COPYRIGHTED CONTENT. Unauthorized use, including screenshots, copying, misuse, reuse, or resale of any content from this app, is strictly prohibited. Our app monitors and records all screenshots and recordings. Violators will face strict legal action.

THIS IS COPYRIGHTED CONTENT. Unauthorized use, including screenshots, copying, misuse, reuse, or resale of any content from this app, is strictly prohibited. Our app monitors and records all screenshots and recordings. Violators will face strict legal action.

DISCLAIMER

# CHILDHOOD SYSTEMIC DISEASES AND INFECTIOUS DISEASES

## Management of Primary herpetic Gingivostomatitis:

To reduce the risk of virus transmission, advise patients with an active herpes simplex virus infection to avoid direct contact of the lesion with other people.

Treat minor primary oral mucocutaneous herpes with supportive management (ie oral fluids, antipyretic drugs and analgesia). Apply a topical anaesthetic or analgesic, such as:

benzylamine 1% gel (adult and child 6 years or older), topically to the lesions, 2- to 3-hourly as necessary.

If this is not available, lidocaine viscous solution is an alternative topical anaesthetic for hospital settings (but be aware of the higher cost):

lidocaine 2% viscous solution

adult: use the lowest dose necessary up to 15 mL, rinsed in the mouth for 30 seconds then spat out, 3-hourly as necessary; maximum 8 doses in 24 hours

child 3 years or older: use the lowest dose necessary up to 0.2 mL/kg (maximum 5 mL), rinsed in the mouth for 30 seconds then spat out, 3-hourly as necessary; maximum 4 doses in 24 hours\*

child younger than 3 years: use the lowest dose necessary up to 0.2 mL/kg (maximum 1.25 mL), applied to the affected areas with a cotton swab, 3-hourly as necessary; maximum 4 doses in 24 hours.\*

If the pharynx is affected in adults and children older than 12 years, lidocaine viscous solution can be gargled and swallowed.

Management of primary oral mucocutaneous herpes differs for the following patients, so referral to a medical practitioner is required:

- patients with severe presentations
- immunocompromised patients
- patients with HIV.

Source: TG

THIS IS COPYRIGHTED CONTENT. Unauthorized use, including screenshots, copying, misuse, reuse, or resale of any content from this app, is strictly prohibited. Our app monitors and records all screenshots and recordings. Violators will face strict legal action.

### DISCLAIMER

THIS IS COPYRIGHTED CONTENT. Unauthorized use, including screenshots, copying, misuse, reuse, or resale of any content from this app, is strictly prohibited. Our app monitors and records all screenshots and recordings. Violators will face strict legal action.

THIS IS COPYRIGHTED CONTENT. Unauthorized use, including screenshots, misuse, reuse, or any content from this app, is strictly prohibited. Our app monitors and records all screenshots and recordings. Violators will face strict legal action.

**DISCLAIMER**  
THIS IS COPYRIGHTED CONTENT. Unauthorized use, including screenshots, copying, misuse, reuse, or resale of any content from this app, is strictly prohibited. Our app monitors and records all screenshots and recordings. Violators will face strict legal action.

THIS IS COPYRIGHTED CONTENT. Unauthorized use, including screenshots, copying, misuse, reuse, or any content from this app, is strictly prohibited. Our app monitors and records all screenshots and recordings. Violators will face strict legal action.

THIS IS COPYRIGHTED CONTENT. Unauthorized use, including screenshots, copying, misuse, reuse, or resale of any content from this app, is strictly prohibited. Our app monitors and records all screenshots and recordings. Violators will face strict legal action.

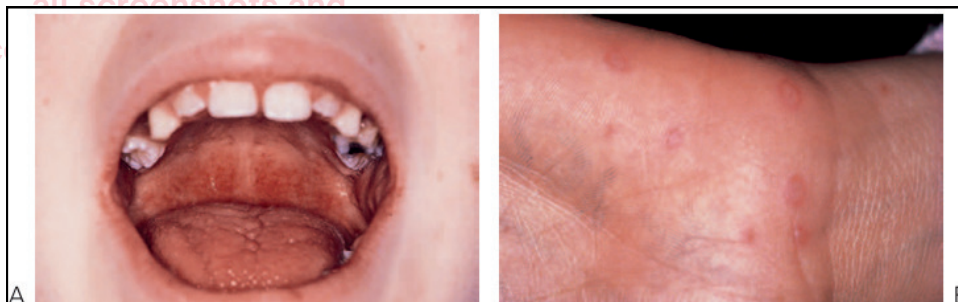
**DISCLAIMER**



# CHILDHOOD SYSTEMIC DISEASES AND INFECTIOUS DISEASES

## 3) Herpangina and hand, foot and mouth disease

- These infections are caused by the Coxsackie group A viruses.
- As with primary herpes, both of the above conditions have a prodromal phase of low-grade fever and malaise that may last for several days before the appearance of the vesicles.
- In herpangina a cluster of four to five vesicles are usually found on the palate, pillars of the faucets and pharynx,
- Whereas in hand, foot and mouth disease up to 10 vesicles occur at these sites and elsewhere in the mouth, in addition to the hands and feet.
- The skin lesions appear on the palmar surfaces of the hands and plantar surface of the feet and are surrounded by an erythematous margin.
- The severity of both diseases is usually milder than primary herpes and healing occurs within 10 days.
- Both diseases occur in epidemics, mainly affecting children.
- Diagnosis depends on clinical history and appearance and viral culture from swab.
- Management is symptomatic treatment as other viral infections.



**Figure 10.3** Infections caused by Coxsackie group A viruses. (A) Herpangina with characteristic palatal and pharyngeal ulceration and inflammation. (B) Cutaneous lesions in hand, foot and mouth disease.

THIS IS COPYRIGHTED CONTENT. Unauthorized use, including screenshots, copying, misuse, reuse, or resale of any content from this app, is strictly prohibited. Our app monitors and records all screenshots and recordings. Violators will face strict legal action.

### DISCLAIMER

THIS IS COPYRIGHTED CONTENT. Unauthorized use, including screenshots, copying, misuse, reuse, or resale of any content from this app, is strictly prohibited. Our app monitors and records all screenshots and recordings. Violators will face strict legal action.

**DISCLAIMER**  
THIS IS COPYRIGHTED CONTENT. Unauthorized use, including screenshots, copying, misuse, reuse, or resale of any content from this app, is strictly prohibited. Our app monitors and records all screenshots and recordings. Violators will face strict legal action.

THIS IS COPYRIGHTED CONTENT. Unauthorized use, including screenshots, copying, misuse, reuse, or resale of any content from this app, is strictly prohibited. Our app monitors and records all screenshots and recordings. Violators will face strict legal action.

DISCLAIMER



# CHILDHOOD SYSTEMIC DISEASES AND INFECTIOUS DISEASES

## 4) Infectious mononucleosis

- This infection is caused by the Epstein–Barr virus (EBV) and mainly affects older adolescents and young adults.
- The disease is highly infective and is characterized by malaise, fever, lymphadenopathy and acute pharyngitis.
- In young children, ulcers and petechiae are often found in the posterior pharynx and soft palate.
- The disease is self-limiting.

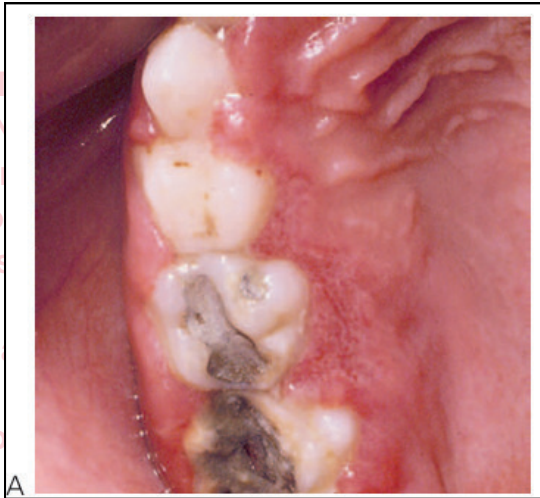

Image: A) Gingival ulceration and stomatitis during an acute episode of infectious mononucleosis.

## 5) Varicella infection:

- This is a highly contagious virus causing chickenpox in younger subjects and shingles in older individuals.
- There is a prodromal phase of malaise and fever for 24 h followed by macular eruptions and vesicles.
- In chickenpox, oral lesions occur in around 50% of cases but only a small number of vesicles occur in the mouth.
- These lesions may be found anywhere in the mouth in addition to other mucosal sites such as conjunctivae, nose or anus.
- Healing of oral lesions is uneventful.

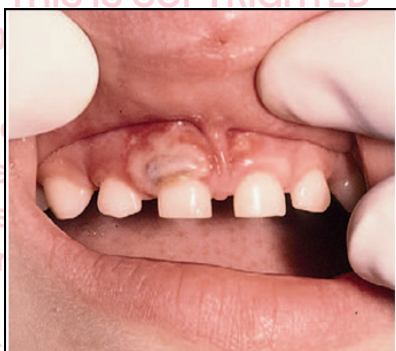

Image: Gingival ulceration in chickenpox infection

### DISCLAIMER

THIS IS COPYRIGHTED CONTENT. Unauthorized use, including screenshots, copying, misuse, reuse, or resale of any content from this app, is strictly prohibited. Our app monitors and records all screenshots and recordings. Violators will face strict legal action.

DISCLAIMER

THIS IS COPYRIGHTED CONTENT. Unauthorized use, including screenshots, copying, misuse, reuse, or resale of any content from this app, is strictly prohibited. Our app monitors and records all screenshots and recordings. Violators will face strict legal action.

THIS IS COPYRIGHTED CONTENT. Unauthorized use, including screenshots, copying, misuse, reuse, or resale of any content from this app, is strictly prohibited. Our app monitors and records all screenshots and recordings. Violators will face strict legal action.

DISCLAIMER

# CHILDHOOD SYSTEMIC DISEASES AND INFECTIOUS DISEASES

## 6) Acute pseudomembranous candidiasis

- The most common presentation of candida infection in infants is thrush.
- White plaques are present, which on removal reveal an erythematous, sometimes hemorrhagic, base.
- In older children, thrush occurs when children are immunocompromised such as in acquired immune deficiency syndrome (AIDS) or in diabetes, or when prescribed antibiotics, steroids, or during chemotherapy and radiotherapy for malignancies.

## 7) Commonly occurring ulceration in children

### a) Lip ulceration after mandibular block anesthesia:

- This is one of the most common causes of traumatic ulceration.
- Parents should be warned and children reminded not to bite their lips after mandibular block anesthesia.

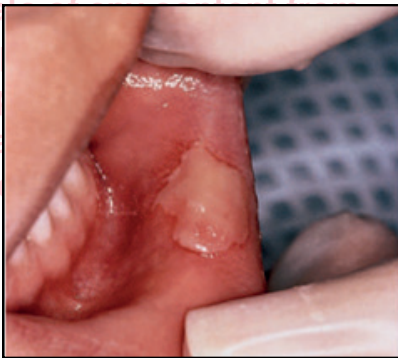

Image: Traumatic oral ulceration from biting the lip after a mandibular block injection.

### b) Riga-Fede ulceration:

- This is ulceration of the ventral surface of the tongue caused by trauma from continual protrusive and retrusive movements over the lower incisors.
- Once a common finding in cases of whooping cough, it is now almost exclusively seen in children with cerebral palsy.
- Management involves Smoothing sharp incisal edges or place domes of composite resin over the teeth. Rarely, in severe cases, extraction of the teeth might be considered.

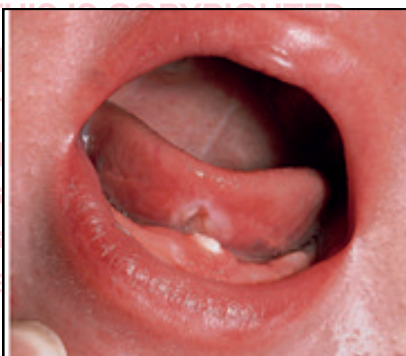

Image: Riga-Fede ulcer on the ventral surface of the tongue arising from rubbing on the solitary mandibular incisor.

## DISCLAIMER

THIS IS COPYRIGHTED CONTENT. Unauthorized use, including screenshots, copying, misuse, reuse, or resale of any content from this app, is strictly prohibited. Our app monitors and records all screenshots and recordings. Violators will face strict legal action.

DISCLAIMER

THIS IS COPYRIGHTED CONTENT. Unauthorized use, including screenshots, copying, misuse, reuse, or resale of any content from this app, is strictly prohibited. Our app monitors and records all screenshots and recordings. Violators will face strict legal action.

THIS IS COPYRIGHTED CONTENT. Unauthorized use, including screenshots, copying, misuse, reuse, or resale of any content from this app, is strictly prohibited. Our app monitors and records all screenshots and recordings. Violators will face strict legal action.

DISCLAIMER