



WINSPERT

**PROSTHODONTICS**

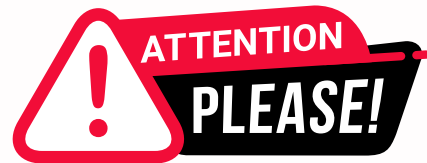**H.O.T**

**HIGH-PRIORITY ORGANISED THEORY**

**NOTES**

By Dr. Jigyasa Sharma





Dear Students,

We'd like to remind you about the importance of respecting the integrity of the resources provided in our app.

Please be aware that **WINSPERT HOT NOTES ARE COPYRIGHTED CONTENT. Unauthorized use, including screenshots, copying, misuse, reuse, or resale of any content from this app, is strictly prohibited.**

**Our app monitors and records all screenshots and recordings. Violators will face strict legal action.**

We're committed to providing you with the best tools for your success, and we appreciate your cooperation in maintaining a fair and secure learning environment.

Thank you for your understanding and continued dedication.

Best regards,  
WINSPERT TEAM

# **PROSTHODONTICS**

## **H.O.T TOPICS**

- 1. Combination syndrome**
- 2. Occlusion schemes, canine guidance, group function, bilaterally, balanced occlusion**
- 3. RPD parts clasps Kennedy's classification**
- 4. RPD and denture repairs**
- 5. Over dentures on natural teeth and over dentures on implant supported**
- 6. Peri implants and Peri implant mucositis and implant maintenance**
- 7. Denture troubleshooting**
- 8. FPD failures, chippings, and repairs**
- 9. Impression, techniques and materials**
- 10. Implant complications and risk factors**

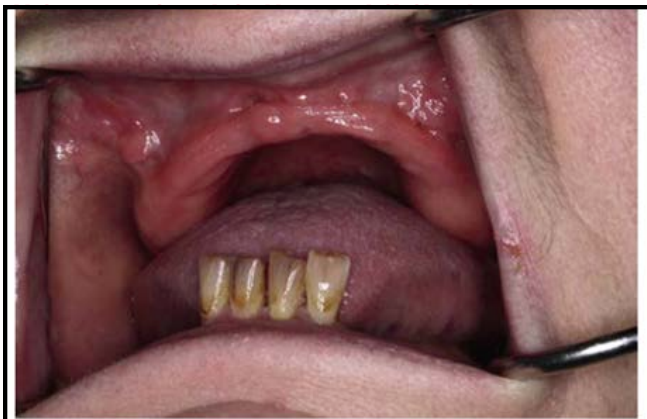# COMBINATION SYNDROME

Reference: TG

## Introduction

- Combination syndrome is defined as “the characteristic features that occur when edentulous maxilla is opposed by natural mandibular anterior teeth, including loss of bone from the anterior portion of the maxillary ridge, overgrowth of the tuberosities, papillary hyperplasia of the hard palatal mucosa, extrusion of mandibular anterior teeth, and loss of alveolar bone and ridge height beneath the mandibular removable partial denture bases, also called anterior hyperfunction syndrome” (GLOSSARY OF PROSTHODONTIC TERMS)
- Combination syndrome mostly occurs in cases of complete maxillary denture opposing a bilateral distal extension mandibular partial denture.
- Ellsworth Kelly followed up 6 such patients for 3 years and coined the term combination syndrome.

## Features:



• **Fig. 72.1** An intraoral anterior view of the patient in question, showing the maxillary ridge form and remaining mandibular dentition. The anterior maxillary ridge is relatively mobile on palpation.

Image- Typical case of Combination syndrome (Class 1 mod 1) Source-Odell

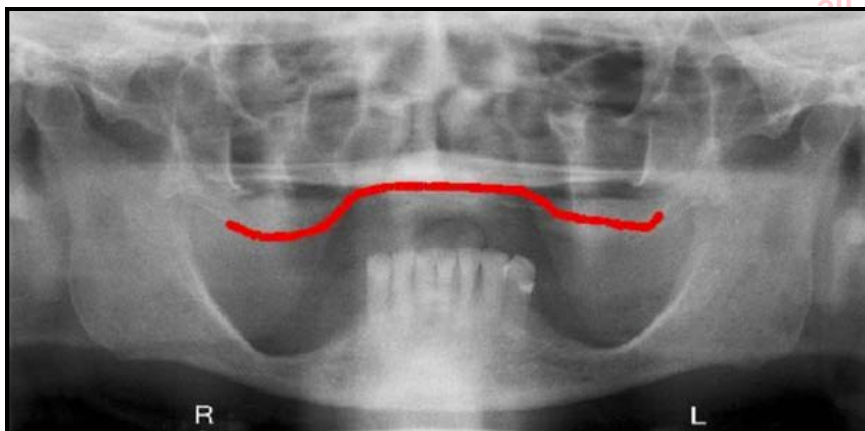


Image-OPG of patient with combination syndrome with severe atrophy of posterior mandible. (Source- Internet)

## DISCLAIMER

THIS IS COPYRIGHTED CONTENT. Unauthorized use, including screenshots, copying, misuse, reuse, or resale of any content from this app, is strictly prohibited. Our app monitors and records all screenshots and recordings. Violators will face strict legal action.

DISCLAIMER  
THIS IS COPYRIGHTED CONTENT. Unauthorized use, including screenshots, copying, misuse, reuse, or resale of any content from this app, is strictly prohibited. Our app monitors and records all screenshots and recordings. Violators will face strict legal action.

THIS IS COPYRIGHTED CONTENT. Unauthorized use, including screenshots, copying, misuse, reuse, or resale of any content from this app, is strictly prohibited. Our app monitors and records all screenshots and recordings. Violators will face strict legal action.

DISCLAIMER

# COMBINATION SYNDROME

Reference: TG

- Loss of bone of the anterior edentulous maxilla when opposed by natural mandibular anterior teeth is 1 of the several features of the combination syndrome.
- Ellsworth Kelly described 3 key features of combination syndrome:
  - i) Reduction of anterior maxillary bone
  - ii) Enlargement of maxillary tuberosities
  - iii) Bone resorption under mandibular RPD bases.
- Other features can also occur at the same time along with these, which are:
  - i) Loss of vertical dimension of occlusion (VDO)
  - ii) Extrusion of lower natural teeth
  - iii) Occlusal plane discrepancy
  - iv) Anterior spatial reposition of the mandible.
  - v) Poor adaptation of prosthesis
  - vi) Epulis fissuratum
  - vii) Periodontal changes
- Despite the negative role of mandibular RPD, the early loss of bone from the anterior part of the maxillary jaw is the key to other changes of the combination syndrome.
- Severe maxillary resorption is the dominant feature of combination syndrome.
- In a typical case of combination syndrome maxillary ridge is completely edentulous. However, patients with partial maxillary edentulism also have similar signs and symptoms.
- Partial maxillary edentulism like cases of missing maxillary anterior teeth replace with anterior RPD and having preserved posterior teeth opposed by mandibular anterior natural teeth and posterior distal extension RPD or natural dentition demonstrates similar deteriorating effects as Combination syndrome.
- It is noteworthy that when the posterior maxillary teeth are present in one or both sides opposed by posterior mandibular teeth, the hypertrophic changes (overgrowth) of posterior maxilla and maxillary tuberosities does not happen.

## Residual Ridge Resorption::

- After extraction of teeth a remodeling process of the alveolar bone occurs including bone resorption and a changed bone contour.
- In the initial remodeling phase immediately after extraction, the resorption in maxilla can be reduced with the use of immediate denture than without dentures, whereas no significant difference is found in resorption rate of mandible during this stage with or without dentures.
- After initial remodeling there is continuous resorption under denture bases which is inevitable.
- The use of removable denture plays an important causative role in the bone resorption process.

### DISCLAIMER

THIS IS COPYRIGHTED CONTENT. Unauthorized use, including screenshots, copying, misuse, reuse, or resale of any content from this app, is strictly prohibited. Our app monitors and records all screenshots and recordings. Violators will face strict legal action.

DISCLAIMER  
THIS IS COPYRIGHTED CONTENT. Unauthorized use, including screenshots, copying, misuse, reuse, or resale of any content from this app, is strictly prohibited. Our app monitors and records all screenshots and recordings. Violators will face strict legal action.

DISCLAIMER

THIS IS COPYRIGHTED CONTENT. Unauthorized use, including screenshots, copying, misuse, reuse, or resale of any content from this app, is strictly prohibited. Our app monitors and records all screenshots and recordings. Violators will face strict legal action.



# COMBINATION SYNDROME

Reference: TG

## Classification of combination syndrome:

- A clinically relevant classification of combination syndrome purposes 3 classes and 10 modification of combination syndrome.
- An anterior maxillary resorption resulting from the force of anterior mandibular teeth is the key feature of this classification and is present in all cases and all modification.
- Class is defined by “maxillary edentulous condition”. Modification within the class is defined by “mandibular condition”.

- The classification is as follows:

### 1) Class I:

- Maxilla: Completely edentulous alveolar ridge.
- Mandible:
  - a. Modification 1 (M1): Partially edentulous ridge with preserved anterior teeth only.
  - b. Modification 2 (M2): Stable ‘fixed’ full dentition (natural teeth or implant-supported crowns/bridges).
  - c. Modification 3 (M3): Partially edentulous ridge with preserved teeth in anterior and one posterior region.

CS Class	CS Modification	Type of Maxillary Edentulism	Type of Mandibular Edentulism	Anterior Maxilla	Anterior Mandible
I	1	Completely edentulous arch	Partial edentulism with anterior teeth present only (or recently removed)	Severe atrophy	Severe hypertrophy; teeth extrusion
	2	Completely edentulous arch	Fixed dentition	Severe atrophy	Severe hypertrophy
	3	Completely edentulous arch	Partial edentulism with anterior and posterior teeth on one side	Severe atrophy	Severe hypertrophy

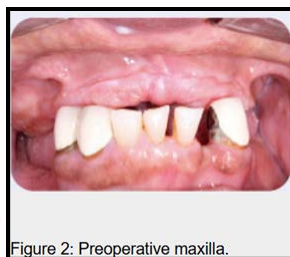
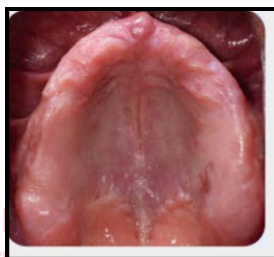
Figure 2: Preoperative maxilla.

Image- Class 1 combination syndrome (Internet)

### DISCLAIMER

THIS IS COPYRIGHTED CONTENT. Unauthorized use, including screenshots, copying, misuse, reuse, or resale of any content from this app, is strictly prohibited. Our app monitors and records all screenshots and recordings. Violators will face strict legal action.

### DISCLAIMER

THIS IS COPYRIGHTED CONTENT. Unauthorized use, including screenshots, copying, misuse, reuse, or resale of any content from this app, is strictly prohibited. Our app monitors and records all screenshots and recordings. Violators will face strict legal action.

THIS IS COPYRIGHTED CONTENT. Unauthorized use, including screenshots, copying, misuse, reuse, or resale of any content from this app, is strictly prohibited. Our app monitors and records all screenshots and recordings. Violators will face strict legal action.

# COMBINATION SYNDROME

Reference: TG

## 2) Class II:

- **Maxilla:** Partially edentulous alveolar ridge with teeth present in both posterior regions, edentulous and atrophic anterior region.
- **Mandible:** Modifications are the same as in class I (M1, M2 and M3).

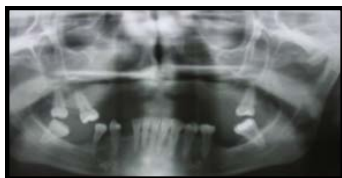


Image- Class II mod 3 combination syndrome (Internet)

II	1	Partially edentulous arch with posterior teeth present on both sides	Partial edentulism with anterior teeth present only (or recently removed)	Severe atrophy	Severe hypertrophy
	2	Partially edentulous arch with posterior teeth present on both sides	Fixed dentition	Severe atrophy	Severe hypertrophy
	3	Partially edentulous arch with posterior teeth present on both sides	Partial edentulism with anterior and posterior teeth on one side	Severe atrophy	Severe hypertrophy

## 3) Class III:

- **Maxilla:** Partially edentulous alveolar ridge with teeth present in one posterior region only, edentulous and atrophic anterior and one posterior region.
- **Mandible:** Modifications are consistent with class I and II (M1, M2, M3A and M3B)

III	1	Partial edentulous arch with posterior teeth present on one side only	Partial edentulism with anterior teeth present only (or recently removed)	Severe atrophy	Severe hypertrophy
	2	Partial edentulous arch with posterior teeth present on one side only	Fixed dentition	Severe atrophy	Severe hypertrophy
	3A	Partial edentulous arch with posterior teeth present on one side only	Partial edentulism with anterior and posterior teeth on one occluding side	Severe atrophy	Severe hypertrophy
	3B	Partial edentulous arch with posterior teeth present on one side only	Partial edentulism with anterior and posterior teeth on one nonoccluding side	Severe atrophy	Severe hypertrophy

Note\*Refer to flow chart 1 and 2

### DISCLAIMER

THIS IS COPYRIGHTED CONTENT. Unauthorized use, including screenshots, copying, misuse, reuse, or resale of any content from this app, is strictly prohibited. Our app monitors and records all screenshots and recordings. Violators will face strict legal action.

### DISCLAIMER

THIS IS COPYRIGHTED CONTENT. Unauthorized use, including screenshots, copying, misuse, reuse, or resale of any content from this app, is strictly prohibited. Our app monitors and records all screenshots and recordings. Violators will face strict legal action.

### DISCLAIMER

THIS IS COPYRIGHTED CONTENT. Unauthorized use, including screenshots, copying, misuse, reuse, or resale of any content from this app, is strictly prohibited. Our app monitors and records all screenshots and recordings. Violators will face strict legal action.

# COMBINATION SYNDROME

Reference: TG

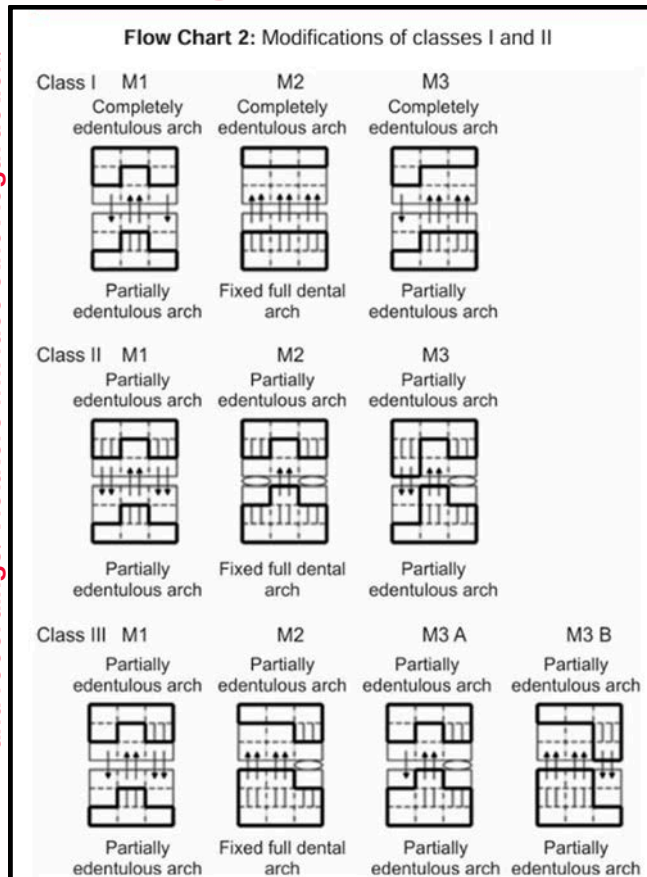
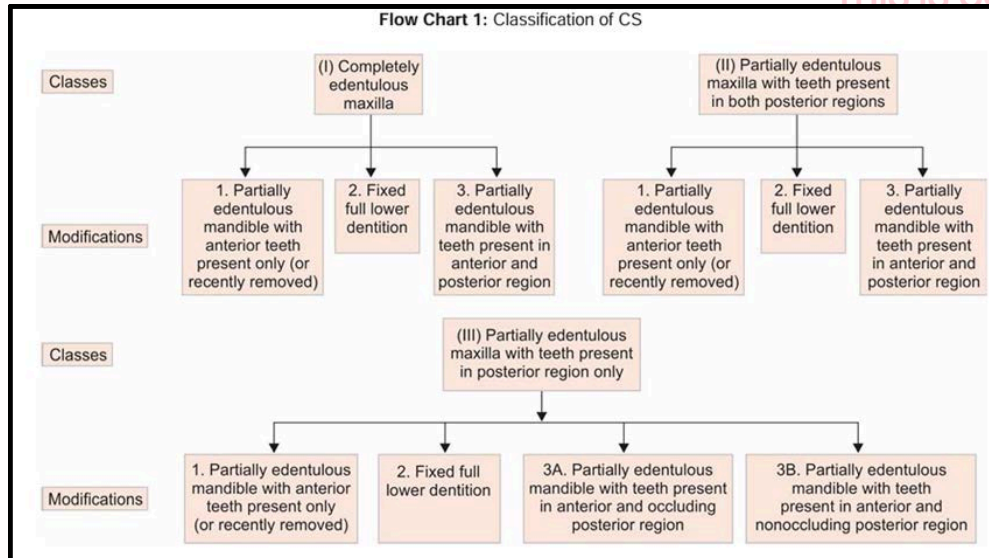


Image- Articles

**DISCLAIMER**

THIS IS COPYRIGHTED CONTENT. Unauthorized use, including screenshots, copying, misuse, reuse, or resale of any content from this app, is strictly prohibited. Our app monitors and records all screenshots and recordings. Violators will face strict legal action.

**DISCLAIMER**

THIS IS COPYRIGHTED CONTENT. Unauthorized use, including screenshots, copying, misuse, reuse, or resale of any content from this app, is strictly prohibited. Our app monitors and records all screenshots and recordings. Violators will face strict legal action.

THIS IS COPYRIGHTED CONTENT. Unauthorized use, including screenshots, copying, misuse, reuse, or resale of any content from this app, is strictly prohibited. Our app monitors and records all screenshots and recordings. Violators will face strict legal action.

THIS IS COPYRIGHTED CONTENT. Unauthorized use, including screenshots, copying, misuse, reuse, or resale of any content from this app, is strictly prohibited. Our app monitors and records all screenshots and recordings. Violators will face strict legal action.

**DISCLAIMER**



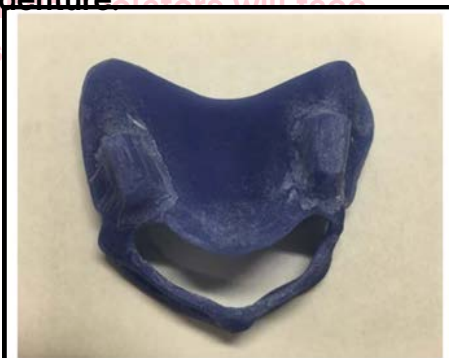# COMBINATION SYNDROME

Reference: TG

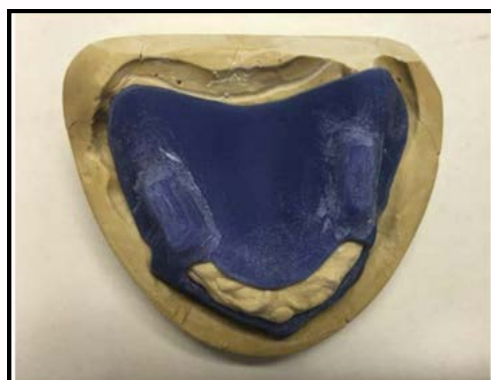## Treatment approaches for patient with combination syndrome:

- Prevention of loss of posterior occlusion and avoidance of anterior hyperfunction are considered the main treatment approaches for a patient with combination syndrome.
- Based on the pathogenesis of the combination syndrome four treatment modalities can be applied to correct a traumatic anterior hyperfunction and treat combination syndrome. **The first two treatment modalities are conventional pre implant restorative techniques. The last two is a surgical- prosthetic rehabilitation of stomatognathic system** that can prevent the continuous deterioration and related signs and symptoms of combination syndrome. They are:

- 1) A properly designed mandibular partial denture around stable, mildly supra-erupted anterior teeth opposed by complete maxillary denture with even distribution of occlusal stresses over hard and soft tissues:
  - If there is **Anterior fibrous change** of maxillary ridge a **mucostatic impression technique** using a **specialized open window tray** with a light body silicone or zinc oxide eugenol paste, or alginate in a generously spaced and perforated special tray should be used. The aim of this impression technique is to avoid displacing the mobile fibrous tissue during recording of the impression which if not done can lead to both soreness and reduced stability of the final denture.



• Fig. 72.3 A special tray showing the open window constructed from light-cured laboratory special tray material. Note the bilateral stub handles, for the operator's fingers to stabilize the tray while recording the impression.



• Fig. 72.2 The maxillary tray is close fitting on the model, with the anterior window for the fibrous anterior ridge showing.

Source- Odell case

- If the mandibular anterior teeth are over erupted treating them with root canal treatment and shortening of their clinical crowns to properly position maxillary teeth should be done.
  - Careful maintenance through follow up care with the goal to preserve posterior occlusion should be done.
- 2) An extraction of the anterior mandibular teeth with or without alveoloplasty and construction of functional complete upper and lower dentures with a stable posterior occlusion that is maintained through follow up care.

### DISCLAIMER

THIS IS COPYRIGHTED CONTENT. Unauthorized use, including screenshots, copying, misuse, reuse, or resale of any content from this app, is strictly prohibited. Our app monitors and records all screenshots and recordings. Violators will face strict legal action.

### DISCLAIMER

THIS IS COPYRIGHTED CONTENT. Unauthorized use, including screenshots, copying, misuse, reuse, or resale of any content from this app, is strictly prohibited. Our app monitors and records all screenshots and recordings. Violators will face strict legal action.

THIS IS COPYRIGHTED CONTENT. Unauthorized use, including screenshots, copying, misuse, reuse, or resale of any content from this app, is strictly prohibited. Our app monitors and records all screenshots and recordings. Violators will face strict legal action.

### DISCLAIMER

# COMBINATION SYNDROME

Reference: TG

- 3) An implant treatment of the existing dentition with or without extraction of teeth:
  - Through this method re establishment of solid posterior occlusion with implant assisted or implant supported maxillary and mandibular prosthesis is done.
  - Both implanted supported prosthesis and implant retained prosthesis are popular and successful prosthetic rehabilitation for partially and fully edentulous maxilla.
  - A modern bi-maxillary surgical therapy, is now a common approach for Combination syndrome treatment that includes:
    - i. An implant-based reconstruction of the mandibular arch with
    - ii. implant stabilization of the maxillary arch
- 4) Using advanced bone grafting techniques to rebuild the maxillary anterior ridge along with one of the above three options.
  - As patients with combination syndrome have extensive bone loss especially in maxillary arch surgical and prosthetic technique for correction of maxillary atrophy combined with immediate or delayed placement of implants is being increasingly used.
  - These reconstructive approaches include the following (highlighted portion)

Severe maxillary resorption is a dominant feature of combination syndrome patients. These CS patients as well as many other clinical cases of extensive three-dimensional maxillary bone loss have guided dental clinicians and surgeons towards the development of many innovative surgical and prosthetic techniques of correction of maxillary bone atrophy combined with immediate or delayed placement of dental implants. These reconstructive approaches for the compromised maxillary bone include vertical alveolar distraction osteogenesis,<sup>7,8</sup> horizontal distraction in combination with bilateral sinus lift/bone grafting procedure,<sup>9,10</sup> maxillary ridge-splitting techniques followed by immediate dental implants,<sup>11</sup> autogenous iliac crest<sup>12</sup> and calvarial bone grafting,<sup>13</sup> reconstruction of the resorbed edentulous maxilla with autogenous rib grafts,<sup>14</sup> tibial grafting for maxillary bone loss,<sup>15</sup> treatment of severe maxillary atrophy with vascularized free fibula flap in combination with dental implants,<sup>16</sup> interpositional bone grafting with LeFort I osteotomy,<sup>17</sup> orthognathic surgery with or without onlay bone grafting,<sup>18,19</sup> use of the osseoinductive effect of bone morphogenic protein within endosseous dental implants placed in the maxilla,<sup>20</sup> zygomatic implants with or without sinus lift/bone graft,<sup>21,22</sup> pterygomaxillary implants combined with zygomatic and conventional implants,<sup>23</sup> the Marius implant bridge for the surgical-prosthetic rehabilitation of the resorbed completely edentulous maxilla with 6 implants,<sup>24</sup> "all-on-4" maxillary edentulous rehabilitation with 4 strategically placed and immediately loaded implants,<sup>25</sup> combination of short implants and osteotome technique for the posterior maxilla,<sup>26</sup> use of transitional implants and bone grafting before placement of definitive implants,<sup>27</sup> optimal use of the anatomic features of the maxillary arch with tilted implants,<sup>28</sup> use of transmandibular implant<sup>29</sup> and Tatum custom ramus frame implant in CS patients,<sup>30</sup> and others.

In typical CS cases, a maxillary ridge is completely edentulous. However, patients with a partial maxillary

Source-Article

- According to our classification, **most of the Class I** cases can be treated with
  - i. Implant retained or supported maxillary prosthesis on 2 to 4 splinted implants placed in posterior maxillary region opposed by mandibular bilateral distal extension RPD.
  - ii. This helps to redistribute the occlusal loads to the posterior region and correct the condition.

CS Class	CS Modification	Posterior Maxilla	Posterior Mandible	Conventional Treatment: Maxilla/Mandible	Suggested Implant Treatment of Maxillary Arch (Based on Bone Availability)
I	1	Moderate hypertrophy	Moderate atrophy	FUD/bilateral distal extension RPD	Placement of 2 to 4 implants in the posterior maxilla on each side, alveoplasty ± sinus lift; implant-retained or supported overdenture
	2	Severe atrophy	Severe hypertrophy	FUD	Implants are unlikely
	3	Severe atrophy on one side and moderate hypertrophy on the other	Severe hypertrophy on one side and moderate atrophy on the other	FUD/unilateral distal extension RPD	Placement of 2 to 4 implants in the posterior maxilla on hypertrophic side, alveoplasty ± sinus lift; implant-retained overdenture

**DISCLAIMER** Image- Treatment modalities for Class 1 combination syndrome cases. (Article)

**THIS IS COPYRIGHTED CONTENT.** Unauthorized use, including screenshots, copying, misuse, reuse, or resale of any content from this app, is strictly prohibited. Our app monitors and records all screenshots and recordings. Violators will face strict legal action.

**DISCLAIMER**

**THIS IS COPYRIGHTED CONTENT.** Unauthorized use, including screenshots, copying, misuse, reuse, or resale of any content from this app, is strictly prohibited. Our app monitors and records all screenshots and recordings. Violators will face strict legal action.

**DISCLAIMER**

**THIS IS COPYRIGHTED CONTENT.** Unauthorized use, including screenshots, copying, misuse, reuse, or resale of any content from this app, is strictly prohibited. Our app monitors and records all screenshots and recordings. Violators will face strict legal action.

# COMBINATION SYNDROME

Reference: TG

- **Class II and Class III** cases with partially edentulous maxilla and salvageable posterior teeth are best treated with
  - i. Well-designed and maintained conventional RPD.
  - ii. An implant prosthesis can be an alternative for these cases.
- Patients with poor maxillary posterior teeth may need
  - i. Extraction and immediate or delayed implant placement with or without sinus lift for implant retained or implant supported prosthesis.
  - ii. Prior to or at implant surgical phase, the hypertrophy of posterior maxilla and overgrowth of maxillary tuberosities can be corrected with: a) Alveoloplasty and maxillary endosseous implants with better vertical relationship. b) Sub antral augmentation (sinus lift) with direct (Tatum) or indirect (Summer) method.
  - iii. Due to poor bone quality of maxillary posterior region (Type 3 and 4 bone), at least 2 implants of sufficient length on each side should be done.

CS Class	CS Modification	Posterior Maxilla	Posterior Mandible	Conventional Treatment: Maxilla/Mandible	Suggested Implant Treatment of Maxillary Arch (Based on Bone Availability)
II	1	Severe hypertrophy	Severe atrophy	Anterior extension RPD/bilateral distal extension RPD	Teeth extraction with placement of 2 to 4 implants in the posterior maxilla on each side $\pm$ sinus lift; implant-retained or supported overdenture
	2	No significant changes	No significant changes	Anterior extension RPD	Teeth extraction with placement of 2 to 4 implants in the posterior maxilla on each side $\pm$ sinus lift; implant-retained or supported overdenture
	3	Severe hypertrophy on one side and no changes on the other	Severe atrophy on one side and no changes on the other	Anterior extension RPD/unilateral distal extension RPD	Teeth extraction with placement of 2 to 4 implants in the posterior maxilla on each side $\pm$ sinus lift; implant-retained or supported overdenture

Image- Treatment modalities for Class 2 combination syndrome cases. (Article)

CS Class	CS Modification	Posterior Maxilla	Posterior Mandible	Conventional Treatment: Maxilla/Mandible	Suggested Implant Treatment of Maxillary Arch (Based on Bone Availability)
III	1	Different degree of hypertrophy on both sides	Different degree of atrophy on both sides	Unilateral distal extension RPD/bilateral distal extension RPD	Placement of 2 to 4 implants in the posterior maxilla on 1 or 2 sides $\pm$ extraction/sinus lift; implant-retained or supported overdenture
	2	Severe atrophy on one side and no changes on the other	Severe hypertrophy on one side and no changes on the other	Unilateral distal extension RPD	Placement of 2 to 4 implants in the posterior maxilla on one side $\pm$ extraction/sinus lift; implant-retained overdenture
	3A	Moderate hypertrophy on one side and no changes on the other	Moderate atrophy on one side and no changes on the other	Unilateral distal extension RPD for both jaws	Placement of 2 to 4 implants in the posterior maxilla on 1 or 2 sides $\pm$ extraction/sinus lift; implant-retained or supported overdenture
	3B	Severe atrophy on one side and severe hypertrophy on the other	Opposite of posterior maxilla	Unilateral distal extension RPD for both jaws	Placement of 2 to 4 implants in the posterior maxilla on 1 or 2 sides $\pm$ extraction/sinus lift; implant-retained overdenture

Image- Treatment modalities for patients with Class 3 combination syndrome cases. (Article)

## DISCLAIMER

THIS IS COPYRIGHTED CONTENT. Unauthorized use, including screenshots, copying, misuse, reuse, or resale of any content from this app, is strictly prohibited. Our app monitors and records all screenshots and recordings. Violators will face strict legal action.

## DISCLAIMER

THIS IS COPYRIGHTED CONTENT. Unauthorized use, including screenshots, copying, misuse, reuse, or resale of any content from this app, is strictly prohibited. Our app monitors and records all screenshots and recordings. Violators will face strict legal action.

THIS IS COPYRIGHTED CONTENT. Unauthorized use, including screenshots, copying, misuse, reuse, or resale of any content from this app, is strictly prohibited. Our app monitors and records all screenshots and recordings. Violators will face strict legal action.



# COMBINATION SYNDROME

Reference: TG

- An implant supported prosthesis has bone preserving effect where as conventional denture treatment promotes continued ridge resorption.
- When treated with implant prosthesis, after osteointegration occurs the prosthesis should be splinted to increase the resistance of occlusal forces. Non-splinting of implants when placed into the poor bone quality of maxilla compromises the treatment outcome due to uneven load distribution eventually leading to implant(s) loss.
- An immediate or early replacement of lost teeth with dental implants is one of the most effective treatment options that can avoid development of combination syndrome.

THIS IS COPYRIGHTED CONTENT. Unauthorized use, including screenshots, copying, misuse, reuse, or resale of any content from this app, is strictly prohibited. Our app monitors and records all screenshots and recordings. Violators will face strict legal action.

THIS IS COPYRIGHTED CONTENT. Unauthorized use, including screenshots, copying, misuse, reuse, or resale of any content from this app, is strictly prohibited. Our app monitors and records all screenshots and recordings. Violators will face strict legal action.

THIS IS COPYRIGHTED CONTENT. Unauthorized use, including screenshots, copying, misuse, reuse, or resale of any content from this app, is strictly prohibited. Our app monitors and records all screenshots and recordings. Violators will face strict legal action.

**DISCLAIMER**

THIS IS COPYRIGHTED CONTENT. Unauthorized use, including screenshots, copying, misuse, reuse, or resale of any content from this app, is strictly prohibited. Our app monitors and records all screenshots and recordings. Violators will face strict legal action.

**DISCLAIMER**

THIS IS COPYRIGHTED CONTENT. Unauthorized use, including screenshots, copying, misuse, reuse, or resale of any content from this app, is strictly prohibited. Our app monitors and records all screenshots and recordings. Violators will face strict legal action.

**DISCLAIMER**

THIS IS COPYRIGHTED CONTENT. Unauthorized use, including screenshots, copying, misuse, reuse, or resale of any content from this app, is strictly prohibited. Our app monitors and records all screenshots and recordings. Violators will face strict legal action.



# OCCLUSION SCHEMES

- In restorative treatment the goal is to create occlusal contacts in the posterior teeth that is stable, instead of creating defluctive contacts that may destabilize the mandibular position.
- The occlusion in restoration should be made in harmony with optimum condylar position, centric relation.

## Important Terminologies:

### 1) Centric relation:

- Centric relation is defined as the maxillomandibular relationship in which the condyles articulate with the thinnest avascular portion of their respective disks with the condyle-disk complex in the anterosuperior position against the articular eminences. This position is independent of tooth contact.

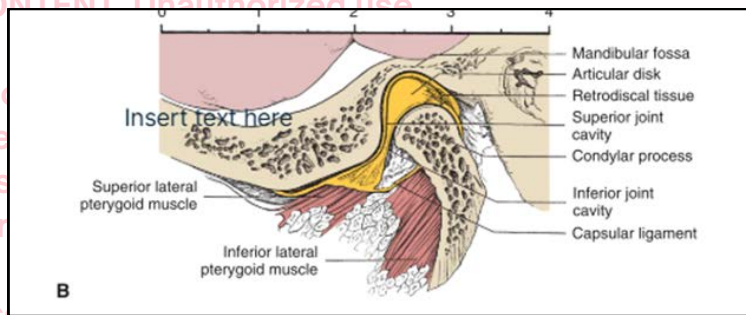
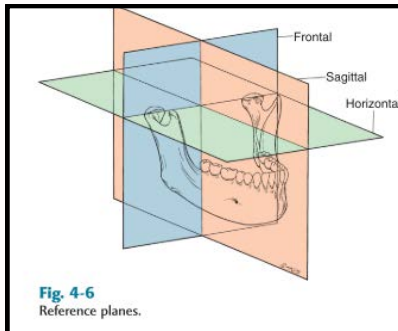


Fig: Components of TMJ (Rosensteil)

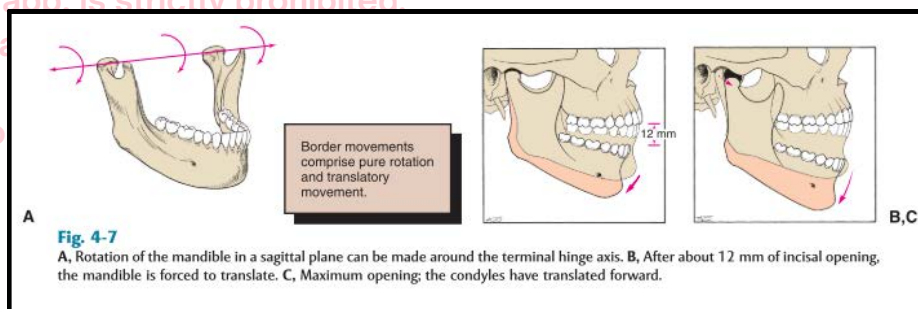
- This position is clinically detectable whether mandible is directed superiorly and anteriorly.
- Centric relation is an anatomically determined most repeatable and reproducible position that acts as a reliable reference point for accurately recording the relationship of maxilla and mandible.
- Therefore, determination of centric relation is a pre requisite for analyses of dental interarch, condylar position and skeletal relationships.
- The condylar position (anatomical relationship) cannot be determined with certainty at clinical examination but the terminal hinge axis (a relationship determined by jaw movement) can be demonstrated.
- The physiologic transverse hinge axis is located by series of controlled opening and closing of the jaw when the mandible is held in the most retruded position relative to maxilla (centric relation). These movement are called terminal hinge movements.

# OCCLUSION SCHEMES

## 2) Mandibular movements:

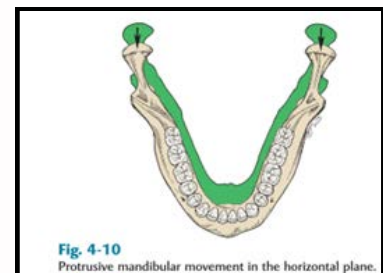
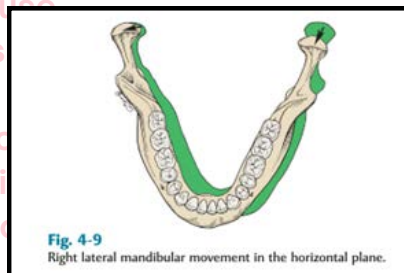
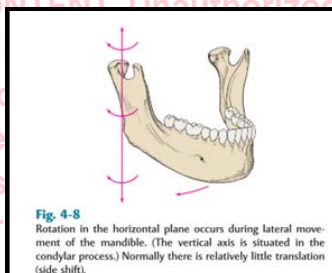


- A) In **sagittal plane** mandible has **purely rotational** opening and closing movement as well as translation around the **transverse horizontal axis (terminal hinge axis)** an imaginary horizontal line through the rotational centers of right and left condylar processes. The initial movement is rotational (hingeing) that occurs for about 12mm of incisor separation after which translation occurs. Condylar movement is similar during protrusive mandibular movement.



- B) In **Horizontal plane** the mandible is capable of rotation around several vertical axes.

- For example, Lateral movement consists of rotation around an axis in the working (latrusive) condylar process with little concurrent translation. A slight lateral translation of the condyle in the working side known as laterotrusion aka Bennett movement or mandibular side shift is seen that can be slightly forward (lateroprotrusion) or slightly backward (lateroretrusion).
- The non-working condyle moves forward and medially and the mandible can make a straight protrusive movement.



recordings. Violators will face strict legal action.

### DISCLAIMER

THIS IS COPYRIGHTED CONTENT. Unauthorized use, including screenshots, copying, misuse, reuse, or resale of any content from this app, is strictly prohibited. Our app monitors and records all screenshots and recordings. Violators will face strict legal action.

THIS IS COPYRIGHTED CONTENT. Unauthorized use, including screenshots, copying, misuse, reuse, or resale of any content from this app, is strictly prohibited. Our app monitors and records all screenshots and recordings. Violators will face strict legal action.

DISCLAIMER

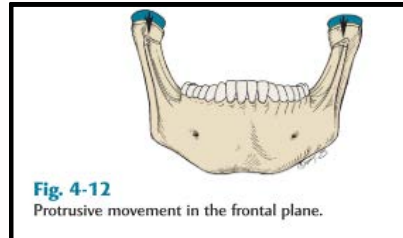
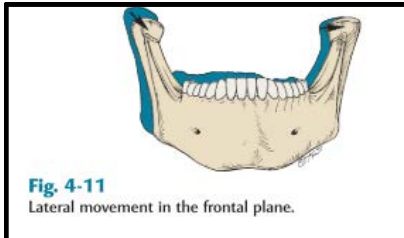
DISCLAIMER  
THIS IS COPYRIGHTED CONTENT. Unauthorized use, including screenshots, copying, misuse, reuse, or resale of any content from this app, is strictly prohibited. Our app monitors and records all screenshots and recordings. Violators will face strict legal action.

THIS IS COPYRIGHTED CONTENT. Unauthorized use, including screenshots, copying, misuse, reuse, or resale of any content from this app, is strictly prohibited. Our app monitors and records all screenshots and recordings. Violators will face strict legal action.

# OCCLUSION SCHEMES

## 2) Mandibular movements:

- C) In Frontal plane** when the lateral movement occurs the non-working condyle moves downward and medially and working condyle rotates around the sagittal axis perpendicular to frontal plane.



## 3) Maximum intercuspation (MI)

- It is the position of teeth when upper and lower teeth are in maximum contact and intercuspation.
- Ideally, it should coincide with the centric relation.
- But MI may or may not coincide with centric relation.
- If maximum intercuspation coincides with the centric relation position, restorative treatment is often straightforward. When maximum intercuspation does not coincide with centric relation, it is necessary to determine whether corrective occlusal therapy is needed before restorative treatment.

## 4) Centric Occlusion:

- It is the occlusion of opposing teeth when the mandible is in the centric relation.

### Maxillomandibular relationships for Complete dentures:

#### A) Determination of Vertical Jaw relation

- They are classified as vertical dimension at rest (VDR) and vertical dimension at occlusion (VDO).
- They can be determined by physiological and mechanical methods.
- All the estimates of vertical dimension must be considered tentative until the teeth are arranged in their trial bases and observation of phonetics and esthetics can be used as a check against the vertical relation established by physiological or mechanical methods.



# OCCLUSION SCHEMES

## B) Determination of Horizontal Jaw relation

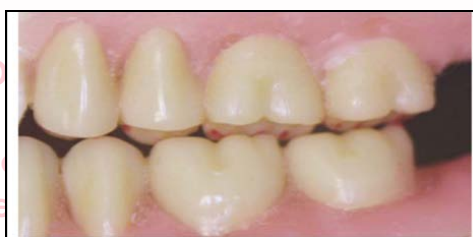- The basic horizontal jaw relation is centric relation.
- It is a reference relationship that must be recorded in any prosthodontic treatment.
- A centric relation record provides the orientation of mandibular to maxillary teeth in centric relation in terminal hinge position in which opening and closing are purely rotational movement.
- Other horizontal jaw relations are at points of movement away from centric relation in the horizontal plane collectively known as eccentric relation.
- Eccentric relation includes protrusive position, right and left lateral excursion and all intermediate position.
- In protrusive excursion the condyles move downward and forward.
- When the mandible moves to one side laterally the condyle on the opposite side moves downward, forward and inward.

## Various types of occlusions in Prosthodontics:

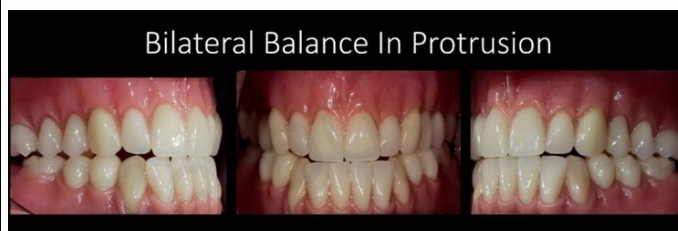There are three recognized concepts that describes the manner in which the teeth should and should not contact in various functional and extrusive position of the mandible.

### 1) Bilaterally balanced occlusion:

- The concept of bilaterally balanced occlusion dictates that maximum number of teeth should contact in all excursive positions of the mandible.
- This requires having a maximum number of teeth in contact in maximum intercuspation and all excursive positions. (Simultaneous contact in centric and eccentric position on both sides)
- In complete denture fabrication, this tooth arrangement helps maintain denture stability because the contact on non-working side prevents the denture from being dislodged. So, it is mostly used in complete denture fabrication.
- In fixed prosthodontics or natural dentition bilaterally balance occlusion is difficult to accomplish and has high rates of failure with increased or accelerated periodontal breakdown.
- Bilaterally balanced occlusion in eccentric positions should be formulated when a maxillary complete denture opposes the removable partial denture. This will improve the stability of denture.



**FIGURE 17-1** Posterior occlusion of a maxillary complete denture opposing a Class I mandibular removable partial denture. The stability of the maxillary complete denture can be promoted by developing balanced occlusion as shown.



Bilateral Balance In Protrusion

## DISCLAIMER

THIS IS COPYRIGHTED CONTENT. Unauthorized use, including screenshots, copying, misuse, reuse, or resale of any content from this app, is strictly prohibited. Our app monitors and records all screenshots and recordings. Violators will face strict legal action.

## DISCLAIMER

THIS IS COPYRIGHTED CONTENT. Unauthorized use, including screenshots, copying, misuse, reuse, or resale of any content from this app, is strictly prohibited. Our app monitors and records all screenshots and recordings. Violators will face strict legal action.

## DISCLAIMER

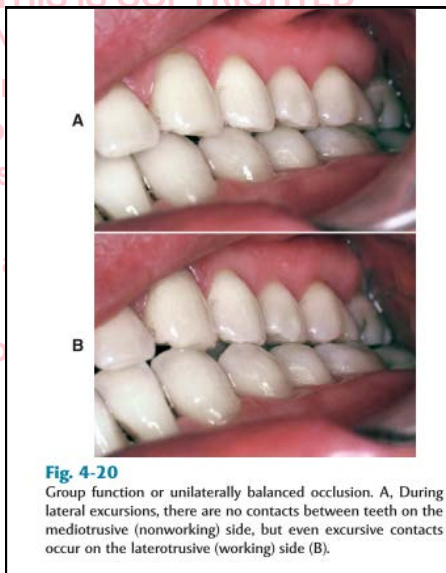
THIS IS COPYRIGHTED CONTENT. Unauthorized use, including screenshots, copying, misuse, reuse, or resale of any content from this app, is strictly prohibited. Our app monitors and records all screenshots and recordings. Violators will face strict legal action.



# OCCLUSION SCHEMES

## 2) Unilateral Balanced occlusion (Group Function Occlusion)

- In a unilaterally balanced articulation, excursive contact occurs between all opposing posterior teeth on the laterotrusive (working) side only. On the mediotrusive (nonworking) side, no contact occurs until the mandible has reached centric relation.
- Thus, in this occlusal arrangement, the load is distributed among the periodontal support of all posterior teeth on the working side.
- This is advantageous especially when the periodontal support of canine is compromised.
- During excursive movement: On the working side occlusal load is distributed and on the non-working side posterior teeth do not contact
- During protrusive movement, there is no posterior teeth contact.



- As the concept of unilateral balanced occlusion evolved, allowing some freedom in anteroposterior direction was suggested to be advantageous. This concept is known as long centric occlusion.
- When the mandible translates from centric relation forward to make anterior tooth contact it is important for posterior teeth to be in harmonious gliding contact. However, the length of long centric is arbitrary ranging from 0.5mm to 1.5 mm and also requires a greater horizontal space between the maxillary and mandibular anterior teeth (deeper lingual concavity), allowing horizontal movement before posterior disocclusion (separation of opposing teeth during eccentric movements of the mandible).

DISCLAIMER

THIS IS COPYRIGHTED CONTENT. Unauthorized use, including screenshots, copying, misuse, or resale of any content from this app, is strictly prohibited. Our app monitors and records all screenshots and recordings. Violators will face strict legal action.

DISCLAIMER

THIS IS COPYRIGHTED CONTENT. Unauthorized use, including screenshots, copying, misuse, or resale of any content from this app, is strictly prohibited. Our app monitors and records all screenshots and recordings. Violators will face strict legal action.

DISCLAIMER

THIS IS COPYRIGHTED CONTENT. Unauthorized use, including screenshots, copying, misuse, or resale of any content from this app, is strictly prohibited. Our app monitors and records all screenshots and recordings. Violators will face strict legal action.

# OCCLUSION SCHEMES

## 3) Mutually protected occlusion (Canine- protected occlusion)

- In this arrangement of occlusion, centric relation coincides with maximum intercuspation.
- The six anterior maxillary teeth together with the six anterior mandibular teeth, guide excursive movements on the mandible, and no posterior occlusal contact occurs during any protrusive or lateral excursions.
- The relationship of the anterior teeth also known as anterior guidance, is critical to the success of this occlusal scheme. In a mutually protected articulation, the posterior teeth come into contact only at the very end of each chewing stroke, minimizing horizontal loading on the teeth.
- Here, the posterior teeth also act as a stop for vertical closure when the mandible returns to its maximum intercuspation.
- Posterior cusps should be sharp and should pass each other closely without contacting to maximize occlusal function.

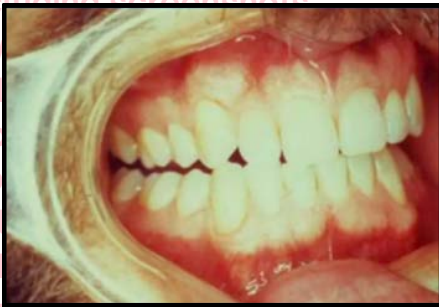

Fig 1: In lateral position, working side

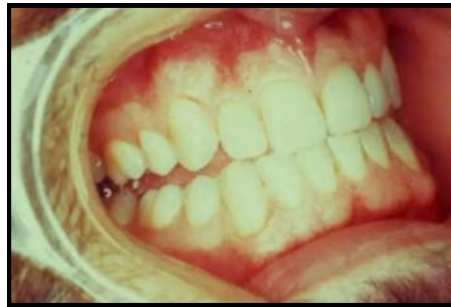

Fig 2: In protrusive position.

DISCLAIMER

THIS IS COPYRIGHTED CONTENT. Unauthorized use, including screenshots, copying, misuse, reuse, or resale of any content from this app, is strictly prohibited. Our app monitors and records all screenshots and recordings. Violators will face strict legal action.

THIS IS COPYRIGHTED CONTENT. Unauthorized use, including screenshots, copying, misuse, reuse, or resale of any content from this app, is strictly prohibited. Our app monitors and records all screenshots and recordings. Violators will face strict legal action.

DISCLAIMER

THIS IS COPYRIGHTED CONTENT. Unauthorized use, including screenshots, copying, misuse, reuse, or resale of any content from this app, is strictly prohibited. Our app monitors and records all screenshots and recordings. Violators will face strict legal action.

DISCLAIMER

THIS IS COPYRIGHTED CONTENT. Unauthorized use, including screenshots, copying, misuse, reuse, or resale of any content from this app, is strictly prohibited. Our app monitors and records all screenshots and recordings. Violators will face strict legal action.

THIS IS COPYRIGHTED CONTENT. Unauthorized use, including screenshots, copying, misuse, reuse, or resale of any content from this app, is strictly prohibited. Our app monitors and records all screenshots and recordings. Violators will face strict legal action.

# REMOVABLE PARTIAL DENTURE (PARTS, CLASP, KENNEDY'S CLASSIFICATION)

Source- Mc crackens, RPD manual, Internet, BDJ Article

- A removable partial denture is a prosthesis that replaces one or more, but not all, natural teeth and supporting structures that can be removed and replaced in the mouth by the patient.

## Indications for RPD

- 1) Lengthy edentulous span (too long for a fixed prosthesis)
- 2) No posterior abutment for a fixed prosthesis
- 3) Excessive alveolar bone loss (leading to esthetic problem)
- 4) Poor prognosis for complete dentures due to residual ridge morphology
- 5) Reduced periodontal support of remaining teeth (that cannot support fixed prosthesis)
- 6) Need for Cross arch stabilization of teeth
- 7) Need for immediate replacement of extracted teeth
- 8) Cost/patient desire considerations

## Classification of Partially edentulous arches:

- The classification proposed by Kennedy is the most widely accepted classification for partially edentulous arches.
- Kennedy divided all partial edentulous arches into four basic classes. Edentulous areas other than those that determine the basic classes were designated as modification spaces.
- The four basic classes are:
  - 1) **Class I:** Bilateral edentulous area located posterior to natural teeth

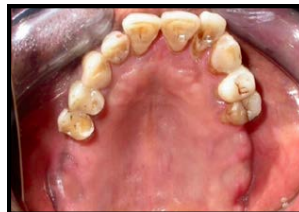

Fig: Kennedy Class I arches (Source-internet and Mc' cracken)

- 2) **Class II:** A Unilateral edentulous area located posterior to natural teeth

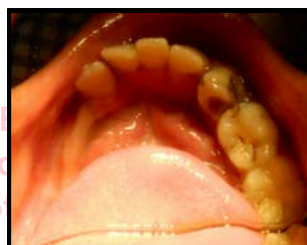
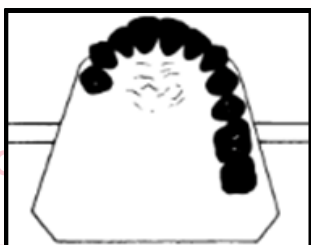
Fig: Kennedy Class II arches (Source-Internet, Mc' cracken)

## DISCLAIMER

THIS IS COPYRIGHTED CONTENT. Unauthorized use, including screenshots, copying, misuse, reuse, or resale of any content from this app, is strictly prohibited. Our app monitors and records all screenshots and recordings. Violators will face strict legal action.

## DISCLAIMER

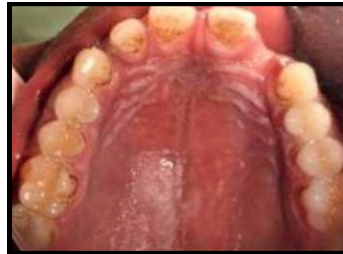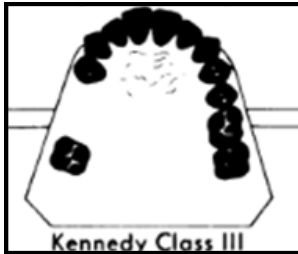
THIS IS COPYRIGHTED CONTENT. Unauthorized use, including screenshots, copying, misuse, reuse, or resale of any content from this app, is strictly prohibited. Our app monitors and records all screenshots and recordings. Violators will face strict legal action.

THIS IS COPYRIGHTED CONTENT. Unauthorized use, including screenshots, copying, misuse, reuse, or resale of any content from this app, is strictly prohibited. Our app monitors and records all screenshots and recordings. Violators will face strict legal action.

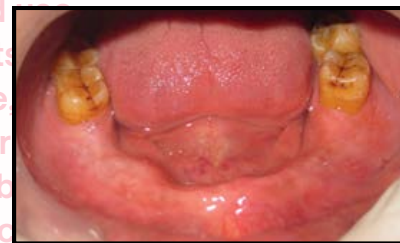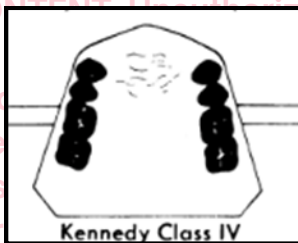
# REMOVABLE PARTIAL DENTURE (PARTS, CLASP, KENNEDY'S CLASSIFICATION)

Source- Mc crackens, RPD manual, Internet, BDJ Article

- 3) **Class III:** A unilateral edentulous area with natural teeth remaining both anterior and posterior to it.



- 4) **Class IV:** A single, but bilateral (crossing the midline), edentulous area located anterior to the remaining natural teeth



DISCLAIMER

THIS IS COPYRIGHTED CONTENT. Unauthorized use, including screenshots, copying, misuse, reuse, or resale of any content from this app, is strictly prohibited. Our app monitors and records all screenshots and recordings. Violators will face strict legal action.

THIS IS COPYRIGHTED CONTENT. Unauthorized use, including screenshots, copying, misuse, reuse, or resale of any content from this app, is strictly prohibited. Our app monitors and records all screenshots and recordings. Violators will face strict legal action.

DISCLAIMER

THIS IS COPYRIGHTED CONTENT. Unauthorized use, including screenshots, copying, misuse, reuse, or resale of any content from this app, is strictly prohibited. Our app monitors and records all screenshots and recordings. Violators will face strict legal action.

THIS IS COPYRIGHTED CONTENT. Unauthorized use, including screenshots, copying, misuse, reuse, or resale of any content from this app, is strictly prohibited. Our app monitors and records all screenshots and recordings. Violators will face strict legal action.

THIS IS COPYRIGHTED CONTENT. Unauthorized use, including screenshots, copying, misuse, reuse, or resale of any content from this app, is strictly prohibited. Our app monitors and records all screenshots and recordings. Violators will face strict legal action.

DISCLAIMER

THIS IS COPYRIGHTED CONTENT. Unauthorized use, including screenshots, copying, misuse, reuse, or resale of any content from this app, is strictly prohibited. Our app monitors and records all screenshots and recordings. Violators will face strict legal action.



# REMOVABLE PARTIAL DENTURE (PARTS, CLASP, KENNEDY'S CLASSIFICATION)

Source- Mc crackens, RPD manual, Internet, BDJ Article

## Rules Governing the Application of Kennedy Method. (Applegate's rule)

### 1) Rule 1

Classification should follow rather than precede any extractions of teeth that might alter the original classification.

### 2) Rule 2

If a third molar is missing and is not to be replaced, it is not considered in the classification.

### 3) Rule 3

If a third molar is present and is to be used as an abutment, it is considered in the classification.

### 4) Rule 4

If a second molar is missing and is not to be replaced, it is not considered in the classification (e.g., if the opposing second molar is likewise missing and is not to be replaced).

### 5) Rule 5

The most posterior edentulous area (or areas) always determines the classification.

### 6) Rule 6

Edentulous areas other than those that determine the classification are referred to as modifications and are designated by their number.

### 7) Rule 7

The extent of the modification is not considered, only the number of additional edentulous areas.

### 8) Rule 8

No modification areas can be included in Class IV arches. (Other edentulous areas that lie posterior to the single bilateral areas crossing the midline would instead determine the classification; see Rule 5.)

## Some Examples of various classification

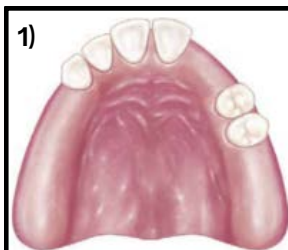


Fig 1: Class I MOD 1

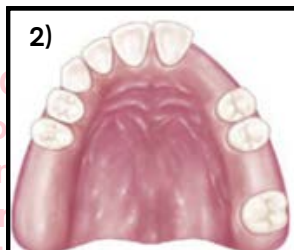

Fig 2: Class II MOD 2

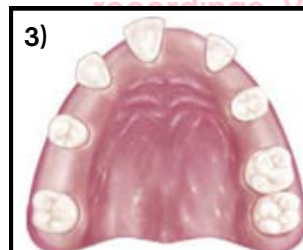

Fig 3: Class III MOD 5

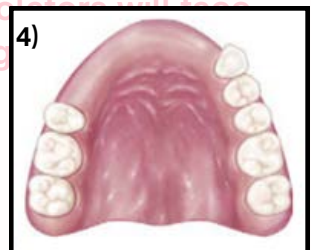

Fig 4: Kennedy Class IV

# REMOVABLE PARTIAL DENTURE (PARTS, CLASP, KENNEDY'S CLASSIFICATION)

Source- Mc crackens, RPD manual, Internet, BDJ Article

## Components of Removeable Partial Denture:

- 1) Major Connector:** The unit of a removable partial denture that connects the parts of one side of the dental arch to those of the other side. Its principal functions are to provide unification and rigidity to the denture.
- 2) Minor Connector:** A unit of a partial denture that connects other components (i.e., direct retainer, indirect retainer, denture base, etc.) to the major connector. The principal functions of minor connectors are to provide unification and rigidity to the denture.
  - Minor connectors are those components that serve as the connecting link between the major connector or the base of a removable partial denture and the other components of the prosthesis, such as the clasp assembly, indirect retainers, occlusal rests, or cingulum rests.
  - Those portions of a removable partial denture framework that retain the denture bases are also minor connectors.

## Basic types of minor connectors are:

- Minor connectors placed into embrasures between two adjacent teeth.

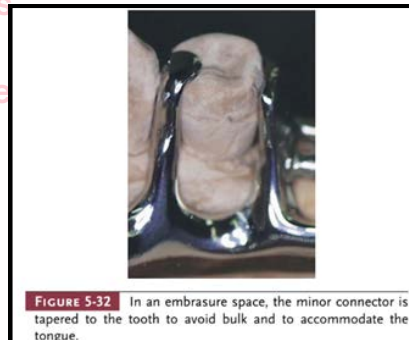
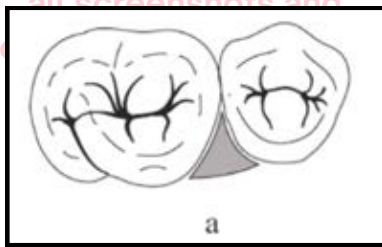


Fig: These connectors should be somewhat triangular shaped in cross section to minimize intrusion into the tongue or vestibular spaces, while still providing adequate bulk for rigidity

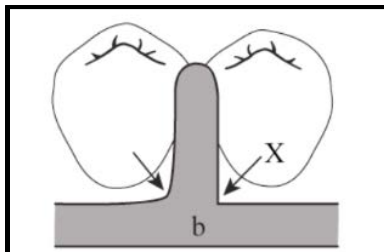
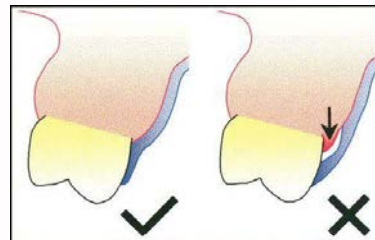


Fig: A minor connector should join the major connector at a right angle and cover as small an area of tissue as possible. The juncture to the major connector should be rounded (arrow) not sharp (X) unless the juncture includes an acrylic finish line.

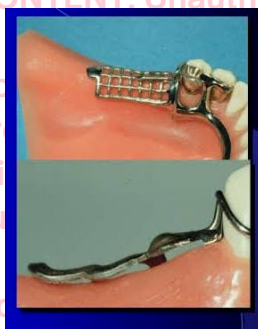

Fig: Relief should be placed on the master cast so that the minor connector does not lie directly on the soft tissue.



Where the minor connector crosses the gingiva perpendicularly there relief should not be given as the gap may lead to gingival overgrowth and plaque trapment

## DISCLAIMER

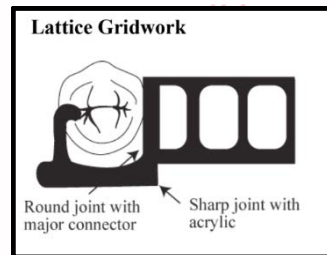
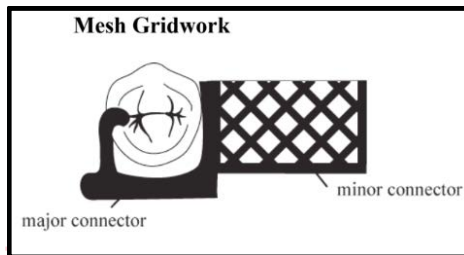
THIS IS COPYRIGHTED CONTENT. Unauthorized use, including screenshots, copying, misuse, reuse, or resale of any content from this app, is strictly prohibited. Our app monitors and records all screenshots and recordings. Violators will face strict legal action.

# REMOVABLE PARTIAL DENTURE (PARTS, CLASP, KENNEDY'S CLASSIFICATION)

Source- Mc crackens, RPD manual, Internet, BDJ Article

**Basic types of minor connectors are:**

- b) Gridwork minor connectors that connect the denture base and teeth to the major connector.



**3) Direct Retainer:** A unit of a partial denture that provides retention against dislodging forces. A direct retainer is commonly called a 'clasp' or 'clasp unit' and is composed of four elements, a rest, a retentive arm, a reciprocal arm and a minor connector.

**4) Indirect Retainer:** A unit of a Class I or II partial denture that prevents or resists movement or rotation of the base(s) away from the residual ridge.

**Indirect retainers usually take the form of rests, and they are placed away from the fulcrum line.**

Indirect retainers should be placed as far as possible from the distal extension base to gain the best possible leverage advantage against lifting of the distal extension base.

The most commonly used indirect retainer is an auxiliary occlusal rest located on an occlusal surface and as far away from the distal extension base as possible.

- **The fulcrum line** on a Class I partial denture as passes through the rest areas of the most posterior abutment on either side of the arch.

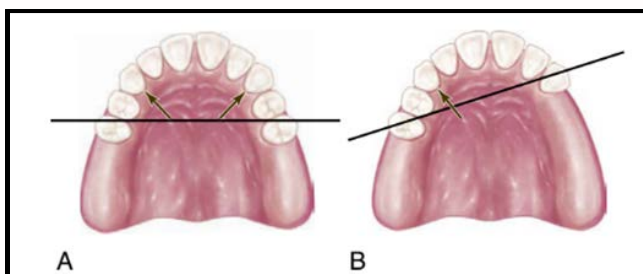


Fig: Class I partially edentulous arch with fulcrum line.  
(arrows indicate the most advantageous position of indirect retainers)

- **The fulcrum line** on class II partial denture is always diagonal, passing through the occlusal rest area of the abutment on the distal extension side and occlusal rest area of the most distal abutment on the other side.

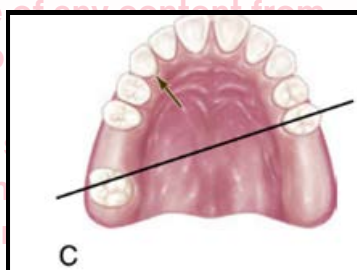


Fig: Class II partially edentulous arch with fulcrum line  
(arrows showing location of indirect retainer)

DISCLAIMER

THIS IS COPYRIGHTED CONTENT. Unauthorized use, including screenshots, copying, misuse, reuse, or resale of any content from this app, is strictly prohibited. Our app monitors and records all screenshots and recordings. Violators will face strict legal action.

DISCLAIMER

THIS IS COPYRIGHTED CONTENT. Unauthorized use, including screenshots, copying, misuse, reuse, or resale of any content from this app, is strictly prohibited. Our app monitors and records all screenshots and recordings. Violators will face strict legal action.

THIS IS COPYRIGHTED CONTENT. Unauthorized use, including screenshots, copying, misuse, reuse, or resale of any content from this app, is strictly prohibited. Our app monitors and records all screenshots and recordings. Violators will face strict legal action.



# REMOVABLE PARTIAL DENTURE (PARTS, CLASP, KENNEDY'S CLASSIFICATION)

Source- Mc crackens, RPD manual, Internet, BDJ Article

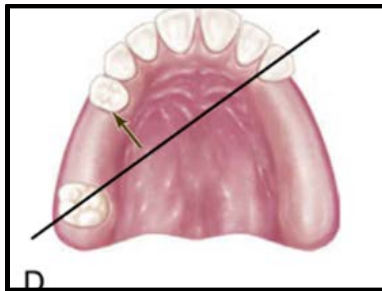


Fig: In class II arch with modification space, if the abutment tooth anterior to the modification space lies far enough away (removed) from the fulcrum line, it may be used effectively for support of the indirect retainer.

- **The fulcrum line** on Class IV partial denture passes through the two abutments adjacent to the single edentulous space.

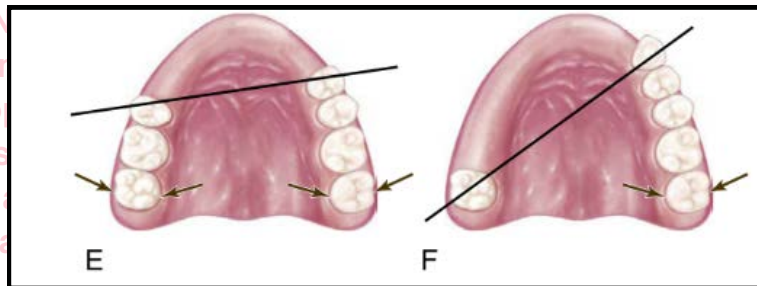


Fig: Class IV arches with fulcrum line. (Arrow shows placement of indirect retainer)

- **The fulcrum line** in a tooth and tissue supported Class III partial denture, is determined by considering the weaker abutment as nonexistent. That end of the base is considered as being a distal extension

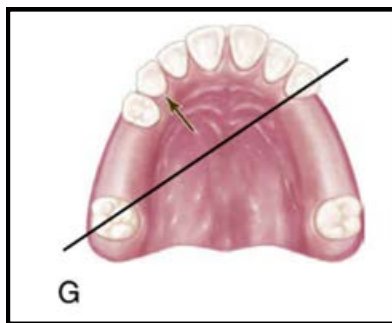


Fig: In a Class III arch with a posterior tooth on the right side, which has a poor prognosis and eventually will be lost, the fulcrum line is considered the same as though posterior tooth were not present. (arrows showing the most advantageous location for indirect retainers)

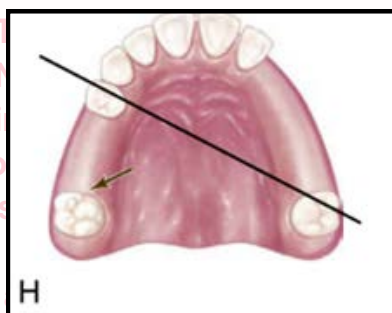


Fig: In a Class III arch with non-supporting anterior teeth, the adjacent edentulous area is considered to be the tissue-supported end, with a diagonal fulcrum line passing through the two principal abutments, as in a Class II arch. (arrows showing the most advantageous position for indirect retainer)

**5) Denture Base:** The unit of a partial denture that covers the residual ridges and supports the denture teeth.

**DISCLAIMER**

THIS IS COPYRIGHTED CONTENT. Unauthorized use, including screenshots, copying, misuse, reuse, or resale of any content from this app, is strictly prohibited. Our app monitors and records all screenshots and recordings. Violators will face strict legal action.

**DISCLAIMER**

THIS IS COPYRIGHTED CONTENT. Unauthorized use, including screenshots, copying, misuse, reuse, or resale of any content from this app, is strictly prohibited. Our app monitors and records all screenshots and recordings. Violators will face strict legal action.

THIS IS COPYRIGHTED CONTENT. Unauthorized use, including screenshots, copying, misuse, reuse, or resale of any content from this app, is strictly prohibited. Our app monitors and records all screenshots and recordings. Violators will face strict legal action.



# REMOVABLE PARTIAL DENTURE (PARTS, CLASP, KENNEDY'S CLASSIFICATION)

Source- Mc crackens, RPD manual, Internet, BDJ Article

## Major Connectors:

- A major connector is the component of the partial denture that connects the parts of the prosthesis located on one side of the arch with those on the opposite side.
- It is that unit of the partial denture to which all other parts are directly or indirectly attached. This component also provides cross-arch stability to help resist displacement by functional stresses.
- Major connectors should be designed and located with the following guidelines in mind
  - a) Major connectors should be free of movable tissue.
  - b) Impingement of gingival tissue should be avoided.
  - c) Bony and soft tissue prominences should be avoided during placement and removal.
  - d) Relief should be provided beneath a major connector to prevent its settling into areas of possible interference, such as inoperable tori or elevated median palatal sutures.
  - e) Major connectors should be located and/or relieved to prevent impingement of tissue that occurs because the distal extension denture rotates in function.

## Types of Major Connectors:

### 1) Mandibular major connectors

The six types of mandibular major connectors include the following:

#### i. Lingual bar:

- Most commonly used major connector in mandible is lingual bar. However, it requires sufficient lingual vestibular depth (about 8mm)
- To avoid any possible impingement the superior border of a lingual bar connector should be located a minimum of 4 mm below the gingival margin.
- The inferior border of a lingual mandibular major connector must not impinge on the tissue in the floor of the mouth. The more inferiorly a lingual bar can be located, the farther the superior border of the bar can be placed from the lingual gingival crevices of adjacent teeth, thereby avoiding impingement on the gingival tissue.
- In distal extension cases there will be some tissue-ward movement of the lingual bar as the denture base moves during function. If bone loss occurs over the edentulous ridges, this movement can become more pronounced and this will cause the lingual bar to impinge upon the lingual tissues. To eliminate the lingual bar from impinging the soft tissues, a wax spacer (relief) of one thickness of 30 gauge wax is placed under the major connector when it is being waxed for casting.



Fig: Lingual Bar

DISCLAIMER

THIS IS COPYRIGHTED CONTENT. Unauthorized use, including screenshots, copying, misuse, reuse, or resale of any content from this app, is strictly prohibited. Our app monitors and records all screenshots and recordings. Violators will face strict legal action.

DISCLAIMER

THIS IS COPYRIGHTED CONTENT. Unauthorized use, including screenshots, copying, misuse, reuse, or resale of any content from this app, is strictly prohibited. Our app monitors and records all screenshots and recordings. Violators will face strict legal action.

THIS IS COPYRIGHTED CONTENT. Unauthorized use, including screenshots, copying, misuse, reuse, or resale of any content from this app, is strictly prohibited. Our app monitors and records all screenshots and recordings. Violators will face strict legal action.

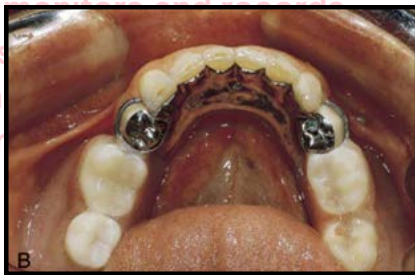DISCLAIMER

# REMOVABLE PARTIAL DENTURE (PARTS, CLASP, KENNEDY'S CLASSIFICATION)

Source- Mc crackens, RPD manual, Internet, BDJ Article

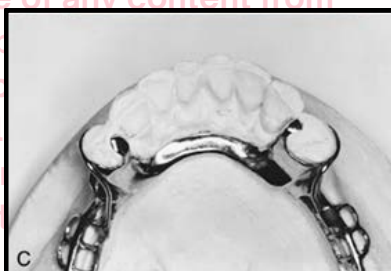## ii. Linguoplate (Lingual Plate)

- The lingual plate consists of a lingual bar plus an extension over the cingula of anterior teeth. It should only be considered in cases where a lingual bar cannot be used.
- Mostly, it is used when there is a high floor of the mouth, a prominent lingual frenum or lingual tori that would be impinged upon by a lingual bar. (When a clinical measurement from the free gingival margins to the slightly elevated floor of the mouth is less than 8 mm, a lingual plate is indicated rather than a lingual bar)
- In Class I situations in which the residual ridges have undergone excessive vertical resorption. A correctly designed lingual plate will engage the remaining teeth to help resist horizontal rotations that is provided by the bracing effect of remaining teeth.
- For stabilizing periodontally weakened teeth, splinting with a lingual plate can be done with definite rests on sound adjacent teeth. (In cases where there is anterior tooth mobility, these connectors stabilizes the teeth but doesn't reduce mobility.)



## iii. Sublingual bar

- A modification of the lingual bar that has been demonstrated to be useful when the height of the floor of the mouth does not allow placement of the superior border of the bar at least 4 mm below the free gingival margin.
- Placement is inferior and posterior to the usual placement of a lingual bar, lying over and parallel to the anterior floor of the mouth.
- It is generally accepted that a sublingual bar can be used in lieu of a lingual plate if the lingual frenum does not interfere, or in the presence of an anterior lingual undercut that would require considerable blockout for a conventional lingual bar.
- Contraindications include interfering lingual tori, high attachment of a lingual frenum, and interference with elevation of the floor of the mouth during functional movements.



DISCLAIMER

THIS IS COPYRIGHTED CONTENT. Unauthorized use, including screenshots, copying, misuse, reuse, or resale of any content from this app, is strictly prohibited. Our app monitors and records all screenshots and recordings. Violators will face strict legal action.

DISCLAIMER  
THIS IS COPYRIGHTED CONTENT. Unauthorized use, including screenshots, copying, misuse, reuse, or resale of any content from this app, is strictly prohibited. Our app monitors and records all screenshots and recordings. Violators will face strict legal action.

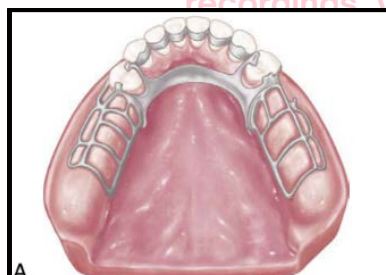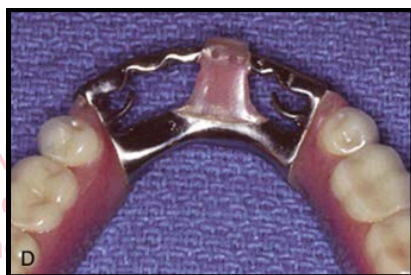DISCLAIMER  
THIS IS COPYRIGHTED CONTENT. Unauthorized use, including screenshots, copying, misuse, reuse, or resale of any content from this app, is strictly prohibited. Our app monitors and records all screenshots and recordings. Violators will face strict legal action.

# REMOVABLE PARTIAL DENTURE (PARTS, CLASP, KENNEDY'S CLASSIFICATION)

Source- Mc crackens, RPD manual, Internet, BDJ Article

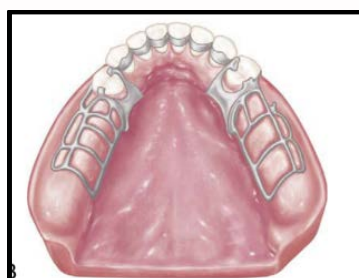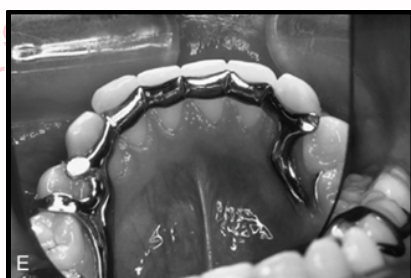## iv. Lingual bar with cingulum bar (continuous bar)

- The connector consists of a lingual bar plus a secondary bar resting above the cingula of the anterior teeth. The secondary bar supposedly acts as an indirect retainer and performs a role in the horizontal stabilization of periodontally-involved teeth.
- The performance of these functions is questionable. Additionally, this major connector can create a food trap between the two bars. Thus, the use of this type of connector is not encouraged.



## v. Cingulum bar (continuous bar)

- Although this design may reduce the food entrapment it will not provide adequate rigidity.



## vi. Labial bar

- Where extreme lingual inclination of the remaining teeth is present and no reasonable way exists to use a lingual bar without interfering with tongue movements, a labial bar may be used.
- Margins of major connectors adjacent to gingival tissue should be located far enough from the tissue
- To accomplish this, it is recommended that) At the inferior border of the lingual bar connector, the limiting factor is the height of the moving tissue in the floor of the mouth. Because the connector must have sufficient width and bulk to provide rigidity, lingual plate is commonly used when space is insufficient for a lingual bar.

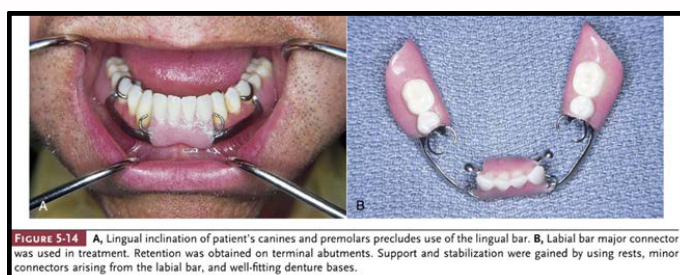
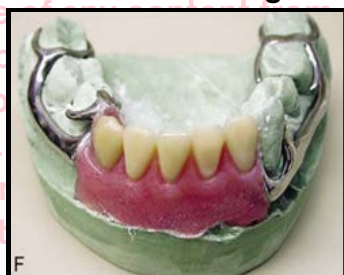

FIGURE 5-14 A, Lingual inclination of patient's canines and premolars precludes use of the lingual bar. B, Labial bar major connector was used in treatment. Retention was obtained on terminal abutments. Support and stabilization were gained by using rests, minor connectors arising from the labial bar, and well-fitting denture bases.

DISCLAIMER

THIS IS COPYRIGHTED CONTENT. Unauthorized use, including screenshots, copying, misuse, reuse, or resale of any content from this app, is strictly prohibited. Our app monitors and records all screenshots and recordings. Violators will face strict legal action.

DISCLAIMER

THIS IS COPYRIGHTED CONTENT. Unauthorized use, including screenshots, copying, misuse, reuse, or resale of any content from this app, is strictly prohibited. Our app monitors and records all screenshots and recordings. Violators will face strict legal action.

DISCLAIMER

THIS IS COPYRIGHTED CONTENT. Unauthorized use, including screenshots, copying, misuse, reuse, or resale of any content from this app, is strictly prohibited. Our app monitors and records all screenshots and recordings. Violators will face strict legal action.



# REMOVABLE PARTIAL DENTURE (PARTS, CLASP, KENNEDY'S CLASSIFICATION)

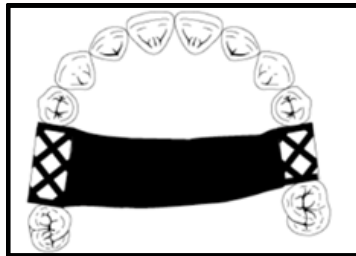
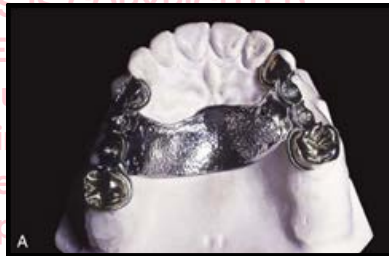Source- Mc crackens, RPD manual, Internet, BDJ Article

## 2) Maxillary major connectors:

Six basic types of maxillary major connectors are as follows:

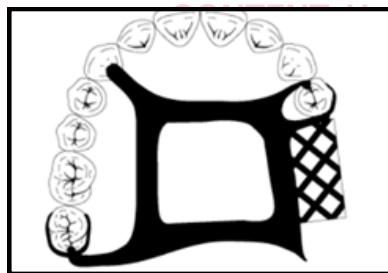
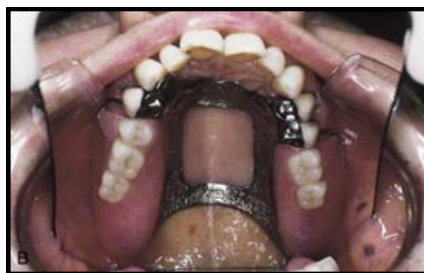### i. Single palatal strap

- It should never be used in cases involving distal extensions or replacement of anterior teeth.
- The palatal strap is similar to palatal bar, but with a broader area of contact, providing better stabilization and stress distributing properties with minimum bulk. Therefore, it is preferable to the palatal bar for posterior tooth supported cases. However, other connectors should be chosen if there is a large torus or if many teeth are being replaced.



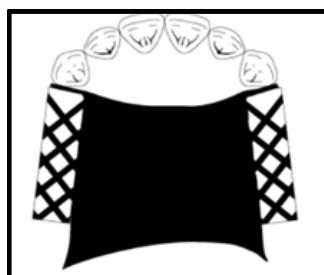
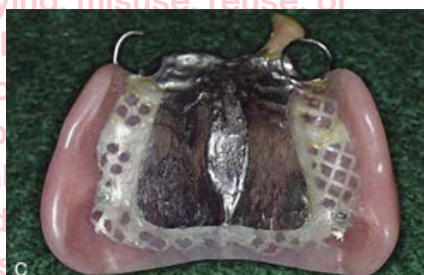### ii. Combination anterior and posterior palatal strap-type connector

- The anterior-posterior palatal strap provides maximum rigidity and minimum bulk.
- It can be used in most maxillary partial denture designs and is especially useful in cases with a torus palatinus.



### iii. Full Palatal plate-type connector

- The full palatal plate is particularly indicated when maximum tissue support is required.
- It should be the major connector of choice in long distal extension cases or where six or less anterior teeth remain.



DISCLAIMER

THIS IS COPYRIGHTED CONTENT. Unauthorized use, including screenshots, copying, misuse, reuse, or resale of any content from this app, is strictly prohibited. Our app monitors and records all screenshots and recordings. Violators will face strict legal action.

DISCLAIMER

THIS IS COPYRIGHTED CONTENT. Unauthorized use, including screenshots, copying, misuse, reuse, or resale of any content from this app, is strictly prohibited. Our app monitors and records all screenshots and recordings. Violators will face strict legal action.

THIS IS COPYRIGHTED CONTENT. Unauthorized use, including screenshots, copying, misuse, reuse, or resale of any content from this app, is strictly prohibited. Our app monitors and records all screenshots and recordings. Violators will face strict legal action.

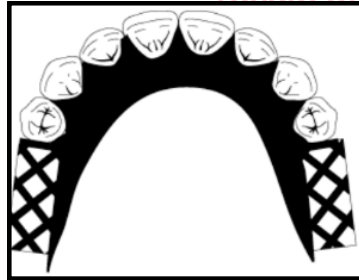
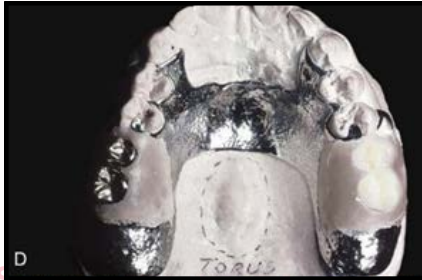

# REMOVABLE PARTIAL DENTURE (PARTS, CLASP, KENNEDY'S CLASSIFICATION)

Source- Mc crackens, RPD manual, Internet, BDJ Article

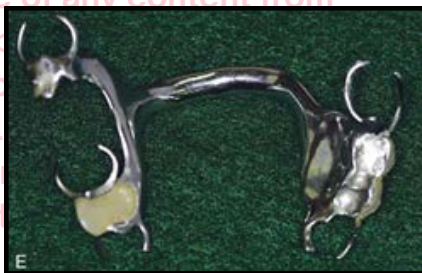## iv. U-shaped palatal connector

- From a biomechanical standpoint the palatal horseshoe is a poor connector and should never be used unless absolutely necessary.



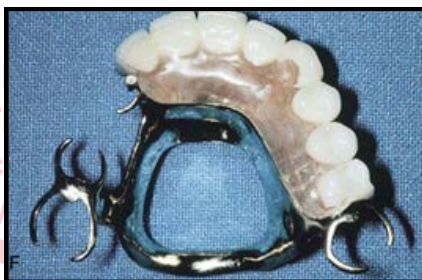## v. Single palatal bar

- The palatal bar should only be used in tooth supported cases where no other connector can be used. It is usually objectionable due to its bulk.



## vi. Anterior-posterior palatal bars

- A variation of the double palatal strap is the anterior-posterior palatal bar connector where the palatal connector elements are narrower anterior-posteriorly.
- Due to the narrowness of the elements, the bars must have greater bulk for rigidity, and thus the design is more objectionable to the patient.
- In addition, strap connectors provide greater distribution of stresses to the palatal tissues since a greater surface area is contacted.



DISCLAIMER

THIS IS COPYRIGHTED CONTENT. Unauthorized use, including screenshots, copying, misuse, reuse, or resale of any content from this app, is strictly prohibited. Our app monitors and records all screenshots and recordings. Violators will face strict legal action.

DISCLAIMER  
THIS IS COPYRIGHTED CONTENT. Unauthorized use, including screenshots, copying, misuse, reuse, or resale of any content from this app, is strictly prohibited. Our app monitors and records all screenshots and recordings. Violators will face strict legal action.

DISCLAIMER

THIS IS COPYRIGHTED CONTENT. Unauthorized use, including screenshots, copying, misuse, reuse, or resale of any content from this app, is strictly prohibited. Our app monitors and records all screenshots and recordings. Violators will face strict legal action.

# REMOVABLE PARTIAL DENTURE (PARTS, CLASP, KENNEDY'S CLASSIFICATION)

Source- Mc crackens, RPD manual, Internet, BDJ Article

## Direct Retainer

- A direct retainer is a unit of a removable partial denture that engages an abutment tooth in such a manner as to resist displacement of the prosthesis away from basal seat tissues.
- It is usually composed of a retentive arm, a reciprocal (bracing) element or arm, a rest and a minor connector.
- Most mechanical retention is derived from the use of direct retainers (clasp assemblies) utilizing tooth undercuts. There are two classes of mechanical retainers:
  1. **Intracoronaral:** Intracoronaral retainers (precision attachments) are mechanical devices set into the casting of a full crown. These are generally reserved for removable partial denture therapy that requires exceptional effort in producing ideal esthetics. There are many contraindications and disadvantages to precision attachments.
  2. **Extra coronal:** They engage the external surface of an abutment in a natural undercut or in a prepared depression. There are two main classes of clasps:
    - i. **SupraBulge Retainers** - those that approach the undercut from above the height of contour
    - ii. **InfraBulge Retainers** - those that approach the undercut from below.

## Requirements of Clasp Assembly:

All clasp assemblies must meet the following requirements.

1. The occlusal rest must be designed to prevent movement of the clasp arms toward the cervical.
2. Each retentive terminal should be opposed by a reciprocal component capable of resisting any transient pressures exerted by the retentive arm during placement and removal.
3. Clasp retainers on abutment teeth adjacent to distal extension bases should be designed so that they will avoid direct transmission of tipping and rotational forces to the abutment. This is accomplished through proper location of the retentive terminal relative to the rest, or by the use of a more flexible clasp arm in relation to the anticipated rotation of the denture under functional forces.
4. Retention - retentive arms located in undercuts on the abutments  
Encirclement of greater than 180° of the teeth. This prevents the prosthesis from moving away from the tooth.
5. Passivity - at rest, a direct retainer should not exert force against a tooth

## Types of Clasp Assembly (Direct Retainers)

### DISCLAIMER

THIS IS COPYRIGHTED CONTENT. Unauthorized use, including screenshots, copying, misuse, reuse, or resale of any content from this app, is strictly prohibited. Our app monitors and records all screenshots and recordings. Violators will face strict legal action.

### DISCLAIMER

THIS IS COPYRIGHTED CONTENT. Unauthorized use, including screenshots, copying, misuse, reuse, or resale of any content from this app, is strictly prohibited. Our app monitors and records all screenshots and recordings. Violators will face strict legal action.

THIS IS COPYRIGHTED CONTENT. Unauthorized use, including screenshots, copying, misuse, reuse, or resale of any content from this app, is strictly prohibited. Our app monitors and records all screenshots and recordings. Violators will face strict legal action.

### DISCLAIMER

# REMOVABLE PARTIAL DENTURE (PARTS, CLASP, KENNEDY'S CLASSIFICATION)

Source- Mc crackens, RPD manual, Internet, BDJ Article

## Types of Clasp Assembly (Direct Retainers)

### A) For tooth born RPDs:

- For Kennedy Class III and IV removable partial dentures and for modification spaces of Class I and II (tooth and tissue supported RPDs) these clasps can be used as their only function is to prevent dislodgement of the prosthesis without the damage to the abutment teeth.
- Cast Supra bulge clasp design should be used in most tooth born RPDs.
- Exception to the use of cast supra bulge clasp design used in tooth borne cases are:
  - a. Esthetic concerns: Since wrought-wire clasps can be placed into greater undercuts (0.02") than cast clasps (0.01") they can be placed lower on teeth, allowing better esthetics in some cases. Infrabulge clasps are also less visible.
  - b. Where a posterior abutment is mobile or of questionable prognosis, the use of the stress-breaking qualities of a wrought clasp on the anterior abutment may be needed. This would allow the prosthesis to be converted into a distal extension type if the weak posterior abutment should be lost.
  - c. Where abutments are mobile, the tooth borne segment is extensive, the use of the stress-breaking clasps should be considered.

### The suprabulge clasp assembly include:

#### 1. Circumferential Clasp (Circle or Akers Clasp)

- It is the clasp of choice for tooth borne RPDs, because of its retentive and stabilizing ability.
- It consists of one retentive arm opposed by reciprocal arm(non-retentive) originating from the rest.
- The retentive arm begins above the height of contour, and curves and tapers to its terminal tip, in the gingival 1/3rd of the tooth.

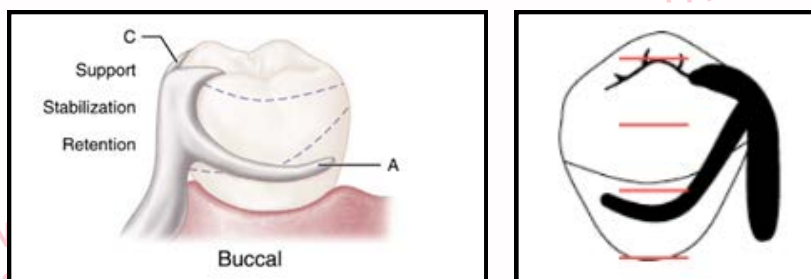


Fig: Retentive arm of Akers or circumferential clasp assembly.

- The bracing arm(reciprocal) is in the middle 1/3 of the tooth, and is broader occluso-gingivally, does not taper and is either entirely above the height of contour or completely on a prepared guiding plane.
- it should never be designed into an undercut, as it is a rigid element.

### DISCLAIMER

THIS IS COPYRIGHTED CONTENT. Unauthorized use, including screenshots, copying, misuse, reuse, or resale of any content from this app, is strictly prohibited. Our app monitors and records all screenshots and recordings. Violators will face strict legal action.

### DISCLAIMER

THIS IS COPYRIGHTED CONTENT. Unauthorized use, including screenshots, copying, misuse, reuse, or resale of any content from this app, is strictly prohibited. Our app monitors and records all screenshots and recordings. Violators will face strict legal action.

THIS IS COPYRIGHTED CONTENT. Unauthorized use, including screenshots, copying, misuse, reuse, or resale of any content from this app, is strictly prohibited. Our app monitors and records all screenshots and recordings. Violators will face strict legal action.



# REMOVABLE PARTIAL DENTURE (PARTS, CLASP, KENNEDY'S CLASSIFICATION)

Source- Mc crackens, RPD manual, Internet, BDJ Article


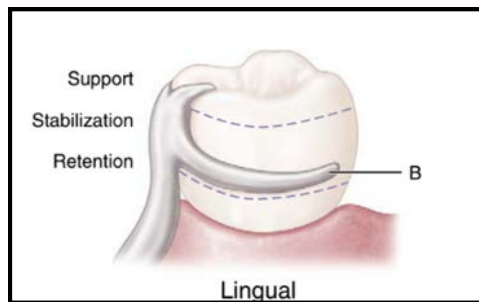


Fig: Reciprocal arm of Akers Clasp

- A direct retainer should be designed with its elements in the proper positions and in the correct proportions. If the height of contour is incorrect for placement of the arms of the direct retainer, the heights of contour should be modified in the abutment tooth.
- Direct retainer (Clasp assembly) itself should not be altered (i.e., Perform abutment modifications – don't distort the design of the direct retainer)

## 2. Ring Clasp

- It is a form of circumferential clasp which encircles nearly all of a tooth from its point of origin.
- It is usually used with mesially and lingually tilted mandibular molars (with a mesiolingual undercut) or mesially and buccally tilted maxillary molars (with a mesiobuccal undercut)
- For this clasp assembly to be used undercut should be present on the same side of the rest seat that is adjacent to edentulous space.
- It is used when a proximal undercut cannot be approached by other means. For example, when a mesiolingual undercut on a lower molar abutment cannot be approached directly because of its proximity to the occlusal rest area and cannot be approached with a bar clasp arm because of lingual inclination of the tooth.
- The ring clasp encircling the tooth allows the undercut to be approached from the distal aspect of the tooth. The clasp should never be used as an unsupported ring because if it is free to open and close as a ring, it cannot provide reciprocation or stabilization. Instead, the ring-type clasp should always be used with a supporting strut on the nonretentive side, with or without an auxiliary occlusal rest on the opposite marginal ridge.

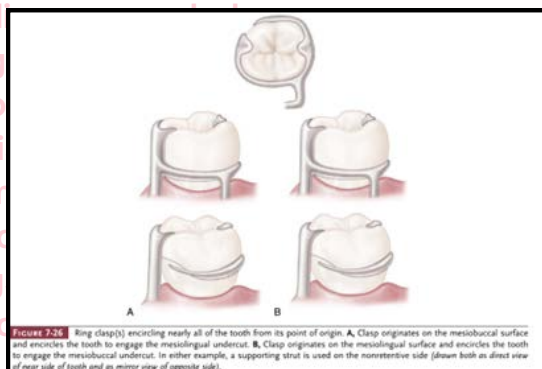
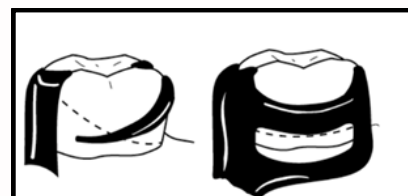


FIGURE 2-36 Ring clasp(s) encircling nearly all of the tooth from its point of origin. A, Clasp originates on the mesiobuccal surface and encircles the tooth to engage the mesiolingual undercut. B, Clasp originates on the mesiolingual surface and encircles the tooth to engage the mesiobuccal undercut. In either example, a supporting strut is used on the nonretentive side (shown both as direct view of rear side of tooth and as mirror view of opposite side).



DISCLAIMER

THIS IS COPYRIGHTED CONTENT. Unauthorized use, including screenshots, copying, misuse, reuse, or resale of any content from this app, is strictly prohibited. Our app monitors and records all screenshots and recordings. Violators will face strict legal action.

DISCLAIMER

THIS IS COPYRIGHTED CONTENT. Unauthorized use, including screenshots, copying, misuse, reuse, or resale of any content from this app, is strictly prohibited. Our app monitors and records all screenshots and recordings. Violators will face strict legal action.

THIS IS COPYRIGHTED CONTENT. Unauthorized use, including screenshots, copying, misuse, reuse, or resale of any content from this app, is strictly prohibited. Our app monitors and records all screenshots and recordings. Violators will face strict legal action.

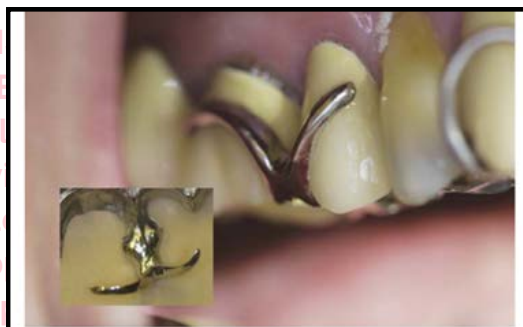

# REMOVABLE PARTIAL DENTURE (PARTS, CLASP, KENNEDY'S CLASSIFICATION)

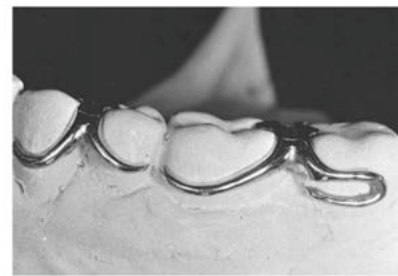Source- Mc crackens, RPD manual, Internet, BDJ Article

## 3. Embrasure (Double Akers) Clasp

- Used in a quadrant where no edentulous area exists, or where a distal approach clasp cannot be used on the most posterior tooth. (That is where there is no usable retentive undercuts)
- It has two rests, two retentive arms and two bracing arms.
- Allows placement of direct retainer where none could otherwise be placed (especially contralateral to the edentulous span on a Class II case)
- Hygiene considerations are there as it covers a large surface area.



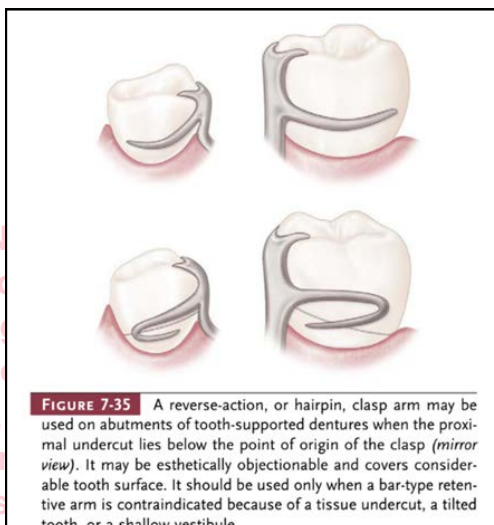
**FIGURE 7-29** Embrasure clasps extend through occlusal embrasures to engage facial undercuts when no modification spaces are present.



**FIGURE 7-30** Embrasure and hairpin circumferential retentive clasp arms. The terminus of each engages a suitable retentive undercut. Use of a hairpin-type clasp on the second molar is made necessary by the fact that the only available undercut lies directly below the point of origin of the clasp arm.

## 4. C clasp (Hairpin or reverse action Clasp)

- The retentive area (undercut) is adjacent the occlusal rest.
- The upper arm is a minor a connector giving rise to tapered lower arm.
- The reverse-action, or hairpin, clasp arm is designed to allow a proximal undercut to be engaged from an occlusal approach.
- It is almost impossible to adjust and is non-esthetic and also covers extensive tooth surface and acts as a food trap.



**FIGURE 7-35** A reverse-action, or hairpin, clasp arm may be used on abutments of tooth-supported dentures when the proximal undercut lies below the point of origin of the clasp (mirror view). It may be esthetically objectionable and covers considerable tooth surface. It should be used only when a bar-type retentive arm is contraindicated because of a tissue undercut, a tilted tooth, or a shallow vestibule.

DISCLAIMER

THIS IS COPYRIGHTED CONTENT. Unauthorized use, including screenshots, copying, misuse, reuse, or resale of any content from this app, is strictly prohibited. Our app monitors and records all screenshots and recordings. Violators will face strict legal action.

DISCLAIMER

THIS IS COPYRIGHTED CONTENT. Unauthorized use, including screenshots, copying, misuse, reuse, or resale of any content from this app, is strictly prohibited. Our app monitors and records all screenshots and recordings. Violators will face strict legal action.

DISCLAIMER

THIS IS COPYRIGHTED CONTENT. Unauthorized use, including screenshots, copying, misuse, reuse, or resale of any content from this app, is strictly prohibited. Our app monitors and records all screenshots and recordings. Violators will face strict legal action.

# REMOVABLE PARTIAL DENTURE (PARTS, CLASP, KENNEDY'S CLASSIFICATION)

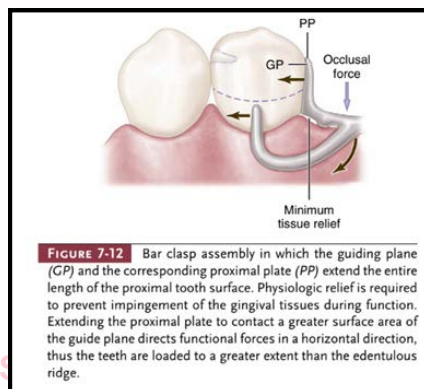
Source- Mc crackens, RPD manual, Internet, BDJ Article

## B) For Tooth and Tissue borne Prosthesis:

- For Class I and II (partially edentulous arches) a direct retainer(clasp assembly) should be placed with special attention.
- In these cases, stress is created due to rotational movement of the prosthesis. When the denture bases are placed under function rotation occurs about the rest seats of the most posterior abutments.
- Direct retainers with stress breaking capabilities should be placed in these cases. These include:

### 1. Bar Clasps (gingivally approaching clasp)

- The bar clasp is a cast clasp that arises from the partial denture framework and approaches the retentive undercut from gingival direction (as opposed to a circumferential clasp that approaches the undercut from the occlusal direction).
- The bar clasp arm has been classified by the shape of the retentive terminal and are present as T, modified T, I, Y, L, U, S
- The shape is not important as long as the clasp assembly is mechanically and functionally stable, covers minimal tooth structure with minimum display (**the I bar most often meets these requirements**)
- T- and Y-shaped terminal ends are the most misused clasps. The full area coverage of the T and Y terminal ends is rarely necessary for adequate retention.
- Soft tissue relief is provided under the approach arm with 28- or 30-gauge wax, to prevent tissue impingement.



- It should not be used in cases with deep cervical and severe soft tissue or bony undercuts and in area with pronounced frenal attachments as it can lead to food trap and impingement.
- At least of 4mm of vestibular depth is required for the approach arm of bar type clasp (3mm from free gingival margin and 1mm for thickness of clasp) so should not be used if insufficient depth is present.

## DISCLAIMER

THIS IS COPYRIGHTED CONTENT. Unauthorized use, including screenshots, copying, misuse, reuse, or resale of any content from this app, is strictly prohibited. Our app monitors and records all screenshots and recordings. Violators will face strict legal action.

## DISCLAIMER

THIS IS COPYRIGHTED CONTENT. Unauthorized use, including screenshots, copying, misuse, reuse, or resale of any content from this app, is strictly prohibited. Our app monitors and records all screenshots and recordings. Violators will face strict legal action.

THIS IS COPYRIGHTED CONTENT. Unauthorized use, including screenshots, copying, misuse, reuse, or resale of any content from this app, is strictly prohibited. Our app monitors and records all screenshots and recordings. Violators will face strict legal action.

## DISCLAIMER

# REMOVABLE PARTIAL DENTURE (PARTS, CLASP, KENNEDY'S CLASSIFICATION)

Source- Mc crackens, RPD manual, Internet, BDJ Article

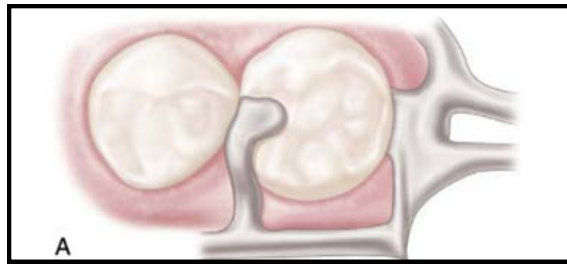


Fig: A) Occlusal view of bar clasp assembly with proximal plate, rest with minor connector and retentive arm)

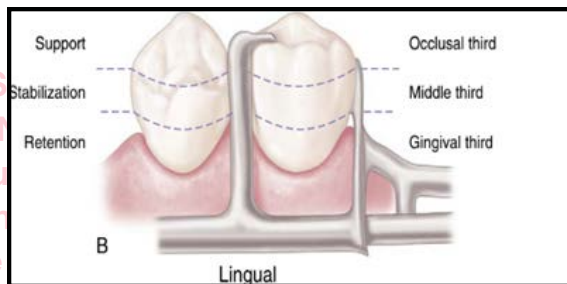
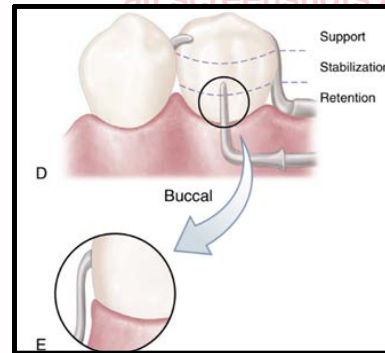


Fig: B) The proximal plate minor connector extends just far enough lingually so that it combines with the mesial minor connector to prevent lingual migration of the abutment. D) I-bar retainer located at greatest prominence of tooth in the gingival third. E) Mesial view of I-bar illustrating the retentive tip relationship to the undercut and a region superior to the height of contour, which serves a stabilization function in encirclement.



- The most commonly used clasp assembly for tooth and tissue born prosthesis where stress release is required is **RPI clasp assembly**

## RPI Clasp assembly:



Fig: The RPI system with mandibular distal extension saddles

- Basically, this clasp assembly consists of a mesio-occlusal rest with the minor connector placed into the mesiolingual embrasure, but not contacting the adjacent tooth.
- A distal guiding plane, extending from the marginal ridge to the junction of the middle and gingival thirds of the abutment tooth, that is prepared to receive a proximal plate. The buccolingual width of the guiding plane is determined by the proximal contour of the tooth. The proximal plate, in conjunction with the minor connector supporting the rest, provides the stabilizing and reciprocal aspects of the clasp assembly.

## DISCLAIMER

THIS IS COPYRIGHTED CONTENT. Unauthorized use, including screenshots, copying, misuse, reuse, or resale of any content from this app, is strictly prohibited. Our app monitors and records all screenshots and recordings. Violators will face strict legal action.

## DISCLAIMER

THIS IS COPYRIGHTED CONTENT. Unauthorized use, including screenshots, copying, misuse, reuse, or resale of any content from this app, is strictly prohibited. Our app monitors and records all screenshots and recordings. Violators will face strict legal action.

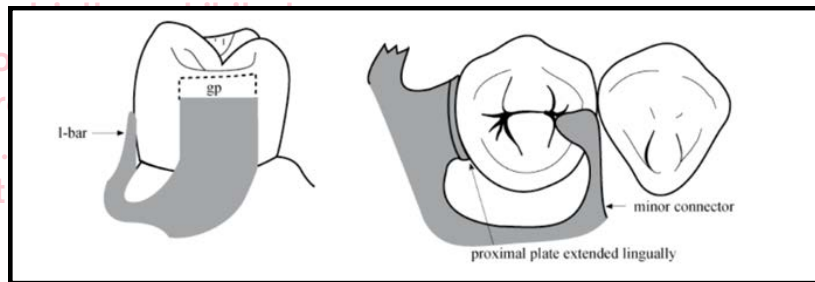
THIS IS COPYRIGHTED CONTENT. Unauthorized use, including screenshots, copying, misuse, reuse, or resale of any content from this app, is strictly prohibited. Our app monitors and records all screenshots and recordings. Violators will face strict legal action.



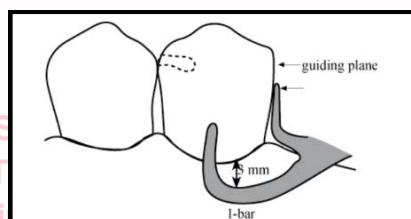
# REMOVABLE PARTIAL DENTURE (PARTS, CLASP, KENNEDY'S CLASSIFICATION)

Source- Mc crackens, RPD manual, Internet, BDJ Article

- The I-bar should be located in the gingival third of the buccal or labial surface of the abutment in a 0.01-inch undercut. The whole arm of the I-bar should be tapered to its terminus, with no more than 2 mm of its tip contacting the abutment. The retentive tip contacts the tooth from the undercut to the height of contour.
- Its components include
  - i. "R" - rest (always present mesially)-The rest is located at the mesio-occlusal surface or mesiolingual surface.
  - ii. "P" - proximal plate- The proximal plate (essentially a wide minor connector) is located on a guide plane on the distal surface of the tooth. The superior edge of the proximal plate is located at the bottom of the guiding plane. The proximal plate extends lingually so that the distance between the minor connector and the proximal plate is less than the mesio-distal width of the tooth. The plate is approximately 1 mm thick and joins the framework at a right angle.



- iii. "I" - I-bar (retentive arm) The I-bar clasp is located on the buccal surface of the premolar and on the mesio-buccal surface of the canine. The I-bar originates at the gridwork and approaches the tooth from the gingival direction. The bend in the I-bar should be located at least 3 mm from the gingival margin to prevent food entrapment and provide the length for the necessary flexibility. Cast clasp is used and usually placed below the height of the contour.



## Contraindications to the R.P.I. Clasp

1. Insufficient depth of the vestibule. (The inferior border of the I-bar must be located at least 4 mm from the gingival margin.)
2. No labial or buccal undercut on the abutment
3. Severe soft tissue undercut
4. Disto-buccal undercut (less than 180° encirclement)

## DISCLAIMER

THIS IS COPYRIGHTED CONTENT. Unauthorized use, including screenshots, copying, misuse, reuse, or resale of any content from this app, is strictly prohibited. Our app monitors and records all screenshots and recordings. Violators will face strict legal action.

## DISCLAIMER

THIS IS COPYRIGHTED CONTENT. Unauthorized use, including screenshots, copying, misuse, reuse, or resale of any content from this app, is strictly prohibited. Our app monitors and records all screenshots and recordings. Violators will face strict legal action.

THIS IS COPYRIGHTED CONTENT. Unauthorized use, including screenshots, copying, misuse, reuse, or resale of any content from this app, is strictly prohibited. Our app monitors and records all screenshots and recordings. Violators will face strict legal action.

## DISCLAIMER



# REMOVABLE PARTIAL DENTURE (PARTS, CLASP, KENNEDY'S CLASSIFICATION)

Source- Mc crackens, RPD manual, Internet, BDJ Article

## 2. RPA Clasp

- This clasp assembly is similar to the RPI design except a wrought wire circumferential clasp (Akers) is used instead of the I-bar.
- It is used when there is insufficient vestibule depth or when a severe tissue undercut exists.

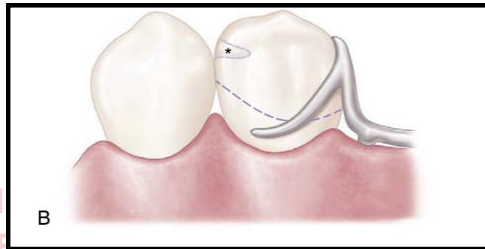
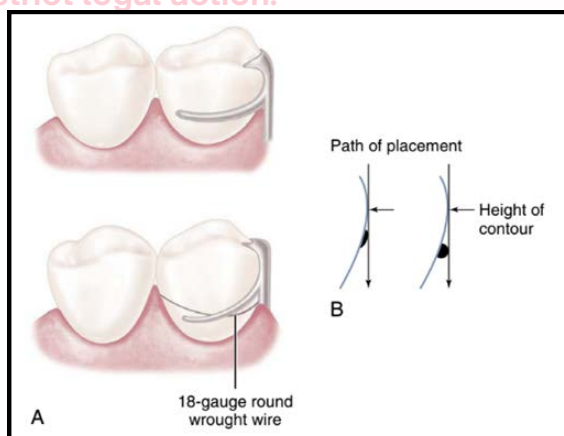


Fig: B, Modification of the RPI system, (rest, proximal plate, Akers) or RPA clasp is indicated when a bar-type clasp is contraindicated and a desirable undercut is located in the gingival third of the tooth away from the extension base area.

## 3. Combination Clasp

- The combination clasp is similar to the cast circumferential clasp with the exception that the retentive arm is fabricated from a round wrought wire (platinum-gold-palladium alloy or chrome-cobalt alloy).
- It consists of a cast reciprocal arm. The retentive arm (the wrought wire is flexible and in round form)
- It is more adjustable than cast or 1/2 round forms and provides better esthetics (due to its round form and smaller diameter - 18 gauge)



**FIGURE 7-21** A, A combination clasp consists of a cast reciprocal arm and a tapered, round wrought-wire retentive clasp arm. The latter is cast to, or soldered to, a cast framework. This design is recommended for the anterior abutment of the posterior modification space in a Class II partially edentulous arch, where only a mesiobuccal undercut exists, to minimize the effects of a first-class lever system. B, In addition to the advantages of flexibility, adjustability, and appearance, a wrought-wire retentive arm makes only line contact with the abutment tooth, rather than broader contact with the cast clasp.

- It can be used with a mesial or buccal undercut and also can be placed in 0.02" undercut due to its flexibility (allows lower placement for better esthetics)
- It can be used in tooth borne cases.

### DISCLAIMER

THIS IS COPYRIGHTED CONTENT. Unauthorized use, including screenshots, copying, misuse, reuse, or resale of any content from this app, is strictly prohibited. Our app monitors and records all screenshots and recordings. Violators will face strict legal action.

### DISCLAIMER

THIS IS COPYRIGHTED CONTENT. Unauthorized use, including screenshots, copying, misuse, reuse, or resale of any content from this app, is strictly prohibited. Our app monitors and records all screenshots and recordings. Violators will face strict legal action.

THIS IS COPYRIGHTED CONTENT. Unauthorized use, including screenshots, copying, misuse, reuse, or resale of any content from this app, is strictly prohibited. Our app monitors and records all screenshots and recordings. Violators will face strict legal action.

# RPD AND DENTURE REPAIRS

## REPAIR OF REMOVEABLE PARTIAL DENTURES

Source- Articles and Internet

- Fractures of clasp component of removeable partial denture is a commonly encountered problem in dental office. Repair or replacement procedures are often required and even preferred over refabrication of entire prosthesis whenever possible.
- Even in a meticulously planned prosthesis occasional mishaps are inevitable that can cause loss of retention, instability and discomfort to the patient.
- Maintenance of the partial denture is hence required and it includes repair, replacement or modification of components of the framework.
- Although repair procedures can be time consuming and expensive they are sometimes the most feasible solution for broken prosthesis.

The most common type of cast partial denture metal framework repair includes:

### Repair of the Clasp Components:

- The cause of breakage of clasp has to be evaluated prior to commencing the repair procedure.
- If poor design or inadequate mouth preparation is the cause it should be corrected to prevent repeated fractures. If the thickness of metal at the fracture site is less than 1.2 mm, mouth preparation should be done.
- Repair of a broken clasp can be grouped as:
  - a. Repair with wrought wire clasp:
    - It is used commonly for broken retentive arms of circumferential type of clasp.
    - It is quick and simple but may not yield the best result.
    - For this type of repair an accurate impression of the prosthesis, in its proper position in the mouth, without altering the relationship of the framework to the abutment tooth is required.
    - Infrabulge clasp can also be repaired using wrought wire which is always retained with acrylic resin.

### Procedure:

1. A soft impression (with alginate) can be used for a pickup impression and a cast is produced.

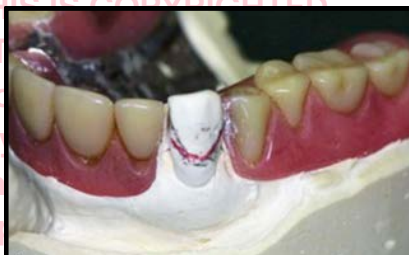

Fig: The cast produced from an irreversible hydrocolloid pick-up impression. The height of contour is shown in pencil, with a red line illustrating to the laboratory the location of repair wire (18-gauge).

### DISCLAIMER

THIS IS COPYRIGHTED CONTENT. Unauthorized use, including screenshots, copying, misuse, reuse, or resale of any content from this app, is strictly prohibited. Our app monitors and records all screenshots and recordings. Violators will face strict legal action.

DISCLAIMER

THIS IS COPYRIGHTED CONTENT. Unauthorized use, including screenshots, copying, misuse, reuse, or resale of any content from this app, is strictly prohibited. Our app monitors and records all screenshots and recordings. Violators will face strict legal action.

THIS IS COPYRIGHTED CONTENT. Unauthorized use, including screenshots, copying, misuse, reuse, or resale of any content from this app, is strictly prohibited. Our app monitors and records all screenshots and recordings. Violators will face strict legal action.

DISCLAIMER

# RPD AND DENTURE REPAIRS

2. After the impression, a groove is made in the rest—minor connector area adjacent to the repair area. The groove may originate at the remnant of broken clasp on the buccal aspect of the minor connector and should pass under the mesioproximal edge of the replacement tooth nearest to the abutment.

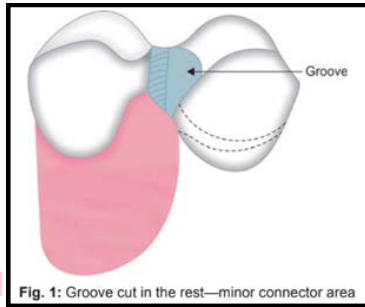


Fig. 1: Groove cut in the rest—minor connector area

3. An opening should be made in the acrylic resin of the lingual flange that should pass through the base just below the occlusal surface of the denture tooth immediately adjacent to the minor connector.

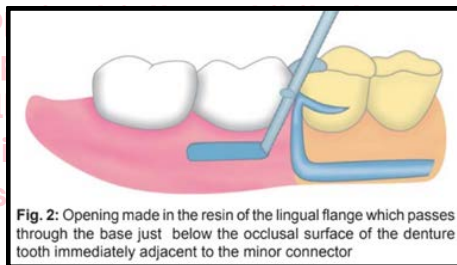


Fig. 2: Opening made in the resin of the lingual flange which passes through the base just below the occlusal surface of the denture tooth immediately adjacent to the minor connector

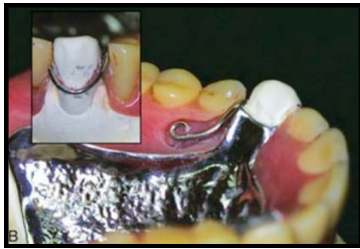


Fig: Clasp adapted to the designated line on the canine and fitted into the resin trough distal to the canine and palatal to the first and second premolars. Note the curvature placed at the end of the wire to prevent movement within the polymerized resin.

4. A box like preparation can be made in the lingual flange to house an anchorage for new clasp arm and the wire can be anchored within the resin.

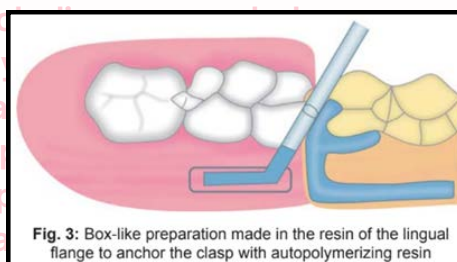


Fig. 3: Box-like preparation made in the resin of the lingual flange to anchor the clasp with autopolymerizing resin

## DISCLAIMER

THIS IS COPYRIGHTED CONTENT. Unauthorized use, including screenshots, copying, misuse, reuse, or resale of any content from this app, is strictly prohibited. Our app monitors and records all screenshots and recordings. Violators will face strict legal action.

## DISCLAIMER

THIS IS COPYRIGHTED CONTENT. Unauthorized use, including screenshots, copying, misuse, reuse, or resale of any content from this app, is strictly prohibited. Our app monitors and records all screenshots and recordings. Violators will face strict legal action.

THIS IS COPYRIGHTED CONTENT. Unauthorized use, including screenshots, copying, misuse, reuse, or resale of any content from this app, is strictly prohibited. Our app monitors and records all screenshots and recordings. Violators will face strict legal action.



# RPD AND DENTURE REPAIRS

5. 18 gauge (wrought wire) is contoured and adapted to the precise line of clasp contact. The wire is secured to the denture base by **using auto polymerizing acrylic resin** (curing done in heated pressure pot or closed container) **or Electric soldering** (to prevent overheating of the wire using a low fusing triple thick solder with soldering tip in position for 1-2 seconds).

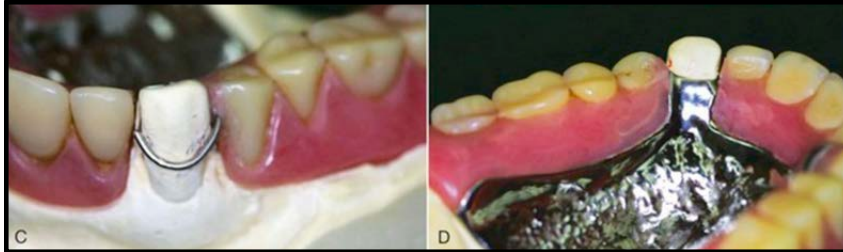


Fig: Finished and polished wire repair from the buccal. D, Palatal view.

## b. Repair with cast clasp:

- It is a more definitive method of cast repair and is useful in cases where rigidity is needed due to fracture of an occlusal rest or other type of supporting area.
- Embrasure clasp or clasp associated with single tooth replacements can be replaced more conveniently in this manner than by forming them in wrought wire.
- In this technique a pattern for the replacement clasp is fabricated either in wax or auto polymerizing resin directly on the stone cast and reproduced in cobalt chrome alloy.
- A broken circumferential clasp can be replaced with an infrabulge clasp as the replacement will be contained entirely in the resin denture base and not involve occlusal surfaces.
- Replacement with a cast clasp is superior and long lasting but require additional laboratory steps, thus, making the repair expensive and time consuming.

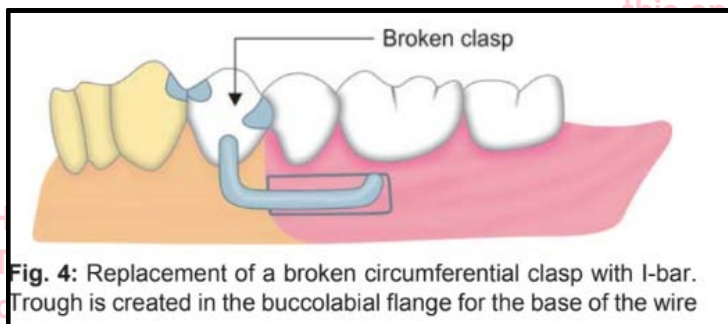


Fig. 4: Replacement of a broken circumferential clasp with I-bar. Trough is created in the buccolabial flange for the base of the wire

DISCLAIMER

THIS IS COPYRIGHTED CONTENT. Unauthorized use, including screenshots, copying, misuse, reuse, or resale of any content from this app, is strictly prohibited. Our app monitors and records all screenshots and recordings. Violators will face strict legal action.

DISCLAIMER

THIS IS COPYRIGHTED CONTENT. Unauthorized use, including screenshots, copying, misuse, reuse, or resale of any content from this app, is strictly prohibited. Our app monitors and records all screenshots and recordings. Violators will face strict legal action.

DISCLAIMER

THIS IS COPYRIGHTED CONTENT. Unauthorized use, including screenshots, copying, misuse, reuse, or resale of any content from this app, is strictly prohibited. Our app monitors and records all screenshots and recordings. Violators will face strict legal action.

# RPD AND DENTURE REPAIRS

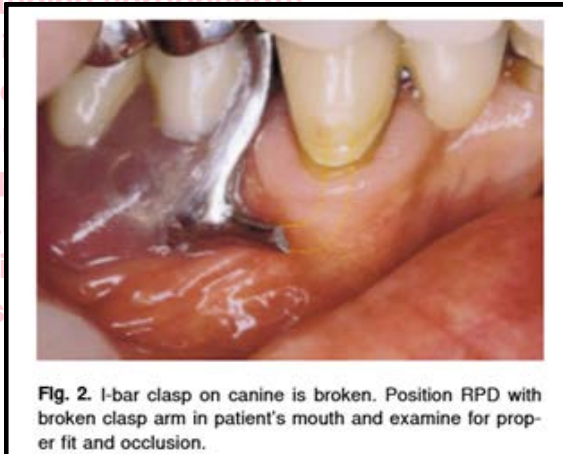
## c. Repair with surveyed cast clasp while patient retains denture.

- A simple, quick and effective method to replace a broken bar type cast clasp with a new cast clasp of the same design using a close-fitting resin matrix which enables accurate positioning of the new clasp arm and eliminates need for stabilizing arms.
- Procedures in which denture is retained by the patient during the repair process enable temporary function of the RPD and precise placement of the new clasp arm in the existing denture.

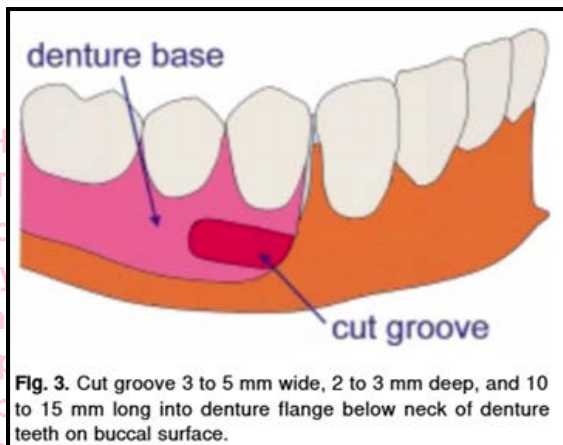
### Procedure:

#### In the first clinical visit

1. Position the RPD with the broken clasp arm in the patient's mouth and check it for proper fit and occlusion, then remove the RPD.



2. Remove the remaining portion of the broken clasp arm with a high-speed carbide bur.
3. Cut a groove 3 to 5 mm wide, 2 to 3 mm deep, and 10 to 15 mm long into the denture flange below the necks of the teeth on the buccal surface of the RPD.



### DISCLAIMER

THIS IS COPYRIGHTED CONTENT. Unauthorized use, including screenshots, copying, misuse, reuse, or resale of any content from this app, is strictly prohibited. Our app monitors and records all screenshots and recordings. Violators will face strict legal action.

### DISCLAIMER

THIS IS COPYRIGHTED CONTENT. Unauthorized use, including screenshots, copying, misuse, reuse, or resale of any content from this app, is strictly prohibited. Our app monitors and records all screenshots and recordings. Violators will face strict legal action.

THIS IS COPYRIGHTED CONTENT. Unauthorized use, including screenshots, copying, misuse, reuse, or resale of any content from this app, is strictly prohibited. Our app monitors and records all screenshots and recordings. Violators will face strict legal action.

# RPD AND DENTURE REPAIRS

4. Apply a minimal amount of impression material on the tissue (intaglio) side of the RPD around the repair area and the abutment, and seat the RPD in the mouth.
5. Make a full arch impression with the RPD in place in the mouth.
6. Remove the impression from the mouth and separate the RPD from the impression.

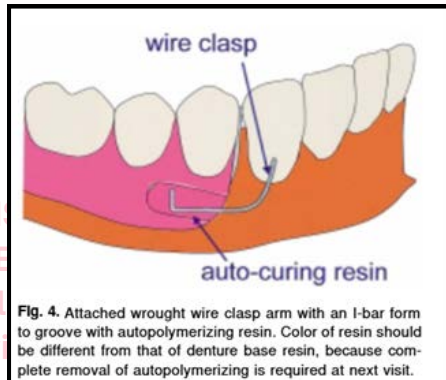


Fig. 4. Attached wrought wire clasp arm with an I-bar form to groove with autopolymerizing resin. Color of resin should be different from that of denture base resin, because complete removal of autopolymerizing is required at next visit.

7. Apply a slight amount of denture adhesive to the RPD and check for retention. If the retention and stability are acceptable, fill the groove on the RPD with tissue conditioner for comfortable use.

## In the laboratory

8. Use a conventional procedure to make a working cast with improved dental stone. Survey the full arch working cast and draw the design of the clasp on the cast.

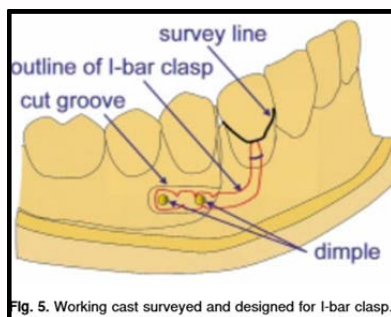


Fig. 5. Working cast surveyed and designed for I-bar clasp.

9. Position the new cast clasp arm in its proper position on the working cast. The dimples should make it easy to align properly. Fix it in position in the groove in the cast with sticky wax.

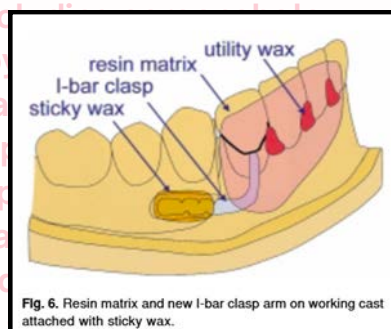


Fig. 6. Resin matrix and new I-bar clasp arm on working cast attached with sticky wax.

DISCLAIMER

THIS IS COPYRIGHTED CONTENT. Unauthorized use, including screenshots, copying, misuse, reuse, or resale of any content from this app, is strictly prohibited. Our app monitors and records all screenshots and recordings. Violators will face strict legal action.

DISCLAIMER

THIS IS COPYRIGHTED CONTENT. Unauthorized use, including screenshots, copying, misuse, reuse, or resale of any content from this app, is strictly prohibited. Our app monitors and records all screenshots and recordings. Violators will face strict legal action.

DISCLAIMER

THIS IS COPYRIGHTED CONTENT. Unauthorized use, including screenshots, copying, misuse, reuse, or resale of any content from this app, is strictly prohibited. Our app monitors and records all screenshots and recordings. Violators will face strict legal action.



# RPD AND DENTURE REPAIRS

10. Use utility wax to block out the undercut between the abutment and the first denture tooth and the undercuts below the contact points in the interproximal of the anterior teeth.
11. Paint the working cast with a resin separating medium and make a matrix with auto polymerizing resin to cover the abutment, anterior part of the I-bar clasp arm, and adjacent anterior teeth. The resin must not cover the incisal edges of the incisor teeth or the occlusal surface of the denture teeth because such extension will interfere with the intercuspation.
12. Remove the set resin matrix from the working cast keeping the clasp arm connected to the matrix.

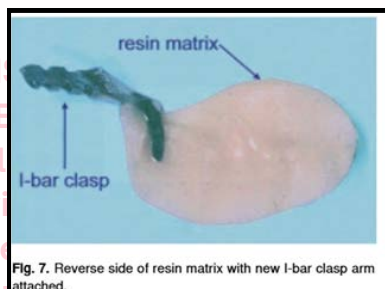


Fig. 7. Reverse side of resin matrix with new I-bar clasp arm attached.

## In the second clinical visit:

13. Remove the tissue conditioner in the groove in the RPD. If a wire clasp arm was temporarily attached to the RPD (as in Fig. 4), remove it and the auto polymerizing resin with a bur.
14. Remove a slight amount of resin from the bottom of the groove in the RPD to create a space between the denture base resin and the new clasp arm retentive segment.
15. Seat the RPD in the mouth and position the resin matrix with the new clasp arm.

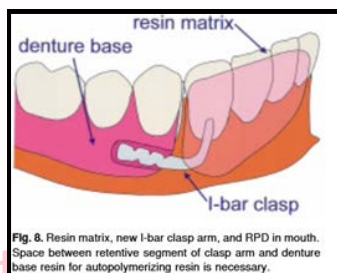


Fig. 8. Resin matrix, new I-bar clasp arm, and RPD in mouth. Space between retentive segment of clasp arm and denture base resin for autopolymerizing resin is necessary.

16. Attach the retentive segment of the new clasp arm to the denture base with auto polymerizing acrylic resin.

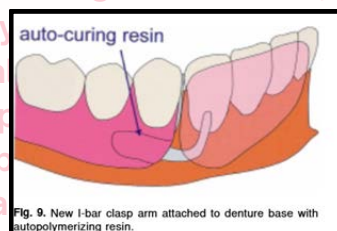


Fig. 9. New I-bar clasp arm attached to denture base with autopolymerizing resin.

DISCLAIMER

THIS IS COPYRIGHTED CONTENT. Unauthorized use, including screenshots, copying, misuse, reuse, or resale of any content from this app, is strictly prohibited. Our app monitors and records all screenshots and recordings. Violators will face strict legal action.

DISCLAIMER

THIS IS COPYRIGHTED CONTENT. Unauthorized use, including screenshots, copying, misuse, reuse, or resale of any content from this app, is strictly prohibited. Our app monitors and records all screenshots and recordings. Violators will face strict legal action.

DISCLAIMER

THIS IS COPYRIGHTED CONTENT. Unauthorized use, including screenshots, copying, misuse, reuse, or resale of any content from this app, is strictly prohibited. Our app monitors and records all screenshots and recordings. Violators will face strict legal action.

# RPD AND DENTURE REPAIRS

17. After the resin sets, remove the resin matrix horizontally
18. Examine the RPD for appropriate fit, occlusion, and retention. Make any necessary corrections.
19. Polish the RPD and then seat it in the mouth

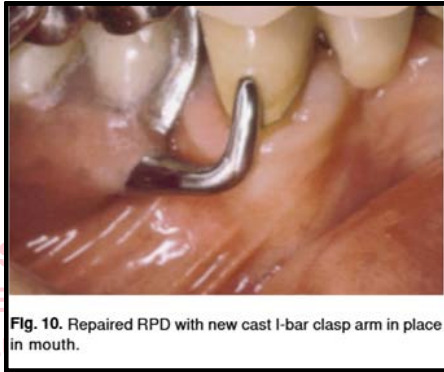

Fig. 10. Repaired RPD with new cast I-bar clasp arm in place in mouth.

## d. Repair of a fractured occlusal rest:

- A fractured occlusal rest is a result of thin metal over the marginal ridge of the abutment tooth due to inadequate tooth preparation.
- Therefore, the first step in repair is to provide required space for the rest by reducing the marginal ridge.

## e. Laser Welding:

- It is an attractive alternative method to join dental casting alloy. It is considered to be superior to soldering.
- Pulsed laser (Nd: YAG) are often used for metal repairs.
- The advantages of this method include, high reproducible strength for all metals, localized heat production, accurate fit of the framework, reduced working time, ease of operation and no need for investment and soldering alloy.
- However, laser welding is technique sensitive and has higher equipment cost and success depends on operators welding dexterity and choice of welding parameters.

# OVER DENTURES ON NATURAL TEETH AND OVER DENTURES ON IMPLANT SUPPORTED

Source- BDJ Articles on implant supported overdentures, adj article on implants for ageing population, Rosensteil (textbook), Article on implant supported overdenture by Journal of Canadian Dental association

- Over dentures are any removable dental prosthesis that covers and rests on one or more remaining natural teeth, the roots of natural teeth, and/or dental implants.
- It is a dental prosthesis that covers and is partially supported by natural teeth, natural tooth roots, and/or dental implants.
- Also called *Overlay denture, overlay prosthesis or superimposed prosthesis*.

## Implant therapy:

- Implant treatment has established benefits over traditional alternatives. Dental implant forms can be subperiosteal, transosteal, endosseous plate (blade) form implants, and the endosseous root form implant is the mainstay of modern day implantology.

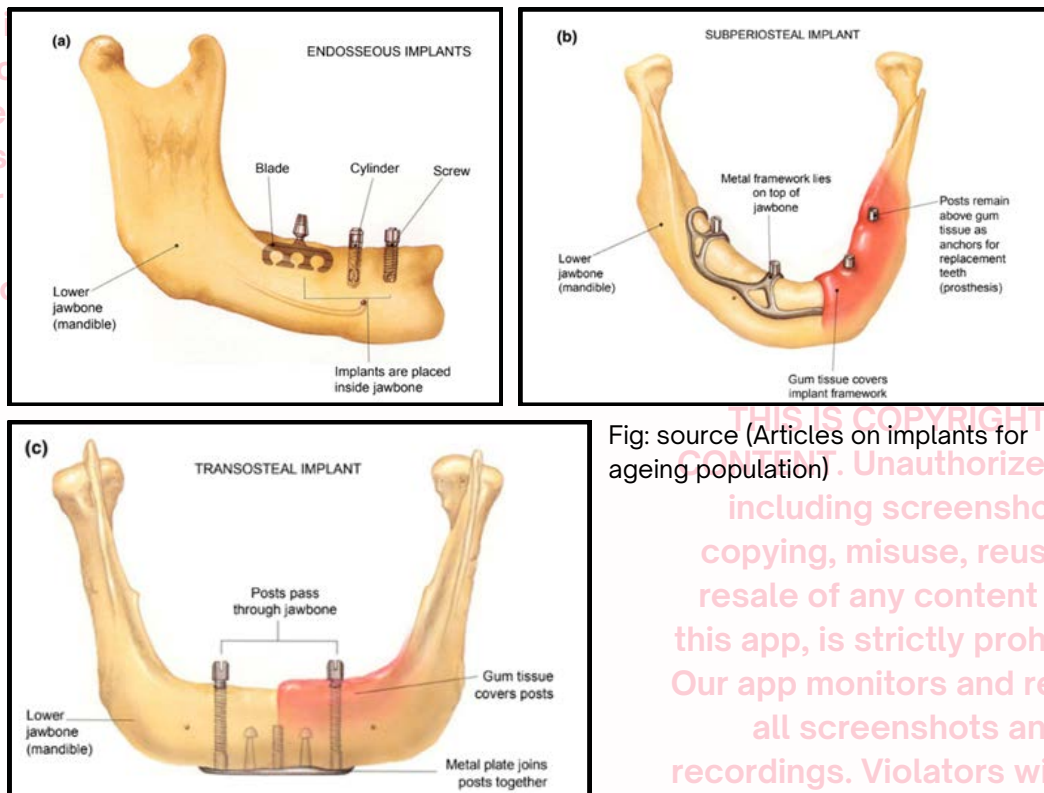


Fig: source (Articles on implants for ageing population)

- Age (advanced age) of the patient is not a contraindication for implant prosthesis however, careful planning and appropriate case selection, followed by adequate maintenance is essential for success of implant prosthesis.
- For edentulous mandible the treatment alternatives can be:

### 1) Removable prosthesis:

- a) Conventional complete denture
- b) Overdenture (implant supported and tooth supported)

### 2) Fixed prosthesis:

- a) Implant supported mandibular fixed prosthesis: Fixed mandibular denture supported exclusively by *three Implants* without mucosal support.

DISCLAIMER

THIS IS COPYRIGHTED CONTENT. Unauthorized use, including screenshots, copying, misuse, reuse, or resale of any content from this app, is strictly prohibited. Our app monitors and records all screenshots and recordings. Violators will face strict legal action.

DISCLAIMER

THIS IS COPYRIGHTED CONTENT. Unauthorized use, including screenshots, copying, misuse, reuse, or resale of any content from this app, is strictly prohibited. Our app monitors and records all screenshots and recordings. Violators will face strict legal action.

THIS IS COPYRIGHTED CONTENT. Unauthorized use, including screenshots, copying, misuse, reuse, or resale of any content from this app, is strictly prohibited. Our app monitors and records all screenshots and recordings. Violators will face strict legal action.



# OVER DENTURES ON NATURAL TEETH AND OVER DENTURES ON IMPLANT SUPPORTED

Source- BDJ Articles on implant supported overdentures, adj article on implants for ageing population, Rosensteil (textbook), Article on implant supported overdenture by Journal of Canadian Dental association

- For edentulous maxilla the treatment alternatives are:

## 1) Removable Prosthesis:

- a) Conventional complete denture
- b) Over denture (implant supported and tooth supported)

## 2) Fixed Prosthesis

- a) Implant supported maxillary Fixed prosthesis: Fixed maxillary denture supported by *four or more implants*.

- Criteria for outlining which patient group may be considered for access to implant treatments:

1. Patients with developmental conditions leading to tooth loss or malformed teeth
2. Patients with traumatic events leading to tooth loss
3. Patients who have undergone surgical interventions resulting in tooth and tissue loss; for example, head and neck cancer and non-malignant tumours
4. Patients with congenital or acquired conditions with extraoral defects of, for example, eyes or ears
5. Patients who are edentulous in either one jaw or both, in whom repeated conventional denture treatment options have been unsuccessful. In such instances, the quality of previous dentures must be assessed by a consultant in restorative dentistry
6. Patients with severe oro-mucosal disorders and those with severe xerostomia where conventional prosthetic treatment is not possible and/or the provision of conventional treatment would be detrimental to the mucosal disorders
7. Patients who do not have suitable existing teeth that can be used for anchorage to facilitate orthodontic treatment.

(Image- Source Article)

DISCLAIMER

THIS IS COPYRIGHTED CONTENT. Unauthorized use, including screenshots, copying, misuse, reuse, or resale of any content from this app, is strictly prohibited. Our app monitors and records all screenshots and recordings. Violators will face strict legal action.

DISCLAIMER

THIS IS COPYRIGHTED CONTENT. Unauthorized use, including screenshots, copying, misuse, reuse, or resale of any content from this app, is strictly prohibited. Our app monitors and records all screenshots and recordings. Violators will face strict legal action.

DISCLAIMER

THIS IS COPYRIGHTED CONTENT. Unauthorized use, including screenshots, copying, misuse, reuse, or resale of any content from this app, is strictly prohibited. Our app monitors and records all screenshots and recordings. Violators will face strict legal action.

# OVER DENTURES ON NATURAL TEETH AND OVER DENTURES ON IMPLANT SUPPORTED

Source- BDJ Articles on implant supported overdentures, adj article on implants for ageing population, Rosensteil (textbook), Article on implant supported overdenture by Journal of Canadian Dental association

## Implant- supported over denture (removable prosthesis):

- Complete denture is the most commonly used treatment for edentulism since many years. However, the conventional dentures or overdentures have their own shortcomings which include difficulty in chewing a variety of food, lack of proper retention and stability and psychological impact especially with atrophic mandible.
- The removeable prosthesis can be implant retained or implant supported. Although often used interchangeably they have distinct differences.
  - a) **Implant retained overdenture:** It is retained by the attachment system but supported by underlying soft tissues. It requires accurate impression taking to ensure accurate recording of the supporting soft tissue in an undisputed/passive state. If not recorded accurately it results in rapid implant component wear.
  - b) **Implant supported overdenture:** It is supported in its entirety by the implants without loading of the underlying soft tissues.
- Implant retained over dentures are widely applied for rehabilitation of edentulous jaws because it increases retention, stability, enhance masticatory function and reduce alveolar bone resorption by regulating neuromuscular adaptation.
- While considered an excellent treatment option, implant supported overdenture may not be appropriate in all cases. As such implant planning is complex and must consider multiple variables including the number of fixtures, whether or not to splint implants and the utilization implants to support or retain a denture. Thus, a thorough patient assessment and planning is required.

## Advantages of implant supported/retained overdenture over conventional complete denture includes:

- a) Minimum anterior bone loss
- b) Improved stability by reducing or eliminating prosthetic movement
- c) Improved occlusion
- d) Increased occlusal efficiency and improved chewing efficiency
- e) Improved retention and speech while improving comfort and taste by allowing reduction in palatal coverage.
- f) It facilitates greater access for oral hygiene when compared to fixed implant bridges.
- g) Improved patients psychological outlook

DISCLAIMER

THIS IS COPYRIGHTED CONTENT. Unauthorized use, including screenshots, copying, misuse, reuse, or resale of any content from this app, is strictly prohibited. Our app monitors and records all screenshots and recordings. Violators will face strict legal action.

DISCLAIMER

THIS IS COPYRIGHTED CONTENT. Unauthorized use, including screenshots, copying, misuse, reuse, or resale of any content from this app, is strictly prohibited. Our app monitors and records all screenshots and recordings. Violators will face strict legal action.

DISCLAIMER

THIS IS COPYRIGHTED CONTENT. Unauthorized use, including screenshots, copying, misuse, reuse, or resale of any content from this app, is strictly prohibited. Our app monitors and records all screenshots and recordings. Violators will face strict legal action.

# OVER DENTURES ON NATURAL TEETH AND OVER DENTURES ON IMPLANT SUPPORTED

Source- BDJ Articles on implant supported overdentures, adj article on implants for ageing population, Rosensteil (textbook), Article on implant supported overdenture by Journal of Canadian Dental association

## Challenges of implants and implant supported/retained overdenture:

- The need for implant surgery which may involve multiple surgical procedures especially in cases where bone grafting is required.
- Implant treatment is more challenging in maxilla when compared to mandible. This is due to poor bone quality (Type 3 and Type 4) bone in maxillary posterior region.
- Thus, removable prosthesis in maxilla should be supported by more implants than a similar prosthesis in mandible.
- Patient must be aware of the possibilities of treatment complications and failure including periimplantitis.
- The implant supported maxillary denture is reported to be associated with highest implant failure rate.
- The implant retained prosthesis require more frequent maintenance appointments when compared to a conventional denture.

## Types of implant attachment systems:

- There are many attachment systems and each system consists of two parts:
  - The abutment: Part that attaches to the implant directly.**
  - The housing and retentive insert: Part that attaches to the prosthesis.**
- The implants can be splinted with a bar or can be free-standing.
- Attachments can also be described as rigid or resilient. Resilient attachments allow pre calculated amount of movement that serves to distribute potential harmful forces. Resilient attachments include clips, ball attachments and locator.

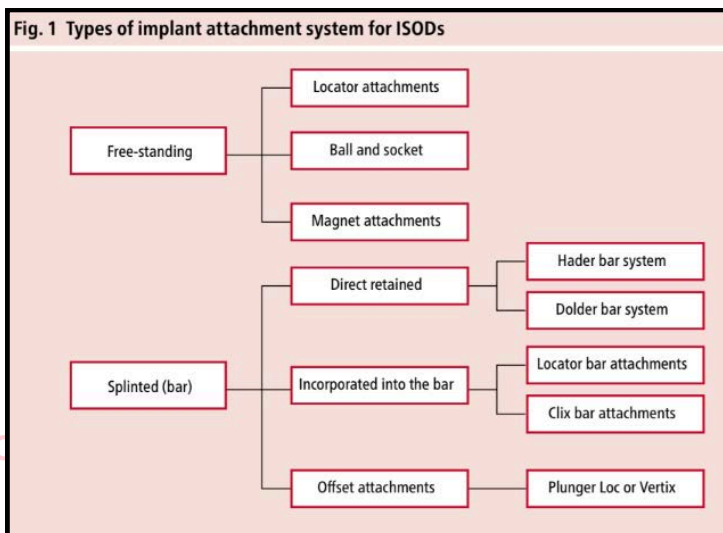


Fig: Attachment systems for implant prosthesis



# OVER DENTURES ON NATURAL TEETH AND OVER DENTURES ON IMPLANT SUPPORTED

Source- BDJ Articles on implant supported overdentures, adj article on implants for ageing population, Rosensteil (textbook), Article on implant supported overdenture by Journal of Canadian Dental association

## A) Splinted attachments:

- Bars are method of splinting many implants and connect multiple implants and distribute forces across a large area. Particularly useful in zygomatic attachments.

Bars come in various shapes and can be designed with a multitude of attachment systems:

1. Direct retainers, such as the Hader or Dolder systems
2. Bars with secondary attachments (such as Locator attachments) (see Figure 2)
3. Offset attachments, such as the Plunger Loc or Vertex.

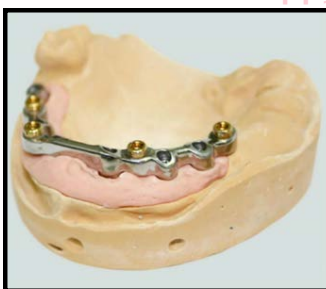
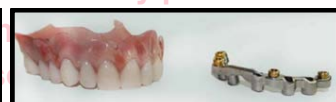
Fig: Splinted (bar attachment) Locators incorporated into a custom bar



## B) Free Standing attachments:

- Dentures utilizing free standing attachments are implant retained and partly tissue supported that can be incorporated into new prosthesis or cold cured into existing prosthesis.
- These have no primary splinting, so, cleansability is improved specially in patients with reduced manual dexterity.
- The Locator attachments are most widely and commonly used attachment system in implant supported over dentures. It is compatible with many implant systems. It consists of a denture housing, a locator abutment and a retentive insert.

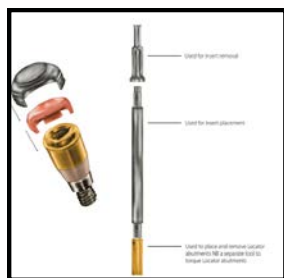

Fig: Parts of locator attachments

- The housing is inserted in the denture either during denture construction or utilizing a chairside relining technique. The retentive inserts fit within the denture housing and are easily interchangeable based on amount of retention required. The retentive component wears and requires regular replacement (when the denture begins to lose retention).

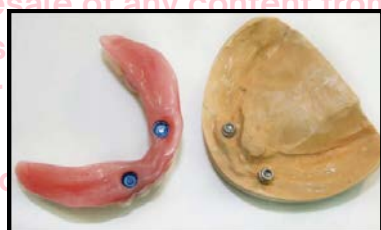

Fig: Implant-supported overdenture with two locators

DISCLAIMER

THIS IS COPYRIGHTED CONTENT. Unauthorized use, including screenshots, copying, misuse, reuse, or resale of any content from this app, is strictly prohibited. Our app monitors and records all screenshots and recordings. Violators will face strict legal action.

DISCLAIMER

THIS IS COPYRIGHTED CONTENT. Unauthorized use, including screenshots, copying, misuse, reuse, or resale of any content from this app, is strictly prohibited. Our app monitors and records all screenshots and recordings. Violators will face strict legal action.

DISCLAIMER

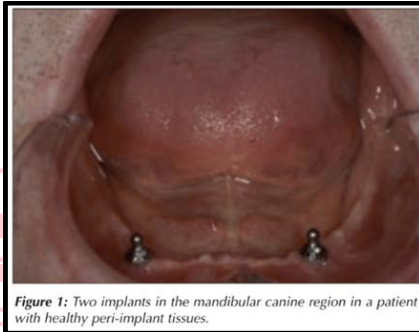THIS IS COPYRIGHTED CONTENT. Unauthorized use, including screenshots, copying, misuse, reuse, or resale of any content from this app, is strictly prohibited. Our app monitors and records all screenshots and recordings. Violators will face strict legal action.

# OVER DENTURES ON NATURAL TEETH AND OVER DENTURES ON IMPLANT SUPPORTED

Source- BDJ Articles on implant supported overdentures, adj article on implants for ageing population, Rosensteil (textbook), Article on implant supported overdenture by Journal of Canadian Dental association

## A) Mandibular implant supported overdenture:

- The implant supported overdenture is useful especially in atrophic mandible has high success rate and **the recent consensus recommends the use of two-implant-supported overdenture as a first choice of restoration for edentulous mandible.**



- Two implants placed bilaterally in the interforaminal region of mandible is the most accepted protocol for mandibular implant overdenture. However, 1,3 and 4 implants have also been proposed.
- Patients have greater prosthesis satisfaction and masticatory capacity with mandibular implant overdenture when compared to conventional full lower dentures.
- In dissatisfied denture wearers also conversion of existing mandibular dentures to implant supported over dentures provided significant improvement in oral health.
- Problems can arise with the nature of locator attachments used (that can lead to problems with insertion and hygiene). Hence, important considerations should be taken while planning.
- While there is established differences in the retentive strength of various designs such as ball, bar and clip and locator attachments, no conclusive evidence provides overall superiority of one particular system over another. No particular attachment is associated with greater implant survival or patient satisfaction.
- However, individual Locator attachment system have been associated with reduced prevalence of Candida albicans and denture related stomatitis, when compared to bar attachments for mandibular implant overdentures. This is important in patient who have difficulty in maintaining sound oral hygiene.

DISCLAIMER

THIS IS COPYRIGHTED CONTENT. Unauthorized use, including screenshots, copying, misuse, reuse, or resale of any content from this app, is strictly prohibited. Our app monitors and records all screenshots and recordings. Violators will face strict legal action.

DISCLAIMER

THIS IS COPYRIGHTED CONTENT. Unauthorized use, including screenshots, copying, misuse, reuse, or resale of any content from this app, is strictly prohibited. Our app monitors and records all screenshots and recordings. Violators will face strict legal action.

DISCLAIMER

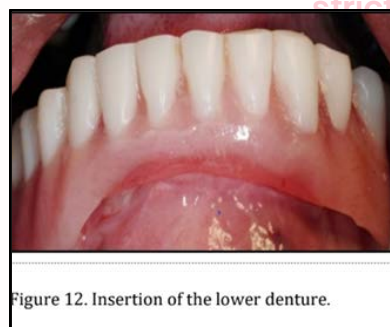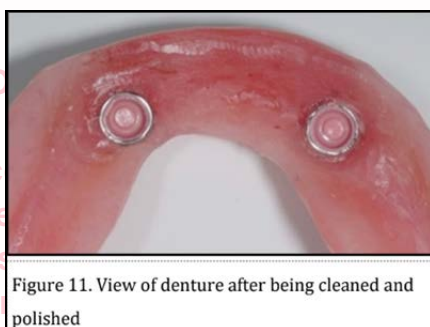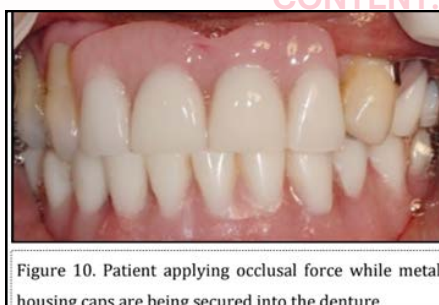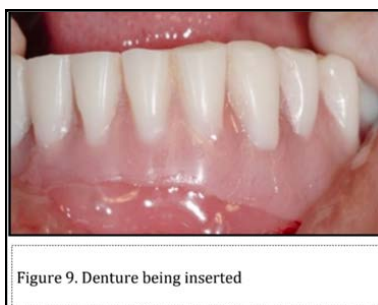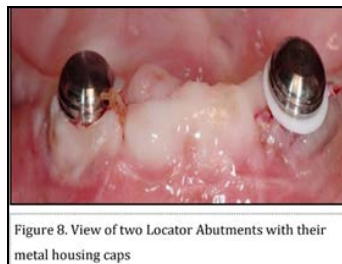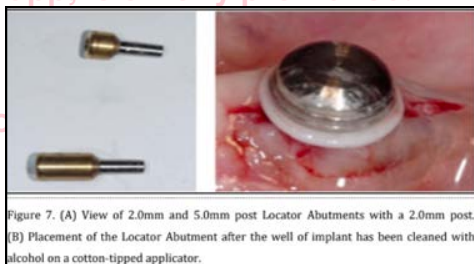
THIS IS COPYRIGHTED CONTENT. Unauthorized use, including screenshots, copying, misuse, reuse, or resale of any content from this app, is strictly prohibited. Our app monitors and records all screenshots and recordings. Violators will face strict legal action.

# OVER DENTURES ON NATURAL TEETH AND OVER DENTURES ON IMPLANT SUPPORTED

Source- BDJ Articles on implant supported overdentures, adj article on implants for ageing population, Rosensteil (textbook), Article on implant supported overdenture by Journal of Canadian Dental association

## Clinical significance for implant supported mandibular overdenture:

- Overdenture with pivoting locator attachment allow resilient connection of overdenture without any retention loss.
- **The interarch space** required for retention of the prosthesis to the implant (distance from the shoulder of the implant to the incisal edge) is about **12- 14 mm**. A thickness of 2- 3 mm of soft tissue above the implant, an area of 2mm from the lining of the edentulous ridge to the bar (for suitable cleaning), 4.5 mm bar thickness ,2mm for acrylic resin and 3mm for the teeth.
- Placement of two independent implants at the same height, equidistant from the midline and parallel to each other with proper angulations prevent wearing away or disengagement of the attachments.
- Success criteria for implants include: lack of vertical bone loss less than 1mm during first year and less than 0.2 mm annually thereafter.
- Overall, immediate loading of two implants supporting a locator retained mandibular overdenture is a suitable treatment option.



DISCLAIMER

THIS IS COPYRIGHTED CONTENT. Unauthorized use, including screenshots, copying, misuse, reuse, or resale of any content from this app, is strictly prohibited. Our app monitors and records all screenshots and recordings. Violators will face strict legal action.

DISCLAIMER

THIS IS COPYRIGHTED CONTENT. Unauthorized use, including screenshots, copying, misuse, reuse, or resale of any content from this app, is strictly prohibited. Our app monitors and records all screenshots and recordings. Violators will face strict legal action.

DISCLAIMER

THIS IS COPYRIGHTED CONTENT. Unauthorized use, including screenshots, copying, misuse, reuse, or resale of any content from this app, is strictly prohibited. Our app monitors and records all screenshots and recordings. Violators will face strict legal action.



# OVER DENTURES ON NATURAL TEETH AND OVER DENTURES ON IMPLANT SUPPORTED

Source- BDJ Articles on implant supported overdentures, adj article on implants for ageing population, Rosensteil (textbook), Article on implant supported overdenture by Journal of Canadian Dental association

## B) Maxillary implant supported overdenture:

- Restoration of edentulous maxilla using implants is complex and challenging and requires meticulous planning.
- Maxillary overdentures implant has the lowest survival rates of all implant prosthesis types. High prosthetic maintenance is also required for maxillary implant overdentures when compared with mandibular implant overdentures.
- Most frequently proclaimed benefits of maxillary overdentures are added retention and reduced palatal coverage that increased comfort and ease to the patient.
- The maintenance requirements for maxillary implant overdenture are a direct consequence of attachment systems. And although the type of attachment systems used will be based on clinicians' preference, unsplinted implant attachment systems offer greater ease for hygiene maintenance and repair than splinted attachment systems.
- Patients have shown higher satisfaction rate with enhanced ability to speak clearly and ease of cleaning with the use of removeable maxillary over denture (with a long bar design and without palatal coverage) compared to fixed prosthesis or conventional prosthesis.

## Complications of implant retained over dentures:

- The most common complication is deactivation or replacement of insert, loosening of abutment screw, relining the implant supported overdenture, fracture of denture teeth and peri implant mucositis or tissue hyperplasia.
- Less frequent complication includes fracture of abutment screw, remake and fracture of implant supported over denture.

## Tooth supported overdentures:

- Lack of denture stability and gradual loss of supporting bone is a common difficulty encountered with complete dentures.
- Problems with stability mostly arises in cases where mandibular incisors are only teeth retained with damage to the opposing pre maxilla (combination syndrome)
- For such cases in selected patients as an alternative to fixed prosthesis or implant supported prosthesis, providing an overdenture that rests on endodontically treated roots may help preserve residual alveolar ridge and enhance the stability of complete denture.

DISCLAIMER

THIS IS COPYRIGHTED CONTENT. Unauthorized use, including screenshots, copying, misuse, reuse, or resale of any content from this app, is strictly prohibited. Our app monitors and records all screenshots and recordings. Violators will face strict legal action.

DISCLAIMER

THIS IS COPYRIGHTED CONTENT. Unauthorized use, including screenshots, copying, misuse, reuse, or resale of any content from this app, is strictly prohibited. Our app monitors and records all screenshots and recordings. Violators will face strict legal action.

DISCLAIMER

THIS IS COPYRIGHTED CONTENT. Unauthorized use, including screenshots, copying, misuse, reuse, or resale of any content from this app, is strictly prohibited. Our app monitors and records all screenshots and recordings. Violators will face strict legal action.

## PERI IMPLANT DISEASES AND IMPLANT MAINTENANCE

- The provision for implant retained prosthesis is increasing with modern dentistry, the Osseo integrated dental implants have high survival rates however, integrated implants are susceptible to diseases that lead to loss of implant.
- Although placement and restoration are generally in the field of specialist, with the increasing number of Osseo integrated fixtures the maintenance of these implant is becoming or will become more common by the general dentist.
- Implant failure can be due to number of causes including prosthesis instability, implant mobility, occlusal trauma, fractured components, pain, inflammation, infection and neuropathy.
- Failures can be early (immediately after implant placement where osseointegration was never really achieved) and Late (after successful osseointegration sometime after placement and subsequent restoration).
- The major cause of late failure is due to Peri implant diseases (peri-implantitis).

**Peri implant Diseases:** (Source- Tg, Articles on dental implants)

- Peri implant diseases are caused by the accumulation of plaque around the Osseo integrated dental implant. It can be classified as:
  - a) **Peri implant mucositis:** It is defined as reversible inflammatory reaction in the soft tissues surrounding an implant without bone loss.
  - b) **Peri-implantitis:** It is an inflammatory reaction with loss of supporting bone surrounding an implant. (Can lead to loss of the implant)
- Peri-implant tissues is colonized by the same flora as the periodontium and the diseases of this tissue (peri-implant disease) is very similar to gingivitis and periodontitis

The microbiota associated with healthy peri-implant tissues closely resembles that of the flora associated with gingival health. The organisms associated with mucositis are very similar to that of gingivitis and, unsurprisingly, that of peri-implantitis is very similar to that seen in periodontitis.

Image- Source- ADJ ARTICLE

- Peri implant disease is most likely:
  - a) if the dental implant is not professionally maintained
  - b) If the patient smokes
  - c) If patient has history of periodontitis
  - d) Patient has poor oral hygiene or is unable to clean their implant.
  - e) Peri implantitis is also associated with excess cement or poor fit of dental implant components.

### DISCLAIMER

THIS IS COPYRIGHTED CONTENT. Unauthorized use, including screenshots, copying, misuse, reuse, or resale of any content from this app, is strictly prohibited. Our app monitors and records all screenshots and recordings. Violators will face strict legal action.

### DISCLAIMER

THIS IS COPYRIGHTED CONTENT. Unauthorized use, including screenshots, copying, misuse, reuse, or resale of any content from this app, is strictly prohibited. Our app monitors and records all screenshots and recordings. Violators will face strict legal action.

### DISCLAIMER

THIS IS COPYRIGHTED CONTENT. Unauthorized use, including screenshots, copying, misuse, reuse, or resale of any content from this app, is strictly prohibited. Our app monitors and records all screenshots and recordings. Violators will face strict legal action.

# PERI IMPLANT DISEASES AND IMPLANT MAINTENANCE

## a) Peri implant mucositis:

- It is a reversible inflammatory change of peri implant soft tissue without bone loss. It is similar to gingivitis in normal periodontium.
- The accumulation of plaque around implant can lead to peri implant mucositis.
- Slight swelling with loss of marginal stippling with bleeding on probing and no radiographic bone defect can be seen.

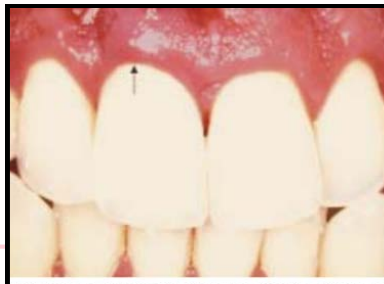

Fig 2A. Slight oedematous swelling and loss of stippling of marginal peri-implant mucosa of an implant replacing 11.

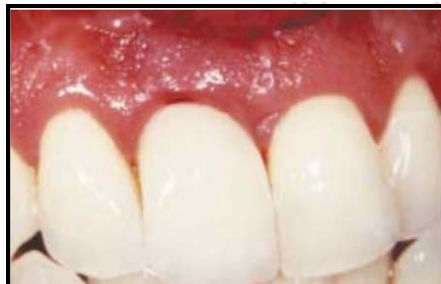

Fig 2C. Bleeding after gentle probing.

Image- Case with signs of peri implant mucositis without radiographic bone defect (Source article)

## b) Peri implantitis:

- Peri implantitis is evidenced by inflammatory change around Osseo integrated implants in function, affecting the mucosa resulting in the loss of supporting bone around the implant.
- It is indicated by 6mm or more probing depth in conjunction with profuse bleeding and suppuration.
- Diagnosis of peri implantitis can also be made when there is evidence of radiographic bone loss around the implant.

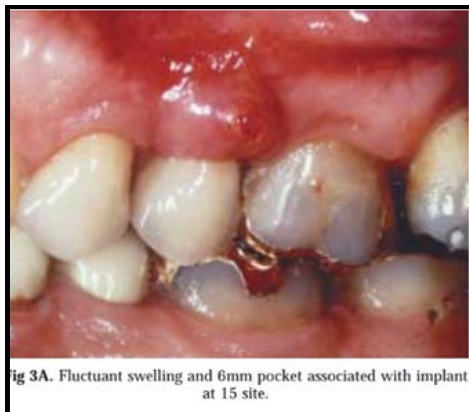

Fig 3A. Fluctuant swelling and 6mm pocket associated with implant at 15 site.

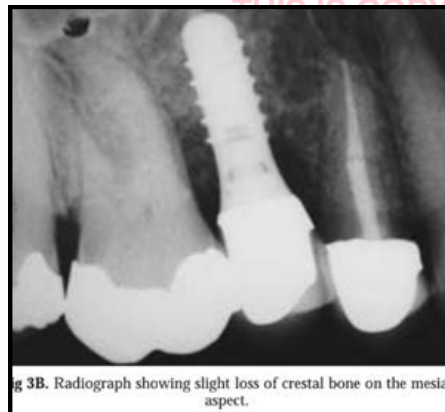


Fig 3B. Radiograph showing slight loss of crestal bone on the mesial aspect.

Image- Case of acute abscess associated with peri-implantitis. (Article)



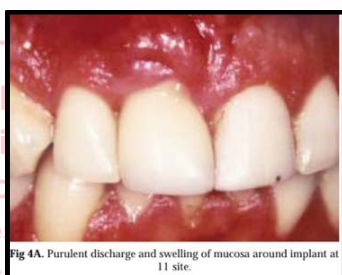## PERI IMPLANT DISEASES AND IMPLANT MAINTENANCE

### Diagnosis of peri-implant diseases:

- Early disease detection, through frequent follow up and regular assessment will help the clinician to modify oral hygiene practices of the patient and if the disease is detected it can be managed at the initial stage.
- The diagnosis of periimplantitis requires careful differentiation from peri-implant mucositis
- The parameters for diagnosis of peri-implantitis include:

#### i) Clinical indices:

Swelling and redness around a peri-implant mucosa is reported along with other signs in cases of peri-implantitis. The amount of plaque around implant should always be evaluated.



#### ii) Peri-implant probing:

- Probing around the oral implants is considered a reliable and sensitive parameter for the long-term monitoring of the peri-implant mucosal tissues.
- Periodontal probing does not affect the integrity of an implant so can be done routinely, but a metal probe may damage implant surface.
- A rigid plastic probe is ideal.
- Peri implant tissues has parallel attachment of the junctional epithelium around the implant surface that is different from healthy periodontium which has connective tissue fibers attached perpendicularly to the root surface. So, there is less resistance when probing around the implant.
- This type of attachment can lead to deeper peri-implant probing depth when compared to probing around natural tooth.
- A light probing force (0.25 N) should be used to avoid tissue trauma while probing peri implant tissues.
- On probing the peri-implant sulcus with a blunt probe an excellent sealing effect is seen with healthy tissue and peri implant mucositis, whereas, relatively uninhibited penetration to the alveolar crest in peri-implantitis.
- Under healthy conditions probing depths of implants placed in sites excluding esthetic zone is around 2- 4mm. In aesthetic zone where implant is usually placed deep the probing depth are more profound than usual.
- Hence, an initial baseline value using a fixed landmark like implant abutment junction should be used and this should be recorded for any change at a later date.
- Whenever peri-implant probing depth is more than 5mm other clinical parameters should also be considered and be present along with it (like bone loss around the implant fixture, gingival phenotype, depth of margin placement and prosthetic contour) for a diagnosis of peri implantitis.

#### DISCLAIMER

THIS IS COPYRIGHTED CONTENT. Unauthorized use, including screenshots, copying, misuse, reuse, or resale of any content from this app, is strictly prohibited. Our app monitors and records all screenshots and recordings. Violators will face strict legal action.

#### DISCLAIMER

THIS IS COPYRIGHTED CONTENT. Unauthorized use, including screenshots, copying, misuse, reuse, or resale of any content from this app, is strictly prohibited. Our app monitors and records all screenshots and recordings. Violators will face strict legal action.

#### DISCLAIMER

THIS IS COPYRIGHTED CONTENT. Unauthorized use, including screenshots, copying, misuse, reuse, or resale of any content from this app, is strictly prohibited. Our app monitors and records all screenshots and recordings. Violators will face strict legal action.

## PERI IMPLANT DISEASES AND IMPLANT MAINTENANCE

### iii) Bleeding on probing:

- It indicates inflammation in the pocket or sulcus.
- It is not a reliable indicator for progression of periodontal disease instead its absence is a much better predictor for stability. (Similar concept applies for peri-implant tissues)

### iv) Suppuration:

- High numbers of neutrophils are linked with inflammation of peri implant tissues, suggesting that suppuration may be a sign of peri-implantitis.

### v) Peri-implant radiography:

- A baseline radiograph must be established to record the bone levels at the time of prosthesis placement.
- The radiograph should be taken with a standardized film holder and should clearly show the implant reference point with distinct visualization of implant thread. (the distance from the implant shoulder to the alveolar crest is a reliable parameter).
- Long cone radiographs taken annually for the first 3 years is recommended after which further radiographic evaluation will be based on clinical assessment.
- Most implant show small amount of marginal bone loss within the first year of function.

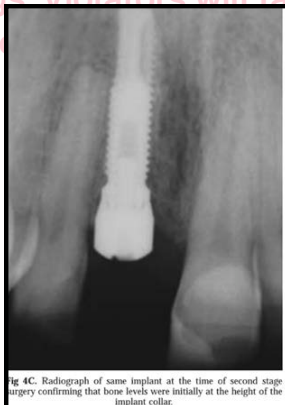


Fig 1:

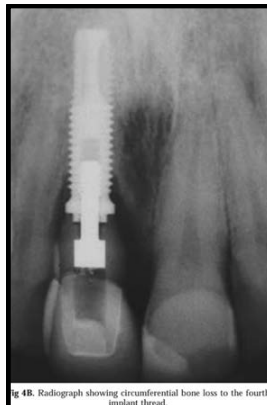


Fig 2:

Image- Fig 1) Base line radiograph with no bone loss. Fig 2) Circumferential radiographic Bone loss associated with peri-implantitis

### Main diagnostic difference between periimplantitis and peri implant mucositis

Table 1. Main diagnostic differences between peri-implant mucositis and peri-implantitis

Clinical parameter	Peri-implant mucositis	Peri-implantitis
Increased probing depth	+/-	+
BOP	+	+
Suppuration	+/-	+
Mobility	-	+/-
Radiographic bone loss	-	+

Image- Source (Article)

#### DISCLAIMER

THIS IS COPYRIGHTED CONTENT. Unauthorized use, including screenshots, copying, misuse, reuse, or resale of any content from this app, is strictly prohibited. Our app monitors and records all screenshots and recordings. Violators will face strict legal action.

#### DISCLAIMER

THIS IS COPYRIGHTED CONTENT. Unauthorized use, including screenshots, copying, misuse, reuse, or resale of any content from this app, is strictly prohibited. Our app monitors and records all screenshots and recordings. Violators will face strict legal action.

#### DISCLAIMER

THIS IS COPYRIGHTED CONTENT. Unauthorized use, including screenshots, copying, misuse, reuse, or resale of any content from this app, is strictly prohibited. Our app monitors and records all screenshots and recordings. Violators will face strict legal action.

# PERI IMPLANT DISEASES AND IMPLANT MAINTENANCE

## Management of Peri-Implant Diseases:

### a) Management of Peri implant mucositis:

- Assessment for the presence/absence of plaque and bleeding on probing and pocket depth should be done, if probing depth is within the normal limits and plaque and bleeding on probing is positive the patients oral hygiene measures should be checked and proper plaque control measures should be introduced or reinforced.
- The implant should be cleaned by instruments softer than titanium such as polishing with rubber cup and paste, interdental floss, interdental brushes or using plastic scaling instruments.

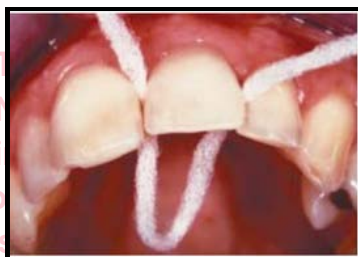

Fig 1A. A length of floss has been threaded through the mesial contact point between the implant crown and the adjacent natural tooth, and looped back through the distal contact point (Ultradent; Oral-B Laboratories, Sydney, Australia).

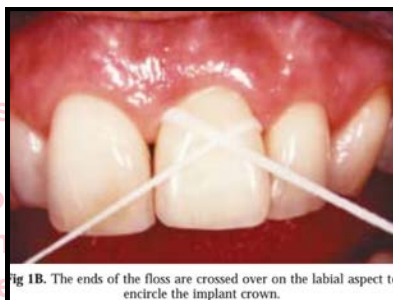

Fig 1B. The ends of the floss are crossed over on the labial aspect to encircle the implant crown.

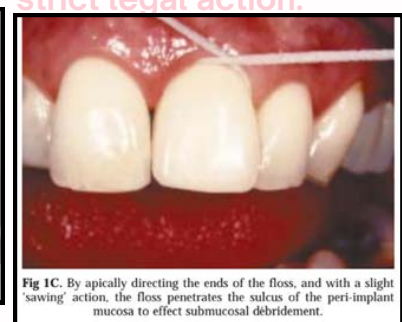


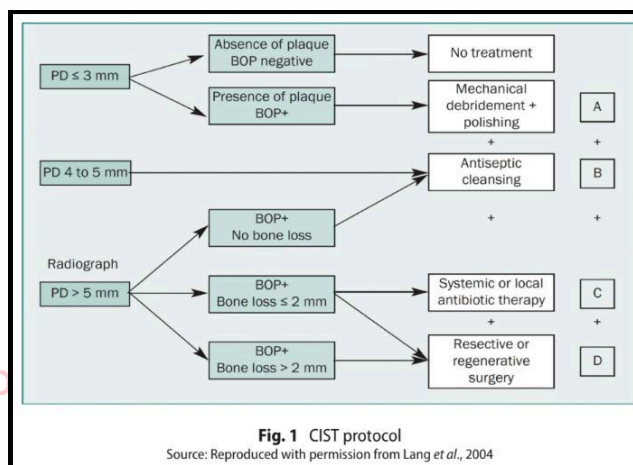
Fig 1C. By apically directing the ends of the floss, and with a slight 'sawing' action, the floss penetrates the sulcus of the peri-implant mucosa to effect submucosal debridement.

Image- Source (Article)

- Regular dental review should be encouraged, including maintenance of implants.
- Antibiotic therapy is not required.

### b) Management of Peri Implantitis:

- **Cumulative Interceptive Supportive Therapy (CSIT) protocol** will help treat majority of peri implantitis cases



- If there is progressive bone loss (that can be caused due to occlusal overload or bacteria induced inflammation), then cause must be ascertained.
- Bacteria induced inflammation can be initially treated with non- surgical therapy, but it depends on the initial clinical presentation.
- The presence of pus or pockets greater than 5mm indicates additional measures may be required which includes application of antiseptics like 2% CHX, 3% hydrogen peroxide.

**DISCLAIMER**

THIS IS COPYRIGHTED CONTENT. Unauthorized use, including screenshots, copying, misuse, reuse, or resale of any content from this app, is strictly prohibited. Our app monitors and records all screenshots and recordings. Violators will face strict legal action.

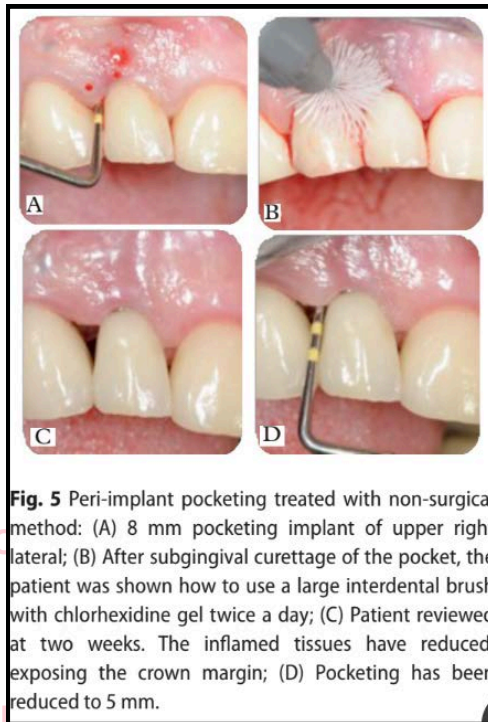
**DISCLAIMER**

THIS IS COPYRIGHTED CONTENT. Unauthorized use, including screenshots, copying, misuse, reuse, or resale of any content from this app, is strictly prohibited. Our app monitors and records all screenshots and recordings. Violators will face strict legal action.

THIS IS COPYRIGHTED CONTENT. Unauthorized use, including screenshots, copying, misuse, reuse, or resale of any content from this app, is strictly prohibited. Our app monitors and records all screenshots and recordings. Violators will face strict legal action.



## PERI IMPLANT DISEASES AND IMPLANT MAINTENANCE



- In conjunction with other intervention antibiotic therapy is also considered, using:
  - Amoxicillin 500 mg orally, TDS (8 -hourly) for 7 days
  - PLUS
  - Metronidazole 400 mg orally, BD (12-hourly) for 7 days
- \*If patient has hypersensitivity with penicillin, use metronidazole as a single drug

### Surgical Therapy in Peri-implantitis cases:

- The aim of surgical therapy is to increase the cleaning ability of the implant surface and correct the condition of soft and hard peri-implant tissues.
- If there is probing depth of 5mm or more and bone loss greater than 2 mm surgical intervention is needed
- Re osseointegration is the expected outcome of the treatment.
- The surgical therapy includes resective, regenerative or their combination depending on the anatomy of the bone defect surrounding the implant.
- If the site has one walled defect or supra bony defect, resection with osseous surgery and apically repositioned flaps should be performed.

THIS IS COPYRIGHTED CONTENT. Unauthorized use, including screenshots, copying, misuse, reuse, or resale of any content from this app, is strictly prohibited. Our app monitors and records all screenshots and recordings. Violators will face strict legal action.

DISCLAIMER

THIS IS COPYRIGHTED CONTENT. Unauthorized use, including screenshots, copying, misuse, reuse, or resale of any content from this app, is strictly prohibited. Our app monitors and records all screenshots and recordings. Violators will face strict legal action.

DISCLAIMER

THIS IS COPYRIGHTED CONTENT. Unauthorized use, including screenshots, copying, misuse, reuse, or resale of any content from this app, is strictly prohibited. Our app monitors and records all screenshots and recordings. Violators will face strict legal action.

DISCLAIMER

THIS IS COPYRIGHTED CONTENT. Unauthorized use, including screenshots, copying, misuse, reuse, or resale of any content from this app, is strictly prohibited. Our app monitors and records all screenshots and recordings. Violators will face strict legal action.

# PERI IMPLANT DISEASES AND IMPLANT MAINTENANCE

## Aims of resective surgery are:

The main aims of resective surgery are as follows:

1. To eliminate the inflammatory tissues
2. To stop the disease from progressing further

3. To maintain the implant in function with healthy peri-implant tissues
4. To reduce the peri-implant pocket depths
5. To gain a soft tissue morphology that allows cleanability for the patient and leads to healthy peri-implant tissues

- In addition to resective and regenerative surgery adjunctive treatment such as surface decontamination is always included in cases of peri-implantitis due to difficulty in mechanical debridement of implant surface
- Open flap debridement by raising buccal and palatal flaps can be done to treat the infection in case of peri-implantitis, where after raising the flaps the implant surface can be carefully debrided to remove granulation tissue and disinfected with alternating application of 2% CHX and 3% H<sub>2</sub>O<sub>2</sub> flushed away with copious saline.

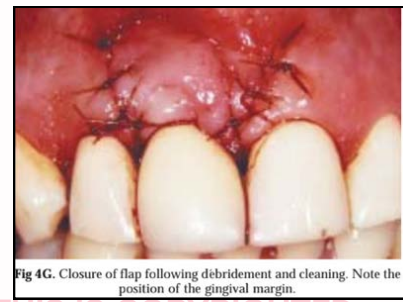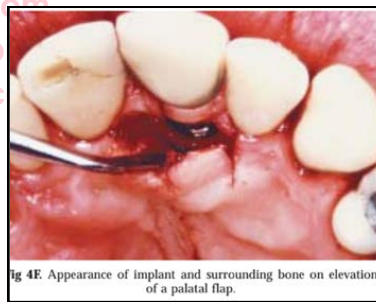
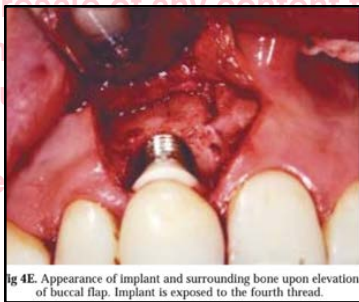
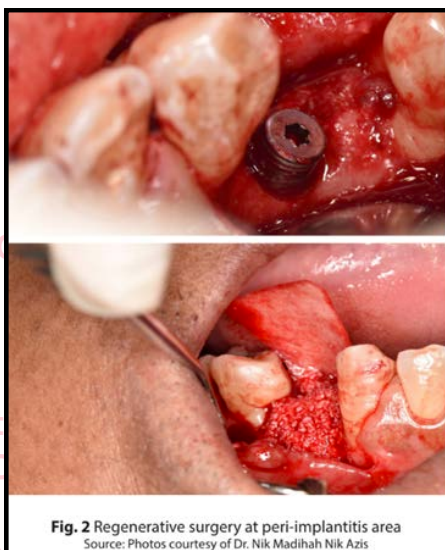


Image: Open flap Debridement for a case of peri-implantitis

- For circumferential bony defects with intact bony walls, regenerative surgery with natural bone and collagen membrane has shown success.
- Case selection is essential for success of treatment, a three-dimensional radiograph (CBCT) is required before regenerative surgery.



## DISCLAIMER

THIS IS COPYRIGHTED CONTENT. Unauthorized use, including screenshots, copying, misuse, reuse, or resale of any content from this app, is strictly prohibited. Our app monitors and records all screenshots and recordings. Violators will face strict legal action.

## DISCLAIMER

THIS IS COPYRIGHTED CONTENT. Unauthorized use, including screenshots, copying, misuse, reuse, or resale of any content from this app, is strictly prohibited. Our app monitors and records all screenshots and recordings. Violators will face strict legal action.

THIS IS COPYRIGHTED CONTENT. Unauthorized use, including screenshots, copying, misuse, reuse, or resale of any content from this app, is strictly prohibited. Our app monitors and records all screenshots and recordings. Violators will face strict legal action.

## PERI IMPLANT DISEASES AND IMPLANT MAINTENANCE

### Maintenance of Implants:

- To improve the long-term prognosis of the implant fixtures and implants, patient motivation and oral hygiene measures are paramount.
- Periodontal health should be achieved prior to proceeding with implant therapy.
- Restorations should be cleansable with well- fitting margins, with preservation of as much marginal tissue as possible.
- After a successful implant therapy, a maintenance program should be undertaken that should be tailored to the individual and include regular recalls to provide optimal disease prevention.
- Each recall visit should include examination, reevaluation, diagnosis, motivation and treatment of the infected sites.
- Before starting maintenance program, a baseline data with probing pocket depth, mucosal margin position and radiographic crestal bone level should be established.
- The decision process for maintenance and treatment should be evidence based and the table below shows a protocol for the same.

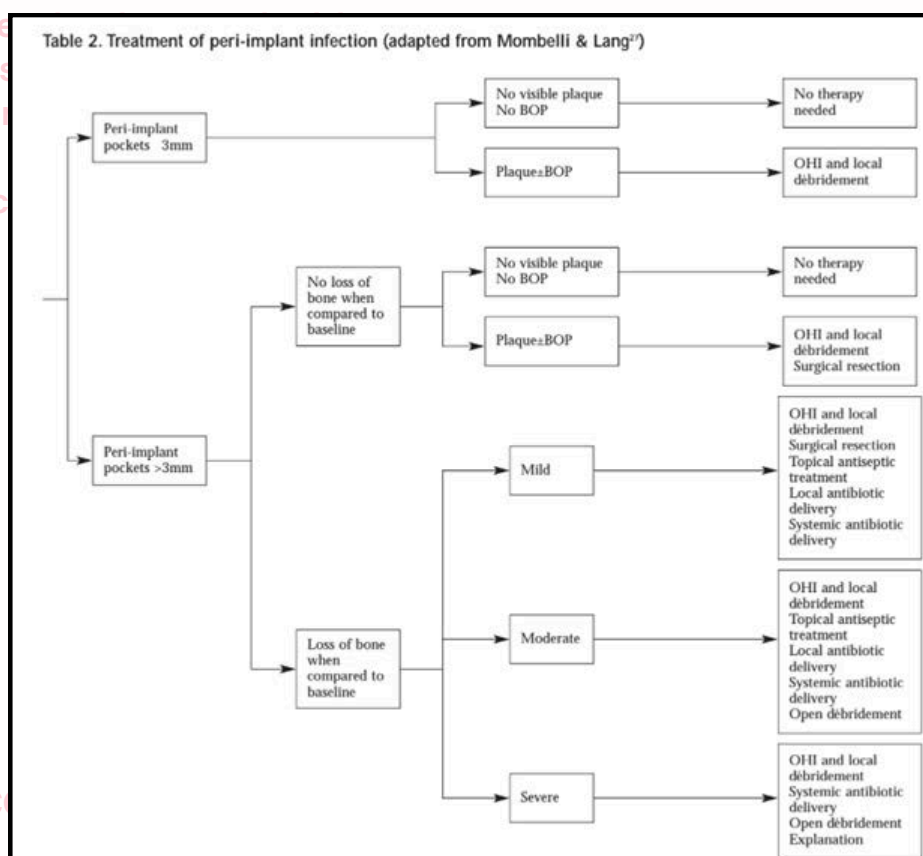


Image- Source (Article)

- During the maintenance review a complete oral examination should be conducted to detect early signs of disease.

### DISCLAIMER

THIS IS COPYRIGHTED CONTENT. Unauthorized use, including screenshots, copying, misuse, reuse, or resale of any content from this app, is strictly prohibited. Our app monitors and records all screenshots and recordings. Violators will face strict legal action.

DISCLAIMER

THIS IS COPYRIGHTED CONTENT. Unauthorized use, including screenshots, copying, misuse, reuse, or resale of any content from this app, is strictly prohibited. Our app monitors and records all screenshots and recordings. Violators will face strict legal action.

DISCLAIMER

THIS IS COPYRIGHTED CONTENT. Unauthorized use, including screenshots, copying, misuse, reuse, or resale of any content from this app, is strictly prohibited. Our app monitors and records all screenshots and recordings. Violators will face strict legal action.



# PERI IMPLANT DISEASES AND IMPLANT MAINTENANCE

## Oral Hygiene measures for implant prosthesis:

- Good oral hygiene must be maintained by the patient with the use of tooth brush (either manual or electric) to reduce plaque biofilm, Floss (including super floss and interdental brush) to clean interproximal surfaces.
  - a) In case of a single unit implant: Interdental floss is recommended.
  - b) In a fixed-bridge prosthesis- Super floss or if gap is present interdental brush (tufted brush) is recommended.

### Super floss:

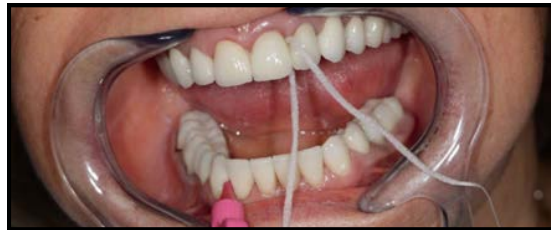
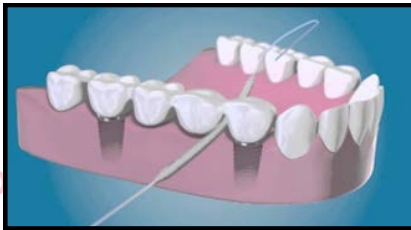
Image: Flossing the Crows using Super Floss

- The upper part of the Super floss resembles a 10 cm long, strong plastic line with the aid of which the dental floss can be guided beneath the pontic and between the teeth. This is the end that needs to be introduced between the teeth and underneath the replacement tooth.

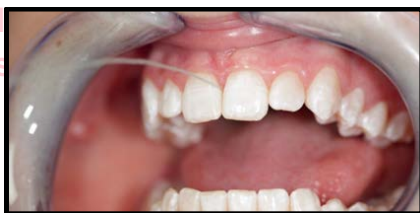

Image: Upper part of super Floss (Source-Internet)

- The cleaning section of the Super floss is made of a thicker, spongy material with which the retainers and the underside of pontics bridging the edentulous area, that is, difficult-to-access areas can be cleaned.

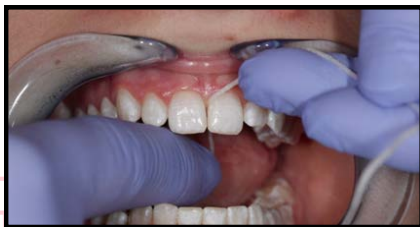

Image-Cleaning section of super floss (Source- Internet)

- The third section is plain dental floss, and is to be used accordingly.

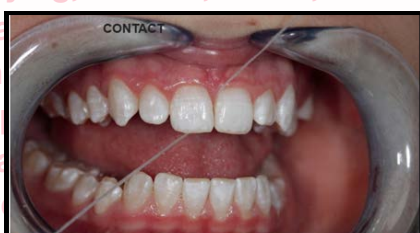

Image: Third section of super floss (source internet)

DISCLAIMER

THIS IS COPYRIGHTED CONTENT. Unauthorized use, including screenshots, copying, misuse, reuse, or resale of any content from this app, is strictly prohibited. Our app monitors and records all screenshots and recordings. Violators will face strict legal action.

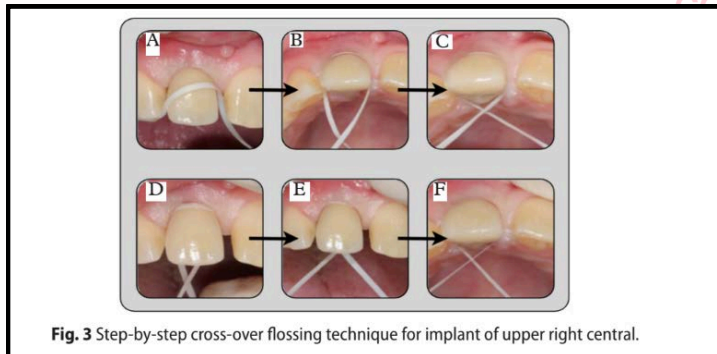
DISCLAIMER

THIS IS COPYRIGHTED CONTENT. Unauthorized use, including screenshots, copying, misuse, reuse, or resale of any content from this app, is strictly prohibited. Our app monitors and records all screenshots and recordings. Violators will face strict legal action.

THIS IS COPYRIGHTED CONTENT. Unauthorized use, including screenshots, copying, misuse, reuse, or resale of any content from this app, is strictly prohibited. Our app monitors and records all screenshots and recordings. Violators will face strict legal action.

## PERI IMPLANT DISEASES AND IMPLANT MAINTENANCE

- c) If the implant is positioned in an ideal position in the esthetic zone a cross over flossing technique can be used.



- d) If the implant is not in the ideal position, then it can lead to difficulty in cleaning so use of super floss or tufted brush is often indicated.

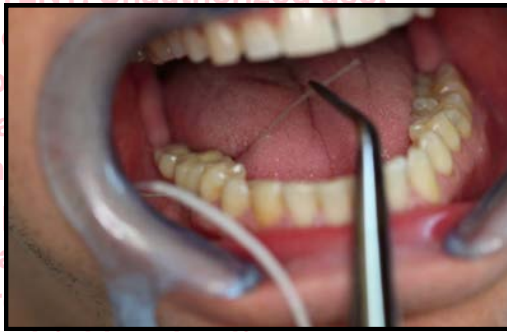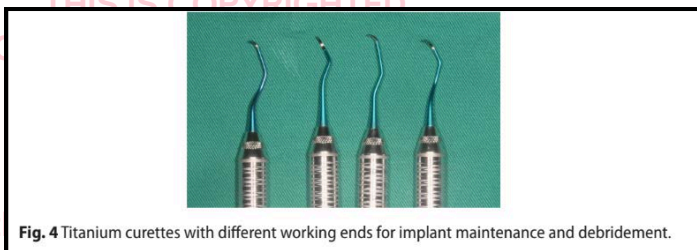


Image: The cleaning of a screw-retained bridge anchored on two lower implants with Super floss (Source- Internet)

- A review appointment at 2 weeks after the fit of final prosthesis is essential to observe the patient perform the oral hygiene technique.

### Professional Cleaning of Implant surfaces:

- Calculus formation on the implant surface is very similar to that on the tooth but as the abutment and porcelain is highly polished the calculus is not tenacious.
- When removing supragingival calculus from the implant crowns, stainless steel scalers must not be used as they will damage the titanium surfaces.
- Use of titanium, carbon fiber or plastic reinforced with graphite curettes or scalers is recommended as they will not roughen or scratch the treated implant surface.



- An ultrasonic scaler is never used on an implant as it will heat the implant and damage the bone that helps the implant integrate.

### DISCLAIMER

THIS IS COPYRIGHTED CONTENT. Unauthorized use, including screenshots, copying, misuse, reuse, or resale of any content from this app, is strictly prohibited. Our app monitors and records all screenshots and recordings. Violators will face strict legal action.

DISCLAIMER

THIS IS COPYRIGHTED CONTENT. Unauthorized use, including screenshots, copying, misuse, reuse, or resale of any content from this app, is strictly prohibited. Our app monitors and records all screenshots and recordings. Violators will face strict legal action.

THIS IS COPYRIGHTED CONTENT. Unauthorized use, including screenshots, copying, misuse, reuse, or resale of any content from this app, is strictly prohibited. Our app monitors and records all screenshots and recordings. Violators will face strict legal action.

## DENTURE TROUBLESHOOTING

- Problems arising with the insertion of complete denture is inevitable which can be transient or severe enough that the patient cannot tolerate the denture.

Factors that can cause problems can be grouped as:

- 1) Adverse intraoral anatomical factors: e.g., atrophic mucosa.
- 2) Clinical factors: e.g., Poor denture stability
- 3) Technical factors: e.g., Failure to preserve the peripheral roll on a master cast.
- 4) Patient adaptational factors which are the most critical factors by far.
  - Once a denture- wearing problem becomes apparent, it should be addressed in a logical and systemic way.
  - First, an adequate history of the problem should be obtained followed by careful examination of the mouth so that an accurate diagnosis can be made and appropriate treatment plan formulated.
  - The **first step** should be **listening to the patient (as their difficulties are described)**.
  - The most commonly encountered complete denture problems at the time of insertion or during review appointments in the days and weeks after insertion with their causes and suitable forms of treatment are:
    - a) Discomfort associated with dentures
    - b) Looseness of dentures
    - c) Problems relating to instability to adapt to dentures

### A) DISCOMFORT ASSOCIATED WITH DENTURES

- Many patients experience some discomfort for a period (up to a few days) after receiving new or replacement dentures.
- Majority of patients achieve comfortable co-existence with their appliances following a short period of adjustment to the new conditions that can be carefully assisted by the operator.
- In some cases, where potential problems are not identified at the time of insertion, the discomfort can be prolonged.
- The commonly encountered causes of prolonged discomfort with their management are given below:

#### 1) Discomfort related to impression surface of the denture

##### a) Discomfort due to Discrete painful areas:

**Cause:** They are caused by pearls or sharp ridges of acrylic on fitting surface due to lack of laboratory finishing.

**Treatment:** They can be located with finger, snagging of dry cotton wool fibers or using disclosing solution and corrected.

Symptoms/clinical findings	Cause	Treatment
Related to impression surface Discrete painful areas	Pearls or sharp ridges of acrylic on the fitting surface arising from deficiency in laboratory finishing	Locate with finger, or snagging dry cotton wool fibres. Use disclosing material to assist locality to ease denture

### DISCLAIMER

THIS IS COPYRIGHTED CONTENT. Unauthorized use, including screenshots, copying, misuse, reuse, or resale of any content from this app, is strictly prohibited. Our app monitors and records all screenshots and recordings. Violators will face strict legal action.

### DISCLAIMER

THIS IS COPYRIGHTED CONTENT. Unauthorized use, including screenshots, copying, misuse, reuse, or resale of any content from this app, is strictly prohibited. Our app monitors and records all screenshots and recordings. Violators will face strict legal action.

### DISCLAIMER

THIS IS COPYRIGHTED CONTENT. Unauthorized use, including screenshots, copying, misuse, reuse, or resale of any content from this app, is strictly prohibited. Our app monitors and records all screenshots and recordings. Violators will face strict legal action.



# DENTURE TROUBLESHOOTING

## 1) Discomfort related to impression surface of the denture

### b) Discomfort due to Area painful to pressure:

- They are caused by pressure areas.

Symptoms/clinical findings	Cause	Treatment
Areas painful to pressure	Pressure areas resulting eg from faulty impressions, damage to working cast, warpage of denture base. Consider also residual pathology (eg retained root), lack of relief for active frena, non-displaceable mucosa over bony prominence (eg torus)	Use disclosing material to accurately locate area to be relieved. If severe, remake may be required. Consider removal of root

### c) Discomfort associated with Pain on insertion or removal of denture with inflamed mucosa on sides of ridges.

Symptoms/clinical findings	Cause	Treatment
Pain on insertion and removal, possibly inflamed mucosa on side(s) of ridges	Denture not relieved in region of undercuts	Use disclosing material to adjust in region of 'wipe off'. Exercise care as excessive removal may reduce retention. Also clinician should only insert denture and then remove it - the patient should not occlude as this may confuse an occlusal fault with support problems

### d) Discomfort owing to Generalized (Diffuse) pain over denture-supporting area

\*FWS= Freeway space

Symptoms/clinical findings	Cause	Treatment
Generalised pain over denture-supporting area	Under-extended denture base - may be the result of over-adjustment to the periphery, or impression surface. Check for adequacy of FWS	Extend denture to optimal available denture support area. If insufficient FWS, remake may be required

### e) Discomfort due to Painful mylohyoid ridge/ Denture lifts on tongue protrusion / It is painful to swallow / There is Over-extension of lingual flange.

Symptoms/clinical findings	Cause	Treatment
Over-extension of lingual flange. Painful mylohyoid ridge; denture lifts on tongue protrusion; painful to swallow	Over-extended lower impression: instructions to laboratory not clear or non-existent	Determine position and extent of over-extension using disclosing material and relieve accordingly

### f) Discomfort due to Lack of relief of relief area/ sore throat/ Difficulty swallowing.

Symptoms/clinical findings	Cause	Treatment
Lack of relief for frena or muscle attachments; pinching of tissue between denture base and retromolar pad or tuberosity. Sore throat, difficulty in swallowing	Peripheral over-extension resulting from impression stage and/or design error. Palatal soreness as post dam too deep	Relieve with aid of disclosing material. Care with adjustment of post dam - removal of existing seal and its replacement in greenstick prior to permanent addition may be required

DISCLAIMER

THIS IS COPYRIGHTED CONTENT. Unauthorized use, including screenshots, copying, misuse, reuse, or resale of any content from this app, is strictly prohibited. Our app monitors and records all screenshots and recordings. Violators will face strict legal action.

DISCLAIMER  
THIS IS COPYRIGHTED CONTENT. Unauthorized use, including screenshots, copying, misuse, reuse, or resale of any content from this app, is strictly prohibited. Our app monitors and records all screenshots and recordings. Violators will face strict legal action.

DISCLAIMER

THIS IS COPYRIGHTED CONTENT. Unauthorized use, including screenshots, copying, misuse, reuse, or resale of any content from this app, is strictly prohibited. Our app monitors and records all screenshots and recordings. Violators will face strict legal action.

## DENTURE TROUBLESHOOTING

### 2) Discomfort related to occlusal surfaces of denture:

#### a) Pain on eating due to occlusal imbalance (without problems in support):

- Means the pain occurs due to occlusal imbalance without problems in support, (i.e., the underlying tissues and ridges are stable)
- Cause: Anterior or posterior occlusal prematurity due to premature contacts between denture teeth where teeth come in contact too soon leading to uneven pressure distribution on chewing.  
Or Due to incisal locking when the incisal edges of opposing anterior teeth lock together, restricting proper functional movement.  
Or when there is no harmony between upper and lower denture teeth during mastication leading to discomfort. (No balanced articulation)

Symptoms/clinical findings	Cause	Treatment
Related to occlusal surfaces Pain on eating in presence of occlusal imbalance (no support problems)	Anterior prematurity or posterior prematurity, incisal locking, lack of balanced articulation	Determine where occlusal prematurities exist. Adjust occlusion by selective grinding. If severe error remount using facebow and new interocclusal records

#### b) Pain present in the lingual to mandibular anterior ridge (pain specifically localized to lingual side of the lower anterior ridge)

- This is due to interferences during mandibular movements.
- It is caused either due to overextension of the lingual denture flange that impinges the soft tissues in the lingual area.
- Or, if no overextension is present, the pain could be due to a protrusive slide from retruded contact position (RCP) to intercuspal position (ICP) caused by deflective contacts on the posterior teeth.

Symptoms/clinical findings	Cause	Treatment
Pain lingual to lower anterior ridge	If no over-extension present, look for protrusive slide from RCP to ICP	Mark deflecting inclines of posterior teeth with thin articulating paper. If slide exceeds half a cusp width, re-register and reset

#### c) Pain and inflammation in the labial aspect of lower ridge

- It is caused when the denture base is not properly adapted to the tissues causing pressure or irritation (impression surface defect)
- It can also be caused if there is lack of incisal overjet due to improper tooth positioning that leads to incisal locking. It leads to excess pressure on the labial ridge.

Symptoms/clinical findings	Cause	Treatment
Pain and/or inflammation on labial aspect of lower ridge	If no impression surface defect, may be lack of incisal overjet causing incisal locking	Reduce incisal vertical overlap. If appearance compromised, resetting the incisors may be required

#### d) Pain around the periphery of dentures (with associated muscle pain)

- It is caused by excessive VDO (Vertical dimension of occlusion) where the occlusal height of the denture exceeds more than the patient can comfortably tolerate.

Symptoms/clinical findings	Cause	Treatment
Pain about periphery of dentures possibly accompanied by pain in masseter and posterior temporalis muscles (classically pain increases as the day progresses)	Vertical dimension of occlusion more than patient can tolerate	If excess less than 1.5 mm, grind to provide FWS. If greater than 1.5 mm, re-register to reset dentures at new OVD

#### DISCLAIMER

THIS IS COPYRIGHTED CONTENT. Unauthorized use, including screenshots, copying, misuse, reuse, or resale of any content from this app, is strictly prohibited. Our app monitors and records all screenshots and recordings. Violators will face strict legal action.

#### DISCLAIMER

THIS IS COPYRIGHTED CONTENT. Unauthorized use, including screenshots, copying, misuse, reuse, or resale of any content from this app, is strictly prohibited. Our app monitors and records all screenshots and recordings. Violators will face strict legal action.

#### DISCLAIMER

THIS IS COPYRIGHTED CONTENT. Unauthorized use, including screenshots, copying, misuse, reuse, or resale of any content from this app, is strictly prohibited. Our app monitors and records all screenshots and recordings. Violators will face strict legal action.

# DENTURE TROUBLESHOOTING

## 2) Discomfort related to occlusal surfaces of denture:

### e) Discomfort due to cheek or lip biting

- Cheek biting is caused when the functional width of the denture's buccal or labial flange is inadequate and proper soft tissue support is not present, leading to cheek trapping or biting.
- Lip biting is caused by poor positioning of anterior teeth with insufficient incisal guidance or inadequate overlap leading to unintentional lip biting.

Symptoms/clinical findings	Cause	Treatment
Cheek and/or lip biting	For cheeks - likely that functional width of sulcus was not restored. For lips - poor lip support/inadequate anterior horizontal overlap	For cheek biting, restore functional width of sulcus and/or reset. For lips, grind lower incisors to provide a more appropriate incisal guidance angle

### f) Discomfort due to tongue biting

- It is caused due to lack of lingual overjet (i.e., when the mandibular teeth are placed too far lingually, encroaching on the tongue space.)

Symptoms/clinical findings	Cause	Treatment
Tongue biting	Lack of lingual overjet - teeth generally placed lingual to lower ridge	Remove lower lingual cusps, or reset teeth

## 3) associated with polished surface of denture:

### a) Pain on mouth opening on posterior aspect of the upper denture

- It is caused due to overextension of buccal flange or if the flange is too thick impinging on the buccal tissues or the coronoid process during jaw movements.

Symptoms/clinical findings	Cause	Treatment
Related to polished surfaces Pain at posterior aspect of upper denture on opening	Flange on buccal aspect of tuberosity too thick and constraining coronoid process	Use disclosing material to accurately define area involved, relieve and repolish

## 4) Discomfort in denture wearers that may be related with systemic conditions:

Symptoms/clinical findings	Cause	Treatment
Burning sensation over upper denture supporting tissues, but may involve other intra-oral tissues, eg tongue.	Burning mouth syndrome often seen in middle-aged or elderly females. Denture faults must be excluded, also general organic and psychogenic factors	Correction of any denture faults, may require multivitamin/nutrition advice and treatment. Possibly antidepressant therapy. Refer to Consultant in Oral Medicine
Beefy red tongue, possibly glossodynia	Vitamin B12/folate deficiency	Refer for medical treatment
Frictional lesions related to dentures, mucosa may adhere to probing finger, may be complaint of dry mouth	Xerostomia, commonly side effect of prescribed drugs	Where some saliva flow is present, sugar-free citrus lozenges may help. Where there is an obvious paucity of saliva, artificial saliva may be considered
Tongue thrusting. Empty mouth 'chewing'. Often seen in elderly patients	May have neurological or psychological aspects. Possibly drug related	Difficult to manage. Treatment may be required to include occlusal adjustment and/or occlusal pivots
Presence of herpetiform ulcers in mouth	Herpes simplex or Herpes zoster virus. History and distribution of lesions to confirm	Dentures merely coincidental to the condition. May be useful to suggest preventive remedy (eg acyclovir) for some sufferers



## DENTURE TROUBLESHOOTING

### 5) Discomfort in denture wearers that may be related to denture issues:

#### a) Painful 'Click' Related to TMJ

- It is Caused due to TMJ Dysfunction Syndrome, often linked to rapid change in occlusal vertical dimension (OVD) during denture fabrication or psychological factors, or part of generalized joint disease (e.g., arthritis).

Symptoms/clinical findings	Cause	Treatment
Painful 'click' related to TMJ on opening and/or closing mouth and/or tenderness of muscles of mastication	TMJ pain dysfunction syndrome may be related to rapid change on OVD (either gross increase or decrease) on production of new denture. May have psychological aspects, occasionally part of general joint disease	If denture faults present, careful correction required with special care to registration and vertical dimension

#### b) Allergy to Denture Material

- It is rare but possible due to residual monomer content in acrylic dentures.

Symptoms/clinical findings	Cause	Treatment
Patient complains of allergy to denture material	Rare symptoms may relate to higher residual monomer content of acrylic	If excess residual monomer detected, rebase denture using controlled heat cure cycle. May need to consider remaking denture using polycarbonate resin

#### c) Painless Erythema of Mucosa

- Usually present as denture-related stomatitis, caused by ill-fitting dentures, candida infection (opportunistic fungal infection) or nutritional deficiencies (e.g., iron, folate).

Symptoms/clinical findings	Cause	Treatment
Painless erythema of mucosa related to support of (usually) upper denture, may be accompanied by angular cheilitis	Denture-related stomatitis. Often has a frictional element due to ill-fitting denture plus opportunistic candidal infection. Occasionally related to iron or folate deficiency	Best to leave denture out until condition clears, then remake. If not possible, correct denture faults, eg using occlusal pivots, regularly supervised and replaced tissue conditioners prior to remake. If angular cheilitis present, combinations of antifungal and antibacterial agents (eg miconazole) useful

# DENTURE TROUBLESHOOTING

## B) LOOSENESS OF DENTURE

- Denture looseness is most commonly associated with lower dentures and sometimes with upper dentures as well
- Patient complains of their denture rocking, falling (for upper denture) or rising (for lower denture), shifting or sometimes of feeling too big.
- The retention and stability of complete denture is with the balance of retaining force on one side and displacing force on the other side. If the displacing force is more than the retaining force then instability/looseness will occur, however it will depend on the patient's ability to adapt to dentures.

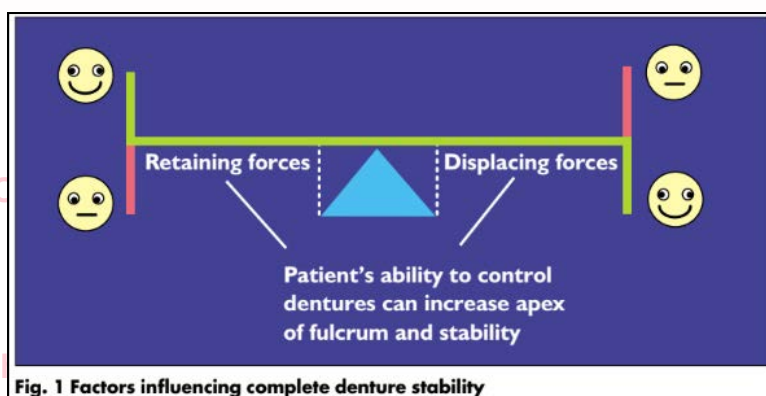


Fig. 1 Factors influencing complete denture stability

- The commonly encountered causes of looseness of denture with their cause management and clinical finding is given below:

### 1) Looseness of dentures due to decrease in retention forces

#### a) Lack of Peripheral Seal

- It can be due to Border under-extension in depth where the denture flange doesn't extend far enough into the sulcus or vestibule to create an effective seal.
- Or, due to Border under extension in width that often occurs in the disto-buccal area of the upper denture, where the denture may be displaced by functional movements like chewing or opening the mouth (involvement of buccinator or masseter muscles).
- It can be due to an improperly placed or short posterior border can compromise the seal.

Symptoms/clinical findings	Cause	Treatment
Lack of peripheral seal	<p>Border under-extension in depth</p> <p>Border under-extension in width. Often a particular problem in disto-buccal aspects of upper periphery which may be displaced by buccinator on mouth opening.</p> <p>Posterior border of upper denture</p>	<p>Add softened tracing compound to relevant border, mould digitally and by functional movements by patient. Replace compound with acrylic resin. As a temporary measure a chairside reline material may be used as described above</p> <p>Check border is correctly sited on fixed tissue at junction with mobile tissue of soft palate. Trace thin string of softened tracing compound along impression surface of posterior border and seat denture firmly in mouth. Replace compound with acrylic resin. For temporary solution, use butymethacrylate resin as above</p>

#### DISCLAIMER

THIS IS COPYRIGHTED CONTENT. Unauthorized use, including screenshots, copying, misuse, reuse, or resale of any content from this app, is strictly prohibited. Our app monitors and records all screenshots and recordings. Violators will face strict legal action.

#### DISCLAIMER

THIS IS COPYRIGHTED CONTENT. Unauthorized use, including screenshots, copying, misuse, reuse, or resale of any content from this app, is strictly prohibited. Our app monitors and records all screenshots and recordings. Violators will face strict legal action.

#### DISCLAIMER

THIS IS COPYRIGHTED CONTENT. Unauthorized use, including screenshots, copying, misuse, reuse, or resale of any content from this app, is strictly prohibited. Our app monitors and records all screenshots and recordings. Violators will face strict legal action.

# DENTURE TROUBLESHOOTING

## 1) Looseness of dentures due to decrease in retention forces

### b) Inelasticity of Cheek Tissues:

- Due to Loss of elasticity in oral tissues due to, aging process (common in elderly patients) or Systemic conditions like scleroderma or submucous fibrosis.

Symptoms/clinical findings	Cause	Treatment
Inelasticity of cheek tissues	Consequence of ageing process; scleroderma, submucous fibrous	Mould denture borders incrementally using softened tracing-compound as functional movements are performed - aim to slightly under-extend depth and width of denture periphery. Repeated treatment may be required as inelasticity progresses

### c) Air Beneath the Impression Surface

- It can be caused due to Poor denture fit resulting from deficient impression or damaged denture base, improper relief of impression surface or over-adjustment during fabrication
- It can also be caused due to ridge resorption or excessive relief causing a loss of intimate contact with tissues.

Symptoms/clinical findings	Cause	Treatment
Air beneath impression surface. Denture may rock under finger pressure. May see gap between periphery of flange and ridge. Occlusal error subsequent to warpage	Deficient impression. Damaged cast. Warped denture. Over-adjustment of impression surface. Residual ridge resorption. Undercut ridge. Excessive relief chamber. Change in fluid content of supporting tissues	Reline if design parameters of denture satisfactory, otherwise remake as required. Ensure that areas of heavy contact between denture and tissues are relieved prior to impression making. Where change in tissue fluid distribution is suspected check medication (eg diuretics) posture (eg heart failure) lack of recovery of tissues from effects of old denture prior to working impressions being obtained. Stabilise fluid content of tissues and use minimal pressure impression method

### d) Xerostomia (Reduced ability to form a suitable seal)

- Dry mouth causes insufficient saliva which will result in poor adhesion between denture base and the mucosa. There will be reduced suction (cohesion and adhesion forces) required for denture retention that causes discomfort, irritation and increased risk of denture movement during function.

Symptoms/clinical findings	Cause	Treatment
Xerostomia Reduces ability to form a suitable seal	Medication by many commonly prescribed drugs, irradiation of head and neck region, salivary gland disease	Design dentures to maximise retention and minimise displacing forces. Prescribe artificial saliva where appropriate

### e) Poor control of neuromuscular ability which is essential for successful denture wearing

- Neuromuscular control is the ability of lips, tongue, cheeks and masticatory muscles to stabilize and retain the denture during function.

Symptoms/clinical findings	Cause	Treatment
Neuromuscular control Essential for successful denture wearing: speech and eating difficulties occur	Basic shape of denture incorrect, lower molars too lingual; occlusal plane too high: upper molars buccal to ridge and buccal flange not wide enough to accommodate this; lingual flange of lower convex. Patient of advanced biological age, infirm	Correct design faults by, eg removal of lingual cusps of posterior teeth. Flatten polished lingual surface of lower from occlusal surface to periphery, fill sulci to optimal width. May require remake to optimal design. Use information from successful previous denture if available. Denture adhesives may be deemed to be necessary

#### DISCLAIMER

THIS IS COPYRIGHTED CONTENT. Unauthorized use, including screenshots, copying, misuse, reuse, or resale of any content from this app, is strictly prohibited. Our app monitors and records all screenshots and recordings. Violators will face strict legal action.

#### DISCLAIMER

THIS IS COPYRIGHTED CONTENT. Unauthorized use, including screenshots, copying, misuse, reuse, or resale of any content from this app, is strictly prohibited. Our app monitors and records all screenshots and recordings. Violators will face strict legal action.

#### DISCLAIMER

THIS IS COPYRIGHTED CONTENT. Unauthorized use, including screenshots, copying, misuse, reuse, or resale of any content from this app, is strictly prohibited. Our app monitors and records all screenshots and recordings. Violators will face strict legal action.



## DENTURE TROUBLESHOOTING

### 2) Looseness of denture due to increase in displacing forces

#### a) Over extension in depth of denture border causes

- Displacement when opening the mouth halfway.
- Ulceration or soreness on areas like sulcus or posterior palate
- Discomfort and pain can be seen due to excessive post dam extension.

Symptoms/clinical findings	Cause	Treatment
<i>Denture borders</i> <i>Over-extension in depth</i> Slow rise of lower denture when mouth half open, line of inflammation at reflection of sulcal tissues; ulceration in sulcal region. Deep post dam on upper base may cause pain, ulceration	If buccal to tuberosities, denture displaces on mouth opening, or cheek soreness occurs. Thickened lingual flange enables tongue to lift denture; thick upper and lower labial flanges may produce displacement during muscle activity	Slightly under-extend denture flange and accurately mould softened tracing compound. Check borders of record rims and trial dentures at the appropriate stages. Deep post dam to be cautiously reduced and denture worn sparingly until inflammation clears

#### b) Overextension in width leads to

- Plumped out appearance of cheeks, it occurs due to incorrect design where flanges are extended too far lingually.

Symptoms/clinical findings	Cause	Treatment
<i>Overextension in width</i> Cheeks appear plumped out. In lower, the buccal flange may be palpated lateral to external oblique ridge	Design error	Reduce over-extension. Use disclosing material to determine what is excessive

#### c) Poor fit to supporting tissue

- It can be caused due to tissue recoil or poor impression technique resulting in loose denture with inadequate adaptation to underlying ridge.

Symptoms/clinical findings	Cause	Treatment
<i>Poor fit to supporting tissue</i> Recoil of displaced tissue lifts denture	Poor/inappropriate impression technique especially in posterior lingual pouch area	Reline if all other design parameters satisfactory, otherwise remake. Ensure denture is removed from mouth 90 mins prior to impression

#### d) Denture not in optimal space

When dentures are not in their optimal space the presented symptoms can be Lingual cusps or surfaces of posterior teeth trapping the tongue, Poor triangular shape of denture arches, leading to instability or Anterior teeth improperly positioned, causing pressure on the lips or nasolabial angle.

Cause for this can be:

- Molars set too lingually on the lower ridge.
- Excessive width of the posterior occlusal table.
- Thick lingual flanges that interfere with tongue space.
- Poor positioning of anterior teeth, causing excessive lip pressure.

## DENTURE TROUBLESHOOTING

### 2) Looseness of denture due to increase in displacing forces

#### d) Denture not in optimal space

Symptoms/clinical findings	Cause	Treatment
Denture not in optimal space	<p>Molars on lower denture lingual to ridge, optimum triangular shape of dentures absent</p> <p>Posterior occlusal table too broad, causing tongue trapping</p> <p>Thick lingual flanges encroaching on tongue space, causing lifting. Excess lip pressure to lower anterior aspect - teeth anterior to ridge, thick periphery</p> <p>Excess pressure from upper lip to upper denture arising from teeth too labially sited to acute naso-labial angle; or failure to adequately seat denture during relining impression procedure</p>	<p>Remove lingual cusps and lingual surface from relevant area, repolish. If triangular form not restored, reset teeth or remake dentures</p> <p>Narrow posterior teeth and/or remove most distal teeth from dentures. Reshape lingual polished surface</p> <p>Thin lower labial flange, ensure optimal extension to retromolar pads to resist displacement, reset anterior teeth if necessary</p> <p>Usually requires remaking denture</p>

#### e) Occlusal errors leading to looseness of dentures

The uneven tooth contact leads to tilting or movement of the denture and the dentures fail to seat properly and may become unstable during mastication.

Causes:

- Uneven Contact: Unequal contact between teeth in occlusion causes instability.
- ICP (Intercuspal Position) and RCP (Retruded Contact Position) Not Coincident: Discrepancy between these positions disrupts border seal and denture stability.
- Lack of Freedom in ICP: Dentures lock into occlusion and shift on the supporting tissues, especially in patients with poor mandibular control.

Symptoms/clinical findings	Cause	Treatment
Occlusal errors	<p>Uneven tooth contact causing tilting of dentures and prevents even seating of loosened appliances</p> <p>ICP and RCP not coincident - disrupts border seal and prevents accurate reseating</p> <p>Lack of freedom in ICP (occlusal-locking) dentures will shift on supporting tissues for those patients with poor control of mandibular movements</p>	<p>Adjust occlusion until even initial contact in RCP obtained. If gaps between teeth exceeds 1.5 mm reset teeth or remake dentures. For gaps less than 1.5 mm it may still be necessary, in the interest of accurate diagnosis, to remount the dentures, as a patient's mouth may be too tender to permit chairside adjustment. Adjust occlusion for coincident ICP/RCP contact. If error is greater than half width of cusp, all teeth on at least one denture need resetting.</p> <p>Remount dentures on adjustable articulator and adjust area of occlusal contact. Allow 1.5 mm of anterior movement from RCP. May use cusplless teeth where appropriate</p>

#### DISCLAIMER

THIS IS COPYRIGHTED CONTENT. Unauthorized use, including screenshots, copying, misuse, reuse, or resale of any content from this app, is strictly prohibited. Our app monitors and records all screenshots and recordings. Violators will face strict legal action.

#### DISCLAIMER

THIS IS COPYRIGHTED CONTENT. Unauthorized use, including screenshots, copying, misuse, reuse, or resale of any content from this app, is strictly prohibited. Our app monitors and records all screenshots and recordings. Violators will face strict legal action.

#### DISCLAIMER

THIS IS COPYRIGHTED CONTENT. Unauthorized use, including screenshots, copying, misuse, reuse, or resale of any content from this app, is strictly prohibited. Our app monitors and records all screenshots and recordings. Violators will face strict legal action.

## DENTURE TROUBLESHOOTING

### 2) Looseness of denture due to increase in displacing forces

#### f) Looseness due Excessive vertical overlap of anterior teeth

- Poor balance or contact in anterior teeth causing denture tilting and discomfort with ulceration in the lower ridge.

Treatment: It can be corrected by reducing the height of lower anterior. If aesthetic is a concern resetting of teeth may be required.

#### g) Looseness can occur due to Lower molars placed too far posteriorly onto the retromolar pad or ascending ramus

- This posterior placement of teeth will lead to occlusal contact in inclined plane causing the denture to slip forward.

Treatment: It can be corrected by removing most posterior teeth from denture.

#### h) Looseness due to improper orientation of occlusal plane

- This tends to move the denture over the supporting tissues

Correction: Usually requires teeth to be reset or denture to be remade.

#### i) Looseness due to bony prominences over a thin mucosa (like tori)

- This will lead to rocking of the denture over the prominence.

Correction: Relief should be provided to the area by removing acrylic from the impression surface where excessive loading is shown by the disclosing solution.

If excessive relief is produced loss of retention will occur. (Care should be taken)

### C) PROBLEMS DUE TO INABILITY TO ADAPT TO DENTURES

- The symptoms may be functionally related or psychologically related.
- The functionally related problems i.e., in association to eating, chewing or speech should be identified in the planning stage and avoided by trial denture visits.
- The common problems are:

#### 1) Gagging

- Immediate gagging after insertion is due to Over extension of the posterior borders of upper denture (that are too thick)
- Or due to too thick lower lingual flange

Correction: Reduction in the posterior dam area. The lower lingual flange should be reduced carefully from outside.

Delayed gagging 2 weeks to 2 months after insertion is due to faulty post dam resulting in pooling of saliva or malocclusion leading to seepage of saliva

Correction: Laboratory Rebasing is required to correct the posterior dam seal.

#### DISCLAIMER

THIS IS COPYRIGHTED CONTENT. Unauthorized use, including screenshots, copying, misuse, reuse, or resale of any content from this app, is strictly prohibited. Our app monitors and records all screenshots and recordings. Violators will face strict legal action.

#### DISCLAIMER

THIS IS COPYRIGHTED CONTENT. Unauthorized use, including screenshots, copying, misuse, reuse, or resale of any content from this app, is strictly prohibited. Our app monitors and records all screenshots and recordings. Violators will face strict legal action.

THIS IS COPYRIGHTED CONTENT. Unauthorized use, including screenshots, copying, misuse, reuse, or resale of any content from this app, is strictly prohibited. Our app monitors and records all screenshots and recordings. Violators will face strict legal action.

#### DISCLAIMER



## DENTURE TROUBLESHOOTING

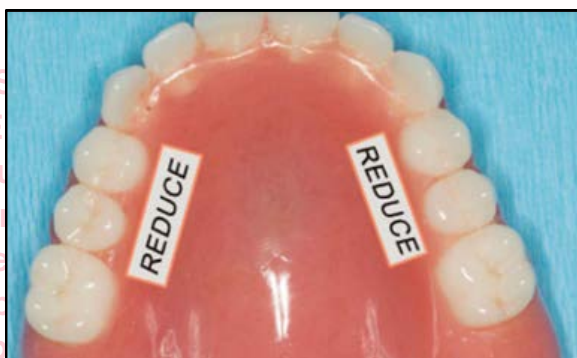### 2) Complaints related to difficulty in speaking:

#### a) Whistle on S sound:

Cause:

- Can be due to too narrow space in the bicuspid area and not enough space for tongue.
- Or, If the anterior part of the palate is under contoured causing narrow air space anteriorly. (If there is no contact in the anterior area during pronunciation of s it will lead to whistle sound.)

Correction: Either remove or move bicuspids more buccally or if room is available grind out more space for tongue.



#### b) Lisp on S sound

- Can be due to over contoured anterior area of the palate that excessively blocks the air flow for producing S sound
- There is too much space for the tongue between the bicuspids

Correction can be done by reducing the thickness of the denture base in the anterior part of maxilla.

Or by adding a ledge of acrylic between the bicuspids

#### c) Inability to distinct between Th and T sounds:

Cause: It can occur when the anterior are placed too far lingual

Or, there is not enough room for tongue.

Correction will be to reset the anterior teeth in the correct position.

"Th" and "T" sounds indistinct	1. Not enough room in dentures for tongue 2. If "Th" and "T" sound alike the anteriors are too far lingual	1. Thin out dentures from lingual sides – don't grind tissue side. 2. Remount and move anteriors out to the buccal.
--------------------------------	---	--

#### d) Inability to distinguish between F and V sound:

- It occurs due to incorrect vertical positions of the maxillary incisors
- If 'F sound' sounds like V anterior teeth are too long
- If 'V sound' sounds like F anterior teeth are too short

Correction: Teeth should be reset in the correct position.

#### DISCLAIMER

THIS IS COPYRIGHTED CONTENT. Unauthorized use, including screenshots, copying, misuse, reuse, or resale of any content from this app, is strictly prohibited. Our app monitors and records all screenshots and recordings. Violators will face strict legal action.

#### DISCLAIMER

THIS IS COPYRIGHTED CONTENT. Unauthorized use, including screenshots, copying, misuse, reuse, or resale of any content from this app, is strictly prohibited. Our app monitors and records all screenshots and recordings. Violators will face strict legal action.

#### DISCLAIMER

THIS IS COPYRIGHTED CONTENT. Unauthorized use, including screenshots, copying, misuse, reuse, or resale of any content from this app, is strictly prohibited. Our app monitors and records all screenshots and recordings. Violators will face strict legal action.

## DENTURE TROUBLESHOOTING

### 2) Complaints related to difficulty in speaking:

#### c) Creases at corners of mouth

Symptoms/clinical findings	Cause	Treatment
Creases at corners of mouth	Labial fullness and anterior tooth position may be inaccurate. OVD may be inadequate	Adjust tooth position as appropriate. If OVD problem, re-register jaw relations

#### d) Too much visibility of the teeth

Symptoms/clinical findings	Cause	Treatment
Too much visibility of teeth	Level of occlusal plane unacceptable, teeth placed on upper anterior ridge and no/poor lip support	Accurate prescription to laboratory via optimally adjusted occlusal rim

#### e) Unnatural color of denture base material

Symptoms/clinical findings	Cause	Treatment
Colour of denture base material 'unnatural'	Patient's skin colour not taken into account in determining colour of base material	Remake using suitable base material

DISCLAIMER

THIS IS COPYRIGHTED CONTENT. Unauthorized use, including screenshots, copying, misuse, reuse, or resale of any content from this app, is strictly prohibited. Our app monitors and records all screenshots and recordings. Violators will face strict legal action.

THIS IS COPYRIGHTED CONTENT. Unauthorized use, including screenshots, copying, misuse, reuse, or resale of any content from this app, is strictly prohibited. Our app monitors and records all screenshots and recordings. Violators will face strict legal action.

THIS IS COPYRIGHTED CONTENT. Unauthorized use, including screenshots, copying, misuse, reuse, or resale of any content from this app, is strictly prohibited. Our app monitors and records all screenshots and recordings. Violators will face strict legal action.

THIS IS COPYRIGHTED CONTENT. Unauthorized use, including screenshots, copying, misuse, reuse, or resale of any content from this app, is strictly prohibited. Our app monitors and records all screenshots and recordings. Violators will face strict legal action.

DISCLAIMER

THIS IS COPYRIGHTED CONTENT. Unauthorized use, including screenshots, copying, misuse, reuse, or resale of any content from this app, is strictly prohibited. Our app monitors and records all screenshots and recordings. Violators will face strict legal action.

DISCLAIMER

THIS IS COPYRIGHTED CONTENT. Unauthorized use, including screenshots, copying, misuse, reuse, or resale of any content from this app, is strictly prohibited. Our app monitors and records all screenshots and recordings. Violators will face strict legal action.

## FPD FAILURES, CHIPPINGS AND REPAIRS

Source: Article on Classification system for conventional crown and fixed partial denture failures John Joy Manappallil, MDSa Jahra Dental Center, Ministry of Health, Kuwait | Provisional Repair of a Zirconia Fixed Partial Denture with Fibre-Reinforced Restorative Composite: A Clinical Report | Intraoral Repair of All Ceramic Fixed Partial Denture Utilizing Preimpregnated Fiber Reinforced Composite | Repair, Don't Replace – Part 1: Resurfacing an Existing Porcelain Fused to Metal Restoration with a Porcelain Veneer

- Fixed prosthodontic failures can be frustrating and complex in terms of both diagnosis and treatment.
- When a crown or a FPD fails the primary question is whether the problem can be easily resolved, or requires extensive rehabilitation and reconstruction
- A mild failure may be considered one that is generally correctable without having to remake the restoration. More severe failures can result in the loss of supporting teeth.
- When a problem occurs, the design and condition of the restoration and associated structures must be considered which will determine whether the problem can be resolved by intraoral or extraoral adjustment or repair, or by replacement of restoration.

A classification of different types conventional fixed prosthodontic failure based on the severity is given below:

- It can be classified into 6 categories with severity increasing from Class I To Class VI

TABLE I. Grading of failures based on severity

Class	Description
Class I	Cause of failure is correctable without replacing restoration.
Class II	Cause of failure is correctable without replacing restoration; however, supporting tooth structure or foundation requires repair or reconstruction.
Class III	Failure requiring restoration replacement only. Supporting tooth structure and/or foundation acceptable.
Class IV	Failure requiring restoration replacement in addition to repair or reconstruction of supporting tooth structure and/or foundation.
Class V	Severe failure with loss of supporting tooth or inability to reconstruct using original tooth support. Fixed prosthodontic replacement remains possible through use of other or additional support for redesigned restoration.
Class VI	Severe failure with loss of supporting tooth or inability to reconstruct using original tooth support. Conventional fixed prosthodontic replacement is not possible.

DISCLAIMER

THIS IS COPYRIGHTED CONTENT. Unauthorized use, including screenshots, copying, misuse, or resale of any content from this app, is strictly prohibited. Our app monitors and records all screenshots and recordings. Violators will face strict legal action.

DISCLAIMER  
THIS IS COPYRIGHTED CONTENT. Unauthorized use, including screenshots, copying, misuse, or resale of any content from this app, is strictly prohibited. Our app monitors and records all screenshots and recordings. Violators will face strict legal action.

DISCLAIMER

THIS IS COPYRIGHTED CONTENT. Unauthorized use, including screenshots, copying, misuse, reuse, or resale of any content from this app, is strictly prohibited. Our app monitors and records all screenshots and recordings. Violators will face strict legal action.

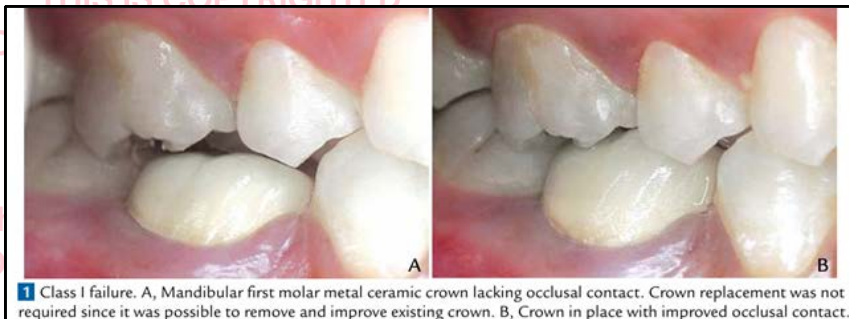


## FPD FAILURES, CHIPPINGS AND REPAIRS

Source: Article on Classification system for conventional crown and fixed partial denture failures John Joy Manappallil, MDSa Jahra Dental Center, Ministry of Health, Kuwait | Provisional Repair of a Zirconia Fixed Partial Denture with Fibre-Reinforced Restorative Composite: A Clinical Report | Intraoral Repair of All Ceramic Fixed Partial Denture Utilizing Preimpregnated Fiber Reinforced Composite | Repair, Don't Replace – Part 1: Resurfacing an Existing Porcelain Fused to Metal Restoration with a Porcelain Veneer

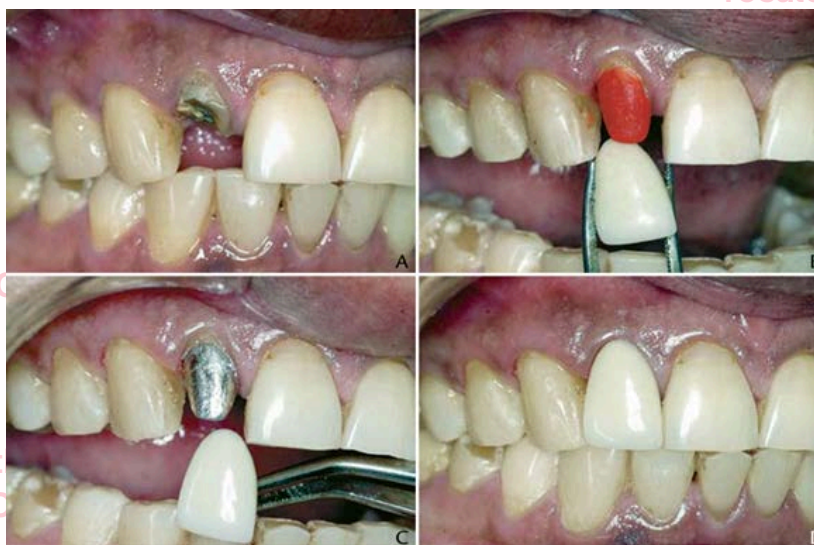### a) Class I FPD Failures:

- Class I failures are correctable through occlusal adjustment or composite resin repairs without requiring replacement of the restoration.
- An example for Class I failure would be decementation of Crown or FPD due to loss of cement bond that is not related to design flaw.
- If the restoration resists removal attempts and has to be sectioned for removal, or if either the restoration or tooth support is damaged during the process, the problem would be reclassified into a higher order of failure.



### b) Class II FPD failure:

- In Class II failure the restoration itself is acceptable but the supporting tooth structure or foundation (core restoration or post and core) requires repair or reconstruction.
- Examples of Class II failures are foundation failures and loss of supporting tooth structure resulting from caries or fracture. Fractures can also occur during attempts to remove a restoration.



2 Class II failure. A, Fracture involving endodontically treated lateral incisor restored with complete crown. B, Acrylic resin post-and-core pattern custom made to fit existing crown. C, Cast post and core cemented into remaining tooth structure. D, Original crown cemented in place.

DISCLAIMER

THIS IS COPYRIGHTED CONTENT. Unauthorized use, including screenshots, copying, misuse, reuse, or resale of any content from this app, is strictly prohibited. Our app monitors and records all screenshots and recordings. Violators will face strict legal action.

DISCLAIMER

THIS IS COPYRIGHTED CONTENT. Unauthorized use, including screenshots, copying, misuse, reuse, or resale of any content from this app, is strictly prohibited. Our app monitors and records all screenshots and recordings. Violators will face strict legal action.

DISCLAIMER

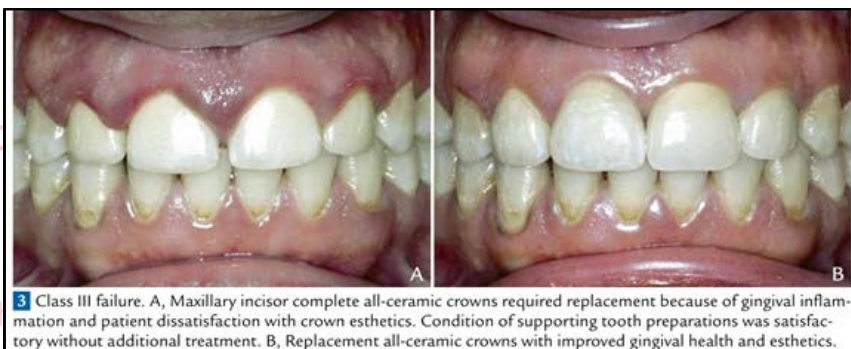
THIS IS COPYRIGHTED CONTENT. Unauthorized use, including screenshots, copying, misuse, reuse, or resale of any content from this app, is strictly prohibited. Our app monitors and records all screenshots and recordings. Violators will face strict legal action.

## FPD FAILURES, CHIPPINGS AND REPAIRS

Source: Article on Classification system for conventional crown and fixed partial denture failures John Joy Manappallil, MDSa Jahra Dental Center, Ministry of Health, Kuwait | Provisional Repair of a Zirconia Fixed Partial Denture with Fibre-Reinforced Restorative Composite: A Clinical Report | Intraoral Repair of All Ceramic Fixed Partial Denture Utilizing Preimpregnated Fiber Reinforced Composite | Repair, Don't Replace – Part 1: Resurfacing an Existing Porcelain Fused to Metal Restoration with a Porcelain Veneer

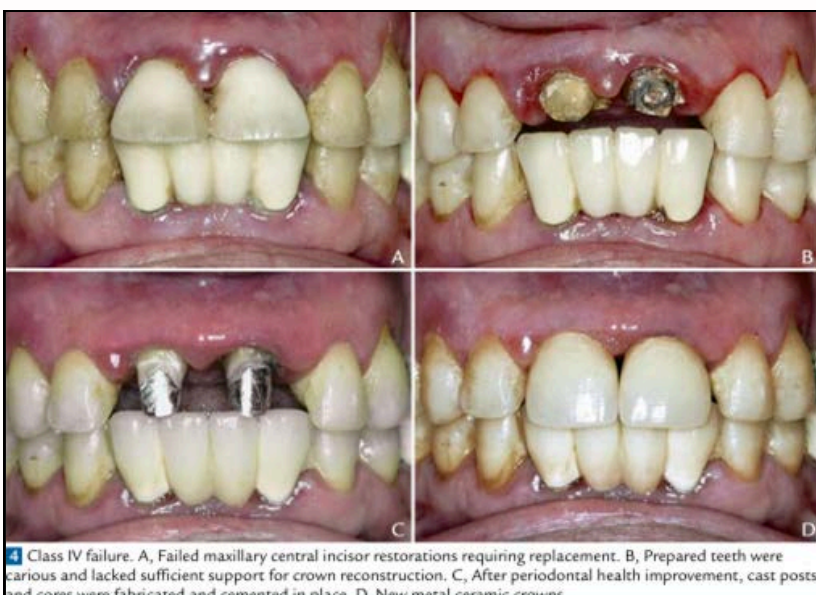### c) Class III Failure:

- For Class III failure replacement of restoration is required, however, the supporting tooth structure or foundation remains intact and would provide acceptable support for a replacement restoration.
- It includes unserviceable restorations due to defective margins, technical failures, or esthetic considerations.



### d) Class IV Failure:

- In Class IV situations, the restoration requires replacement, and the supporting tooth structure or foundation is deficient.
- Before making a new restoration, the tooth structure must be reinforced, reconstructed, or replaced.



DISCLAIMER

THIS IS COPYRIGHTED CONTENT. Unauthorized use, including screenshots, copying, misuse, reuse, or resale of any content from this app, is strictly prohibited. Our app monitors and records all screenshots and recordings. Violators will face strict legal action.

DISCLAIMER  
THIS IS COPYRIGHTED CONTENT. Unauthorized use, including screenshots, copying, misuse, reuse, or resale of any content from this app, is strictly prohibited. Our app monitors and records all screenshots and recordings. Violators will face strict legal action.

DISCLAIMER

THIS IS COPYRIGHTED CONTENT. Unauthorized use, including screenshots, copying, misuse, reuse, or resale of any content from this app, is strictly prohibited. Our app monitors and records all screenshots and recordings. Violators will face strict legal action.

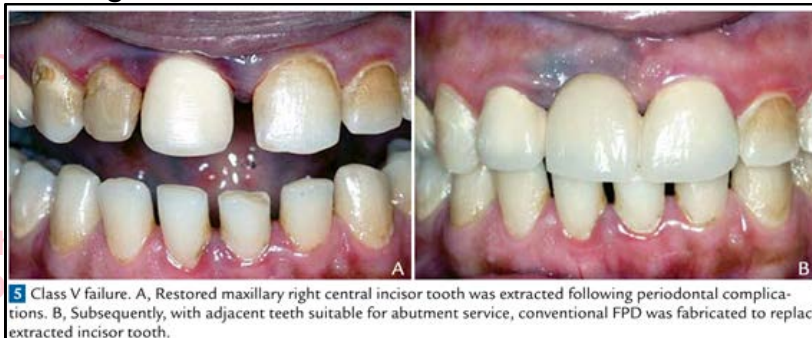

## FPD FAILURES, CHIPPINGS AND REPAIRS

Source: Article on Classification system for conventional crown and fixed partial denture failures John Joy Manappallil, MDSa Jahra Dental Center, Ministry of Health, Kuwait | Provisional Repair of a Zirconia Fixed Partial Denture with Fibre-Reinforced Restorative Composite: A Clinical Report | Intraoral Repair of All Ceramic Fixed Partial Denture Utilizing Preimpregnated Fiber Reinforced Composite | Repair, Don't Replace – Part 1: Resurfacing an Existing Porcelain Fused to Metal Restoration with a Porcelain Veneer

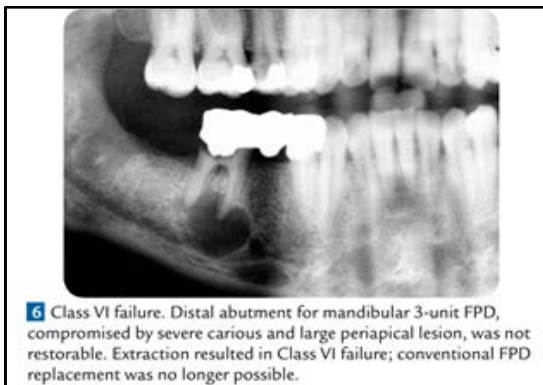
### e) Class V Failure:

- In a Class V failure, support structures can no longer provide adequate support for the existing restoration due to extensive fracture, carious destruction, periodontal problems, or other complications.
- A damaged tooth may require extraction. Even though the failure may involve tooth loss, restoration of the site with a conventional fixed prosthesis remains a reasonable option when other available teeth can be incorporated into the redesigned restoration.



### f) Class VI Failure

- A Class VI failure is the most severe failure; in this situation, a conventional fixed replacement is no longer possible because of supporting tooth failure and the lack of additional support for use in a redesigned restoration.



DISCLAIMER

THIS IS COPYRIGHTED CONTENT. Unauthorized use, including screenshots, copying, misuse, reuse, or resale of any content from this app, is strictly prohibited. Our app monitors and records all screenshots and recordings. Violators will face strict legal action.

DISCLAIMER  
THIS IS COPYRIGHTED CONTENT. Unauthorized use, including screenshots, copying, misuse, reuse, or resale of any content from this app, is strictly prohibited. Our app monitors and records all screenshots and recordings. Violators will face strict legal action.

DISCLAIMER

THIS IS COPYRIGHTED CONTENT. Unauthorized use, including screenshots, copying, misuse, reuse, or resale of any content from this app, is strictly prohibited. Our app monitors and records all screenshots and recordings. Violators will face strict legal action.



## FPD FAILURES, CHIPPINGS AND REPAIRS

Source: Article on Classification system for conventional crown and fixed partial denture failures John Joy Manappallil, MDSa Jahra Dental Center, Ministry of Health, Kuwait | Provisional Repair of a Zirconia Fixed Partial Denture with Fibre-Reinforced Restorative Composite: A Clinical Report | Intraoral Repair of All Ceramic Fixed Partial Denture Utilizing Preimpregnated Fiber Reinforced Composite | Repair, Don't Replace – Part 1: Resurfacing an Existing Porcelain Fused to Metal Restoration with a Porcelain Veneer

### Cause of Fixed partial prosthesis Failures:

- The cause of failure is usually multifactorial.
- Fractures associated with Ceramic infused to metal crowns and bridges (PFM) and even all ceramic crowns and bridges is encountered in dental practice. The reason for such failure is repeated stress and strains during chewing function or trauma.
- The prevalence of ceramic fracture ranged from 5 to 10 % over 10 years of use.
- The most frequent reasons for ceramic failures are related to cracks within the ceramic.
- When crowns are cemented intraorally factors other than inherent mechanical strength of the materials come into play. Under continuous mechanical environmental loads, progressive degradation may lead to crack initiation and growth ultimately causing catastrophic failure of the restoration.

### Factors affecting failure of metal ceramic restorations:

- Differences in modulus and thermal expansion between metal and ceramic materials.
- Stress development at the interface due to mismatched properties.
- Environmental Factors includes material weakening due to exposure to moisture. Structural integrity of the materials is affected by change in the oral cavity environments.
- Cyclic stresses (e.g., chewing, mastication) causing crack initiation and propagation. Stress concentration occurs at sharp notches or flaws in the material.
- Microcracks, voids, and inclusions in ceramics leads to structural weakness.
- Incompatibility between thermal coefficients of ceramic and metal layers also contributes to it.
- Errors during restoration preparation, such as uneven firing or inadequate thickness also affects the ceramic integrity. Voids in cement layers or improper design reduces restoration longevity.
- Poor preparation design and insufficient support for the restoration leads to improper occlusion causing undue stresses.
- Misjudgment in treatment planning and restoration placement and lack of clinical skill in avoiding stress concentration areas can also be a factor influencing failures.

DISCLAIMER

THIS IS COPYRIGHTED CONTENT. Unauthorized use, including screenshots, copying, misuse, or resale of any content from this app, is strictly prohibited. Our app monitors and records all screenshots and recordings. Violators will face strict legal action.

DISCLAIMER

THIS IS COPYRIGHTED CONTENT. Unauthorized use, including screenshots, copying, misuse, or resale of any content from this app, is strictly prohibited. Our app monitors and records all screenshots and recordings. Violators will face strict legal action.

DISCLAIMER

THIS IS COPYRIGHTED CONTENT. Unauthorized use, including screenshots, copying, misuse, or resale of any content from this app, is strictly prohibited. Our app monitors and records all screenshots and recordings. Violators will face strict legal action.

## FPD FAILURES, CHIPPINGS AND REPAIRS

Source: Article on Classification system for conventional crown and fixed partial denture failures John Joy Manappallil, MDSa Jahra Dental Center, Ministry of Health, Kuwait | Provisional Repair of a Zirconia Fixed Partial Denture with Fibre-Reinforced Restorative Composite: A Clinical Report | Intraoral Repair of All Ceramic Fixed Partial Denture Utilizing Preimpregnated Fiber Reinforced Composite | Repair, Don't Replace – Part 1: Resurfacing an Existing Porcelain Fused to Metal Restoration with a Porcelain Veneer

### Repair procedures for Fixed Prosthesis

- All ceramic restorations (like Zirconia) have increasing popularity in recent years due to their esthetic appearance and metal free structure with high flexural strength and low degree of bacterial adhesion.
- Although zirconia has high fracture strength, fractures may still occur after cementation of the restoration. If the fractured restoration is fulfilling its requirements and replacement is not feasible, repair is indicated.
- Intraoral repair, if possible, is the first choice.
- Intraoral repair systems provide the possibility of repairing the FPD directly in the patients' mouth and prevent the replacement of the complete restoration.
- Mostly, particulate filler composites (PFC) are employed in intraoral repairs due to the esthetic properties and ease of application. However, the success is limited because PFC cannot resist the high-tension forces. Fiber-reinforced composites (FRC)s have been used to increase the mechanical properties of restorations without compromising the esthetic properties.
- Fiber reinforced composite have the ability to withstand tensile stresses and stop crack propagation at the adhesive interfaces.
- Although 3-unit zirconia bridges have shown high fracture resistance, the use of this material for a longer span FPD is limited.
- Fractures may result from trauma, inadequate occlusal adjustment, parafunctional habits such as bruxism, inadequate tooth reduction during dental preparation, inappropriate design or failure of the cementation.
- The structure of a zirconia framework is also important in terms of strength of the restoration. A framework design allowing uniform thickness and support of veneering porcelain optimizes the strength of zirconia.

### Steps in fracture repair process

- 1) Connector fracture is the primary reason of failure in all-ceramic FPDs failure modes.
- 2) The primary mode of failure for long span zirconia bridge is also fracture, usually in the area between the retainer and pontic, originating from the gingival surface of the connectors under high tensile stress, resulting in catastrophic loss
- 3) Repair methods may be classified into 2 types, the direct method and the indirect method.
  - a) **Direct repairs** include techniques that use composites applied directly to the fractured restoration, Direct intraoral repair of fractured porcelain traditionally relied on mechanical roughening of the fractured surface, followed by application of a silane coupling agent to enhance the resin-to-porcelain bond.

#### DISCLAIMER

THIS IS COPYRIGHTED CONTENT. Unauthorized use, including screenshots, copying, misuse, reuse, or resale of any content from this app, is strictly prohibited. Our app monitors and records all screenshots and recordings. Violators will face strict legal action.

#### DISCLAIMER

THIS IS COPYRIGHTED CONTENT. Unauthorized use, including screenshots, copying, misuse, reuse, or resale of any content from this app, is strictly prohibited. Our app monitors and records all screenshots and recordings. Violators will face strict legal action.

THIS IS COPYRIGHTED CONTENT. Unauthorized use, including screenshots, copying, misuse, reuse, or resale of any content from this app, is strictly prohibited. Our app monitors and records all screenshots and recordings. Violators will face strict legal action.

## FPD FAILURES, CHIPPINGS AND REPAIRS

Source: Article on Classification system for conventional crown and fixed partial denture failures John Joy Manappallil, MDSa Jahra Dental Center, Ministry of Health, Kuwait | Provisional Repair of a Zirconia Fixed Partial Denture with Fibre-Reinforced Restorative Composite: A Clinical Report | Intraoral Repair of All Ceramic Fixed Partial Denture Utilizing Preimpregnated Fiber Reinforced Composite | Repair, Don't Replace – Part 1: Resurfacing an Existing Porcelain Fused to Metal Restoration with a Porcelain Veneer

### Steps in fracture repair process

- 1) Connector fracture is the primary reason of failure in all-ceramic FPDs failure modes.
- 2) The primary mode of failure for long span zirconia bridge is also fracture, usually in the area between the retainer and pontic, originating from the gingival surface of the connectors under high tensile stress, resulting in catastrophic loss
- 3) Repair methods may be classified into 2 types, the direct method and the indirect method.
  - a) **Direct repairs** include techniques that use composites applied directly to the fractured restoration. Direct intraoral repair of fractured porcelain traditionally relied on mechanical roughening of the fractured surface, followed by application of a silane coupling agent to enhance the resin-to-porcelain bond.
  - b) **Indirect repairs** include those that use porcelain that is applied as a laboratory procedure and is bonded to the fractured restoration. Various methods of repairing fractured porcelain with composite have been reported.
  - c) The primary advantages of using composites for repair are less chair time, lower cost, and ease of application. The limitation of low strength and poor wear qualities are mitigated with the use of fiber reinforced composite.
  - d) One method of intraoral repair for zirconia bridge fractured between the pontic includes preparing the cavity, etching, sandblasting, silanizing and applying dual-adhesive resin cement and glass-fibre-reinforced composite.

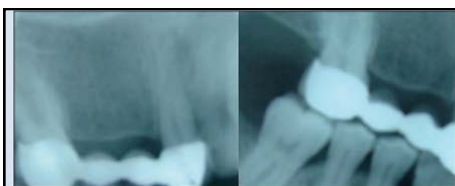

Figure 1: Radiographic view of the fractured bridge.

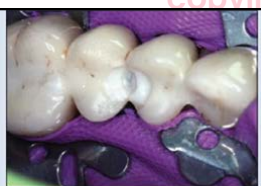

Figure 2: Clinical view of the fractured bridge showing the prepared cavity.

- e) It has been reported that roughening the surface of exposed metal or ceramics, using a combination of sandblasting and hydrofluoric acid gives the best results. High-alumina or zirconia ceramics cannot be roughened by etching as these materials do not contain a silicon dioxide (silica) phase. And in practice, etching may only be useful to remove the smear layer in ceramics.

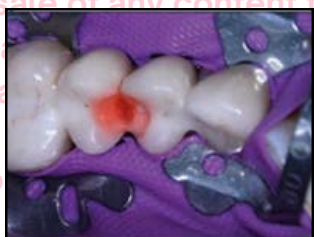

Figure 3: Acid etching material coating the cavity.

### DISCLAIMER

THIS IS COPYRIGHTED CONTENT. Unauthorized use, including screenshots, copying, misuse, reuse, or resale of any content from this app, is strictly prohibited. Our app monitors and records all screenshots and recordings. Violators will face strict legal action.

### DISCLAIMER

THIS IS COPYRIGHTED CONTENT. Unauthorized use, including screenshots, copying, misuse, reuse, or resale of any content from this app, is strictly prohibited. Our app monitors and records all screenshots and recordings. Violators will face strict legal action.

### DISCLAIMER

THIS IS COPYRIGHTED CONTENT. Unauthorized use, including screenshots, copying, misuse, reuse, or resale of any content from this app, is strictly prohibited. Our app monitors and records all screenshots and recordings. Violators will face strict legal action.

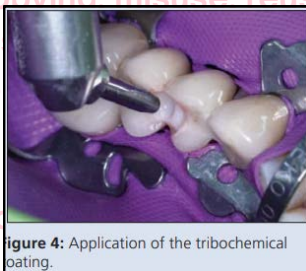

## FPD FAILURES, CHIPPINGS AND REPAIRS

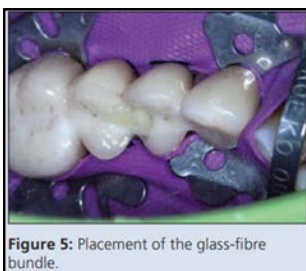
Source: Article on Classification system for conventional crown and fixed partial denture failures John Joy Manappallil, MDSa Jahra Dental Center, Ministry of Health, Kuwait | Provisional Repair of a Zirconia Fixed Partial Denture with Fibre-Reinforced Restorative Composite: A Clinical Report | Intraoral Repair of All Ceramic Fixed Partial Denture Utilizing Preimpregnated Fiber Reinforced Composite | Repair, Don't Replace – Part 1: Resurfacing an Existing Porcelain Fused to Metal Restoration with a Porcelain Veneer

### Steps in fracture repair process

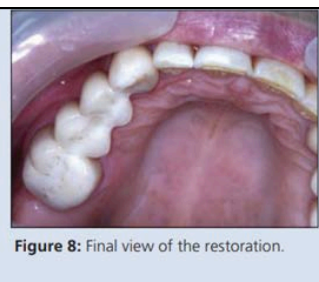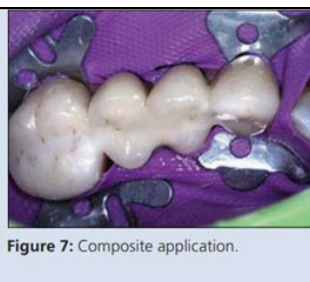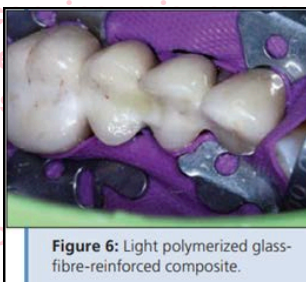
- 3) Repair methods may be classified into 2 types, the direct method and the indirect method.
  - f) Surface conditioning can be also done using Aluminium oxide coated silica particles with silane application as silica coating with silanization increases bond strength significantly for all high-strength ceramics compared with airborne particle abrasion with (aluminium oxide)  $Al_2O_3$  and silanization.
  - g) After the etching and abrasion process, a silane coupling agent should be applied to the surface cavity to improve the bonding strength of the resin-based material which will be applied to the cavity. (Tribochemical silica coating followed by silanization increases the silica content of the ceramic surface)



- h) Unidirectional glass fiber material can be used for the mechanical support of the repair.



- i) The strength of the repair depends on the quantity of glass fibre, the direction of the fibres and their attachment to the ceramic.
- j) A dual adhesive resin cement can be flowed through the fracture area that fills the space between the fracture pieces.
- k) Repaired restoration should be resistant to fatigue.



### DISCLAIMER

THIS IS COPYRIGHTED CONTENT. Unauthorized use, including screenshots, copying, misuse, reuse, or resale of any content from this app, is strictly prohibited. Our app monitors and records all screenshots and recordings. Violators will face strict legal action.

### DISCLAIMER

THIS IS COPYRIGHTED CONTENT. Unauthorized use, including screenshots, copying, misuse, reuse, or resale of any content from this app, is strictly prohibited. Our app monitors and records all screenshots and recordings. Violators will face strict legal action.

THIS IS COPYRIGHTED CONTENT. Unauthorized use, including screenshots, copying, misuse, reuse, or resale of any content from this app, is strictly prohibited. Our app monitors and records all screenshots and recordings. Violators will face strict legal action.

## FPD FAILURES, CHIPPINGS AND REPAIRS

Source: Article on Classification system for conventional crown and fixed partial denture failures John Joy Manappallil, MDSa Jahra Dental Center, Ministry of Health, Kuwait | Provisional Repair of a Zirconia Fixed Partial Denture with Fibre-Reinforced Restorative Composite: A Clinical Report | Intraoral Repair of All Ceramic Fixed Partial Denture Utilizing Preimpregnated Fiber Reinforced Composite | Repair, Don't Replace – Part 1: Resurfacing an Existing Porcelain Fused to Metal Restoration with a Porcelain Veneer

**An example of intraoral repair of distal connector fracture of the three-unit heat-pressed lithium disilicate-reinforced glass ceramic FPD is provided below:**

- 1) In the given example Two all-ceramic FPDs were constructed because of missing lateral incisors but canines were in lateral incisors position. The abutment teeth and the all ceramic FPD units both were in good condition except the fractured connector. The pontic was disconnected from the distal crown and additionally luting cement was detached from the mesial abutment tooth 22, the crown and the still attached pontic was removed from the mesial abutment tooth.

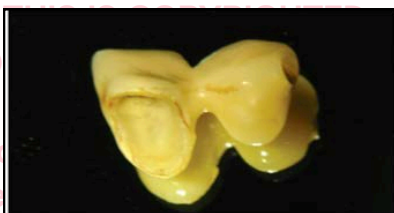

Figure 1. The mesial retainer crown and the pontic separated from the distal crown because of connector fracture.

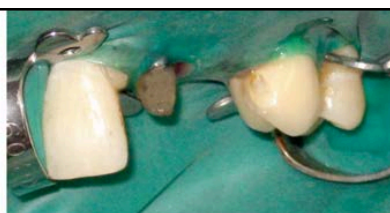

Figure 2. The isolated restoration area utilizing rubber-dam.

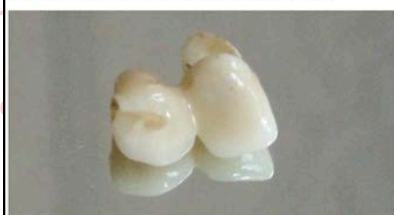

Figure 3. Groove formed on the palatal side of the pontic.

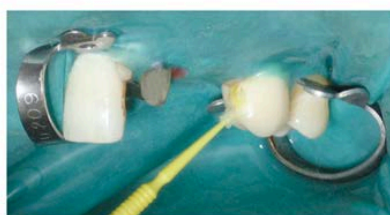

Figure 4. The grooves were acid etched with 9 % hydrofluoric acid and silane coupling agent was applied.

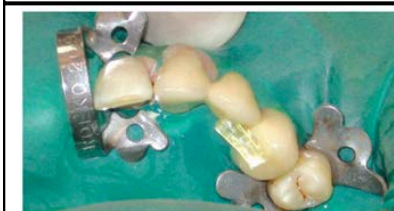

Figure 5. FRC was cut 0,5 mm short of finish line of grooves.

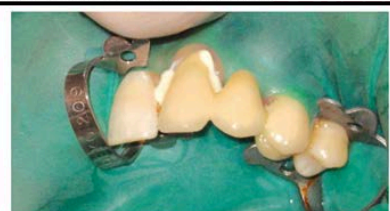

Figure 6. The mesial retainer crown cemented on the mesial abutment tooth.

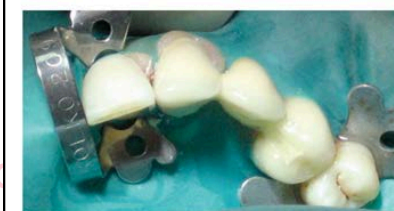

Figure 7. FRC adapted in the grooves utilizing transparent silicone block.

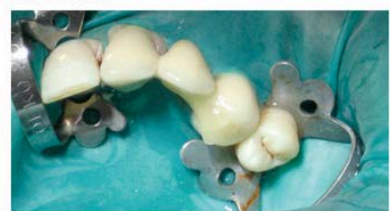

Figure 8. The restored area was covered with flowable composite.

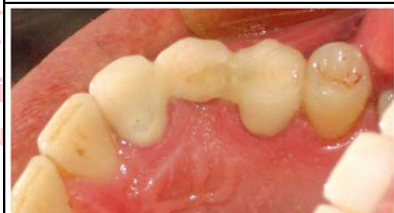

Figure 9. Occlusal view of the restored area after finishing and polishing procedures.

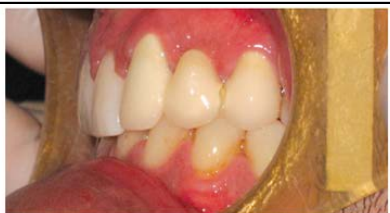

Figure 10. Facial view of the restored area after 3 weeks.

DISCLAIMER

THIS IS COPYRIGHTED CONTENT. Unauthorized use, including screenshots, copying, misuse, reuse, or resale of any content from this app, is strictly prohibited. Our app monitors and records all screenshots and recordings. Violators will face strict legal action.

DISCLAIMER

THIS IS COPYRIGHTED CONTENT. Unauthorized use, including screenshots, copying, misuse, reuse, or resale of any content from this app, is strictly prohibited. Our app monitors and records all screenshots and recordings. Violators will face strict legal action.

DISCLAIMER

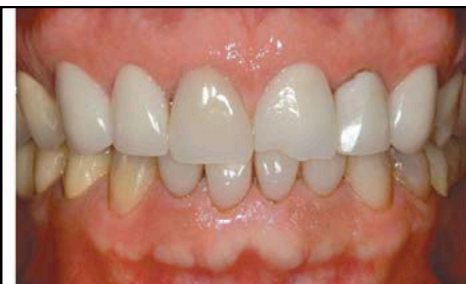THIS IS COPYRIGHTED CONTENT. Unauthorized use, including screenshots, copying, misuse, reuse, or resale of any content from this app, is strictly prohibited. Our app monitors and records all screenshots and recordings. Violators will face strict legal action.



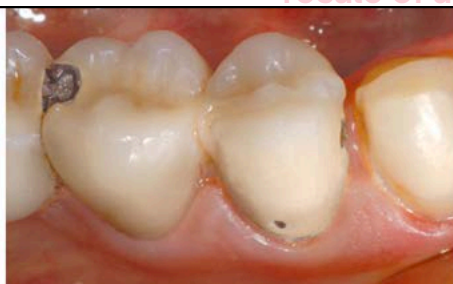## FPD FAILURES, CHIPPINGS AND REPAIRS

Source: Article on Classification system for conventional crown and fixed partial denture failures John Joy Manappallil, MDSa Jahra Dental Center, Ministry of Health, Kuwait | Provisional Repair of a Zirconia Fixed Partial Denture with Fibre-Reinforced Restorative Composite: A Clinical Report | Intraoral Repair of All Ceramic Fixed Partial Denture Utilizing Preimpregnated Fiber Reinforced Composite | Repair, Don't Replace – Part 1: Resurfacing an Existing Porcelain Fused to Metal Restoration with a Porcelain Veneer

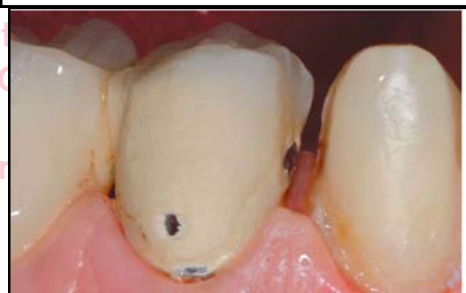### An example of intraoral repair of existing porcelain restoration.



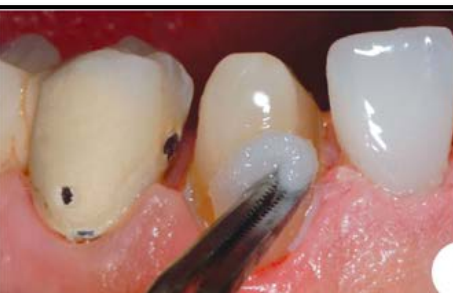**Figure 1:** A smile in need of a remake. The patient requested a porcelain makeover of the esthetic zone with occlusal corrections to prevent future porcelain fracture. The posterior bridgework is clinically acceptable; however, the anterior abutments in the esthetic zone will require resurfacing to match the anterior units.



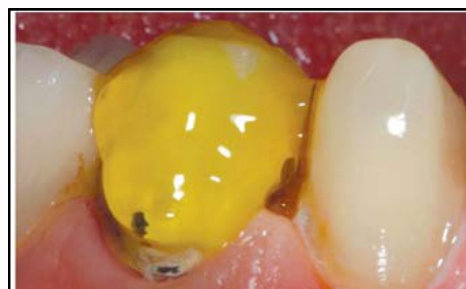**Figure 2:** Preparations for porcelain veneers on teeth #27 and #28. The small metal exposures will not appreciably affect the bond of the veneers to the porcelain surface.



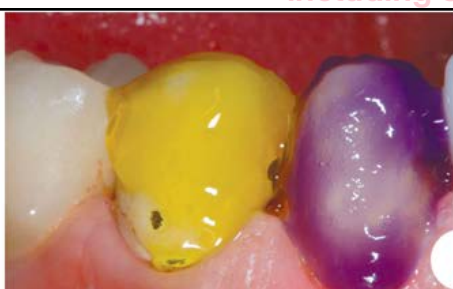**Figure 3:** A 2x magnified facial view of the veneer preparations.



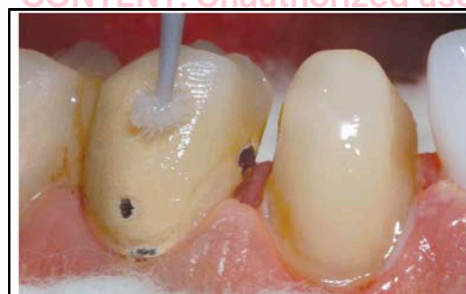**Figure 4:** A dentin desensitizer with antibacterial agent (AcquaSeal B [AcquaMed Technologies]) is applied to cleanse the prepared tooth surface prior to the etching procedure.



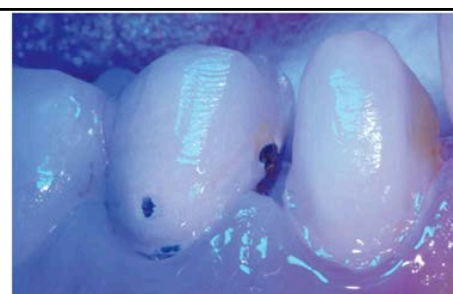**Figure 5:** Hydrofluoric acid is used to etch the porcelain preparation.



**Figure 6:** Phosphoric acid is used to etch the prepared tooth surface.



**Figure 9:** Bonding resin is applied to both prepared surfaces.



**Figure 10:** Bonding resin is light-cured for 30 seconds.

DISCLAIMER

THIS IS COPYRIGHTED CONTENT. Unauthorized use, including screenshots, copying, misuse, reuse, or resale of any content from this app, is strictly prohibited. Our app monitors and records all screenshots and recordings. Violators will face strict legal action.

DISCLAIMER

THIS IS COPYRIGHTED CONTENT. Unauthorized use, including screenshots, copying, misuse, reuse, or resale of any content from this app, is strictly prohibited. Our app monitors and records all screenshots and recordings. Violators will face strict legal action.

DISCLAIMER

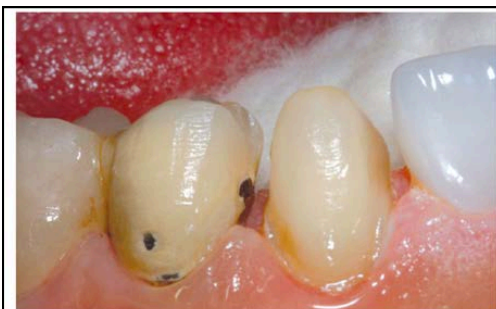THIS IS COPYRIGHTED CONTENT. Unauthorized use, including screenshots, copying, misuse, reuse, or resale of any content from this app, is strictly prohibited. Our app monitors and records all screenshots and recordings. Violators will face strict legal action.



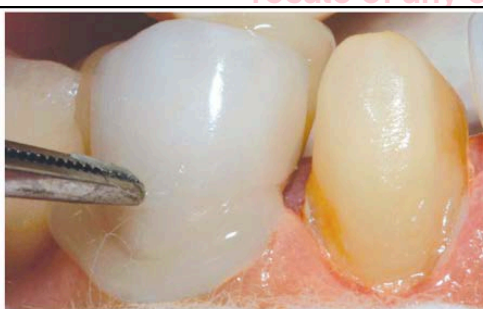## FPD FAILURES, CHIPPINGS AND REPAIRS

Source: Article on Classification system for conventional crown and fixed partial denture failures John Joy Manappallil, MDSa Jahra Dental Center, Ministry of Health, Kuwait | Provisional Repair of a Zirconia Fixed Partial Denture with Fibre-Reinforced Restorative Composite: A Clinical Report | Intraoral Repair of All Ceramic Fixed Partial Denture Utilizing Preimpregnated Fiber Reinforced Composite | Repair, Don't Replace – Part 1: Resurfacing an Existing Porcelain Fused to Metal Restoration with a Porcelain Veneer

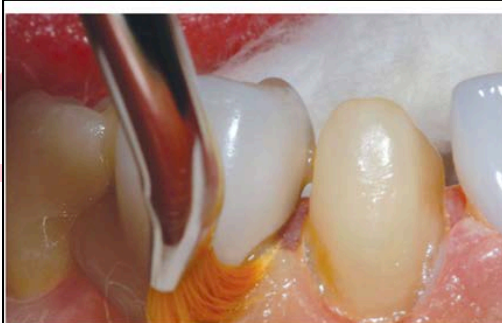### An example of intraoral repair of existing porcelain restoration.



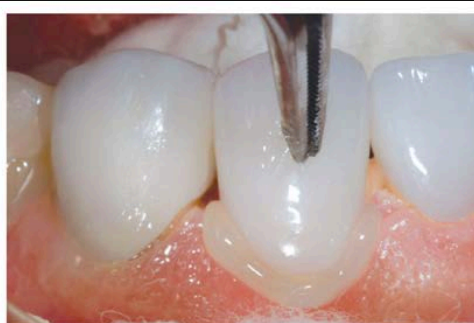**Figure 11:** Facial view of the prepared surfaces after curing of the adhesive resin. Note the shiny appearance of both the dentin and porcelain surfaces. This clinically shows the presence of the hybrid zone for bonding.



**Figure 12:** The porcelain veneer for tooth #28 is filled with resin cement and placed on the preparation.



**Figure 13:** The excess resin cement can be removed with a Keystone brush.



**Figure 14:** The restoration is placed on tooth #27.

DISCLAIMER

THIS IS COPYRIGHTED CONTENT. Unauthorized use, including screenshots, copying, misuse, reuse, or resale of any content from this app, is strictly prohibited. Our app monitors and records all screenshots and recordings. Violators will face strict legal action.

THIS IS COPYRIGHTED CONTENT. Unauthorized use, including screenshots, copying, misuse, reuse, or resale of any content from this app, is strictly prohibited. Our app monitors and records all screenshots and recordings. Violators will face strict legal action.

DISCLAIMER

THIS IS COPYRIGHTED CONTENT. Unauthorized use, including screenshots, copying, misuse, reuse, or resale of any content from this app, is strictly prohibited. Our app monitors and records all screenshots and recordings. Violators will face strict legal action.

DISCLAIMER

THIS IS COPYRIGHTED CONTENT. Unauthorized use, including screenshots, copying, misuse, reuse, or resale of any content from this app, is strictly prohibited. Our app monitors and records all screenshots and recordings. Violators will face strict legal action.

THIS IS COPYRIGHTED CONTENT. Unauthorized use, including screenshots, copying, misuse, reuse, or resale of any content from this app, is strictly prohibited. Our app monitors and records all screenshots and recordings. Violators will face strict legal action.

# IMPRESSION TECHNIQUES AND MATERIALS

Source: Articles and Text Books

- An impression is an imprint or negative likeness mouth. From this negative form of the teeth and surrounding structures, a positive reproduction, or cast, is made.
- Impression is a negative likeness or copy in reverse of the surface of an object; an imprint of the teeth and adjacent structures for use in dentistry (GPT-9)
- Impression material is any substance or combination of substances used for making an impression or negative reproduction. (GPT-9)
- Impression technique a method and manner used in making a negative likeness (GPT-4)
- It is made by placing some soft, semi-fluid material in the mouth and allowing the material to set.
- Depending on the material used the set impression can either be hard or elastic.

## Classification of impression materials

### 1) Non-elastic impression materials:

- a) Impression compound.
- b) Impression plaster.
- c) Zinc-oxide eugenol paste: It is an irreversible nonelastic material. It records the tissues in the undistorted state. It can be used as Wash impressions (secondary impression) in complete denture fabrication and dual impression in distal extensions partial dentures. It is a brittle material so cannot be used in dentulous mouths or severe undercuts areas.

### 2) Elastic impression materials:

#### a) Hydrocolloids (water-based systems):

- Reversible hydrocolloids (agar impression material): Agar -agar gives us accurate details but it needs special tray and extra equipment so most of the dentists don't use this type of materials although it has accuracy.
- Irreversible hydrocolloids (alginate impression material): Alginate is used as a primary impression material. As irreversible hydrocolloid is largely water it readily absorbs liquid (by imbibition) as well as gives off liquid (by syneresis) to the atmosphere, causing distortion of impression. Alginate impression must therefore be poured immediately.

#### b) Elastomers:

- This type of impression set by chemical reaction. Usually is supplied in different consistencies/viscosity that depends on the amount of fillers. These are heavy, medium and light bodied.
- Mostly, heavy body is used as tray material while the light body is used with special plastic syringe to be placed on the preparation.
- Whatever the consistency of the elastic rubber material it is supplied as two containers or tubes (the base and the catalyst).
- It includes:
  1. Polysulfide.
  2. Condensation silicone.
  3. Polyether.
  4. Addition silicone.

## DISCLAIMER

THIS IS COPYRIGHTED CONTENT. Unauthorized use, including screenshots, copying, misuse, reuse, or resale of any content from this app, is strictly prohibited. Our app monitors and records all screenshots and recordings. Violators will face strict legal action.

# IMPRESSION TECHNIQUES AND MATERIALS

Source: Articles and Text Books

## Various Impression techniques

- 1) **Mucostatic impression technique:** The impression is made with oral mucous membrane and the jaws in relaxed condition. It aims to record the soft tissues in their resting state with minimal pressure. This technique is carried out using impression trays with special characteristics and low-density materials. Mostly used for flabby ridges to record the impression in the non-displaced state.
- 2) **Mucocompressive impression technique:** It records the tissue on its functional and displaced form. Applies pressure to the tissues during impression taking to simulate functional forces.
- 3) **Selective pressure technique:** Applies pressure only to specific areas of the tissue to achieve desired support and stability. In this technique the idea of tissue preservation is combined with mechanical factor of achieving retention through minimal pressure which is within the physiologic limits if tissue preservation. Used for all complete denture cases except for flabby ridges.
- 4) **Single stage (Double Mix) Impression technique:** Mostly used with silicone-based impression material. Uses a single mix of impression material to capture the desired anatomy in one step. This dental impression technique involves taking the impression in a single session:
  - Simultaneously prepare heavy and light viscosity impression materials.
  - Draw the wash material into a syringe.
  - Apply the wash material to all surfaces, starting from the distal of the preparation area.
  - Apply the prepared putty over the dental arch.
  - Allow both materials to polymerize simultaneously.
- 5) **Two-Stage (Single Mix) Impression Technique:** Involves taking multiple impressions with different viscosities of the same material, often used for complex cases. This technique is often used with silicone impression materials and involves two separate steps:

### First Stage:

- Select and check a suitable stock tray or custom-made tray in the patient's mouth.
- Perform gingival retraction.
- Place heavy-bodied impression material (putty) in the tray and apply over the dental arch.
- Allow the material to set, then remove, wash, and dry the impression.

### Second Stage:

- Create space in the first impression by scraping.
- Remove retraction cords from the patient's mouth.
- Prepare the second, lighter-bodied impression material (wash).
- Place the wash material in the tray and reapply in the mouth.
- After setting, remove, wash, dry, and inspect the final dental impression.

## DISCLAIMER

THIS IS COPYRIGHTED CONTENT. Unauthorized use, including screenshots, copying, misuse, reuse, or resale of any content from this app, is strictly prohibited. Our app monitors and records all screenshots and recordings. Violators will face strict legal action.



# IMPRESSION TECHNIQUES AND MATERIALS

Source: Articles and Text Books

## Various Complete Denture impression techniques for resorbed ridges:

Source- Article On Complete Denture Impression Techniques For Resorbed Ridges: A Review From The Journal Of Prosthetic And Implant Dentistry

### a) Conventional technique:

- The impression is made using the conventional method, that is, zinc oxide eugenol wash impression after border molding with a green stick compound in open mouth position.

### b) Dynamic Impression:

- In extremely resorbed ridges the shape of osseous structures compromises the retention and stability of complete dentures, as muscle attachments are located near the crest of residual ridges the dislocating effect of the muscles on denture is great, hence an accurately recorded impression is necessary
- Mostly Irreversible hydrocolloid materials are used for this impression technique.

### Steps:

- A special tray should be fabricated, which should not interfere with active muscle movement and stabilize the mandible in correct position to maxilla.
- \*Special tray for dynamic impression is fabricated by building up a ridge with self-cure resin in the premolar molar region in each side of the ridge, and while the material is soft the tray is placed in the mouth and patient is asked to close the jaw slowly, the upper residual ridge will form an impression in the soft thermoplastic material at a height corresponding to the rest mandible then, the tray is removed from the mouth and cooled. Lingually the mandibular rests should be concave to provide space for the tongue.

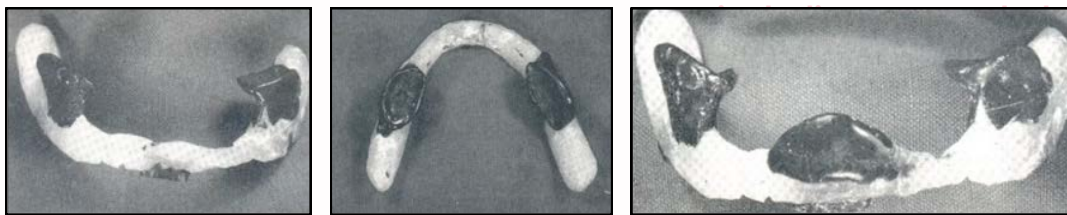


Fig: Special tray Mandibular rest and tongue rest

- Now, sufficient amount of an irreversible hydrocolloid is mixed with 50% extra water and material are placed directly into the mouth to cover all tissues.
- The tray is pressured through alginate by digital force until the stops are firmly seated on the residual ridge.
- Then, the patient is asked to close his mouth slowly until the mandibular rests have obtained firm contact with the maxillae.
- The patient is instructed to swallow, forcefully protrude the lips and vigorously contract the buccinator muscle in between swallowing which will help to record active muscle movements.
- asked to close his mouth slowly until the mandibular rests have obtained firm contact with the maxillae.

### DISCLAIMER

THIS IS COPYRIGHTED CONTENT. Unauthorized use, including screenshots, copying, misuse, reuse, or resale of any content from this app, is strictly prohibited. Our app monitors and records all screenshots and recordings. Violators will face strict legal action.

DISCLAIMER

THIS IS COPYRIGHTED CONTENT. Unauthorized use, including screenshots, copying, misuse, reuse, or resale of any content from this app, is strictly prohibited. Our app monitors and records all screenshots and recordings. Violators will face strict legal action.

DISCLAIMER

THIS IS COPYRIGHTED CONTENT. Unauthorized use, including screenshots, copying, misuse, reuse, or resale of any content from this app, is strictly prohibited. Our app monitors and records all screenshots and recordings. Violators will face strict legal action.

# IMPRESSION TECHNIQUES AND MATERIALS

Source: Articles and Text Books

## Various Complete Denture impression techniques for resorbed ridges:

Source- Article On Complete Denture Impression Techniques For Resorbed Ridges: A Review From The Journal Of Prosthetic And Implant Dentistry

### c) Dynamic Impression second technique:

- The impression is made using the conventional method, that is, zinc oxide eugenol wash impression after border molding with a green stick compound in open mouth position.

### d) Dynamic impression Third technique:

- The denture is first processed on the basis of conventional impression, and then a correcting dynamic impression is made in the denture base to reshape and complete the final design and the denture is relined.

### e) All green technique

- In this technique the mandibular secondary impression is made using green stick tracing compound. Greenstick compound is kneaded to a homogenous mass and loaded on the special tray and border movements done. The final impression is made using zinc oxide eugenol.

### f) Closed mouth functional impression technique

- In this technique, a denture base and occlusal rims are fabricated on the primary cast and tentative jaw relation is done.
- Tissue conditioning material is applied on the tissue surface of mandibular denture base do various functional movements such as puffing, blowing, whistling and smiling.
- Three application of tissue conditioner material is done at an interval of 8–10 minutes.
- The final impression is made with light body addition silicone material with closed mouth technique.

### g) Cocktail impression technique:

- This technique is used for flat mandibular ridges, and for definitive impression.
- In this technique, a customized tray is fabricated according to the dynamic impression technique using auto polymerizing acrylic resin. A tray with cylindrical mandibular rests in the posterior region and 1mm wax spacer is made at increased vertical height.

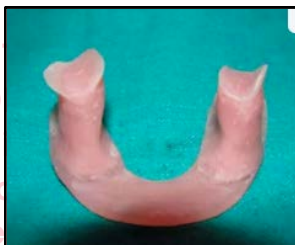

Fig: Specialized tray for Cocktail impression technique, fabricated according to dynamic impression technique.

- The patient is advised to close his mouth so that the mandibular rests fit against the maxillary alveolar ridge like in case of dynamic impression. This helps to stabilize the tray in position. Lingual surfaces of mandibular rests are made concave.

#### DISCLAIMER

THIS IS COPYRIGHTED CONTENT. Unauthorized use, including screenshots, copying, misuse, reuse, or resale of any content from this app, is strictly prohibited. Our app monitors and records all screenshots and recordings. Violators will face strict legal action.

#### DISCLAIMER

THIS IS COPYRIGHTED CONTENT. Unauthorized use, including screenshots, copying, misuse, reuse, or resale of any content from this app, is strictly prohibited. Our app monitors and records all screenshots and recordings. Violators will face strict legal action.

THIS IS COPYRIGHTED CONTENT. Unauthorized use, including screenshots, copying, misuse, reuse, or resale of any content from this app, is strictly prohibited. Our app monitors and records all screenshots and recordings. Violators will face strict legal action.

#### DISCLAIMER

# IMPRESSION TECHNIQUES AND MATERIALS

Source: Articles and Text Books

## Various Complete Denture impression techniques for resorbed ridges:

Source- Article On Complete Denture Impression Techniques For Resorbed Ridges: A Review From The Journal Of Prosthetic And Implant Dentistry

- Impression material and green stick compound are used in the ratio of 3:7, it is kneaded into a homogeneous mass and loaded, then the patient is guided to close his mouth on the mandibular rests.
- To record the functional state, patient is instructed to perform functional movements (run his tongue along his lips, suck in his cheek, pull his lips and swallow by keeping his mouth closed), till impression material hardens.

### h) Elastomeric impression technique:

- In this technique, the mandibular secondary impression is made using elastomeric impression material. Tray adhesive is applied over the border, an internal and external surface of the acrylic custom tray, to facilitate the retention of the silicone border molding material.
- An addition silicon putty material with an extended working time is loaded along the borders of a special tray.
- The special tray is placed in the mouth and is border molded, the patient is asked to move the tongue according to standard impression procedures. The tray is removed from the mouth, and the impression is examined.
- Light-body addition of silicone impression material is loaded in the impression and inserted in the mouth. The patient is instructed to repeat the tongue movements, more vigorously, while the light-body impression material is border molded along the buccal and labial flange areas.
- After the material is set, the impression is removed from the mouth and examined for any discrepancy.

### i) Modified Fluid wax impression technique:

- The preliminary impression is recorded with an irreversible hydrocolloid. A custom impression tray is fabricated on the preliminary cast.
- Softened modeling plastic impression compound is placed on the impression surface of the tray, corresponding to the region of the mandibular central incisors and both the mandibular first molars to serve as a spacer for wax.
- Segmental border molding is done with a compound. Spacers are removed with a scalpel blade once the border molding is complete. The tray is trimmed over the crest of the residual ridge to create a window opening above the displaceable alveolar ridge using a No.8 round bur.
- Mouth temperature impression wax is melted and applied onto the borders of the tray (Ensure that the wax temperature is less than the working temperature of the modeling plastic impression compound) to prevent distortion. Place the impression tray immediately over the edentulous ridge, and leave it in the mouth for approximately 5 minutes.
- Allow adequate time for the mouth temperature impression wax to flow and escape to the periphery of the impression, as well as to solidify.

#### DISCLAIMER

THIS IS COPYRIGHTED CONTENT. Unauthorized use, including screenshots, copying, misuse, reuse, or resale of any content from this app, is strictly prohibited. Our app monitors and records all screenshots and recordings. Violators will face strict legal action.

#### DISCLAIMER

THIS IS COPYRIGHTED CONTENT. Unauthorized use, including screenshots, copying, misuse, reuse, or resale of any content from this app, is strictly prohibited. Our app monitors and records all screenshots and recordings. Violators will face strict legal action.

#### DISCLAIMER

THIS IS COPYRIGHTED CONTENT. Unauthorized use, including screenshots, copying, misuse, reuse, or resale of any content from this app, is strictly prohibited. Our app monitors and records all screenshots and recordings. Violators will face strict legal action.



# IMPRESSION TECHNIQUES AND MATERIALS

Source: Articles and Text Books

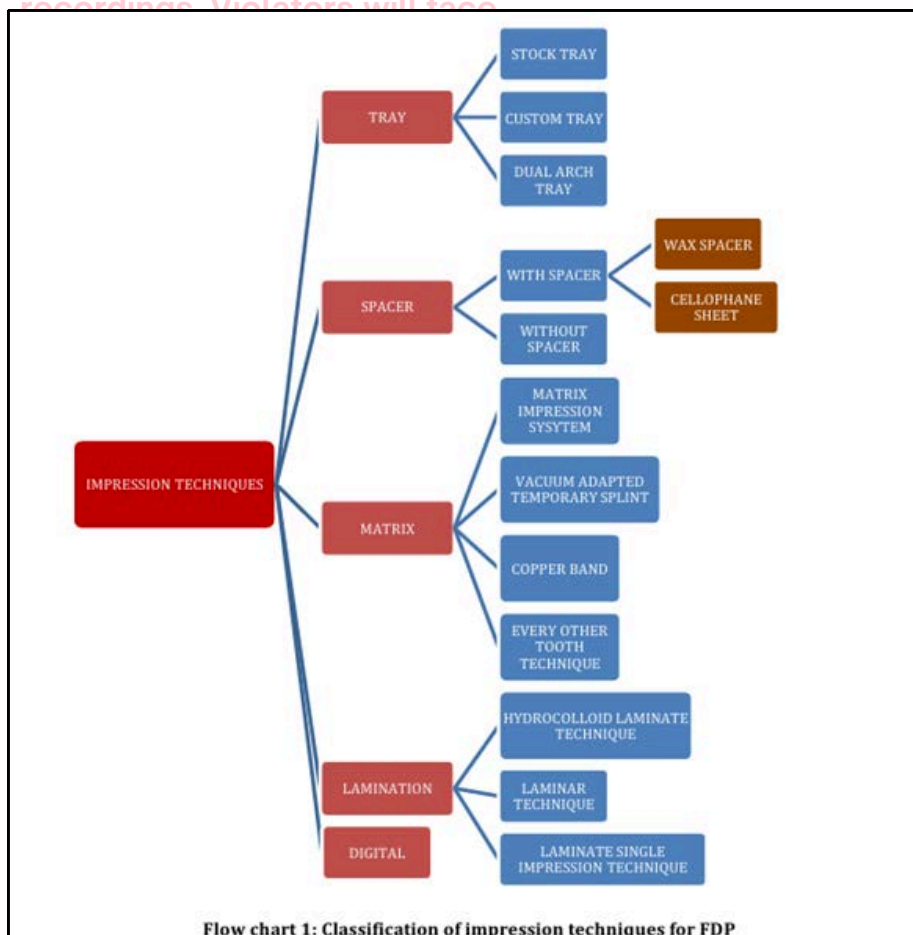
## Various Complete Denture impression techniques for resorbed ridges:

Source- Article On Complete Denture Impression Techniques For Resorbed Ridges: A Review From The Journal Of Prosthetic And Implant Dentistry

- Apply impression wax onto the remaining intaglio surface of the tray. Add impression wax onto the slopes of the ridge, rather than the crest, in increments until a glossy surface is visible.
- Trim away any excess impression wax on the periphery or over the window opening with a scalpel blade. Apply adhesive on the tray in the area surrounding the window opening, and allow it to dry.
- Place the impression tray onto the residual ridge and inject vinyl polysiloxane impression material over the window opening.
- Prevent distortion of the soft tissues by placing the impression material in the most passive manner possible. Remove and box the impression using a mix of plaster and pumice.
- Avoid using a conventional boxing procedure that requires boxing wax, as it may distort the impression wax.

## Various Impression technique for Fixed partial denture:

Source- Impression Techniques for Tooth-Supported Fixed Partial Denture International Journal of Drug Research and Dental Science Volume 4 Issue 2 (Page: 38-48), 2022 ISSN: 2582-0826



DISCLAIMER

THIS IS COPYRIGHTED CONTENT. Unauthorized use, including screenshots, copying, misuse, reuse, or resale of any content from this app, is strictly prohibited. Our app monitors and records all screenshots and recordings. Violators will face strict legal action.

DISCLAIMER  
THIS IS COPYRIGHTED CONTENT. Unauthorized use, including screenshots, copying, misuse, reuse, or resale of any content from this app, is strictly prohibited. Our app monitors and records all screenshots and recordings. Violators will face strict legal action.

DISCLAIMER

THIS IS COPYRIGHTED CONTENT. Unauthorized use, including screenshots, copying, misuse, reuse, or resale of any content from this app, is strictly prohibited. Our app monitors and records all screenshots and recordings. Violators will face strict legal action.

# IMPRESSION TECHNIQUES AND MATERIALS

Source: Articles and Text Books

## Various Impression technique for Fixed partial denture:

Source- Impression Techniques for Tooth-Supported Fixed Partial Denture International Journal of Drug Research and Dental Science Volume 4 Issue 2 (Page: 38-48), 2022 ISSN: 2582-0826

- Different techniques used different types of material for recording prepared finish lines precisely.
- Various studies have reported better results with the two-step putty wash technique than with one step putty wash technique.
- Fabrication of custom tray provides even thickness of material with close adaptation, thereby reducing the wastage of material and increasing the accuracy. so, better than stock tray.
- The accuracy mainly depends on the type of material rather than the technique used.
- Various studies have shown better marginal accuracy with digital impressions compared to conventional ones.

### a) Two Step Putty Wash Technique Using Cellophane Sheet as Spacer:

- Initially, putty is manipulated and loaded into the tray. Over that thin cellophane, the sheet is adapted and an impression is made. After complete polymerization, the tray is removed from the mouth and the cellophane sheet is peeled off. This putty impression act as a custom tray.
- Light body impression material is dispensed around the prepared tooth and over the custom putty tray. A loaded tray placed in the mouth and removed after complete polymerization.
- The disadvantage is as there is no tissue stop or landmark in the putty tray, it becomes quite difficult to accurately replace the tray while making the wash impression.

### b) An Alternative Putty/Wash Impression Technique

- This technique provides an alternative by fabricating a custom tray of putty intraorally with a wax spacer. To reduce the polymerization shrinkage of the putty, polyvinyl siloxane materials are recommended use.
- Soften a sheet of base plate wax and adapt it around the teeth.
- 2 mm square sections were in the premolar regions to act as occlusal stops. The closest fitting stock tray was selected to seat around the wax.
- Apply adhesive and load the tray with putty and insert it into the mouth. On polymerization, the tray is removed from the mouth, and the wax is peeled off.
- Now the putty will act as a custom tray. In the space previously occupied by wax, dispense low viscosity impression material and insert the tray.

### c) Simultaneous OR Squash Impression Technique

- This technique requires simultaneous manipulation of putty and light body elastomeric impression material.
- Putty loaded stock tray is placed over syringed light body around prepared tooth. No spacer is used in this method.
- This method of making the impression is unacceptable.

#### DISCLAIMER

THIS IS COPYRIGHTED CONTENT. Unauthorized use, including screenshots, copying, misuse, reuse, or resale of any content from this app, is strictly prohibited. Our app monitors and records all screenshots and recordings. Violators will face strict legal action.

DISCLAIMER

THIS IS COPYRIGHTED CONTENT. Unauthorized use, including screenshots, copying, misuse, reuse, or resale of any content from this app, is strictly prohibited. Our app monitors and records all screenshots and recordings. Violators will face strict legal action.

THIS IS COPYRIGHTED CONTENT. Unauthorized use, including screenshots, copying, misuse, reuse, or resale of any content from this app, is strictly prohibited. Our app monitors and records all screenshots and recordings. Violators will face strict legal action.

DISCLAIMER

# IMPRESSION TECHNIQUES AND MATERIALS

Source: Articles and Text Books

## Various Impression technique for Fixed partial denture:

Source- Impression Techniques for Tooth-Supported Fixed Partial Denture International Journal of Drug Research and Dental Science Volume 4 Issue 2 (Page: 38-48), 2022 ISSN: 2582-0826

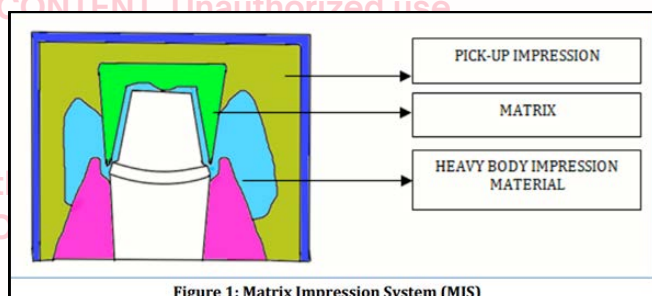
### d) Relieved Putty Impression

- A close-fitting stock tray is used for making a putty impression. In the areas of tooth preparations, putty is relieved with the help of a scalpel or bur to provide space for light body impression material. An impression is washed with low-viscosity impression material.

### Based on basis of matrix impression can be:

Matrix is a mold or impression in which something is formed.

### e) Matrix Impression System (MIS) and Every other tooth technique use heavy body material for displacing sulcus and recording margins.



### f) A technique that uses vacuum adapted splints for forming a matrix, sulcus is recorded by mixing equal parts of regular and light body rubber base impression material.

### g) In hydrocolloid laminate technique, critical areas are recorded by reversible hydrocolloid material.

### g) Digital Impression technique:

- Digital impression making is an innovative approach with more ease and comfort.
- It helps in capturing the record more precisely and faster than the conventional method.
- CEREC, Lava C.O.S. system, iTero, E4D, and TRIOS are a few of the systems used in intraoral digital system.
- CAD-CAM technology includes 3 main parts: data acquisition, data processing, and manufacturing unit.
- In this method, with the help of intra-oral scanners impression is made followed by the fabrication of a virtual 3D model without using impression materials and pouring of cast.
- The main drawback with this system lies in its cost. The setup and maintenance of a digital system are expensive with a steep learning curve.
- Intraoral scanning eliminates tray selection, material dispensing, material setting, material disinfection, impression packaging and shipping, gypsum pouring, die sectioning and trimming, and articulation and mounting. An error in any of these steps can lead to an inadequate fit of the prosthesis.

### DISCLAIMER

THIS IS COPYRIGHTED CONTENT. Unauthorized use, including screenshots, copying, misuse, reuse, or resale of any content from this app, is strictly prohibited. Our app monitors and records all screenshots and recordings. Violators will face strict legal action.

### DISCLAIMER

THIS IS COPYRIGHTED CONTENT. Unauthorized use, including screenshots, copying, misuse, reuse, or resale of any content from this app, is strictly prohibited. Our app monitors and records all screenshots and recordings. Violators will face strict legal action.

### DISCLAIMER

THIS IS COPYRIGHTED CONTENT. Unauthorized use, including screenshots, copying, misuse, reuse, or resale of any content from this app, is strictly prohibited. Our app monitors and records all screenshots and recordings. Violators will face strict legal action.



# IMPRESSION TECHNIQUES AND MATERIALS

Source: Articles and Text Books

## Various impression technique for implant prosthesis:

(Source- Impressions in implant dentistry British dental Journal)

- To effectively carry out any procedure, it is crucial to familiarize oneself with the components involved. Invariably, the first step is to determine the implant system used
- Each implant system has its own set of impression components that are designed to fit accurately onto the fixture head of the implant, which is machined to specific geometry. Irrespective of the implant system used, the impression components and techniques are broadly very similar.

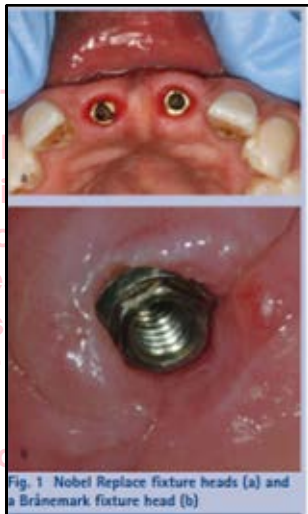

Fig. 1 Nobel Replace fixture heads (a) and Brånemark fixture head (b)

- Similar to crown and bridge prosthodontics, impression trays can either be stock trays or custom-made trays. Custom trays are preferred as they are generally more rigid and permit the impression material to be used in its optimal thickness.
- In implant prosthodontics, trays can further be classified as open or closed. An open tray permits direct access to the implant fixture head with the tray seated intra-orally.

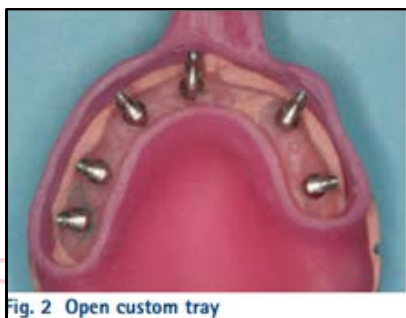

Fig. 2 Open custom tray

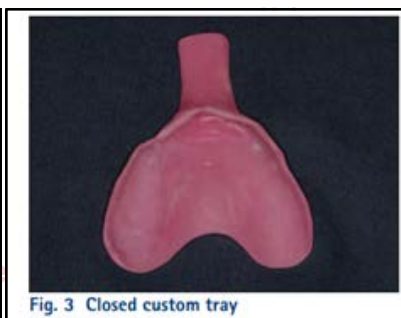

Fig. 3 Closed custom tray

- A custom tray can be used to make an impression at fixture head level, abutment level or both within the same impression.
- A primary impression is a prerequisite for the construction of the custom tray.. The clinician should provide the technician with their choice of impression material, so that the appropriate spacer can be laid down. It is recommended to use of rigid acrylic resin as the custom tray material.

## DISCLAIMER

THIS IS COPYRIGHTED CONTENT. Unauthorized use, including screenshots, copying, misuse, reuse, or resale of any content from this app, is strictly prohibited. Our app monitors and records all screenshots and recordings. Violators will face strict legal action.

## DISCLAIMER

THIS IS COPYRIGHTED CONTENT. Unauthorized use, including screenshots, copying, misuse, reuse, or resale of any content from this app, is strictly prohibited. Our app monitors and records all screenshots and recordings. Violators will face strict legal action.

THIS IS COPYRIGHTED CONTENT. Unauthorized use, including screenshots, copying, misuse, reuse, or resale of any content from this app, is strictly prohibited. Our app monitors and records all screenshots and recordings. Violators will face strict legal action.

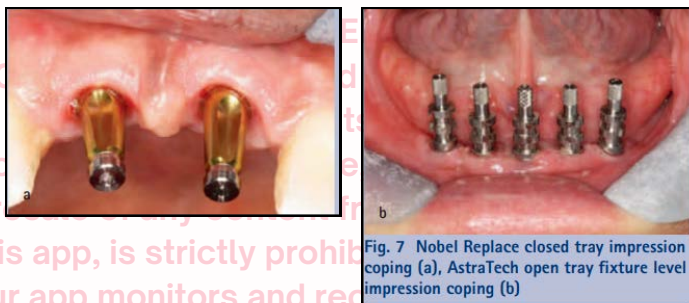
# IMPRESSION TECHNIQUES AND MATERIALS

Source: Articles and Text Books

## Various impression technique for implant prosthesis:

(Source- Impressions in implant dentistry British dental Journal)

- The recommended impression materials for implant are Quadrafunctional Vinyl polysiloxanes silicones (eg Aquasil Ultra, Dentsply, UK) Addition Cured Silicones (eg Extrude, Kerr, UK) and Polyethers
- The impression coping is the component that fits onto the implant fixture head or an implant abutment while making an impression.
- Broadly, there are two types of impression copings: one that is used with a closed tray and retained in the mouth after the impression is removed (Fig.7a) and the second, used with an open custom tray, in which the impression is removed with the coping in situ within the impression (Fig.7b)



- On clinical situations, like unfavorably positioned implants, the need to support adjacent soft tissues, poor access, etc. dictate the need for a custom impression coping.
- Custom copings are often conventional copings, which have been modified by trimming or by roughening and adding acrylic resin.

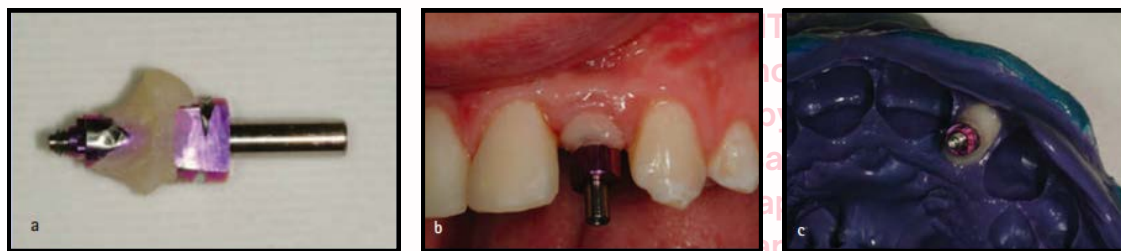

Fig: An impression coping modified by the addition of acrylic resin to maintain the position of the soft tissues a) during impression taking , b) the coping in the mouth and c) in the impression

### 1) Implant level impressions

- a) Pick up (Open tray)
- b) Transfer type (Closed tray)

### 2) Abutment level impressions

- a) Direct technique
- b) Indirect technique

DISCLAIMER

THIS IS COPYRIGHTED CONTENT. Unauthorized use, including screenshots, copying, misuse, reuse, or resale of any content from this app, is strictly prohibited. Our app monitors and records all screenshots and recordings. Violators will face strict legal action.

DISCLAIMER

THIS IS COPYRIGHTED CONTENT. Unauthorized use, including screenshots, copying, misuse, reuse, or resale of any content from this app, is strictly prohibited. Our app monitors and records all screenshots and recordings. Violators will face strict legal action.

THIS IS COPYRIGHTED CONTENT. Unauthorized use, including screenshots, copying, misuse, reuse, or resale of any content from this app, is strictly prohibited. Our app monitors and records all screenshots and recordings. Violators will face strict legal action.

# IMPRESSION TECHNIQUES AND MATERIALS

Source: Articles and Text Books

## A) Implant level impression techniques:

- Two techniques are commonly employed to make an impression of the fixture head: the closed tray and open tray techniques

### a) Closed tray technique (Transfer type)

#### Steps:

- 1) The healing abutment/cap is removed with a screwdriver and the implant fixture head is exposed.

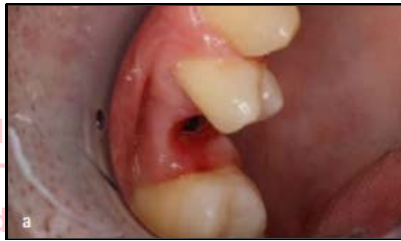

Fig: exposed fixture head after removal of the healing abutment

- 2) A closed-tray impression coping, appropriate to the type and size of implant, is selected and fitted onto the exposed fixture head. If the clinician is unsure about the complete seating of the coping onto the fixture head, a confirmatory radiograph should be taken.

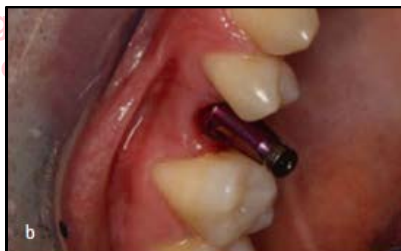

Fig: closed tray impression coping screwed in place

- 3) An appropriate stock tray or a closed custom tray is tried in. It is important to ensure that the tray covers the entire arch, provides adequate vertical space for the impression coping and optimum space for the impression material.

- 4) Generally, a combination of light bodied and heavy bodied silicone in a manner similar to conventional crown and bridge impressions is used.

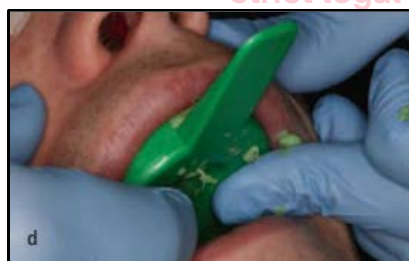
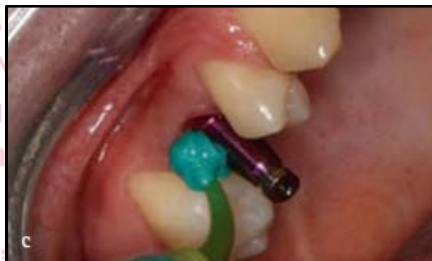

Fig: Light bodied impression material syringed around impression coping (c), impression taken in a stock tray (d),

#### DISCLAIMER

THIS IS COPYRIGHTED CONTENT. Unauthorized use, including screenshots, copying, misuse, reuse, or resale of any content from this app, is strictly prohibited. Our app monitors and records all screenshots and recordings. Violators will face strict legal action.

#### DISCLAIMER

THIS IS COPYRIGHTED CONTENT. Unauthorized use, including screenshots, copying, misuse, reuse, or resale of any content from this app, is strictly prohibited. Our app monitors and records all screenshots and recordings. Violators will face strict legal action.

THIS IS COPYRIGHTED CONTENT. Unauthorized use, including screenshots, copying, misuse, reuse, or resale of any content from this app, is strictly prohibited. Our app monitors and records all screenshots and recordings. Violators will face strict legal action.



# IMPRESSION TECHNIQUES AND MATERIALS

Source: Articles and Text Books

## A) Implant level impression techniques:

### a) Closed tray technique (Transfer type)

#### Steps:

- 5) Once set, the impression is removed, leaving the impression coping in the mouth.

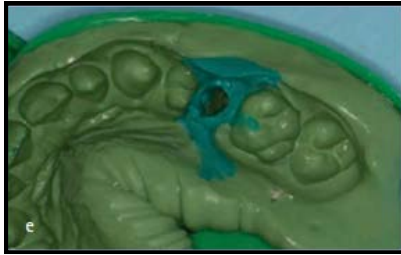

Fig: Impression with details of soft tissue around the implant and adjacent teeth

- 6) The impression coping is then removed and manually repositioned into the impression

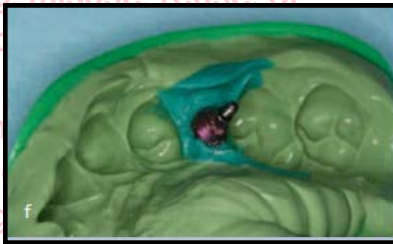


Fig: impression coping repositioned into the impression

- 7) It is important that the coping relocates positively and it is critical to ensure that the geometric details of the impression coping is recorded accurately in the impression.

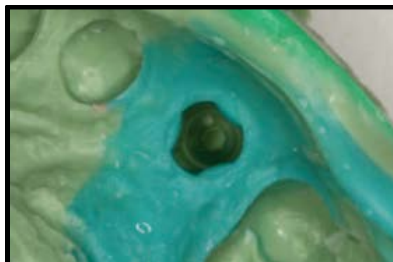

Fig: Detail of the impression coping recorded in a closed tray impression

- 8) The healing abutment is replaced.

DISCLAIMER

THIS IS COPYRIGHTED CONTENT. Unauthorized use, including screenshots, copying, misuse, reuse, or resale of any content from this app, is strictly prohibited. Our app monitors and records all screenshots and recordings. Violators will face strict legal action.

THIS IS COPYRIGHTED CONTENT. Unauthorized use, including screenshots, copying, misuse, reuse, or resale of any content from this app, is strictly prohibited. Our app monitors and records all screenshots and recordings. Violators will face strict legal action.

DISCLAIMER

THIS IS COPYRIGHTED CONTENT. Unauthorized use, including screenshots, copying, misuse, reuse, or resale of any content from this app, is strictly prohibited. Our app monitors and records all screenshots and recordings. Violators will face strict legal action.

DISCLAIMER  
THIS IS COPYRIGHTED CONTENT. Unauthorized use, including screenshots, copying, misuse, reuse, or resale of any content from this app, is strictly prohibited. Our app monitors and records all screenshots and recordings. Violators will face strict legal action.

THIS IS COPYRIGHTED CONTENT. Unauthorized use, including screenshots, copying, misuse, reuse, or resale of any content from this app, is strictly prohibited. Our app monitors and records all screenshots and recordings. Violators will face strict legal action.

THIS IS COPYRIGHTED CONTENT. Unauthorized use, including screenshots, copying, misuse, reuse, or resale of any content from this app, is strictly prohibited. Our app monitors and records all screenshots and recordings. Violators will face strict legal action.

# IMPRESSION TECHNIQUES AND MATERIALS

Source: Articles and Text Books

## A) Implant level impression techniques:

### b) Open tray technique (Pick up)

#### Steps:

- 1) At the preliminary appointment: A conventional alginate impression is made and study models are cast fabricated. A rigid custom tray is manufactured with a window cut through over the implant.

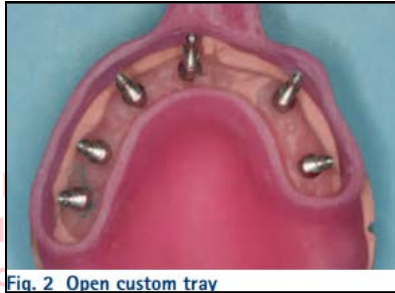

Fig. 2 Open custom tray

- 2) At a subsequent appointment: The healing abutments are removed and appropriate impression copings are selected and fitted. In some cases, these copings may be splinted together intraorally to provide greater rigidity and possibly greater accuracy.

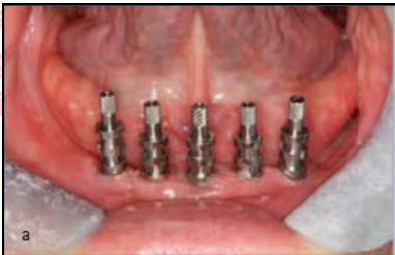
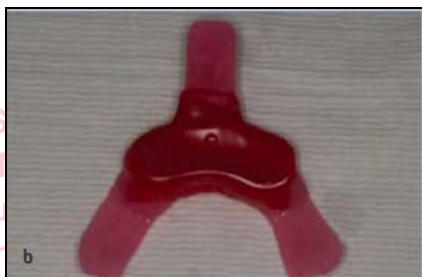
Fig: Impression copings in place

- 3) The open tray is tried in – the impression copings should emerge level with the window. This permits easy removal of the impression copings, while ensuring that the copings are supported by sufficient impression material.

- 4) The window is sealed with wax.



b

#### DISCLAIMER

THIS IS COPYRIGHTED CONTENT. Unauthorized use, including screenshots, copying, misuse, reuse, or resale of any content from this app, is strictly prohibited. Our app monitors and records all screenshots and recordings. Violators will face strict legal action.

#### DISCLAIMER

THIS IS COPYRIGHTED CONTENT. Unauthorized use, including screenshots, copying, misuse, reuse, or resale of any content from this app, is strictly prohibited. Our app monitors and records all screenshots and recordings. Violators will face strict legal action.

THIS IS COPYRIGHTED CONTENT. Unauthorized use, including screenshots, copying, misuse, reuse, or resale of any content from this app, is strictly prohibited. Our app monitors and records all screenshots and recordings. Violators will face strict legal action.

# IMPRESSION TECHNIQUES AND MATERIALS

Source: Articles and Text Books

## A) Implant level impression techniques:

### b) Open tray technique (Pick up)

#### Steps:

- 5) An impression is taken in the open tray with a silicone impression material. The tips of the impression copings should be felt through the wax covering the window.

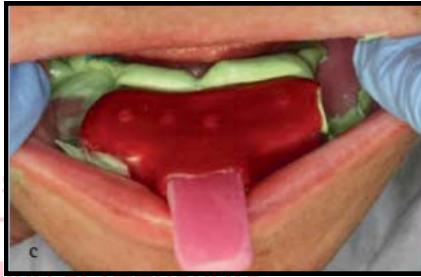


Fig: impression in place with the tips of the impression copings projecting through the wax window

- 6) Once the impression has set, the impression copings are unscrewed through the window on the tray and the impression is removed from the mouth along with all the impression copings in place.

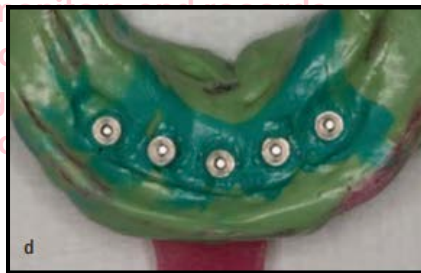

Fig: the completed impression with the impression copings in situ

- 7) The healing abutments are replaced.

### Closed tray Vs Open tray technique:

- Closed tray impression technique is generally simpler and quicker but involves reseating the impression coping, which may introduce potential inaccuracies.
- With three or fewer implants, there was no difference between an open tray and closed tray approach according to systematic review.
- With four or more implants, impressions are more accurate with an open tray technique. splinting of impression copings to improve impression accuracy.
- An open tray technique is specifically indicated where implants are divergent as it may not be possible to remove a closed tray in these situations. However, an open tray technique may not be suitable if the patient has an exaggerated gag reflex, has restricted mouth opening or if there is limited access (e.g., Posterior dentition).

#### DISCLAIMER

THIS IS COPYRIGHTED CONTENT. Unauthorized use, including screenshots, copying, misuse, reuse, or resale of any content from this app, is strictly prohibited. Our app monitors and records all screenshots and recordings. Violators will face strict legal action.

DISCLAIMER

THIS IS COPYRIGHTED CONTENT. Unauthorized use, including screenshots, copying, misuse, reuse, or resale of any content from this app, is strictly prohibited. Our app monitors and records all screenshots and recordings. Violators will face strict legal action.

THIS IS COPYRIGHTED CONTENT. Unauthorized use, including screenshots, copying, misuse, reuse, or resale of any content from this app, is strictly prohibited. Our app monitors and records all screenshots and recordings. Violators will face strict legal action.

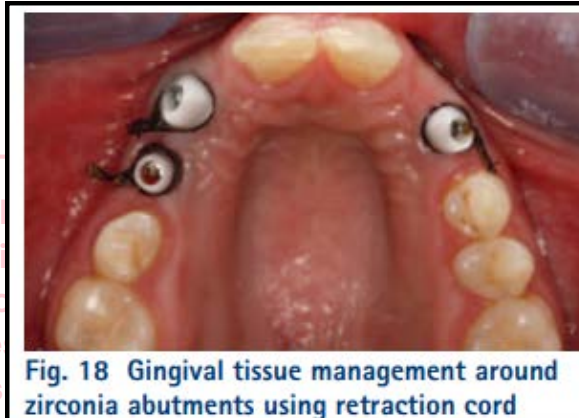

# IMPRESSION TECHNIQUES AND MATERIALS

Source: Articles and Text Books

## B) Abutment level impression techniques:

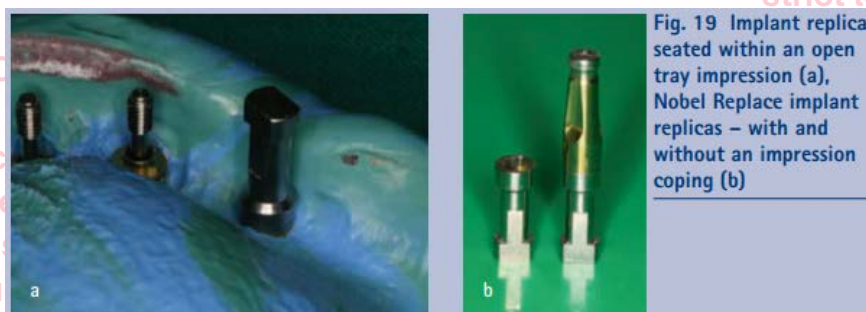
- Within general dental practice, there is often a need to replace an implant crown, which is aesthetically unsatisfactory, while the underlying abutment is satisfactory.
- In these situations, a routine crown and bridge approach may be employed, i.e. the gingivae may be retracted using displacement cord and a conventional impression in a rigid tray may be made.



- Care must be taken not to damage the fragile epithelial attachment to the abutment. The crown/bridgework can then be made and cemented onto the abutments.
- Alternately, the implant crown can be over contoured along the gingival margin by adding a small amount of composite resin, following which the crown is reseated for 5–10 minutes. This will displace the gingival tissue and permit an accurate impression of the abutment to be made.

### Further laboratory steps for implant impressions:

- Once an impression has been made, the impression should be thoroughly inspected. All teeth should be accurately recorded to allow future articulation and replication of contralateral tooth contours.
- The impression coping should be securely located within the impression. Implant replicas or analogues are attached to the impression coping before casting the impression



DISCLAIMER

THIS IS COPYRIGHTED CONTENT. Unauthorized use, including screenshots, copying, misuse, reuse, or resale of any content from this app, is strictly prohibited. Our app monitors and records all screenshots and recordings. Violators will face strict legal action.

DISCLAIMER

THIS IS COPYRIGHTED CONTENT. Unauthorized use, including screenshots, copying, misuse, reuse, or resale of any content from this app, is strictly prohibited. Our app monitors and records all screenshots and recordings. Violators will face strict legal action.

DISCLAIMER

THIS IS COPYRIGHTED CONTENT. Unauthorized use, including screenshots, copying, misuse, reuse, or resale of any content from this app, is strictly prohibited. Our app monitors and records all screenshots and recordings. Violators will face strict legal action.

# IMPRESSION TECHNIQUES AND MATERIALS

Source: Articles and Text Books

## B) Abutment level impression techniques:

### Further laboratory steps for implant impressions:

- The replicas get embedded within the model and reproduce the positions and geometry of the implant fixture heads. The clinician should carefully attach the implant replica, taking care to avoid any rotation of the impression coping.
- The prescription to the laboratory should include details of the implant system, type of restoration required (i.e. temporary or definitive crown, etc.), choice of material for the crown and abutment and shade.
- Often, a small volume of soft silicone is poured directly into the impression around the impression coping in order to mimic gingival tissues.

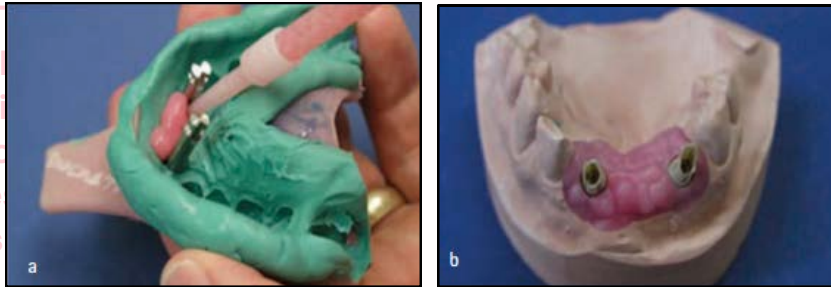


Fig-Silicone mimicking gingival tissues being syringed around the implant replicas (a), working model with removable silicone cuff around implants(b).

- This is done to permit the removal and replacement of the gingival tissues, thus providing access to the fixture head, without damaging the model. The technician has to be careful not to cover the implant replicas or any of the adjacent teeth with the soft silicone as this may introduce errors.

DISCLAIMER

THIS IS COPYRIGHTED CONTENT. Unauthorized use, including screenshots, copying, misuse, reuse, or resale of any content from this app, is strictly prohibited. Our app monitors and records all screenshots and recordings. Violators will face strict legal action.

THIS IS COPYRIGHTED CONTENT. Unauthorized use, including screenshots, copying, misuse, reuse, or resale of any content from this app, is strictly prohibited. Our app monitors and records all screenshots and recordings. Violators will face strict legal action.

DISCLAIMER

THIS IS COPYRIGHTED CONTENT. Unauthorized use, including screenshots, copying, misuse, reuse, or resale of any content from this app, is strictly prohibited. Our app monitors and records all screenshots and recordings. Violators will face strict legal action.

DISCLAIMER

THIS IS COPYRIGHTED CONTENT. Unauthorized use, including screenshots, copying, misuse, reuse, or resale of any content from this app, is strictly prohibited. Our app monitors and records all screenshots and recordings. Violators will face strict legal action.

# IMPLANT COMPLICATIONS AND RISK FACTORS

Sources: Review Article on implant abutment and their selection | Patient related risk factors for implant therapy (ADJ) | ADJ Assessment of bone grafts | ADJ implants for ageing population | Why do implant fail part 1 and part 2

- Dental implants have become the most promising and accepted prosthetic alternative to missing teeth.
- With the growth in implant dentistry various implant brands and their components are made available in the market that vary in terms of design and other features.
- Successful implant restoration depends on various factors that includes case selection, implant placement, osseointegration, abutment selection and maintenance.
- Implant abutment is the link between the implant and restoration, and abutment selection step is an extremely important step to achieve esthetic and functional harmony in implant prosthesis.

## Parts of implants:

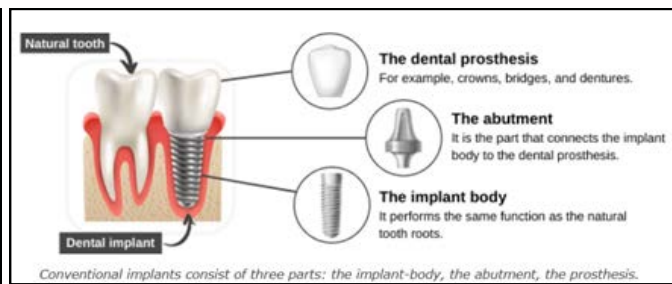
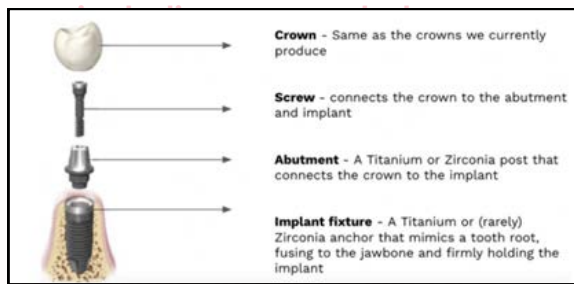
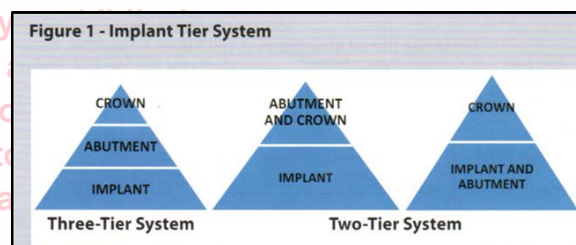


Fig: Source- Internet

- The abutment is the portion of the implant that supports or retains prosthesis or implant super structure. The abutment has three parts:
  - a) Prosthesis connection segment: that connects to the prosthesis
  - b) Implant connection segment: that connects to the implant
  - c) Transgingival segment: That is surrounded by gingival tissue above prosthetic platform of implant.
- The implant super structure is the metal framework that attaches to the implant abutments and either provides retention for removable prosthesis or acts as framework for fixed prosthesis.
- The restoration can be connected to the implant in two or three ways referred to as implant tier system:

Can be:

- a) **Two tier system:** Comprises of two individual components, Implant as one component, abutment and crown as one component OR implant and abutment in one component and crown as one component.
- b) **Three tier system:** It comprises of implant, abutment and crown as individual components.



DISCLAIMER

THIS IS COPYRIGHTED CONTENT. Unauthorized use, including screenshots, copying, misuse, reuse, or resale of any content from this app, is strictly prohibited. Our app monitors and records all screenshots and recordings. Violators will face strict legal action.

THIS IS COPYRIGHTED CONTENT. Unauthorized use, including screenshots, copying, misuse, reuse, or resale of any content from this app, is strictly prohibited. Our app monitors and records all screenshots and recordings. Violators will face strict legal action.

DISCLAIMER  
THIS IS COPYRIGHTED CONTENT. Unauthorized use, including screenshots, copying, misuse, reuse, or resale of any content from this app, is strictly prohibited. Our app monitors and records all screenshots and recordings. Violators will face strict legal action.

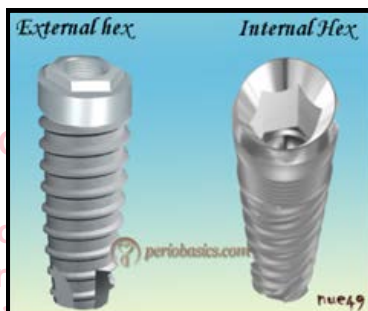

# IMPLANT COMPLICATIONS AND RISK FACTORS

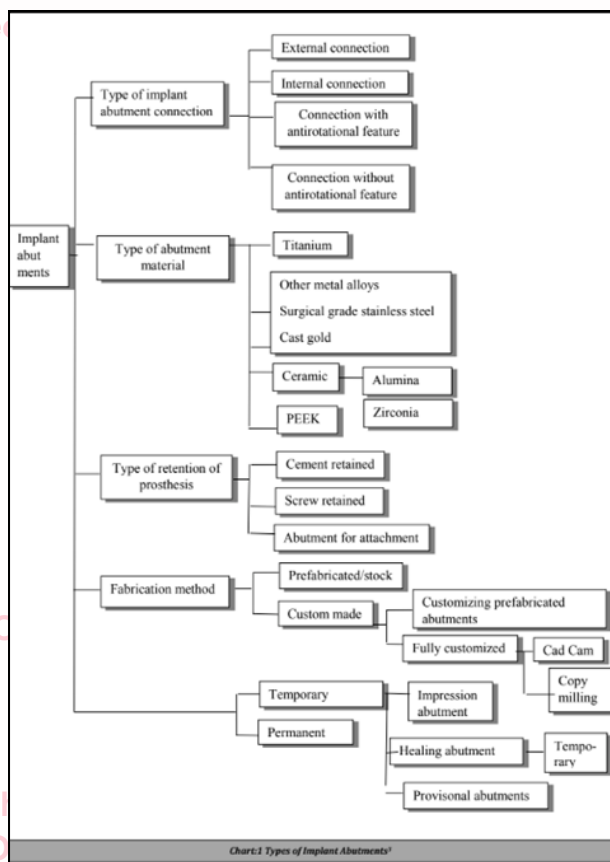
Sources: Review Article on implant abutment and their selection | Patient related risk factors for implant therapy (ADJ) | ADJ Assessment of bone grafts | ADJ implants for ageing population | Why do implant fail part 1 and part 2

## Types of implant abutments:

- The implant abutment connection region has a platform on which abutment is seated and this platform bears anti-rotational features to resist rotation between abutment and implant body.
- If this anti-rotational component is on implant platform on which abutment is seated, it is **external hex**, if this feature extends within the implant body it is **internal hex**. These anti-rotational features can take up various configurations namely hexagonal, octagonal, tripod, spline and mores taper connections.



- The implant with anti-rotational features is recommended in single tooth restorations to prevent rotation of abutments.



DISCLAIMER

THIS IS COPYRIGHTED CONTENT. Unauthorized use, including screenshots, copying, misuse, reuse, or resale of any content from this app, is strictly prohibited. Our app monitors and records all screenshots and recordings. Violators will face strict legal action.

DISCLAIMER

THIS IS COPYRIGHTED CONTENT. Unauthorized use, including screenshots, copying, misuse, reuse, or resale of any content from this app, is strictly prohibited. Our app monitors and records all screenshots and recordings. Violators will face strict legal action.

DISCLAIMER

THIS IS COPYRIGHTED CONTENT. Unauthorized use, including screenshots, copying, misuse, reuse, or resale of any content from this app, is strictly prohibited. Our app monitors and records all screenshots and recordings. Violators will face strict legal action.

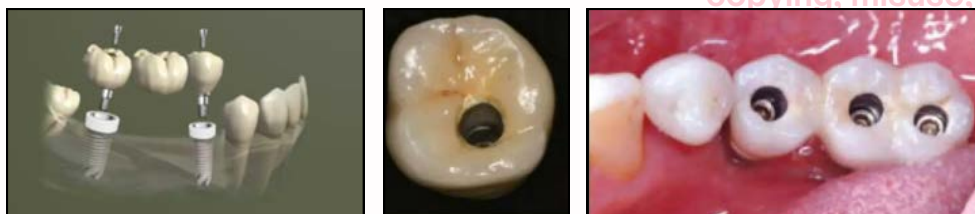
## IMPLANT COMPLICATIONS AND RISK FACTORS

Sources: Review Article on implant abutment and their selection | Patient related risk factors for implant therapy (ADJ) | ADJ Assessment of bone grafts | ADJ implants for ageing population | Why do implant fail part 1 and part 2

Based on retention of prosthesis abutments can be classified:

- Implant prosthesis can be:

a) **Screw retained:**



- More expensive as it involves additional components and complex laboratory procedure for fabrication.
- Can deliver enhanced esthetics if ideal implant position is achieved, but aesthetics is less predictable than cemented restorations.
- Difficult to access in comparison to cement retained restorations esp. in posterior areas or with limited jaw opening.
- Occlusion is less precise than cement retained restorations due to presence of screw access holes. These screw access holes occupy more than 50% of occlusal table and need to be covered with occlusal restorative material to conceal screw channel and under occlusal loading restorative material tends to wear off.
- Screw retained restorations are connected directly to the implants without the use of intermediate abutment and need less interocclusal space. Hence, **cases with inadequate interocclusal space are better managed with screw retained restorations.**

Crown height space is measured from the crest of the ridge to plane of occlusion in posterior region and incisal edge in anterior region. Insufficient crown height space can be managed by screw retained, customised and metal abutments and in cases with excessive crown height space, prefabricated and customised abutments can be used.<sup>15</sup>

- Screw loosening is a hindering factor with screw retained restorations, therefore, precise protocol should be followed for tightening the screws. After initial torquing, retorquing of screw after 5 minutes, and again after few weeks is recommended.
- Screw retained can be easily retrieved** without damaging the prosthesis and the implant.
- A passive fit of the prosthesis is desired for implant success, screw retained prosthesis does not provide good passivity.
- Screw retained restorations are ideal for provisional restorations because of their easy retrievability and better tissue response.
- It is recommended that long span restorations be screw retained for easier maintenance as they have high risk of complications.
- The approach of screw retention is beneficial for elderly and special needs patients, because the removal of prosthesis is a possible alternative for maintenance that preserves the health of peri-implant mucosa.

### DISCLAIMER

THIS IS COPYRIGHTED CONTENT. Unauthorized use, including screenshots, copying, misuse, reuse, or resale of any content from this app, is strictly prohibited. Our app monitors and records all screenshots and recordings. Violators will face strict legal action.

### DISCLAIMER

THIS IS COPYRIGHTED CONTENT. Unauthorized use, including screenshots, copying, misuse, reuse, or resale of any content from this app, is strictly prohibited. Our app monitors and records all screenshots and recordings. Violators will face strict legal action.

### DISCLAIMER

THIS IS COPYRIGHTED CONTENT. Unauthorized use, including screenshots, copying, misuse, reuse, or resale of any content from this app, is strictly prohibited. Our app monitors and records all screenshots and recordings. Violators will face strict legal action.

# IMPLANT COMPLICATIONS AND RISK FACTORS

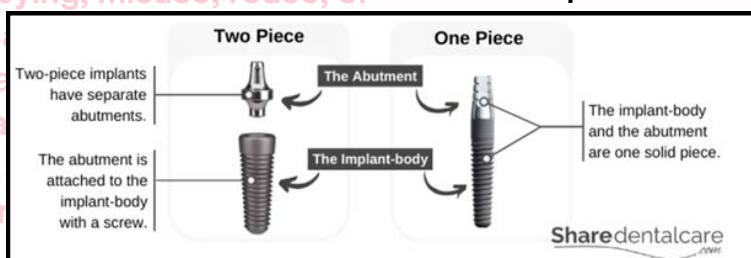
Sources: Review Article on implant abutment and their selection | Patient related risk factors for implant therapy (ADJ) | ADJ Assessment of bone grafts | ADJ implants for ageing population | Why do implant fail part 1 and part 2

## b) Cement retained:

- i) Easier to fabricate and less expensive than screw retained prosthesis.
- ii) Esthetics is more predictable with cemented restorations as it does not involve screw access holes.
- iii) Cement retained restorations are more preferred in posterior region or cases with limited mouth opening owing to their better accessibility.
- iv) More precise occlusion is possible with cement retained restorations.
- v) Cement retained restorations require more interocclusal space, because with cement retained restorations **at least 4mm height of abutment** is required to achieve desirable retention, so a minimum of 8 mm interocclusal space is required for cemented restorations.
- vi) Retrieving cement retained restorations is possible but unpredictable and might damage implant and restorations.
- vii) Cementation for cemented restorations can be achieved by either provisional or definitive cementation. Provisional cementation offers better retrievability but increases risk of microleakage and retention loss compared to definitive cementation.
- viii) Passivity is better with cemented restorations; passivity is achieved by the cement that acts as a shock absorber and lowers stress at implant abutment complex and bone.
- ix) Excess cement is an issue with cemented restorations especially in anterior region when implant is placed 3- 4mm apically to achieve emergence profile. This excess cement can cause peri-implantitis and related complications.
- x) Whenever cement retained restorations are chosen, abutment design plays a primary role, as poorly designed abutments lead to improperly contoured and unacceptable restorations leading to aesthetic and mechanical complications.
- xi) Two broad categories of abutments are used for cement retained restorations:

**One-piece abutments:** It connects to the implants with friction or screw threads and does not have additional retaining screws, generally used with immediate and provisional restorations. They are structurally strong, require less components and offers precise control over final fitting of restorations. They also offer reduced cost. However, the abutment positioning procedure is complicated and may interfere with osseointegration and stability of implants.

**Two-piece abutments:** It has two components one engages anti rotational feature and other fixes abutment to implants.



## DISCLAIMER

THIS IS COPYRIGHTED CONTENT. Unauthorized use, including screenshots, copying, misuse, reuse, or resale of any content from this app, is strictly prohibited. Our app monitors and records all screenshots and recordings. Violators will face strict legal action.

## DISCLAIMER

THIS IS COPYRIGHTED CONTENT. Unauthorized use, including screenshots, copying, misuse, reuse, or resale of any content from this app, is strictly prohibited. Our app monitors and records all screenshots and recordings. Violators will face strict legal action.

## DISCLAIMER

THIS IS COPYRIGHTED CONTENT. Unauthorized use, including screenshots, copying, misuse, reuse, or resale of any content from this app, is strictly prohibited. Our app monitors and records all screenshots and recordings. Violators will face strict legal action.



# IMPLANT COMPLICATIONS AND RISK FACTORS

Sources: Review Article on implant abutment and their selection | Patient related risk factors for implant therapy (ADJ) | ADJ Assessment of bone grafts | ADJ implants for ageing population | Why do implant fail part 1 and part 2

## c) Retained by an attachment

### Type of material used for customized implant abutment:

- The implant abutment material should be biocompatible with tissue as it remains deep within the soft tissue complex. This material should also have ideal mechanical properties to withstand occlusal loads and survive in oral environment.
- Currently used materials are titanium, zirconia, alumina, Peek, gold alloys or other metal alloys.
- In regards to biocompatibility and mechanical properties, titanium is the most ideal implant material, however due to thin gingival biotype it displays greyish hue under tissue compromising esthetic especially in anterior region. Therefore, for esthetic regions esthetic ceramic materials like zirconia or alumina is preferred.
- In high occlusal conditions as in posterior region titanium is more ideal, and in esthetic demanding area and low occlusal loading area like anterior region Zirconia is recommended.

In cases with high esthetic situation, high smile line, anatomically demanding situations like triangular teeth and high scalloping of tissues, and mechanically low challenges, customized all ceramic abutments are recommended. In mechanically challenging situations with low esthetic demand, metallic abutments are recommended. In esthetically demanding situations which are mechanically challenging, hybrid abutments with titanium base are a good option.<sup>7</sup>

### Prefabricated Abutments:

- The first pre-fabricated abutments are branemark abutments that consisted of a hollow cylinder with internal hex fitted to implant and was secured with abutment screw. These designs were the treaded tapered posts which were hand tightened, ratcheted within the implant body or cemented to the implant body, but they had limited applications due to esthetic concerns.
- Invention Plastic UCLA abutments was significant breakthrough in implant restoration with enhanced esthetics. It is a castable abutment that comes with a machined gold cylinder and a plastic sleeve that can be modified to custom abutment. It can be used with single or multiple screw retained or cement retained restorations and can correct up to 30-degree angulations when used as a custom abutment.

cavity.<sup>10</sup> Prefabricated / stock abutments cannot remain deep in the margin without being too deep interproximally, hence customised abutments have a better application in highly scalloped gingival margins.<sup>7</sup>

Custom abutments provide freedom to individualize position, angulations and emergence profile. Crown margins

## DISCLAIMER

THIS IS COPYRIGHTED CONTENT. Unauthorized use, including screenshots, copying, misuse, reuse, or resale of any content from this app, is strictly prohibited. Our app monitors and records all screenshots and recordings. Violators will face strict legal action.

## DISCLAIMER

THIS IS COPYRIGHTED CONTENT. Unauthorized use, including screenshots, copying, misuse, reuse, or resale of any content from this app, is strictly prohibited. Our app monitors and records all screenshots and recordings. Violators will face strict legal action.

## DISCLAIMER

THIS IS COPYRIGHTED CONTENT. Unauthorized use, including screenshots, copying, misuse, reuse, or resale of any content from this app, is strictly prohibited. Our app monitors and records all screenshots and recordings. Violators will face strict legal action.

# IMPLANT COMPLICATIONS AND RISK FACTORS

Sources: Review Article on implant abutment and their selection | Patient related risk factors for implant therapy (ADJ) | ADJ Assessment of bone grafts | ADJ implants for ageing population | Why do implant fail part 1 and part 2

## Implant Failure:

- Implant failure is defined as the total failure of implants to fulfill its purpose (functional, esthetic, or phonetic) because of mechanical or biologic reasons.
- Implant failure can be biologic (related to biologic process) or mechanical (related to fracture of implants, coatings, connecting screws and prosthesis)
- However, fracture of connecting screw or prosthesis can be considered as a complication rather than failure because they can be managed in most cases.
- Meffert, proposed a classification of failure of implants namely:
- Ailing implants: Those showing radiographic bone loss without inflammatory signs or mobility.
- Failing implants: Those showing progressive bone loss, signs of inflammation and no mobility. (Still in reversible state, can be managed)
- Failed implants: Progressive bone loss with clinical mobility and not functioning in the intended state.

Balshi<sup>9,10</sup> explained the clinical picture of the implant fracture, management, and treatment of the fractured implant, and Zarb and Schmitt<sup>11</sup> explained how to manage a connecting screw fracture. Therefore, if the condition is reversible (i.e., could be corrected) the authors considered these to be complications in the same way as a general practitioner would consider a fractured amalgam filling.

- The warning signs of implant failure are:

1. Connecting screw loosening
2. Connecting screw fracture
3. Gingival bleeding and enlargement
4. Purulent exudate from large pockets
5. Pain (not very common)
6. Fracture prosthetic component
7. Angular bone loss noted radiographically
8. Long-standing infection and soft tissue sloughing during the healing period of first-stage surgery

- Implant failure can be due to host factors, surgical placement, implant selection and restorative problems.

DISCLAIMER

THIS IS COPYRIGHTED CONTENT. Unauthorized use, including screenshots, copying, misuse, reuse, or resale of any content from this app, is strictly prohibited. Our app monitors and records all screenshots and recordings. Violators will face strict legal action.

DISCLAIMER  
THIS IS COPYRIGHTED CONTENT. Unauthorized use, including screenshots, copying, misuse, reuse, or resale of any content from this app, is strictly prohibited. Our app monitors and records all screenshots and recordings. Violators will face strict legal action.

DISCLAIMER

THIS IS COPYRIGHTED CONTENT. Unauthorized use, including screenshots, copying, misuse, reuse, or resale of any content from this app, is strictly prohibited. Our app monitors and records all screenshots and recordings. Violators will face strict legal action.

# IMPLANT COMPLICATIONS AND RISK FACTORS

Sources: Review Article on implant abutment and their selection | Patient related risk factors for implant therapy (ADJ) | ADJ Assessment of bone grafts | ADJ implants for ageing population | Why do implant fail part 1 and part 2

## Risk factors for dental implant failure:

- The primary factor to predispose to implant failure is low bone density (Type IV bone quality)- mostly in maxillary premolar region.
- Treatment planning for dental implants involves assessment of patient related risk factors prior to formulation of treatment plan.
  - a) Patient who has suffered cardiac infraction within the previous six months should not undergo implant surgery as there is increased risk of potential adverse cerebrovascular and cardiovascular events.
  - b) Patients with history of angina should have glycerin trinitrate tablets or sublingual sprays available when undergoing implant surgery.
  - c) No increased risk of failure is associated in patients with hypertension and other cardiovascular disorders if they are able to undergo minor oral surgery.
  - d) Surgery should be avoided for poorly controlled diabetes, but diabetes is not a contraindication to implant therapy.
  - e) Patients with auto immune diseases are usually in immunosuppressive therapy. Patients on systemic steroid therapy may have complications like osteoporosis, delayed wound healing and increased susceptibility to infection. Evidence is lacking for implant treatment for these patients, so a delayed approach and increased healing times is recommended before loading for these patients.
  - f) Tendency towards higher implant failure rate is noted for patients with Crohn's disease.
  - g) Patients on long term bisphosphonates may be susceptible to ONJ (Osteonecrosis of Jaw) as a potential major complication. The risk morbidity with ONJ is high for these patients.
  - h) There is no evidence of higher failure rate of implants in osteoporotic patients treated with adapted bone preparation and extended healing times.
  - i) In terms of radiotherapy, no evidence of implant failures is reported when the radiation dose is less than 45 Gray. However, the implants placed in irradiated bone with doses 50 Gy exhibited higher failure rate (2-3) times more than non-irradiated bone. The waiting period between the end of radiation therapy and implant placement is not definite and ranges from 3,6 to 12 months.
  - j) There is increased risk of peri-implantitis and implant failure, with a patient consisting of history of periodontitis related tooth loss.
  - k) Smoking is a recognized risk factor for wound healing which is fundamental to the process of osseointegration. Smokers have significantly higher failure rate for implants esp. in maxilla, however this can be managed if patient stopped smoking at least one week before implant surgery.
  - l) Implant failure is almost twice in maxilla than in mandible due to poor bone quality (Type IV), with failures more in posterior maxilla than in anterior maxilla.
  - m) In mandible implant failure is more in posterior region than anterior mandible.
  - n) There is emerging evidence, which suggests there is correlation between genetic traits and Osseo-integration.

## DISCLAIMER

THIS IS COPYRIGHTED CONTENT. Unauthorized use, including screenshots, copying, misuse, reuse, or resale of any content from this app, is strictly prohibited. Our app monitors and records all screenshots and recordings. Violators will face strict legal action.

## DISCLAIMER

THIS IS COPYRIGHTED CONTENT. Unauthorized use, including screenshots, copying, misuse, reuse, or resale of any content from this app, is strictly prohibited. Our app monitors and records all screenshots and recordings. Violators will face strict legal action.

## DISCLAIMER

THIS IS COPYRIGHTED CONTENT. Unauthorized use, including screenshots, copying, misuse, reuse, or resale of any content from this app, is strictly prohibited. Our app monitors and records all screenshots and recordings. Violators will face strict legal action.



# IMPLANT COMPLICATIONS AND RISK FACTORS

Sources: Review Article on implant abutment and their selection | Patient related risk factors for implant therapy (ADJ) | ADJ Assessment of bone grafts | ADJ implants for ageing population | Why do implant fail part 1 and part 2

- o) There is a direct relationship between accumulation of dental plaque and onset and progression of gingivitis. Dental plaque (Poor oral hygiene) can be one of the main factors that leads to implant failure if left unmanaged.
- p) Old age is not a contraindication for implant therapy.

## Complication with surgical placement of implant

- Alveolar process resorption (esp. for patients with long periods of edentulism) is a big problem that can be managed by:
  - a) Grafting the area to place the implant properly
  - b) Place the implant with an angulation
  - c) Use an angulated abutment to achieve the proper alignment with opposing arch or the adjacent natural teeth.
- Pre restoring the implant position by grafting (preferably using an autogenous graft) to avoid offset loading is recommended.
- The purpose of alveolar augmentation is to increase the alveolar bone volume sufficiently to allow primary stability and to ensure that the implant is surrounded by bone. Autogenous grafts can be taken either intraorally or extra orally.
- There is significantly higher failure rate of grafts in patients who had block graft (a solid piece or block of bone) than those that had particulate graft (Granules or small particles of bone material). Block graft are typically cortical or cortico cancellous in nature.
- Graft failure is also increased in patients who received mixed autogenous graft.
- Smoking and diabetes mellitus are risk factors that significantly affect the outcomes of bone grafts, particularly diabetes.
- In cases of grafted bone sites, a waiting period of (6- 9 months) is mandatory for implant survival before loading the implant.
- There is a strong correlation between overheating the bone and implant failure. Minimal temperature elevation during surgical drilling of bone is a key factor in atraumatic surgical technique. Bone cell death occurs at a temperature of 47-degree Celsius and higher when drilling is performed for 1 minute.
- Extended cantilever implant supported prosthesis should be approached more cautiously as increased amount of occlusal forces may be encountered.
- Too rapid loading of the implant supported system is considered to be one of the most common causes of prosthetic related failures.

DISCLAIMER

THIS IS COPYRIGHTED CONTENT. Unauthorized use, including screenshots, copying, misuse, reuse, or resale of any content from this app, is strictly prohibited. Our app monitors and records all screenshots and recordings. Violators will face strict legal action.

DISCLAIMER

THIS IS COPYRIGHTED CONTENT. Unauthorized use, including screenshots, copying, misuse, reuse, or resale of any content from this app, is strictly prohibited. Our app monitors and records all screenshots and recordings. Violators will face strict legal action.

DISCLAIMER

THIS IS COPYRIGHTED CONTENT. Unauthorized use, including screenshots, copying, misuse, reuse, or resale of any content from this app, is strictly prohibited. Our app monitors and records all screenshots and recordings. Violators will face strict legal action.