



WINSPERT

**ORAL SURGERY**

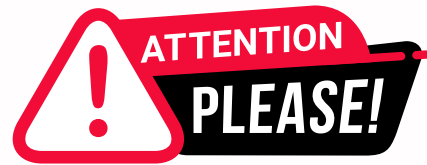**H.O.T**

**HIGH-PRIORITY ORGANISED THEORY**

**NOTES**

By Dr. Jigyasa Sharma





Dear Students,

We'd like to remind you about the importance of respecting the integrity of the resources provided in our app.

Please be aware that **WINSPERT HOT NOTES ARE COPYRIGHTED CONTENT. Unauthorized use, including screenshots, copying, misuse, reuse, or resale of any content from this app, is strictly prohibited.**

**Our app monitors and records all screenshots and recordings. Violators will face strict legal action.**

We're committed to providing you with the best tools for your success, and we appreciate your cooperation in maintaining a fair and secure learning environment.

Thank you for your understanding and continued dedication.

Best regards,  
WINSPERT TEAM

# Table of Contents

## ORAL SURGERY H.O.T TOPICS

HOT TOPIC	Page
Exodontia - procedures, risks, complications	04
ASA - classification	14
Third molar extraction and complications	18
TMD's and splint types and Bruxism	26
Jaw cysts and tumors	41
LA techniques and complications	59
Pyogenic granuloma	83
Retained Roots/ Odontomas/ Radiopacities of Jaw	88
Oro-antral communication and fistula	94
Suture and Suture Techniques	104

## EXODONTIA - PROCEDURE, RISK AND COMPLICATION

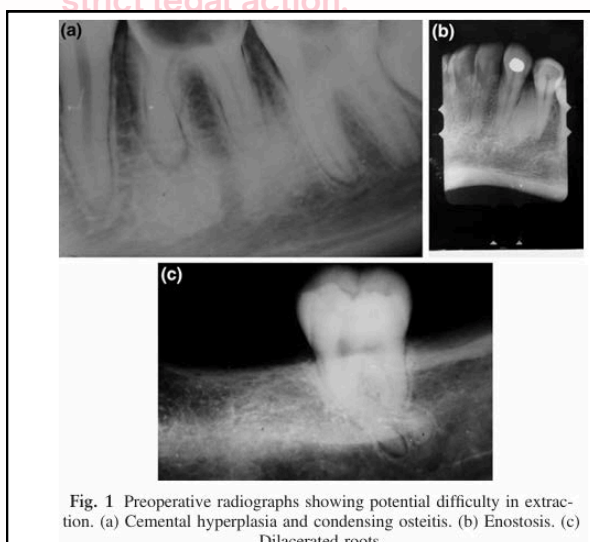
(Sources: Contemporary exodontia (ADJ), Dental extraction in a patient with undiagnosed Von Willebrand's Disease: a case report (ADJ), Principles of Exodontia Part 4 Dr. Hamid Hammad Enezei)

- Exodontia is a cardinal skill of all dentist and Patients expect extractions to be skillfully and painlessly accomplished every time.
- However, Extractions are not necessarily simple and can be challenging.
- All surgical procedure requires careful consideration of the harm and benefits which requires a full diagnostic process of history and examination and special tests.

**Table 1. Harm benefit analysis for surgical procedures – Exodontia**

	Benefit	Harm
Procedure performed		
Exodontia	control pain resolves problem	incomplete procedure dry socket damage
Procedure not performed		
No Extraction	saves tooth avoids procedure avoids complications	spreading infection later complications

- Pre extraction radiographs will confirm the diagnosis and indicate factors of potential difficulty. Pulpal sensibility and assessment of the periodontium can be invaluable additional pieces of information.



**Fig. 1** Preoperative radiographs showing potential difficulty in extraction. (a) Cemental hyperplasia and condensing osteitis. (b) Enostosis. (c) Dilacerated roots.

### Objective of Exodontia

- To remove the whole tooth whilst preserving the alveolus for future prosthetics or implants.

#### DISCLAIMER

THIS IS COPYRIGHTED CONTENT. Unauthorized use, including screenshots, copying, misuse, reuse, or resale of any content from this app, is strictly prohibited. Our app monitors and records all screenshots and recordings. Violators will face strict legal action.

**DISCLAIMER**  
THIS IS COPYRIGHTED CONTENT. Unauthorized use, including screenshots, copying, misuse, reuse, or resale of any content from this app, is strictly prohibited. Our app monitors and records all screenshots and recordings. Violators will face strict legal action.

## EXODONTIA - PROCEDURE, RISK AND COMPLICATION

Consideration of tooth for extraction should be done at:

### i. At the level of the individual tooth:

- The decision to extract tooth is straightforward in presence of gross decay, advanced periodontal disease and fracture.
- It is mandatory that a proper history and examination are undertaken to exclude referred pain from cramped masticatory muscles or sinus disease as causes of maxillary tooth pain.
- Trigeminal neuralgia also mimics tooth ache which should be carefully diagnosed.
- Dentists should not take out teeth on the insistence of patients in the absence of a clear-cut diagnosis.
- A surgeon who removed a normal body part because the patient demanded it would justifiably be sued.
- If the patient returns and demands another extraction or root filling because the pain is still there, they mandatorily need to be carefully reevaluated or referred for advice.

### ii. At patient's mouth

- Common indications for extraction of normal teeth, but at a mouth level, include orthodontic extractions where there is a tooth size/jaw size discrepancy or as part of a prosthodontic plan.

### iii. Overall patient's health

- Management of oncology patients does sometimes involve the extraction of compromised but individually savable teeth for patients undergoing head and neck radiotherapy or chemotherapy including intravenous antiresorptive agents.
- Only looking at individual tooth level is a common failing and should not be done.

THIS IS COPYRIGHTED  
CONTENT. Unauthorized use,  
including screenshots,  
copying, misuse, reuse, or  
resale of any content from  
this app, is strictly prohibited.  
Our app monitors and records  
all screenshots and  
recordings. Violators will face  
strict legal action.

#### DISCLAIMER

THIS IS COPYRIGHTED CONTENT. Unauthorized use, including screenshots, copying, misuse, reuse, or resale of any content from this app, is strictly prohibited. Our app monitors and records all screenshots and recordings. Violators will face strict legal action.

DISCLAIMER  
THIS IS COPYRIGHTED CONTENT. Unauthorized use, including screenshots, copying, misuse, reuse, or resale of any content from this app, is strictly prohibited. Our app monitors and records all screenshots and recordings. Violators will face strict legal action.



## EXODONTIA - PROCEDURE, RISK AND COMPLICATION

### Technique for extraction:

- After the decision to extract the tooth is made, the initial concern is pain control for the procedure.
- **Multiple choices are available for pain control:**
  - i. local anesthesia (LA)
  - ii. LA + oral sedation
  - iii. LA + IV sedation in rooms or in hospital or day stay general anesthetic (GA).
- A harm/benefit analysis needs to be applied to each and **most commonly local anesthesia** is the technique employed but this is not without complication.
- To facilitate the extraction of tooth without much damage to the alveolus, fine periostomes are used. Fine periostomes which are carefully inserted down the periodontal membrane to split it and gently expand the socket.

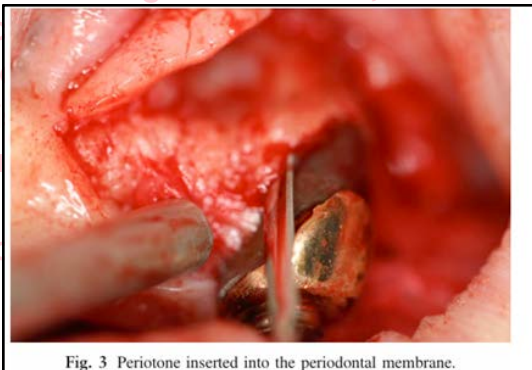


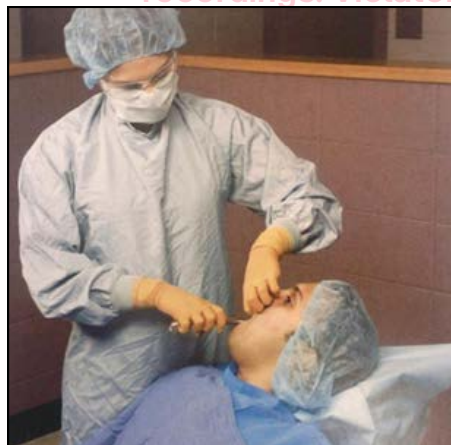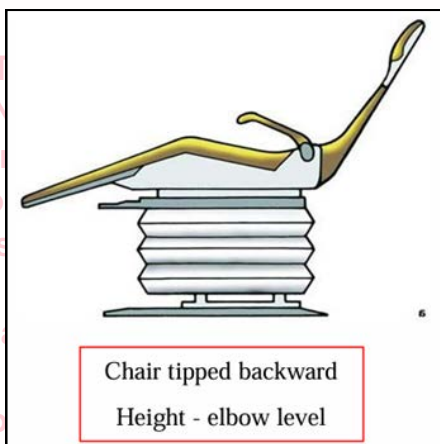
Fig. 3 Periostome inserted into the periodontal membrane.

### Position of Chair and dentist during extraction:

#### A) Chair position:

##### i. For maxillary teeth:

- The chair should be tipped backward so that when the patient opens his mouth the occlusal plane is at an angle of about 60 degrees to the floor.
- The height of the chair should be in such a way that patient's mouth is at or slightly below the operator's elbow level.



#### DISCLAIMER

THIS IS COPYRIGHTED CONTENT. Unauthorized use, including screenshots, copying, misuse, reuse, or resale of any content from this app, is strictly prohibited. Our app monitors and records all screenshots and recordings. Violators will face strict legal action.

#### DISCLAIMER

THIS IS COPYRIGHTED CONTENT. Unauthorized use, including screenshots, copying, misuse, reuse, or resale of any content from this app, is strictly prohibited. Our app monitors and records all screenshots and recordings. Violators will face strict legal action.

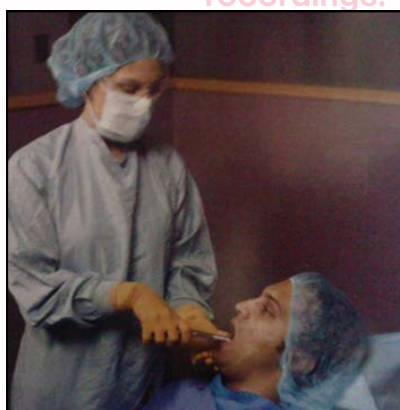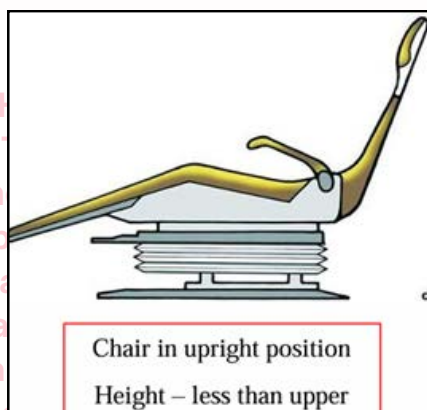
# EXODONTIA - PROCEDURE, RISK AND COMPLICATION

## Position of Chair and dentist during extraction:

### A) Chair position:

#### ii. For Mandibular teeth:

- The chair should be in more upright position so that when the patient opens his mouth, the occlusal plane is parallel to the floor.
- The height of the chair should be lower than for upper teeth which provide stable comfortable position.



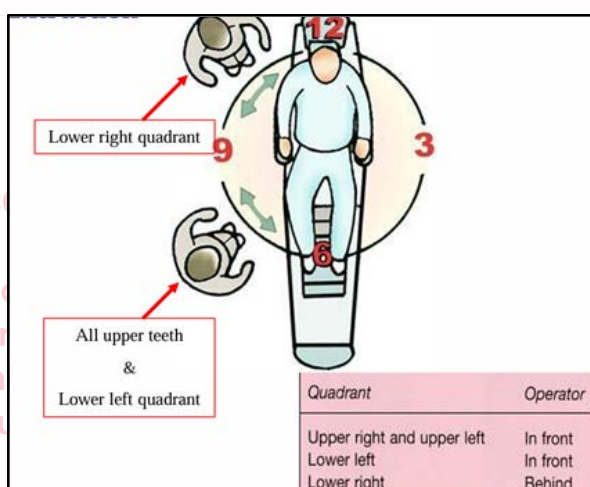
### B) Position Of Dentist:

#### i. For maxillary teeth:

- For all maxillary teeth (left & right) the dentist should stand in front of the patient and to the right side during the extraction.

#### i. For mandibular teeth:

- For left quadrant, the dentist should stand in front of the patient to the right side. (For right-handed operator)
- For right quadrant, the dentist should stand behind the patient in the right side.



#### Note:

- 1 These positions are for a standing, right handed dentist, while for seated position or left handed dentist modifications required.
- 2 During extraction the left hand plays an important role in
  - A- Providing support and stability for the alveolar process and the jaw.
  - B- Provide tactile information to the surgeon regarding the progress of extraction.
  - C- Reflection of the soft tissues like lip, cheek, or tongue.

#### DISCLAIMER

THIS IS COPYRIGHTED CONTENT. Unauthorized use, including screenshots, copying, misuse, reuse, or resale of any content from this app, is strictly prohibited. Our app monitors and records all screenshots and recordings. Violators will face strict legal action.

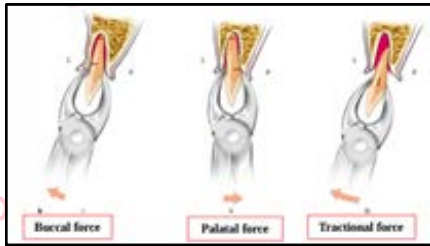
DISCLAIMER  
THIS IS COPYRIGHTED CONTENT. Unauthorized use, including screenshots, copying, misuse, reuse, or resale of any content from this app, is strictly prohibited. Our app monitors and records all screenshots and recordings. Violators will face strict legal action.

# EXODONTIA - PROCEDURE, RISK AND COMPLICATION

## Movement of tooth:

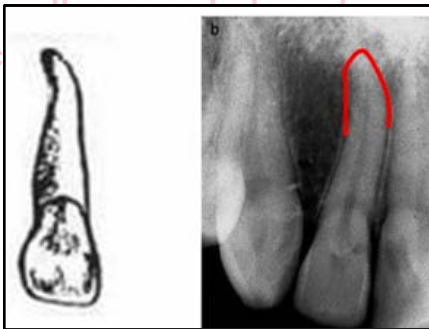
### 1. Maxillary Central Incisors:

- The initial movements are in a labial direction, and then palatal. Since the root is conical in shape, rotational forces are applied and the final extraction force is applied labially.



### 2. Maxillary lateral incisors:

- The same technique as for central incisors, the difference is that the extraction movements are labial and palatal only without rotational force because it has curvature of the root tip palato-distally.



### 3. Maxillary canine:

- The extraction technique is the same for lateral incisors with some degree of difficulty due to:
  - Their firm anchorage in alveolar bone.
  - The roots are long with frequent curvature of the root tip.
  - The labial surface of the root is covered by thin alveolar bone, so there is a risk of fracturing the alveolar process.

### 4. Maxillary premolar:

- For the **first premolar**, because it usually has two roots, buccal and palatal pressure should be gentle and slight. If movements are vigorous and abrupt, there is a risk of fracturing the root tips. Rotational motions are not allowed due to the tooth's anatomy.
- For the **second premolar** the extraction is easier, because the tooth mostly has one root.
- The final movement for both teeth is buccal.

## DISCLAIMER

THIS IS COPYRIGHTED CONTENT. Unauthorized use, including screenshots, copying, misuse, reuse, or resale of any content from this app, is strictly prohibited. Our app monitors and records all screenshots and recordings. Violators will face strict legal action.

DISCLAIMER

THIS IS COPYRIGHTED CONTENT. Unauthorized use, including screenshots, copying, misuse, reuse, or resale of any content from this app, is strictly prohibited. Our app monitors and records all screenshots and recordings. Violators will face strict legal action.

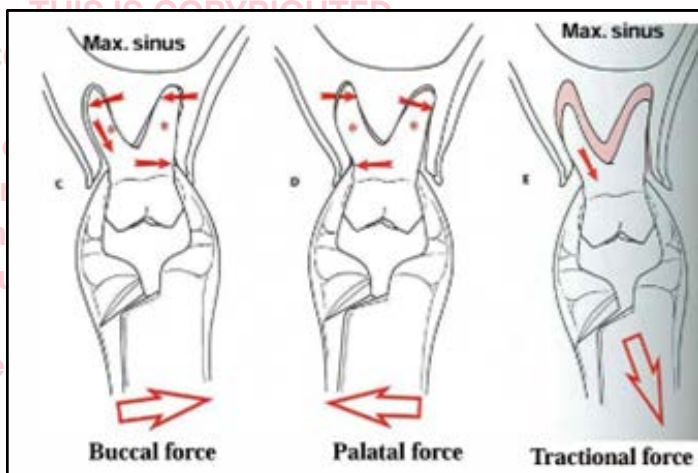


## EXODONTIA - PROCEDURE, RISK AND COMPLICATION

### Movement of tooth:

#### 5. Maxillary First Molar:

- The maxillary first molar has three diverging roots, and the tooth is firmly anchored in the alveolar bone, therefore this tooth requires the application of strong force during its extraction, which may cause fracture of the crown or root tips.
- To avoid tooth fracture, initial movements must be gentle, with bucco palatal pressure and an increasing range of motion, especially buccally, where resistance is less. The final extraction movement is a buccal curved motion.



#### 6. Maxillary second molar:

- The same as for maxillary first molars because the teeth have similar anatomy, however, it is easier because of little divergence of the roots and quite often are fused together in a conical shape.

#### 7. Maxillary Third molars:

- If the third molar has erupted completely its extraction is accomplished by applying buccal pressure and very gentle palatal pressure. Root anatomy of the third molar may permit extraction using elevator only. The elevator is positioned in the mesio-buccal corner.

#### 8. Mandibular incisors and canines.:

- Extraction of mandibular incisors is easy, due to their morphology (narrow, single roots) and the thin labial alveolar bone surrounding the root.
- Mandibular canines are more difficult to extract compared to incisors, due to the long root and frequent curvature of the root tip.
- Pressure is applied labially and lingually, gradually increasing in intensity, only slight rotational force is permitted. The final extraction movement is outwards and downwards (to avoid damaging opposing teeth)

#### DISCLAIMER

THIS IS COPYRIGHTED CONTENT. Unauthorized use, including screenshots, copying, misuse, reuse, or resale of any content from this app, is strictly prohibited. Our app monitors and records all screenshots and recordings. Violators will face strict legal action.

DISCLAIMER

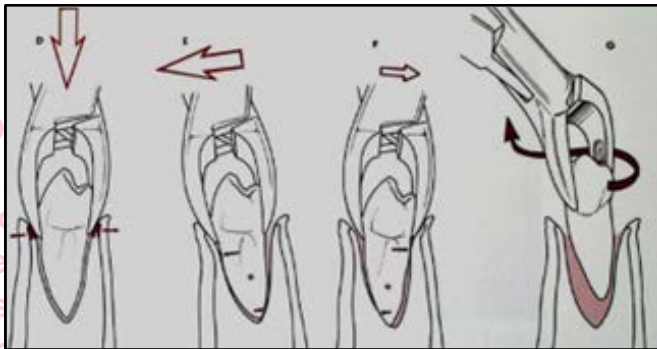
THIS IS COPYRIGHTED CONTENT. Unauthorized use, including screenshots, copying, misuse, reuse, or resale of any content from this app, is strictly prohibited. Our app monitors and records all screenshots and recordings. Violators will face strict legal action.

## EXODONTIA - PROCEDURE, RISK AND COMPLICATION

### Movement of tooth:

#### 9. Mandibular Premolars:

- Premolar extraction is considered quite easy because their roots are straight and conical.
- Buccolingual force is applied for extraction of these teeth. Gentle rotational force may also be applied.
- The final extraction movement is outwards and downwards.

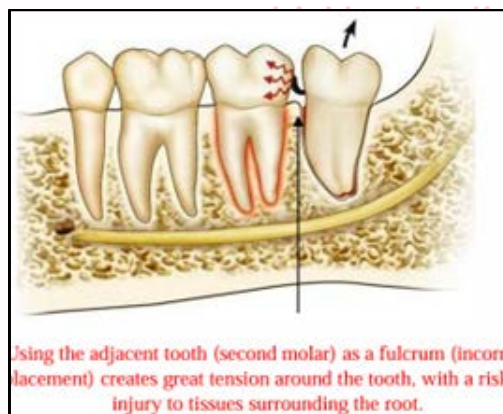
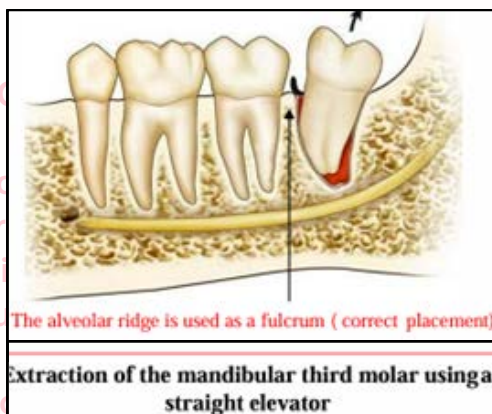


#### 10. Mandibular molars (First and second)

- The mandibular second molar has a morphology similar to that of the first molar, but its removal is more easily than the first molar, because its roots are smaller and less divergent.
- Initially the movements are gentle with buccal and lingual pressure. After the tooth is slightly mobilized, force is gradually increased and the final extraction movement is buccal (outward & downward).

#### 11. Mandibular Third molars:

- Buccolingual pressure is applied, but since the lingual alveolar bone is very thin compared to the buccal alveolar bone, therefore, the force that mobilizes the tooth must be more in the lingual direction.
- If the third molar has one root or if the roots converge, the extraction may be accomplished using the straight elevator alone.



strict legal action.

#### DISCLAIMER

THIS IS COPYRIGHTED CONTENT. Unauthorized use, including screenshots, copying, misuse, reuse, or resale of any content from this app, is strictly prohibited. Our app monitors and records all screenshots and recordings. Violators will face strict legal action.

DISCLAIMER

THIS IS COPYRIGHTED CONTENT. Unauthorized use, including screenshots, copying, misuse, reuse, or resale of any content from this app, is strictly prohibited. Our app monitors and records all screenshots and recordings. Violators will face strict legal action.

## EXODONTIA - PROCEDURE, RISK AND COMPLICATION

### Movement of tooth:

#### 12. Extraction of deciduous tooth:

- The forceps used to extract deciduous teeth are small and have narrow beaks.
- The extraction technique is similar to that used for permanent teeth and it is much easier, especially if their roots are resorbed.
- The beaks of the forceps must be positioned on the mesial or the distal area of the tooth and not the center (root bifurcation), underneath which is the permanent tooth to prevent damage to tooth bud.

### Complications of Exodontia:

- Complications are unforeseen and unexpected adverse sequelae from a surgical procedure.
  - A patient who bleeds after an extraction but has a known bleeding diathesis is not really a complication but a failure of planning.
  - Mandibular fracture after an attempt at elevator only extraction of the molar, in an elderly patient, with a grossly atrophic jaw, is a failure of planning and consent
1. The **most common complication** of exodontia is alveolar osteitis or **dry socket**. Here, common condition the blood clot undergoes fibrinolysis and the bony walls of the socket become exposed. This is a painful but self-limiting condition which resolves in 2–3 weeks. The incidence is 3–5% of extractions with risk factors being traumatic extraction, smoking, posterior teeth and mandible more than maxilla, but it is usually unpredictable.
  2. Penetration into or loss of tooth roots into the sinus must always be considered in the extraction of posterior maxillary teeth.
    - After extraction of such teeth check carefully that they are complete. Check for the presence of an oro-antral communication by holding the patient's nose and getting them to blow, listen for any passage of air or bubbles.
    - If the tooth is intact and the communication small, compress the socket and suture closed. Tell the patient not to blow their nose or create a negative pressure. Discuss fully with the patient the reason for this sometimes-distressing complication. If the communication is large, more than 4 mm or a piece of tooth is missing, promptly refer to an Oral and Maxillofacial Surgeon (OMS).
    - A two-layer mucoperiosteal flap with a buccal fat pad graft is useful for large communication.
  3. Tooth or root displacement, beyond the alveolus into the soft tissues, is usually a sign of excessive or misdirected force, don't ignore this as the probability of infection is high.
    - Promptly refer to an OMS for imaging to localize the tooth and retrieve it.

#### DISCLAIMER

THIS IS COPYRIGHTED CONTENT. Unauthorized use, including screenshots, copying, misuse, reuse, or resale of any content from this app, is strictly prohibited. Our app monitors and records all screenshots and recordings. Violators will face strict legal action.



## EXODONTIA - PROCEDURE, RISK AND COMPLICATION

### Complications of Exodontia:

4. If the tooth breaks or can't be removed and this should be considered as a failure of the decision-making process as much as a technique failure. Most experienced surgeons often start out an extraction as a surgical procedure, raising a mucoperiosteal flap and sectioning the tooth as this provides much greater control and is more swifter and less pressure is required.

5. If a root tip fractures:

- Firstly, consider leaving it there if it is vital, less than 5 mm and in proximity to a vital structure such as a nerve.
- If you can, remove it through a small bony window by maintaining alveolar bone height.

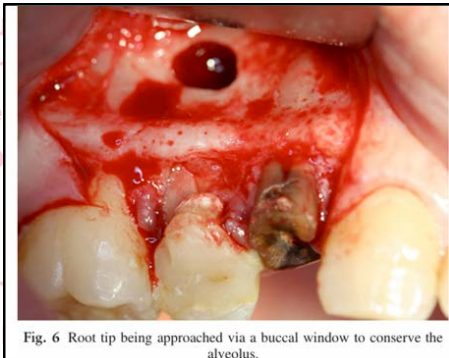


Fig. 6 Root tip being approached via a buccal window to conserve the alveolus.

6. Hemorrhage can be a challenging complication to manage. This is particularly relevant in patients with undiagnosed or underlying bleeding disorders.

- Bleeding disorders or coagulopathies can be classified as congenital or acquired.
- Congenital coagulopathies are typically related to genetic disorders, such as hemophilia and vonWillebrand Disease (vWD).
- Acquired conditions are often secondary to the use of anticoagulant/antiplatelet medications or systemic diseases.
- While acquired coagulopathies may be identified by taking a comprehensive medical history, congenital disorders often remain undetected in asymptomatic individuals.
- Von Willebrand Disease is the most common inherited bleeding disorder in humans.
- The importance of screening for bleeding disorders if any hemorrhagic activity occurs is well known.
- To control a hemorrhagic activity following can be done:
  - i. Direct pressure with non-resorbable gauze remains the gold standard in providing first aid to a bleeding wound.
  - ii. Skillful use of good lighting, magnification and high-volume suction can assist in visualization of the bleeding source.

### DISCLAIMER

THIS IS COPYRIGHTED CONTENT. Unauthorized use, including screenshots, copying, misuse, reuse, or resale of any content from this app, is strictly prohibited. Our app monitors and records all screenshots and recordings. Violators will face strict legal action.

### DISCLAIMER

THIS IS COPYRIGHTED CONTENT. Unauthorized use, including screenshots, copying, misuse, reuse, or resale of any content from this app, is strictly prohibited. Our app monitors and records all screenshots and recordings. Violators will face strict legal action.



## EXODONTIA - PROCEDURE, RISK AND COMPLICATION

### Complications of Exodontia:

6. • To control a hemorrhagic activity following can be done:
  - iii. This allows for direct injection of adrenaline containing local anesthetic agents for their vasoconstrictive properties or the use of electro cautery if available
  - iv. Absorbable materials, such as porcine gelatin sponge and oxidized cellulose, may be used to initiate primary hemostasis and stabilize the blood clot.
  - v. These materials are generally safe for use in the oral cavity.
  - vi. Sutures may be used to achieve primary closure of the wound or hold non-resorbable gauze over the socket for a number of days to provide an additional tamponade effect.
  - vii. Bone wax is a traditional hemostatic agent, composed of a sterile mixture of beeswax and isopropyl palmitate. Its hemostatic effect is by acting as a physical barrier and creating a tamponade on bleeding bone. Although adverse effects are rare, bone wax is a foreign body and can be associated with granulomatous reaction and increased risk of infection.
  - viii. Surgicel (Ethicon) is a resorbable plant derived oxidized cellulose polymer that provides a scaffold for platelet adhesion and aggregation. It should be noted that surgicel can be neurotoxic and should not be placed directly over the neurovascular bundle.
  - xi. Floseal (Baxter ) is a gelatin-thrombin mixture sealant and effective adjunct to hemostasis for coagulopathic patients. It is frequently used in head and neck surgery.
  - x. Tranexamic acid is a useful antifibrinolytic agent. A 5% solution may be applied topically with gauze over a wound for five minutes or by rinsing in the mouth postoperatively for 2 min, four times daily.
  - xi. Tranexamic acid 4.8% mouthwash can be compounded by pharmacies. If this is not available, alternative solution can be prepared by crushing a 500 mg tablet and dispersing it in 10 mL of water immediately before administration.
  - xii. Ideally, a dental practice should have multiple hemostatic adjuncts available for use in case of emergency.
  - xiii. Patients with uncontrollable bleeding or symptoms inadequate end-organ perfusion, including altered mental status, dyspnea, palpitations or chest pain should be rapidly transferred to the local emergency department. Hospitals and Oral and Maxillofacial clinics will be able to provide definitive care.

#### DISCLAIMER

THIS IS COPYRIGHTED CONTENT. Unauthorized use, including screenshots, copying, misuse, reuse, or resale of any content from this app, is strictly prohibited. Our app monitors and records all screenshots and recordings. Violators will face strict legal action.

## ASA CLASSIFICATION

(Source- Statement on ASA Physical Status Classification System)

- The ASA Physical Status Classification System has been in use for over 60 years.
- The purpose of the system is to assess and communicate a patient's pre-anesthesia medical co-morbidities.
- The classification system alone does not predict the perioperative risks, but when used with other factors (like type of surgery, frailty, level of deconditioning), it can be helpful in predicting perioperative risks.
- Assigning a Physical Status classification level is a clinical decision based on multiple factors.
- While the Physical Status classification may initially be determined at various times during the preoperative assessment of the patient, the final assignment of Physical Status classification is made on the day of anesthesia care by the anesthesiologist after evaluating the patient.

### ASA CLASSIFICATION WITH EXAMPLES

#### 1. ASA I:

- A normal healthy patient.
- Examples:
  - a) For Adult Patients: Healthy, non-smoking, no or minimal alcohol use.
  - b) For pediatric patients: Healthy (no acute or chronic disease), normal BMI percentile for age.

#### 2. ASA II:

- A patient with mild systemic disease.
- Examples including but not limited to:
  - a) For Adult patients: Mild diseases only without substantive functional limitations. Like, *Current smoker, social alcohol drinker, pregnancy, obesity (30<BMI<40), well-controlled DM/HTN, mild lung disease.*
  - b) For pediatric patients:
    - Asymptomatic congenital cardiac disease,
    - well controlled dysrhythmias,
    - asthma without exacerbation,
    - well controlled epilepsy,
    - non-insulin dependent diabetes mellitus
    - abnormal BMI percentile for age,
    - mild/moderate OSA,
    - oncologic state in remission,
    - autism with mild limitations

#### DISCLAIMER

THIS IS COPYRIGHTED CONTENT. Unauthorized use, including screenshots, copying, misuse, reuse, or resale of any content from this app, is strictly prohibited. Our app monitors and records all screenshots and recordings. Violators will face strict legal action.

DISCLAIMER  
THIS IS COPYRIGHTED CONTENT. Unauthorized use, including screenshots, copying, misuse, reuse, or resale of any content from this app, is strictly prohibited. Our app monitors and records all screenshots and recordings. Violators will face strict legal action.

## ASA CLASSIFICATION

### 2. ASA II:

- Examples including but not limited to:

#### c) Obstetric patients:

- Normal pregnancy\*: **Although pregnancy is not a disease**, the parturient's physiologic state is significantly altered from when the woman is not pregnant, hence the assignment of **ASA 2 for a woman with uncomplicated pregnancy**.
- Well controlled gestational HTN
- Controlled preeclampsia without severe features
- Diet-controlled gestational DM.

### 3. ASA III:

- A patient with severe systemic disease.

- Examples including but not limited to:

#### a) For Adult patients:

- Substantive functional limitations,
- One or more moderate to severe diseases.
- Poorly controlled DM or HTN, COPD.
- morbid obesity (BMI  $\geq 40$ )
- active hepatitis
- alcohol dependence or abuse
- implanted pacemaker
- moderate reduction of ejection fraction
- ESRD undergoing regularly scheduled dialysis.
- History of (>3 months) of MI, CVA, TIA, or CAD/stents.

#### b) For pediatric patients:

- Uncorrected stable congenital cardiac abnormality
- asthma with exacerbation
- poorly controlled epilepsy
- insulin dependent diabetes mellitus
- morbid obesity
- Malnutrition
- severe OSA
- oncologic state,
- renal failure, muscular dystrophy, cystic fibrosis.
- history of organ transplantation,
- brain/spinal cord malformation,
- symptomatic hydrocephalus
- premature infant PCA <60 weeks
- autism with severe limitations
- metabolic disease
- difficult airway
- long term parenteral nutrition.
- Full term infants <6 weeks of age.

#### DISCLAIMER

THIS IS COPYRIGHTED CONTENT. Unauthorized use, including screenshots, copying, misuse, reuse, or resale of any content from this app, is strictly prohibited. Our app monitors and records all screenshots and recordings. Violators will face strict legal action.

DISCLAIMER  
THIS IS COPYRIGHTED CONTENT. Unauthorized use, including screenshots, copying, misuse, reuse, or resale of any content from this app, is strictly prohibited. Our app monitors and records all screenshots and recordings. Violators will face strict legal action.

## ASA CLASSIFICATION

### 3. ASA III:

- Examples including but not limited to:
  - c) **Obstetric patients:**
    - Preeclampsia with severe features
    - gestational DM with complications or high insulin requirements
    - A thrombophilic disease requiring anticoagulation.

### 4. ASA IV:

- A patient with severe systemic disease that is a constant threat to life.
- Examples, including but not limiting to:
  - a) **For Adult patients:**
    - Recent (<3 months) MI, CVA, TIA or CAD/stents
    - Ongoing cardiac ischemia or severe valve dysfunction
    - severe reduction of ejection fraction
    - shock, sepsis, DIC, ARD or ESRD not undergoing regularly scheduled dialysis
  - b) **For pediatric patients:**
    - Symptomatic congenital cardiac abnormality
    - congestive heart failure
    - active sequelae of prematurity
    - acute hypoxic-ischemic encephalopathy
      - shock
      - sepsis, disseminated intravascular coagulation,
      - automatic implantable cardioverter-defibrillator
      - ventilator dependence
      - Endocrinopathy
      - severe trauma
      - severe respiratory distress
      - advanced oncologic state
  - c) **Obstetric patients:**
    - Preeclampsia with severe features complicated by HELLP or other adverse event
    - peripartum cardiomyopathy with EF <40,
    - uncorrected/decompensated heart disease, acquired or congenital.

#### DISCLAIMER

THIS IS COPYRIGHTED CONTENT. Unauthorized use, including screenshots, copying, misuse, reuse, or resale of any content from this app, is strictly prohibited. Our app monitors and records all screenshots and recordings. Violators will face strict legal action.

DISCLAIMER  
THIS IS COPYRIGHTED CONTENT. Unauthorized use, including screenshots, copying, misuse, reuse, or resale of any content from this app, is strictly prohibited. Our app monitors and records all screenshots and recordings. Violators will face strict legal action.



## ASA CLASSIFICATION

### 5. ASA V:

- A moribund patient who is not expected to survive without the operation.
- Examples, including but not limiting to:
  - a) For Adult patients:
    - Ruptured abdominal/thoracic aneurysm
    - massive trauma
    - intracranial bleed with mass effect
    - ischemic bowel in the face of significant cardiac pathology or multiple organ/system dysfunction.

#### b) For pediatric patients:

- Massive trauma
- intracranial hemorrhage with mass effect
- patient requiring ECMO
- respiratory failure or arrest
- malignant hypertension
- decompensated congestive heart failure
- hepatic encephalopathy
- ischemic bowel or multiple organ/system dysfunction.

#### c) Obstetric patients:

- Uterine rupture.

### 6. ASA VI:

- A declared brain-dead patient whose organs are being removed for donor purposes.

THIS IS COPYRIGHTED CONTENT. Unauthorized use, including screenshots, copying, misuse, reuse, or resale of any content from this app, is strictly prohibited. Our app monitors and records all screenshots and recordings. Violators will face strict legal action.

#### DISCLAIMER

THIS IS COPYRIGHTED CONTENT. Unauthorized use, including screenshots, copying, misuse, reuse, or resale of any content from this app, is strictly prohibited. Our app monitors and records all screenshots and recordings. Violators will face strict legal action.

DISCLAIMER  
THIS IS COPYRIGHTED CONTENT. Unauthorized use, including screenshots, copying, misuse, reuse, or resale of any content from this app, is strictly prohibited. Our app monitors and records all screenshots and recordings. Violators will face strict legal action.

## THIRD MOLAR EXTRACTION AND COMPLICATION

Sources: Consent for third molar tooth extractions in Australia and New Zealand: a review of current practice (ADJ article), The extraction of first, second or third permanent molar teeth and its effect on the dentofacial complex (ADJ article), The contemporary management of third molars (ADJ article)

- The management of third molars requires a significant assessment and decision process both for the patient and the clinician.
- The third molar tooth (M3) is the last to appear and is the most variable tooth affected by morphology, eruption period and oligodontia/hypodontia.
- Wisdom teeth are the most likely to undergo impaction (incomplete eruption in the presence of a fully grown root), which occurs when there is inadequate space in the mouth, if there is an impediment by another tooth or if the tooth has developed in an abnormal position.
- The impacted tooth is generally trouble free and covered totally or partially by soft tissue, bone or a combination of the two.
- Third molars can be classified as: (as per recent literature)
  - a) Disease positive and disease negative and
  - b) Symptom positive and negative

**Table 1. Classification systems**

	Disease Positive	Disease Negative
Symptom Positive	S+/D+	S+/D-
Symptom Negative	S-/D+	S-/D-

THIS IS COPYRIGHTED CONTENT. Unauthorized use, including screenshots, copying, misuse, reuse, or resale of any content from this app, is strictly prohibited. Our app monitors and records all screenshots and recordings. Violators will face strict legal action.

### DISCLAIMER

THIS IS COPYRIGHTED CONTENT. Unauthorized use, including screenshots, copying, misuse, reuse, or resale of any content from this app, is strictly prohibited. Our app monitors and records all screenshots and recordings. Violators will face strict legal action.

DISCLAIMER  
THIS IS COPYRIGHTED CONTENT. Unauthorized use, including screenshots, copying, misuse, reuse, or resale of any content from this app, is strictly prohibited. Our app monitors and records all screenshots and recordings. Violators will face strict legal action.

## THIRD MOLAR EXTRACTION AND COMPLICATION

- According to their symptom and disease status removal of third molars can be grouped as:

**Table 2. Indication for the removal of third molars grouped according to symptom and disease status**

Classification	Disease	Treatment
Symptom Positive & Disease Positive	<ul style="list-style-type: none"> <li>Unrestorable Caries</li> <li>Periapical Pathology</li> <li>Pericoronitis</li> <li>Odontogenic Infection</li> </ul>	
Symptom Negative & Disease Positive	<ul style="list-style-type: none"> <li>Periodontitis</li> <li>Pathology</li> <li>Food Trapping</li> <li>Root Resorption</li> </ul>	<p><b>Timeframe:</b> Treat immediately</p> <p><b>Treatment Options:</b></p> <ol style="list-style-type: none"> <li>1. Surgically Remove</li> <li>2. Coronectomy (only if necessary)</li> <li>3. Oral Hygiene Instruction</li> </ol>
Symptom Negative & Disease Negative	<ul style="list-style-type: none"> <li>In a fracture line</li> <li>Un-restorable / fractured</li> <li>Associated with orthognathic surgery</li> <li>Pre-orthodontics</li> <li>Prosthodontic inhibitor</li> <li>As part of a tumour resection</li> <li>To allow access and maintenance of adjacent teeth</li> </ul>	
	<ul style="list-style-type: none"> <li>Post orthodontics</li> <li>In conjunction with other oral surgery</li> <li>Elite athletes</li> <li>Military and scientific personnel</li> <li>Premedication assessments</li> <li>Pre geriatric assessments</li> <li>Persistent bacteraemia</li> <li>Mild periodontal disease</li> </ul>	<p><b>Timeframe:</b> Utilise the third molar decision matrix</p>

THIS IS COPYRIGHTED CONTENT. Unauthorized use, including screenshots, copying, misuse, reuse, or resale of any content from this app, is strictly prohibited. Our app monitors and records all screenshots and recordings. Violators will face strict legal action.

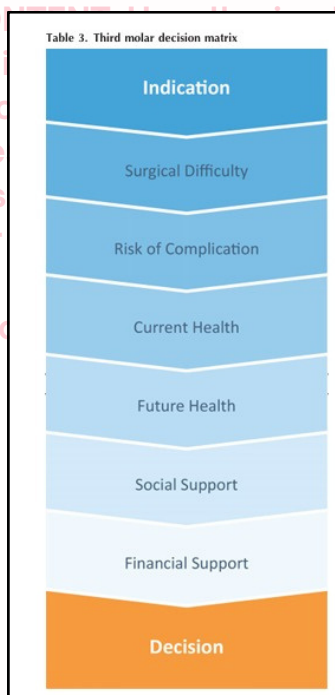
### DISCLAIMER

THIS IS COPYRIGHTED CONTENT. Unauthorized use, including screenshots, copying, misuse, reuse, or resale of any content from this app, is strictly prohibited. Our app monitors and records all screenshots and recordings. Violators will face strict legal action.

**DISCLAIMER**  
THIS IS COPYRIGHTED CONTENT. Unauthorized use, including screenshots, copying, misuse, reuse, or resale of any content from this app, is strictly prohibited. Our app monitors and records all screenshots and recordings. Violators will face strict legal action.

## THIRD MOLAR EXTRACTION AND COMPLICATION

- The decision to **remove a symptom positive/disease positive** third molar is **straight forward**. This decision would only be modified by a significant patient contraindication.
- The decision to remove a symptom positive/disease negative tooth is generally received favorably by both the surgical community and patient's alike.
- Surgeons are often asked to assess and manage the symptom free third molar.
- There is now considerable evidence to support the removal of symptom free/disease positive third molars in young adults.
- The symptom/disease free third molar which are either not in line of occlusion is difficult and challenging for clinicians **and the decision matrix depends on the following:**



1. The decision matrix for the removal of the third molars should always begin with an indication.
2. **Indications** for removal of third molars are based on disease and symptoms status as summarized in above table.
3. Once an indication has been identified, the decision to proceed to surgery will be modified by the surgical difficulty along with the procedural risk of a permanent complication.
4. The patient's current health and future health will then modify the decision further. The final modifying factors include the patient's social support mechanisms and financial capacities.
5. The indications for removal where the patient is symptom free but disease positive are worth further examination.
6. There are also indications where the patient is both symptom negative and disease negative, **which is known as prophylactic removal of third molars.**

### DISCLAIMER

THIS IS COPYRIGHTED CONTENT. Unauthorized use, including screenshots, copying, misuse, reuse, or resale of any content from this app, is strictly prohibited. Our app monitors and records all screenshots and recordings. Violators will face strict legal action.

### DISCLAIMER

THIS IS COPYRIGHTED CONTENT. Unauthorized use, including screenshots, copying, misuse, reuse, or resale of any content from this app, is strictly prohibited. Our app monitors and records all screenshots and recordings. Violators will face strict legal action.



## THIRD MOLAR EXTRACTION AND COMPLICATION

### Prophylactic removal of third molar:

(Source: *The contemporary management of third molars*)

- The prophylactic removal of third molars can be divided into six main groups:

#### A) Sports or military patients:

- Contact sports
- Peak performance patient

#### B) Reduced physical dexterity:

- Tremors
- Neuromuscular disease

#### C) Altered mental capacity:

- Dementia
- Cognitive development

#### D) Pre medication:

- Bisphosphonates
- Anti-coagulants

#### E) Pre Treatment:

- Radiotherapy
- Chemotherapy

#### F) Immunomodifier therapy:

- Bacteremia
- Tissue transfer patients

- Once the clinician has decided that there is an indication for the removal of a tooth, they must then **assess the surgical risk of the procedure**.
- A common system for examining and predicting the difficulty of removal of third molars is the WHARFE system which considers:
  - W**– Winter's lines
  - H**– Height of mandible
  - A**– Angulation
  - R**– Root form
  - F**– Size of follicular sac
  - E**– Exit pathway of tooth.
- This schematic allows for a more thorough examination of the tooth and its radiology prior to its removal.
- An **additional assessment** is whether the **surgeon is capable** of providing the surgery. If a surgeon is incapable of providing the procedure, they **should refer the patient** for assessment to someone who can perform the surgery, so that there is no bias in the decision pathway, especially when conservative management is recommended.

#### DISCLAIMER

THIS IS COPYRIGHTED CONTENT. Unauthorized use, including screenshots, copying, misuse, reuse, or resale of any content from this app, is strictly prohibited. Our app monitors and records all screenshots and recordings. Violators will face strict legal action.

DISCLAIMER  
THIS IS COPYRIGHTED CONTENT. Unauthorized use, including screenshots, copying, misuse, reuse, or resale of any content from this app, is strictly prohibited. Our app monitors and records all screenshots and recordings. Violators will face strict legal action.

## THIRD MOLAR EXTRACTION AND COMPLICATION

- **Post-surgery complications** remain a significant determining factor for patients and clinicians both.
- When the patient is disease or symptom positive, the benefits of surgery are seen to outweigh the risks and surgery ensues. When the patient is asymptomatic, the equation becomes more difficult.
- The relevance of post-surgery complication decreases with surgeon experience. The more experienced the surgeon, the less likely a significant complication. This would suggest that for patients considering prophylactic surgery for asymptomatic teeth, the surgeon's experience is a factor of importance.

### Advantages and indications of third molar extraction:

1. Impaction associated with dental caries (in tractable carious lesion).
2. Periodontal defects close to the preceding molar.
3. Pericoronitis.
4. Odontogenic cyst.
5. Dental tumors.
6. Prophylactic removal of impacted M3 is also indicated for root resorption, crowding of lower incisors and damage to the adjacent tooth.

### Disadvantages of third molar extraction:

1. Increase in probing depth on the distobuccal aspect of the second molars and a reduction in attachment level after surgical removal of impacted mandibular third molar.
2. No appreciable gain in alveolar bone height after removal of the impacted M3 of second molars with distal bone loss due to M3 impaction.
3. One of ten patients after surgical removal experience associated complications that include; intense pain, swelling, hemorrhage, infection, alveolar osteitis, hematoma, lockjaw, alveolar nerve injury, oroantral communication, incomplete root removal, delayed healing, infected subperiosteal hematoma and bony spicule.
4. Although rare, 5 in 1000 patients over 25 years of age experience mandibular angle fracture after M3 extraction.
5. Patients commonly experience anxiety with the removal of M3, which has a significant impact on the outcome of the surgery due to the disturbed emotional state of the patient.

Table 2. Indications, disadvantages and proposed timing for extraction of molar teeth

Tooth/condition	First molar	Second molar	Third molar
Indications	Caries, endodontic problems, hypomineralization	Caries, ectopically eruption, severely rotated, orthodontic treatment	Caries, periodontal defects, pericoronitis, odontogenic cyst, dental tumours
Disadvantages	Shifting of the dental midline, change in chewing habits, periodontal problems, temporomandibular joint problems	Drifting of the adjacent teeth, supraeruption of unopposed teeth, poor gingival contours, poor interproximal contacts, reduced inter-radicular bone, pseudopockets	One of 10 patients faced with intense pain, swelling, haemorrhage, alveolar osteitis, haematoma, lockjaw, alveolar nerve injury
Changes in other molar position	Help in mandibular third molar eruption	Relieve malocclusions, facilitate eruption of the third molars, faster eruption of third molars, maxillary first molars could have move distally	Relieve crowding of lower incisors

- The prophylactic M3 extraction at younger age has a more positive prognosis.

### DISCLAIMER

THIS IS COPYRIGHTED CONTENT. Unauthorized use, including screenshots, copying, misuse, reuse, or resale of any content from this app, is strictly prohibited. Our app monitors and records all screenshots and recordings. Violators will face strict legal action.

DISCLAIMER  
THIS IS COPYRIGHTED CONTENT. Unauthorized use, including screenshots, copying, misuse, reuse, or resale of any content from this app, is strictly prohibited. Our app monitors and records all screenshots and recordings. Violators will face strict legal action.

## THIRD MOLAR EXTRACTION AND COMPLICATION

### Informed Consent for third molar extraction:

*(Source-Consent for third molar tooth extractions in Australia and New Zealand: a review of current practice (Article ADJ))*

- Informed consent is the legal requirement to educate a patient about a proposed medical treatment or procedures so that he or she can make informed decisions.
- It is one of the most important steps in the preoperative consultation, offering information on the treatment including a thorough explanation of the risks involved.
- It is also important in providing legal protection against complications and unforeseen circumstances that may arise during any medical treatment.
- Failure to gain valid consent can result in a claim for trespass, while failure to adequately disclose risk can be construed as negligence.
- There is no absolute guide about how much information to disclose as part of the consent process, but, according to contemporary Australian legislation, the doctor should provide what a reasonable patient would want to know and what that particular patient would want to know in light of their own values and interests.
- Consent must be given voluntarily by a competent patient who is adequately informed about the proposed treatment.
- For a patient to be competent, they must be able to understand the information provided to them and communicate their choice.
- Consent may be given in writing, verbally, or by implication.
- As per The National Health and Medical Research Council (NHMRC), the information that should be included in a informed consent includes:
  - a) The nature of the proposed treatment,
  - b) The risks and benefits,
  - c) Alternative treatment options,
  - d) The consequences of not proceeding, and
  - e) the person who will undertake the procedure.
- Risks to be disclosed include known risks that are common though slight, and rare though severe, as well as particular risks material to the patient.
- Information about a procedure can be written or given verbally.
- some of the potential complications of surgery include:
  - a) lingual and inferior alveolar nerve damage (temporary or permanent)
  - b) postoperative neuropathic pain;
  - c) alveolar osteitis; infection—not alveolar osteitis (general warning)
  - d) Excessive bleeding (general warning)
  - e) unexpected soft tissue injury (lip sores)
  - f) oroantral communication
  - g) bone fracture (general warning)

#### DISCLAIMER

THIS IS COPYRIGHTED CONTENT. Unauthorized use, including screenshots, copying, misuse, reuse, or resale of any content from this app, is strictly prohibited. Our app monitors and records all screenshots and recordings. Violators will face strict legal action.

#### DISCLAIMER

THIS IS COPYRIGHTED CONTENT. Unauthorized use, including screenshots, copying, misuse, reuse, or resale of any content from this app, is strictly prohibited. Our app monitors and records all screenshots and recordings. Violators will face strict legal action.



## THIRD MOLAR EXTRACTION AND COMPLICATION

### Informed Consent for third molar extraction:

(Source-Consent for third molar tooth extractions in Australia and New Zealand: a review of current practice (Article ADJ))

- Written consent for invasive procedures is standard practice in most Australian hospitals.
- A survey revealed the following results for the risk and disclosure of risk and complication for third molar extraction
- Various complications

**Table 1. Vascular, infective and neurological complications of third molar tooth extractions. Number (%) of respondents who routinely include or do not include the risk in their written consent, and total number of responders**

	Yes	No	Total
Excessive bleeding (general warning)	50 (71)	20 (29)	70
Excessive bleeding (specific warning)	12 (18)	56 (82)	68
– requiring additional surgery			
Alveolar osteitis	36 (53)	32 (47)	68
Infection, not alveolar osteitis (general warning)	59 (84)	11 (16)	70
Infection, not alveolar osteitis (specific warning) – deep fascial space involvement	12 (18)	54 (82)	66
Temporary inferior alveolar nerve injury	67 (97)	2 (3)	69
Permanent inferior alveolar nerve injury	67 (97)	2 (3)	69
Temporary lingual nerve injury	63 (91)	6 (9)	69
Permanent lingual nerve injury	60 (88)	8 (12)	68
Temporary nerve injury other than inferior alveolar/lingual nerve injury (any warning, including buccal nerve injury, mylohyoid nerve injury)	8 (11)	62 (89)	70
Permanent nerve injury other than inferior alveolar/lingual nerve injury (any warning, including buccal nerve injury, mylohyoid nerve injury)	5 (7)	63 (93)	68

**Table 3. Complications of third molar tooth extractions related to adjacent structures. Number (%) of respondents who routinely include or do not include the risk in their written consent, and total number of responders**

	Yes	No	Total
Oroantral communication and/or fistula	49 (69)	22 (31)	71
Oronasal communication and/or fistula	10 (14)	59 (86)	69
Temporomandibular joint complications (any warning)	29 (41)	42 (59)	71
Aspiration or ingestion (any warning, including of tooth, tooth fragment, other material or instrument)	4 (6)	67 (94)	71
Subcutaneous and/or tissue space emphysema	1 (1)	69 (99)	70

**Table 2. Technical complications of third molar tooth extractions. Number (%) of respondents who routinely include or do not include the risk in their written consent, and total number of responders**

	Yes	No	Total
Damage to adjacent tooth/teeth	42 (59)	29 (41)	71
Bone fracture (general warning)	28 (39)	43 (61)	71
Bone fracture (specific warning)	11 (16)	59 (84)	70
– Fracture of the alveolus			
Bone fracture (specific warning)	13 (19)	57 (81)	70
– Maxillary tuberosity fracture			
Bone fracture (specific warning)	25 (35)	46 (65)	71
– Mandibular jaw fracture			
Displacement of teeth or roots (general warning)	34 (48)	37 (52)	71
Displacement of teeth or roots (specific warning) – into the maxillary sinus	35 (49)	36 (51)	71
Displacement of teeth or roots (specific warning) – into fascial spaces	5 (7)	65 (93)	70
Displacement of teeth or roots (specific warning) – into the inferior alveolar nerve canal	6 (9)	64 (91)	70
Incomplete tooth/root removal	35 (49)	36 (51)	71
Wound dehiscence	24 (34)	47 (66)	71
Periodontal defects	16 (23)	55 (77)	71
Unexpected soft tissue injury (any warning, including lip or tongue laceration)	11 (15)	60 (85)	71
Bony sequestra	19 (27)	52 (73)	71

**DISCLAIMER**  
THIS IS COPYRIGHTED CONTENT. Unauthorized use, including screenshots, copying, misuse, reuse, or resale of any content from this app, is strictly prohibited. Our app monitors and records all screenshots and recordings. Violators will face strict legal action.

this app, is strictly prohibited. Our app monitors and records all screenshots and recordings. Violators will face strict legal action.

### DISCLAIMER

THIS IS COPYRIGHTED CONTENT. Unauthorized use, including screenshots, copying, misuse, reuse, or resale of any content from this app, is strictly prohibited. Our app monitors and records all screenshots and recordings. Violators will face strict legal action.



## THIRD MOLAR EXTRACTION AND COMPLICATION

- Consensus for the risk where disclosure is required as per Australian survey:

**Table 4. Consensus among surgeons that risk disclosure is required ( $\geq 80\%$  routinely include that risk in their written consent) or that risk disclosure is not required ( $\geq 80\%$  do not routinely include that risk)**

Consensus that risk disclosure is required	Consensus that risk disclosure is not required
Vascular, infective and neurological complications	
Infection, not alveolar osteitis (general warning)	Temporary nerve injury other than inferior alveolar/lingual nerve injury (any warning, including buccal nerve injury, mylohyoid nerve injury)
Temporary inferior alveolar nerve injury	Permanent nerve injury other than inferior alveolar/lingual nerve injury (any warning, including buccal nerve injury, mylohyoid nerve injury)
Permanent inferior alveolar nerve injury	Infection, not alveolar osteitis (specific warning) – deep fascial space involvement
Temporary lingual nerve injury	Excessive bleeding (specific warning) – requiring additional surgery
Permanent lingual nerve injury	
Technical complications	Bone fracture (specific warning) – fracture of the alveolus
	Bone fracture (specific warning) – maxillary tuberosity fracture
	Displacement of teeth or roots (specific warning) – into fascial spaces
	Displacement of teeth or roots (specific warning) – into the inferior alveolar nerve canal
	Unexpected soft tissue injury (any warning, including lip or tongue laceration)
Complications related to adjacent structures	
	Oronasal communication and/or fistula
	Aspiration or ingestion (any warning, including of tooth, tooth fragment, other material or instrument)
	Subcutaneous and/or tissue space emphysema

copying, misuse, reuse, or resale of any content from this app, is strictly prohibited. Our app monitors and records all screenshots and recordings. Violators will face strict legal action.

### DISCLAIMER

THIS IS COPYRIGHTED CONTENT. Unauthorized use, including screenshots, copying, misuse, reuse, or resale of any content from this app, is strictly prohibited. Our app monitors and records all screenshots and recordings. Violators will face strict legal action.

**DISCLAIMER**  
THIS IS COPYRIGHTED CONTENT. Unauthorized use, including screenshots, copying, misuse, reuse, or resale of any content from this app, is strictly prohibited. Our app monitors and records all screenshots and recordings. Violators will face strict legal action.

## TMD'S AND SPLINT TYPES AND BRUXISM

Sources: TG, Temporomandibular Disorder: a practical guide for dental practitioners in diagnosis and management (ADJ article), Types of Occlusal Splint in Management of Temporomandibular Disorders TMD (Article), Management of temporomandibular joint disorders: A surgeon's perspective, Temporomandibular Disorders: Current Concepts and Controversies in Diagnosis and Management (Article)

- Temporomandibular disorder (TMD) is the most common reason for seeking dental care other than dental pain.
- Temporomandibular disorder (TMD) is a broad term encompassing pain and/or dysfunction of the masticatory musculature and the temporomandibular joints.
- TMD is a collective term for clinical problems involving masticatory muscles, Temporomandibular Joints (TMJ) and associated structures.
- TMD can be sub classified into disorders called:
  - a) Temporomandibular Joint (TMJ) disorders
  - b) Masticatory muscle disorders

### 1. Types of TMDs:

- The three most common temporomandibular disorders are:
  - a) **Myofascial pain & dysfunction:** It is primarily a muscle disorder resulting from oral parafunctional habits such as clenching or bruxism that is sometimes related to psychogenic disorders such as headache, fibromyalgia, chronic back pain and irritable bowel syndrome with stress, anxiety and depression being the key features.
  - b) **Internal derangement:** Internal derangement is used to describe a temporomandibular disorder where there is an abnormal position of the articular disc resulting in mechanical interference (i.e., clicking) and restriction of the normal range of mandibular activity (i.e., limited mouth opening) or even hypermobility that may result in jaw dislocation.
  - c) **Osteoarthritis:** Osteoarthritis is a localized degenerative disorder mainly affecting the articular cartilage of the mandibular condyle of the temporomandibular joint and is often seen in older individuals but can uncommonly present in younger patients.
- *Myofascial pain and dysfunction are the most prevalent.*

Table 1. The main temporomandibular disorders

- |   |   |
|---|---|
| 1 | Myofascial pain and dysfunction                   |
| a | Myositis  |
| b | Fibromyalgia                                      |
| c | Neuropathic pain                                  |
| d | Chronic pain syndrome                             |
| 2 | TMJ functional derangement                        |
| a | Internal derangement - disc displacement          |
| b | Hypermobility disorders – dislocation             |
| c | Hypomobility disorders – ankylosis, posttraumatic |
| 3 | TMJ degenerative/inflammatory joint disease       |
| a | Osteoarthritis/arthritis                          |
| b | Rheumatoid arthritis                              |
| c | Psoriatic arthritis                               |
| d | Juvenile arthritis                                |

### DISCLAIMER

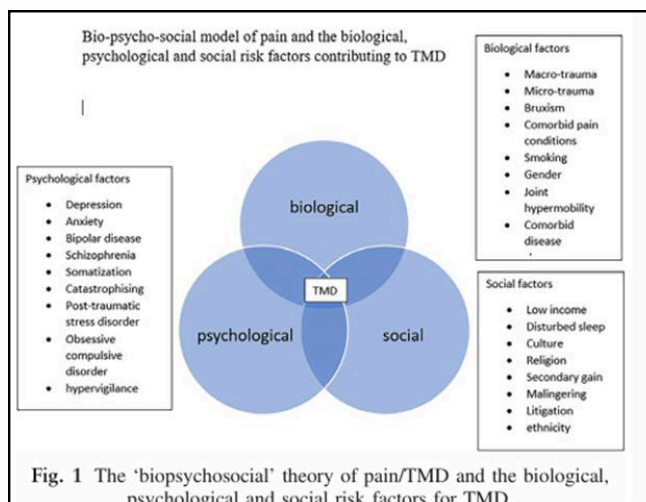
THIS IS COPYRIGHTED CONTENT. Unauthorized use, including screenshots, copying, misuse, reuse, or resale of any content from this app, is strictly prohibited. Our app monitors and records all screenshots and recordings. Violators will face strict legal action.

DISCLAIMER  
THIS IS COPYRIGHTED CONTENT. Unauthorized use, including screenshots, copying, misuse, reuse, or resale of any content from this app, is strictly prohibited. Our app monitors and records all screenshots and recordings. Violators will face strict legal action.

## TMD'S AND SPLINT TYPES AND BRUXISM

### 2. Risk Factors for TMDs:

- a) TMD are a heterogeneous group of conditions that have a multifactorial etiology where a combination of predisposing, initiating and perpetuating factors are at play.
- b) They include:
  - Direct Trauma
  - Indirect Trauma (acceleration and deceleration injury)
  - Parafunctional habits (Tooth grinding and clenching)
  - Psychosocial issues like stress and anxiety have also shown to be contributing to TMDs.
  - Habits such as Lip biting, cheek biting, biting fingernails, chewing gum, smoking can perpetuate an existing temporomandibular disorder.
- c) Chronic TMDs are often associated with psychological disorders.
- d) Comorbid diseases which may specifically affect the TMJ include: rheumatoid arthritis, juvenile idiopathic arthritis, psoriatic arthritis, systemic lupus erythematosus, osteoarthritis and neoplasia.
- e) The incidence rate of TMD is only slightly greater in women than men, but up to four times as many women seek treatment in addition to having a greater overall pain sensitivity.



- f) TMD is also more likely to persist in women.
- g) Patients with TMD and chronic pain should be assessed for psychological factors such as depression or anxiety, catastrophizing, distress, fear avoidance beliefs and post-traumatic stress disorder (PTSD).
- h) **Bruxism and TMD can exist independently.** Bruxism may be a risk factor for some negative oral health consequences such as masticatory muscle pain, temporomandibular joint pain and extreme tooth wear.
- i) **Malocclusion is not a risk factor for TMD.**

#### DISCLAIMER

THIS IS COPYRIGHTED CONTENT. Unauthorized use, including screenshots, copying, misuse, reuse, or resale of any content from this app, is strictly prohibited. Our app monitors and records all screenshots and recordings. Violators will face strict legal action.



## TMD'S AND SPLINT TYPES AND BRUXISM

### 3. Signs and symptoms of TMDs

- The most important feature is pain, followed by restricted or limited jaw movement, and joint noises during jaw movement.
- Pain is the most common presenting complaint and is by far the most difficult problem to evaluate.
- A history of limited mouth opening which may be intermittent or progressive is also a key feature of temporomandibular joint disorders.
- The patient should be evaluated for tenderness in those areas in head and neck accessible to palpation.
- Palpation is accomplished by placing the finger tips in the preauricular region, just in front of the tragus of the ear. The patient is then asked to open their mouth and the finger tip will fall into the depression left by the translating condyle.
- Pain specifically localized to the pre-auricular area is a good sign of actual joint pathology.
- Examination of the masticatory musculature may also be accomplished by digital palpation.
- Areas of tenderness, trigger points and pain referral patterns should be noted to visualize the extend of the pain in the head and neck.
- Joint sounds and their location during opening, closing and lateral excursions of the mandible may be either palpated or detected with a stethoscope placed over the pre-auricular area.
- Clicking is a reliable sign of internal derangement while grating/crepitus is a sign of advanced degenerative joint disease such as osteoarthritis.

**Table 15. Signs and symptoms of temporomandibular disorders**

<b>Common symptoms</b>	pain and restriction with mandibular function pain in and around the ears and masticatory muscles headache neck pain limited jaw opening joint sounds clenching of teeth (bruxism; see p.149)
<b>Uncommon symptoms</b>	reduced hearing changes in occlusion toothache altered sensation in the face (eg paraesthesia, a feeling of swelling)
<b>Signs</b>	tenderness of the temporomandibular joints and masticatory muscles during movement temporomandibular joint sounds (clicking, clunking or crepitus) during repetitive opening and closing of the mouth, as well as lateral and protrusive movements [NB1] deviation on opening of the jaw

NB1: Temporomandibular joint sounds are not an indication for treatment, unless associated with pain or dysfunction.

Image: TG

**Table 1. TMD signs and symptoms**

Common symptoms	Less common symptoms	Common signs
Facial pain	Reduced hearing or Feeling of blocked ears	Temporomandibular joint sounds
Restricted jaw movement	Tooth ache/sensitivity/ Tooth mobility	Restricted opening or jaw deviation upon opening masseteric hypertrophy
Headache	Sleep disturbance	Tenderness muscle of mastication
Pre-auricular pain	Paresthesia/swelling of face	Tenderness TMJ
Difficulty eating	Tinnitus	
Bruxing/ clenching	Occlusal disturbance	tenderness to percussion of teeth
Ear ache	Pain with swallowing	Bruxing/clenching
Joint sounds	Sharp pain in ear	
Neck/shoulder pain	Retro-orbital pain	

Image – source ADJ article on TMD

#### DISCLAIMER

THIS IS COPYRIGHTED CONTENT. Unauthorized use, including screenshots, copying, misuse, reuse, or resale of any content from this app, is strictly prohibited. Our app monitors and records all screenshots and recordings. Violators will face strict legal action.



## TMD'S AND SPLINT TYPES AND BRUXISM

### 4. Investigations for TMDs:

- Investigations are required to not only eliminate the possibility of other pathological processes that may mimic temporomandibular disorder symptoms but also to see if there is pathology specifically related to the TMJ.
- Plain radiographs of the temporomandibular joint, such as high level orthopantomograms and transcranial projections, are useful as baseline investigations for detection of any gross pathological, degenerative or traumatic changes in the mandibular condyle.
- **Magnetic resonance imaging (MRI)** has increasingly been used in the investigation of the status of the articular disc to determine if there is internal derangement of the temporomandibular joint.

### 5. Diagnosis of TMD

- Accurate diagnosis of TMDs requires appropriate history, examination and imaging.
- Amalgamation of the presenting complaint, clinical history and findings from the examination will help the clinician arrive at a diagnosis.
- As TMD etiology is multifactorial, it is essential that clinicians should also consider employing the suggested questions while taking a detailed pain history and amalgamate these with the clinical findings and psychosocial factors to determine the risk.
- Those patients either presenting with an existing TMD or determined to be at risk of developing a TMD, should be treated as 'high risk' and managed with great care.
- Any dental procedure considered 'high risk' has the potential to trigger or exacerbate a TMD.
- Prior to commencing dental treatment it is critical that informed consent be obtained from the patient regarding the possibility of developing a TMD.

	Myalgia	Arthralgia	Intra-articular joint disorder	Degenerative joint disorder
Information from patient history	Pain in the masticatory musculature, modified jaw movement, function or parafunction	Pain in the masticatory structure, modified by jaw movement, function or parafunction	TMJ noise(s) present or TMJ noises present and jaw locks with limited opening	TMJ noises present
Clinical examination findings	Reported pain on palpation of the muscles of mastication, or pain reported with maximum mouth opening	Patient reported pain on palpation of TMJ or patient reported pain upon maximum unassisted or assisted opening, right, left, lateral or protrusive movements	Clicking, popping, or snapping noise present with either opening and closing or opening and closing and lateral or protrusive movements	Crepitus (crackling sounds) present in TMJ during maximum active opening, passive opening, right lateral, left lateral or protrusive movements

#### DISCLAIMER

THIS IS COPYRIGHTED CONTENT. Unauthorized use, including screenshots, copying, misuse, reuse, or resale of any content from this app, is strictly prohibited. Our app monitors and records all screenshots and recordings. Violators will face strict legal action.

## TMD'S AND SPLINT TYPES AND BRUXISM

### 5. Diagnosis of TMD

- The following questions are a guide for clinicians to help gain an understanding of the pain history and to formulate a diagnosis.

- (1) Reason for presenting
- (2) Were there any triggers when the pain first started? (What do you think triggered the pain?)
- (3) History of trauma? (to elicit Macro-trauma (e.g. physical injury) versus micro-trauma (e.g. para-function such as gum chewing)
- (4) Describe the pain in your own words
- (5) When did the pain first start?
- (6) Is the pain there all the time? Is the pain episodic or continuous?
- (7) If there are episodes, how often do the episodes last?
- (8) If there are episodes, how frequently do they occur?
- (9) Is there a pattern to when the pain occurs? (i.e. every morning, during the day)
- (10) Can you rate the pain on a scale out of 10? How is the pain NOW, when it's very bad, and when it's manageable?
- (11) What causes the pain to start? What makes the pain worse? What makes the pain better?
- (12) Can you point to the area of pain?
- (13) Do you have pain elsewhere in your body?
- (14) Are you aware of tooth grinding or clenching? Is this during the day or night or both?
- (15) Do you have any joint noises?
- (16) Do you have an earache or ear noises?
- (17) Do you have other symptoms (for example nausea or vomiting, blocked nose or stuffiness?)
- (18) Do you have headaches? If so, duration, timing, location and frequency of headaches.
- (19) Do you avoid any foods because of facial pain?
- (20) Have you lost weight because of the pain?
- (21) Does this pain prevent you from doing any normal activities?
- (22) Do you have trouble sleeping?
- (23) Do you have airway problems or sleep apnoea?
- (24) Previous treatment for facial pain?
- (25) Have you been experiencing significant stress or anxiety recently?
- (26) Have you experienced significant stressful life events or changes in your family situation, routine or employment?

### 6. Differential Diagnosis if TMDs:

Table 3. Differential diagnosis of temporomandibular disorders (TMD).

Neuropathic Pain
Trigeminal neuralgia
Glossopharyngeal neuralgia
Postherpetic neuralgia
Traumatic neuralgia
Burning mouth syndrome
Atypical odontalgia
Atypical facial pain
Odontogenic Pain
Dental caries
Periodontal disease
Dental abscess
Dental sensitivity
Cracked tooth syndrome
Pericoronitis
Intracranial Pain
Tumours
Aneurysms
Bleeding
Infection
Pain from Other Adjacent Structures
Ear
Nose
Throat
Eyes
Sinus
Salivary glands
Lymph nodes
Vasculature
Cervical region
Headaches not Attributed to TMD
Migraine
Cluster headache
Tension-type headache
Temporal arteritis
Referred Pain
Psychogenic Pain

#### DISCLAIMER

THIS IS COPYRIGHTED CONTENT. Unauthorized use, including screenshots, copying, misuse, reuse, or resale of any content from this app, is strictly prohibited. Our app monitors and records all screenshots and recordings. Violators will face strict legal action.

#### DISCLAIMER

THIS IS COPYRIGHTED CONTENT. Unauthorized use, including screenshots, copying, misuse, reuse, or resale of any content from this app, is strictly prohibited. Our app monitors and records all screenshots and recordings. Violators will face strict legal action.

## TMD'S AND SPLINT TYPES AND BRUXISM

### 7. Management of TMDs:

- The aim of management is to control the patients' symptoms rather than achieve a cure.
- Treatment goals should be tailored to specific diagnosis, and includes:
  - a) Reducing pain
  - b) Adverse loading
  - c) Restoring mandibular function.
  - d) Resuming normal daily activities
- Once a diagnosis of TMD has been established, the dental practitioner needs to recognize whether management falls within their scope or a referral to a specialist is indicated.
- Identification of the 'high risk' patients is paramount, especially in the dental setting, as subjecting a 'high risk' patient to a 'high risk' procedure such as an extended dental visit, could precipitate or aggravate an underlying or undiagnosed TMD.
- It is essential that prior to commencing any dental procedure, the predisposing risks for TMD are discussed with the patient and documented in the clinical record.
- The recommended pathways for management of patients according to the patient risk and procedure risk are:

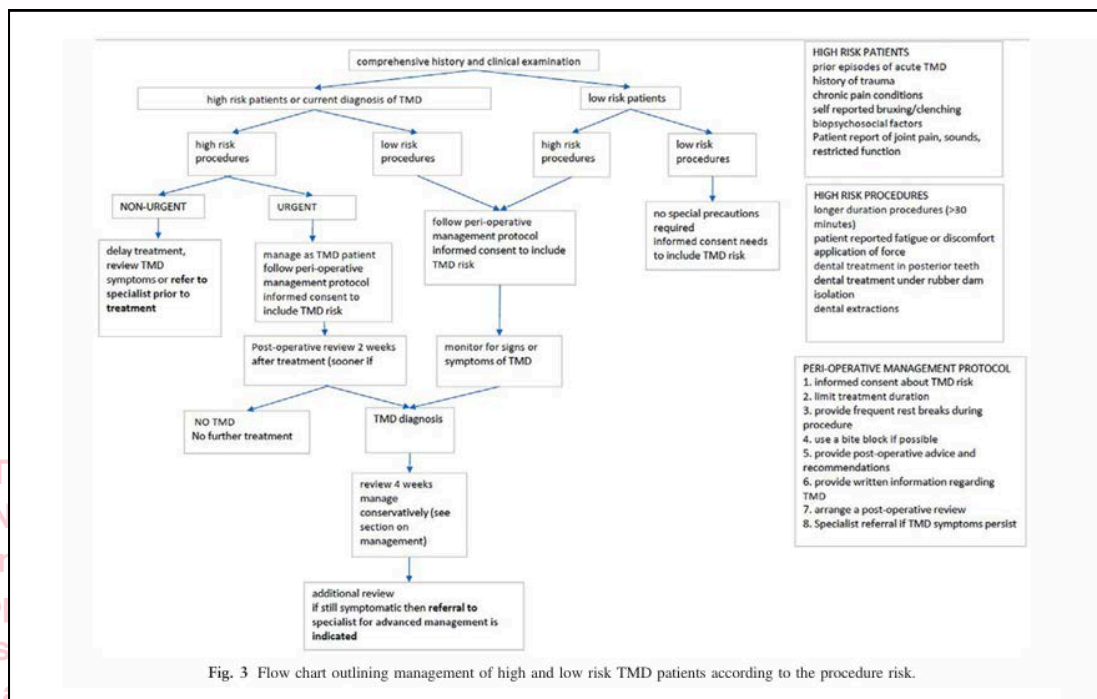


Fig. 3 Flow chart outlining management of high and low risk TMD patients according to the procedure risk.

#### DISCLAIMER

THIS IS COPYRIGHTED CONTENT. Unauthorized use, including screenshots, copying, misuse, reuse, or resale of any content from this app, is strictly prohibited. Our app monitors and records all screenshots and recordings. Violators will face strict legal action.



## TMD'S AND SPLINT TYPES AND BRUXISM

### Management strategies:

Management strategies are conservative and can include:

- patient education and reassurance
- jaw rest, using strategies such as dietary modification to minimise chewing (eg eating only soft foods)
- avoidance of extreme jaw movements (eg yawning, chewing gum, singing)
- massage and application of warm packs to the temporomandibular joints and cheeks several times per day. Cold packs can be useful in the presence of redness and swelling
- behavioural modification (eg identifying and managing sources of stress, which may be facilitated by individual or group counselling)
- regular treatment (gentle muscle stretching and massaging) by a physiotherapist familiar in the management of temporomandibular disorders
- use of custom-made full-coverage intraoral occlusal splints\* to reduce joint loading, muscle activity and pain—splints are generally worn at night and protect teeth from the effects of bruxism. They should constitute only one part of a broader management approach
- short-term use of drugs—discourage patients from relying on drugs alone (particularly drugs of dependence) to treat the symptoms of temporomandibular disorders because of their chronic nature. Analgesics, muscle relaxants, anxiolytics, anticonvulsants, corticosteroids and antidepressants have been used with variable success.

Image: TG

Table 2. TMD management strategies

- 1 Explanation and reassurance
  - a TMD is not life-threatening
  - b TMD is not a Cancer
  - c TMD can become a chronic condition
  - d TMD can be managed
- 2 Education and self care
  - a Soft diet
  - b Jaw rest (especially during long dental appointments)
  - c Avoid extreme jaw movements (i.e yawning)
  - d Topical heat (e.g. wheat packs)
  - e Protect face and jaws from cold weather
  - f Avoid stress and anxiety
- 3 Medications
  - a Antiinflammatories
  - b Anxiolytics
  - c Muscle relaxants
  - d Antidepressants
- 4 Jaw physiotherapy
  - a Massage and stretching
  - b Dry needling
  - c TENS – transcutaneous electrical nerve stimulation
  - d Pulsed ultrasound therapy
- 5 Occlusal appliance therapy
- 6 Behavioural therapy
  - a Lifestyle counselling
  - b Relaxation therapy
  - c Hypnosis
  - d Biofeedback
- 7 Psychotherapy
- 8 Other
  - a Acupuncture
  - b Botox injections
  - c Chiropractic manipulation
- 9 TMJ surgery
  - a Closed procedures
    - i TMJ arthrocentesis
    - j TMJ arthroscopy
  - b Open procedures
    - i TMJ arthrotomy/arthroplasty
    - ii TMJ joint replacements.

Image: Article

- Acute exacerbation of TMD can be treated with Ibuprofen and paracetamol.
- If the conservative methods are inadequate and the pain and dysfunction becomes more severe or chronic, Referral of the patient to ORAL MEDICINE SPECIALSIT OR ORAL AND MAXILLOFACIAL SURGEON should be made.

THIS IS COPYRIGHTED  
CONTENT. Unauthorized use,  
including screenshots,  
copying, misuse, reuse, or  
resale of any content from  
this app, is strictly prohibited.  
Our app monitors and records  
all screenshots and  
recordings. Violators will face  
strict legal action.

#### DISCLAIMER

THIS IS COPYRIGHTED CONTENT. Unauthorized use, including screenshots, copying, misuse, reuse, or resale of any content from this app, is strictly prohibited. Our app monitors and records all screenshots and recordings. Violators will face strict legal action.

DISCLAIMER

THIS IS COPYRIGHTED CONTENT. Unauthorized use, including screenshots, copying, misuse, reuse, or resale of any content from this app, is strictly prohibited. Our app monitors and records all screenshots and recordings. Violators will face strict legal action.



## TMD'S AND SPLINT TYPES AND BRUXISM

### Treatment option for TMDs include:

Treatment options for TMD include reassurance (patient education, self-care and behavior therapy), physiotherapy (such as ultrasound, acupuncture, short wave diathermy laser, heat exercises, and biofeedback), occlusal splint therapy, drug therapy, occlusal adjustment, surgical intervention and combined treatment.

#### 1. Non-surgical treatment:

- The non-surgical treatment of temporomandibular disorders continues to be the most effective way of managing over 90 percent of patients.

##### a) Explanation and reassurance:

- The first step in the management of temporomandibular disorders is to explain to the patient the cause and nature of the disorder they present with, and to reassure them of the benign nature of the condition.

##### b) Patient education and self-care:

- The next step is to formulate a self-care routine which should include the following; limitation of mandibular function, habit awareness and modification, a home exercise program and avoiding stress.
- Voluntary limitation of mandibular function (i.e., avoid excessive chewing and talking) is encouraged to promote rest or immobilization of muscular and articular structures.
- The patient is advised to maintain a soft diet and avoid foods where a considerable amount of chewing is involved.
- The patient should also be discouraged from wide yawning, singing, chewing gum, and any other activities which would promote excessive mandibular function.
- Massage of the affected muscles with application of moist heat will help soothe aching or tired muscles by promoting muscle relaxation.
- Lengthy dental appointments often exacerbate the TMD so the Dentist must allow the patient to intermittently rest their jaw during their appointment. The use of a mouth prop to hold the jaw open may be useful.

##### c) Pharmacotherapy

- Pharmacotherapy can be a valuable adjunctive aid to the relief of symptoms when they are prescribed as part of a comprehensive management program.
- There is no single drug that has been proven to be effective for all cases of temporomandibular disorders.

#### DISCLAIMER

THIS IS COPYRIGHTED CONTENT. Unauthorized use, including screenshots, copying, misuse, reuse, or resale of any content from this app, is strictly prohibited. Our app monitors and records all screenshots and recordings. Violators will face strict legal action.

DISCLAIMER  
THIS IS COPYRIGHTED CONTENT. Unauthorized use, including screenshots, copying, misuse, reuse, or resale of any content from this app, is strictly prohibited. Our app monitors and records all screenshots and recordings. Violators will face strict legal action.

## TMD'S AND SPLINT TYPES AND BRUXISM

### d) Physiotherapy:

- The aim of physiotherapy is to restore normal mandibular function by a number of physical techniques that serve to relieve musculoskeletal pain and promote healing of tissues.
- Physiotherapists may also use adjunctive measures such as dry needling, TENS (transcutaneous electrical nerve stimulation) and pulsed ultrasound therapy to help relieve muscle pain.
- Physiotherapy is especially useful in the management of myofascial pain and TMJ closed lock and is essential following TMJ surgery.

### e) Behavioral therapy:

- Where there are persistent habits which exacerbate or maintain the temporomandibular disorder that cannot be easily modified by simple patient awareness, then a structured program of cognitive behavioral therapy may be required.
- Behavioral modification strategies may include counselling on lifestyle, relaxation therapy, hypnosis and biofeedback which fall in the domain of professional Psychologists.

### f) Occlusal Splint Therapy:

- **The most common form of treatment** provided by dentists for temporomandibular disorders is **occlusal splint therapy**.
- This may be referred to as a bite raising appliance, occlusal appliance or bite guard.
- The idea is to protect the teeth from abnormally high loads in clenchers and grinders and also to reduce the maximum loads on the TMJ, particularly in patients with nocturnal clenching/grinding.
- By distracting the occlusion, maximum contraction of the masticatory muscles is also prevented which theoretically reduces muscle pain.
- The occlusal appliances are considered as deprogrammers or jaw repositioners to establish ideal maxillomandibular relationships and thus relieve pain and restore the function.
- Commonly there are two different materials, based upon consistency, which are used in the fabrication of occlusal appliances:
  - Hard acrylic occlusal splints:** Either Self cured or heat cured which forms hard and rigid tooth borne and occlusal surfaces.
  - Soft or resilient occlusal splint:** Has flexible and pliable tooth-borne and occlusal surface.
  - Dual laminated:** its occlusal surface consists of hard acrylic resin and the tooth-borne surface consist of a soft material.

#### DISCLAIMER

THIS IS COPYRIGHTED CONTENT. Unauthorized use, including screenshots, copying, misuse, reuse, or resale of any content from this app, is strictly prohibited. Our app monitors and records all screenshots and recordings. Violators will face strict legal action.

DISCLAIMER  
THIS IS COPYRIGHTED CONTENT. Unauthorized use, including screenshots, copying, misuse, reuse, or resale of any content from this app, is strictly prohibited. Our app monitors and records all screenshots and recordings. Violators will face strict legal action.

## TMD'S AND SPLINT TYPES AND BRUXISM

### f) Occlusal Splint Therapy:

- Hard acrylic resin occlusal appliances can be either custom fabricated at chairside or indirect fabrication in the dental lab rotary by use of stone casts.
- The soft occlusal appliances can be purchased readily from dental supply houses this type of occlusal appliance ("boil and bite") is molded and adapted by boiling the product in water and then placing the material intra-orally with a biting force to establish the preferred correct occlusion.
- Hard acrylic resin occlusal appliances have several advantages over the soft appliances:
  - i. hardness and resistance of the acrylic resin enable easily and quickly adjustments,
  - ii. easily repaired,
  - iii. the fit of a hard acrylic resin is more accurate,
  - iv. methods of fabrication are more reliable
  - v. greater longevity,
  - vi. more color stable,
  - vii. less food debris accumulation
  - viii. more durable than that of the soft version.
- The adjustment of soft material is more difficult and often results in a less adequate occlusal scheme and these appliances are more susceptible to wearing that in turn result in occlusal changes.

THIS IS COPYRIGHTED  
CONTENT. Unauthorized use,  
including screenshots,  
copying, misuse, reuse, or  
resale of any content from  
this app, is strictly prohibited.  
Our app monitors and records  
all screenshots and  
recordings. Violators will face  
strict legal action.

#### DISCLAIMER

THIS IS COPYRIGHTED CONTENT. Unauthorized use, including screenshots, copying, misuse, reuse, or resale of any content from this app, is strictly prohibited. Our app monitors and records all screenshots and recordings. Violators will face strict legal action.

DISCLAIMER  
THIS IS COPYRIGHTED CONTENT. Unauthorized use, including screenshots, copying, misuse, reuse, or resale of any content from this app, is strictly prohibited. Our app monitors and records all screenshots and recordings. Violators will face strict legal action.

## TMD'S AND SPLINT TYPES AND BRUXISM

### Types of Oral occlusal splints for treatment of TMD:

#### A) Classification of occlusal appliances according to Okeson include:

1. Muscle relaxation appliance/ stabilization appliance used to reduce muscle activity
2. Anterior repositioning appliances/ orthopedic repositioning appliance
3. Anterior bite plane
4. Pivoting appliance
5. Soft/ resilient appliance

#### B) Classification of occlusal appliances according to Dawson include

1. Permissive splints/ muscle deprogrammer
2. Directive splints/ non-permissive splints
3. Pseudo permissive splints (e.g., soft splints, Hydrostatic splint)

#### 1. Flat Plane Stabilization Appliance (Michigan splint)

- Also known as the gnathological splint, Michigan splint, or muscle relaxation appliance.
- This appliance is generally fabricated for the maxillary arch.
- The muscle relaxation appliance is the most commonly used type of occlusal appliance, and it has the least adverse effects to the oral structures when properly fabricated.
- The purpose of the appliance is to provide joint stabilization, protect the teeth, redistribute the occlusal forces, relax the elevator muscles, and decrease bruxism. Additionally, wearing the appliance increases the patient's awareness of jaw habits and helps alter the rest position of the mandible to a more relaxed, open position.

#### 2. Anterior Bite Plane: Traditional Anterior Bite Plane

- These appliances are designed as a palatal-coverage horseshoe shape with an occlusal table covering 6 or 8 anterior maxillary teeth.
- **Not much recommended** as adverse effect includes possible overloading of TMJ.

#### 3. Anterior Bite Plane: Mini Anterior Appliances

- It's an oral appliance that engages only 2-4 maxillary incisors.
- It is also **not recommended** much as the possibility of adverse occlusal changes occurring with continuous and long-term use is of major concern. The design of the appliance only covers the maxillary anterior teeth, leading to the potential for overeruption of the posterior teeth resulting in an anterior open bite.

#### DISCLAIMER

THIS IS COPYRIGHTED CONTENT. Unauthorized use, including screenshots, copying, misuse, reuse, or resale of any content from this app, is strictly prohibited. Our app monitors and records all screenshots and recordings. Violators will face strict legal action.



## TMD'S AND SPLINT TYPES AND BRUXISM

### 4. Anterior Repositioning Appliance (Orthopedic Repositioning Appliance)

- The intent of this appliance, is to alter the maxillomandibular relationship so that a more anterior position assumed by the mandible.
- Acrylic guiding ramp is added to the anterior third of the maxillary appliance that direct the mandible into a more forward position, upon closing.
- It is designed to be used in treating patients with anterior disk displacement with reduction.
- With long term use of this appliance, there are permanent and irreversible occlusal concerns so the anterior bite plane appliance should be used with caution only for short periods of time as a temporary therapeutic measure to relieve internal derangements pain.

### 5. Posterior Bite Plane Appliance (Mandibular Orthopedic Repositioning Appliances)

- These appliances made to be worn on the lower arch.
- These appliances intended to produce vertical dimension and horizontal maxillomandibular relationship changes.
- The major concern regarding posterior bite plane design is that occlusion only on posterior teeth that allow overeruption of the anterior teeth or intrusion of the opposing posterior teeth, that Eventually lead to a posterior open bite, hence not recommended.

### Other Therapies

- Acupuncture
- Botox injections
- Chiropractic/ Osteopath jaw manipulations and other treatments have been tried in TMD management but have yet to be accepted into mainstream practice due to lack of evidence in the effectiveness of these modalities.

### 1. Surgical treatment:

- The literature has shown that about 5–10 per cent of all patients undergoing treatment for temporomandibular disorders require surgical intervention.
- The surgical procedures currently used for the treatment of temporomandibular disorders ranges from
  - i. temporomandibular joint arthrocentesis and arthroscopy to the more complex
  - ii. open joint surgical procedures, referred to as arthrotomy
- Oral & Maxillofacial Surgeons with a special interest in this field will often prefer to see patients undergo a period of non-surgical therapy prior to seeking a surgical opinion.

#### DISCLAIMER

THIS IS COPYRIGHTED CONTENT. Unauthorized use, including screenshots, copying, misuse, reuse, or resale of any content from this app, is strictly prohibited. Our app monitors and records all screenshots and recordings. Violators will face strict legal action.

#### DISCLAIMER

THIS IS COPYRIGHTED CONTENT. Unauthorized use, including screenshots, copying, misuse, reuse, or resale of any content from this app, is strictly prohibited. Our app monitors and records all screenshots and recordings. Violators will face strict legal action.

## TMD'S AND SPLINT TYPES AND BRUXISM

### 1. Surgical treatment:

**Table 3. Indications for for TMJ surgery**

**Absolute indications**

- 1 Ankylosis – eg. Fibrous or osseous joint fusion
- 2 Neoplasia – eg. Osteochondroma of the condyle
- 3 Dislocation – ie. Recurrent or chronic
- 4 Developmental disorders – eg. Condylar hyperplasia

**Relative indications**

- 1 Internal derangement
- 2 Osteoarthritis
- 3 Trauma

**A General indications**

- i Disorder not responding to non-surgical therapy
- ii Where the TMJ is the source of pain and dysfunction
  - a Pain localised to the TMJ
  - b Pain on functional loading and movement of the TMJ
  - c Mechanical interference with TMJ function

**B Specific indications**

- i Chronic severe limited mouth opening
- ii Advanced degenerative joint disease with intolerable symptoms of pain and joint dysfunction
- iii Confirmation of severe joint disease on CT scan or MRI

### 2. Use of Botulinum Toxin for management of TMD:

There is some evidence for the use of botulinum toxin to manage the symptoms of temporomandibular disorders when conservative measures are inadequate. Ensure patients understand that botulinum toxin is not a cure for temporomandibular disorders, but may be used as part of the overall management strategy. The use of botulinum toxin for temporomandibular disorders is off-label. Dentists require additional training to administer botulinum toxin.\* If the recommended doses and protocols are adhered to, the incidence of adverse effects is low. Local complications include stinging during injections, bruising at the site of injection and excessive muscle weakness. Adverse effects associated with inadvertent injection of botulinum toxin into nontarget tissues are rare, but can include alteration in smile and temporary dry mouth. Systemic adverse effects include an influenza-like syndrome that is transient and hypersensitivity reactions.

Surgery for temporomandibular disorders is rarely required. Only consider referring the patient for a surgical assessment if symptoms have not responded to conservative management and there is definitive evidence of internal joint derangement or other joint pathology on imaging.

#### DISCLAIMER

THIS IS COPYRIGHTED CONTENT. Unauthorized use, including screenshots, copying, misuse, reuse, or resale of any content from this app, is strictly prohibited. Our app monitors and records all screenshots and recordings. Violators will face strict legal action.

#### DISCLAIMER

THIS IS COPYRIGHTED CONTENT. Unauthorized use, including screenshots, copying, misuse, reuse, or resale of any content from this app, is strictly prohibited. Our app monitors and records all screenshots and recordings. Violators will face strict legal action.

## TMD'S AND SPLINT TYPES AND BRUXISM

### BRUXISM

- It is the repeated clenching and grinding of teeth and bracing or thrusting of the mandible.
- It can occur in sleep or while awake.
- Etiology is complex and multifactorial and not fully understood.

#### Types of Bruxism:

##### 1. Sleep bruxism:

- No evidence to show that occlusal factors cause sleep bruxism.
- In sleep bruxism, Rhythmic masticatory activity peaks in the minutes before REM (Rapid Eye Movement) sleep, suggesting that it has onset related to sleep-stage transitions.
- Sleep bruxism is usually noted by a partner during sleep

common. However, in the sleep laboratory, approximately 50% of people with a history of tooth grinding have low frequencies of jaw muscle contractions and tooth grinding. It remains to be clarified when tooth grinding becomes a disorder associated with negative consequences such as tooth damage and pain.

Bruxism may rarely be a sign of orofacial dyskinesia, or occur following a head injury. Acute oromandibular dystonia or tardive dyskinesia caused by dopamine antagonist antiemetic drugs (eg metoclopramide, prochlorperazine) or antipsychotic drugs may be mistaken for bruxism.

- Management of sleep bruxism: It includes:
  - i. Avoiding risk factors
  - ii. Relaxation techniques
  - iii. Hypnotherapy
  - iv. Biofeedback
  - v. Cognitive behavioral therapy (CBT)
  - vi. Improving sleep hygiene

Full-coverage intraoral occlusal appliances (splints or dental guards) can be used to protect the teeth from attrition during sleep bruxism. They should be custom-made by a dentist with appropriate expertise or an oral medicine specialist, regularly reviewed and adjusted as required. In addition to preventing tooth damage, intraoral occlusal appliances reduce muscle strain and loading of the temporomandibular joints; however, they do not cure bruxism. Partial coverage splints should not be used because of the potential for significant occlusal changes and the risk of aspiration.

#### DISCLAIMER

THIS IS COPYRIGHTED CONTENT. Unauthorized use, including screenshots, copying, misuse, reuse, or resale of any content from this app, is strictly prohibited. Our app monitors and records all screenshots and recordings. Violators will face strict legal action.



## TMD'S AND SPLINT TYPES AND BRUXISM

### Types of Bruxism:

#### 2. Awake Bruxism

- Occurs when the patient is awake.
- Management requires:
  - i. Habit recognition and reversal
  - ii. Stress management

and stress management. There is no evidence for hypnotherapy, biofeedback or cognitive behavioural therapy for awake bruxism.

- Common Triggers for Bruxism:

Box 17. Common triggers of bruxism	
•	caffeine and other stimulants, including herbal stimulants
•	alcohol
•	smoking
•	snoring
•	obstructive sleep apnoea
•	stress and anxiety
•	antidepressants
–	selective serotonin reuptake inhibitors (SSRIs)
–	serotonin and noradrenaline reuptake inhibitors (SNRIs)
•	antipsychotics
•	amfetamines
–	dexamfetamine
–	lisdexamfetamine
–	metamfetamine
–	MDMA (ecstasy)
•	cocaine

### Signs of Bruxism (parafunction) include:

- cracked teeth, .
- multiple failed restorations
- chipping of incisal edges,
- wear facets
- mobile teeth
- masseteric hypertrophy,
- buccal mucosal ridging and,
- scalloping of the lateral border of the tongue

#### DISCLAIMER

THIS IS COPYRIGHTED CONTENT. Unauthorized use, including screenshots, copying, misuse, reuse, or resale of any content from this app, is strictly prohibited. Our app monitors and records all screenshots and recordings. Violators will face strict legal action.



# JAW CYSTS AND TUMORS

(Source- Text book of White and Pharoah Radiology, Internet)

## CYSTS

- A cyst is a pathologic cavity filled with fluid, lined by epithelium, and surrounded by a definite connective tissue wall.
- The cystic fluid either is secreted by the cells lining the cavity or derives from the surrounding tissue fluid.
- Cysts occur more often in the jaws than in any other bone because most cysts originate from the numerous rests of odontogenic epithelium that remain after tooth formation.
- Cysts are **radiolucent lesions**, and the prevalent clinical features are swelling, pain (unless the cyst becomes secondarily infected or is related to a nonvital tooth), and association with unerupted teeth, especially third molars.
- Cysts may occur centrally (within bone) in any location in the maxilla or mandible but are rare in the condyle and coronoid process.
- Odontogenic cysts are found most often in the tooth-bearing region. In the mandible, they originate above the inferior alveolar nerve canal.
- Cysts that originate in bone usually have a periphery that is well defined and corticated (characterized by a fairly uniform, thin, radiopaque line)
- However, a secondary infection or a chronic state can change this appearance into a thicker, more sclerotic boundary or make the cortex less apparent.

## A. Odontogenic Cysts:

### 1. Radicular cysts:

- Also known as **Periapical cyst, apical periodontal cyst, and dental cyst.**
- A radicular cyst is a cyst that most likely results when rests of epithelial cells (Malassez) in the periodontal ligament are stimulated to proliferate and undergo cystic degeneration by inflammatory products from a nonvital tooth.
- **Radicular cysts are the most common type of cyst in the jaws.**
- They arise from **non-vital teeth.**
- Often radicular cysts produce no symptoms unless secondary infection occurs. A cyst that becomes large may cause swelling.
- The incidence of radicular cysts is greater in the third to sixth decades and shows a slight male predominance
- Radiographically, in most cases the epicenter of a radicular cyst is located approximately at the apex of a nonvital tooth.

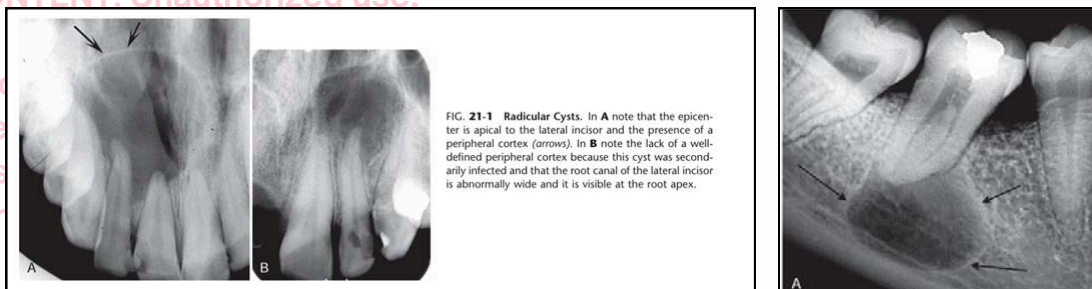


Image: A periapical film of a radicular cyst reveals a lesion with a well-defined cortical boundary (arrows). Note that the presence of the inferior cortex of the mandible has influenced the circular shape of the cyst.

## DISCLAIMER

THIS IS COPYRIGHTED CONTENT. Unauthorized use, including screenshots, copying, misuse, reuse, or resale of any content from this app, is strictly prohibited. Our app monitors and records all screenshots and recordings. Violators will face strict legal action.

DISCLAIMER

THIS IS COPYRIGHTED CONTENT. Unauthorized use, including screenshots, copying, misuse, reuse, or resale of any content from this app, is strictly prohibited. Our app monitors and records all screenshots and recordings. Violators will face strict legal action.

# JAW CYSTS AND TUMORS

## A. Odontogenic Cysts:

### 1. Radicular cysts:

- Most radicular cysts (60%) are found in the maxilla, especially around incisors and canines.
- Treatment of a tooth with a radicular cyst may include extraction, endodontic therapy, and apical surgery.
- Treatment of a large radicular cyst usually involves surgical removal or marsupialization.
- Recurrence of a radicular cyst is unlikely if it has been removed completely.

### 2. Residual Cyst:

- A residual cyst is a cyst that remains after incomplete removal of the original cyst.
- The term residual is used most often for a radicular cyst that may be left behind, most commonly after extraction of a tooth.
- A residual cyst usually is asymptomatic and often is discovered on radiographic examination of an edentulous area.
- The treatment for residual cysts is surgical removal or marsupialization, or both, if the cyst is large.

### 3. Dentigerous Cysts/ Follicular Cyst:

- A dentigerous cyst is a cyst that forms around the crown of an unerupted tooth.
- It begins when fluid accumulates in the layers of **reduced enamel epithelium or between the epithelium and the crown of the unerupted tooth**.
- An eruption cyst is the soft tissue counterpart of a dentigerous cyst.
- Dentigerous cysts are the **second most common type** of cyst in the jaws.
- They develop around the crown of an unerupted or supernumerary tooth.
- The clinical examination reveals a missing tooth or teeth and possibly a hard swelling, occasionally resulting in facial asymmetry.
- The patient typically has no pain or discomfort.
- The epicenter of a dentigerous cyst is found just above the crown of the involved tooth, **most commonly the mandibular or maxillary third molar or the maxillary canine**.
- **An important diagnostic point** is that **this cyst attaches at the cemento-enamel junction**.
- Dentigerous cysts around supernumerary teeth account for about 5% of all dentigerous cysts, most developing around a mesiodens in the anterior maxilla.
- Some dentigerous cysts are eccentric, developing from the lateral aspect of the follicle so that they occupy an area beside the crown instead of above the crown.
- A dentigerous cyst has a propensity to displace and resorb adjacent teeth
- It commonly displaces the associated tooth in an apical direction.

#### DISCLAIMER

THIS IS COPYRIGHTED CONTENT. Unauthorized use, including screenshots, copying, misuse, reuse, or resale of any content from this app, is strictly prohibited. Our app monitors and records all screenshots and recordings. Violators will face strict legal action.

#### DISCLAIMER

THIS IS COPYRIGHTED CONTENT. Unauthorized use, including screenshots, copying, misuse, reuse, or resale of any content from this app, is strictly prohibited. Our app monitors and records all screenshots and recordings. Violators will face strict legal action.

## JAW CYSTS AND TUMORS

### A. Odontogenic Cysts:

#### 3. Dentigerous Cysts/ Follicular Cyst:

- Dentigerous cysts are treated by surgical removal, which may include the tooth as well.
- Large cysts may be treated by marsupialization before removal. The cyst lining should be submitted for histologic examination because ameloblastomas have been reported to occur in the cyst lining.

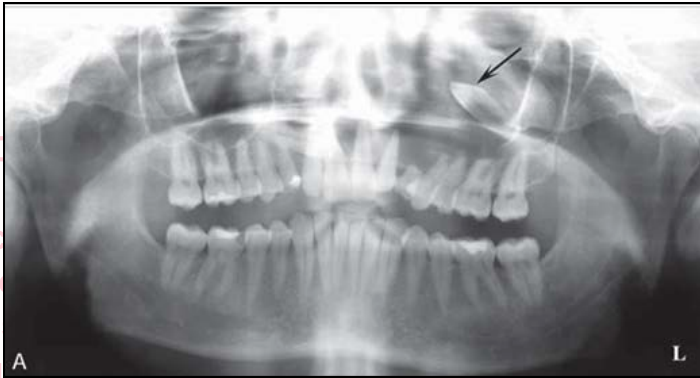


Image: This panoramic image reveals the presence of a large dentigerous cyst associated with the left maxillary cuspid (arrow), which has been displaced.

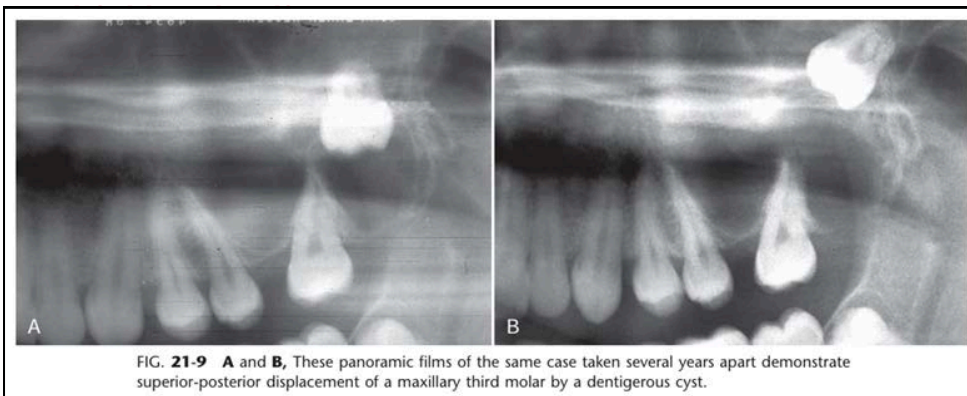


FIG. 21-9 A and B, These panoramic films of the same case taken several years apart demonstrate superior-posterior displacement of a maxillary third molar by a dentigerous cyst.

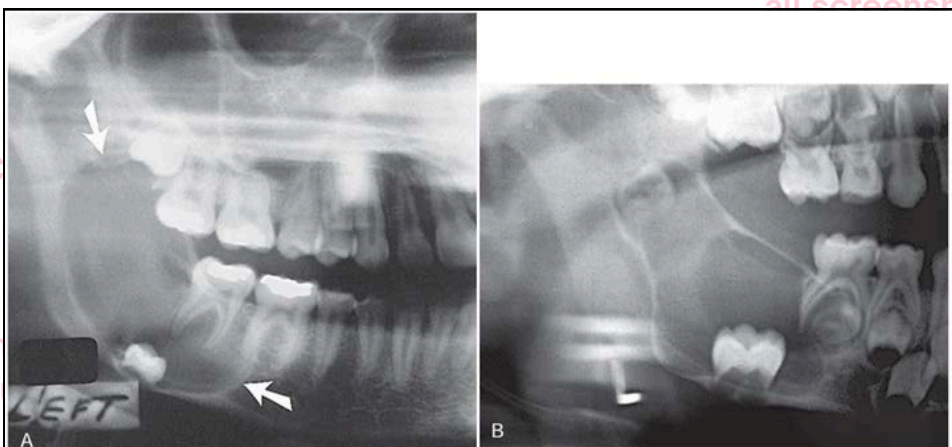


Image: Dentigerous cysts displacing teeth. A, the third molar has been displaced to the inferior cortex. B, the developing second molar has been displaced into the ramus by a cyst associated with the first molar.

#### DISCLAIMER

THIS IS COPYRIGHTED CONTENT. Unauthorized use, including screenshots, copying, misuse, reuse, or resale of any content from this app, is strictly prohibited. Our app monitors and records all screenshots and recordings. Violators will face strict legal action.

DISCLAIMER  
THIS IS COPYRIGHTED CONTENT. Unauthorized use, including screenshots, copying, misuse, reuse, or resale of any content from this app, is strictly prohibited. Our app monitors and records all screenshots and recordings. Violators will face strict legal action.



# JAW CYSTS AND TUMORS

## A. Odontogenic Cysts:

### 4. Keratocystic Odontogenic Tumor (KOT)

- Also known as **Odontogenic keratocyst and primordial cyst**.
- The World Health Organization has reclassified this cystic lesion into a unicystic or multi-cystic odontogenic tumor on the basis of the tumor-like characteristics of the lining epithelium.
- The epithelial lining is distinctive also because it is keratinized (hence the name) and thin (four to eight cells thick).
- Occasionally budlike proliferations of epithelium grow from the basal layer into the adjacent connective tissue wall.
- Islands of epithelium in the wall may give rise to satellite microcysts.
- The inside of the cyst often contains a viscous or cheesy material derived from the epithelial lining.
- They occur in a wide age range, but most develop during the **second and third decades**, with a slight male predominance.
- KOTs usually have no symptoms, although mild swelling may occur. Pain may occur with secondary infection.
- Aspiration may reveal a thick, yellow, cheesy material (keratin).
- Unlike other cysts, KOTs have a high propensity for recurrence, possibly because of small satellite cysts or fragments of epithelium left behind after surgical removal of the cyst.
- **The most common location of KOT is the posterior body of the mandible (90% occur posterior to the canines) and ramus (more than 50%)**
- The epicenter is located superior to the inferior alveolar nerve canal.
- Radiographically the cyst is radiolucent and has the affinity to grow along the internal aspects of the jaws causing minimal expansion.
- **This occurs throughout the mandible except for the upper ramus and coronoid process, where considerable expansion may occur.**
- When in a peri coronal position, a KOT may be indistinguishable from a dentigerous cyst.
- The lesion is likely to be a KOT if the cystic outline is connected to the tooth at a point apical to the cemento-enamel junction or if no expansion of the cortical plates has occurred.
- The typical scalloped margin and multilocular appearance of the KOT may resemble an ameloblastoma, **but ameloblastoma has a greater propensity to expand.**
- A KOT may also show some similarity to an odontogenic myxoma, especially in the characteristics of mild expansion and multilocular appearance

#### DISCLAIMER

THIS IS COPYRIGHTED CONTENT. Unauthorized use, including screenshots, copying, misuse, reuse, or resale of any content from this app, is strictly prohibited. Our app monitors and records all screenshots and recordings. Violators will face strict legal action.



## JAW CYSTS AND TUMORS

### A. Odontogenic Cysts:

#### 4. Keratocystic Odontogenic Tumor (KOT)

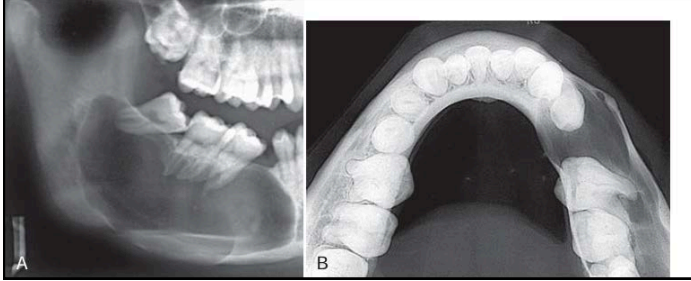


Fig: A large (KOT) occupying most of the right body and ramus of the mandible. Despite the large size, the buccal and lingual cortical plates of the mandible have been expanded only slightly, as can be seen in the occlusal film.

- If a KOT is suspected, referral to a radiologist for a complete radiologic examination is advisable.

#### 5. Lateral Periodontal Cyst

- Lateral periodontal cysts are thought to arise from epithelial rests in periodontium lateral to the tooth root.
- This condition usually is unicystic, but it may appear as a cluster of small cysts, a condition referred to as **botryoid odontogenic cysts**.
- The lesions usually are asymptomatic and less than 1 cm in diameter.
- If these cysts become secondarily infected, they will mimic a lateral periodontal abscess.
- A total of 50% to 75% of lateral periodontal cysts develop in the mandible, mostly in a region extending from **the lateral incisor to the second premolar**.
- A lateral periodontal cyst appears as a well-defined radiolucency with a prominent cortical boundary and a round or oval shape.
- Rare large cysts have a more irregular shape. The internal aspect usually is radiolucent.

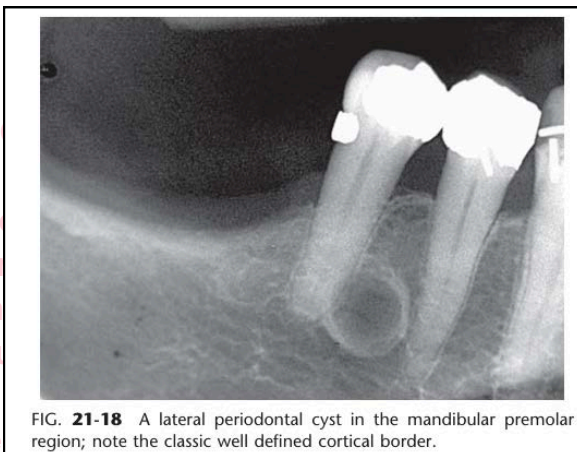


FIG. 21-18 A lateral periodontal cyst in the mandibular premolar region; note the classic well defined cortical border.

THIS IS COPYRIGHTED CONTENT. Unauthorized use, including screenshots, copying, misuse, reuse, or resale of any content from this app, is strictly prohibited. Our app monitors and records all screenshots and recordings. Violators will face strict legal action.

DISCLAIMER  
THIS IS COPYRIGHTED CONTENT. Unauthorized use, including screenshots, copying, misuse, reuse, or resale of any content from this app, is strictly prohibited. Our app monitors and records all screenshots and recordings. Violators will face strict legal action.

DISCLAIMER

THIS IS COPYRIGHTED CONTENT. Unauthorized use, including screenshots, copying, misuse, reuse, or resale of any content from this app, is strictly prohibited. Our app monitors and records all screenshots and recordings. Violators will face strict legal action.

## JAW CYSTS AND TUMORS

### A. Odontogenic Cysts:

#### 5. Lateral Periodontal Cyst

- The botryoid variety may have a multilocular appearance, although this aspect is related more to the histologic appearance.
- Lateral periodontal cysts usually do not require sophisticated imaging because of their small size.
- **Excisional biopsy or simple enucleation is the treatment of choice** because these cysts do not tend to recur.

### B. Non- Odontogenic Cysts:

#### 1. Nasopalatine duct Cyst:

- Also known as **Nasopalatine canal cyst, incisive canal cyst, nasopalatine cyst, median palatine cyst, and median anterior maxillary cyst.**
- Nasopalatine duct cysts account for about 10% of jaw cysts.
- The incidence is three times higher in males.
- Most of these cysts are asymptomatic or cause such minor symptoms that they are tolerated for long periods
- The most frequent complaint is a small, well-defined swelling just posterior to the palatine papilla. This swelling usually is fluctuant and blue if the cyst is near the surface.
- If the cyst expands, it may penetrate the labial plate and produce a swelling below the maxillary labial frenum or to one side.
- Most nasopalatine duct cysts are found in the naso- palatine foramen or canal. However, if this cyst extends posteriorly to involve the hard palate.
- Radiographically, the periphery usually is well defined and corticated and is circular or oval in shape. The shadow of the nasal spine sometimes is superimposed on the cyst, **giving it a heart shape.** Most are typically radiolucent.
- Most commonly this cyst causes the roots of the central incisors to diverge, and occasionally root resorption occurs.

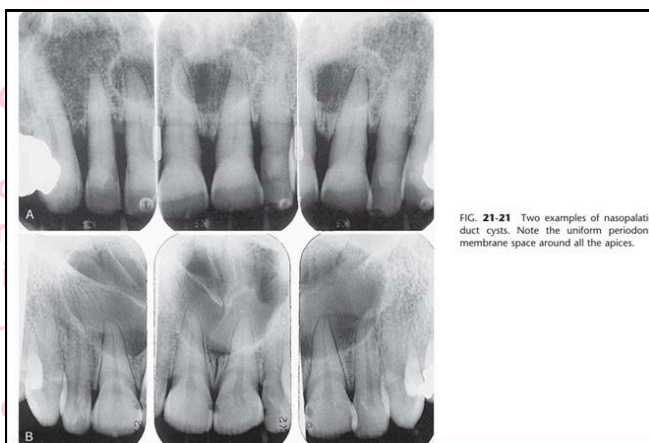


FIG. 21-21 Two examples of nasopalatine duct cysts. Note the uniform periodontal membrane space around all the apices.

#### DISCLAIMER

THIS IS COPYRIGHTED CONTENT. Unauthorized use, including screenshots, copying, misuse, reuse, or resale of any content from this app, is strictly prohibited. Our app monitors and records all screenshots and recordings. Violators will face strict legal action.

#### DISCLAIMER

THIS IS COPYRIGHTED CONTENT. Unauthorized use, including screenshots, copying, misuse, reuse, or resale of any content from this app, is strictly prohibited. Our app monitors and records all screenshots and recordings. Violators will face strict legal action.

# JAW CYSTS AND TUMORS

## B. Non- Odontogenic Cysts:

### 1. Nasopalatine duct Cyst:

- The most common differential diagnosis is a large incisive foramen.
- A foramen larger than 6 mm may simulate the appearance of a cyst.
- The appropriate treatment for a nasopalatine cyst is enucleation, preferably from the palate to avoid the nasopalatine nerve.
- If the cyst is large and the danger exists of devitalizing the tooth or creating a nasooral or antro-oral fistula, the surgeon may perform marsupialization of the cyst.

### 2. Nasolabial Cyst

- **AKA, Naso-alveolar cyst**
- When this rare lesion is small, it may produce a very subtle, unilateral swelling of the nasolabial fold and may elicit pain or discomfort.
- When large, it may bulge into the floor of the nasal cavity, causing some obstruction, flaring of the alae, distortion of the nostrils, and fullness of the upper lip. If infected, it may drain into the nasal cavity.
- It usually is unilateral, but bilateral lesions have occurred.
- Nasolabial cysts are primarily soft tissue lesions located adjacent to the alveolar process above the apices of the incisors.
- Because this is a soft tissue lesion, plain radiographs may not show any detectable changes.
- The investigation could include either CT or magnetic resonance imaging (MRI), both of which can provide an image of soft tissues.
- The nasolabial cyst should be excised through an intraoral approach. These cysts do not tend to recur.

## C. Cyst Like lesions:

### 1. Simple Bone cysts:

- **AKA Traumatic bone cyst, hemorrhagic bone cyst, extravasation cyst, progressive bone cavity, solitary bone cyst, and unicameral bone cyst.**
- An SBC is a cavity within bone that is lined with connective tissue. It may be empty, or it may contain fluid.
- However, because it has no epithelial lining, **it is not a true cyst.**
- SBCs are very common lesions.
- Most occur in the **first two decades of life.**
- lesion shows a male predominance of approximately 2 : 1.
- SBCs are asymptomatic in most cases, but occasionally pain or tenderness may be present, especially if the cyst has become secondarily infected.
- The teeth in the affected region usually **are vital.**
- Most SBCs are discovered only by chance, during radiographic examinations, and for this reason they can become quite large.
- Almost all SBCs are found in the mandible.

#### DISCLAIMER

THIS IS COPYRIGHTED CONTENT. Unauthorized use, including screenshots, copying, misuse, reuse, or resale of any content from this app, is strictly prohibited. Our app monitors and records all screenshots and recordings. Violators will face strict legal action.

DISCLAIMER  
THIS IS COPYRIGHTED CONTENT. Unauthorized use, including screenshots, copying, misuse, reuse, or resale of any content from this app, is strictly prohibited. Our app monitors and records all screenshots and recordings. Violators will face strict legal action.

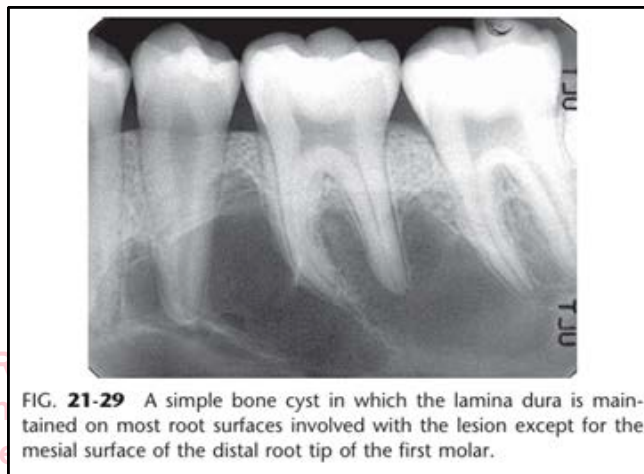
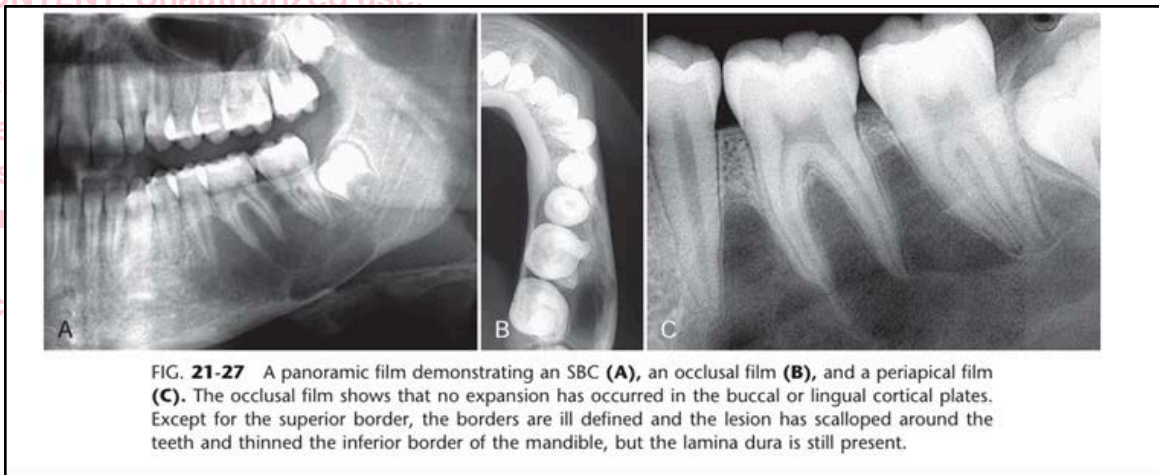


## JAW CYSTS AND TUMORS

### C. Cyst Like lesions:

#### 1. Simple Bone cysts:

- The lesion can occur anywhere in the mandible but is seen most often in the ramus and posterior mandible in older patients.
- SBCs also frequently occur with cemento-osseous and fibrous dysplasia.
- Radiographically, the shape most often is smooth and curved, like a cyst, with an oval or scalloped border. The lesion often scallops between the roots of the teeth.
- The margin may vary from a well-defined, delicate cortex to an ill-defined border that blends into the surrounding bone.



- The customary treatment is a conservative opening into the lesion and careful curettage of the lining; this usually initiates bleeding and subsequent healing. Spontaneous healing has been reported.

#### DISCLAIMER

THIS IS COPYRIGHTED CONTENT. Unauthorized use, including screenshots, copying, misuse, reuse, or resale of any content from this app, is strictly prohibited. Our app monitors and records all screenshots and recordings. Violators will face strict legal action.



# JAW CYSTS AND TUMORS

## TUMORS:

### Benign tumors of jaw:

- Benign tumors are slowly growing and spread by direct extension and not by metastases.
- Benign tumors typically have an insidious onset and grow slowly.
- These tumors usually are painless, do not metastasize, and are not life threatening unless they interfere with a vital organ by direct extension.
- Benign tumors are usually detected clinically by enlargement of the jaws or are found during a radiographic examination.
- Once the clinician has made a preliminary diagnosis of the presence of a tumor, a full radiologic examination should be made to fully document the extent and characteristics of the lesion.
- **Radiographically**, the internal structure may be completely radiolucent or radiopaque or may be a mixture of radiolucent and radiopaque tissues.
- If the lesion contains radiopaque elements, these structures usually represent either residual bone or a calcified material that is being produced by the tumor.
- Benign tumor exerts pressure on neighboring structures, resulting in the displacement of teeth or bony cortices.
- If the growth is slow enough, there will be adequate time for the outer cortex to remodel in response to the pressure, resulting in an appearance that the cortex has been displaced by the tumor.
- Benign tumors may also cause bodily displacement of nearby teeth.
- The roots of teeth may be resorbed by either benign or malignant tumors, but root resorption is more commonly associated with benign processes.
- The benign tumors especially likely to resorb roots are ameloblastomas, ossifying fibromas, and central giant cell granulomas.
- Benign tumors tend to resorb the adjacent root surfaces in a smooth fashion.
- Bone dysplasia such as fibrous dysplasia do not usually resorb teeth.
- When root resorption is associated with malignant tumors, the resorption is usually in smaller quantities, causing thinning of the root into a "spiked" shape.

### 1. Torus Palatinus

- AKA Palatine torus
- Torus palatinus is a bony protuberance (hyperostosis) that occurs in the middle third of the midline of the hard palate.
- Torus palatinus, the most common exostoses, occurs in about 20% of the population.
- The size and shape of a torus palatinus can vary, and these lesions have been described as flat, lobulated, nodular, or mushroom like.

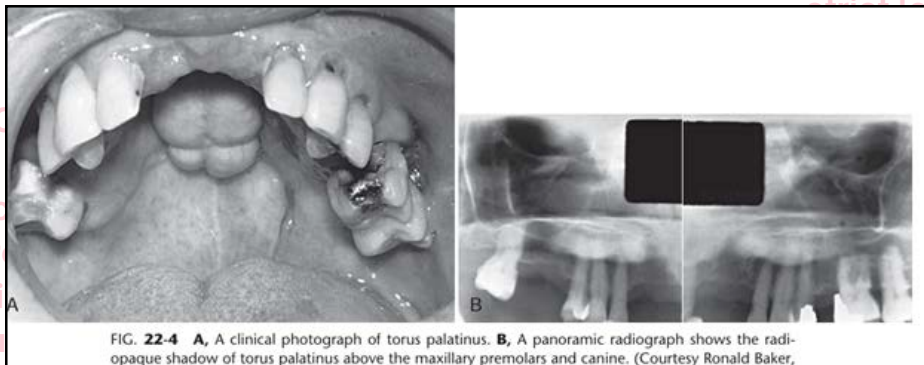
#### DISCLAIMER

THIS IS COPYRIGHTED CONTENT. Unauthorized use, including screenshots, copying, misuse, reuse, or resale of any content from this app, is strictly prohibited. Our app monitors and records all screenshots and recordings. Violators will face strict legal action.

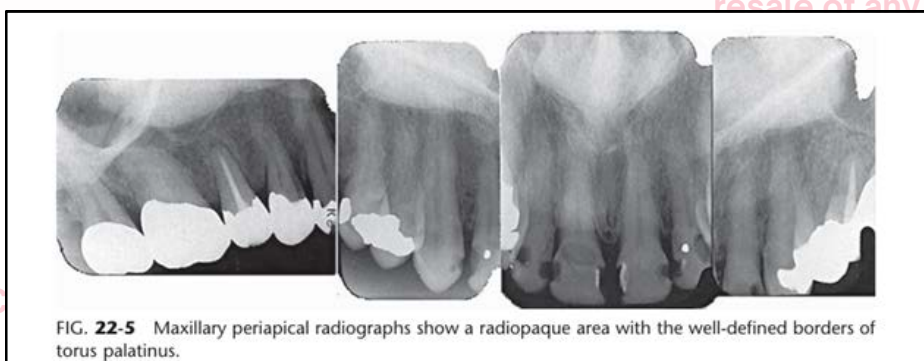
# JAW CYSTS AND TUMORS

## 1. Torus Palatinus

- AKA Palatine torus
- Torus palatinus is a bony protuberance (hyperostosis) that occurs in the middle third of the midline of the hard palate.
- Torus palatinus, the most common exostoses, occurs in about 20% of the population.
- The size and shape of a torus palatinus can vary, and these lesions have been described as flat, lobulated, nodular, or mushroom like.



- On maxillary periapical or panoramic radiographs, a torus palatinus appears as a dense radiopaque shadow below and attached to the hard palate.
- It may be superimposed over the apical areas of the maxillary teeth, especially if the torus has developed in the middle or anterior regions of the palate.
- The image of a palatal torus may project over the roots of the maxillary molars but the shadow will usually move in its position relative to the roots of the teeth if another film is taken with a different horizontal or vertical angulation of the central ray.



copying, misuse, reuse, or resale of any content from this app, is strictly prohibited. Our app monitors and records all screenshots and recordings. Violators will face strict legal action.

### DISCLAIMER

THIS IS COPYRIGHTED CONTENT. Unauthorized use, including screenshots, copying, misuse, reuse, or resale of any content from this app, is strictly prohibited. Our app monitors and records all screenshots and recordings. Violators will face strict legal action.

DISCLAIMER  
THIS IS COPYRIGHTED CONTENT. Unauthorized use, including screenshots, copying, misuse, reuse, or resale of any content from this app, is strictly prohibited. Our app monitors and records all screenshots and recordings. Violators will face strict legal action.

# JAW CYSTS AND TUMORS

## 2. Mandibular Torus:

- Torus mandibularis is a hyperostosis that protrudes from the lingual aspect of the mandibular alveolar process, usually near the premolar teeth.
- Tori occur less often on the lingual surface of the mandible than on the palate.
- These tori develop singly or multiply, unilaterally or bilaterally (usually bilaterally), and most often in the premolar region.
- On mandibular periapical radiographs, a torus mandibularis appears as a radiopaque shadow, usually superimposed on the roots of premolars and molars and occasionally over a canine or incisor.
- It usually is superimposed over about three teeth.
- Mandibular tori are sharply demarcated anteriorly on periapical films and are less dense and less well defined as they extend posteriorly
- There is no margin between the periphery of the torus and the surface of the mandible because the torus is continuous with the mandibular cortex.
- On occlusal radiographs a mandibular torus appears as a radiopaque and homogeneous
- Tori usually do not require any treatment.

## 3. Other exostoses:

- In addition to the torus, other exostoses may occur at other sites in the jaws.
- Exostoses may develop most commonly on the buccal surface of the maxillary alveolar process, usually in the canine or molar area.
- They may also occur on the palatal surface or crest and less commonly on the mandibular alveolar process.
- Occasionally they will grow on the crest under a pontic of a fixed bridge.
- They are less common than mandibular or palatine tori, may attain a large size, and may be solitary or multiple.
- They are nodular, pedunculated, or flat prominences on the surface of the bone.
- Maxillary alveolar process is the most common location and usually the image overlaps the roots of the adjacent teeth.
- The periphery of an exostosis is usually well defined and smoothly contoured with a curved border and The internal aspect of an exostosis usually is homogeneous and radiopaque.

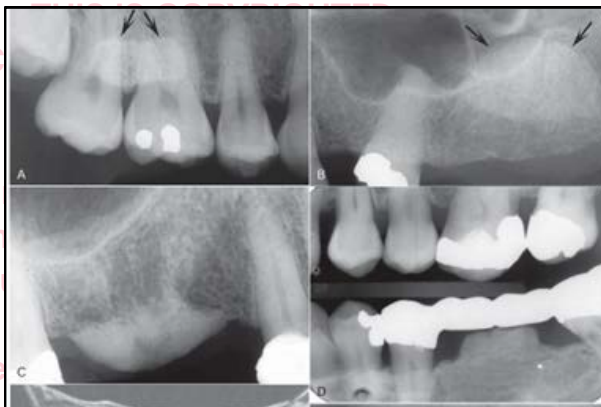

Image: A, A periapical film of a region of hyperostosis on the buccal aspect of the maxillary alveolar process, seen as a region of slight increase in radiopacity overlapping the roots of the molars (arrows). B, another example overlapping an edentulous ridge. C, an example occurring on the crest of the alveolar ridge. D, an example occurring under a bridge pontic.

## DISCLAIMER

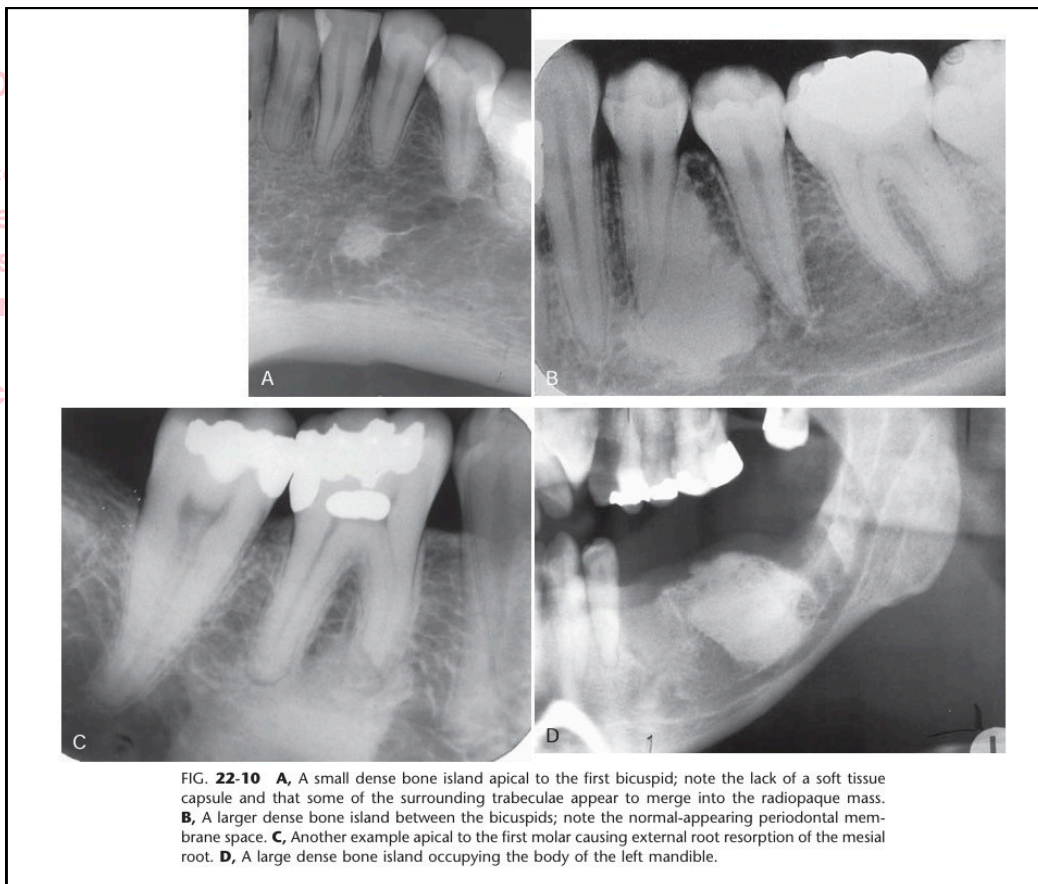
THIS IS COPYRIGHTED CONTENT. Unauthorized use, including screenshots, copying, misuse, reuse, or resale of any content from this app, is strictly prohibited. Our app monitors and records all screenshots and recordings. Violators will face strict legal action.



## JAW CYSTS AND TUMORS

### 4. Dense Bone Islands:

- AKA Enostosis and periapical idiopathic osteosclerosis.
- Dense bone islands (DBIs) are the internal counterparts of exostoses. They are localized growths of compact bone that develop within the cancellous bone.
- They are asymptomatic
- DBIs are more common in the mandible than in the maxilla. They occur most often in the premolar-molar area.
- The tooth most often involved is the mandibular first molar. In all circumstances the tooth is vital.



THIS IS COPYRIGHTED  
CONTENT. Unauthorized use,  
including screenshots,  
copying, misuse, reuse, or  
resale of any content from  
this app, is strictly prohibited.  
Our app monitors and records  
all screenshots and  
recordings. Violators will face  
strict legal action.

#### DISCLAIMER

THIS IS COPYRIGHTED CONTENT. Unauthorized use, including screenshots, copying, misuse, reuse, or resale of any content from this app, is strictly prohibited. Our app monitors and records all screenshots and recordings. Violators will face strict legal action.

DISCLAIMER  
THIS IS COPYRIGHTED CONTENT. Unauthorized use, including screenshots, copying, misuse, reuse, or resale of any content from this app, is strictly prohibited. Our app monitors and records all screenshots and recordings. Violators will face strict legal action.



# JAW CYSTS AND TUMORS

## A. Odontogenic Tumors:

### 1. Ameloblastoma:

- Also known as Adamantinoma, adamantoblastoma, adontomes embryolastiques, and epithelial odontoma.
- The ameloblastoma, a true neoplasm of odontogenic epithelium, is a persistent and locally invasive tumor; it has aggressive but benign growth characteristics.
- It is an aggressive neoplasm that arises from remnants of the dental lamina and dental organ (odontogenic epithelium).
- Ameloblastomas may be divided into:
  - a) the solid/multicystic type,
  - b) the unicystic type, and
  - c) the desmoplastic type
- The unicystic variant may develop as a single entity or may form from the epithelial lining of a dentigerous cyst, called a mural (within the wall) ameloblastoma.
- There is a slight predilection for this lesion to occur in men, and it develops more often in blacks.
- most patients are between 20 and 50 years, with the average age at discovery about 40 years.
- Ameloblastomas grow slowly, and few, if any, symptoms occur in the early stages. The tumor is frequently discovered during a routine dental examination.
- Usually the patient eventually notices gradually increasing facial asymmetry.
- Most ameloblastomas (80%) develop in the molar ramus region of the mandible, but they may extend to the symphyseal area. Most lesions that occur in the maxilla are in the third molar area and extend into the maxillary sinus and nasal floor. In either jaw this tumor can originate in an occlusal position to a developing tooth.
- Radiographically, The ameloblastoma is usually well defined and frequently delineated by a cortical border.
- The border is often curved, and in small lesions the border and shape may be indistinguishable from a cyst
- The internal structure varies from totally radiolucent to mixed with the presence of bony septa creating internal compartments. These septa can be straight but are more commonly coarse and curved and originate from normal bone that has been trapped within the tumor.
- These septa are often remodeled into curved shapes providing a **honeycomb** (numerous small compartments or loculations) or **soap bubble** (larger compartments of variable size) patterns.
- There is a pronounced tendency for ameloblastomas to **cause extensive root resorption**.
- Tooth displacement is common. Because a common point of origin is occlusal to a tooth, some teeth may be displaced apically.

#### DISCLAIMER

THIS IS COPYRIGHTED CONTENT. Unauthorized use, including screenshots, copying, misuse, reuse, or resale of any content from this app, is strictly prohibited. Our app monitors and records all screenshots and recordings. Violators will face strict legal action.

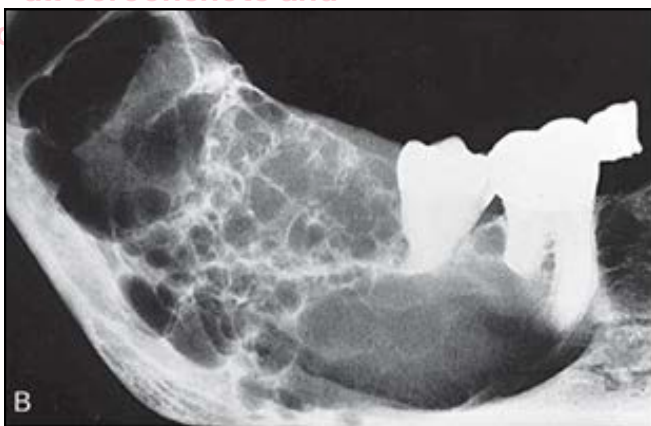
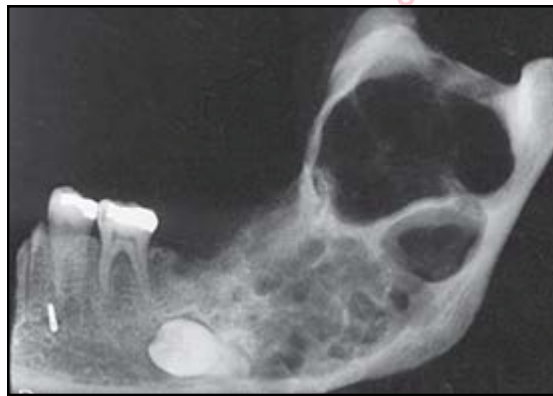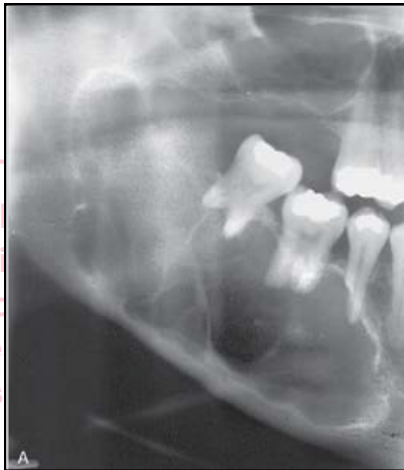DISCLAIMER  
THIS IS COPYRIGHTED CONTENT. Unauthorized use, including screenshots, copying, misuse, reuse, or resale of any content from this app, is strictly prohibited. Our app monitors and records all screenshots and recordings. Violators will face strict legal action.

## JAW CYSTS AND TUMORS

### A. Odontogenic Tumors:

#### 1. Ameloblastoma:

- Computed tomographic (CT) images often reveal regions of perforation of the expanded cortical plate as a result of the inability of the production of periosteal new bone to keep up with the rate of growth of the expanding ameloblastoma.



Images: Examples of ameloblastoma

THIS IS COPYRIGHTED CONTENT. Unauthorized use, including screenshots, copying, misuse, reuse, or resale of any content from this app, is strictly prohibited. Our app monitors and records all screenshots and recordings. Violators will face strict legal action.

#### DISCLAIMER

THIS IS COPYRIGHTED CONTENT. Unauthorized use, including screenshots, copying, misuse, reuse, or resale of any content from this app, is strictly prohibited. Our app monitors and records all screenshots and recordings. Violators will face strict legal action.

THIS IS COPYRIGHTED CONTENT. Unauthorized use, including screenshots, copying, misuse, reuse, or resale of any content from this app, is strictly prohibited. Our app monitors and records all screenshots and recordings. Violators will face strict legal action.

THIS IS COPYRIGHTED CONTENT. Unauthorized use, including screenshots, copying, misuse, reuse, or resale of any content from this app, is strictly prohibited. Our app monitors and records all screenshots and recordings. Violators will face strict legal action.

**DISCLAIMER**  
THIS IS COPYRIGHTED CONTENT. Unauthorized use, including screenshots, copying, misuse, reuse, or resale of any content from this app, is strictly prohibited. Our app monitors and records all screenshots and recordings. Violators will face strict legal action.

## JAW CYSTS AND TUMORS

### B. Mixed Tumors: OF ODONTOGENIC EPITHELIUM AND ODONTOGENIC ECTOMESENCYME

#### 1. Odontoma:

- Also known as Compound odontoma, compound composite odontoma, complex odontoma, complex composite odontoma, odontogenic hamartoma, calcified mixed odontoma, and cystic odontoma.
- The term odontoma is used to identify a tumor that is radiographically and histologically characterized by the production of mature enamel, dentin, cementum, and pulp tissue.
- These components are seen in various states of histodifferentiation and morphodifferentiation.
- Because of its limited and slow growth and well-differentiated tooth tissue, this lesion is considered to be a hamartoma and not a true tumor.
- Odontomas are the most common odontogenic tumor. They often interfere with the eruption of permanent teeth.
- The lesion shows no sex predilection, and most begin forming while the normal dentition is developing. Odontomas develop and mature while the corresponding teeth are forming and cease development when the associated teeth complete development.
- Most odontomas occur in the second decade of life and many times are found during investigation of delayed eruption of adjacent teeth or retained primary teeth.
- There are two types of odontomas.
  - a) Complex
  - b) Compound
- Compound odontomas are about twice as common as the complex type.
- Although the compound variety forms equally between men and women, 60% of complex odontomas occur in women.
- More of the compound type (62%) occur in the anterior maxilla in association with the crown of an unerupted canine.
- In contrast, 70% of complex odontomas are found in the mandibular first and second molar area.
- Radiographically, The borders of odontomas are well defined and may be smooth or irregular. These lesions have a cortical border, and immediately inside and adjacent to the cortical border is a soft tissue capsule.
- The contents of these lesions are largely radiopaque.

#### DISCLAIMER

THIS IS COPYRIGHTED CONTENT. Unauthorized use, including screenshots, copying, misuse, reuse, or resale of any content from this app, is strictly prohibited. Our app monitors and records all screenshots and recordings. Violators will face strict legal action.

#### DISCLAIMER

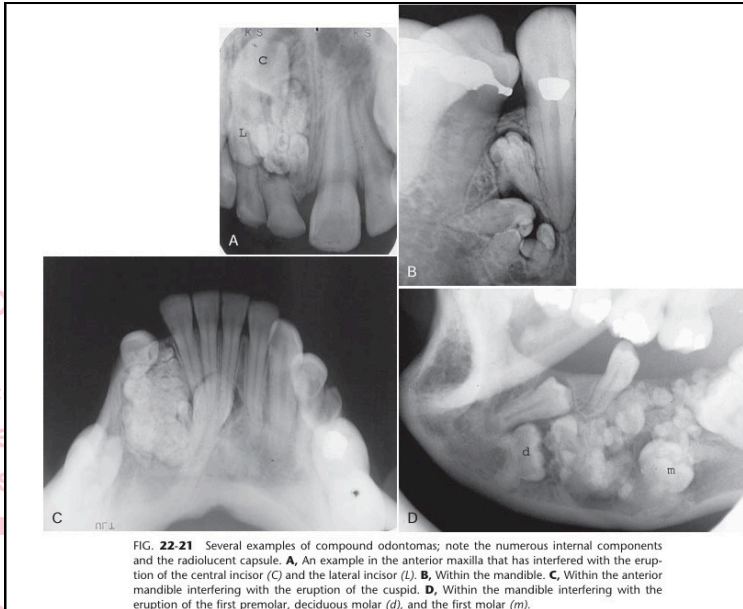
THIS IS COPYRIGHTED CONTENT. Unauthorized use, including screenshots, copying, misuse, reuse, or resale of any content from this app, is strictly prohibited. Our app monitors and records all screenshots and recordings. Violators will face strict legal action.



## JAW CYSTS AND TUMORS

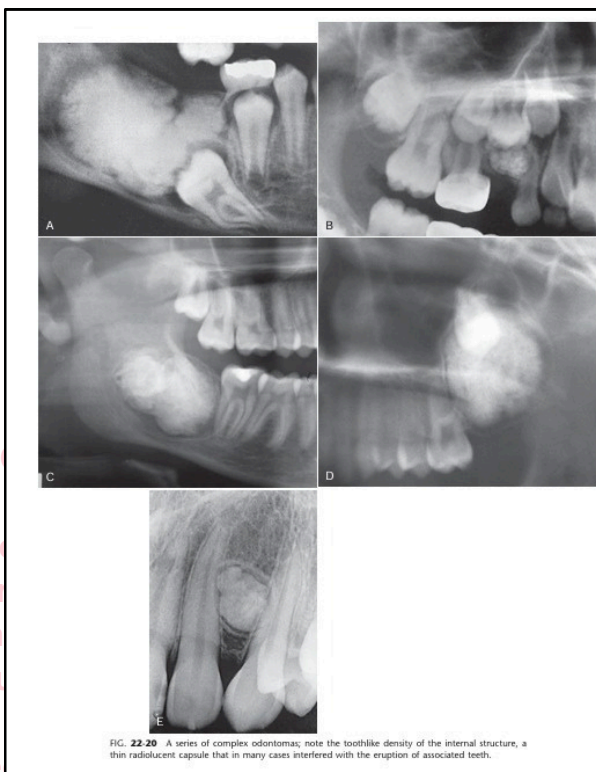
### a) Compound odontomas:

- Compound odontomas have a number of toothlike structures or denticles that look like deformed teeth



### b) Complex Odontomas:

- Complex odontomas contain an irregular mass of calcified tissue.



strict legal action.

#### DISCLAIMER

THIS IS COPYRIGHTED CONTENT. Unauthorized use, including screenshots, copying, misuse, reuse, or resale of any content from this app, is strictly prohibited. Our app monitors and records all screenshots and recordings. Violators will face strict legal action.

THIS IS COPYRIGHTED CONTENT. Unauthorized use, including screenshots, copying, misuse, reuse, or resale of any content from this app, is strictly prohibited. Our app monitors and records all screenshots and recordings. Violators will face strict legal action.

DISCLAIMER  
THIS IS COPYRIGHTED CONTENT. Unauthorized use, including screenshots, copying, misuse, reuse, or resale of any content from this app, is strictly prohibited. Our app monitors and records all screenshots and recordings. Violators will face strict legal action.



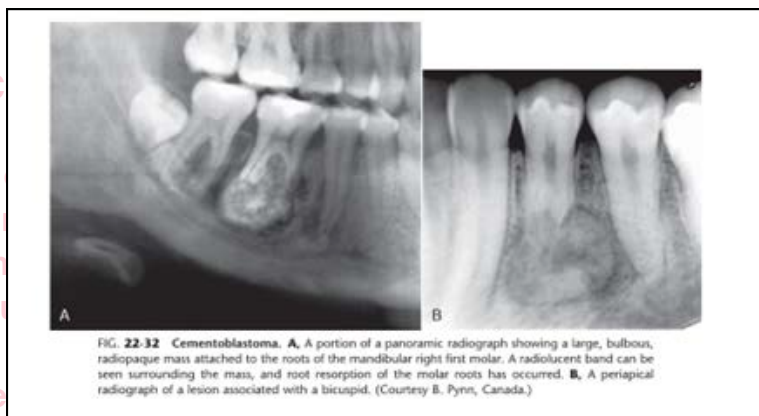
## JAW CYSTS AND TUMORS

### b) Complex Odontomas:

- Odontomas can interfere with the normal eruption of teeth.
- Most odontomas (70%) are associated with abnormalities such as impaction, malpositioning, diastema, aplasia, malformation, and devitalization of adjacent teeth.
- Large complex odontomas may cause expansion of the jaw with maintenance of the cortical boundary.
- Complex and compound odontomas are usually removed by simple excision. They do not recur and are not locally invasive.

### 2. Benign Cementoblastoma

- AKA Cementoblastoma and true cementoma.
- Benign cementoblastomas are slow-growing mesenchymal neoplasms composed principally of cementum-like tissue.
- The tumor manifests as a bulbous growth around and attached to the apex of a tooth root.
- The lesion is more common in males than in females, and the ages of reported patients range from 12 to 65 years, although most patients are relatively young
- The tumor usually is a solitary lesion that is slow growing but that may eventually displace teeth.
- The **involved tooth is vital and often painful**. The pain seems to vary from patient to patient and can be relieved by anti-inflammatory drugs.
- Radiographically, Benign cementoblastomas occur more often in the mandible (78%) and form most commonly on a premolar or first molar (90%). The lesion is a well-defined radiopacity with a cortical border and then a well-defined radiolucent band just inside the cortical border.
- Benign cementoblastomas are mixed radio lucent-radiopaque lesions where the majority of the internal structure is radiopaque. The resulting pattern may be amorphous or may have a wheel spoke pattern.
- This central radiopaque mass as mentioned is surrounded by a radiolucent band, indicating that the tumor is maturing from the central aspect to the periphery.



#### DISCLAIMER

THIS IS COPYRIGHTED CONTENT. Unauthorized use, including screenshots, copying, misuse, reuse, or resale of any content from this app, is strictly prohibited. Our app monitors and records all screenshots and recordings. Violators will face strict legal action.

# JAW CYSTS AND TUMORS

## 2. Benign Cementoblastoma

- Benign cementoblastomas are self-limiting and rarely recur after enucleation.
- Simple excision and extraction of the associated tooth is sufficient treatment.
- In some cases, the tumor may be amputated from the tooth, which is then treated endodontically.

THIS IS COPYRIGHTED CONTENT. Unauthorized use, including screenshots, copying, misuse, reuse, or resale of any content from this app, is strictly prohibited. Our app monitors and records all screenshots and recordings. Violators will face strict legal action.

THIS IS COPYRIGHTED CONTENT. Unauthorized use, including screenshots, copying, misuse, reuse, or resale of any content from this app, is strictly prohibited. Our app monitors and records all screenshots and recordings. Violators will face strict legal action.

THIS IS COPYRIGHTED CONTENT. Unauthorized use, including screenshots, copying, misuse, reuse, or resale of any content from this app, is strictly prohibited. Our app monitors and records all screenshots and recordings. Violators will face strict legal action.

THIS IS COPYRIGHTED CONTENT. Unauthorized use, including screenshots, copying, misuse, reuse, or resale of any content from this app, is strictly prohibited. Our app monitors and records all screenshots and recordings. Violators will face strict legal action.

### DISCLAIMER

THIS IS COPYRIGHTED CONTENT. Unauthorized use, including screenshots, copying, misuse, reuse, or resale of any content from this app, is strictly prohibited. Our app monitors and records all screenshots and recordings. Violators will face strict legal action.

DISCLAIMER  
THIS IS COPYRIGHTED CONTENT. Unauthorized use, including screenshots, copying, misuse, reuse, or resale of any content from this app, is strictly prohibited. Our app monitors and records all screenshots and recordings. Violators will face strict legal action.

## LA TECHNIQUES AND COMPLICATIONS

Sources: (TG, Review Article on Neural Blockade Anesthesia of the Mandibular Nerve and Its Terminal Branches, Methods of administration of local anesthesia by Dr. Elham Hazeim Abdulkareem, nicb article)

- Pain is an unpleasant sensory and psychological experience resulting from actual or potential tissue damage and is commonly associated with dental treatment.
- **Local anesthesia is a safe and effective way of managing pain.**
- Anesthetic agents work by reversibly binding to sodium channels, preventing the entry of sodium into the cells and thereby inhibiting the propagation of nerve impulses. Consequently, nociceptive impulses associated with painful stimuli do not reach the brain, and the patient does not perceive pain.
- Local anesthesia in dentistry can be given as either infiltration or block anesthesia. Generally, infiltration anesthesia is commonly used in the maxilla, whereas block anesthesia is frequently used in the mandible.

### Local Anesthetic Agents

- Local anesthetics are divided into two classes:
  - a) amides and
  - b) esters
- Amide anesthetics are common in dentistry, including lidocaine, prilocaine, mepivacaine, and bupivacaine. Articaine is an amide anesthetic with an ester linkage.
- Ester anesthetics are less frequently utilized in dentistry, but drugs such as benzocaine may be used for topical anesthesia.
- The gold standard and most widely used local anesthetic in dentistry is lidocaine due to its safety and effectiveness.
- Adrenaline is added to lidocaine to counteract its vasodilating properties and delay drug absorption, which prolongs the duration of anesthesia and reduces the toxicity risk.

#### Adding vasoconstrictors to local anaesthetics

Local anaesthetics may be used in combination with a vasoconstrictor to prolong local anaesthetic effects. Vasoconstriction reduces the rate of local anaesthetic loss to the circulation and reduces bleeding, both during and after the procedure.

Adrenaline (epinephrine) is a commonly used vasoconstrictor in dental practice. Avoid adrenaline-containing solutions in patients with known sensitivity to sulfites\*, because metabisulfites are used as a preservative. If adrenaline cannot be used, local anaesthetic solutions containing felypressin or solutions without a vasoconstrictor are alternatives.

Felypressin is an alternative vasoconstrictor to adrenaline (epinephrine) because it has minimal effects on the myocardium at the concentration used in dental cartridges (0.03 international units/mL). Felypressin is safe for dental use in pregnant patients, although previously this was contraindicated.

Our app monitors and records all screenshots and recordings. Violators will face strict legal action.

#### DISCLAIMER

THIS IS COPYRIGHTED CONTENT. Unauthorized use, including screenshots, copying, misuse, reuse, or resale of any content from this app, is strictly prohibited. Our app monitors and records all screenshots and recordings. Violators will face strict legal action.

DISCLAIMER  
THIS IS COPYRIGHTED CONTENT. Unauthorized use, including screenshots, copying, misuse, reuse, or resale of any content from this app, is strictly prohibited. Our app monitors and records all screenshots and recordings. Violators will face strict legal action.



## LA TECHNIQUES AND COMPLICATIONS

### Choice of Local anesthetic agent in dentistry: (TG)

#### Choosing a local anaesthetic in dentistry

Table 19 (below) outlines properties of local anaesthetic preparations for infiltration or regional block in dentistry. Consult a source of drug information for precautions, contraindications, drug interactions and adverse effects (for resources, see p.61).

**Table 19. Local anaesthetics for infiltration or regional block in dentistry**

Local anaesthetic	Comments
<b>Short- to intermediate-acting preparations</b>	
lidocaine	shorter acting—use in dentistry may be limited
lidocaine with adrenaline (epinephrine) [NB1]	intermediate acting first line for routine dental procedures
prilocaine [NB1]	shorter acting—use in dentistry may be limited
prilocaine with adrenaline (epinephrine) [NB1]	intermediate acting
prilocaine with felypressin [NB1]	intermediate acting first line for routine dental procedures when adrenaline (epinephrine) is contraindicated
mepivacaine [NB1]	shorter acting—use in dentistry may be limited do not use in children younger than 3 years
mepivacaine with adrenaline (epinephrine) [NB1]	intermediate acting do not use in children younger than 3 years
articaine with adrenaline (epinephrine) [NB1]	risk of prolonged or permanent anaesthesia for infiltration only—do not use for regional blocks (injection close to inferior alveolar, lingual and mental nerves) do not use in children younger than 4 years

**Table 19. Local anaesthetics for infiltration or regional block in dentistry (cont.)**

Local anaesthetic	Comments
<b>Long-acting preparations</b>	
ropivacaine	useful for situations in which prolonged analgesia (eg 12 to 18 hours) is required, postoperative pain, and refractory acute dental pain concentrations up to 0.5% can be used in children
bupivacaine	similar indications to ropivacaine more cardiotoxic than ropivacaine cardiac toxicity may manifest before neurological toxicity do not use in children younger than 12 years
bupivacaine with adrenaline (epinephrine)	similar indications to ropivacaine more cardiotoxic than ropivacaine cardiac toxicity may manifest before neurological toxicity do not use in children younger than 12 years

NB1: Available in dental cartridges.

#### DISCLAIMER

THIS IS COPYRIGHTED CONTENT. Unauthorized use, including screenshots, copying, misuse, reuse, or resale of any content from this app, is strictly prohibited. Our app monitors and records all screenshots and recordings. Violators will face strict legal action.

## LA TECHNIQUES AND COMPLICATIONS

### Methods of administration:

- The methods of administration of local anesthesia are sub-divided into three methods:

#### a) Topical:

- It is obtained by the application of a suitable anesthetic agent to an area of either skin or mucous membrane in which it penetrates to anesthetize superficial nerve endings. It is commonly used to obtain anesthesia of mucosa prior to injection.
- After topical anesthesia, analgesia occurs approximately 3 mins after administration. (TG)
- It is indicated for minor painful procedures like band removal crown placement, mucosal incision.

Topical administration of a local anaesthetic\* is indicated for minor painful procedures (eg band removal, crown placement, mucosal incision). It may also be used to facilitate injection of local anaesthetic in anxious or needle-phobic patients by eliminating pain on the mucosal surface; however, patients may experience discomfort upon injection of local anaesthetic into the deeper tissues.

#### b) Infiltration:

- In this method the anesthetic solution deposited near the terminal fibers of any nerve, it will infiltrate through the tissues to reach the nerve fibers and thus produce anesthesia of the localized area served by them.
- LA is injected adjacent to the site where analgesia is required.
- Infiltration is sufficient for most teeth, except lower molars.
- Analgesia occurs approximately 2 to 3 minutes after an infiltration injection.
- This technique is subdivided into:

##### i. Sub mucous injection:

- In this technique the solution is deposited just beneath the mucous membrane. This technique is unlikely to produce anesthesia of the dental pulp, it is often employed to anesthetize the long buccal nerve prior to the extraction of mandibular molars or for soft tissue surgery.

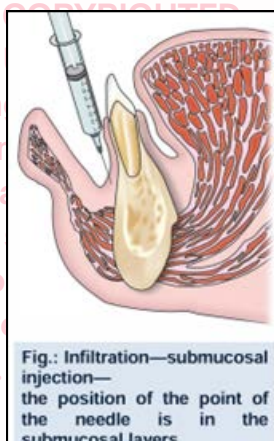


Fig.: Infiltration—submucosal injection—the position of the point of the needle is in the submucosal layers.

DISCLAIMER

THIS IS COPYRIGHTED CONTENT. Unauthorized use, including screenshots, copying, misuse, reuse, or resale of any content from this app, is strictly prohibited. Our app monitors and records all screenshots and recordings. Violators will face strict legal action.

DISCLAIMER  
THIS IS COPYRIGHTED CONTENT. Unauthorized use, including screenshots, copying, misuse, reuse, or resale of any content from this app, is strictly prohibited. Our app monitors and records all screenshots and recordings. Violators will face strict legal action.

## LA TECHNIQUES AND COMPLICATIONS

### Methods of administration:

#### b) Infiltration:

##### ii. Supra periosteal injection:

- In some sites, such as the maxilla, the outer cortical plate of alveolar bone is thin and perforated by tiny vascular canals.
- In these areas when anesthetic solution is deposited outside the periosteum, it will infiltrate through the periosteum, cortical plate, and medullary bone to the nerve fibers.
- The Supra-periosteal injection is the technique most frequently used in dentistry.

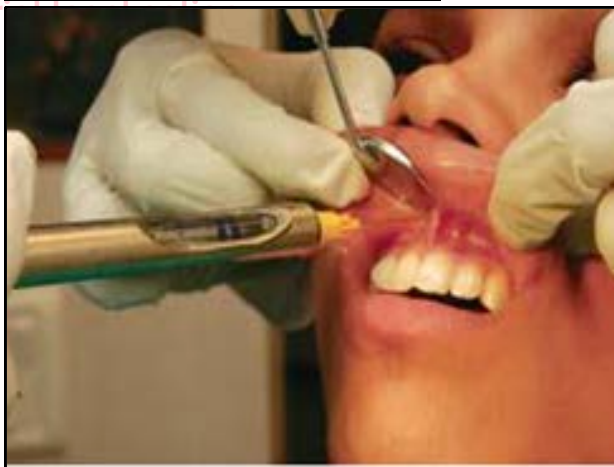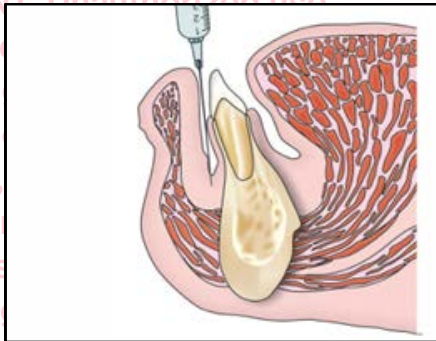


Fig: Infiltration—supraperiosteal injection in anterior maxilla—the position of the point of the needle is at an angle of  $45^\circ$  to the long axis of the tooth



## LA TECHNIQUES AND COMPLICATIONS

### Methods of administration:

#### b) Infiltration:

##### ii. Supra periosteal injection:

##### Buccal Infiltration

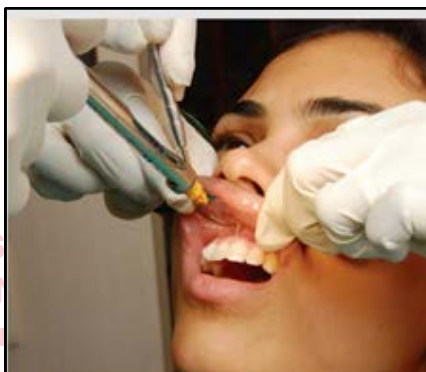- The needle is inserted 2 or 3 mm into the buccal sulcus adjacent to the tooth to be treated. The solution diffuses across the periosteum and alveolar bone to anesthetize the nerves supplying sensation to the tooth, periodontium, and buccal gingiva

##### Palatal Infiltration

- A palatal infiltration can be administered to anesthetize the nasopalatine or greater palatine nerve endings, thus providing anesthesia to the palatal gingiva.
- This injection is often described as painful due to the separation of the tightly-bound mucoperiosteum from the underlying hard palate bone.
- Methods to reduce discomfort may include topical anesthesia, cooling, applying pressure with a mirror handle, or slightly retracting the needle before injection.

##### iii. Sub periosteal injection:

- In this technique the solution is deposited between the periosteum and the cortical plate.
- This technique is painful since the periosteum is firmly bound to the cortical plate.



**Fig.:** Infiltration—subperiosteal injection in anterior maxilla—the position of the point of the needle is at an angle of 90° to the long axis of the tooth and the alveolar bone as seen from the side.

**DISCLAIMER**

THIS IS COPYRIGHTED CONTENT. Unauthorized use, including screenshots, copying, misuse, reuse, or resale of any content from this app, is strictly prohibited. Our app monitors and records all screenshots and recordings. Violators will face strict legal action.

**DISCLAIMER**

THIS IS COPYRIGHTED CONTENT. Unauthorized use, including screenshots, copying, misuse, reuse, or resale of any content from this app, is strictly prohibited. Our app monitors and records all screenshots and recordings. Violators will face strict legal action.

## LA TECHNIQUES AND COMPLICATIONS

### Methods of administration:

#### b) Infiltration:

##### iv. Intra osseous injection:

- In this technique, the solution is deposited within the medullary bone. The procedure is carried out by the use of bone drills and needles especially designed for this purpose.

##### v. Intra ligamentary injection (Periodontal or peri dental injection)

- It anesthetizes the terminal nerve endings at the site of injection at the apex of the tooth.
- A 27-gauge short needle recommended for this technique.
- Area of insertion is the long axis of the tooth to be treated on its mesial or distal of the root and target area is the depth of the gingival sulcus.

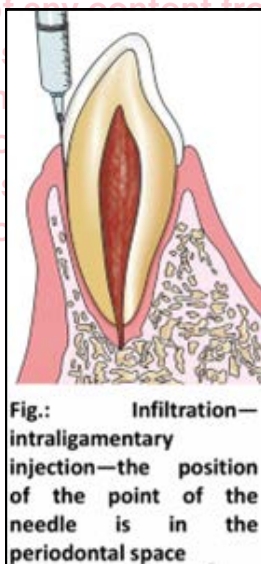


Fig.: Infiltration—  
intra-ligamentary  
injection—the position  
of the point of the  
needle is in the  
periodontal space

##### vi. Intra-pulpal anesthesia:

- This technique is indicated for obtaining anesthesia for procedures which require direct instrumentation of the pulpal tissue.
- A 25 or 27-gauge needle is inserted directly into the pulp chamber.
- The needle should be held firmly or wedged into the pulp chamber or the root canal.
- Initially, slight discomfort is felt by the patient which subsequently gets subsided.
- Sometimes the needle is bent to get a proper angle for good approach.

#### DISCLAIMER

THIS IS COPYRIGHTED CONTENT. Unauthorized use, including screenshots, copying, misuse, reuse, or resale of any content from this app, is strictly prohibited. Our app monitors and records all screenshots and recordings. Violators will face strict legal action.

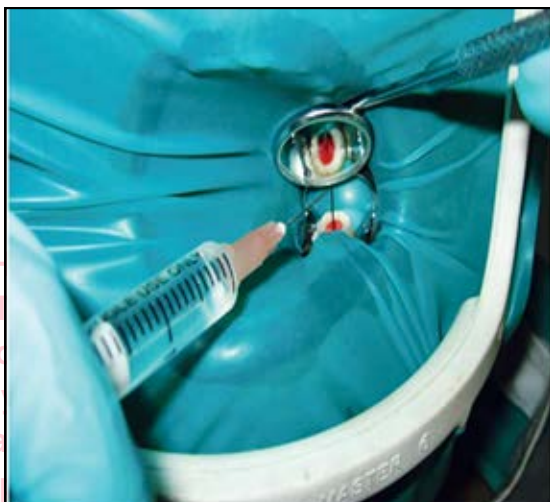DISCLAIMER  
THIS IS COPYRIGHTED CONTENT. Unauthorized use, including screenshots, copying, misuse, reuse, or resale of any content from this app, is strictly prohibited. Our app monitors and records all screenshots and recordings. Violators will face strict legal action.

## LA TECHNIQUES AND COMPLICATIONS

### Methods of administration:

#### b) Infiltration:

##### vi. Intra-pulpal anesthesia:



**Fig.:** Infiltration—intrapulpal injection—the point of the needle is in the pulp chamber (Courtesy: Dr Vibha Hegde)

#### c) Regional techniques:

- LA is injected adjacent to the nerve proximal to the site where analgesia is required.
- A regional block aims to prevent pain experienced in the area of nerve distribution distal to the site of injection.
- Analgesia occurs approximately 4-5 minutes after a block injection. (TG)
- In this technique, the anesthetic solution deposited near a nerve trunk will, by blocking all impulses, produce anesthesia of the area supplied by that nerve.

THIS IS COPYRIGHTED CONTENT. Unauthorized use, including screenshots, copying, misuse, reuse, or resale of any content from this app, is strictly prohibited. Our app monitors and records all screenshots and recordings. Violators will face strict legal action.

#### DISCLAIMER

THIS IS COPYRIGHTED CONTENT. Unauthorized use, including screenshots, copying, misuse, reuse, or resale of any content from this app, is strictly prohibited. Our app monitors and records all screenshots and recordings. Violators will face strict legal action.

THIS IS COPYRIGHTED CONTENT. Unauthorized use, including screenshots, copying, misuse, reuse, or resale of any content from this app, is strictly prohibited. Our app monitors and records all screenshots and recordings. Violators will face strict legal action.

DISCLAIMER  
THIS IS COPYRIGHTED CONTENT. Unauthorized use, including screenshots, copying, misuse, reuse, or resale of any content from this app, is strictly prohibited. Our app monitors and records all screenshots and recordings. Violators will face strict legal action.



## LA TECHNIQUES AND COMPLICATIONS

### MAXILLARY BLOCKS

Maxillary anesthesia is used to provide pain control during dental procedures involving the maxillary (upper) teeth and their surrounding structures. It targets branches of the maxillary division (V2) of the trigeminal nerve, a purely sensory nerve. Unlike the mandible, the maxillary bone is more porous, especially in children and the anterior region, allowing for effective infiltration anesthesia. A variety of injection techniques are available, depending on the extent of anesthesia required.

### TYPES OF MAXILLARY NERVE BLOCKS

#### 1. Local Infiltration

Local infiltration involves depositing the anesthetic near small terminal nerve endings in the immediate area of the procedure. It is most effective in the maxilla due to its bone porosity. It's typically used for soft tissue procedures or limited procedures involving a single tooth.

**Technique:** The anesthetic is deposited in the mucobuccal fold near the apex of the tooth being treated. Onset is rapid due to the thin cortical plate.

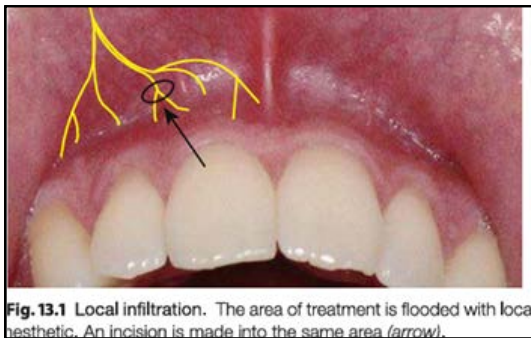


Fig. 13.1 Local infiltration. The area of treatment is flooded with local anesthetic. An incision is made into the same area (arrow).

#### 2. Field Block (Supraperiosteal Injection)

This is often mistakenly referred to as a local infiltration. A field block anesthetizes larger terminal branches before they enter the bone, affecting the tooth, adjacent buccal bone, and soft tissues

**Indication:** Effective for one or two teeth, especially in the anterior maxilla. **Technique:** Injection is placed in the mucobuccal fold over the apex of the tooth. Needle should be advanced a few millimeters to ensure the solution bathes the nerve branches adequately.

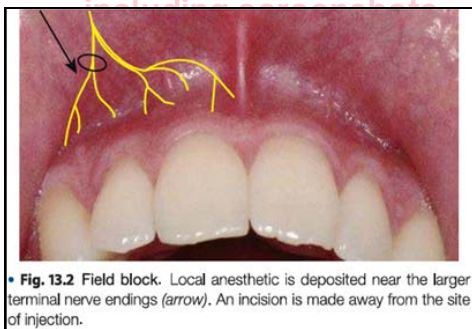


Fig. 13.2 Field block. Local anesthetic is deposited near the larger terminal nerve endings (arrow). An incision is made away from the site of injection.

### DISCLAIMER

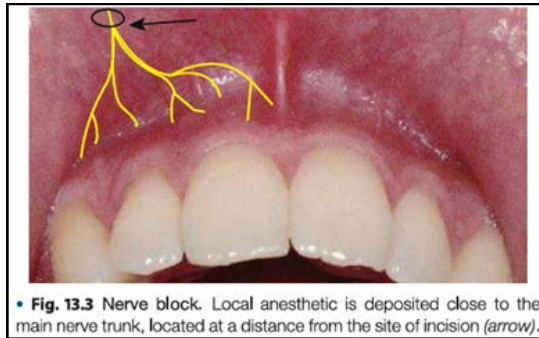
THIS IS COPYRIGHTED CONTENT. Unauthorized use, including screenshots, copying, misuse, reuse, or resale of any content from this app, is strictly prohibited. Our app monitors and records all screenshots and recordings. Violators will face strict legal action.

# LA TECHNIQUES AND COMPLICATIONS

## TYPES OF MAXILLARY NERVE BLOCKS

### 3. Nerve Blocks

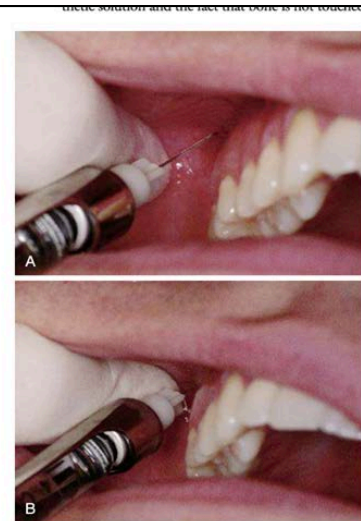
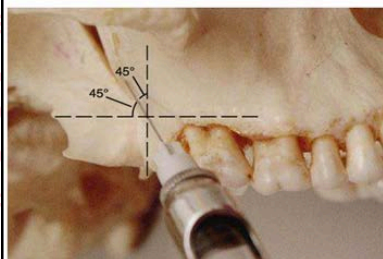
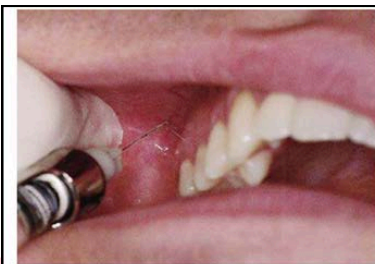
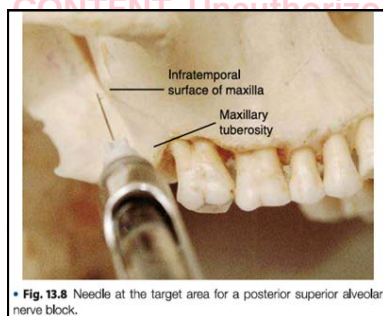
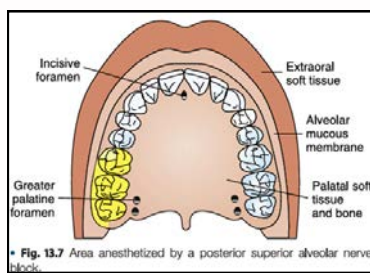
Nerve blocks anesthetize larger nerve trunks, allowing broader areas to be anesthetized with a single injection. These are used for procedures involving multiple teeth or when infiltration is contraindicated.



## SPECIFIC MAXILLARY NERVE BLOCKS

### A. Posterior Superior Alveolar (PSA) Nerve Block

- Nerve anesthetized: PSA nerve, a branch of V2.
- Areas affected: Maxillary molars (except the mesiobuccal root of the first molar in ~28% of patients), buccal periodontium, and overlying soft tissues.
- Landmarks: Mucobuccal fold above the second molar; zygomatic process.
- Technique: The needle is inserted upward, inward, and backward at a 45-degree angle to the long axis of the second molar. It is advanced ~16 mm. Aspiration is critical due to the risk of positive aspiration (3–4%).



### DISCLAIMER

THIS IS COPYRIGHTED CONTENT. Unauthorized use, including screenshots, copying, misuse, reuse, or resale of any content from this app, is strictly prohibited. Our app monitors and records all screenshots and recordings. Violators will face strict legal action.

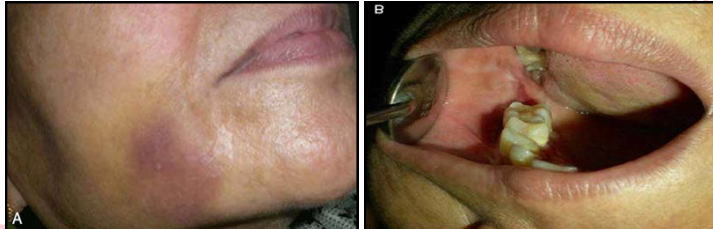


## LA TECHNIQUES AND COMPLICATIONS

### SPECIFIC MAXILLARY NERVE BLOCKS

#### A. Posterior Superior Alveolar (PSA) Nerve Block

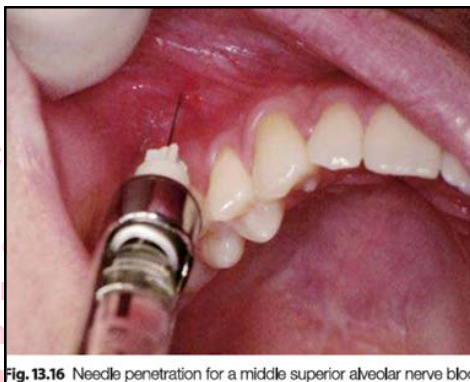
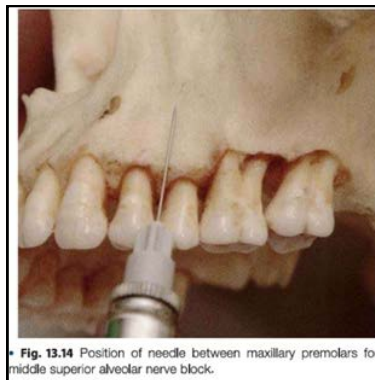
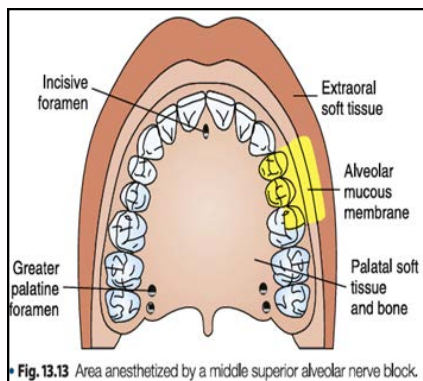
- **Complication:** Risk of hematoma due to proximity to the pterygoid venous plexus.



Haematoma subsequent to PSA nerve block, A- Extraoral, B-Intraoral

#### B. Middle Superior Alveolar (MSA) Nerve Block

- **Nerve anesthetized:** MSA nerve, when present (missing in ~50% of individuals).
- **Areas affected:** Maxillary premolars and mesiobuccal root of the first molar.
- **Landmarks:** Mucobuccal fold over the second premolar.
- **Technique:** Insert the needle above the second premolar apex; direct it toward the bone and advance 5–8 mm.
- **Note:** If the MSA is absent, the ASA and PSA nerves compensate.



#### DISCLAIMER

THIS IS COPYRIGHTED CONTENT. Unauthorized use, including screenshots, copying, misuse, reuse, or resale of any content from this app, is strictly prohibited. Our app monitors and records all screenshots and recordings. Violators will face strict legal action.

#### DISCLAIMER

THIS IS COPYRIGHTED CONTENT. Unauthorized use, including screenshots, copying, misuse, reuse, or resale of any content from this app, is strictly prohibited. Our app monitors and records all screenshots and recordings. Violators will face strict legal action.

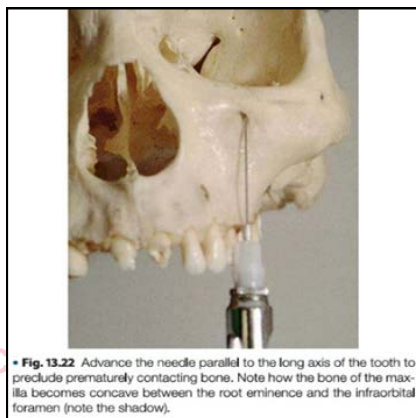
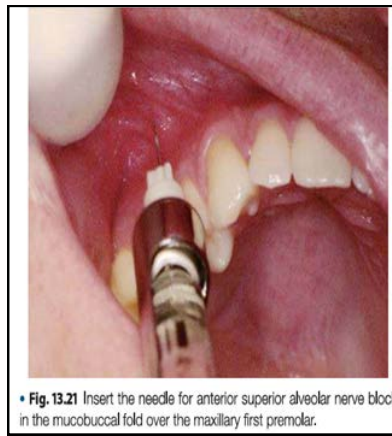
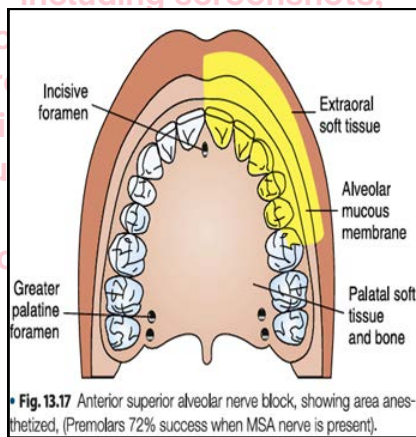


## LA TECHNIQUES AND COMPLICATIONS

### SPECIFIC MAXILLARY NERVE BLOCKS

#### C. Anterior Superior Alveolar (ASA) Nerve Block / Infraorbital Nerve Block

- Nerve anesthetized: ASA nerve and terminal branches of the infraorbital nerve.
- Areas affected: Maxillary central and lateral incisors, canine, premolars, mesiobuccal root of the first molar, and soft tissues of upper lip, side of nose, and lower eyelid.
- Landmarks: Infraorbital notch and foramen.
- Technique: Needle is directed toward the infraorbital foramen via the mucobuccal fold over the first premolar. The finger is used to palpate the infraorbital notch and guide the needle. Advance ~16 mm.
- Note: Apply pressure over the foramen post-injection to facilitate spread into the canal.



copying, misuse, reuse, or resale of any content from this app, is strictly prohibited. Our app monitors and records all screenshots and recordings. Violators will face strict legal action.

#### DISCLAIMER

THIS IS COPYRIGHTED CONTENT. Unauthorized use, including screenshots, copying, misuse, reuse, or resale of any content from this app, is strictly prohibited. Our app monitors and records all screenshots and recordings. Violators will face strict legal action.

DISCLAIMER  
THIS IS COPYRIGHTED CONTENT. Unauthorized use, including screenshots, copying, misuse, reuse, or resale of any content from this app, is strictly prohibited. Our app monitors and records all screenshots and recordings. Violators will face strict legal action.

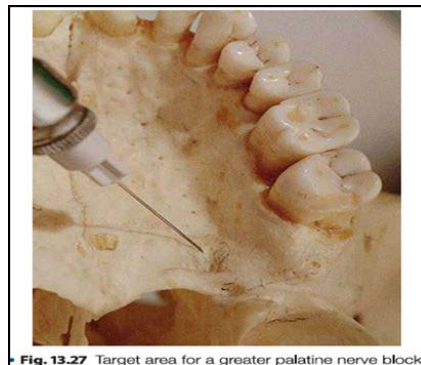
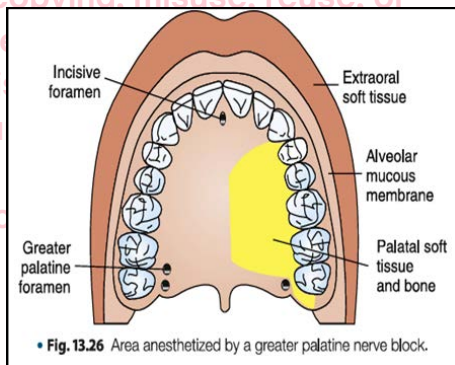
## LA TECHNIQUES AND COMPLICATIONS

### PALATAL ANESTHESIA TECHNIQUES

Palatal tissues are dense and tightly bound to underlying bone, requiring slow, controlled injections to reduce pain. Topical anesthetic and pressure anesthesia help improve comfort.

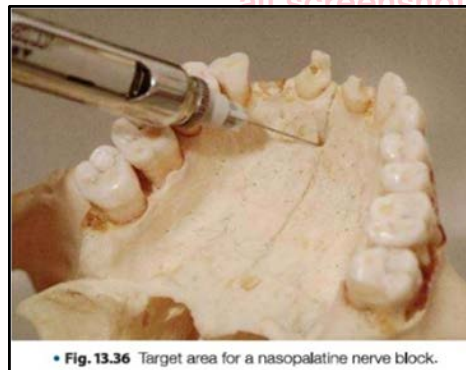
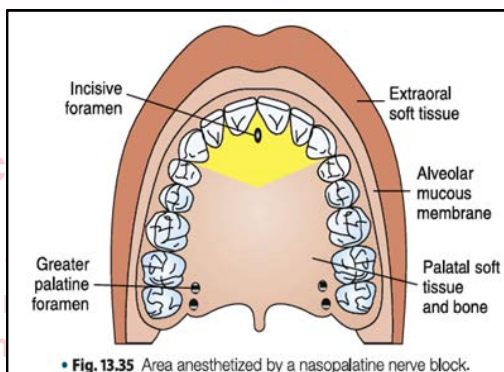
#### A. Greater Palatine Nerve Block

- Nerve anesthetized: Greater palatine nerve.
- Areas affected: Posterior portion of the hard palate and soft tissues from the canine posteriorly.
- Landmarks: Greater palatine foramen, usually distal to the second molar at the junction of the maxillary alveolar process and the palatine bone.
- Technique: Insert the needle 1–2 mm anterior to the foramen at a 90-degree angle. Advance ~5 mm slowly.



#### B. Nasopalatine Nerve Block

- Nerve anesthetized: Nasopalatine nerve.
- Areas affected: Anterior hard palate (canine to canine).
- Landmarks: Incisive papilla.
- Technique: Insert the needle just lateral to the incisive papilla. Penetrate only a few millimeters (~5 mm), and deposit slowly to avoid discomfort.



#### DISCLAIMER

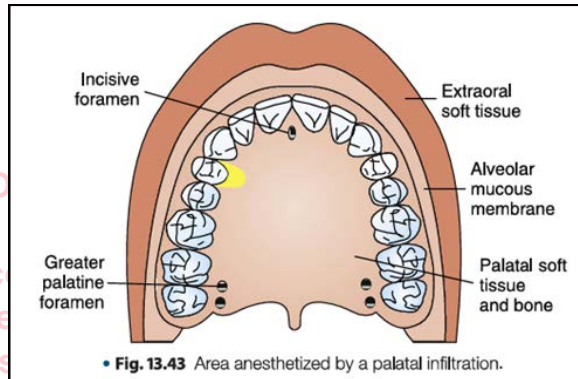
THIS IS COPYRIGHTED CONTENT. Unauthorized use, including screenshots, copying, misuse, reuse, or resale of any content from this app, is strictly prohibited. Our app monitors and records all screenshots and recordings. Violators will face strict legal action.

## LA TECHNIQUES AND COMPLICATIONS

### PALATAL ANESTHESIA TECHNIQUES

#### C. Anterior Palatal (Infiltration)

- Use: Useful for small localized procedures or single-tooth palatal work.
- Technique: Injection made directly into the palatal soft tissue adjacent to the target area.
- Note: May be used with pressure anesthesia for improved patient comfort.



#### Maxillary Nerve (V2) Block

- This is a deep nerve block that anesthetizes the entire second division of the trigeminal nerve.
- Indications:
  - Extensive procedures involving more than one quadrant.
  - Failure of other maxillary blocks due to anatomical variation.
  - Situations where tissue inflammation precludes successful infiltration.
- Approaches:
- High tuberosity approach
  - Needle inserted superior and posterior to the second molar.
  - Penetration depth: ~30 mm.
  - Higher risk of hematoma due to vascular proximity.
- Greater palatine canal approach
  - Through the greater palatine foramen and canal.
  - Requires precise depth control (penetration ~30 mm).
  - More technically difficult, but can be effective for full V2 blockade.
- Extraoral (infrazygomatic) approach
  - Needle introduced through the skin of the face.
  - Primarily used in surgical or hospital settings.
- Structures anesthetized:
  - Maxillary teeth on one side
  - Buccal and palatal soft tissues
  - Skin of the lower eyelid, cheek, side of the nose, and upper lip

#### DISCLAIMER

THIS IS COPYRIGHTED CONTENT. Unauthorized use, including screenshots, copying, misuse, reuse, or resale of any content from this app, is strictly prohibited. Our app monitors and records all screenshots and recordings. Violators will face strict legal action.

#### DISCLAIMER

THIS IS COPYRIGHTED CONTENT. Unauthorized use, including screenshots, copying, misuse, reuse, or resale of any content from this app, is strictly prohibited. Our app monitors and records all screenshots and recordings. Violators will face strict legal action.

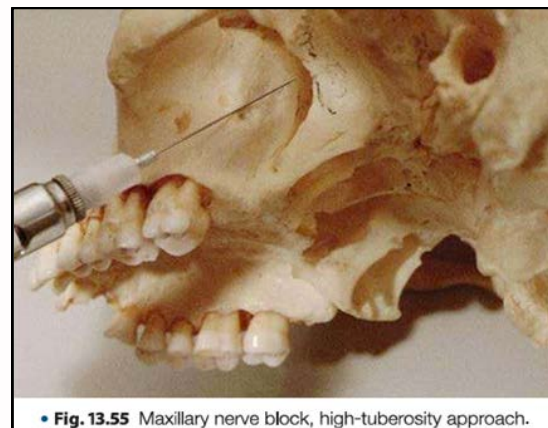
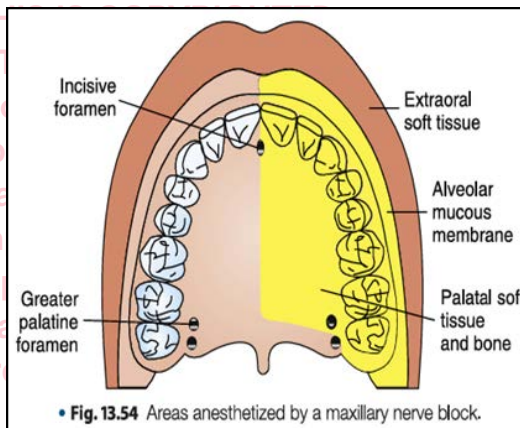


## LA TECHNIQUES AND COMPLICATIONS

### PALATAL ANESTHESIA TECHNIQUES

#### Maxillary Nerve (V2) Block

- **Complications and Considerations**
  - **Hematoma:** Most common with PSA and high tuberosity V2 blocks.
  - **Pain on injection:** Especially during palatal anesthesia. Minimized with slow injection and pressure anesthesia.
  - **Inadequate anesthesia:** May result from anatomical variations or accessory innervation.
  - **Intravascular injection:** Always aspirate to avoid systemic complications.



#### Conclusion:

Maxillary anesthesia is versatile due to the anatomical nature of the maxilla, allowing both infiltration and nerve block techniques to be effective. Understanding the distribution of the maxillary nerve and its branches enables clinicians to select appropriate techniques tailored to the procedure and patient anatomy. Proper technique, knowledge of anatomical landmarks, and care to avoid complications ensure safe and successful anesthesia.

THIS IS COPYRIGHTED CONTENT. Unauthorized use, including screenshots, copying, misuse, reuse, or resale of any content from this app, is strictly prohibited. Our app monitors and records all screenshots and recordings. Violators will face strict legal action.

#### DISCLAIMER

THIS IS COPYRIGHTED CONTENT. Unauthorized use, including screenshots, copying, misuse, reuse, or resale of any content from this app, is strictly prohibited. Our app monitors and records all screenshots and recordings. Violators will face strict legal action.

DISCLAIMER  
THIS IS COPYRIGHTED CONTENT. Unauthorized use, including screenshots, copying, misuse, reuse, or resale of any content from this app, is strictly prohibited. Our app monitors and records all screenshots and recordings. Violators will face strict legal action.

# LA TECHNIQUES AND COMPLICATIONS

## MANDIBULAR BLOCKS

### Overview:

Mandibular nerve blocks are crucial in dentistry for achieving profound anesthesia in the lower jaw (mandible). The mandibular division of the trigeminal nerve (V3) carries both sensory and motor fibers, and successful blockade enables a wide range of dental procedures. These blocks are more technique-sensitive compared to maxillary blocks due to anatomical variations, thicker cortical bone, and indirect needle paths.

### Relevant Anatomy:

The mandibular nerve (a branch of the trigeminal nerve) exits the skull via the foramen ovale and divides into several branches, including:

- Inferior alveolar nerve (IAN): Supplies mandibular teeth.
- Lingual nerve: Supplies the anterior two-thirds of the tongue and floor of the mouth.
- Buccal nerve: Supplies the skin and mucosa of the cheek.
- Mylohyoid nerve: A motor branch that may also carry accessory sensory fibers to mandibular teeth.

Understanding the anatomical location of the mandibular foramen, where the IAN enters the mandible, is vital for effective anesthesia. The location of the foramen varies with age and dental status.

## TYPES OF MANDIBULAR BLOCKS:

### 1. INFERIOR ALVEOLAR NERVE BLOCK

#### A) Direct Technique

- Involves a single needle insertion targeting the inferior alveolar nerve.
- Syringe barrel is positioned over the opposite premolars or canine area.
- Needle advances medially to the ramus until bone is contacted.
- Anesthetic is deposited after negative aspiration.
- Typically anesthetizes inferior alveolar and lingual nerves.
- More commonly used due to its simplicity.
- Higher success rate for inferior alveolar nerve block.
- Less technique-sensitive.

### DISCLAIMER

THIS IS COPYRIGHTED CONTENT. Unauthorized use, including screenshots, copying, misuse, reuse, or resale of any content from this app, is strictly prohibited. Our app monitors and records all screenshots and recordings. Violators will face strict legal action.

# LA TECHNIQUES AND COMPLICATIONS

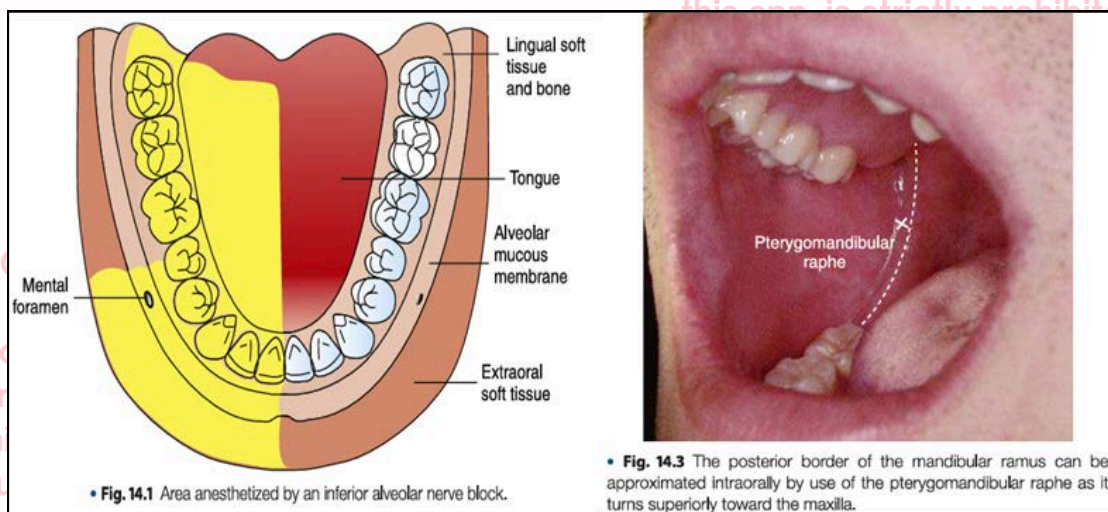
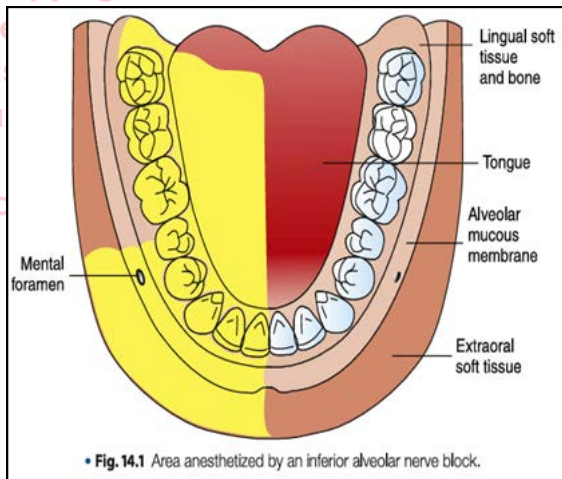
## MANDIBULAR BLOCKS

### TYPES OF MANDIBULAR BLOCKS:

#### 1. INFERIOR ALVEOLAR NERVE BLOCK

##### B) Indirect Technique

- Involves a single needle insertion but anesthetizes multiple nerves (inferior alveolar, lingual, and sometimes buccal).
- Syringe position is shifted during the procedure to redirect the needle.
- Aimed at minimizing the number of tissue penetrations.
- Technically more complex and requires angulation adjustments.
- Slightly lower success rate due to technical difficulty.
- Used less commonly in modern practice.



##### DISCLAIMER

THIS IS COPYRIGHTED CONTENT. Unauthorized use, including screenshots, copying, misuse, reuse, or resale of any content from this app, is strictly prohibited. Our app monitors and records all screenshots and recordings. Violators will face strict legal action.



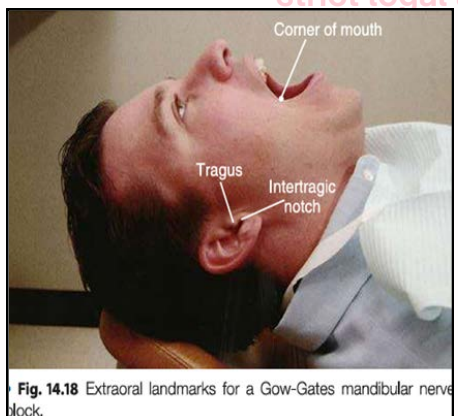
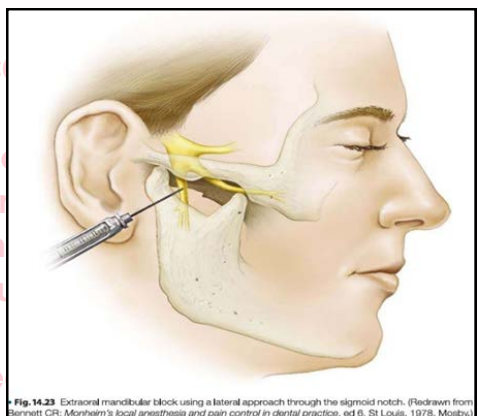
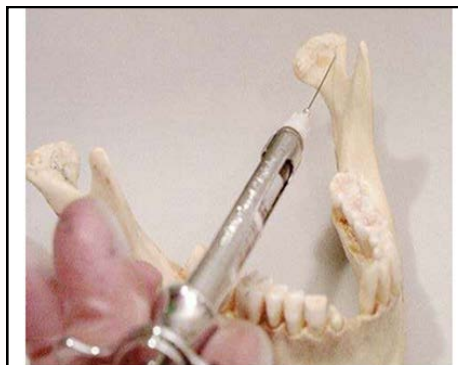
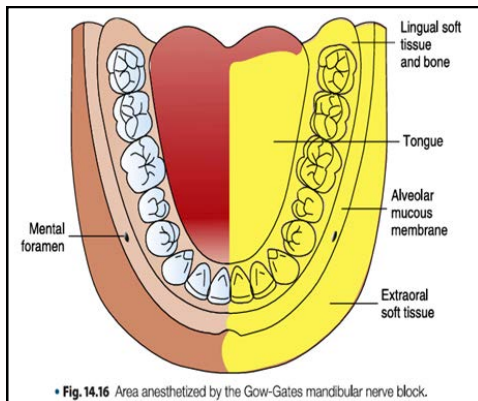
# LA TECHNIQUES AND COMPLICATIONS

## MANDIBULAR BLOCKS

### TYPES OF MANDIBULAR BLOCKS:

#### 2. GOW-GATES MANDIBULAR NERVE BLOCK:

- Purpose: Blocks the entire mandibular nerve trunk before it branches.
- Target area: Neck of the condyle near the mandibular notch.
- Landmarks: Intertragic notch, corner of the mouth, mesiolingual cusp of maxillary second molar.
- Technique:
  - The patient opens the mouth widely.
  - Needle is inserted at the height of the mesiolingual cusp of the maxillary second molar.
  - Penetration depth: ~25 mm until bone is contacted.
  - Entire cartridge is injected slowly.
- Advantages:
  - Higher success rate than IAN.
  - Fewer complications like trismus or hematoma.
  - Useful when conventional IAN block fails.
- Disadvantages: Onset is slower (5–10 minutes), technique requires precise anatomical knowledge.



#### DISCLAIMER

THIS IS COPYRIGHTED CONTENT. Unauthorized use, including screenshots, copying, misuse, reuse, or resale of any content from this app, is strictly prohibited. Our app monitors and records all screenshots and recordings. Violators will face strict legal action.

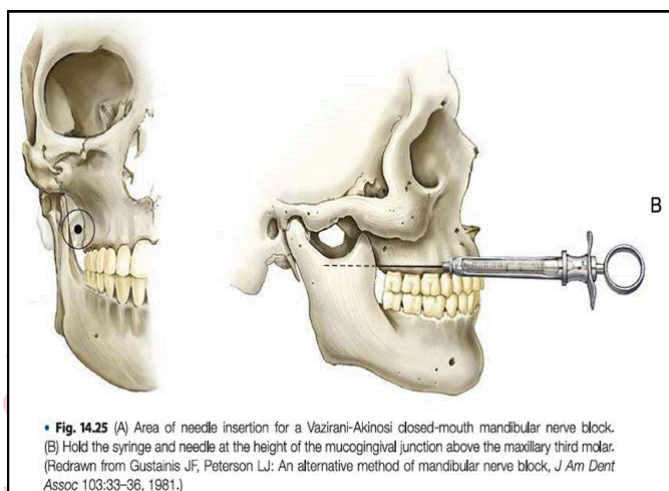
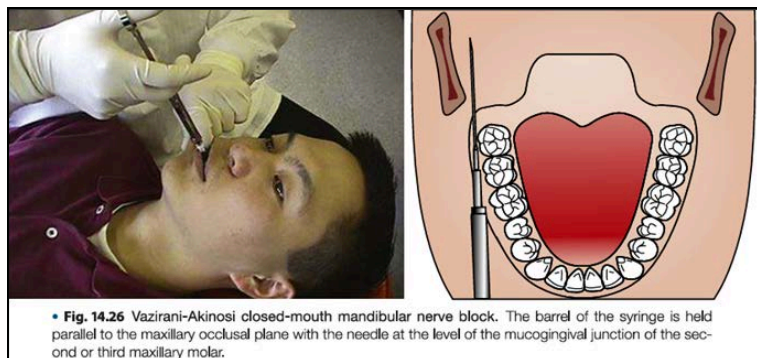
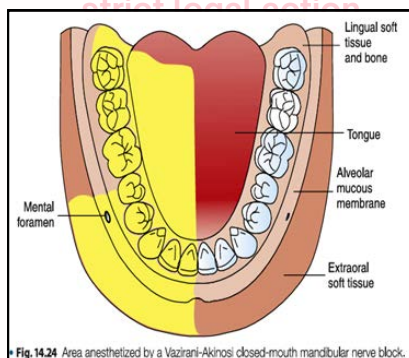
# LA TECHNIQUES AND COMPLICATIONS

## MANDIBULAR BLOCKS

### TYPES OF MANDIBULAR BLOCKS:

#### 3. VAZIRANI-AKINOSI CLOSED-MOUTH BLOCK:

- **Purpose:** Ideal for patients with trismus (inability to open the mouth).
- **Target area:** Between the medial surface of the ramus and the maxillary tuberosity.
- **Technique:**
- Mouth is closed.
- Needle is inserted at the mucogingival junction adjacent to the maxillary second or third molar.
- No bone contact; the depth is ~25 mm.
- The solution is deposited into the pterygomandibular space.
- **Advantages:**
- Good alternative for patients with limited mouth opening.
- Effective for multiple mandibular nerves.
- **Disadvantages:** No bone contact makes the technique more “blind” and possibly difficult for beginners.



#### DISCLAIMER

THIS IS COPYRIGHTED CONTENT. Unauthorized use, including screenshots, copying, misuse, reuse, or resale of any content from this app, is strictly prohibited. Our app monitors and records all screenshots and recordings. Violators will face strict legal action.

## LA TECHNIQUES AND COMPLICATIONS

### MANDIBULAR BLOCKS

#### TYPES OF MANDIBULAR BLOCKS:

#### 4. LONG BUCCAL NERVE BLOCK:

- Purpose: Anesthetizes the buccal soft tissues adjacent to mandibular molars.
- Target area: Buccal nerve anterior to the mandibular ramus.
- Technique:
- Needle inserted into mucosa distal and buccal to the last molar.
- Very shallow penetration (~1–2 mm).
- 0.3 mL of anesthetic is injected.
- Often given as a supplement to IAN or Gow-Gates block for soft tissue procedures.

#### 5. Mental/Incisive Nerve Block:

- Purpose: For soft tissue anesthesia anterior to the mental foramen (mental block) or anterior teeth anesthesia (incisive block).
- Technique:
- Locate the mental foramen (usually between premolars).
- Needle is inserted into the mucobuccal fold, directed toward the foramen.
- Incisive block requires digital pressure after injection to force anesthetic into the mental canal.
- Clinical Considerations:
- Anesthetic Volume and Onset:
- Generally, 1.5–1.8 mL per injection is standard.
- Onset varies by technique: standard IAN (3–5 min), Gow-Gates (5–10 min), Akinosi (3–5 min).
- Failure Rates:
- Standard IAN block has the highest failure rate due to anatomical variability and technique sensitivity.
- Accessory innervation (e.g., from the mylohyoid nerve) may cause incomplete anesthesia.
- Complications:
- Trismus: Resulting from needle trauma or hematoma in the pterygoid region.
- Hematoma: Uncommon but more likely in vascular areas.
- Transient Facial Paralysis: Occurs if anesthetic is injected into the parotid gland affecting the facial nerve.
- Needle Breakage: Rare with modern techniques and materials.

#### DISCLAIMER

THIS IS COPYRIGHTED CONTENT. Unauthorized use, including screenshots, copying, misuse, reuse, or resale of any content from this app, is strictly prohibited. Our app monitors and records all screenshots and recordings. Violators will face strict legal action.



## LA TECHNIQUES AND COMPLICATIONS

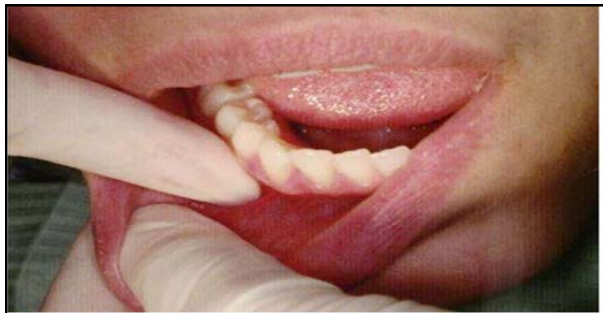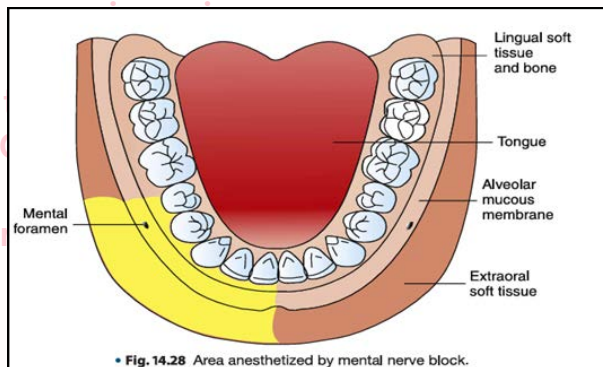
### MANDIBULAR BLOCKS

#### TYPES OF MANDIBULAR BLOCKS:

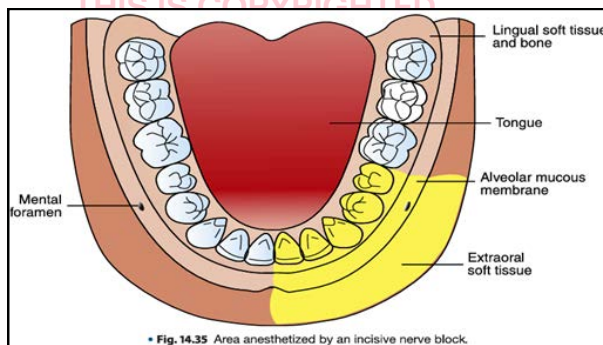
##### 5. Mental/Incisive Nerve Block:

##### Tips for Success:

- Always aspirate to prevent intravascular injection.
- Use anatomical landmarks carefully and consistently.
- Ensure the patient remains open-mouthed during injection for techniques like Gow-Gates.
- Apply proper needle depth and angulation.
- Be patient with onset, especially for deeper techniques



• Fig. 14.30 Locate the mental foramen by moving the fleshy pad of your finger anteriorly until the bone beneath becomes irregular and somewhat concave.



recordings. Violators will face strict legal action.

##### DISCLAIMER

THIS IS COPYRIGHTED CONTENT. Unauthorized use, including screenshots, copying, misuse, reuse, or resale of any content from this app, is strictly prohibited. Our app monitors and records all screenshots and recordings. Violators will face strict legal action.

DISCLAIMER  
THIS IS COPYRIGHTED CONTENT. Unauthorized use, including screenshots, copying, misuse, reuse, or resale of any content from this app, is strictly prohibited. Our app monitors and records all screenshots and recordings. Violators will face strict legal action.

THIS IS COPYRIGHTED CONTENT. Unauthorized use, including screenshots, copying, misuse, reuse, or resale of any content from this app, is strictly prohibited. Our app monitors and records all screenshots and recordings. Violators will face strict legal action.

## LA TECHNIQUES AND COMPLICATIONS

### ALTERNATIVE AND SUPPLEMENTAL TECHNIQUES:

- Intraligamentary injection: When block fails or for single tooth anesthesia.
- Intraosseous injection: Direct delivery into cancellous bone near tooth apex.
- PDL and intrapulpal injections: Used for supplemental pain control.

### Conclusion:

Mandibular nerve blocks are foundational in dental anesthesia, with each method offering distinct benefits and challenges. The standard IAN block remains most common but has a notable failure rate. Techniques like the Gow-Gates and Akinosi blocks are highly effective alternatives, especially when standard approaches fail or aren't feasible. Successful administration depends on a solid understanding of mandibular anatomy, careful technique, and adaptability to individual patient variations.

THIS IS COPYRIGHTED CONTENT. Unauthorized use, including screenshots, copying, misuse, reuse, or resale of any content from this app, is strictly prohibited. Our app monitors and records all screenshots and recordings. Violators will face strict legal action.

THIS IS COPYRIGHTED CONTENT. Unauthorized use, including screenshots, copying, misuse, reuse, or resale of any content from this app, is strictly prohibited. Our app monitors and records all screenshots and recordings. Violators will face strict legal action.

### DISCLAIMER

THIS IS COPYRIGHTED CONTENT. Unauthorized use, including screenshots, copying, misuse, reuse, or resale of any content from this app, is strictly prohibited. Our app monitors and records all screenshots and recordings. Violators will face strict legal action.

THIS IS COPYRIGHTED CONTENT. Unauthorized use, including screenshots, copying, misuse, reuse, or resale of any content from this app, is strictly prohibited. Our app monitors and records all screenshots and recordings. Violators will face strict legal action.

DISCLAIMER  
THIS IS COPYRIGHTED CONTENT. Unauthorized use, including screenshots, copying, misuse, reuse, or resale of any content from this app, is strictly prohibited. Our app monitors and records all screenshots and recordings. Violators will face strict legal action.

## LA TECHNIQUES AND COMPLICATIONS

### Complications and adverse effects of Local Anesthesia:

- The adverse effects of LA includes
  - a) local complications and
  - b) systemic toxicity
- The incidence of adverse effect is low and differs in different local anesthetic.
- Resuscitation drugs and equipment including oxygen, should be available for immediate management of systemic toxicity.
- If adverse effect occur or are suspected the administration of LA should be stopped and appropriate management should be provided.

### A) Problems in Anesthetic Technique causes:

Problems with the injection technique or injection into the incorrect site (due to interindividual anatomical variation) can result in:

- complete or partial failure of local anaesthetic effect—if this occurs, reassess the patient's anatomy and review the injection technique. A repeat injection may be tried, provided the maximum dose (see Table 20; p.208) is not exceeded
- trauma to the nerves and surrounding tissues—for further information on local complications, see below
- profound systemic effects (see p.204) if injected into a blood vessel (particularly if combined with a vasoconstrictor)—to mitigate the risk of intravascular injection, aspirate to exclude the presence of blood, then inject slowly and monitor the patient's response.

### B) Local Complications:

- It can be subdivided into:
  1. Local neurological complications:
    - It includes paresthesia, dysesthesia and temporary nerve paralysis and prolonged anesthesia.
    - Most cases of prolonged anesthesia resolve spontaneously.
    - Permanent anesthesia is rare.
    - Nerve injuries are rare and can be caused by:
      - a) direct nerve trauma
      - b) indirect nerve trauma (i.e., from bleeding within the nerve sheath)
      - c) Localized neurotoxicity
  2. Trauma to tissues:
    - Hematoma can occur during injection of local anesthetic.
    - Accidental intramuscular injection can cause trismus which can be caused either by direct effect of drug or bleeding within the muscle.
    - If trismus occurs, specialist advice or referral to an oral medicine or oral surgery specialist is required, because early management can improve outcomes.

#### DISCLAIMER

THIS IS COPYRIGHTED CONTENT. Unauthorized use, including screenshots, copying, misuse, reuse, or resale of any content from this app, is strictly prohibited. Our app monitors and records all screenshots and recordings. Violators will face strict legal action.

DISCLAIMER  
THIS IS COPYRIGHTED CONTENT. Unauthorized use, including screenshots, copying, misuse, reuse, or resale of any content from this app, is strictly prohibited. Our app monitors and records all screenshots and recordings. Violators will face strict legal action.



# LA TECHNIQUES AND COMPLICATIONS

## Complications and adverse effects of Local Anesthesia:

### B) Local Complications:

2. • Rarely, local complications can arise from equipment failure like cartridge explosion.

### c) Systemic Toxicity:

- It can occur after
  - a. Inadvertent intravascular injection of LA
  - b. Excessive dose administration
  - c. Impaired drug clearance
  - d. Rapid systemic absorption (rare)

Adverse systemic effects are usually seen in a continuum as plasma concentration increases, so use the lowest effective dose and do not exceed the maximum recommended dose (for further discussion of doses of local anaesthetics, see p.206).

Systemic toxicity of local anaesthetics is more likely at higher plasma concentrations, so do not exceed the maximum recommended dose.

- The clinical presentation of systemic toxicity is variable and includes:
  - a. Neurological effects
  - b. Psychiatric effects
  - c. Cardiovascular effects
  - d. Respiratory effects
  - e. Allergic reactions
  - f. Rarely, methemoglobinemia
- Early indicators of systemic toxicity are Minor CNS effects like restlessness, anxiety, dizziness, blurred visions, tremors, CNS depressions and drowsiness.
- In longer acting anesthetics particularly bupivacaine CVS toxicity may occur before CNS effects.
- Methemoglobinemia is mainly associated with (BP)
  1. Prilocaine (above 600mg)
  2. Benzocaine
- Occasionally also reported with
  1. Lidocaine
  2. Articaine
  3. Tetracaine

#### DISCLAIMER

THIS IS COPYRIGHTED CONTENT. Unauthorized use, including screenshots, copying, misuse, reuse, or resale of any content from this app, is strictly prohibited. Our app monitors and records all screenshots and recordings. Violators will face strict legal action.

#### DISCLAIMER

THIS IS COPYRIGHTED CONTENT. Unauthorized use, including screenshots, copying, misuse, reuse, or resale of any content from this app, is strictly prohibited. Our app monitors and records all screenshots and recordings. Violators will face strict legal action.

## LA TECHNIQUES AND COMPLICATIONS

### Methaemoglobinaemia

Methaemoglobinaemia occurs when haemoglobin oxidises to methaemoglobin, resulting in a reduced oxygen-carrying capacity of blood cells, functional anaemia and impaired delivery of oxygen to the tissues. Methaemoglobinaemia can occur after exposure to oxidants, and is a rare adverse effect of local anaesthetics. Onset can occur within minutes or be delayed. Slate-grey skin discolouration and cyanosis are the most distinct features; other signs and symptoms include headache, light-headedness, shortness of breath, fatigue and tachycardia. Blood may appear to be dark red or brown in colour, and can remain so even after administering oxygen.

Methaemoglobinaemia can be life threatening and requires emergency referral to hospital. For management of patients with methaemoglobinaemia, see Box 36 (below).

#### Box 36. Management of methaemoglobinaemia

If methaemoglobinaemia occurs:

- Stop dental treatment.
- Call 000.
- Start supplemental oxygen and airway support if needed.
- Monitor blood pressure, heart rate and pulse oximetry until assistance arrives.
- Start basic life support if required (for 'Basic life support flow chart', see Figure 8; p.235).

If systemic adverse effects of local anaesthetics occur, stop administration of the local anaesthetic and provide appropriate management.

THIS IS COPYRIGHTED CONTENT. Unauthorized use, including screenshots, copying, misuse, reuse, or resale of any content from this app, is strictly prohibited. Our app monitors and records all screenshots and recordings. Violators will face strict legal action.

#### DISCLAIMER

THIS IS COPYRIGHTED CONTENT. Unauthorized use, including screenshots, copying, misuse, reuse, or resale of any content from this app, is strictly prohibited. Our app monitors and records all screenshots and recordings. Violators will face strict legal action.

DISCLAIMER  
THIS IS COPYRIGHTED CONTENT. Unauthorized use, including screenshots, copying, misuse, reuse, or resale of any content from this app, is strictly prohibited. Our app monitors and records all screenshots and recordings. Violators will face strict legal action.

COPYRIGHTED  
Unauthorized use, including screenshots, copying, misuse, reuse, or resale of any content from this app, is strictly prohibited. Our app monitors and records all screenshots and recordings. Violators will face strict legal action.

THIS IS COPYRIGHTED CONTENT. Unauthorized use, including screenshots, copying, misuse, reuse, or resale of any content from this app, is strictly prohibited. Our app monitors and records all screenshots and recordings. Violators will face strict legal action.

THIS IS COPYRIGHTED CONTENT. Unauthorized use, including screenshots, copying, misuse, reuse, or resale of any content from this app, is strictly prohibited. Our app monitors and records all screenshots and recordings. Violators will face strict legal action.

DISCLAIMER

## PYOGENIC GRANULOMA

Source- Odell case 10, Articles on pyogenic granuloma Pyogenic Granuloma - Hyperplastic Lesion of the Gingiva: Case Reports by Pushpendra Kumar Verma, Pyogenic granuloma Stat pearls (internet),

- Pyogenic granuloma is a reactive hyperplasia of connective tissue in response to local irritants.
- Pyogenic granuloma, refers to a common, acquired, benign vascular tumor that arises in tissues such as the skin and mucous membranes. Pyogenic granulomas tend to ooze, and they break and bleed easily.
- The term “pyogenic granuloma” is a **misnomer** because the lesion does not contain pus and is not strictly speaking a granuloma.
- Pyogenic granuloma is a hyperactive benign inflammatory lesion that **occurs mostly** on the mucosa of **females with high levels of steroid hormones** (Pregnancy Tumor/Epulis: A variant of pyogenic granuloma arising in pregnancy). It is generally believed that female sex hormones play important roles in its pathogenesis.
- Pyogenic granuloma is a localized proliferation of granulation tissue or very vascular fibrous tissue.
- The scientifically accurate term for this entity is **lobular capillary hemangioma**.

### Etiology and predisposing factors:

- Approximately one-third of the lesions occur due to **trauma and poor oral hygiene** may also be one of the precipitating factors.
- It arises in association with **local irritants** such as poor oral hygiene, calculus or the margin of a restoration.
- It usually arises in response to various stimuli such as low-grade local irritation, traumatic injury, hormonal factors or certain kinds of drugs.

### Presenting signs and symptoms:

- It often presents as a painless, mostly pedunculated, or sometimes sessile mass of gingiva.
- **The lesion grossly appears as a solitary, red, pedunculated papule that is very friable.**
- It is mostly soft and vascular, bleeds readily, and has an ulcerated surface.
- They may be pink, red, reddish-brown or purple.
- It shows rapid exophytic growth, with a surface that often undergoes ulceration and this is often seen on cutaneous or mucosal surfaces.
- When it occurs in the intraoral mucosa during pregnancy, notably on the gingiva, it is referred to as **granuloma gravidarum, granuloma of pregnancy, or epulis gravidarum**, and usually occurs in the second or third trimester.
- For mucosal Pyogenic Granulomas, common locations include lips and gingival mucosa.
- It has been reported many times that pyogenic granulomas may cause significant bone loss.

### DISCLAIMER

THIS IS COPYRIGHTED CONTENT. Unauthorized use, including screenshots, copying, misuse, reuse, or resale of any content from this app, is strictly prohibited. Our app monitors and records all screenshots and recordings. Violators will face strict legal action.

### DISCLAIMER

THIS IS COPYRIGHTED CONTENT. Unauthorized use, including screenshots, copying, misuse, reuse, or resale of any content from this app, is strictly prohibited. Our app monitors and records all screenshots and recordings. Violators will face strict legal action.



## PYOGENIC GRANULOMA

### FIBROUS EPULIS (gingival fibroepithelial polyp/nodule)

- It is a nodule of more fibrous hyperplastic tissue.
- It is not usually ulcerated, is firmer on palpation and does not bleed so readily.
- Some fibrous epulis develop from pyogenic granuloma through maturation of fibrous tissue.
- They are usually associated with a local irritant in the same manner as pyogenic granulomas.

#### Diagnosis:

- Lobular capillary hemangioma/ Pyogenic granuloma is usually a clinical diagnosis based on history and classical clinical findings.
- The history should include inquiries into previous trauma, association with pregnancy, and a thorough review of medications.
- A histologic examination is warranted if a diagnosis cannot be achieved on clinical grounds
- It is strongly recommended that the tissue is sent for histopathologic confirmation to rule out any other sinister lesions.
- The definitive diagnosis will require a biopsy, and excision is indicated as this swelling will not regress spontaneously, after initial management that includes oral prophylaxis and Oral hygiene instructions.

#### Histopathology of the lesion:

- Histologically, it consists of lobular aggregates of capillary-sized vessels, with each lobule containing a central feeder vessel.
- These develop within highly vascular granulation tissue, with the lobules or tufts of thin-walled capillaries embedded within a loose fibrous stroma, with scattered fibroblasts and inflammatory infiltrate.
- Within the stroma, a scarce, mixed inflammatory infiltrate is noted, consisting of lymphocytes, neutrophils, plasma cells, or mast cells, resembling normal granulation tissue.

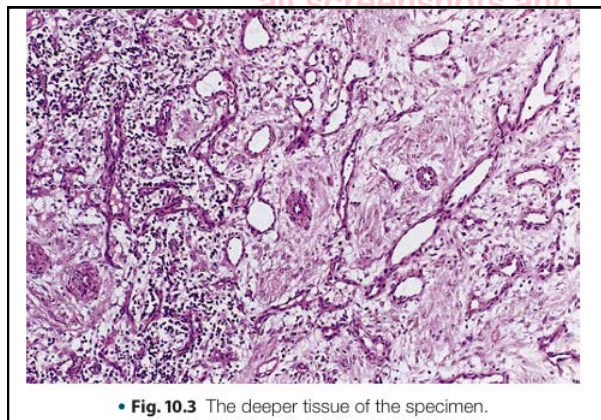
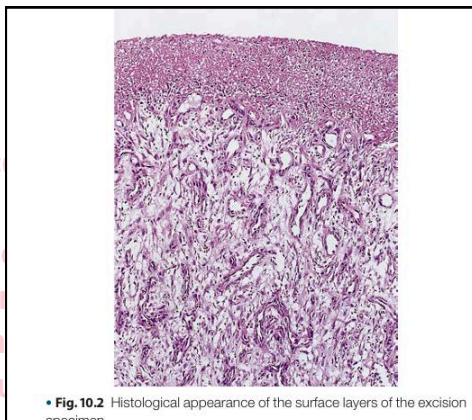


Image: Microscopic appearance of pyogenic granuloma (Odell case 10)

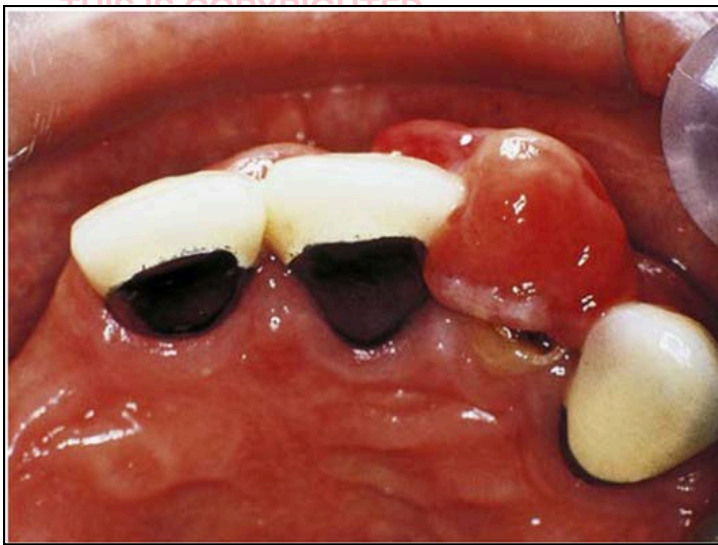
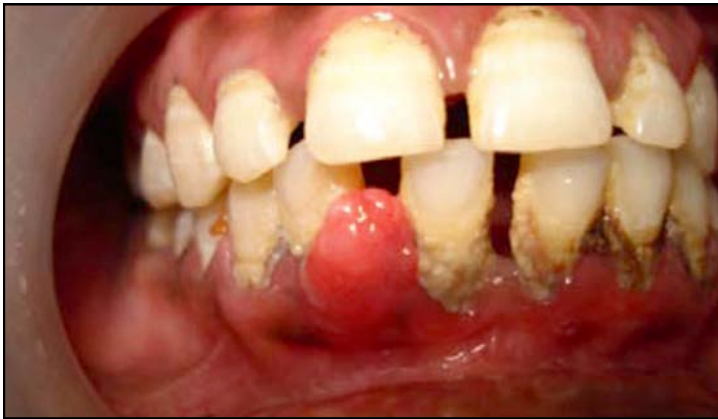#### DISCLAIMER

THIS IS COPYRIGHTED CONTENT. Unauthorized use, including screenshots, copying, misuse, reuse, or resale of any content from this app, is strictly prohibited. Our app monitors and records all screenshots and recordings. Violators will face strict legal action.

#### DISCLAIMER

THIS IS COPYRIGHTED CONTENT. Unauthorized use, including screenshots, copying, misuse, reuse, or resale of any content from this app, is strictly prohibited. Our app monitors and records all screenshots and recordings. Violators will face strict legal action.

## PYOGENIC GRANULOMA



Clinical appearance of the lesion: (Source -Internet)

### Management:

- **Elimination of the causative factors** may induce considerable resolution.
- The degree of resolution varies; softer more vascular lesions shrink most and firmer more fibrous lesions hardly shrinks at all.
- **Non-surgical** treatment includes: Removal of calculus and improved oral hygiene may cause partial or very occasionally complete resolution.
- Partial resolution reduces the size of the lesion, which is then easier to excise and also bleeds much less.
- In pregnancy epulis Oral prophylaxis and OHI is done primarily, both because of the wish to avoid the procedure during pregnancy and because excision during pregnancy carries a risk of recurrence.
- The most definitive management is **Complete Surgical Excision** if the lesion.
- Generally, the only way to cure pyogenic granuloma is to:
  - a) Remove the lesion.
  - b) Eliminate any suspected triggers, such as medications, piercings or dental problems causing irritation in your mouth.

### DISCLAIMER

THIS IS COPYRIGHTED CONTENT. Unauthorized use, including screenshots, copying, misuse, reuse, or resale of any content from this app, is strictly prohibited. Our app monitors and records all screenshots and recordings. Violators will face strict legal action.

THIS IS COPYRIGHTED CONTENT. Unauthorized use, including screenshots, copying, misuse, reuse, or resale of any content from this app, is strictly prohibited. Our app monitors and records all screenshots and recordings. Violators will face strict legal action.

DISCLAIMER  
THIS IS COPYRIGHTED CONTENT. Unauthorized use, including screenshots, copying, misuse, reuse, or resale of any content from this app, is strictly prohibited. Our app monitors and records all screenshots and recordings. Violators will face strict legal action.



## PYOGENIC GRANULOMA

### Management:

- Granulomas in pregnancy can typically disappear after delivery.
- No matter the treatment, the patient should be counseled about the risk of recurrence.
- These lesions have no malignant potential. However, since they do not regress spontaneously and may bleed, ulcerate, or be cosmetically disfiguring, they may necessitate treatment on these grounds.
- Partial resection by shave excision or curettage may lead to recurrence in the future, hence complete primary excision is preferred. **For recurrence, a complete surgical excision is warranted.**

### Advice to patients:

- Patients typically need reassurance for this condition since they may be worried about more sinister conditions.
- They should be discouraged from scratching or picking at the lesion and must take some precautions to avoid trauma or secondary infection.
- They should be advised about the risk of recurrence with partial excisions and the risk of scarring with a total surgical excision.
- The decision of which modality to use for the lesion must be arrived at jointly by the patient and their physician.

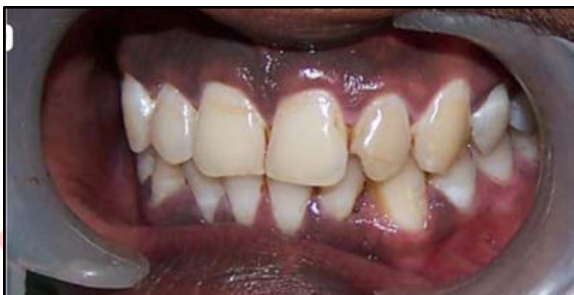
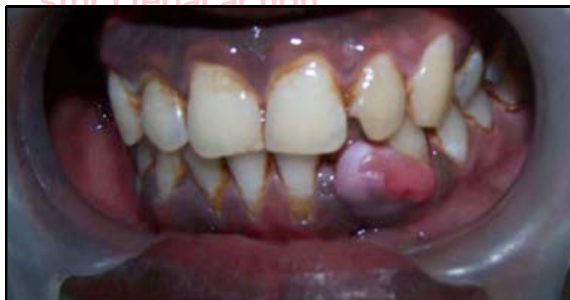
Image: Pyogenic granuloma pre-operative and after complete excision (Internet)

### DISCLAIMER

THIS IS COPYRIGHTED CONTENT. Unauthorized use, including screenshots, copying, misuse, reuse, or resale of any content from this app, is strictly prohibited. Our app monitors and records all screenshots and recordings. Violators will face strict legal action.

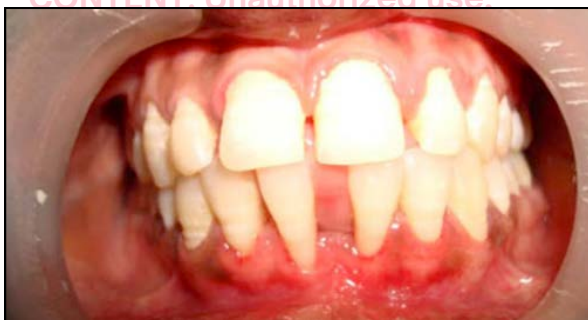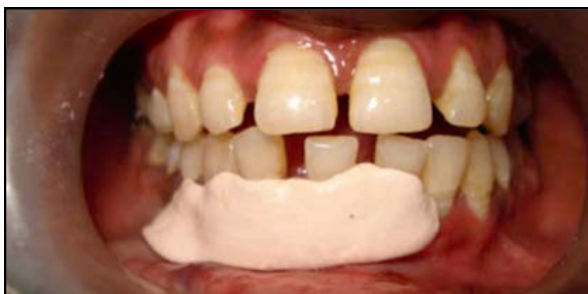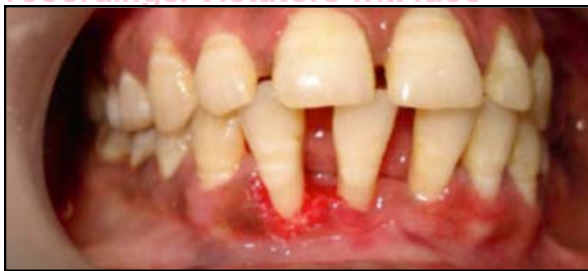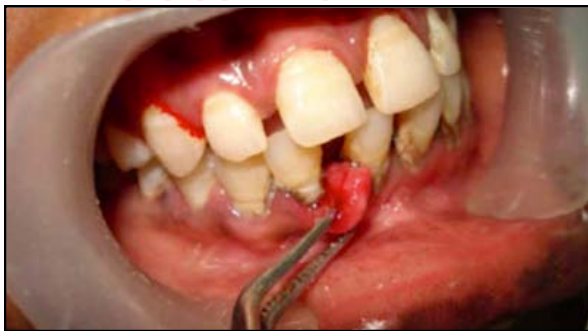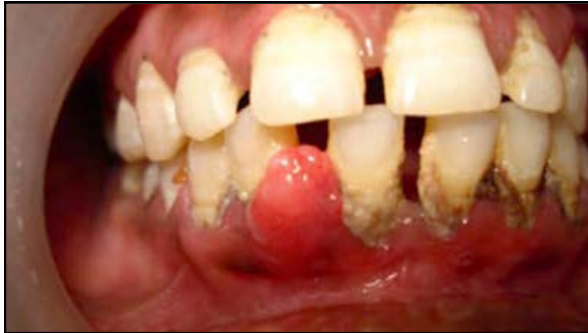### DISCLAIMER

THIS IS COPYRIGHTED CONTENT. Unauthorized use, including screenshots, copying, misuse, reuse, or resale of any content from this app, is strictly prohibited. Our app monitors and records all screenshots and recordings. Violators will face strict legal action.



## PYOGENIC GRANULOMA

Example of management of a case with pyogenic granuloma, (Preoperative – Post operative)



strict legal action.

**DISCLAIMER**

THIS IS COPYRIGHTED CONTENT. Unauthorized use, including screenshots, copying, misuse, reuse, or resale of any content from this app, is strictly prohibited. Our app monitors and records all screenshots and recordings. Violators will face strict legal action.

THIS IS COPYRIGHTED CONTENT. Unauthorized use, including screenshots, copying, misuse, reuse, or resale of any content from this app, is strictly prohibited. Our app monitors and records all screenshots and recordings. Violators will face strict legal action.

THIS IS COPYRIGHTED CONTENT. Unauthorized use, including screenshots, copying, misuse, reuse, or resale of any content from this app, is strictly prohibited. Our app monitors and records all screenshots and recordings. Violators will face strict legal action.

**DISCLAIMER**  
THIS IS COPYRIGHTED CONTENT. Unauthorized use, including screenshots, copying, misuse, reuse, or resale of any content from this app, is strictly prohibited. Our app monitors and records all screenshots and recordings. Violators will face strict legal action.

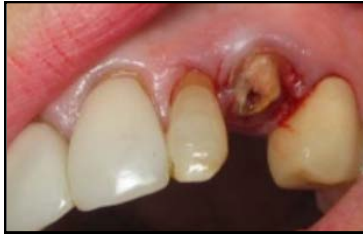# RADIOPACITIES OF JAW/ RETAINED ROOTS

## Retained Roots

(Source- Stat pearls Oral Surgery, Extraction of Roots Parker N. Benton; Paul Chang)

\*Link to article: <https://www.ncbi.nlm.nih.gov/books/NBK589696/>

- A residual root is a tooth root which was left over in the jaw after a past extraction.



- These sometimes can give problems such as pain and infection. Usually these can be removed surgically using local anesthetic.
- The retained tooth root is a common consequence of tooth fracture, which may occur for various reasons.
- Tooth roots are a significant contributor to the ease or complexity of dental extraction surgery and often require unique management approaches not typically employed in routine exodontia.
- Root morphology tends to follow a pattern in most individuals.
- In the **maxilla**, **central and lateral incisors** traditionally have single, straight, and typically conical roots.
- **Maxillary canines** are also single-rooted and are the longest of all tooth roots.
- The **maxillary first premolar** often has a long root trunk with bifurcated buccal and palatal roots, but single root variants exist. Maxillary premolar roots are typically thin.
- Unlike the maxillary first premolar, the **maxillary second premolar** is usually single-rooted and rarely presents with two roots or a bifurcated root.
- **Maxillary first molars** typically have two buccal roots and one larger palatal root. Roots may splay and have variable curvature.
- The **second molar** also traditionally has three roots that are usually less splayed than the first molar.
- The roots of the **maxillary third molar** tend to be fused and shorter than the maxillary first and second molars.
- In the **mandible**, **central and lateral incisors** have single roots, with central incisors often lacking apical curvature.
- **Mandibular canines** usually present with single roots, but one unique difference between maxillary and mandibular canines is that mandibular canines may have bifurcated roots similar to those seen in maxillary first premolars.
- The **mandibular first and second premolars** typically present with single roots but may have bifurcated roots in rare situations.
- The **mandibular first and second molars** usually have two distally tilted roots: a mesial and a distal root. The mandibular second molar's roots are usually shorter with less splay than the first molar roots.
- The **mandibular third molars** typically have two shorter, often parallel, mesial, and distal roots. But have significant variation.

## DISCLAIMER

THIS IS COPYRIGHTED CONTENT. Unauthorized use, including screenshots, copying, misuse, reuse, or resale of any content from this app, is strictly prohibited. Our app monitors and records all screenshots and recordings. Violators will face strict legal action.

DISCLAIMER

THIS IS COPYRIGHTED CONTENT. Unauthorized use, including screenshots, copying, misuse, reuse, or resale of any content from this app, is strictly prohibited. Our app monitors and records all screenshots and recordings. Violators will face strict legal action.

## RADIOPACITIES OF JAW/ RETAINED ROOTS

### Indications of removal of retained roots:

- Retained dental roots may present with one or many indications for removal:
  - i. The presence of acute or chronic infection
  - ii. Partial or complete fracture of the crown
  - iii. Future dental implant placement
  - iv. Pain
  - v. Vertical root fractures
  - vi. Periodontal disease
  - vii. Caries
  - viii. Presence of pathology
  - ix. Future prosthetic restoration of the site with a fixed or removable prosthesis
  - x. Preservation of vital adjacent teeth and structures
  - xi. Patient esthetic concerns
- Sometimes retained roots are removed prophylactically, even in the asymptomatic patient.

### Technique of removal:

- Once consent is obtained and all team members agree with the planned procedure, the patient is locally anesthetized, and the anesthetic is allowed time to take effect before initiating surgery.
- There are a variety of methods:
  1. **Closed surgical technique:**
    - This technique involves elevating, luxating, and delivering the root segment from the coronal aspect of the socket without creating a mucoperiosteal flap.
    - Once appropriate surgical visualization of the root segment is achieved, dental elevators can be used.
    - The instruments can be used using either of three fundamental physical concepts: 1. Wheel, 2. A lever 3. A wedge.
    - When using an elevator as a wheel like while using Cryer's elevator, a rotational arc between the elevator tip and the body of the root develops to lift the root out coronally.
    - When using an elevator as a class 1 lever, a fulcrum point is created between the alveolar crest and the root. This concept requires a reliable purchase point so that force can be applied without instrument slippage or misdirection.
    - A hole can be drilled in the root to allow for a crane pick or similar instrument to lever the root coronally.
    - Another modern advancement in atraumatic tooth extraction is Piezosurgery.

#### DISCLAIMER

THIS IS COPYRIGHTED CONTENT. Unauthorized use, including screenshots, copying, misuse, reuse, or resale of any content from this app, is strictly prohibited. Our app monitors and records all screenshots and recordings. Violators will face strict legal action.

#### DISCLAIMER

THIS IS COPYRIGHTED CONTENT. Unauthorized use, including screenshots, copying, misuse, reuse, or resale of any content from this app, is strictly prohibited. Our app monitors and records all screenshots and recordings. Violators will face strict legal action.



## RADIOPACITIES OF JAW/ RETAINED ROOTS

### Technique of removal:

#### 2. Open Surgical Technique:

- Removal of root segments using an open surgical technique involves the reflection of a tissue flap to improve visualization and gain surgical access to the root.
- Removal of cortical bone is often necessary following mucosal flap reflection.
- Removing roots usually requires a full-thickness flap, meaning the mucosal flap of soft tissue carries an adherent periosteal layer.

#### 3. Endodontic File Technique:

- Using endodontic files to retrieve retained root segments involves the insertion of an endodontic file through the visible root canal orifice from the coronal aspect and advancing it apically until friction develops within the canal.
- The more contact surface area the file has within the canal, the more generated force when pulling the root segment coronally.
- The type and size of endodontic file best suited for extraction in root tips have yet to be well-studied, but it has been shown that a #25 Hedstrom file generates a tremendous pullout force in all roots, regardless of the length of the root.

## RADIOPACITIES OF JAW/ RETAINED ROOTS

### Radiopacities of Jaw

(Source: Practical Approach to Radiopaque Jaw Lesions Article, White and pharoah radiology)

- A radiopacity is the white area on a conventional radiograph.
- Multiple radiopacities, particularly if they are distributed throughout the jaws, suggest a systemic cause, whereas a single radiopacity suggests a local cause.
- Two most frequent causes of radiopacities in the jaws, includes **dense bone islands (also known as idiopathic osteosclerosis) and sclerosing osteitis**.
- Adenomatoid odontogenic tumor, calcifying epithelial odontogenic tumor, calcifying odontogenic cyst, and dentinogenic ghost cell tumor. All four present radiologically as containing radiopacities.
- The radiologic analysis of these lesions requires a systematic approach and a broad consideration of clinical and imaging characteristics to enable reliable radiologic diagnosis.
- Specifically, the appearance of radiopaque lesions can be described as
  - Densely sclerotic:** All densely sclerotic lesions are benign and have a relatively homogeneous attenuation similar to that of cortical bone or tooth constituents (eg, dentin or cementum), without significant lucent components.
  - Ground glass:** Ground-glass lesions of the jaw have a differential diagnosis of four entities: fibrous dysplasia, cemento-ossifying fibroma (COF), Paget disease of bone (PDB), and renal osteodystrophy. Ground-glass lesions are so named because of their hazy homogeneous intermediate attenuation between lucency and/or absence of bone and dense sclerosis. They are characterized by mineralization of fibrous matrix, which obscures or destroys trabeculae. Fibrous dysplasia is the prototypical ground-glass bone lesion. Fibrous dysplasia is the prototypical ground-glass bone lesion.
  - Mixed lytic-sclerotic:** Mixed lytic-sclerotic lesions are a heterogeneous group of entities including both benign and malignant neoplasms and aggressive processes such as osteomyelitis and osteonecrosis.
- Each category represents a distinct although occasionally overlapping differential diagnosis.

Lesion Type	Densely Sclerotic	Ground-Glass	Mixed Lytic-Sclerotic
Odontogenic	Odontoma Condensing osteitis COD Cementoblastoma	COF	Developing odontoma CEOT
Nonodontogenic	Osteoma Exostoses and tori	Fibrous dysplasia PDB Renal osteodystrophy	Osteosarcoma Metastases Chronic osteomyelitis Osteonecrosis

Note.—CEOT = calcifying epithelial odontogenic tumor, COD = cemento-osseous dysplasia, COF = cemento-ossifying fibroma, PDB = Paget disease of bone.

- Dense radiopacities mainly result from unerupted teeth, aberrant production of odontogenic hard tissues, or local osteosclerosis and cortical thickening.

### DISCLAIMER

THIS IS COPYRIGHTED CONTENT. Unauthorized use, including screenshots, copying, misuse, reuse, or resale of any content from this app, is strictly prohibited. Our app monitors and records all screenshots and recordings. Violators will face strict legal action.

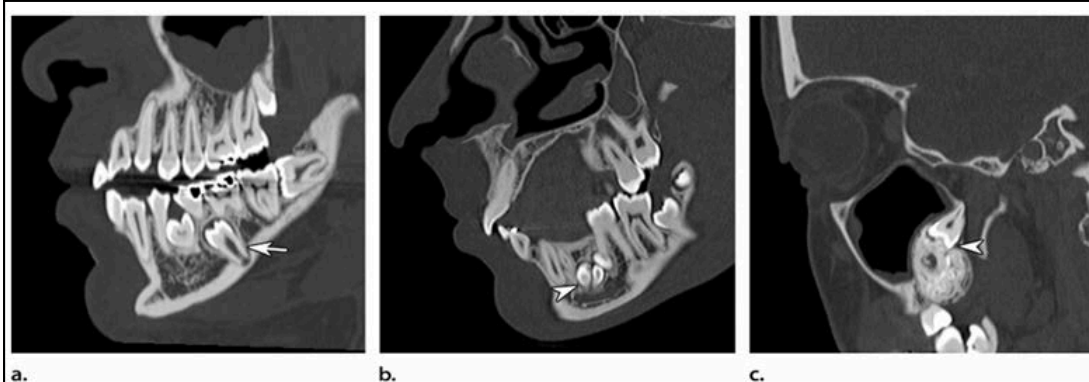
DISCLAIMER  
THIS IS COPYRIGHTED CONTENT. Unauthorized use, including screenshots, copying, misuse, reuse, or resale of any content from this app, is strictly prohibited. Our app monitors and records all screenshots and recordings. Violators will face strict legal action.

# RADIOPACITIES OF JAW/ RETAINED ROOTS

## 1. Odontogenic Lesions

### a) Odontoma and Supernumerary Teeth:

- Odontomas are hamartomas of mixed hard and soft dental tissues.
- These lesions are the most commonly diagnosed odontogenic tumor, with most manifesting before the age of 20 years, without a significant gender predilection.
- Odontomas can be categorized as compound or complex.
- Compound odontomas are well-defined collections of small structures with a toothlike resemblance, termed denticles.
- Complex odontomas exhibit a lower degree of differentiation, reflecting poorly organized enamel, cementum, and dentin.
- **Supernumerary teeth**, which are morphologically normal erupted or unerupted teeth in addition to the full permanent tooth set, share the same pathogenesis as odontomas, namely focal hyperactivity or failed resorption of the dental lamina, a tissue involved in tooth development.
- **Anatomically, compound odontomas** show a predilection for the **anterior maxilla**, typically involving the anterior sextant, while **complex odontomas** are mostly found in the **posterior mandible**.
- The presence of multiple odontomas should raise suspicion for **Gardner syndrome**.



**Figure 3.** Three cases of incidentally identified supernumerary teeth and odontomas at CT. **(a)** Sagittal CT image of supernumerary teeth shows a morphologically normal unerupted tooth (arrow) with a thin well-defined lucent rim and thin bony capsule. Tooth count confirmed that this is a supernumerary tooth. **(b)** Sagittal CT image of a compound odontoma shows multiple abnormal-appearing unerupted teeth (arrowhead) encapsulated by a thin lucent and bony rim. **(c)** Sagittal CT image of a complex odontoma shows an amorphous densely sclerotic pericoronal lesion with a well-defined rim of sclerosis (arrowhead). Mineralized lesion matrix contains components that are isoattenuating relative to the enamel and dentin in the adjacent tooth.

#### DISCLAIMER

THIS IS COPYRIGHTED CONTENT. Unauthorized use, including screenshots, copying, misuse, reuse, or resale of any content from this app, is strictly prohibited. Our app monitors and records all screenshots and recordings. Violators will face strict legal action.

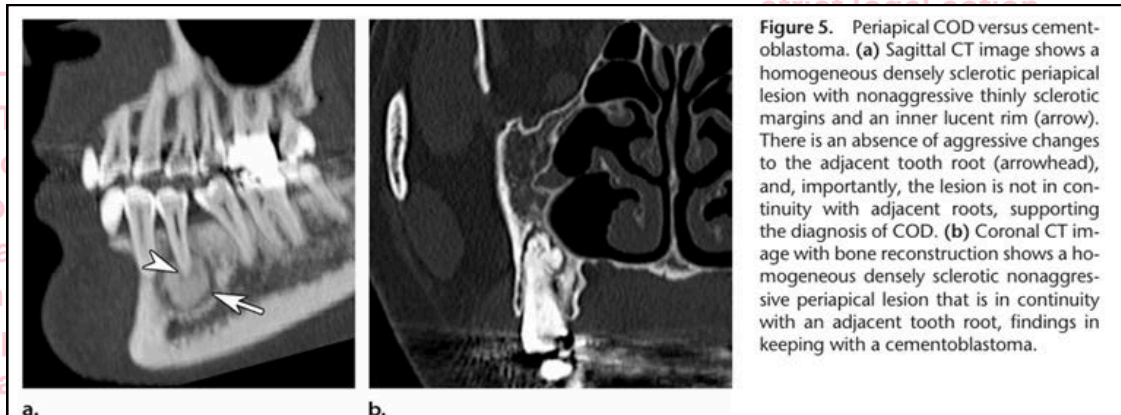


# RADIOPACITIES OF JAW/ RETAINED ROOTS

## 1. Odontogenic Lesions

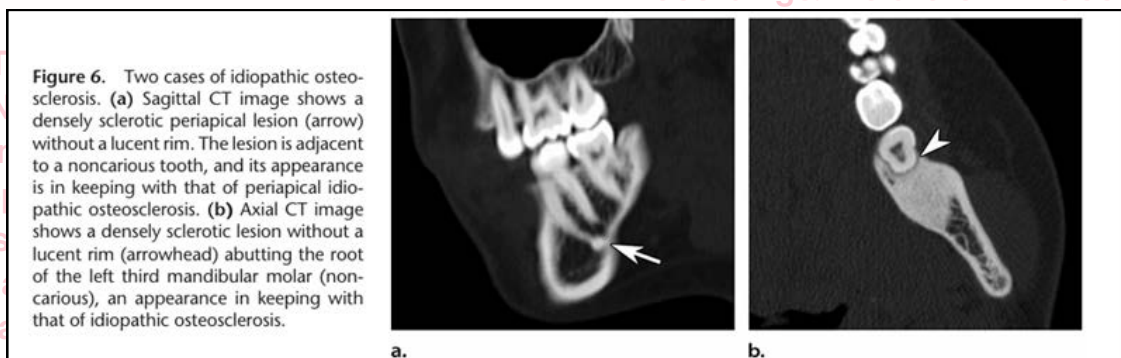
### b) Condensing Osteitis:

- Condensing osteitis (also termed sclerosing osteitis or sclerosing osteomyelitis) refers to local reactive sclerosis resulting from chronic odontogenic inflammation, typically related to periodontal or endodontal disease.
- Patients with condensing osteitis are usually symptomatic. Condensing osteitis manifests as **focal ill-defined sclerosis**.



### c) Idiopathic Osteosclerosis.

- Idiopathic osteosclerosis or dense bone island, refers to a focal increase in bone density of unclear origin but may represent a developmental variant.
- Patients are asymptomatic, with idiopathic osteosclerosis typically identified incidentally at imaging for other reasons.
- While idiopathic osteosclerosis manifests as a similar-appearing sclerotic focus to that of condensing osteitis, idiopathic osteosclerosis can be distinguished by well-defined margins lacking a radiolucent rim.
- Idiopathic osteosclerosis is also less frequently associated with the roots of teeth, and if adjacent to a root, pulp vitality testing should be normal, in contrast to that of condensing osteitis.



#### DISCLAIMER

THIS IS COPYRIGHTED CONTENT. Unauthorized use, including screenshots, copying, misuse, reuse, or resale of any content from this app, is strictly prohibited. Our app monitors and records all screenshots and recordings. Violators will face strict legal action.

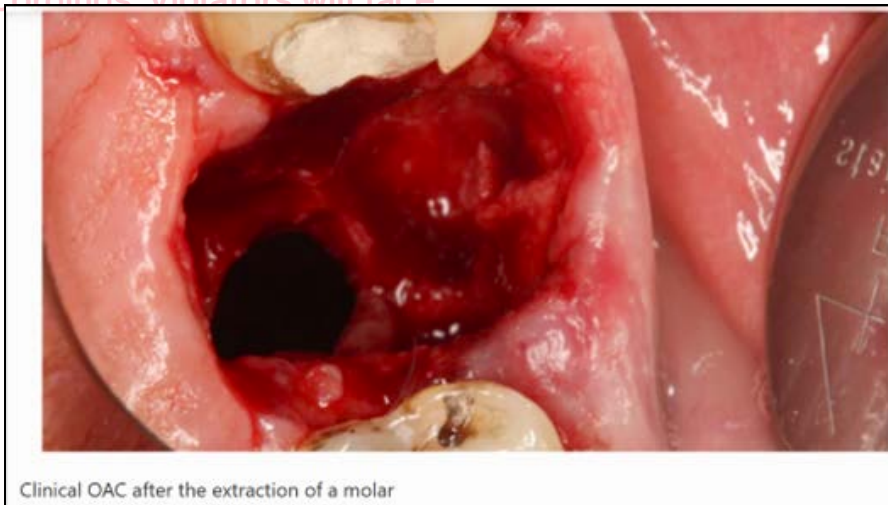## ORO-ANTRAL COMMUNICATION AND FISTULA

(Sources: Odell case 18, Article on Management of Oro-antral Communication and Fistula: Various Surgical Options Pulkit Khandelwal<sup>1\*</sup>, Neha Hajira, Internet)

- Oro-antral communications and fistulas (OACs & OAFs) are complications frequently encountered by oral and maxillofacial surgeons.

### Oroantral communication:

- Oro-antral communication is an unnatural communication between the oral cavity and the maxillary sinus.
- Oroantral communications either close spontaneously or become epithelialized and persist as fistulae.
- In the absence of any infection of maxillary sinus, the defects which are smaller than 2 mm can heal spontaneously following the blood clot formation and secondary healing.
- However, untreated larger defects can lead to development of acute sinus disease like sinusitis (50% of patients within 48 hours, 90% of patients within 2 weeks)
- Closure of this communication is very important to prevent any food or saliva accumulation. It can cause sinus contamination leading infection, impaired healing and chronic sinusitis.



Clinical OAC after the extraction of a molar

Source- Internet

### DISCLAIMER

THIS IS COPYRIGHTED CONTENT. Unauthorized use, including screenshots, copying, misuse, reuse, or resale of any content from this app, is strictly prohibited. Our app monitors and records all screenshots and recordings. Violators will face strict legal action.

### DISCLAIMER

THIS IS COPYRIGHTED CONTENT. Unauthorized use, including screenshots, copying, misuse, reuse, or resale of any content from this app, is strictly prohibited. Our app monitors and records all screenshots and recordings. Violators will face strict legal action.

## ORO-ANTRAL COMMUNICATION AND FISTULA

### Oro antral fistulae:

- An **oroantral fistula** is a persistent epithelialized communication between the maxillary antrum and the mouth, present for more than 48 hours.
- The epithelial lining of the fistula grows from the gingival epithelium, periodontal pocket lining or the antral lining, and it may take up to 7 days for the epithelium to completely line the walls of the communication.
- If the tract is not lined by epithelium, it is known as an oroantral **communication or perforation**.
- It develops when the oro-antral communication fails to close spontaneously, remains patent and gets epithelialized.
- There is migration of oral epithelium into the defect.
- This epithelialization usually occurs when the perforation persists for at least 48-72 hours.
- Within few days, the fistula gets organized and with the epithelialization of the fistulous tract, osteitis of the surrounding bony margins, presence of foreign bodies or development of maxillary sinusitis, spontaneous healing is hampered which may result in chronic fistula formation.
- OAF can be further classified as alveolo-sinusal, palatal-sinusal and vestibulo-sinusal.

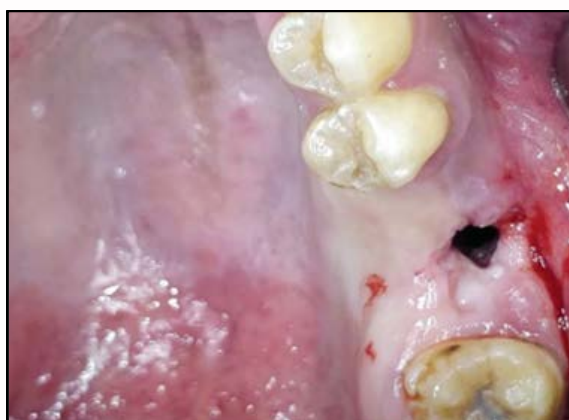

Image: Intraoral view showing a left maxillary OAC of 7 mm diameter. (Source-Internet)

THIS IS COPYRIGHTED CONTENT. Unauthorized use, including screenshots, copying, misuse, reuse, or resale of any content from this app, is strictly prohibited. Our app monitors and records all screenshots and recordings. Violators will face strict legal action.

#### DISCLAIMER

THIS IS COPYRIGHTED CONTENT. Unauthorized use, including screenshots, copying, misuse, reuse, or resale of any content from this app, is strictly prohibited. Our app monitors and records all screenshots and recordings. Violators will face strict legal action.

DISCLAIMER  
THIS IS COPYRIGHTED CONTENT. Unauthorized use, including screenshots, copying, misuse, reuse, or resale of any content from this app, is strictly prohibited. Our app monitors and records all screenshots and recordings. Violators will face strict legal action.



## ORO-ANTRAL COMMUNICATION AND FISTULA

### Causes of OACs AND OFCs

- The vast majority of OAF result from dental extraction. Up to 10% of upper molar extractions may create oroantral communications, but very few, only 0.5%, persist to become fistulae. Other causes include malignant neoplasms arising in the oral cavity or in the antrum.
- OACs and OAFs occur most commonly during extraction of upper molar and premolar teeth (48%). The major reason is the anatomic proximity or projection of the roots within the maxillary sinus.
- Other causes of OAC/OAF include tuberosity fracture, dentoalveolar/periapical infections of molars, implant dislodgement into maxillary sinus, trauma, presence of maxillary cysts or tumors, osteoradionecrosis, flap necrosis, dehiscence following implant failure and sometimes as a complication of the Caldwell-Luc procedure.

### Predisposing factors of Oroantral communication:

- Proximity of roots to maxillary antrum, large sinus
- Difficult extraction, unfavourable root morphology
- Periapical lesions such as apical granulomas or cysts
- Bone loss caused by periodontitis or periodontal-endodontic lesion
- Hypercementosis
- Displaced root fragment
- Local infection or sequestrum
- Predisposition to infection (e.g. diabetes)
- Dry socket or other poor healing
- Advanced age
- Pre-existing diseases in the sinus, although this is probably not a very significant factor.

Image: Odell case 18

THIS IS COPYRIGHTED CONTENT. Unauthorized use, including screenshots, copying, misuse, reuse, or resale of any content from this app, is strictly prohibited. Our app monitors and records all screenshots and recordings. Violators will face strict legal action.

#### DISCLAIMER

THIS IS COPYRIGHTED CONTENT. Unauthorized use, including screenshots, copying, misuse, reuse, or resale of any content from this app, is strictly prohibited. Our app monitors and records all screenshots and recordings. Violators will face strict legal action.

DISCLAIMER  
THIS IS COPYRIGHTED CONTENT. Unauthorized use, including screenshots, copying, misuse, reuse, or resale of any content from this app, is strictly prohibited. Our app monitors and records all screenshots and recordings. Violators will face strict legal action.

## ORO-ANTRAL COMMUNICATION AND FISTULA

### Signs and Symptoms:

- The symptoms depend on the size of the fistula.
- **Initially**, there may be **persistent pain localized to the tooth socket** but **later**, when inflammation has subsided, the fistula **will be painless**.
- If pain is a prominent symptom, some additional element such as infection must be suspected.
- The socket may present as an empty cavity or as a pro lapse of antral lining through the socket into the mouth.
- The most characteristic symptoms are the escape of fluids from the mouth into the nose on eating, or air or fluid into the mouth on blowing the nose.
- Due to passage of saliva, food and bacteria into the antrum **sinusitis occurs** and can be presented as unilateral nasal obstruction, a feeling of fullness, pain over maxilla and tenderness on pressure.

### Investigations:

- Investigations need to be performed to
  - a) confirm the communication with the antrum
  - b) to check for associated complications and
  - c) to exclude the possibility that a malignant neoplasm is the cause of either the antral
  - d) communication itself or the failure of the socket to heal.
- Patient usually complains of nasal regurgitation of liquid, altered nasal resonance, difficulty in sucking through straw, unilateral nasal discharge, bad taste in the mouth and whistling sound while speaking.
- Pain may be present at malar region.
- At later stage, there is formation of antral polyp which is visible through the defect intra-orally.
- However, some patients may be asymptomatic. Clinically, a large fistula is easily seen on inspection.
- However, diagnosis of small defects can be made by the nose blowing test. **The patient is asked to close his nostrils and blow gently down the nose with the mouth open.**
- Presence of OAF appears as a whistling sound as air passes down the fistula into the oral cavity.
- It can also be seen as air bubbles, blood or mucoid secretion around the orifice.
- The escape of air through the nostril can be tested by placing a cotton wisp near the orifice.
- A mouth mirror placed at oro-antral fistula causes fogging of the mirror.
- **Probing** (the introduction of a probe into the antrum through the fistula) **should never be attempted.**
- Panoramic radiograph gives an accurate estimation of the dimension of the bony defect of the fistula and also reveals about the presence and location of dental roots or implants or any foreign body that may have been dislodged into the antrum. Computed tomography can be done to rule out the presence of maxillary sinusitis.

### DISCLAIMER

THIS IS COPYRIGHTED CONTENT. Unauthorized use, including screenshots, copying, misuse, reuse, or resale of any content from this app, is strictly prohibited. Our app monitors and records all screenshots and recordings. Violators will face strict legal action.

DISCLAIMER  
THIS IS COPYRIGHTED CONTENT. Unauthorized use, including screenshots, copying, misuse, reuse, or resale of any content from this app, is strictly prohibited. Our app monitors and records all screenshots and recordings. Violators will face strict legal action.

## ORO-ANTRAL COMMUNICATION AND FISTULA

A summary of investigations and their purpose:

TABLE 18.1 Summary of Investigations	
Aim of Investigation	Methods
To demonstrate communication between antrum and mouth, the definitive test for oroantral fistula if there is no history of fluid or air passing between sinus and mouth.	If the fistula is large it may be possible to see into the antrum or pass a probe or large gutta percha point through into the antrum. If not, the patient can be asked to blow air into the nose with the anterior nares pinched closed and keeping the mouth open. You may see air bubbles, hear a hissing noise or detect air movement with a wisp of cotton wool at the socket opening.
To detect retained root fragments or sequestra in the socket.	Radiographs of the socket, ideally a periapical view, possibly also a panoramic tomograph.
To exclude the possibility of other lesions such as malignant neoplasms.	
To detect root fragments displaced into the antrum and exclude other antral disease.	Radiographs of antrum, usually a panoramic tomograph or standard occipito-mental view is sufficient. However, it is difficult to visualize the whole antrum in any one view without superimposition of other structures. Cone beam computed tomography (CBCT) is the best modality to examine the sinus if a root fragment is suspected but cannot be detected on other views. However, it requires a higher x-ray dose, and a plain film should be taken first.
To eliminate dental causes for any pain.	Vitality tests (thermal and/or electric) and examination for mobility of adjacent teeth.
To exclude malignancy or identify other causes for impaired socket healing.	Biopsy. Not usually required but if there is a worrying radiographic appearance or solid tissue in the socket, biopsy is indicated.

### ◆ How Could an Oroantral Communication Be Confirmed At the Time of Extraction? How Might This Help?

If an antral communication is present, an echoing 'wind tunnel sound' will be heard if a small suction tip is held in the socket, the result of air being sucked from the antrum as well as the mouth. If the communication is large, you may be able to see into the antrum or identify nasal regurgitation of your irrigation fluids or blood from the extraction site. Do not ask patient to blow through their nose while holding it. The sinus lining may still be intact but would be burst by the pressure and a small communication might be enlarged.

If a communication is suspected, stabilization of the clot, closure of the socket with resorbable sutures and appropriate warnings to the patient about blowing the nose should prevent a fistula developing. This is likely to be effective if the diameter of the communication is 4 mm or less. If it is larger, it should be repaired immediately using a suitable flap technique to avoid sinusitis and infection.

Image: Odell

THIS IS COPYRIGHTED CONTENT. Unauthorized use, including screenshots, copying, misuse, reuse, or resale of any content from this app, is strictly prohibited. Our app monitors and records all screenshots and recordings. Violators will face strict legal action.

#### DISCLAIMER

THIS IS COPYRIGHTED CONTENT. Unauthorized use, including screenshots, copying, misuse, reuse, or resale of any content from this app, is strictly prohibited. Our app monitors and records all screenshots and recordings. Violators will face strict legal action.

DISCLAIMER  
THIS IS COPYRIGHTED CONTENT. Unauthorized use, including screenshots, copying, misuse, reuse, or resale of any content from this app, is strictly prohibited. Our app monitors and records all screenshots and recordings. Violators will face strict legal action.



## ORO-ANTRAL COMMUNICATION AND FISTULA

### Management:

- If there is a retained root fragment visible in the radiograph then,
  - i. Determine whether the root fragment is loose in the antrum or trapped under the sinus lining or in granulation tissue.
  - ii. **The root will have to be removed.**
  - iii. If it is under the lining or trapped, it is possible to remove it through the socket.
  - iv. If it is loose in the antrum, removal in this way may be impossible, hence elective surgical procedure such as the Clad-well Luc procedure is needed.
- Ways to determine if the fragment is loose or trapped:
  - i. If the fistula opening is large you might try to visualize the fragment directly.
  - ii. If not, a second radiograph at right angles to the periapical, such as an occipito-mental view will help localize it.
  - iii. A further view with the patient's head tilted would reveal whether or not the root moves.

### Preoperative management:

- If the symptoms are severe or pus is present in the fistula consider treating the sinusitis first and closing the fistula later after the sinusitis has partially resolved (it will not resolve completely until the fistula is closed).
- If there is a long-standing infective sinusitis, it should be treated prior to surgical closure otherwise healing will be compromised.
- Preoperatively, the affected maxillary sinus should be irrigated through the fistulous opening with normal saline followed by an iodine-containing solution diluted with normal saline (1:1; betadine) to eradicate infection.
- This regimen should be administered until the lavage fluid is clear and no longer contains inflammatory exudates.
- Numerous surgical procedures have been advocated for closure of OAC/OAF which prevents undesirable and harmful consequences of persistent OAC/OAF.
- These procedures may be categorized into local flaps, distant flaps and grafting.
- **The most common methods** used for closure of OAF are the **buccal flap and the palatal pedicled flap techniques.**

### DISCLAIMER

THIS IS COPYRIGHTED CONTENT. Unauthorized use, including screenshots, copying, misuse, reuse, or resale of any content from this app, is strictly prohibited. Our app monitors and records all screenshots and recordings. Violators will face strict legal action.

### DISCLAIMER

THIS IS COPYRIGHTED CONTENT. Unauthorized use, including screenshots, copying, misuse, reuse, or resale of any content from this app, is strictly prohibited. Our app monitors and records all screenshots and recordings. Violators will face strict legal action.

## ORO-ANTRAL COMMUNICATION AND FISTULA

### Surgical procedure for excision of fistula and flap surgery:

- Under local anesthesia, incise around the edge of the socket from gingiva right down into the antrum, removing all the soft tissue in the socket as a cylinder or cone-shaped piece and draw it into the mouth.
- Depending on the size of the bony defect and the amount of bone resorption (which is usually greater in long-standing fistulae), a large hole opens up into the sinus.
- With suction, good light and direct vision, try to identify the root fragment if present, and remove it with fine forceps, sucker tip or another instrument.
- Take care not to displace it into the sinus. If it becomes displaced, it may be possible to wash it out by flushing saline into the sinus. Alternatively, better surgical access to the sinus with Caldwell Luc approach may be done, which is done under GA, and main reason to refer the patient to the hospital.
- The excised tract should be sent for histopathological examination.

### Closing the Defect:

- The **buccal mucoperiosteal flap with advancement (buccal advancement flap)** is the most commonly used technique.
- After excision of the fistula following steps should be followed for buccal advancement flap technique:
  - i. Make two incisions buccally, anterior and posterior to the socket, passing parallel up the attached gingiva and then splaying to provide a wider base to ensure a good blood supply for the flap.
  - ii. The line of the incisions must be compatible with the flap sliding palatally to cover the defect in the alveolus.
  - iii. Elevate the mucoperiosteal flap you have outlined by lifting the soft tissues in the plane beneath the periosteum.
  - iv. Now Advance the flap: The flap cannot yet be pulled across the defect because the periosteum cannot be stretched so Fold the flap back to expose its periosteal surface and make several shallow parallel incisions across the flap that penetrate only the periosteum.
  - v. This must be done very carefully with the flap under slight tension.
  - vi. As the periosteum is incised the flap will be felt to stretch.
  - vii. Make sufficient incisions to lengthen the flap so that it can reach across to the palatal side of the defect with minimal tension.
  - viii. Prepare the palatal aspect of the alveolar defect. Refresh the margin of the palatal side to expose a narrow bony rim at least 1 mm wide, preferably 2 mm. The flap must be sutured into place at a site that has bony support.
  - ix. Suture the flap in place with sutures.

### DISCLAIMER

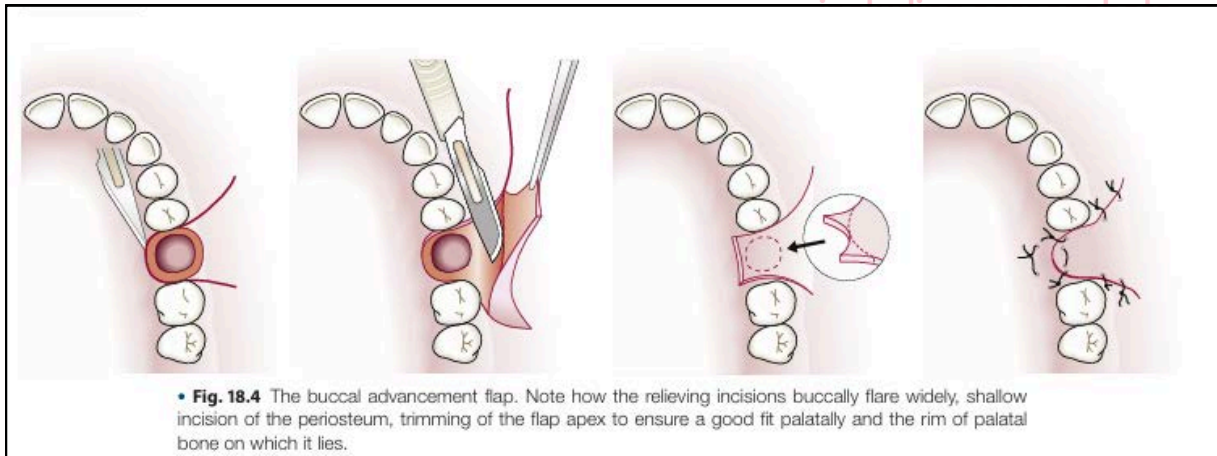
THIS IS COPYRIGHTED CONTENT. Unauthorized use, including screenshots, copying, misuse, reuse, or resale of any content from this app, is strictly prohibited. Our app monitors and records all screenshots and recordings. Violators will face strict legal action.

### DISCLAIMER

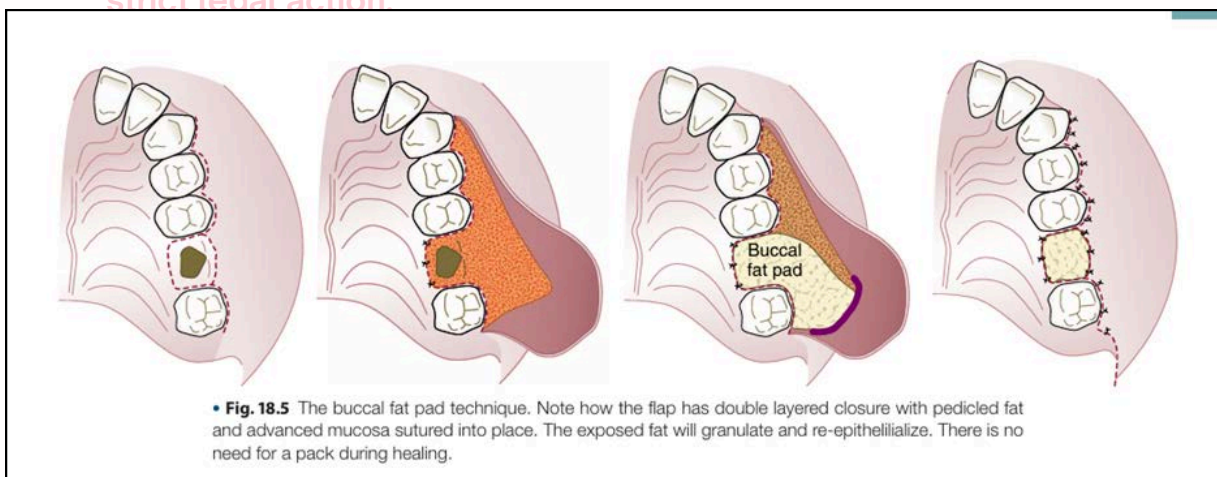
THIS IS COPYRIGHTED CONTENT. Unauthorized use, including screenshots, copying, misuse, reuse, or resale of any content from this app, is strictly prohibited. Our app monitors and records all screenshots and recordings. Violators will face strict legal action.

## ORO-ANTRAL COMMUNICATION AND FISTULA

### Closing the Defect:



- The buccal advancement flap may not be possible when the bony defect is very large or when a previous attempt at repair has failed.
- A number of other flaps are possible, including the palatal island flap, submucosal palatal island flap, combined buccal and palatal flaps and even pedicled grafts from the tongue.
- However the buccal fat pad technique is the second most commonly used method.



THIS IS COPYRIGHTED  
CONTENT. Unauthorized use,  
including screenshots,  
copying, misuse, reuse, or  
resale of any content from  
this app, is strictly prohibited.  
Our app monitors and records  
all screenshots and  
recordings. Violators will face  
strict legal action.

#### DISCLAIMER

THIS IS COPYRIGHTED CONTENT. Unauthorized use, including screenshots, copying, misuse, reuse, or resale of any content from this app, is strictly prohibited. Our app monitors and records all screenshots and recordings. Violators will face strict legal action.

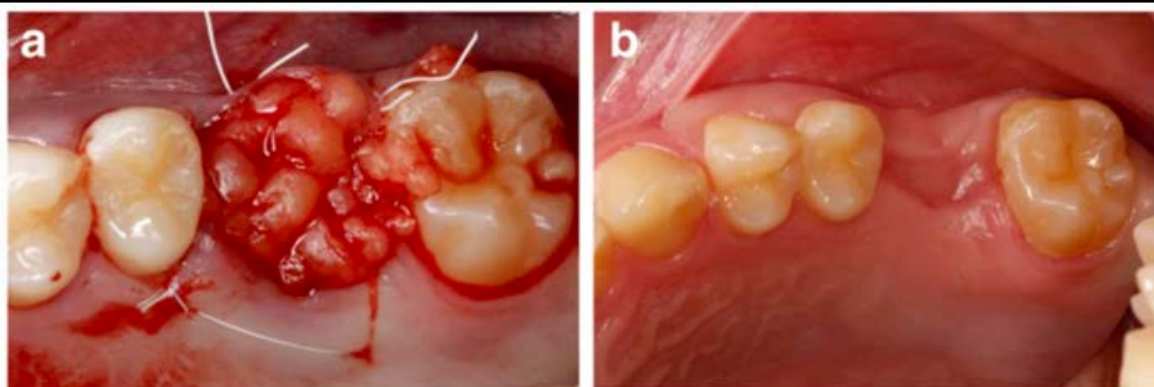
DISCLAIMER  
THIS IS COPYRIGHTED CONTENT. Unauthorized use, including screenshots, copying, misuse, reuse, or resale of any content from this app, is strictly prohibited. Our app monitors and records all screenshots and recordings. Violators will face strict legal action.



## ORO-ANTRAL COMMUNICATION AND FISTULA

Various alternative flap design are:

Local Flap Design	Indications/Advantages	Contraindications/Disadvantages
Buccal advancement flap (see Fig. 18.4).	Relatively simple, no flap donor site to heal, suitable for local analgesia.	Not ideal for large defect, advancing the flap reduces the depth of the residual buccal sulcus. Alveolar rather than masticatory mucosa advanced onto the ridge. Flap may break down if under tension.
Buccal fat pad technique. As above, and the buccal fat pad is dissected from under the buccal flap on a pedicle and secure in the socket (see Fig. 18.5).	As above, able to fill a larger defect.	General anaesthesia is required for fat pad dissection, sulcus loss.
Palatal flap.	Possible when buccal flap has failed or would have insufficient length to cover a palatally placed bone defect. Covers the defect with masticatory mucosa.	The flap is of thick tissue and is difficult to mobilize. The donor site is left to granulate and this is painful until healed.



**a** Closure by the buccal fat pad. **b** Healing after 3 months closure by buccal fat pad

THIS IS COPYRIGHTED CONTENT. Unauthorized use, including screenshots, copying, misuse, reuse, or resale of any content from this app, is strictly prohibited. Our app monitors and records all screenshots and recordings. Violators will face strict legal action.

### DISCLAIMER

THIS IS COPYRIGHTED CONTENT. Unauthorized use, including screenshots, copying, misuse, reuse, or resale of any content from this app, is strictly prohibited. Our app monitors and records all screenshots and recordings. Violators will face strict legal action.

**DISCLAIMER**  
THIS IS COPYRIGHTED CONTENT. Unauthorized use, including screenshots, copying, misuse, reuse, or resale of any content from this app, is strictly prohibited. Our app monitors and records all screenshots and recordings. Violators will face strict legal action.

this app, is strictly prohibited. Our app monitors and records all screenshots and recordings. Violators will face strict legal action.

## ORO-ANTRAL COMMUNICATION AND FISTULA

### Postoperative Management of the patient:

- The patients should be instructed not to eat hard food items.
- They should eat soft food items and drink fluid from the opposite side to avoid trauma to operated site.
- Strenuous physical activities which can increase the intra-sinusoidal pressure should be avoided until healing occurs.
- Nose blowing and sneezing with a closed mouth is prohibited for 2 weeks. Patient should open mouth while coughing or sneezing.
- Patients should not roll tongue over suture line or the flap for 07 days after surgery.
- The wound should be kept clean with warm saline mouth rinses.
- Use of straw or smoking is prohibited.
- Use of steam inhalations moistens the airway and stimulates serous gland activity preventing crusting of blood and mucous.
- In addition to the routine instructions given after extraction, the patient must be placed on an antral regime to reduce inflammation and prevent a rise in air pressure in the antrum.
- Decongestants maintain the patency of the opening of the sinus to favor drainage to the nose.

A suitable antral regime would be:

- an absolute ban on blowing the nose for 48 hours
  - sneeze allowing pressure to escape through the mouth
  - nasal decongestant (e.g. ephedrine nasal spray 0.5%)
  - decongestant inhalant.
- In addition, chlorhexidine mouthwash should be given. The repair will fail if there is leakage of saliva and bacteria past the flap from the oral aspect. No rinsing should be performed for 18 hours.

### Prevention:

- The risk of oroantral communication should be assessed routinely on a radiograph before extraction of upper molars.
- If the risk is high, an experienced surgeon should remove the tooth.
- Surgical extraction, possibly with elective sectioning of the tooth, reduces the chances of disrupting the maxillary floor.

#### DISCLAIMER

THIS IS COPYRIGHTED CONTENT. Unauthorized use, including screenshots, copying, misuse, reuse, or resale of any content from this app, is strictly prohibited. Our app monitors and records all screenshots and recordings. Violators will face strict legal action.

DISCLAIMER  
THIS IS COPYRIGHTED CONTENT. Unauthorized use, including screenshots, copying, misuse, reuse, or resale of any content from this app, is strictly prohibited. Our app monitors and records all screenshots and recordings. Violators will face strict legal action.

## SUTURE AND SUTURE TECHNIQUES

Effective wound management requires a thorough understanding of tissue healing, wound types, and the proper selection and application of sutures. Suturing remains the most reliable and widely used method for wound closure, although alternatives like surgical adhesives, staples, and tapes are also gaining popularity.

### Wound Management:

The main steps in wound care include:

- Cleansing and debridement
- Haemostasis
- Tetanus immunisation
- Wound dressing and closure
- Antibiotic therapy

Wound closure is especially necessary when there's significant exposure of connective tissue. The primary goal is to bring wound edges together to support healing, minimize scarring, and reduce infection risk.

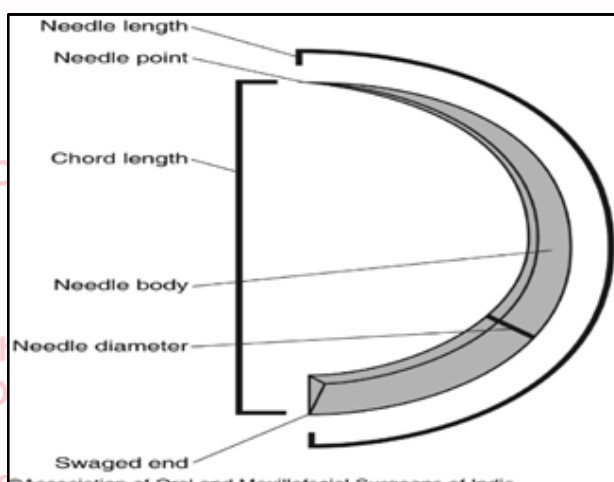
### Suturing Instruments:

Basic tools used in suturing include:

- **Needle holder:** Used to hold and drive the needle. Types include Mayo-Hegar and Webster. It often has a locking mechanism for better grip.
- **Tissue forceps:** Helps lift and evert wound edges during stitching. Adson forceps are commonly used.
- **Suture scissors:** Designed to cut sutures safely after tying, without damaging surrounding tissue.

### Suture Needles:

- Suture needles guide the thread through tissues with minimal trauma. Made from stainless or carbon steel, a needle has three parts: tip, body, and suture attachment end.
- **Shape:** Mostly curved in  $\frac{3}{8}$ ,  $\frac{1}{2}$ , or  $\frac{5}{8}$  circles.  $\frac{1}{2}$  circle needles are common in oral and maxillofacial surgeries



Association of Oral and Maxillofacial Surgeons of India

strict legal action.

### DISCLAIMER

THIS IS COPYRIGHTED CONTENT. Unauthorized use, including screenshots, copying, misuse, reuse, or resale of any content from this app, is strictly prohibited. Our app monitors and records all screenshots and recordings. Violators will face strict legal action.

DISCLAIMER  
THIS IS COPYRIGHTED CONTENT. Unauthorized use, including screenshots, copying, misuse, reuse, or resale of any content from this app, is strictly prohibited. Our app monitors and records all screenshots and recordings. Violators will face strict legal action.

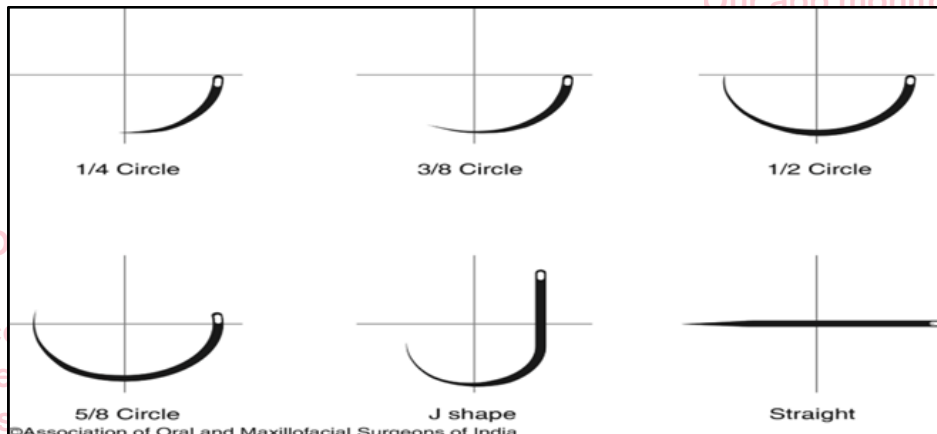


# SUTURE AND SUTURE TECHNIQUES

## Suture Needles:

### Eyed vs. Swaged:

- Eyed needles are reusable but cause more tissue drag.
- Swaged needles have thread fused to the needle, causing less trauma and are called atraumatic.



## Suture Classification

Sutures are classified by several criteria:

### Source:

- Natural: Catgut, silk, cotton
- Synthetic: Nylon, polyester, PGA

### Absorbability:

- Absorbable: Gradually degraded and absorbed by the body.
- Non-absorbable: Must be removed manually after healing.

### Filament Type:

- Monofilament: Single strand; less risk of infection.
- Multifilament: Braided; better knot security but higher risk of bacterial colonization.

### Sizes:

- Labeled as 1 to 11-0 (smaller numbers = thicker threads). Common intraoral sizes are 3-0 to 5-0.

## DISCLAIMER

THIS IS COPYRIGHTED CONTENT. Unauthorized use, including screenshots, copying, misuse, reuse, or resale of any content from this app, is strictly prohibited. Our app monitors and records all screenshots and recordings. Violators will face strict legal action.

DISCLAIMER

THIS IS COPYRIGHTED CONTENT. Unauthorized use, including screenshots, copying, misuse, reuse, or resale of any content from this app, is strictly prohibited. Our app monitors and records all screenshots and recordings. Violators will face strict legal action.

# SUTURE AND SUTURE TECHNIQUES

## Types of Suture Materials

### Natural Absorbable

- Catgut: Derived from animal intestines, digested by enzymes; has high tissue reactivity and poor strength.
- Chromic catgut: Treated with chromic salts for delayed absorption and reduced tissue reaction.

### Natural Non-Absorbable

- Silk: Most commonly used natural non-absorbable suture. Easy to handle but can incite a tissue reaction. Often used in oral surgery.

### Synthetic Non-Absorbable

- Nylon (Polyamide): High strength and elasticity. Monofilament type has memory, making knot tying harder.
- Polypropylene: Blue-colored, highly elastic, inert. Commonly used in skin and vascular surgery.
- Polyester (Dacron): Braided with good knot security. Used in cardiovascular and prosthetic procedures.
- PTFE (Teflon): Monofilament, smooth, inert, and ideal for oral surgery.
- Stainless Steel: Extremely strong, but difficult to handle; used in orthopedic and sternal closures.

### Synthetic Absorbable

- PGA (Polyglycolic acid): Braided, retains strength for 2 weeks.
- Polyglactin 910 (Vicryl): Braided with better absorption than PGA. Dyed violet, used in oral and facial surgeries.
- Poliglecaprone 25 (Monocryl): Monofilament, pliable; absorbed in 100 days.
- Polydioxanone (PDS): Monofilament, long-lasting strength, ideal for fascia.
- Polyglyconate: Long-term absorption with strong tensile retention.
- Polyglytone 6211: Fast absorption, low tissue reaction.

THIS IS COPYRIGHTED  
CONTENT. Unauthorized use,  
including screenshots,  
copying, misuse, reuse, or  
resale of any content from  
this app, is strictly prohibited.  
Our app monitors and records  
all screenshots and  
recordings. Violators will face  
strict legal action.

#### DISCLAIMER

THIS IS COPYRIGHTED CONTENT. Unauthorized use, including screenshots, copying, misuse, reuse, or resale of any content from this app, is strictly prohibited. Our app monitors and records all screenshots and recordings. Violators will face strict legal action.


DISCLAIMER  
THIS IS COPYRIGHTED CONTENT. Unauthorized use, including screenshots, copying, misuse, reuse, or resale of any content from this app, is strictly prohibited. Our app monitors and records all screenshots and recordings. Violators will face strict legal action.

# SUTURE AND SUTURE TECHNIQUES

## Suturing Techniques

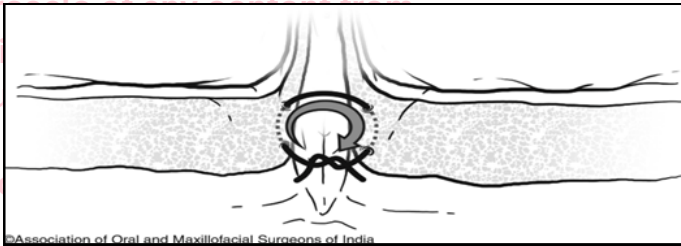
### Simple Interrupted

- Most common and basic stitch. Each loop is individually tied, providing strong wound security. Easy to place and adjust but may leave visible scars.



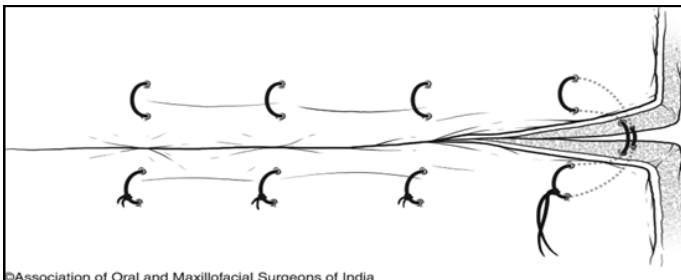
### Simple Buried

- Knot remains beneath the skin. Used for deeper tissue layers and prevents external stitch exposure. Good for cosmetic areas.




### Vertical Mattress

- Includes deep and superficial bites for enhanced wound edge eversion. Good tensile strength, commonly used on skin surfaces.



### Simple Continuous

- Single strand runs along the wound with knots only at both ends. Fast but if one loop fails, the whole suture may unravel.



THIS IS COPYRIGHTED CONTENT. Unauthorized use, including screenshots, copying, misuse, reuse, or resale of any content from this app, is strictly prohibited. Our app monitors and records all screenshots and recordings. Violators will face strict legal action.

**DISCLAIMER**  
THIS IS COPYRIGHTED CONTENT. Unauthorized use, including screenshots, copying, misuse, reuse, or resale of any content from this app, is strictly prohibited. Our app monitors and records all screenshots and recordings. Violators will face strict legal action.

**DISCLAIMER**

THIS IS COPYRIGHTED CONTENT. Unauthorized use, including screenshots, copying, misuse, reuse, or resale of any content from this app, is strictly prohibited. Our app monitors and records all screenshots and recordings. Violators will face strict legal action.

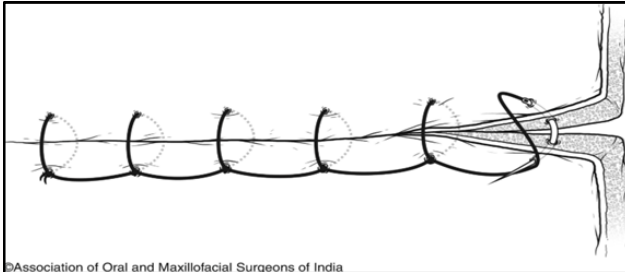


# SUTURE AND SUTURE TECHNIQUES

## Suturing Techniques

### Locking Continuous


- A locked version of continuous sutures. Provides even tension and better wound alignment.



©Association of Oral and Maxillofacial Surgeons of India

### Subcuticular

- A buried, aesthetic suture often used on the face. Minimizes scarring. Time-consuming and requires precision.



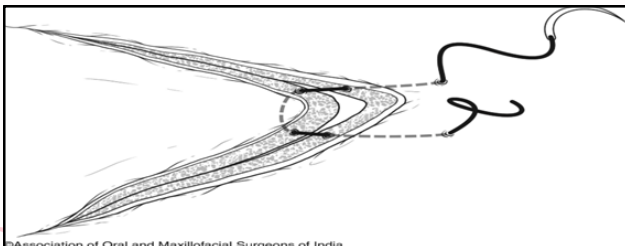
©Association of Oral and Maxillofacial Surgeons of India

### Purse-String

- Circular stitch used to close round wounds or reduce defect size. Common in drain fixation or around stomas.

### Three-Point

- Used for triangular or pointed flaps (e.g., cleft lip). Ensures proper tip alignment.



©Association of Oral and Maxillofacial Surgeons of India

THIS IS COPYRIGHTED CONTENT. Unauthorized use, including screenshots, copying, misuse, reuse, or resale of any content from this app, is strictly prohibited. Our app monitors and records all screenshots and recordings. Violators will face strict legal action.

THIS IS COPYRIGHTED CONTENT. Unauthorized use, including screenshots, copying, misuse, reuse, or resale of any content from this app, is strictly prohibited. Our app monitors and records all screenshots and recordings. Violators will face strict legal action.

including screenshots, copying, misuse, reuse, or resale of any content from this app, is strictly prohibited. Our app monitors and records all screenshots and recordings. Violators will face strict legal action.

### DISCLAIMER

THIS IS COPYRIGHTED CONTENT. Unauthorized use, including screenshots, copying, misuse, reuse, or resale of any content from this app, is strictly prohibited. Our app monitors and records all screenshots and recordings. Violators will face strict legal action.

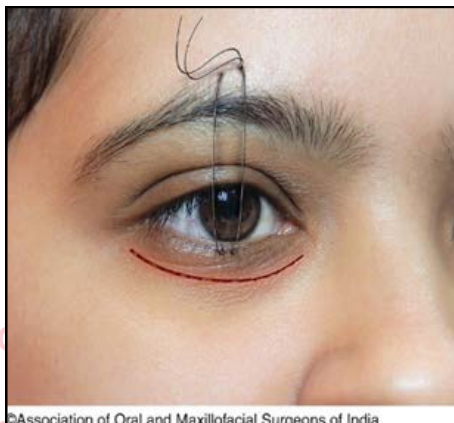DISCLAIMER  
THIS IS COPYRIGHTED CONTENT. Unauthorized use, including screenshots, copying, misuse, reuse, or resale of any content from this app, is strictly prohibited. Our app monitors and records all screenshots and recordings. Violators will face strict legal action.

# SUTURE AND SUTURE TECHNIQUES

## Suturing Techniques

### Frost Suture

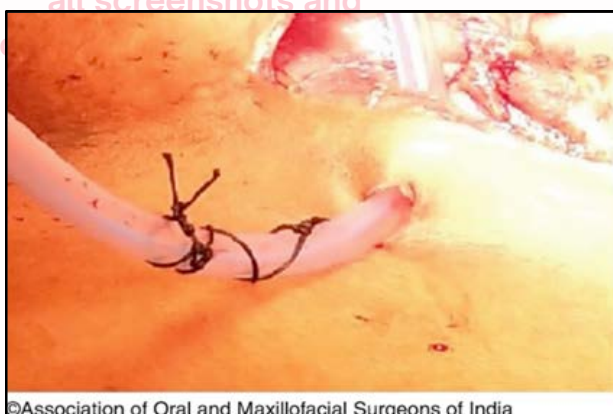- Temporary lower eyelid support after surgery. Removed after a few days.



©Association of Oral and Maxillofacial Surgeons of India

### Drain Anchoring

- Used to secure surgical drains (e.g., Roman Garter method) with multiple windings around the tube.



©Association of Oral and Maxillofacial Surgeons of India

THIS IS COPYRIGHTED CONTENT. Unauthorized use, including screenshots, copying, misuse, reuse, or resale of any content from this app, is strictly prohibited. Our app monitors and records all screenshots and recordings. Violators will face strict legal action.

THIS IS COPYRIGHTED CONTENT. Unauthorized use, including screenshots, copying, misuse, reuse, or resale of any content from this app, is strictly prohibited. Our app monitors and records all screenshots and recordings. Violators will face strict legal action.

THIS IS COPYRIGHTED CONTENT. Unauthorized use, including screenshots, copying, misuse, reuse, or resale of any content from this app, is strictly prohibited. Our app monitors and records all screenshots and recordings. Violators will face strict legal action.

#### DISCLAIMER

THIS IS COPYRIGHTED CONTENT. Unauthorized use, including screenshots, copying, misuse, reuse, or resale of any content from this app, is strictly prohibited. Our app monitors and records all screenshots and recordings. Violators will face strict legal action.

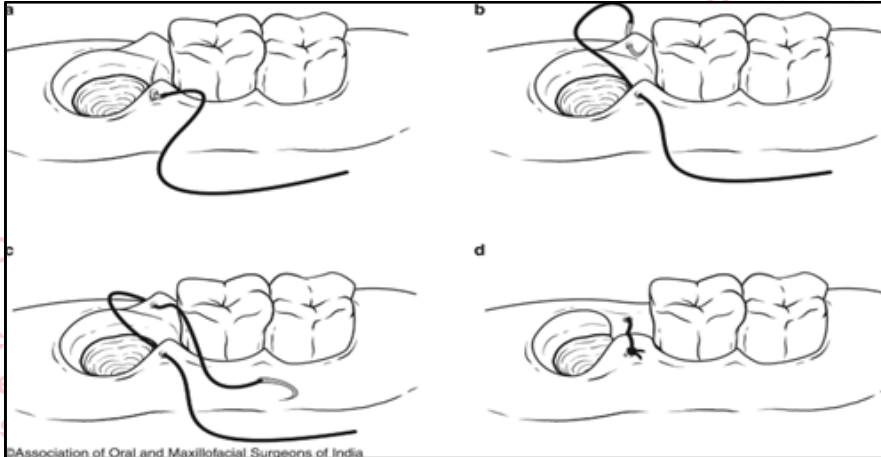
DISCLAIMER  
THIS IS COPYRIGHTED CONTENT. Unauthorized use, including screenshots, copying, misuse, reuse, or resale of any content from this app, is strictly prohibited. Our app monitors and records all screenshots and recordings. Violators will face strict legal action.

# SUTURE AND SUTURE TECHNIQUES

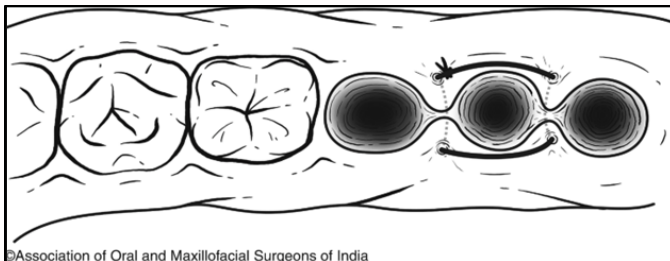
## Dentoalveolar Suturing Techniques

### Common in dental and oral surgeries.

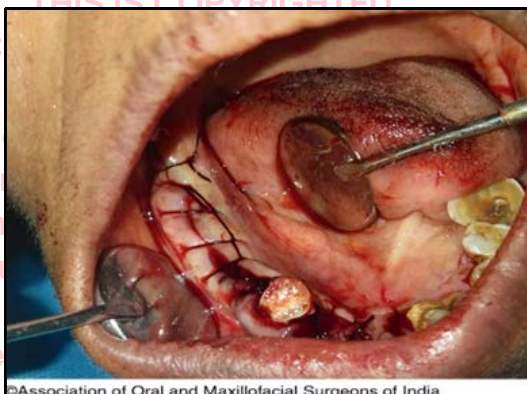- Simple Interrupted (Interdental): Closes flaps after extractions or flap surgery; knot usually tied on buccal side.
- Reversing Suture: Used when both buccal and lingual flaps are elevated.



- Vertical Mattress: Aids in papilla stabilization.
- Horizontal Mattress: Provides wide tissue apposition; suitable for edentulous regions.



- Figure-of-Eight: Common for extraction sites. Crosses the wound for better tension and haemostasis.
- Continuous Sutures: For long edentulous wounds; efficient and quick.
- Locking Continuous: Improves alignment and wound tension control.



### DISCLAIMER

THIS IS COPYRIGHTED CONTENT. Unauthorized use, including screenshots, copying, misuse, reuse, or resale of any content from this app, is strictly prohibited. Our app monitors and records all screenshots and recordings. Violators will face strict legal action.

DISCLAIMER  
THIS IS COPYRIGHTED CONTENT. Unauthorized use, including screenshots, copying, misuse, reuse, or resale of any content from this app, is strictly prohibited. Our app monitors and records all screenshots and recordings. Violators will face strict legal action.



## SUTURE AND SUTURE TECHNIQUES

### Suture Removal

Timing depends on location:

- Face/oral: 5–7 days
- Eyelids: 3–5 days
- Neck/scalp: 7–10 days
- Limbs/trunk: 10–14 days

In continuous sutures, each loop should be individually cut. Subcuticular sutures are pulled from one end after cutting the knot.

THIS IS COPYRIGHTED CONTENT. Unauthorized use, including screenshots, copying, misuse, reuse, or resale of any content from this app, is strictly prohibited. Our app monitors and records all screenshots and recordings. Violators will face strict legal action.

THIS IS COPYRIGHTED CONTENT. Unauthorized use, including screenshots, copying, misuse, reuse, or resale of any content from this app, is strictly prohibited. Our app monitors and records all screenshots and recordings. Violators will face strict legal action.

#### DISCLAIMER

THIS IS COPYRIGHTED CONTENT. Unauthorized use, including screenshots, copying, misuse, reuse, or resale of any content from this app, is strictly prohibited. Our app monitors and records all screenshots and recordings. Violators will face strict legal action.

THIS IS COPYRIGHTED CONTENT. Unauthorized use, including screenshots, copying, misuse, reuse, or resale of any content from this app, is strictly prohibited. Our app monitors and records all screenshots and recordings. Violators will face strict legal action.

THIS IS COPYRIGHTED CONTENT. Unauthorized use, including screenshots, copying, misuse, reuse, or resale of any content from this app, is strictly prohibited. Our app monitors and records all screenshots and recordings. Violators will face strict legal action.

DISCLAIMER  
THIS IS COPYRIGHTED CONTENT. Unauthorized use, including screenshots, copying, misuse, reuse, or resale of any content from this app, is strictly prohibited. Our app monitors and records all screenshots and recordings. Violators will face strict legal action.

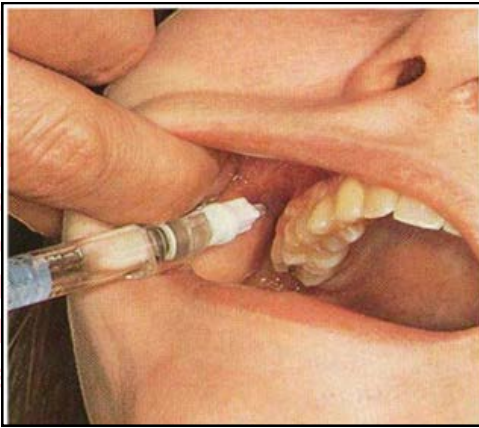


## LA TECHNIQUES AND COMPLICATIONS

### A) Maxillary Blocks

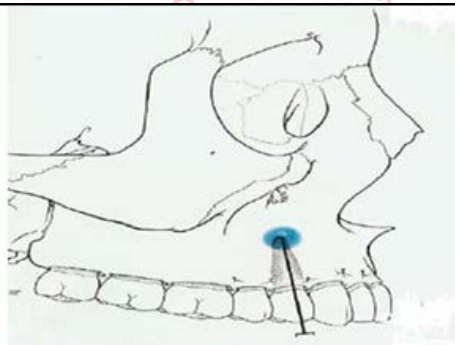
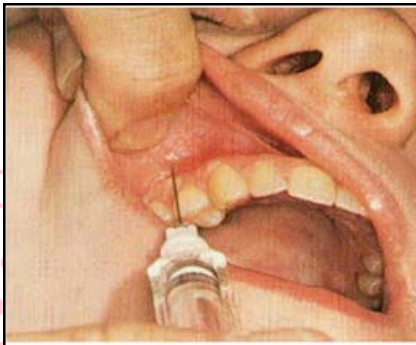#### a) The posterior superior alveolar block (PSA)

- The posterior superior alveolar block is used to anesthetize the maxillary molars, excluding the mesio-buccal root of the first molar.
- It also anesthetizes their periodontium and the adjacent buccal soft tissues.
- The needle is inserted 15 mm into the buccal vestibule distal to the malar at 45 degrees to the occlusal plane, and 1 ml of anesthetic solution is injected.
- Insert the needle into the height of the mucobuccal fold over the second molar. Advance the needle slowly in an upward, inward, and backward direction in one movement.



#### b) The middle superior alveolar block (MSA)

- It anesthetizes the maxillary premolars, the mesio-buccal root of the first molar, their periodontium, and adjacent buccal soft tissues.
- The needle is inserted 5 mm into the buccal vestibule adjacent to the maxillary second premolar, and 1 ml of anesthetic solution is given.



#### DISCLAIMER

THIS IS COPYRIGHTED CONTENT. Unauthorized use, including screenshots, copying, misuse, reuse, or resale of any content from this app, is strictly prohibited. Our app monitors and records all screenshots and recordings. Violators will face strict legal action.

#### DISCLAIMER

THIS IS COPYRIGHTED CONTENT. Unauthorized use, including screenshots, copying, misuse, reuse, or resale of any content from this app, is strictly prohibited. Our app monitors and records all screenshots and recordings. Violators will face strict legal action.



## LA TECHNIQUES AND COMPLICATIONS

### A) Maxillary Blocks

#### c) The anterior superior alveolar block (ASA)

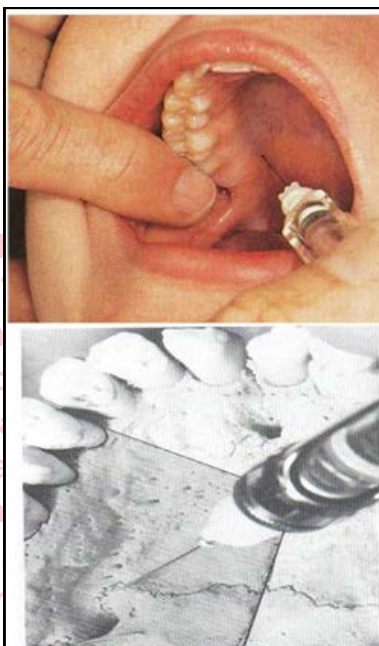
- It anesthetizes the maxillary incisor and canine teeth, periodontium, and buccal soft tissues.
- The needle is inserted 5 mm into the buccal vestibule of the maxillary canine, and 1 ml of anesthetic solution is given.

#### d) The infraorbital block

- It serves to anesthetize the ipsilateral maxillary teeth, periodontium, buccal soft tissues, maxillary tuberosity, and the skin of the lower eyelid, nose, cheek, and upper lip.
- The needle is parallel to the second premolar and inserted into the mucosa above this tooth.
- The operator's fingers of the non-dominant hand are placed over the infraorbital rim, and the needle is inserted until palpated in the vicinity of the infraorbital foramen.

#### e) The greater palatine block

- It anesthetizes the ipsilateral hard palate posterior to the canine tooth.
- The needle is inserted at the entrance of the greater palatine foramen to a depth of less than 5 mm until the bone is contacted and 0.5 ml of anesthetic solution is injected.
- The greater palatine foramen is a palpable depression or soft area on the hard palate, usually at the third maxillary molar level or 5 mm anterior to the hard and soft palate junction and halfway between the gingiva and palate midline.



**DISCLAIMER**

THIS IS COPYRIGHTED CONTENT. Unauthorized use, including screenshots, copying, misuse, reuse, or resale of any content from this app, is strictly prohibited. Our app monitors and records all screenshots and recordings. Violators will face strict legal action.

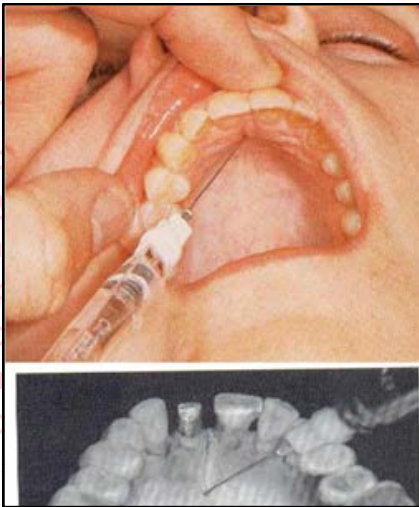
**DISCLAIMER**  
THIS IS COPYRIGHTED CONTENT. Unauthorized use, including screenshots, copying, misuse, reuse, or resale of any content from this app, is strictly prohibited. Our app monitors and records all screenshots and recordings. Violators will face strict legal action.

## LA TECHNIQUES AND COMPLICATIONS

### A) Maxillary Blocks

#### f) The nasopalatine block

- It anesthetizes the palatal premaxilla bilaterally. In some patients, it further provides some anesthesia to the maxillary incisors.
- Following buccal and intrapapillary infiltrations, the needle is inserted into the blanched incisive papilla to a depth of less than 5 mm until the bone is contacted and the tip contacts the lateral soft tissue of the incisive papilla. 0.25 ml of anesthetic solution is usually sufficient.



- In nasopalatine nerve block, the solution is deposited near the incisive foramen, which is located in the midline of the palate about 1cm posterior to the maxillary central incisors.

#### \*Palatal anesthesia

- It could be achieved by:
  1. **greater palatine nerve block**, which provides anesthesia of the posterior portion of the hard palate, or
  2. **nasopalatine nerve block**, which provides anesthesia of the anterior portion of the hard palate, or
  3. by **infiltration technique** in which the solution is deposited in the palatal tissue adjacent to the target tooth.

#### DISCLAIMER

THIS IS COPYRIGHTED CONTENT. Unauthorized use, including screenshots, copying, misuse, reuse, or resale of any content from this app, is strictly prohibited. Our app monitors and records all screenshots and recordings. Violators will face strict legal action.

#### DISCLAIMER

THIS IS COPYRIGHTED CONTENT. Unauthorized use, including screenshots, copying, misuse, reuse, or resale of any content from this app, is strictly prohibited. Our app monitors and records all screenshots and recordings. Violators will face strict legal action.

## LA TECHNIQUES AND COMPLICATIONS

### B) Mandibular Blocks:

- The portions of the mandible consist of dense, thickened bone, making it difficult for externally deposited local anesthetic to diffuse toward the inferior alveolar nerve (IAN) that lies within the substance of the mandible.
- Therefore, clinicians commonly attempt to anaesthetize this nerve, which supplies all mandibular teeth on the ipsilateral side, before it enters the mandibular canal via blockade anesthesia.
- Many techniques of mandibular blockade are present. However, the most commonly used ones are:

1. The direct inferior alveolar nerve block (IANB)
2. the indirect IANB
3. The Akinosi closed mouth technique
4. The Gow-Gates technique

*\*Some extraoral techniques via the mandibular notch, are useful in some trauma patients.*

#### 1. The Direct IANB:

- Although there are many techniques described, the direct IANB, also known as the direct thrust approach, remains one of the most commonly used to obtain mandibular anesthesia.
- It involves needle insertion into the pterygomandibular space by piercing the buccinator muscle, anteriorly.
- Once in this anatomical space, the objective of this technique is to deposit local anesthetic solution near the inferior alveolar nerve, just before it enters the mandibular foramen that leads into the mandibular canal.
- The exact location of where the needle tip should be located in relation to the IAN is hard to assess in any one patient due to the required 20-25mm depth of tissue penetration, but, it is advantageous to administer the injection so that the tip of the needle contacts bone just superior to the tip of the lingula.

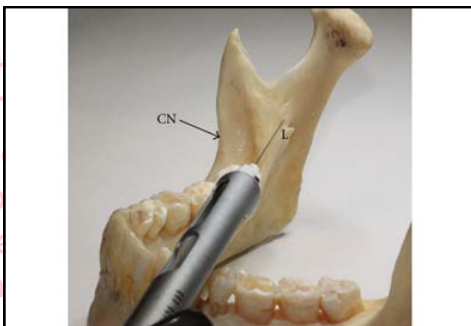

FIGURE 2: Photograph of the mandible where the needle tip is directed toward the area of bone just superior to the lingula. This positioning of the needle will allow for local anaesthetic deposition in a location in close proximity to the IAN and associated vessels, yet minimising the risk of damaging them. This photograph reflects where local anaesthetic is injected with the direct and indirect IANB (CN: Coronoid notch, L: Lingula).

Image: Article

#### DISCLAIMER

THIS IS COPYRIGHTED CONTENT. Unauthorized use, including screenshots, copying, misuse, reuse, or resale of any content from this app, is strictly prohibited. Our app monitors and records all screenshots and recordings. Violators will face strict legal action.

#### DISCLAIMER

THIS IS COPYRIGHTED CONTENT. Unauthorized use, including screenshots, copying, misuse, reuse, or resale of any content from this app, is strictly prohibited. Our app monitors and records all screenshots and recordings. Violators will face strict legal action.

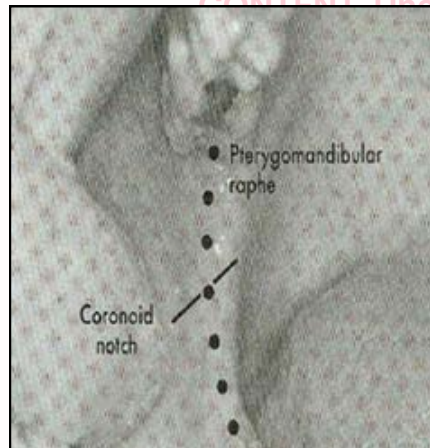
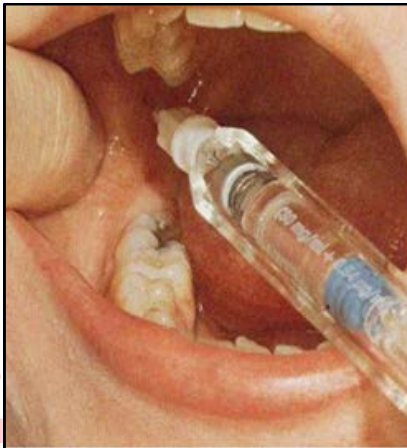


# LA TECHNIQUES AND COMPLICATIONS

## B) Mandibular Blocks:

### 1. The Direct IANB:

- The lingual nerve lies medial and anterior to the IAN and can be anaesthetized during an IANB by withdrawing the needle and swinging the barrel of the syringe toward the dental midline.
- Upon intra-oral inspection, two important landmarks should be identified: **the retromolar triangle and the pterygomandibular raphe** (this structure passes upward and inward from the posterior end of the mylohyoid line of the mandible to the Hamulus of the medial pterygoid plate, the point of insertion of the needle should be lateral to and Infront of it).
- The thumb of the left hand is passed along the buccal surfaces of the lower molar teeth until the external oblique ridge is felt. The tip of the thumb is then passed inward to lie in the retro-molar fossa.
- The mid-point of the nail should lie in the deepest part of the coronoid notch.
- A long needle is inserted at this point. With the barrel of the syringe held parallel to the mandibular occlusal plane and over the second premolar tooth of the opposite side of the mouth, the tip of the needle is inserted for about 2 - 2.5 cm until its tip lightly contact the bone above the mandibular foramen.
- When bone is contacted withdraw approximately 1mm to prevent subperiosteal injection and about 1.5 ml of the solution deposited. Then slowly withdraw the syringe and when approximately half its length remains within tissues deposit few drops of the solution to anesthetize the lingual nerve.



including screenshots, copying, misuse, reuse, or resale of any content from this app, is strictly prohibited. Our app monitors and records all screenshots and recordings. Violators will face strict legal action.

#### DISCLAIMER

THIS IS COPYRIGHTED CONTENT. Unauthorized use, including screenshots, copying, misuse, reuse, or resale of any content from this app, is strictly prohibited. Our app monitors and records all screenshots and recordings. Violators will face strict legal action.

DISCLAIMER  
THIS IS COPYRIGHTED CONTENT. Unauthorized use, including screenshots, copying, misuse, reuse, or resale of any content from this app, is strictly prohibited. Our app monitors and records all screenshots and recordings. Violators will face strict legal action.

# LA TECHNIQUES AND COMPLICATIONS

## B) Mandibular Blocks:

### 2. Indirect IANB:

- The indirect IANB is a variation of the direct technique where the level and site of injection is the same.
- The fundamental difference, however, lies in the method by which the appropriate depth of needle insertion ( 20–25mm) is obtained.
- The indirect technique involves the insertion of the needle using the same landmarks to indicate correct height and mediolateral needle placement, but with a significantly greater degree of syringe angulation on the contralateral side.
- The effect of this is to make early bone contact near the anterior border of the ramus, anterior to the mandibular foramen.
- A variation of indirect IANB is Anterior injection technique that involves the insertion of the needle for approximately 10mm into the pterygomandibular space where the local anesthetic is deposited, allowing for the anesthetic solution to slowly diffuse across the space and toward the IAN.

### 3. Gow-Gates Mandibular Block Technique:

- The Gow-Gates mandibular block is often referred to as a **true mandibular block** as the distribution of its effect is larger than that of lower-level nerve block techniques and it anaesthetizes the auriculotemporal and long buccal nerves in most cases.
- **This technique involves the intraoral insertion** of a needle through the pterygomandibular space until bony contact is made with the anterolateral condylar neck.

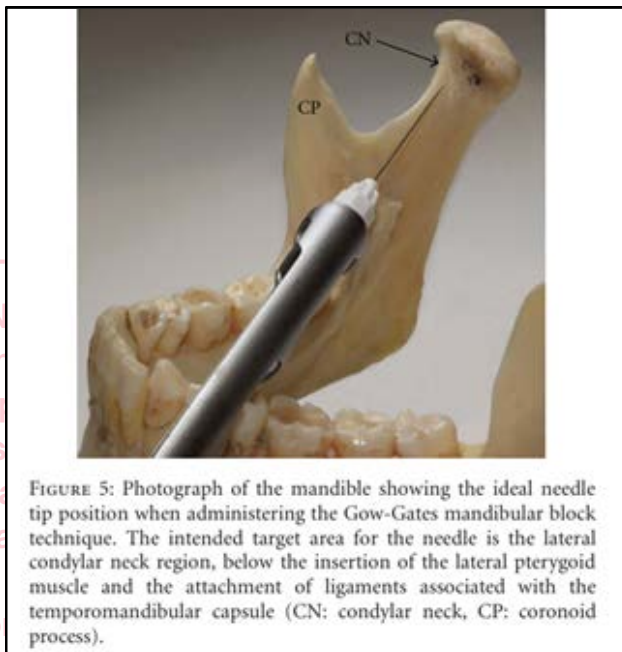


FIGURE 5: Photograph of the mandible showing the ideal needle tip position when administering the Gow-Gates mandibular block technique. The intended target area for the needle is the lateral condylar neck region, below the insertion of the lateral pterygoid muscle and the attachment of ligaments associated with the temporomandibular capsule (CN: condylar neck, CP: coronoid process).

#### DISCLAIMER

THIS IS COPYRIGHTED CONTENT. Unauthorized use, including screenshots, copying, misuse, reuse, or resale of any content from this app, is strictly prohibited. Our app monitors and records all screenshots and recordings. Violators will face strict legal action.

#### DISCLAIMER

THIS IS COPYRIGHTED CONTENT. Unauthorized use, including screenshots, copying, misuse, reuse, or resale of any content from this app, is strictly prohibited. Our app monitors and records all screenshots and recordings. Violators will face strict legal action.

## LA TECHNIQUES AND COMPLICATIONS

### B) Mandibular Blocks:

#### 3. Gow-Gates Mandibular Block Technique:

- Although different for every patient, the average depth of needle insertion is 25mm, and following needle contact, withdrawal of 1-2mm, and an aspiration test is required.
- Malamed has suggested that the patient should keep their mouth open for 60–90 seconds following injection to allow for more speedy diffusion of local anesthetic as mandibular opening reduces the distance between where the local anesthetic is deposited and the mandibular nerve.

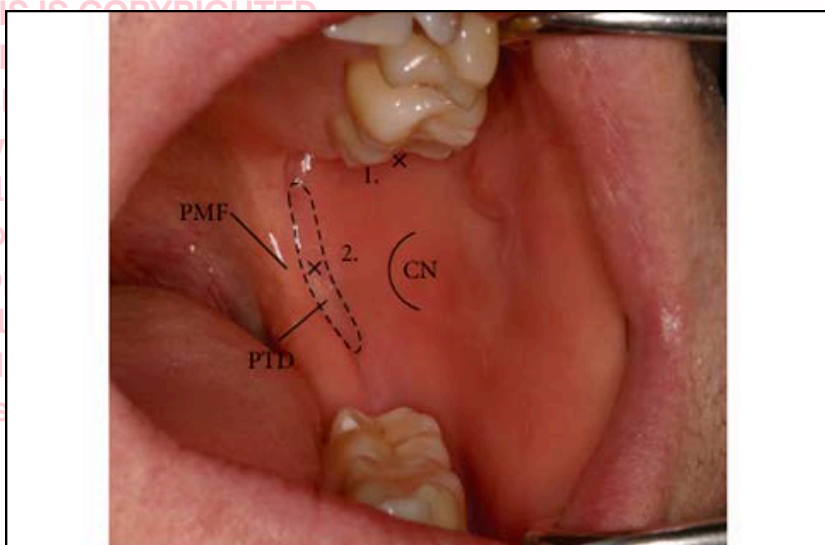


FIGURE 3: Intraoral photograph of the left side of the oral cavity showing the injection sites for different mandibular block techniques. The pterygotemporal depression exists between the pterygomandibular fold and coronoid notch and represents the area where a direct or indirect IANB is administered in the mediolateral plane. The height at which this block is given is approximately the level of the coronoid notch. In contrast, the Gow-Gates mandibular block is administered at a much higher level. The mesiopalatal cusp of the upper second molar determines the height of the injection while the site in the mediolateral plane is the area of tissue just posterior to the upper second or third molar (PTD: pterygotemporal depression, PMF: pterygomandibular fold, CN: coronoid notch, 1: area where a Gow-Gates mandibular block would be administered, 2: area where a direct/indirect IANB would be administered).

#### DISCLAIMER

THIS IS COPYRIGHTED CONTENT. Unauthorized use, including screenshots, copying, misuse, reuse, or resale of any content from this app, is strictly prohibited. Our app monitors and records all screenshots and recordings. Violators will face strict legal action.

DISCLAIMER  
THIS IS COPYRIGHTED CONTENT. Unauthorized use, including screenshots, copying, misuse, reuse, or resale of any content from this app, is strictly prohibited. Our app monitors and records all screenshots and recordings. Violators will face strict legal action.



## LA TECHNIQUES AND COMPLICATIONS

### B) Mandibular Blocks:

#### 4. Akinosi Closed-Mouth Technique.

- The Akinosi **closed mouth mandibular block** approach provides an alternate technique for individuals who have limited mouth opening, which is a distinct contraindication for the other block techniques
- This technique involves the intraoral insertion of a needle into the pterygomandibular space for 25–30mm **while the mouth is fully closed**.
- This technique does not involve bony contact, where the desired location of the needle tip should be in the loose areolar tissue medial to the mandibular ramus.
- As with other block procedures, an aspiration test is performed before deposition of local anesthetic.
- The site of injection for this technique is at the level of the mucogingival junction of the maxillary second or third molar.
- Although this technique can be used for anyone, most clinicians reserve it for those who have severe mouth opening deficiencies or are severe gaggers.

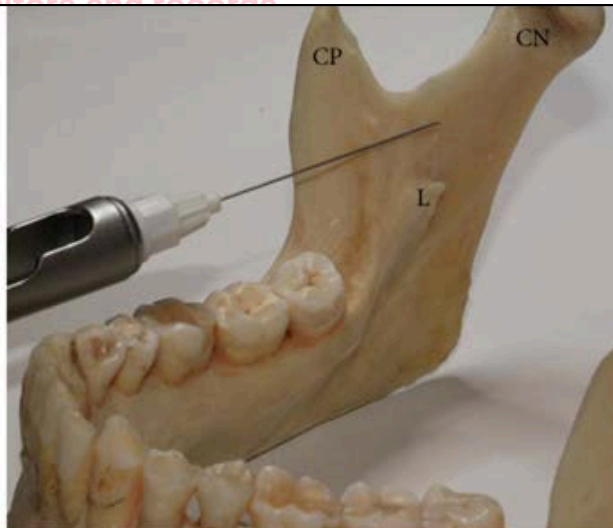


FIGURE 6: Photograph of the mandibular ramus from a medial view showing the needle tip positioning required for the Akinosi closed mouth mandibular nerve block technique. Note that the needle should not contact bone during needle insertion. The needle tip slips along the medial aspect of the ramus to its intended target area, the loose areolar tissue within the superior reach of the pterygomandibular space (CN: condylar neck, CP: coronoid process, L: lingula).

#### DISCLAIMER

THIS IS COPYRIGHTED CONTENT. Unauthorized use, including screenshots, copying, misuse, reuse, or resale of any content from this app, is strictly prohibited. Our app monitors and records all screenshots and recordings. Violators will face strict legal action.

## LA TECHNIQUES AND COMPLICATIONS

### B) Mandibular Blocks:

#### 5. Supplementation to Blockade Anesthesia with Local Supra-periosteal Infiltrations

- The success rates of some injection techniques can be quite low, especially with direct and indirect IANBs.
- Hence, supplementation of these injections with local infiltrations has been suggested.
- These infiltration injections should not be confused with buccal nerve blocks or infiltrations which are administered following a direct or indirect IANB to anaesthetize the long buccal nerve which innervates the buccal gingivae of lower posterior molars.
- The long buccal nerve and the lingual nerve must be anaesthetized, in addition to the IAN, if lower posterior teeth are to be extracted.

#### 6. Mental and Incisive Blocks

- Although the mental and incisive nerves are anesthetized by an IANB, mental and incisive blocks are useful when bilateral anesthesia is desired on or anterior to the mandibular premolars.

#### 7. Buccal Nerve Block

- The buccal nerve block is administered when anesthesia of the buccal mucosa or the buccal gingiva of the mandibular molars is required.
- The needle is advanced 1 to 3 mm into the buccal vestibule distal to the second or third molar until the bone is contacted.
- The point of insertion is medial to the coronoid notch.
- A small amount of anesthetic solution, usually 0.25 ml, tends to suffice.

THIS IS COPYRIGHTED  
CONTENT. Unauthorized use,  
including screenshots,  
copying, misuse, reuse, or  
resale of any content from  
this app, is strictly prohibited.  
Our app monitors and records  
all screenshots and  
recordings. Violators will face  
strict legal action.

#### DISCLAIMER

THIS IS COPYRIGHTED CONTENT. Unauthorized use, including screenshots, copying, misuse, reuse, or resale of any content from this app, is strictly prohibited. Our app monitors and records all screenshots and recordings. Violators will face strict legal action.

DISCLAIMER  
THIS IS COPYRIGHTED CONTENT. Unauthorized use, including screenshots, copying, misuse, reuse, or resale of any content from this app, is strictly prohibited. Our app monitors and records all screenshots and recordings. Violators will face strict legal action.