



WINSPERT

**RADIOLOGY**

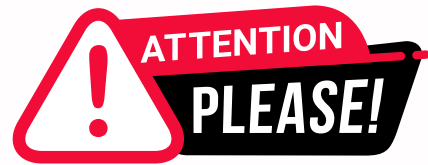**H.O.T**

**HIGH-PRIORITY ORGANISED THEORY**

**NOTES**

By Dr. Jigyasa Sharma





Dear Students,

We'd like to remind you about the importance of respecting the integrity of the resources provided in our app.

Please be aware that **WINSPERT HOT NOTES ARE COPYRIGHTED CONTENT. Unauthorized use, including screenshots, copying, misuse, reuse, or resale of any content from this app, is strictly prohibited.**

**Our app monitors and records all screenshots and recordings. Violators will face strict legal action.**

We're committed to providing you with the best tools for your success, and we appreciate your cooperation in maintaining a fair and secure learning environment.

Thank you for your understanding and continued dedication.

Best regards,  
WINSPERT TEAM

# **RADIOLOGY**

## **H.O.T TOPICS**

- 1. Anatomical landmarks on Radiographs**
- 2. OPG errors**
- 3. Bitewing and IOPA errors**
- 4. Dental Caries Radiology**
- 5. Periodontitis Radiology**
- 6. Periapical Lesions**
- 7. Jaw cysts, Tumors, Radiolucent lesions**

# ANATOMICAL LANDMARKS ON RADIOGRAPHS

(Source- Oral radiology (White and Pharoah radiology) , Langlais)

## 1) TEETH

- Teeth are composed primarily of dentin, with an enamel cap over the coronal portion and a thin layer of cementum over the root surface.
- The enamel cap characteristically appears more radiopaque than the other tissues because it is the most dense, naturally occurring substance in the body. Its radiographic appearance is uniformly opaque and without evidence of the fine structure.
- Dentin is smooth and homogeneous on radiographs because of its uniform morphologic features. The junction between enamel and dentin appears as a distinct interface that separates these two structures.
- The thin layer of cementum on the root surface has a mineral content (50%) comparable to that of dentin. Cementum is not usually apparent radiographically because the contrast between it and dentin is so low and the cementum layer is so thin.
- The pulp of normal teeth is composed of soft tissue and consequently appears radiolucent.

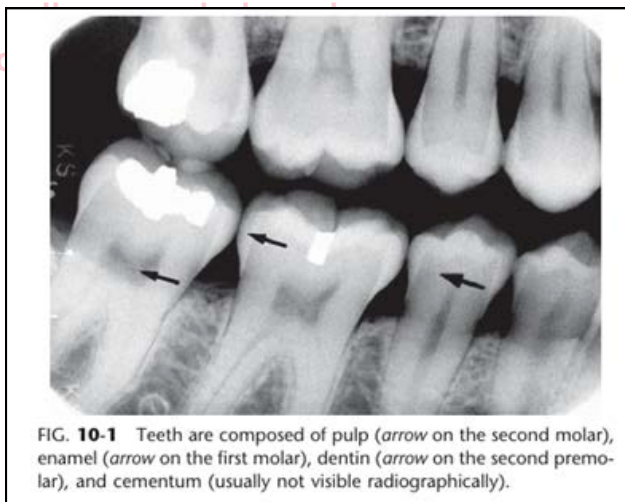


FIG. 10-1 Teeth are composed of pulp (arrow on the second molar), enamel (arrow on the first molar), dentin (arrow on the second premolar), and cementum (usually not visible radiographically).

### \*Cervical burnout

- Diffuse radiolucent areas with ill-defined borders may be apparent radiographically on the mesial or distal aspects of teeth in the cervical regions between the edge of the enamel cap and the crest of the alveolar ridge.
- This phenomenon, called **cervical burnout**, is caused by the normal configuration of the affected teeth, which results in decreased x-ray absorption in the areas in question. **Close inspection will reveal intact edges of the proximal surfaces.**
- They are also usually present in almost all the teeth as the perception of these radiolucent areas results from the contrast with the adjacent, relatively opaque enamel and alveolar bone.

#### DISCLAIMER

THIS IS COPYRIGHTED CONTENT. Unauthorized use, including screenshots, copying, misuse, reuse, or resale of any content from this app, is strictly prohibited. Our app monitors and records all screenshots and recordings. Violators will face strict legal action.



# ANATOMICAL LANDMARKS ON RADIOGRAPHS

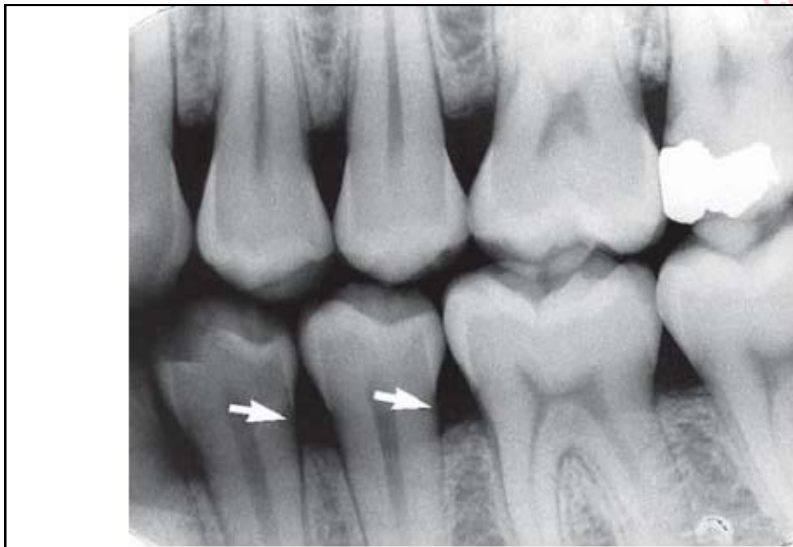


FIG. 10-2 Cervical burnout caused by overexposure of the lateral portion of teeth between the enamel and alveolar crest (arrows).

## Supporting structures in Radiographs:

### 1) Lamina Dura:

- In a radiograph of a normal healthy teeth, we can see a **thin radiopaque layer** of dense bone that bounds the tooth socket.
- This layer is continuous with the shadow of the cortical bone at the alveolar crest.

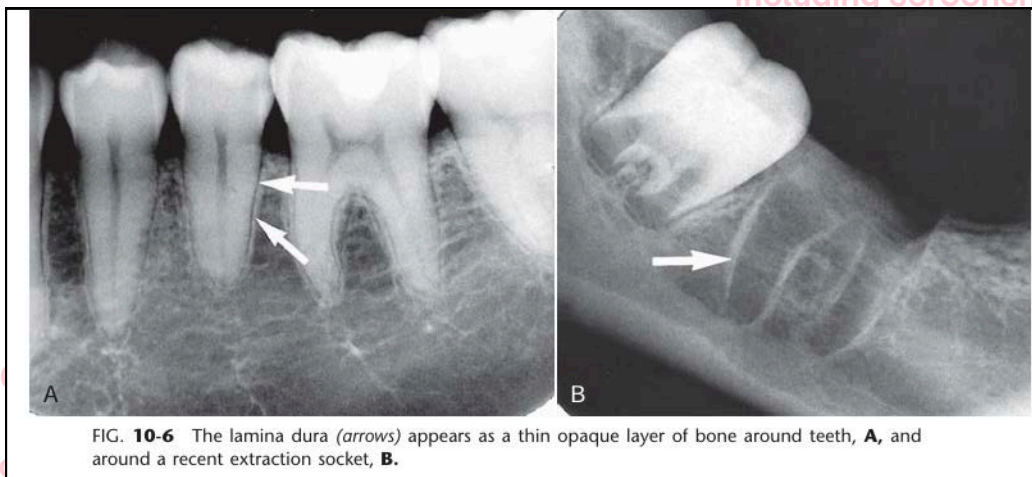


FIG. 10-6 The lamina dura (arrows) appears as a thin opaque layer of bone around teeth, **A**, and around a recent extraction socket, **B**.

- Developmentally the lamina dura is an extension of the lining of the bony crypt that surrounds each tooth during development. The appearance of the lamina dura on radiographs may vary and sometimes may be difficult to track.

### DISCLAIMER

THIS IS COPYRIGHTED CONTENT. Unauthorized use, including screenshots, copying, misuse, reuse, or resale of any content from this app, is strictly prohibited. Our app monitors and records all screenshots and recordings. Violators will face strict legal action.

### DISCLAIMER

THIS IS COPYRIGHTED CONTENT. Unauthorized use, including screenshots, copying, misuse, reuse, or resale of any content from this app, is strictly prohibited. Our app monitors and records all screenshots and recordings. Violators will face strict legal action.

THIS IS COPYRIGHTED CONTENT. Unauthorized use, including screenshots, copying, misuse, reuse, or resale of any content from this app, is strictly prohibited. Our app monitors and records all screenshots and recordings. Violators will face strict legal action.

THIS IS COPYRIGHTED CONTENT. Unauthorized use, including screenshots, copying, misuse, reuse, or resale of any content from this app, is strictly prohibited. Our app monitors and records all screenshots and recordings. Violators will face strict legal action.

THIS IS COPYRIGHTED CONTENT. Unauthorized use, including screenshots, copying, misuse, reuse, or resale of any content from this app, is strictly prohibited. Our app monitors and records all screenshots and recordings. Violators will face strict legal action.

# ANATOMICAL LANDMARKS ON RADIOGRAPHS

## Supporting structures in Radiographs:

### 1) Lamina Dura:

- In a radiograph of a normal healthy teeth, we can see a **thin radiopaque layer** of dense bone that bounds the tooth socket.
- This layer is continuous with the shadow of the cortical bone at the alveolar crest.
- The lamina dura is wider and more dense around the roots of teeth in heavy occlusion and thinner and less dense around teeth not subjected to occlusal function.
- The appearance of the lamina dura is a valuable diagnostic feature. The presence of an intact lamina dura around the apex of a tooth strongly suggests a vital pulp. Because of the variable appearance of the lamina dura, however, the absence of its image around an apex on a radiograph may be normal.

### 2) Alveolar Crest

- The gingival margin of the alveolar process that extends between the teeth is apparent on radiographs as a radiopaque line which is the alveolar crest.

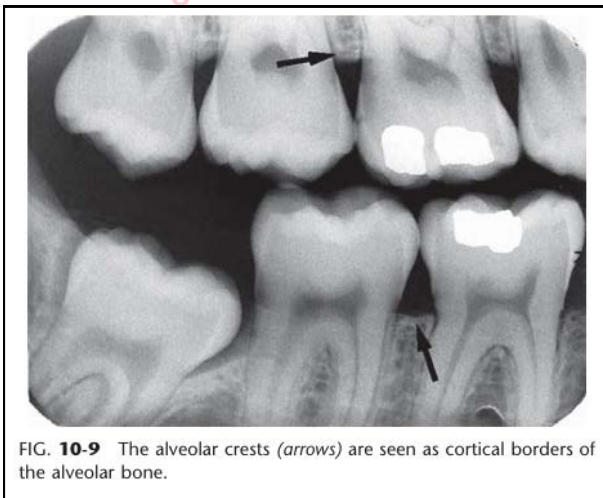


FIG. 10-9 The alveolar crests (arrows) are seen as cortical borders of the alveolar bone.

- The level of this bony crest is considered normal when it is not more than 1.5 mm from the cemento-enamel junction of the adjacent teeth.
- The alveolar crest may recede apically with age and show marked resorption with periodontal disease.

#### DISCLAIMER

THIS IS COPYRIGHTED CONTENT. Unauthorized use, including screenshots, copying, misuse, reuse, or resale of any content from this app, is strictly prohibited. Our app monitors and records all screenshots and recordings. Violators will face strict legal action.

DISCLAIMER  
THIS IS COPYRIGHTED CONTENT. Unauthorized use, including screenshots, copying, misuse, reuse, or resale of any content from this app, is strictly prohibited. Our app monitors and records all screenshots and recordings. Violators will face strict legal action.

DISCLAIMER

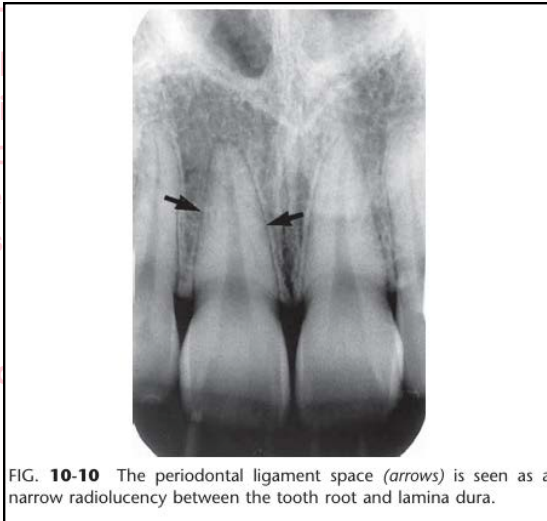
THIS IS COPYRIGHTED CONTENT. Unauthorized use, including screenshots, copying, misuse, reuse, or resale of any content from this app, is strictly prohibited. Our app monitors and records all screenshots and recordings. Violators will face strict legal action.

# ANATOMICAL LANDMARKS ON RADIOGRAPHS

## Supporting structures in Radiographs:

### 3) Periodontal Ligament Space

- The periodontal ligament (PDL) is composed primarily of collagen and it appears as a radiolucent space between the tooth root and the lamina dura.
- This space begins at the alveolar crest, extends around the portions of the tooth roots within the alveolus, and returns to the alveolar crest on the opposite side of the tooth.



- The PDL varies in width from patient to patient, from tooth to tooth in the individual, and even from location to location around one tooth.

THIS IS COPYRIGHTED  
CONTENT. Unauthorized use,  
including screenshots,  
copying, misuse, reuse, or  
resale of any content from  
this app, is strictly prohibited.  
Our app monitors and records  
all screenshots and  
recordings. Violators will face  
strict legal action.

#### DISCLAIMER

THIS IS COPYRIGHTED CONTENT. Unauthorized use, including screenshots, copying, misuse, reuse, or resale of any content from this app, is strictly prohibited. Our app monitors and records all screenshots and recordings. Violators will face strict legal action.

DISCLAIMER  
THIS IS COPYRIGHTED CONTENT. Unauthorized use, including screenshots, copying, misuse, reuse, or resale of any content from this app, is strictly prohibited. Our app monitors and records all screenshots and recordings. Violators will face strict legal action.

THIS IS COPYRIGHTED  
CONTENT. Unauthorized use,  
including screenshots,  
copying, misuse, reuse, or  
resale of any content from  
this app, is strictly prohibited.  
Our app monitors and records  
all screenshots and  
recordings. Violators will face  
strict legal action.

THIS IS COPYRIGHTED  
CONTENT. Unauthorized use,  
including screenshots,  
copying, misuse, reuse, or  
resale of any content from  
this app, is strictly prohibited.  
Our app monitors and records  
all screenshots and  
recordings. Violators will face  
strict legal action.

DISCLAIMER  
THIS IS COPYRIGHTED CONTENT. Unauthorized use, including screenshots, copying, misuse, reuse, or resale of any content from this app, is strictly prohibited. Our app monitors and records all screenshots and recordings. Violators will face strict legal action.

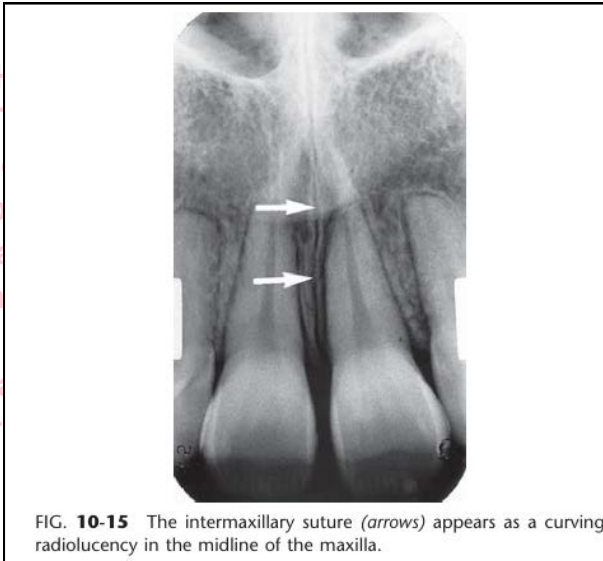
# ANATOMICAL LANDMARKS ON RADIOGRAPHS

## Normal anatomical variants:

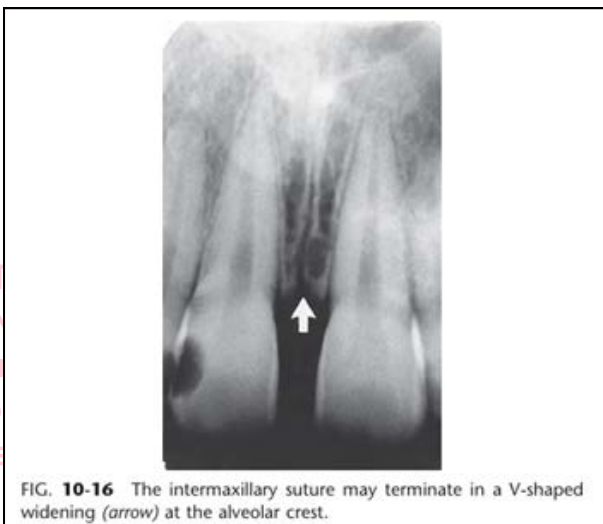
### A) Maxilla:

#### a) Intermaxillary Suture:

- The intermaxillary suture (also called the median suture) appears on intraoral periapical radiographs as a thin radiolucent line in the midline between the two portions of the premaxilla.



- This narrow radiolucent suture can terminate at the alveolar crest in a small rounded or V-shaped enlargement.



#### DISCLAIMER

THIS IS COPYRIGHTED CONTENT. Unauthorized use, including screenshots, copying, misuse, reuse, or resale of any content from this app, is strictly prohibited. Our app monitors and records all screenshots and recordings. Violators will face strict legal action.

#### DISCLAIMER

THIS IS COPYRIGHTED CONTENT. Unauthorized use, including screenshots, copying, misuse, reuse, or resale of any content from this app, is strictly prohibited. Our app monitors and records all screenshots and recordings. Violators will face strict legal action.

THIS IS COPYRIGHTED CONTENT. Unauthorized use, including screenshots, copying, misuse, reuse, or resale of any content from this app, is strictly prohibited. Our app monitors and records all screenshots and recordings. Violators will face strict legal action.

THIS IS COPYRIGHTED CONTENT. Unauthorized use, including screenshots, copying, misuse, reuse, or resale of any content from this app, is strictly prohibited. Our app monitors and records all screenshots and recordings. Violators will face strict legal action.

THIS IS COPYRIGHTED CONTENT. Unauthorized use, including screenshots, copying, misuse, reuse, or resale of any content from this app, is strictly prohibited. Our app monitors and records all screenshots and recordings. Violators will face strict legal action.

THIS IS COPYRIGHTED CONTENT. Unauthorized use, including screenshots, copying, misuse, reuse, or resale of any content from this app, is strictly prohibited. Our app monitors and records all screenshots and recordings. Violators will face strict legal action.

THIS IS COPYRIGHTED CONTENT. Unauthorized use, including screenshots, copying, misuse, reuse, or resale of any content from this app, is strictly prohibited. Our app monitors and records all screenshots and recordings. Violators will face strict legal action.

DISCLAIMER



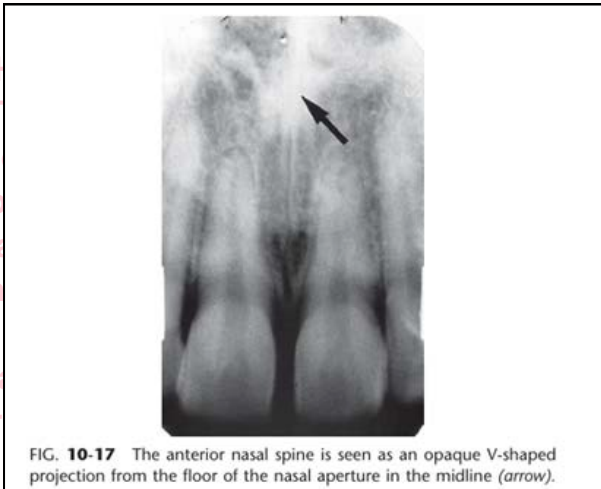
# ANATOMICAL LANDMARKS ON RADIOGRAPHS

## Normal anatomical variants:

### A) Maxilla:

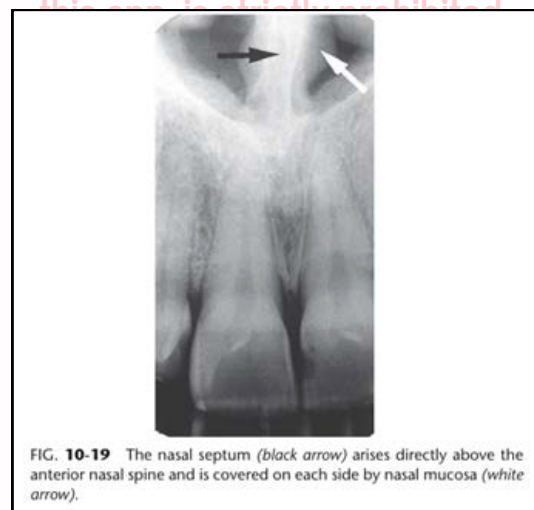
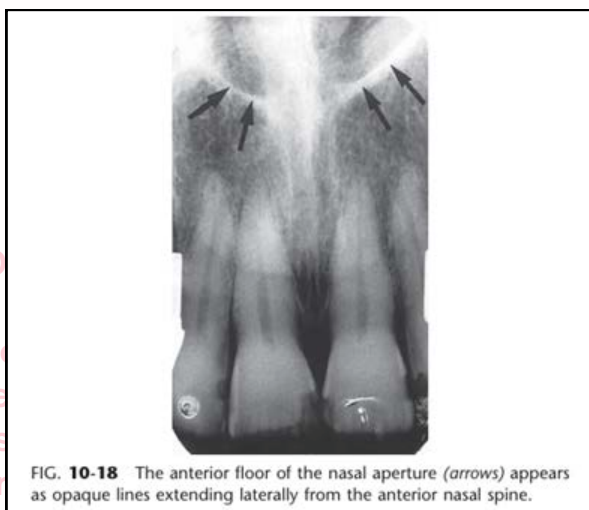
#### b) Anterior Nasal Spine

- The anterior nasal spine is most frequently demonstrated on periapical radiographs of the maxillary central incisors.
- It is radiopaque because of its bony composition and it is usually V shaped.



#### c) Nasal Aperture:

- The air-filled nasal aperture (and cavity) lies just above the oral cavity.
- On periapical radiographs of the incisors the inferior border of the fossa aperture as a radiopaque line extending bilaterally away from the base of the anterior nasal spine is seen.



### DISCLAIMER

THIS IS COPYRIGHTED CONTENT. Unauthorized use, including screenshots, copying, misuse, reuse, or resale of any content from this app, is strictly prohibited. Our app monitors and records all screenshots and recordings. Violators will face strict legal action.

### DISCLAIMER

THIS IS COPYRIGHTED CONTENT. Unauthorized use, including screenshots, copying, misuse, reuse, or resale of any content from this app, is strictly prohibited. Our app monitors and records all screenshots and recordings. Violators will face strict legal action.

THIS IS COPYRIGHTED CONTENT. Unauthorized use, including screenshots, copying, misuse, reuse, or resale of any content from this app, is strictly prohibited. Our app monitors and records all screenshots and recordings. Violators will face strict legal action.

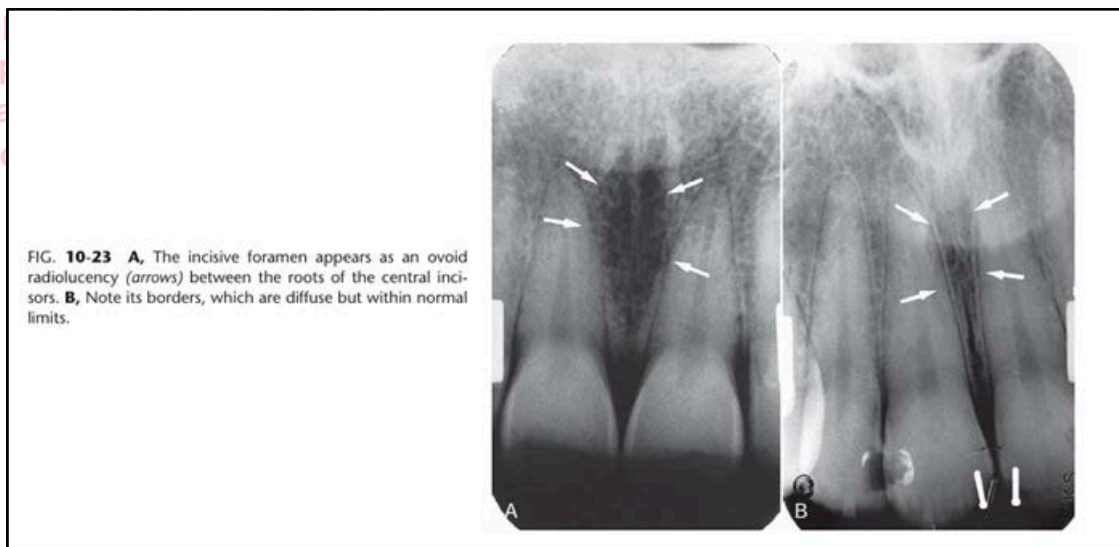
# ANATOMICAL LANDMARKS ON RADIOGRAPHS

## Normal anatomical variants:

### A) Maxilla:

#### d) Incisive Foramen

- The incisive foramen (also called the nasopalatine or anterior palatine foramen) in the maxilla is the oral terminus of the nasopalatine canal.
- The incisive foramen transmits the nasopalatine vessels and nerves and lies in the midline of the palate behind the central incisors at approximately the junction of the median palatine and incisive sutures.
- Its radiographic image is usually projected between the roots and in the region of the middle and apical thirds of the central incisors.
- The position of the foramen is also variable and may be recognized at the apices of the central incisor roots, near the alveolar crest, anywhere in between, or extending over the entire distance.



- Familiarity with the incisive foramen is important because it is a potential site of cyst formation. An incisive canal cyst is radiographically viewed as enlargement of the foramen and canal. The presence of a cyst is presumed if
  - a) the width of the foramen exceeds 1 cm or
  - b) if enlargement can be demonstrated on successive radiographs.
- Also, if the radiolucency of the normal foramen is projected over the apex of one central incisor, it may suggest a pathologic periapical condition. The absence of disease is indicated by a lack of clinical symptoms and an intact lamina dura around the central incisor in question.

#### DISCLAIMER

THIS IS COPYRIGHTED CONTENT. Unauthorized use, including screenshots, copying, misuse, reuse, or resale of any content from this app, is strictly prohibited. Our app monitors and records all screenshots and recordings. Violators will face strict legal action.

DISCLAIMER  
THIS IS COPYRIGHTED CONTENT. Unauthorized use, including screenshots, copying, misuse, reuse, or resale of any content from this app, is strictly prohibited. Our app monitors and records all screenshots and recordings. Violators will face strict legal action.

THIS IS COPYRIGHTED CONTENT. Unauthorized use, including screenshots, copying, misuse, reuse, or resale of any content from this app, is strictly prohibited. Our app monitors and records all screenshots and recordings. Violators will face strict legal action.

DISCLAIMER



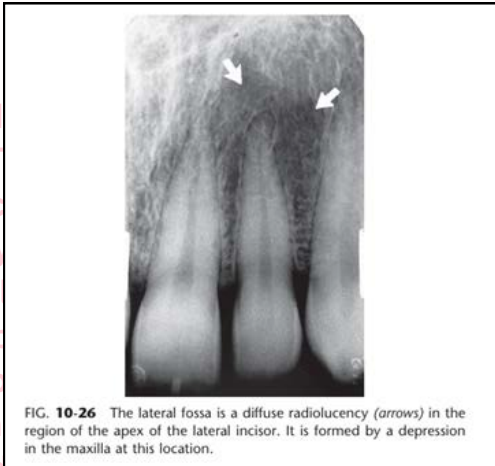
# ANATOMICAL LANDMARKS ON RADIOGRAPHS

## Normal anatomical variants:

### A) Maxilla:

#### e) Lateral Fossa

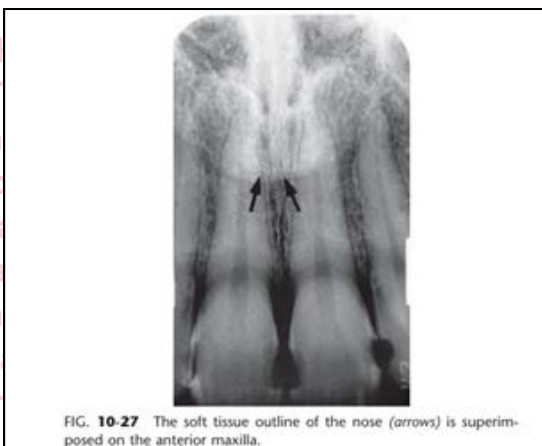
- The lateral fossa (also called incisive fossa) is a gentle depression in the maxilla near the apex of the lateral incisor.



- On periapical projections of this region, it may appear diffusely radiolucent.
- It can be distinguished from a pathological condition, if the radiograph is examined for an intact lamina dura around the root of the lateral incisor. This finding, along with absence of clinical symptoms, suggests normalcy of the bone.

#### f) Nose

- The soft tissue of the tip of the nose is frequently seen in projections of the maxillary central and lateral incisors, superimposed over the roots of these teeth.
- The image of the nose has a uniform, slightly opaque appearance with a sharp border.



## DISCLAIMER

THIS IS COPYRIGHTED CONTENT. Unauthorized use, including screenshots, copying, misuse, reuse, or resale of any content from this app, is strictly prohibited. Our app monitors and records all screenshots and recordings. Violators will face strict legal action.

## DISCLAIMER

THIS IS COPYRIGHTED CONTENT. Unauthorized use, including screenshots, copying, misuse, reuse, or resale of any content from this app, is strictly prohibited. Our app monitors and records all screenshots and recordings. Violators will face strict legal action.

THIS IS COPYRIGHTED CONTENT. Unauthorized use, including screenshots, copying, misuse, reuse, or resale of any content from this app, is strictly prohibited. Our app monitors and records all screenshots and recordings. Violators will face strict legal action.

## DISCLAIMER

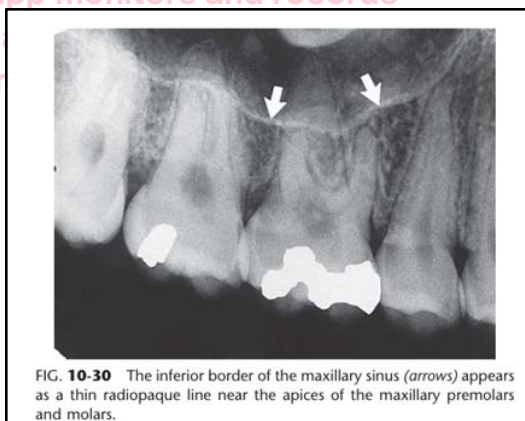
# ANATOMICAL LANDMARKS ON RADIOGRAPHS

## Normal anatomical variants:

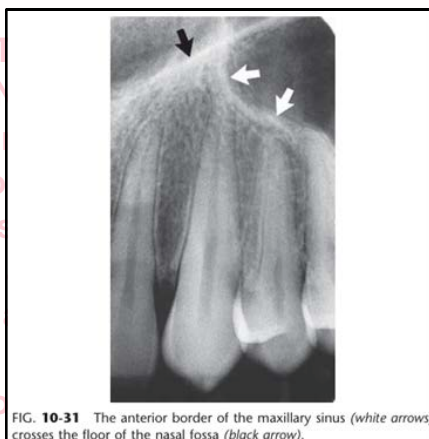
### A) Maxilla:

#### g) Maxillary Sinus

- The maxillary sinus, is an air containing cavity lined with mucous membrane.
- It is the largest of the paranasal sinuses, and it normally occupies virtually the entire body of the maxilla. Its function is unknown.
- The sinus can be considered as three-sided pyramid, with its base the medial wall adjacent to the nasal cavity and its apex extending laterally into the zygomatic process of the maxilla.
- Its three sides are
  - i. the superior wall forming the floor of the orbit,
  - ii. the anterior wall extending above the premolars,
  - iii. the posterior wall bulging above the molar teeth and maxillary tuberosity.
- The borders of the maxillary sinus appear on periapical radiographs as a thin, delicate, tenuous radiopaque line (actually a thin layer of cortical bone).



- Consequently, on periapical radiographs of the canine, the floors of the sinus and nasal cavity are often super imposed and may be seen crossing one another, forming an **inverted Y** in the area.



#### DISCLAIMER

THIS IS COPYRIGHTED CONTENT. Unauthorized use, including screenshots, copying, misuse, reuse, or resale of any content from this app, is strictly prohibited. Our app monitors and records all screenshots and recordings. Violators will face strict legal action.

DISCLAIMER  
THIS IS COPYRIGHTED CONTENT. Unauthorized use, including screenshots, copying, misuse, reuse, or resale of any content from this app, is strictly prohibited. Our app monitors and records all screenshots and recordings. Violators will face strict legal action.

THIS IS COPYRIGHTED CONTENT. Unauthorized use, including screenshots, copying, misuse, reuse, or resale of any content from this app, is strictly prohibited. Our app monitors and records all screenshots and recordings. Violators will face strict legal action.

DISCLAIMER

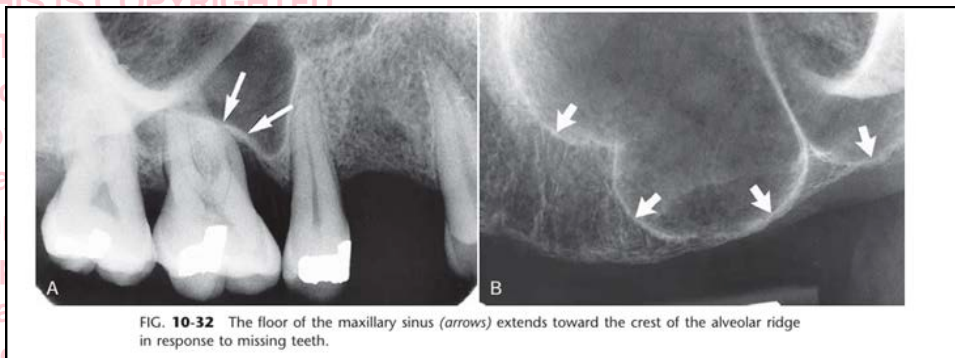
# ANATOMICAL LANDMARKS ON RADIOGRAPHS

## Normal anatomical variants:

### A) Maxilla:

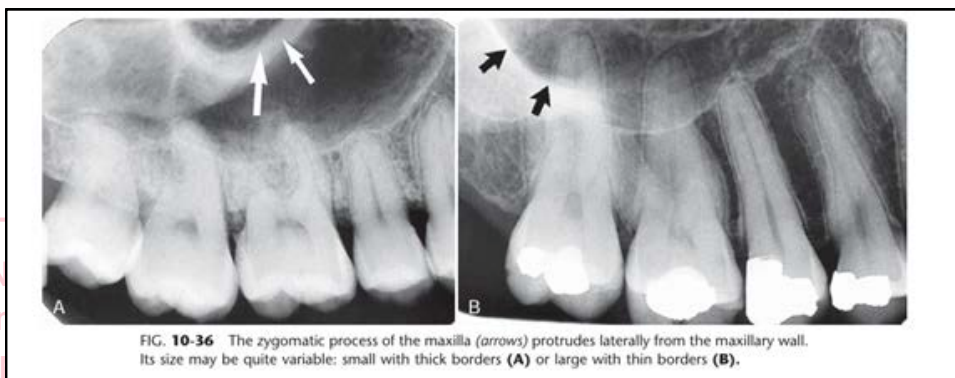
#### g) Maxillary Sinus

- The degree of extension of the maxillary sinus into the alveolar process is extremely variable.
- In some projections the floor of the sinus will be well above the apices of the posterior teeth and in others it may extend well beyond the apices toward the alveolar ridge (like loss of function due to loss of posterior teeth).



#### h) Zygomatic Process and Zygomatic Bone

- The zygomatic process of the maxilla is an extension of the lateral maxillary surface that arises in the region of the apices of the first and second molars and serves as the articulation for the zygomatic bone.
- On periapical radiographs the **zygomatic process** appears as a U-shaped radiopaque line with its open end directed superiorly. The enclosed rounded end is projected in the apical region of the first and second molars.



### DISCLAIMER

THIS IS COPYRIGHTED CONTENT. Unauthorized use, including screenshots, copying, misuse, reuse, or resale of any content from this app, is strictly prohibited. Our app monitors and records all screenshots and recordings. Violators will face strict legal action.

DISCLAIMER  
THIS IS COPYRIGHTED CONTENT. Unauthorized use, including screenshots, copying, misuse, reuse, or resale of any content from this app, is strictly prohibited. Our app monitors and records all screenshots and recordings. Violators will face strict legal action.

THIS IS COPYRIGHTED CONTENT. Unauthorized use, including screenshots, copying, misuse, reuse, or resale of any content from this app, is strictly prohibited. Our app monitors and records all screenshots and recordings. Violators will face strict legal action.



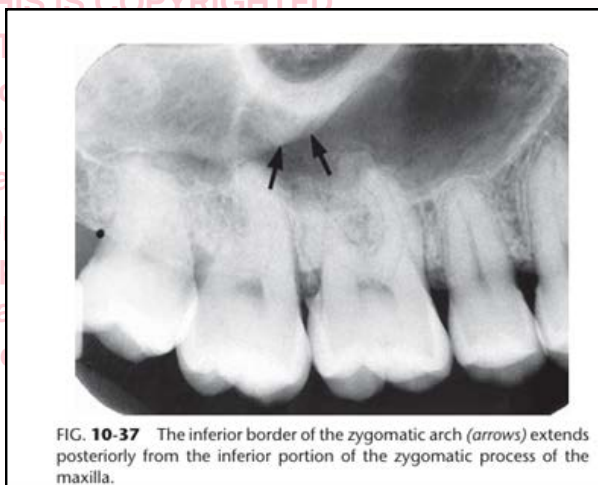
# ANATOMICAL LANDMARKS ON RADIOGRAPHS

## Normal anatomical variants:

### A) Maxilla:

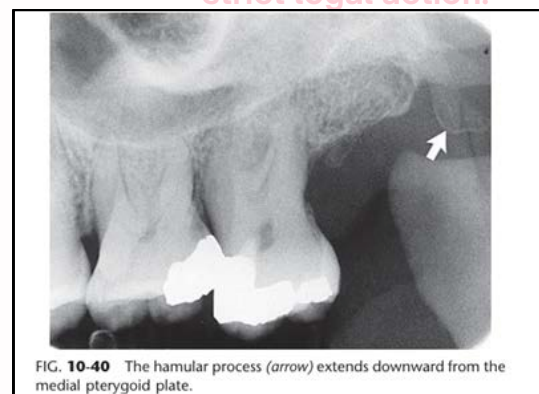
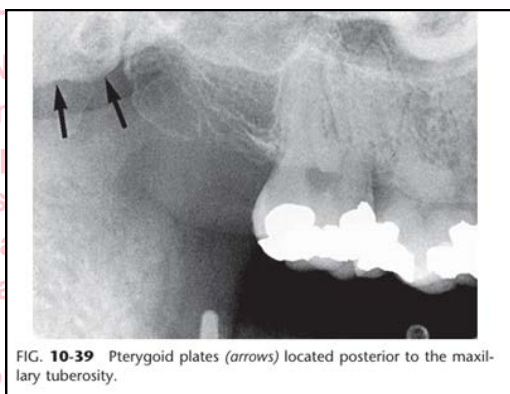
#### h) Zygomatic Process and Zygomatic Bone

- The inferior portion of the zygomatic bone may be seen extending posteriorly from the inferior border of the zygomatic process of the maxilla (thereby completing the zygomatic arch between the zygomatic processes of the maxillary and temporal bones). It can be identified as a uniform gray or white radiopacity over the apices of the molars.



#### i) Pterygoid Plates

- The medial and lateral pterygoid plates lie immediately posterior to the tuberosity of the maxilla.
- The image of these two plates is extremely variable, and on many intraoral radiographs of the third molar area they do not appear at all.
- When they are apparent, they almost always cast a single radiopaque homogeneous shadow without any evidence of trabeculation.
- Extending inferiorly from the medial pterygoid plate is the hamular process, which on close inspection can show trabeculae.



### DISCLAIMER

THIS IS COPYRIGHTED CONTENT. Unauthorized use, including screenshots, copying, misuse, reuse, or resale of any content from this app, is strictly prohibited. Our app monitors and records all screenshots and recordings. Violators will face strict legal action.

DISCLAIMER  
THIS IS COPYRIGHTED CONTENT. Unauthorized use, including screenshots, copying, misuse, reuse, or resale of any content from this app, is strictly prohibited. Our app monitors and records all screenshots and recordings. Violators will face strict legal action.

THIS IS COPYRIGHTED CONTENT. Unauthorized use, including screenshots, copying, misuse, reuse, or resale of any content from this app, is strictly prohibited. Our app monitors and records all screenshots and recordings. Violators will face strict legal action.

DISCLAIMER

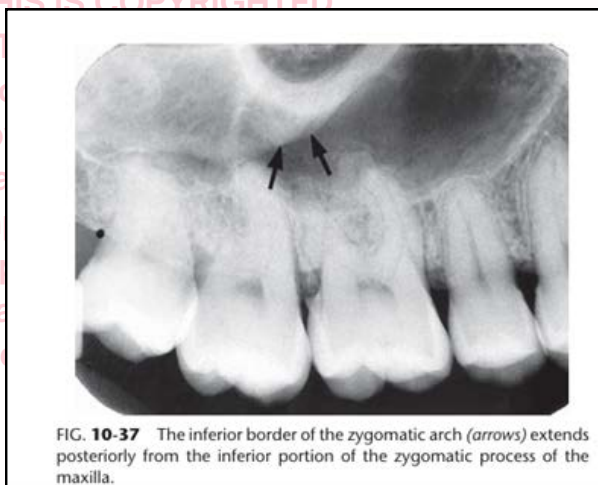
# ANATOMICAL LANDMARKS ON RADIOGRAPHS

## Normal anatomical variants:

### A) Maxilla:

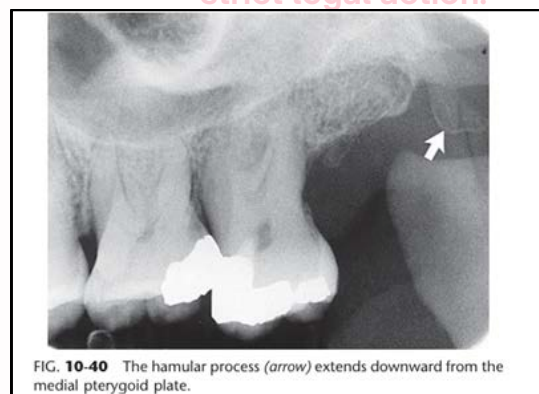
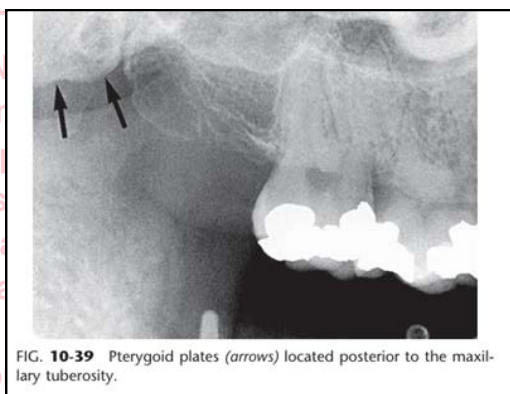
#### h) Zygomatic Process and Zygomatic Bone

- The inferior portion of the zygomatic bone may be seen extending posteriorly from the inferior border of the zygomatic process of the maxilla (thereby completing the zygomatic arch between the zygomatic processes of the maxillary and temporal bones). It can be identified as a uniform gray or white radiopacity over the apices of the molars.



#### i) Pterygoid Plates

- The medial and lateral pterygoid plates lie immediately posterior to the tuberosity of the maxilla.
- The image of these two plates is extremely variable, and on many intraoral radiographs of the third molar area they do not appear at all.
- When they are apparent, they almost always cast a single radiopaque homogeneous shadow without any evidence of trabeculation.
- Extending inferiorly from the medial pterygoid plate is the hamular process, which on close inspection can show trabeculae.



### DISCLAIMER

THIS IS COPYRIGHTED CONTENT. Unauthorized use, including screenshots, copying, misuse, reuse, or resale of any content from this app, is strictly prohibited. Our app monitors and records all screenshots and recordings. Violators will face strict legal action.

DISCLAIMER  
THIS IS COPYRIGHTED CONTENT. Unauthorized use, including screenshots, copying, misuse, reuse, or resale of any content from this app, is strictly prohibited. Our app monitors and records all screenshots and recordings. Violators will face strict legal action.

THIS IS COPYRIGHTED CONTENT. Unauthorized use, including screenshots, copying, misuse, reuse, or resale of any content from this app, is strictly prohibited. Our app monitors and records all screenshots and recordings. Violators will face strict legal action.

DISCLAIMER

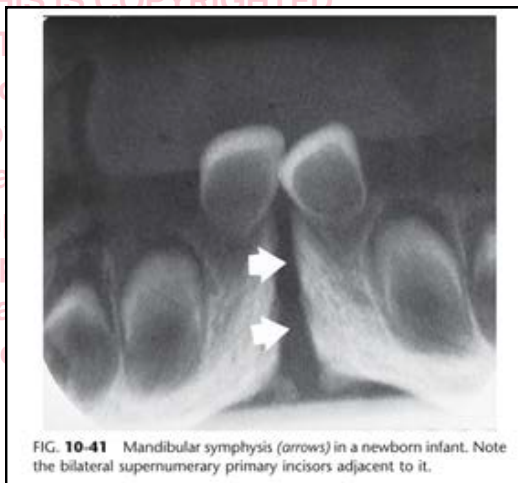# ANATOMICAL LANDMARKS ON RADIOGRAPHS

## Normal anatomical variants:

### B) Mandible

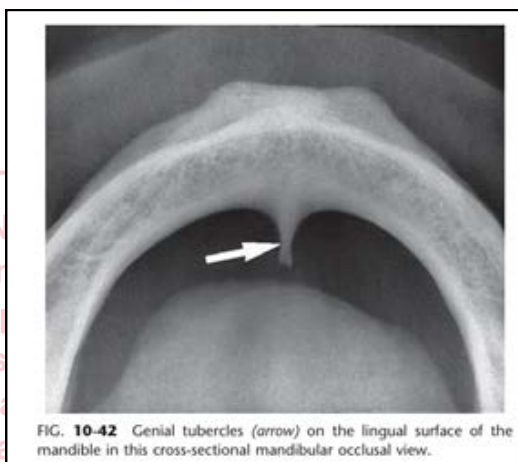
#### a) Symphysis

- Radiographs of the region of the mandibular symphysis in infants demonstrate a radiolucent line through the midline of the jaw between the images of the forming deciduous central incisors.
- This suture usually fuses by the end of the first year of life, after which it is no longer radiographically apparent.



#### b) Genial Tubercles

- The genial tubercles (also called the mental spine) are located on the lingual surface of the mandible slightly above the inferior border and in the midline.
- They are well visualized on mandibular occlusal radiographs as one or more small projections.



### DISCLAIMER

THIS IS COPYRIGHTED CONTENT. Unauthorized use, including screenshots, copying, misuse, reuse, or resale of any content from this app, is strictly prohibited. Our app monitors and records all screenshots and recordings. Violators will face strict legal action.

DISCLAIMER  
THIS IS COPYRIGHTED CONTENT. Unauthorized use, including screenshots, copying, misuse, reuse, or resale of any content from this app, is strictly prohibited. Our app monitors and records all screenshots and recordings. Violators will face strict legal action.

THIS IS COPYRIGHTED CONTENT. Unauthorized use, including screenshots, copying, misuse, reuse, or resale of any content from this app, is strictly prohibited. Our app monitors and records all screenshots and recordings. Violators will face strict legal action.



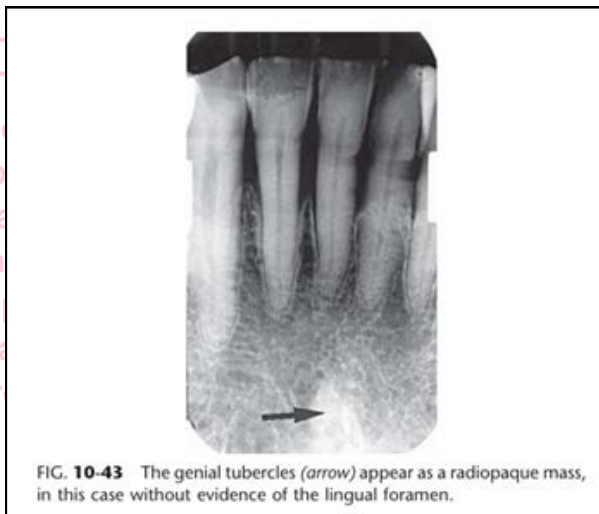
# ANATOMICAL LANDMARKS ON RADIOGRAPHS

## Normal anatomical variants:

### B) Mandible

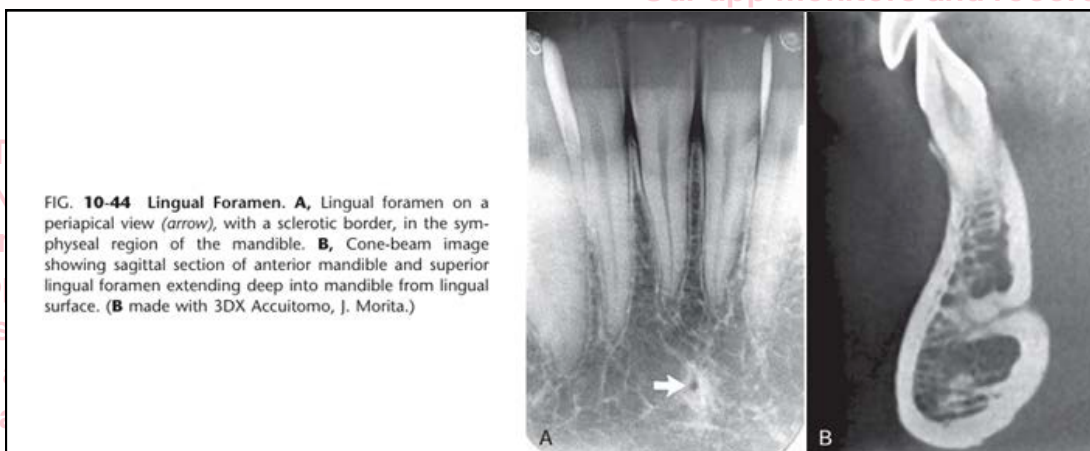
#### b) Genial Tubercles

- Their appearance on periapical radiographs of the mandibular incisor region is variable: often they appear as a radiopaque mass (up to 3 to 4 mm in diameter) in the midline below the incisor roots. They also may not be apparent at all.



#### c) Lingual Foramen

- There is usually a foramen on the lingual surface of the midline of the mandible in the region of the genial tubercles.
- The lingual foramen is typically visualized as a single round radiolucent canal with a well-defined opaque border lying in the midline below the level of the apices of the incisors.



### DISCLAIMER

THIS IS COPYRIGHTED CONTENT. Unauthorized use, including screenshots, copying, misuse, reuse, or resale of any content from this app, is strictly prohibited. Our app monitors and records all screenshots and recordings. Violators will face strict legal action.

DISCLAIMER  
THIS IS COPYRIGHTED CONTENT. Unauthorized use, including screenshots, copying, misuse, reuse, or resale of any content from this app, is strictly prohibited. Our app monitors and records all screenshots and recordings. Violators will face strict legal action.

THIS IS COPYRIGHTED CONTENT. Unauthorized use, including screenshots, copying, misuse, reuse, or resale of any content from this app, is strictly prohibited. Our app monitors and records all screenshots and recordings. Violators will face strict legal action.

DISCLAIMER

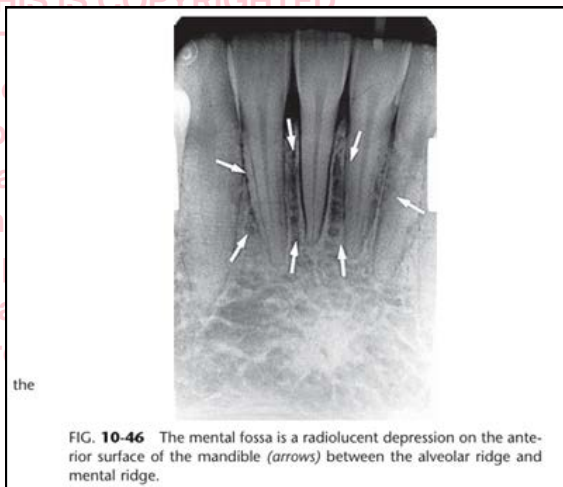
# ANATOMICAL LANDMARKS ON RADIOGRAPHS

## Normal anatomical variants:

### B) Mandible

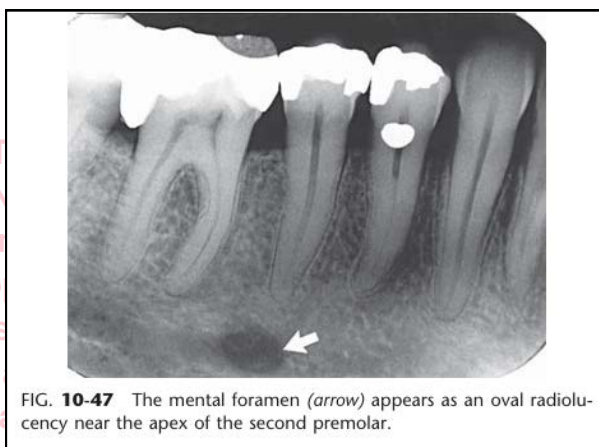
#### d) Mental Fossa

- The mental fossa is a depression on the labial aspect of the mandible extending laterally from the midline and above the mental ridge.
- Because of the resulting thinness of jawbone in this area, the image of this depression may be similar to that of the submandibular fossa and may also be mistaken for periapical disease involving the incisors.



#### e) Mental Foramen

- The mental foramen is usually the anterior limit of the inferior dental canal that is apparent on periapical radiographs.
- Its image is quite variable, and it may be identified only about half the time because the opening of the mental canal is directed superiorly and posteriorly.



### DISCLAIMER

THIS IS COPYRIGHTED CONTENT. Unauthorized use, including screenshots, copying, misuse, reuse, or resale of any content from this app, is strictly prohibited. Our app monitors and records all screenshots and recordings. Violators will face strict legal action.

DISCLAIMER  
THIS IS COPYRIGHTED CONTENT. Unauthorized use, including screenshots, copying, misuse, reuse, or resale of any content from this app, is strictly prohibited. Our app monitors and records all screenshots and recordings. Violators will face strict legal action.

THIS IS COPYRIGHTED CONTENT. Unauthorized use, including screenshots, copying, misuse, reuse, or resale of any content from this app, is strictly prohibited. Our app monitors and records all screenshots and recordings. Violators will face strict legal action.

DISCLAIMER

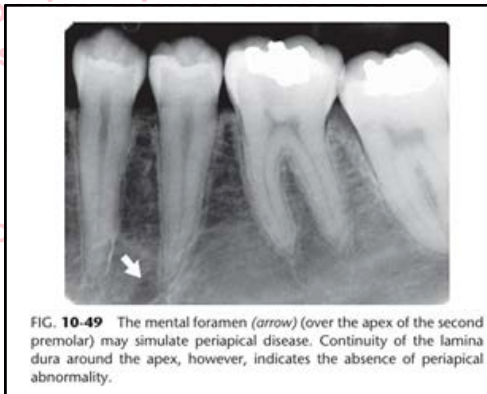
# ANATOMICAL LANDMARKS ON RADIOGRAPHS

## Normal anatomical variants:

### B) Mandible

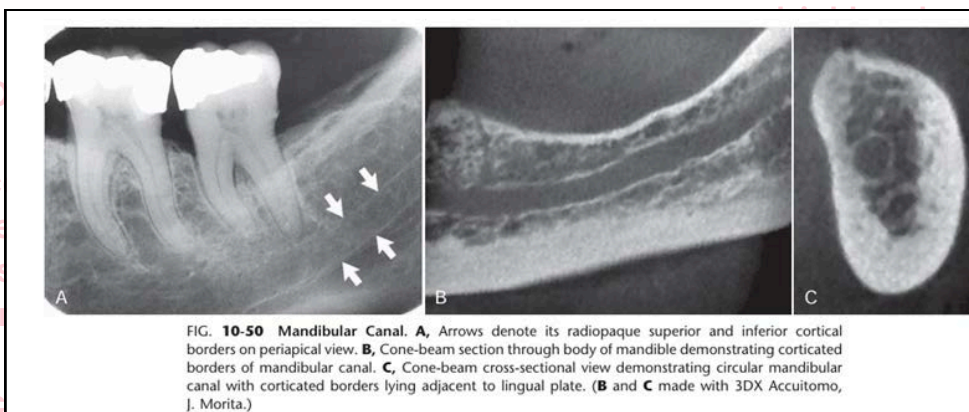
#### e) Mental Foramen

- When the mental foramen is projected over one of the premolar apices, it may mimic periapical disease. In such cases, evidence of the inferior dental canal extending to the suspect radiolucency or a detectable lamina dura in the area would suggest the true nature of the dark shadow.
- Sometimes the lamina dura might be superimposed with radiolucency which can complicate its recognition but a second radiograph from another angle is likely to show the lamina dura clearly, as well as some shift in position of the radiolucent foramen relative to the apex.



#### f) Mandibular Canal

- The radiographic image of the mandibular canal is a dark linear shadow with thin radiopaque superior and inferior borders cast by the lamella of bone that bounds the canal.
- Sometimes the borders are seen only partially or not at all. The width of the canal shows some interpatient variability but is usually rather constant anterior to the third molar region.



strict legal action.

#### DISCLAIMER

THIS IS COPYRIGHTED CONTENT. Unauthorized use, including screenshots, copying, misuse, reuse, or resale of any content from this app, is strictly prohibited. Our app monitors and records all screenshots and recordings. Violators will face strict legal action.

DISCLAIMER  
THIS IS COPYRIGHTED CONTENT. Unauthorized use, including screenshots, copying, misuse, reuse, or resale of any content from this app, is strictly prohibited. Our app monitors and records all screenshots and recordings. Violators will face strict legal action.

THIS IS COPYRIGHTED CONTENT. Unauthorized use, including screenshots, copying, misuse, reuse, or resale of any content from this app, is strictly prohibited. Our app monitors and records all screenshots and recordings. Violators will face strict legal action.

DISCLAIMER



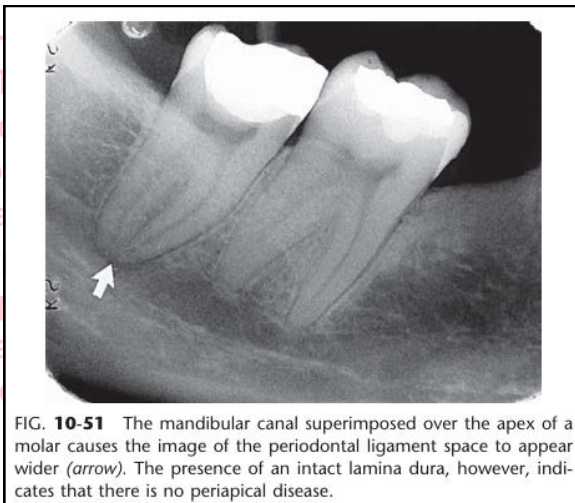
# ANATOMICAL LANDMARKS ON RADIOGRAPHS

## Normal anatomical variants:

### B) Mandible

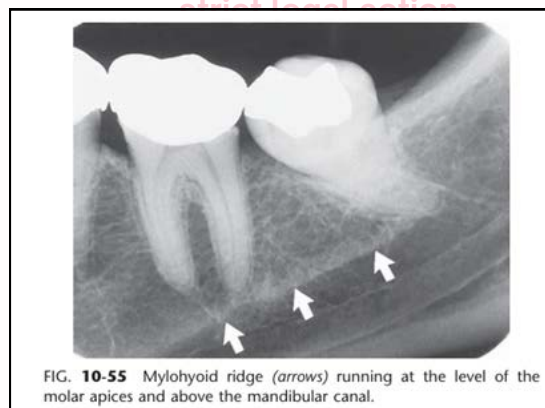
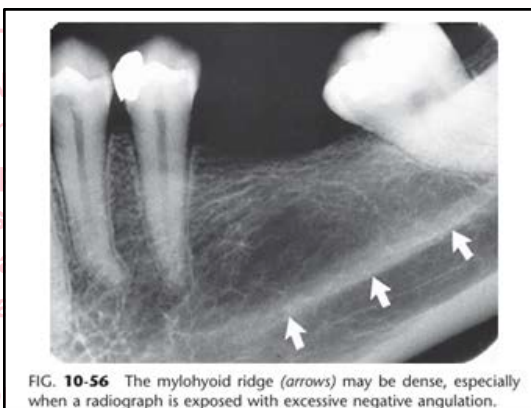
#### f) Mandibular Canal

- When the apices of the molars are projected over the canal, the lamina dura may be overexposed, conveying the impression of a missing lamina or a thickened PDL space that is more radiolucent than apparently normal for the patient.



#### g) Mylohyoid Ridge

- The mylohyoid ridge is a slightly irregular crest of bone on the lingual surface of the mandibular body.
- Extending from the area of the third molars to the lower border of the mandible in the region of the chin, it serves as an attachment for the mylohyoid muscle.
- Its radiographic image runs diagonally downward and forward from the area of the third molars to the premolar region, at approximately the level of the apices of the posterior teeth.



### DISCLAIMER

THIS IS COPYRIGHTED CONTENT. Unauthorized use, including screenshots, copying, misuse, reuse, or resale of any content from this app, is strictly prohibited. Our app monitors and records all screenshots and recordings. Violators will face strict legal action.

### DISCLAIMER

THIS IS COPYRIGHTED CONTENT. Unauthorized use, including screenshots, copying, misuse, reuse, or resale of any content from this app, is strictly prohibited. Our app monitors and records all screenshots and recordings. Violators will face strict legal action.

THIS IS COPYRIGHTED CONTENT. Unauthorized use, including screenshots, copying, misuse, reuse, or resale of any content from this app, is strictly prohibited. Our app monitors and records all screenshots and recordings. Violators will face strict legal action.

# ANATOMICAL LANDMARKS ON RADIOGRAPHS

## Normal anatomical variants:

### B) Mandible

#### h) Submandibular Gland Fossa

- On the lingual surface of the mandibular body, immediately below the mylohyoid ridge in the molar area, there is frequently a depression in the bone.
- This concavity accommodates the submandibular gland and often appears as a radiolucent area with the sparse trabecular pattern characteristic of the region.

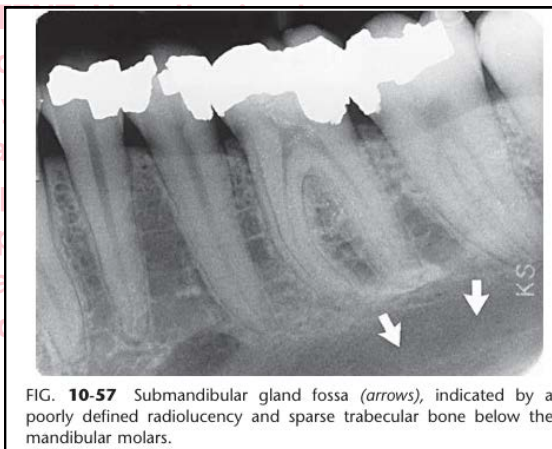


FIG. 10-57 Submandibular gland fossa (arrows), indicated by a poorly defined radiolucency and sparse trabecular bone below the mandibular molars.

#### i) External Oblique Ridge

- The external oblique ridge is a continuation of the anterior border of the mandibular ramus.
- It appears as a radiopaque line of varying width, density, and length, blending at its anterior end with the shadow of the alveolar bone.

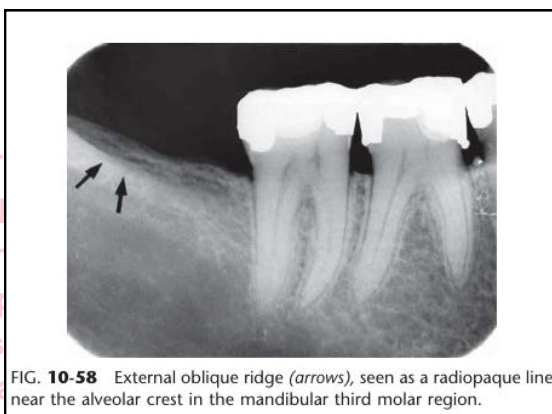


FIG. 10-58 External oblique ridge (arrows), seen as a radiopaque line near the alveolar crest in the mandibular third molar region.

### DISCLAIMER

THIS IS COPYRIGHTED CONTENT. Unauthorized use, including screenshots, copying, misuse, reuse, or resale of any content from this app, is strictly prohibited. Our app monitors and records all screenshots and recordings. Violators will face strict legal action.

DISCLAIMER  
THIS IS COPYRIGHTED CONTENT. Unauthorized use, including screenshots, copying, misuse, reuse, or resale of any content from this app, is strictly prohibited. Our app monitors and records all screenshots and recordings. Violators will face strict legal action.

THIS IS COPYRIGHTED CONTENT. Unauthorized use, including screenshots, copying, misuse, reuse, or resale of any content from this app, is strictly prohibited. Our app monitors and records all screenshots and recordings. Violators will face strict legal action.

DISCLAIMER

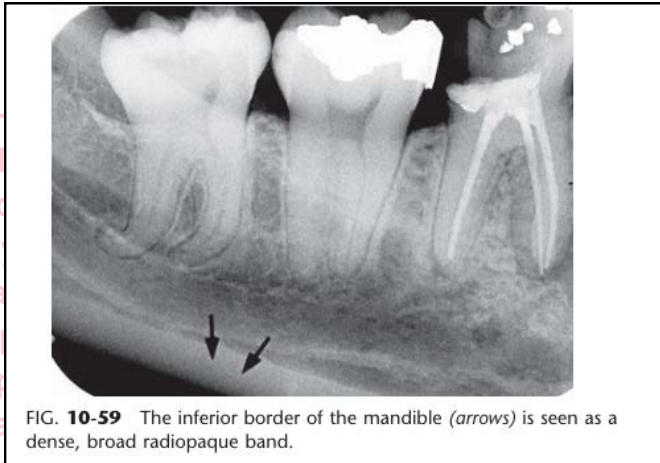
# ANATOMICAL LANDMARKS ON RADIOGRAPHS

## Normal anatomical variants:

### B) Mandible

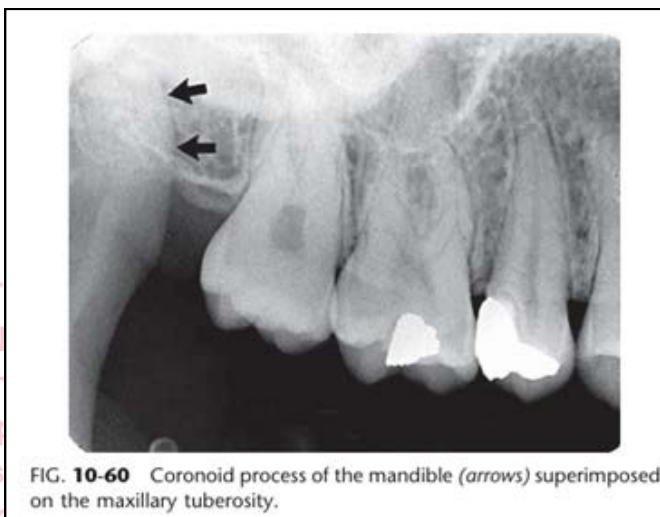
#### j) Inferior Border of the Mandible

- Occasionally the inferior mandibular border will be seen on periapical projections as a characteristically dense, broad radiopaque band of bone.



#### k) Coronoid Process:

- The image of the coronoid process of the mandible is frequently apparent on periapical radiographs of the maxillary molar region as a triangular radiopacity, with its apex directed superiorly and somewhat anteriorly, superimposed on the region of the third molar.



### DISCLAIMER

THIS IS COPYRIGHTED CONTENT. Unauthorized use, including screenshots, copying, misuse, reuse, or resale of any content from this app, is strictly prohibited. Our app monitors and records all screenshots and recordings. Violators will face strict legal action.

DISCLAIMER  
THIS IS COPYRIGHTED CONTENT. Unauthorized use, including screenshots, copying, misuse, reuse, or resale of any content from this app, is strictly prohibited. Our app monitors and records all screenshots and recordings. Violators will face strict legal action.

DISCLAIMER  
THIS IS COPYRIGHTED CONTENT. Unauthorized use, including screenshots, copying, misuse, reuse, or resale of any content from this app, is strictly prohibited. Our app monitors and records all screenshots and recordings. Violators will face strict legal action.



# ANATOMICAL LANDMARKS ON RADIOGRAPHS

## Restorative materials on Radiographs:

- Restorative materials vary in their radiographic appearance.
- A variety of restorative materials may be recognized on intraoral radiographs.
- The most common, **silver amalgam**, is completely radiopaque.

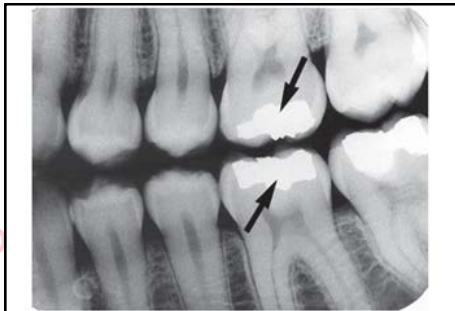


FIG. 10-61 Amalgam restorations appear completely radiopaque (arrows).

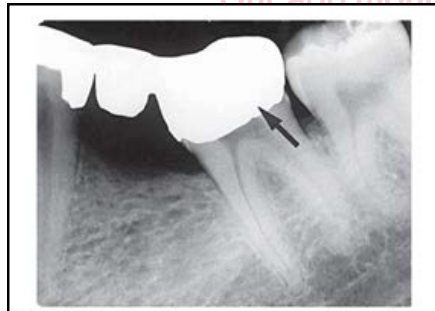


FIG. 10-62 A cast gold crown, appearing completely radiopaque (arrow), serves as the terminal abutment of a bridge.

- **Gold** is equally opaque to x rays, whether cast as a crown or an inlay.
- **Stainless steel pins** also appear radiopaque

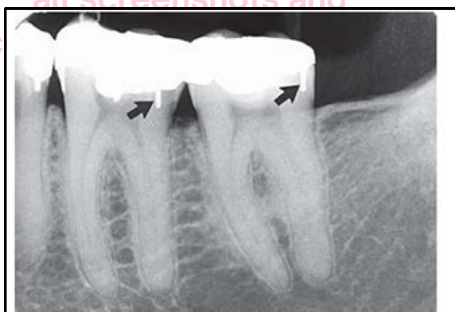

FIG. 10-63 Stainless steel pins (arrows) provide retention for amalgam restorations.

- A calcium hydroxide base is usually placed in a deep cavity to protect the pulp. Although such base material may be radiolucent, most is radiopaque.

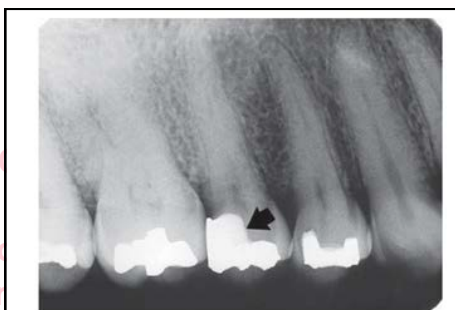

FIG. 10-64 Base material (arrow) is usually radiopaque but less opaque than the amalgam restoration.

DISCLAIMER

THIS IS COPYRIGHTED CONTENT. Unauthorized use, including screenshots, copying, misuse, reuse, or resale of any content from this app, is strictly prohibited. Our app monitors and records all screenshots and recordings. Violators will face strict legal action.

DISCLAIMER

THIS IS COPYRIGHTED CONTENT. Unauthorized use, including screenshots, copying, misuse, reuse, or resale of any content from this app, is strictly prohibited. Our app monitors and records all screenshots and recordings. Violators will face strict legal action.

THIS IS COPYRIGHTED CONTENT. Unauthorized use, including screenshots, copying, misuse, reuse, or resale of any content from this app, is strictly prohibited. Our app monitors and records all screenshots and recordings. Violators will face strict legal action.

DISCLAIMER

# ANATOMICAL LANDMARKS ON RADIOGRAPHS

## Restorative materials on Radiographs:

- Another material of comparable radiopacity is gutta-percha a rubberlike substance used to fill tooth canals during endodontic therapy.

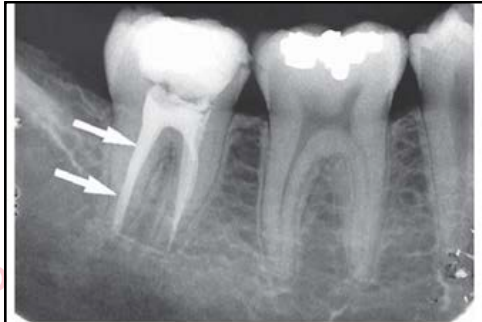


FIG. 10-65 Gutta-percha (arrows) is a radiopaque rubberlike material used in endodontic therapy.

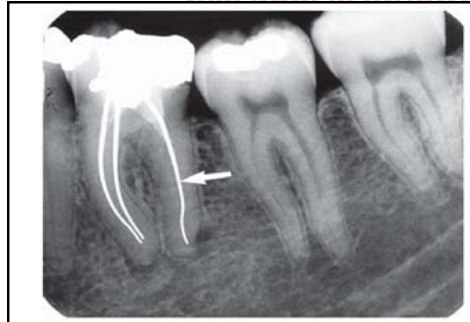


FIG. 10-66 Silver points (arrow) were used to fill the root canal in this patient.

- Silver points were previously used to obliterate canals during endodontic therapy and they appear radiopaque on x-rays.
- Restorative materials that appear rather radiolucent on intraoral films include silicates, usually in combination with a base but now rarely used.

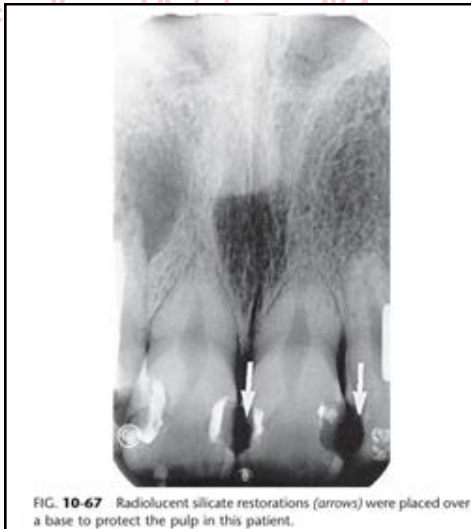


FIG. 10-67 Radiolucent silicate restorations (arrows) were placed over a base to protect the pulp in this patient.

- Composite, usually in anterior teeth appear radiolucent on X- rays. Composite restorative materials may also be opaque. Nowadays, more radiopaque composite is available.

### DISCLAIMER

THIS IS COPYRIGHTED CONTENT. Unauthorized use, including screenshots, copying, misuse, reuse, or resale of any content from this app, is strictly prohibited. Our app monitors and records all screenshots and recordings. Violators will face strict legal action.

DISCLAIMER  
THIS IS COPYRIGHTED CONTENT. Unauthorized use, including screenshots, copying, misuse, reuse, or resale of any content from this app, is strictly prohibited. Our app monitors and records all screenshots and recordings. Violators will face strict legal action.

THIS IS COPYRIGHTED CONTENT. Unauthorized use, including screenshots, copying, misuse, reuse, or resale of any content from this app, is strictly prohibited. Our app monitors and records all screenshots and recordings. Violators will face strict legal action.

THIS IS COPYRIGHTED CONTENT. Unauthorized use, including screenshots, copying, misuse, reuse, or resale of any content from this app, is strictly prohibited. Our app monitors and records all screenshots and recordings. Violators will face strict legal action.

DISCLAIMER  
THIS IS COPYRIGHTED CONTENT. Unauthorized use, including screenshots, copying, misuse, reuse, or resale of any content from this app, is strictly prohibited. Our app monitors and records all screenshots and recordings. Violators will face strict legal action.

# ANATOMICAL LANDMARKS ON RADIOGRAPHS

## Restorative materials on Radiographs:

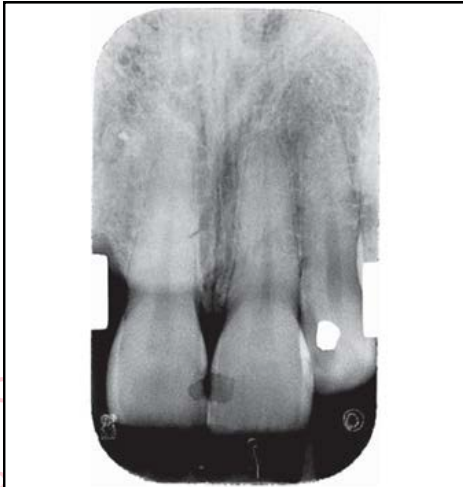


FIG. 10-68 Composite restorations may be radiolucent and may suggest caries but can be recognized by their well-demarcated border with dentin.

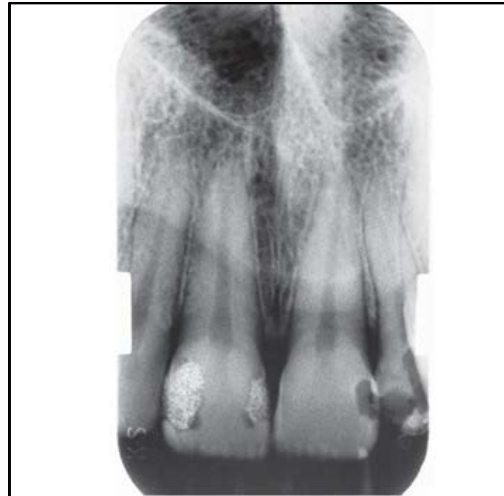

FIG. 10-70 Composite restorations containing particles of barium glass are radiopaque and not likely to be confused with caries.

- Stainless steel crowns and orthodontic appliances around teeth are relatively radiopaque.

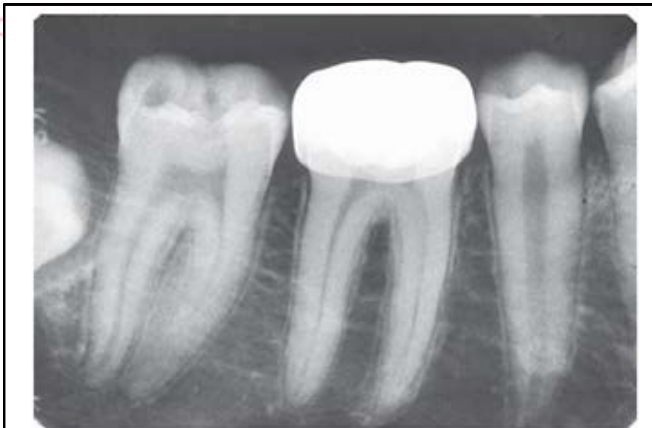

FIG. 10-71 Stainless steel crowns appear mostly radiopaque.

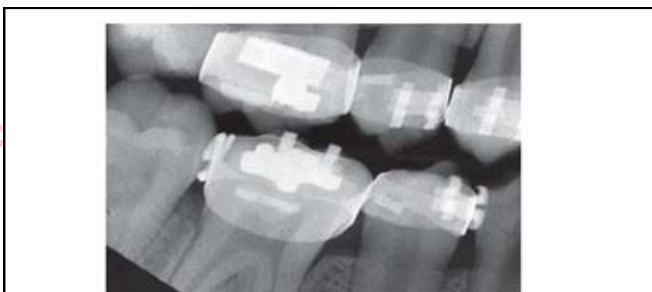


FIG. 10-72 Orthodontic appliances have a characteristic radiopaque appearance.

THIS IS COPYRIGHTED CONTENT. Unauthorized use, including screenshots, copying, misuse, reuse, or resale of any content from this app, is strictly prohibited. Our app monitors and records all screenshots and recordings. Violators will face strict legal action.

### DISCLAIMER

THIS IS COPYRIGHTED CONTENT. Unauthorized use, including screenshots, copying, misuse, reuse, or resale of any content from this app, is strictly prohibited. Our app monitors and records all screenshots and recordings. Violators will face strict legal action.

### DISCLAIMER

THIS IS COPYRIGHTED CONTENT. Unauthorized use, including screenshots, copying, misuse, reuse, or resale of any content from this app, is strictly prohibited. Our app monitors and records all screenshots and recordings. Violators will face strict legal action.

THIS IS COPYRIGHTED CONTENT. Unauthorized use, including screenshots, copying, misuse, reuse, or resale of any content from this app, is strictly prohibited. Our app monitors and records all screenshots and recordings. Violators will face strict legal action.

### DISCLAIMER



# OPG ERRORS

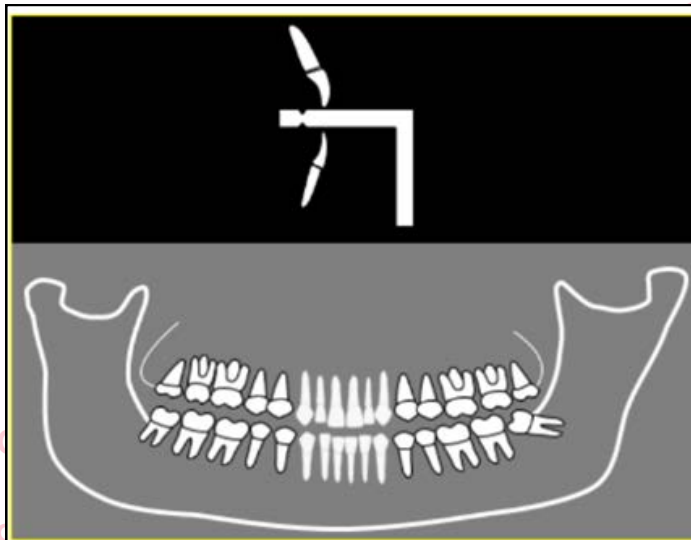
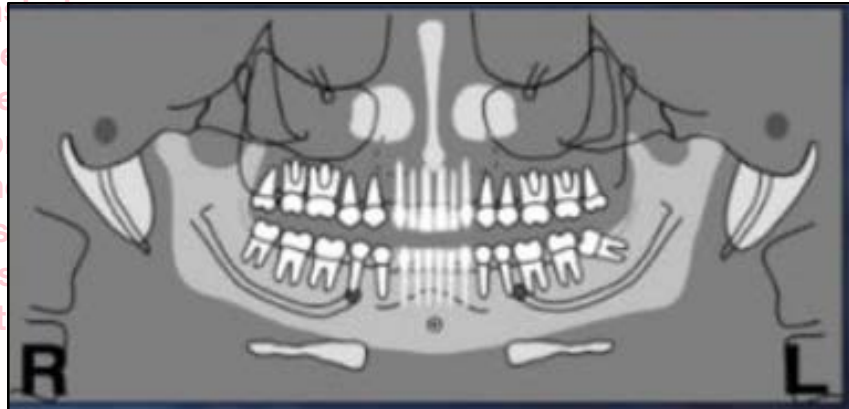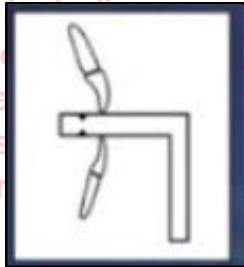(Source: OPG errors in the drive and Panoramic Technique Errors: By Mahmood Al-Fahdawi, Internet)

- A considerable number of radiographs exposed in dentistry are of marginal or nondiagnostic quality.
- The value of a panoramic radiograph is reduced when it is of poor diagnostic quality, due to various **positioning and processing errors**.

## Patient Positioning Errors in OPG

### 1) Teeth too anterior: Patient too far forward (anterior to focal trough)

- If the teeth are positioned in front of the notches in the bite stick like in the image shown below, the anterior teeth will appear narrower and will be blurred (less sharp than normal).



resale of any content from this app, is strictly prohibited. Our app monitors and records all screenshots and recordings. Violators will face strict legal action.

#### DISCLAIMER

THIS IS COPYRIGHTED CONTENT. Unauthorized use, including screenshots, copying, misuse, reuse, or resale of any content from this app, is strictly prohibited. Our app monitors and records all screenshots and recordings. Violators will face strict legal action.

#### DISCLAIMER

THIS IS COPYRIGHTED CONTENT. Unauthorized use, including screenshots, copying, misuse, reuse, or resale of any content from this app, is strictly prohibited. Our app monitors and records all screenshots and recordings. Violators will face strict legal action.

#### DISCLAIMER

THIS IS COPYRIGHTED CONTENT. Unauthorized use, including screenshots, copying, misuse, reuse, or resale of any content from this app, is strictly prohibited. Our app monitors and records all screenshots and recordings. Violators will face strict legal action.

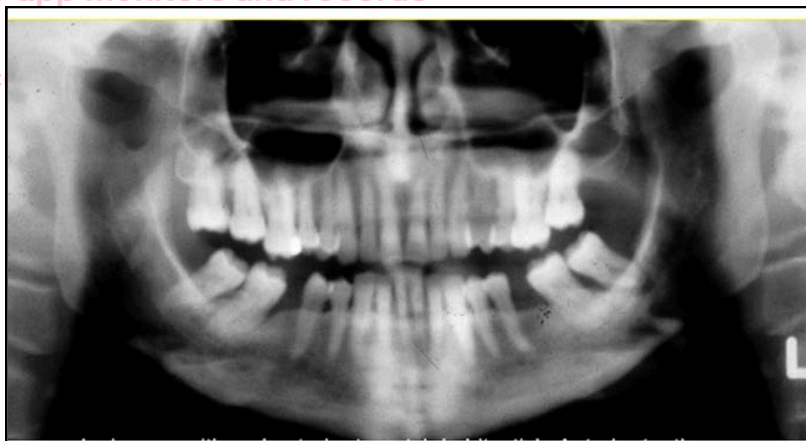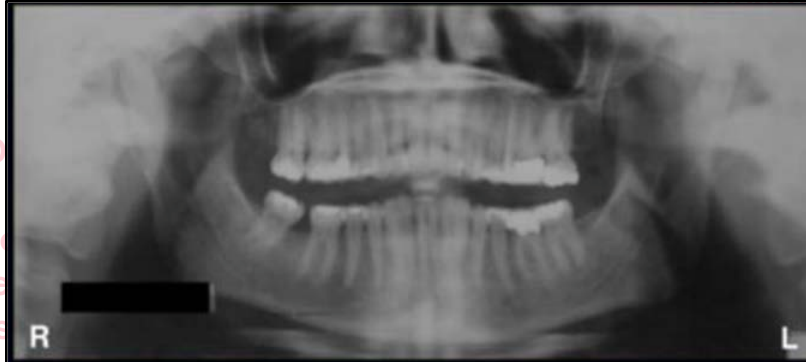# OPG ERRORS

## Patient Positioning Errors in OPG

### 1) Teeth too anterior: Patient too far forward (anterior to focal trough)

#### Reasons

- If the teeth are in front of the notches, then they are closer to the film resulting in less magnification horizontally which leads to narrowing.
- And being out of through makes the images less sharp.



THIS IS COPYRIGHTED  
CONTENT. Unauthorized use,  
including screenshots,  
copying, misuse, reuse, or  
resale of any content from  
this app, is strictly prohibited.  
Our app monitors and records  
all screenshots and  
recordings. Violators will face  
strict legal action.

#### DISCLAIMER

THIS IS COPYRIGHTED CONTENT. Unauthorized use, including screenshots, copying, misuse, reuse, or resale of any content from this app, is strictly prohibited. Our app monitors and records all screenshots and recordings. Violators will face strict legal action.

THIS IS COPYRIGHTED  
CONTENT. Unauthorized use,  
including screenshots,  
copying, misuse, reuse, or  
resale of any content from  
this app, is strictly prohibited.  
Our app monitors and records  
all screenshots and  
recordings. Violators will face  
strict legal action.

THIS IS COPYRIGHTED  
CONTENT. Unauthorized use,  
including screenshots,  
copying, misuse, reuse, or  
resale of any content from  
this app, is strictly prohibited.  
Our app monitors and records  
all screenshots and  
recordings. Violators will face  
strict legal action.

**DISCLAIMER**  
THIS IS COPYRIGHTED CONTENT. Unauthorized use, including screenshots, copying, misuse, reuse, or resale of any content from this app, is strictly prohibited. Our app monitors and records all screenshots and recordings. Violators will face strict legal action.

**DISCLAIMER**

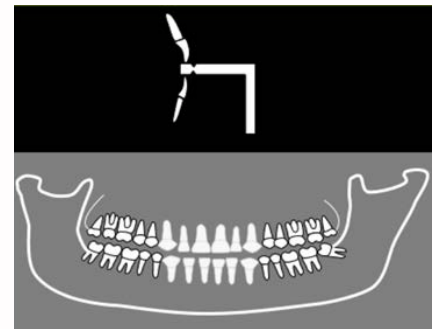
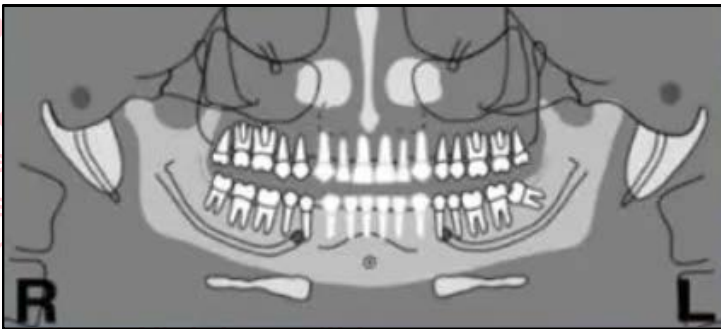
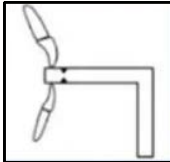
THIS IS COPYRIGHTED CONTENT. Unauthorized use, including screenshots, copying, misuse, reuse, or resale of any content from this app, is strictly prohibited. Our app monitors and records all screenshots and recordings. Violators will face strict legal action.

# OPG ERRORS

## Patient Positioning Errors in OPG

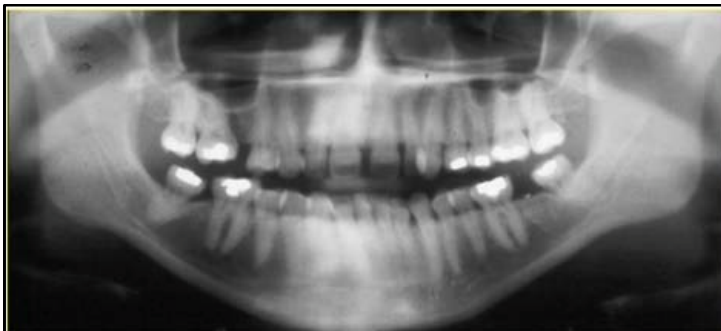### 2) Teeth too posterior: Patient too far back (posterior to focal trough)

- If the teeth are positioned in front of the notches in the bite stick like in the image shown below, the anterior teeth will appear narrower and will be blurred (less sharp than normal).

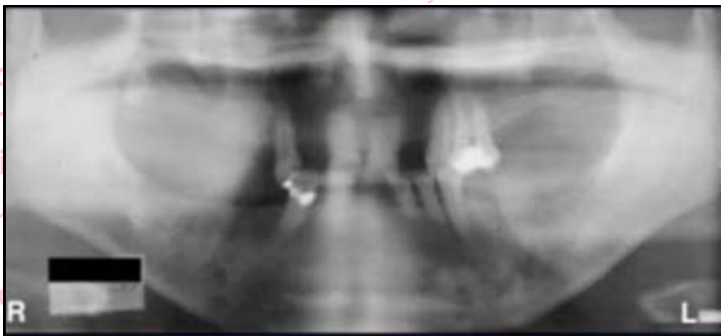

### Reasons

- If the teeth are behind the notches, they are farther from the film, resulting in more magnification horizontally (leading to widening).
- Being out of the focal trough makes the image less sharp.



Incisors positioned posterior to notch in bite stick. Incisors wider than normal and blurred.



THIS IS COPYRIGHTED CONTENT. Unauthorized use, including screenshots, copying, misuse, reuse, or resale of any content from this app, is strictly prohibited. Our app monitors and records all screenshots and recordings. Violators will face strict legal action.

DISCLAIMER  
THIS IS COPYRIGHTED CONTENT. Unauthorized use, including screenshots, copying, misuse, reuse, or resale of any content from this app, is strictly prohibited. Our app monitors and records all screenshots and recordings. Violators will face strict legal action.

### DISCLAIMER

THIS IS COPYRIGHTED CONTENT. Unauthorized use, including screenshots, copying, misuse, reuse, or resale of any content from this app, is strictly prohibited. Our app monitors and records all screenshots and recordings. Violators will face strict legal action.

DISCLAIMER  
THIS IS COPYRIGHTED CONTENT. Unauthorized use, including screenshots, copying, misuse, reuse, or resale of any content from this app, is strictly prohibited. Our app monitors and records all screenshots and recordings. Violators will face strict legal action.

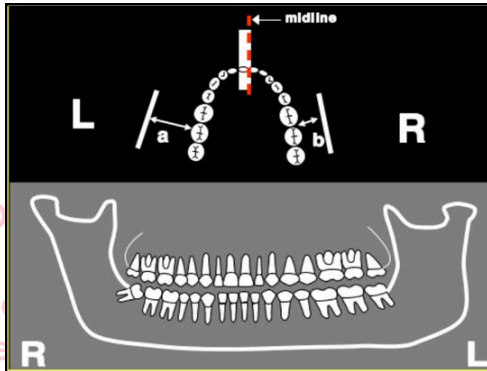


# OPG ERRORS

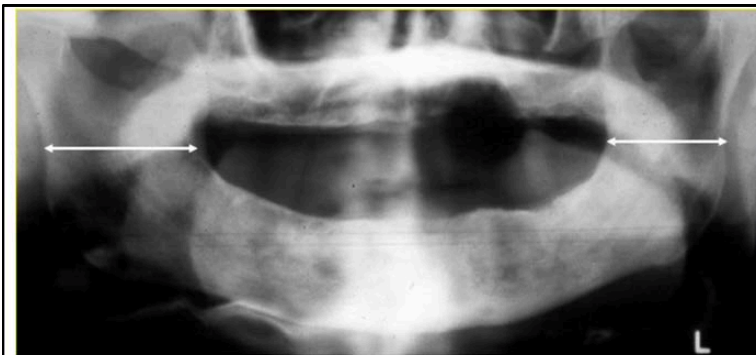
## Patient Positioning Errors in OPG

### 3) Patient Head not centered (Head turned)

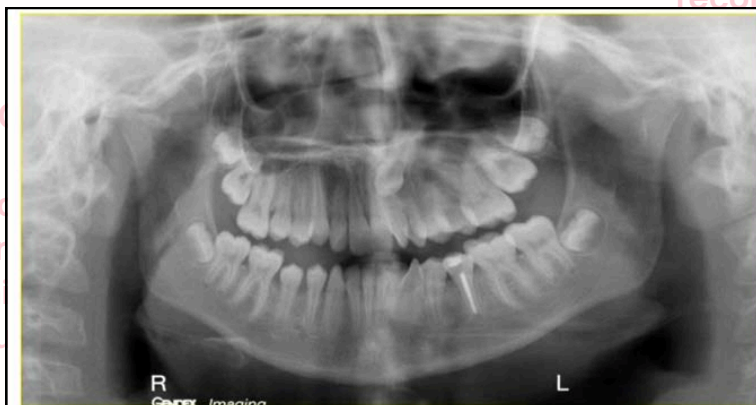- If the head is not centered on the bite stick and turned slightly to the side, then the structures on one side will be closer to the film and the structures on other side will be farther from the film.



- In the image above, the head was turned to the right and the teeth were closer to the film on that side. The teeth are smaller on the side to which the head is turned (as when teeth are closer there is less magnification horizontally). The teeth farther from the film are wider because there is increased magnification horizontally.



Head turned to the left. The ramus is wider on the right side.



Head turned to the right, moving the teeth closer to the film on that side. The teeth on the left side, being farther from the film, will be magnified more and appear larger.

THIS IS COPYRIGHTED CONTENT. Unauthorized use, including screenshots, copying, misuse, reuse, or resale of any content from this app, is strictly prohibited. Our app monitors and records all screenshots and recordings. Violators will face strict legal action.

**DISCLAIMER**  
THIS IS COPYRIGHTED CONTENT. Unauthorized use, including screenshots, copying, misuse, reuse, or resale of any content from this app, is strictly prohibited. Our app monitors and records all screenshots and recordings. Violators will face strict legal action.

**DISCLAIMER**

THIS IS COPYRIGHTED CONTENT. Unauthorized use, including screenshots, copying, misuse, reuse, or resale of any content from this app, is strictly prohibited. Our app monitors and records all screenshots and recordings. Violators will face strict legal action.

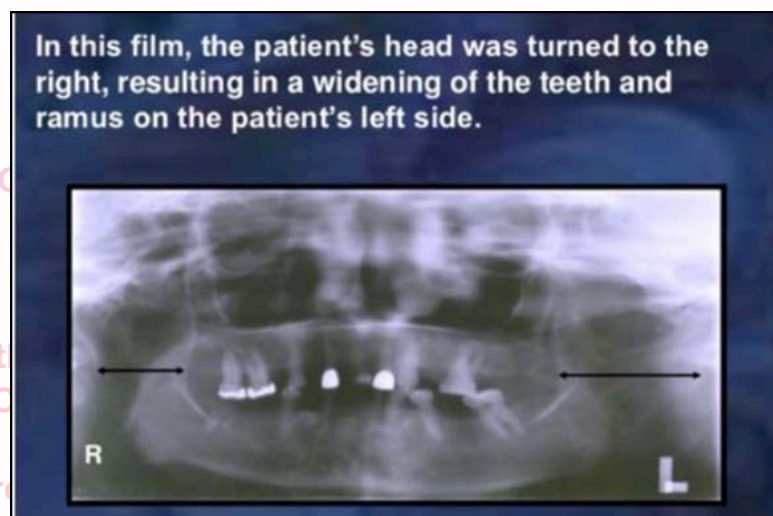
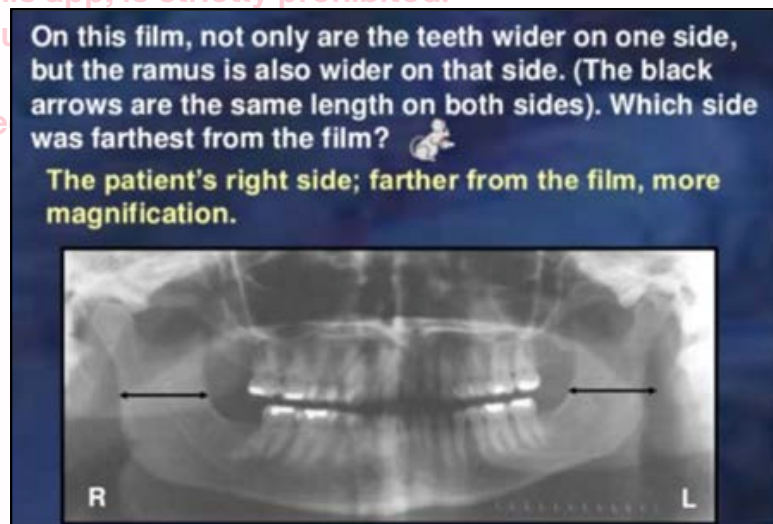
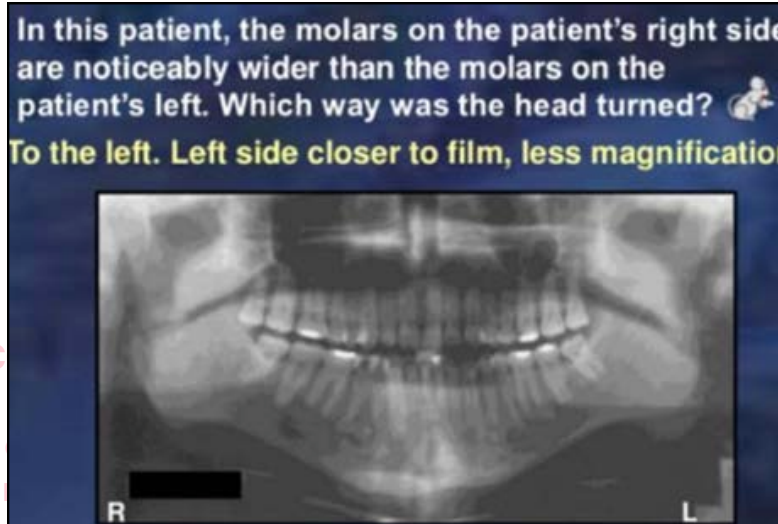
THIS IS COPYRIGHTED CONTENT. Unauthorized use, including screenshots, copying, misuse, reuse, or resale of any content from this app, is strictly prohibited. Our app monitors and records all screenshots and recordings. Violators will face strict legal action.

**DISCLAIMER**

# OPG ERRORS

## Patient Positioning Errors in OPG

### 3) Patient Head not centered (Head turned)



strict legal action.

**DISCLAIMER**

THIS IS COPYRIGHTED CONTENT. Unauthorized use, including screenshots, copying, misuse, reuse, or resale of any content from this app, is strictly prohibited. Our app monitors and records all screenshots and recordings. Violators will face strict legal action.

THIS IS COPYRIGHTED CONTENT. Unauthorized use, including screenshots, copying, misuse, reuse, or sale of any content from this app, is strictly prohibited. Our app monitors and records all screenshots and recordings. Violators will face strict legal action.

**DISCLAIMER**  
THIS IS COPYRIGHTED CONTENT. Unauthorized use, including screenshots, copying, misuse, reuse, or resale of any content from this app, is strictly prohibited. Our app monitors and records all screenshots and recordings. Violators will face strict legal action.

THIS IS COPYRIGHTED CONTENT. Unauthorized use, including screenshots, copying, misuse, reuse, or sale of any content from this app, is strictly prohibited. Our app monitors and records all screenshots and recordings. Violators will face strict legal action.

THIS IS COPYRIGHTED CONTENT. Unauthorized use, including screenshots, copying, misuse, reuse, or resale of any content from this app, is strictly prohibited. Our app monitors and records all screenshots and recordings. Violators will face strict legal action.

**DISCLAIMER**

# OPG ERRORS

## Patient Positioning Errors in OPG

### 4) Head tipped down (Patients chin down)

- If the head is tipped down too much, so that the Frankfort Plane is angled downward, the resulting film will show a V-shaped mandible and shortening of the mandibular incisors.

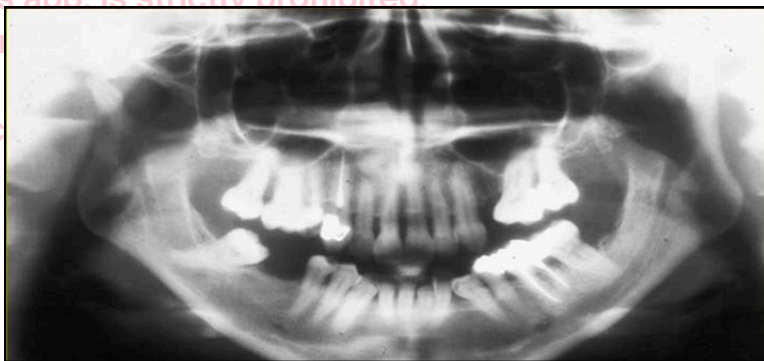
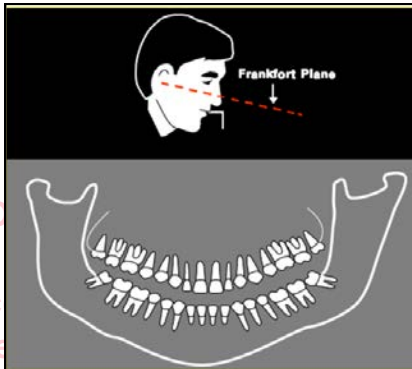


Image: Chin tipped down too much. Roots of mandibular incisors shortened. V-shaped mandible.

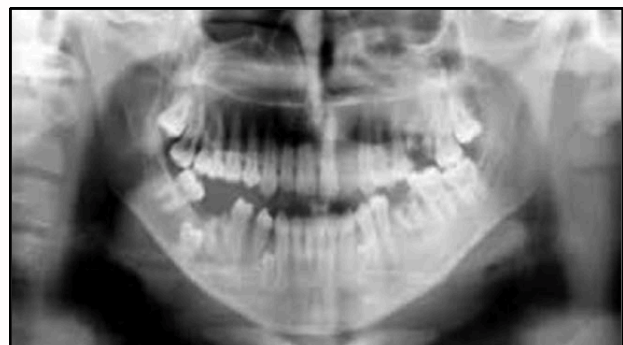
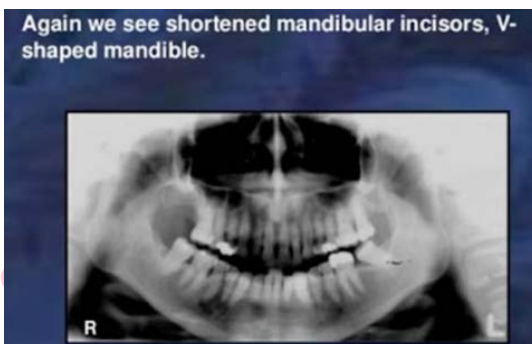
Image: The patient's chin is too low. The occlusal plane is "smiling" and the apices of the mandibular incisors are fuzzy.

#### DISCLAIMER

THIS IS COPYRIGHTED CONTENT. Unauthorized use, including screenshots, copying, misuse, reuse, or resale of any content from this app, is strictly prohibited. Our app monitors and records all screenshots and recordings. Violators will face strict legal action.

#### DISCLAIMER

THIS IS COPYRIGHTED CONTENT. Unauthorized use, including screenshots, copying, misuse, reuse, or resale of any content from this app, is strictly prohibited. Our app monitors and records all screenshots and recordings. Violators will face strict legal action.

THIS IS COPYRIGHTED CONTENT. Unauthorized use, including screenshots, copying, misuse, reuse, or resale of any content from this app, is strictly prohibited. Our app monitors and records all screenshots and recordings. Violators will face strict legal action.



# OPG ERRORS

## Patient Positioning Errors in OPG

### 5) Head tipped up:

- If the head is tipped up too much, so that the Frankfort Plane is angled upward, the resulting film will show a squared-off mandible and the hard palate will be superimposed over the roots of the maxillary teeth.
- A “reverse smile” may be seen.

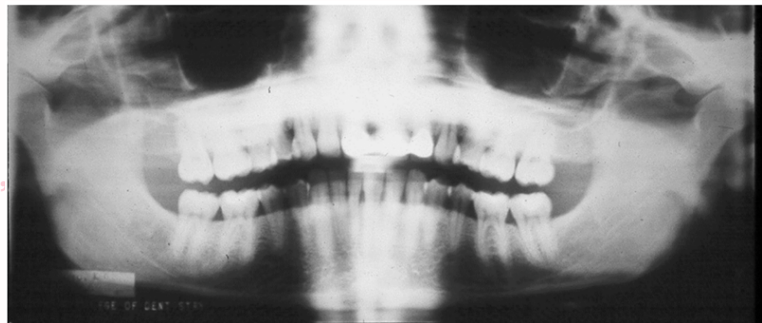
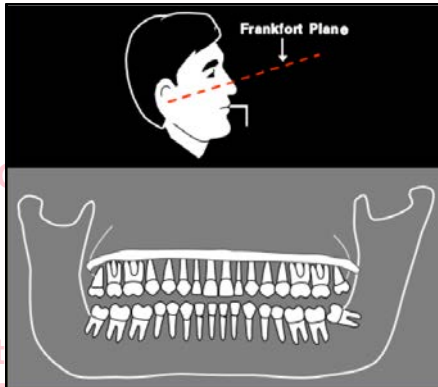


Image: Chin tipped up too much. Hard palate superimposed over roots of maxillary teeth. Squared-off mandible. “Reverse Smile”.

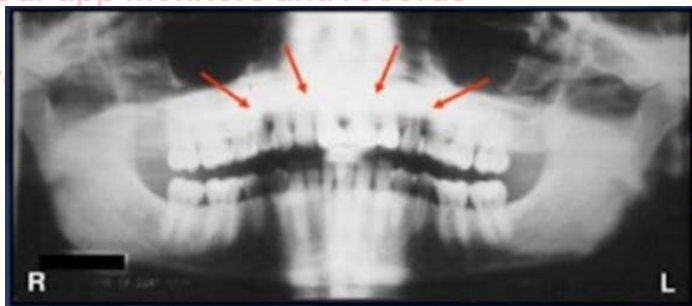


Image: The hard palate (red arrows) covering the roots of maxillary teeth. Note the reverse smile.

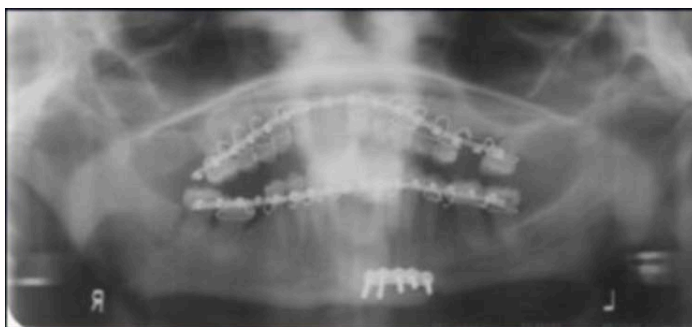


Image: The patient's chin is too high, causing a flat occlusal plane, splayed condyles, and loss of sharpness of the maxillary incisors.

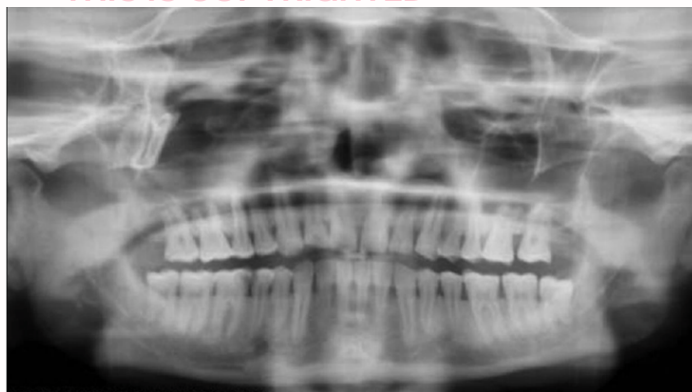

Image: Showing reverse smile and difficult to view root areas of maxillary teeth.

### DISCLAIMER

THIS IS COPYRIGHTED CONTENT. Unauthorized use, including screenshots, copying, misuse, reuse, or resale of any content from this app, is strictly prohibited. Our app monitors and records all screenshots and recordings. Violators will face strict legal action.

### DISCLAIMER

THIS IS COPYRIGHTED CONTENT. Unauthorized use, including screenshots, copying, misuse, reuse, or resale of any content from this app, is strictly prohibited. Our app monitors and records all screenshots and recordings. Violators will face strict legal action.

THIS IS COPYRIGHTED CONTENT. Unauthorized use, including screenshots, copying, misuse, reuse, or resale of any content from this app, is strictly prohibited. Our app monitors and records all screenshots and recordings. Violators will face strict legal action.

### DISCLAIMER



# OPG ERRORS

## Patient Positioning Errors in OPG

### 6) Lead Apron shadow:

- The lead apron should be placed low on the back of the patient's neck so that it does not block off the x-ray beam as the tube head passes behind the patient.
- (A thyroid collar is never used for panoramic films).
- If the apron blocks the beam, a completely radiopaque shadow is produced on the film overlying a portion of the mandible, no evidence of teeth or bone is seen in this area.

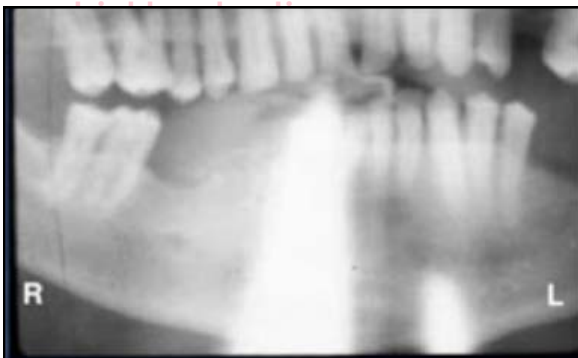
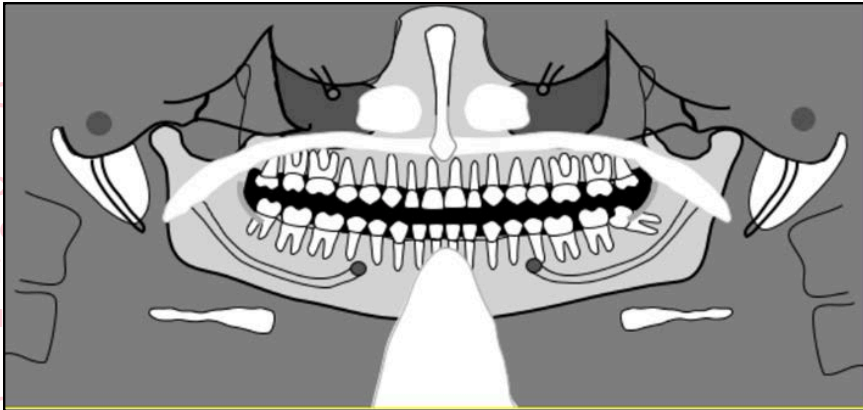
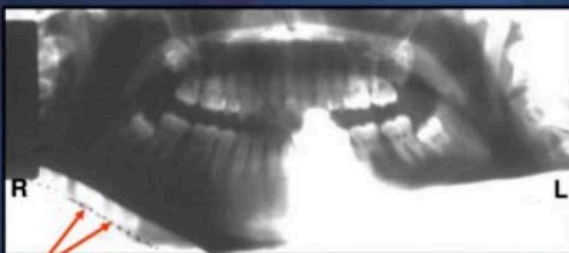

Image showing two completely radiopaque areas of the film caused by lead apron. You cannot see any anatomy in the areas due to complete blockage of the X-ray beam by apron.

The film below shows an extensive white area caused by the lead apron. Note the black dots (arrows) that represent the stitching on the apron. The thyroid collar should never be used for panoramic radiography since it would routinely cause this same problem.



### DISCLAIMER

THIS IS COPYRIGHTED CONTENT. Unauthorized use, including screenshots, copying, misuse, reuse, or resale of any content from this app, is strictly prohibited. Our app monitors and records all screenshots and recordings. Violators will face strict legal action.

### DISCLAIMER

THIS IS COPYRIGHTED CONTENT. Unauthorized use, including screenshots, copying, misuse, reuse, or resale of any content from this app, is strictly prohibited. Our app monitors and records all screenshots and recordings. Violators will face strict legal action.

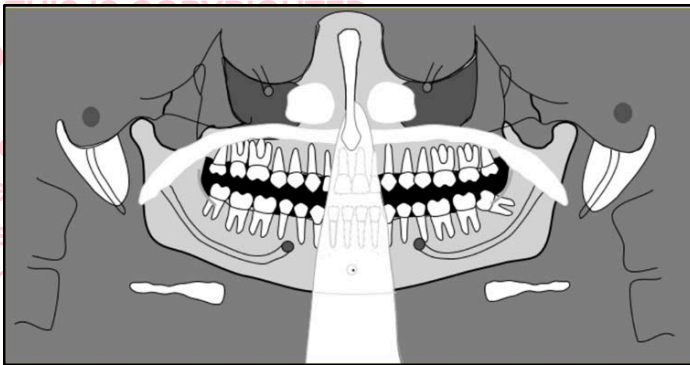
THIS IS COPYRIGHTED CONTENT. Unauthorized use, including screenshots, copying, misuse, reuse, or resale of any content from this app, is strictly prohibited. Our app monitors and records all screenshots and recordings. Violators will face strict legal action.

# OPG ERRORS

## Patient Positioning Errors in OPG

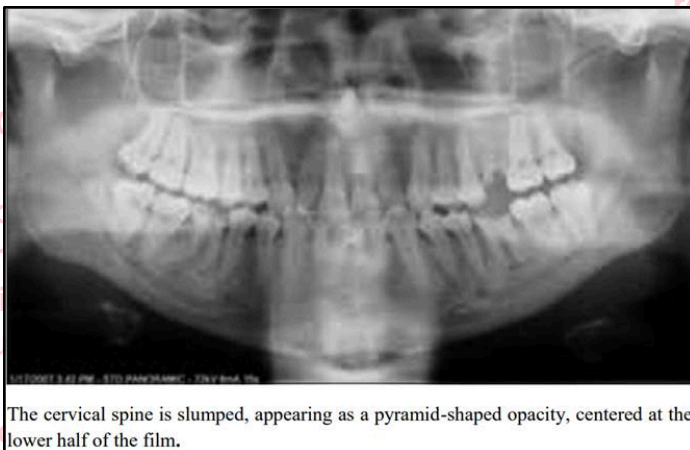
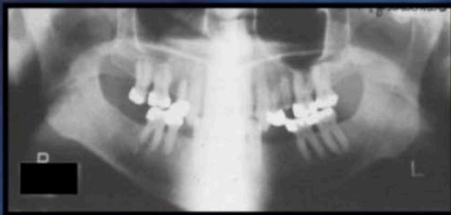### 7) Vertical (spinal) Shadow (Patient spine isn't straight)

- White area in the center of the film represents the shadow of the vertebral column due to **patient slouching**.
- Although faint, you will usually be able to see outlines of the teeth and bone in the area.
- If the patient is not standing straight, the cervical vertebrae may block the X-ray beam as the tube head travels behind the patient at an upward angle.
- This results in a radiopaque area that extend up through the middle of the film.



#### Cervical Vertebrae (Spine)

This film shows the radiopaque "shadow" caused by the cervical vertebrae in a patient that is not standing straight. Note that the edges of this radiopaque area are not as sharp as those produced by the lead apron; here the radiopacity blends in with the surrounding bone.



The cervical spine is slumped, appearing as a pyramid-shaped opacity, centered at the lower half of the film.

#### DISCLAIMER

THIS IS COPYRIGHTED CONTENT. Unauthorized use, including screenshots, copying, misuse, reuse, or resale of any content from this app, is strictly prohibited. Our app monitors and records all screenshots and recordings. Violators will face strict legal action.

#### DISCLAIMER

THIS IS COPYRIGHTED CONTENT. Unauthorized use, including screenshots, copying, misuse, reuse, or resale of any content from this app, is strictly prohibited. Our app monitors and records all screenshots and recordings. Violators will face strict legal action.

THIS IS COPYRIGHTED CONTENT. Unauthorized use, including screenshots, copying, misuse, reuse, or resale of any content from this app, is strictly prohibited. Our app monitors and records all screenshots and recordings. Violators will face strict legal action.

CO  
ca  
re  
this  
Our  
recordings. Violators will face

CO  
ca  
re  
this  
Our  
recordings. Violators will face

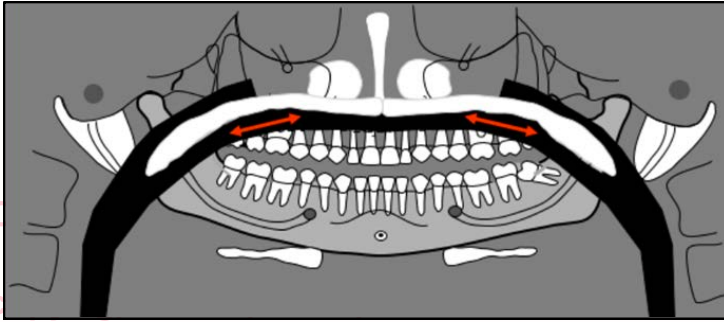
strict legal action.

# OPG ERRORS

## Patient Positioning Errors in OPG

### 8) Palatoglossal Air Space

- The palatoglossal air space (radiolucent band above roots of maxillary teeth) results from failure to place and maintain the tongue against the palate during exposure.



- Right before exposing the film, the patient is asked to swallow (to feel the tongue elevate to contact the palate) and to keep the tongue against the palate during the entire exposure.
- This will help to eliminate the palatoglossal air space (see red arrows above which represent the palatoglossal air space)
- If this radiolucent band appears on the film, it may mask periapical radiolucency that might be present.

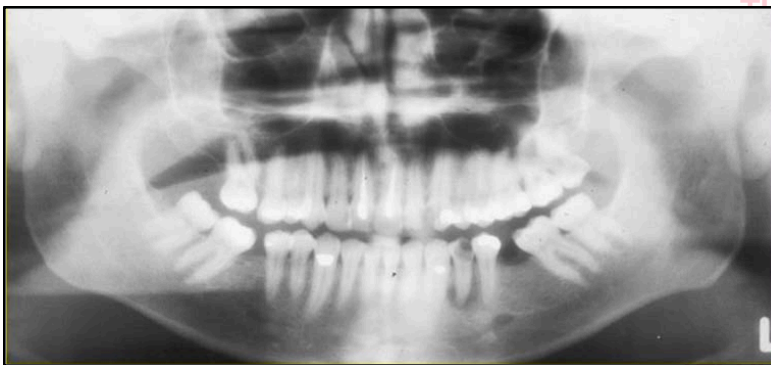


Image: The palatoglossal air space (radiolucent band above roots of maxillary teeth) resulting from failure to place and maintain the tongue against the palate during exposure.

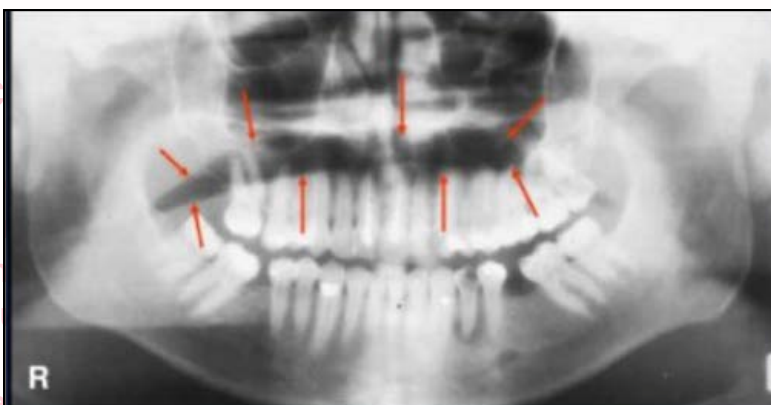


Image: The arrows in the image represent the palatoglossal air space.

#### DISCLAIMER

THIS IS COPYRIGHTED CONTENT. Unauthorized use, including screenshots, copying, misuse, reuse, or resale of any content from this app, is strictly prohibited. Our app monitors and records all screenshots and recordings. Violators will face strict legal action.

DISCLAIMER  
THIS IS COPYRIGHTED CONTENT. Unauthorized use, including screenshots, copying, misuse, reuse, or resale of any content from this app, is strictly prohibited. Our app monitors and records all screenshots and recordings. Violators will face strict legal action.

THIS IS COPYRIGHTED CONTENT. Unauthorized use, including screenshots, copying, misuse, reuse, or resale of any content from this app, is strictly prohibited. Our app monitors and records all screenshots and recordings. Violators will face strict legal action.

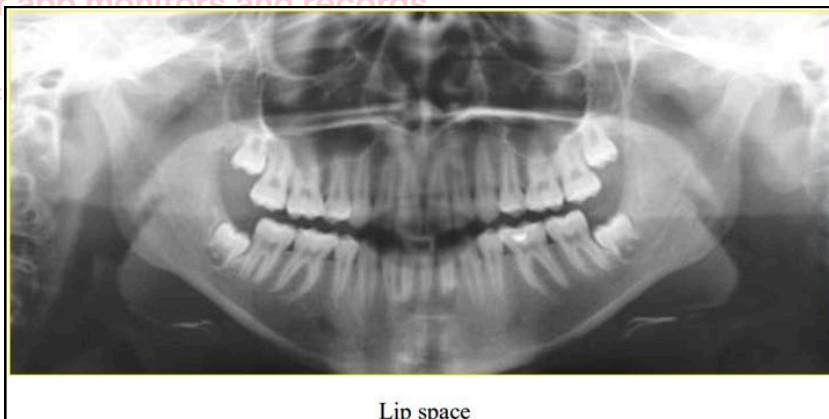
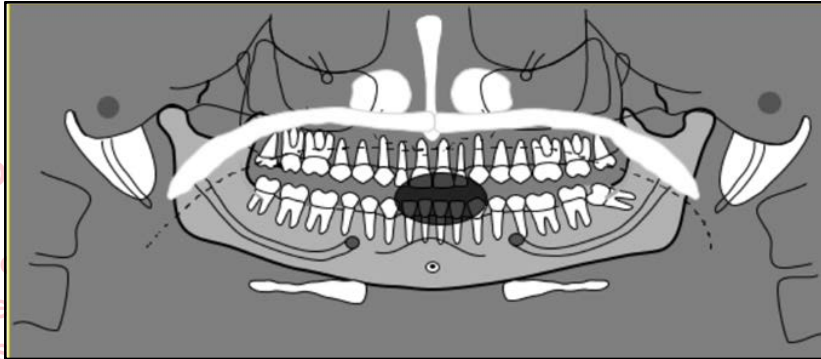


# OPG ERRORS

## Patient Positioning Errors in OPG

### 9) Lip Space

- Right before exposing the film, the patient is asked to close his lips on the bite block. This will help to eliminate the lip space.
- If this radiolucent shadow appears on the film, it masks the crowns of anterior teeth.



Lip space

THIS IS COPYRIGHTED CONTENT. Unauthorized use, including screenshots, copying, misuse, reuse, or resale of any content from this app, is strictly prohibited. Our app monitors and records all screenshots and recordings. Violators will face strict legal action.

#### DISCLAIMER

THIS IS COPYRIGHTED CONTENT. Unauthorized use, including screenshots, copying, misuse, reuse, or resale of any content from this app, is strictly prohibited. Our app monitors and records all screenshots and recordings. Violators will face strict legal action.

THIS IS COPYRIGHTED CONTENT. Unauthorized use, including screenshots, copying, misuse, reuse, or resale of any content from this app, is strictly prohibited. Our app monitors and records all screenshots and recordings. Violators will face strict legal action.

**DISCLAIMER**  
THIS IS COPYRIGHTED CONTENT. Unauthorized use, including screenshots, copying, misuse, reuse, or resale of any content from this app, is strictly prohibited. Our app monitors and records all screenshots and recordings. Violators will face strict legal action.

THIS IS COPYRIGHTED CONTENT. Unauthorized use, including screenshots, copying, misuse, reuse, or resale of any content from this app, is strictly prohibited. Our app monitors and records all screenshots and recordings. Violators will face strict legal action.



# OPG ERRORS

## Panoramic Technique errors in OPG:

### 1) Ghost images:

- Ghost image resembles real image Projected on opposite side of film and is higher.
- As the x-ray beam passes around the patient, objects such as jewelry or dense bone will produce a real image on the side where the object is located and a “ghost” image on the opposite side.
- This ghost image will have the same shape and orientation as the real image, but it will be larger and projected higher on the film and will be very blurred.

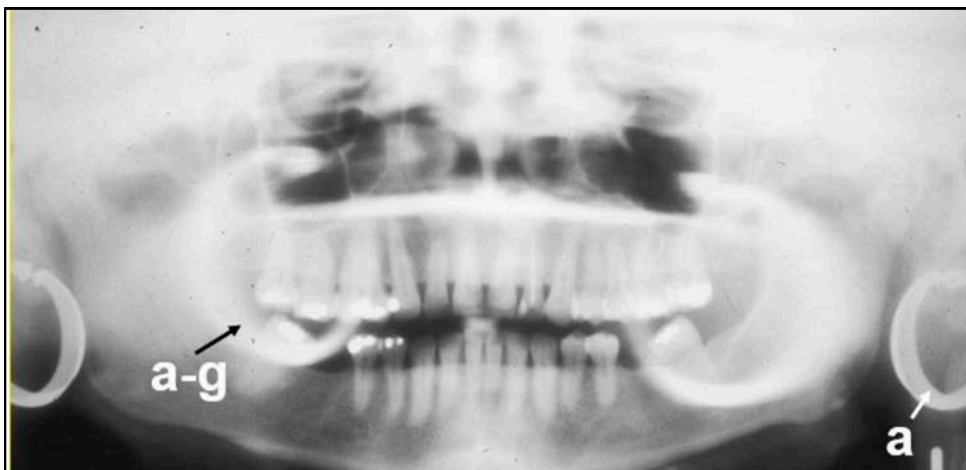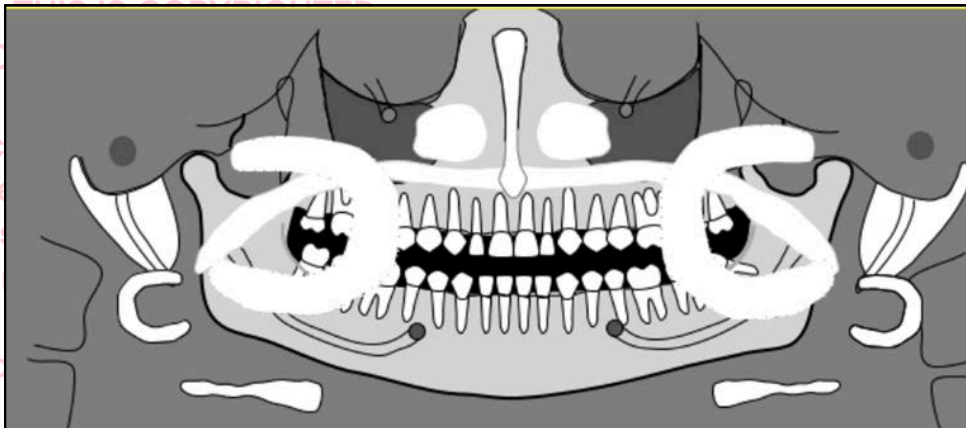


Image: Ghost images of earrings. The ghost image (see “a-g” above) has the same shape and orientation, but is higher, larger and on the opposite side when compared to the image of the actual object (see “a” above).

copying, misuse, reuse, or resale of any content from this app, is strictly prohibited. Our app monitors and records all screenshots and recordings. Violators will face strict legal action.

#### DISCLAIMER

THIS IS COPYRIGHTED CONTENT. Unauthorized use, including screenshots, copying, misuse, reuse, or resale of any content from this app, is strictly prohibited. Our app monitors and records all screenshots and recordings. Violators will face strict legal action.

DISCLAIMER  
THIS IS COPYRIGHTED CONTENT. Unauthorized use, including screenshots, copying, misuse, reuse, or resale of any content from this app, is strictly prohibited. Our app monitors and records all screenshots and recordings. Violators will face strict legal action.

DISCLAIMER

THIS IS COPYRIGHTED CONTENT. Unauthorized use, including screenshots, copying, misuse, reuse, or resale of any content from this app, is strictly prohibited. Our app monitors and records all screenshots and recordings. Violators will face strict legal action.

# OPG ERRORS

## Panoramic Technique errors in OPG:

### 2) Failure to remove metallic objects:

- As a part of patient preparation, appliances should be removed from the mouth.

#### a) Failure to remove acrylic complete denture.

- The image below shows failure to remove complete upper denture before exposure. This is usually not a problem since the denture acrylic is not dense enough to block the image of the maxillary bone.

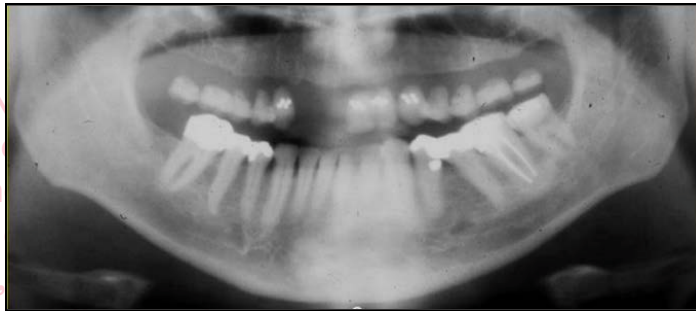


Image: Failure to remove acrylic complete denture

#### b) Failure to remove non-acrylic partial denture:

- Leaving metallic partial dentures in the mouth for a panoramic film will usually obscure important diagnostic information as seen in the image below.
- \*Note also the hearing aid in the left ear (green arrow) and its ghost image overlying the right orbit (red arrows).

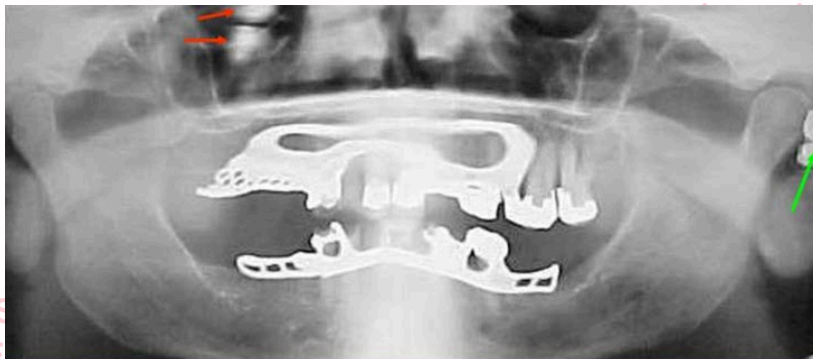


Image: Failure to remove metallic partial denture causing obscured image.

## DISCLAIMER

THIS IS COPYRIGHTED CONTENT. Unauthorized use, including screenshots, copying, misuse, reuse, or resale of any content from this app, is strictly prohibited. Our app monitors and records all screenshots and recordings. Violators will face strict legal action.

DISCLAIMER  
THIS IS COPYRIGHTED CONTENT. Unauthorized use, including screenshots, copying, misuse, reuse, or resale of any content from this app, is strictly prohibited. Our app monitors and records all screenshots and recordings. Violators will face strict legal action.

THIS IS COPYRIGHTED CONTENT. Unauthorized use, including screenshots, copying, misuse, reuse, or resale of any content from this app, is strictly prohibited. Our app monitors and records all screenshots and recordings. Violators will face strict legal action.

DISCLAIMER

# OPG ERRORS

## Panoramic Technique errors in OPG:

### 2) Failure to remove metallic objects:

#### c) Failure to remove glasses:

- Glasses should be routinely removed for panoramic exposures.
- The bottom part of the frame/ lenses may obscure the periapical area of the maxillary anterior teeth.

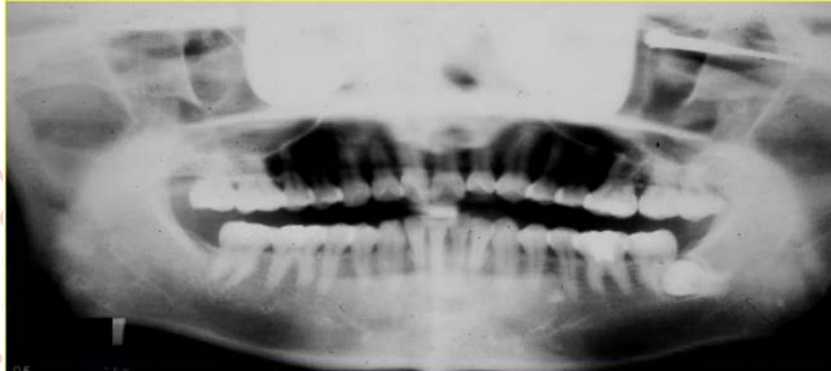
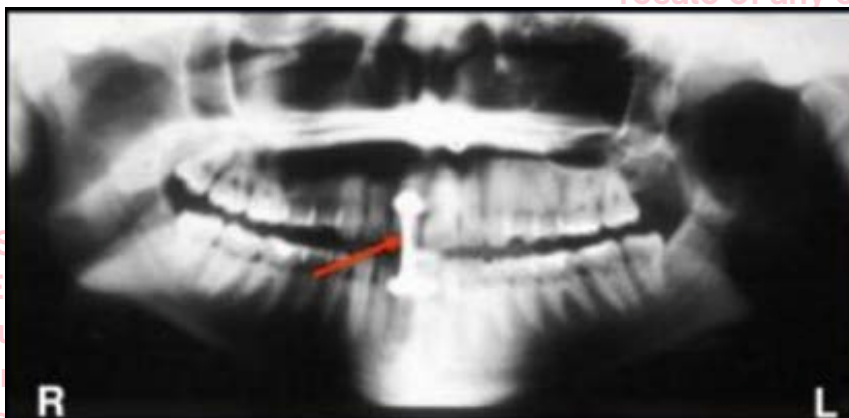


Image: Failure to remove glasses. Also note squared-off mandible and reverse "smile", indicating chin tipped up too much in the same OPG.

#### d) Failure to remove tongue rings:

- Anything removeable in the mouth should be taken out before taking a panoramic x-ray.
- The image below represents failure to remove the tongue ring which blocks a couple of teeth.
- The tongue ring however, is not needed to be removed while taking a periapical radiograph because it would be behind the film and not cause any problem if the film is positioned correctly.



#### DISCLAIMER

THIS IS COPYRIGHTED CONTENT. Unauthorized use, including screenshots, copying, misuse, reuse, or resale of any content from this app, is strictly prohibited. Our app monitors and records all screenshots and recordings. Violators will face strict legal action.

DISCLAIMER  
THIS IS COPYRIGHTED CONTENT. Unauthorized use, including screenshots, copying, misuse, reuse, or resale of any content from this app, is strictly prohibited. Our app monitors and records all screenshots and recordings. Violators will face strict legal action.

THIS IS COPYRIGHTED CONTENT. Unauthorized use, including screenshots, copying, misuse, reuse, or resale of any content from this app, is strictly prohibited. Our app monitors and records all screenshots and recordings. Violators will face strict legal action.

DISCLAIMER

# OPG ERRORS

## Panoramic Technique errors in OPG:

### 3) Patient movement:

- It is important for the patient to remain still during panoramic exposure.
- a) Excessive patient movement**
- The film provided below shows excessive patient movement. (The image should be retaken)

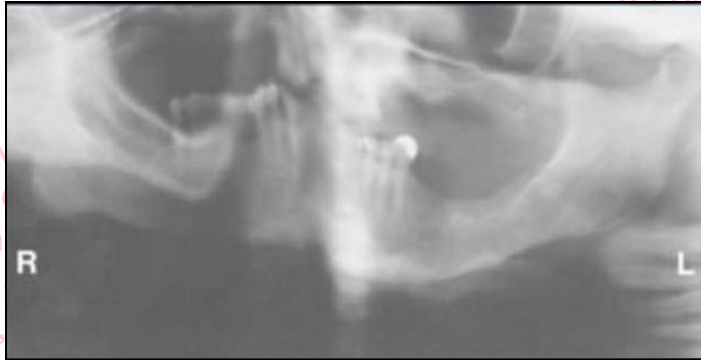

Image: Excessive patient movement

### b) Slight Patient movement

- The image below shows much more subtle patient movement (shown by arrow), resulting in uneven inferior border of the mandible.
- This can be misrepresented as being a result of fracture.

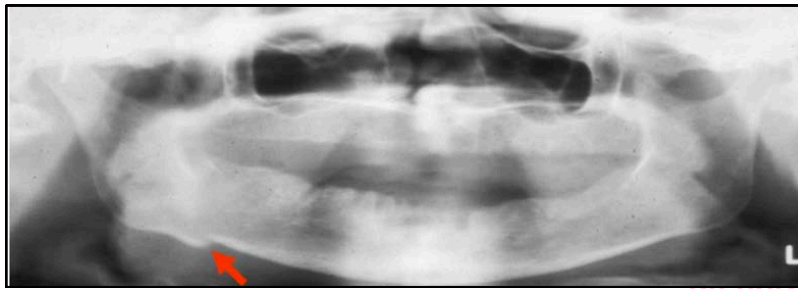
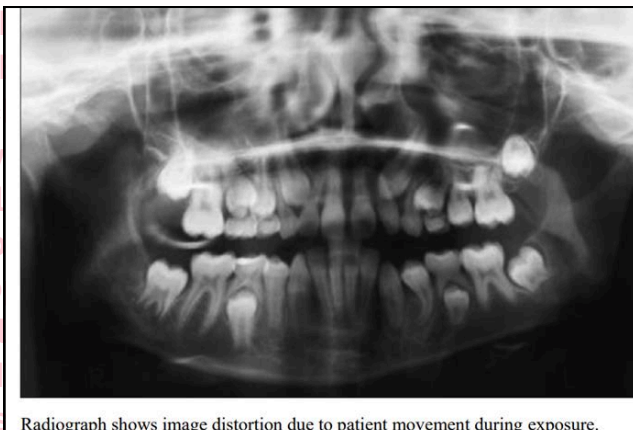
Image: Slight patient movement indicated by notching of mandible at arrow



Radiograph shows image distortion due to patient movement during exposure.

THIS IS COPYRIGHTED CONTENT. Unauthorized use, including screenshots, copying, misuse, reuse, or resale of any content from this app, is strictly prohibited. Our app monitors and records all screenshots and recordings. Violators will face strict legal action.

**DISCLAIMER**  
THIS IS COPYRIGHTED CONTENT. Unauthorized use, including screenshots, copying, misuse, reuse, or resale of any content from this app, is strictly prohibited. Our app monitors and records all screenshots and recordings. Violators will face strict legal action.

**DISCLAIMER**

THIS IS COPYRIGHTED CONTENT. Unauthorized use, including screenshots, copying, misuse, reuse, or resale of any content from this app, is strictly prohibited. Our app monitors and records all screenshots and recordings. Violators will face strict legal action.

THIS IS COPYRIGHTED CONTENT. Unauthorized use, including screenshots, copying, misuse, reuse, or resale of any content from this app, is strictly prohibited. Our app monitors and records all screenshots and recordings. Violators will face strict legal action.

**DISCLAIMER**



# OPG ERRORS

## Panoramic Technique errors in OPG:

### 4) Static electricity image:

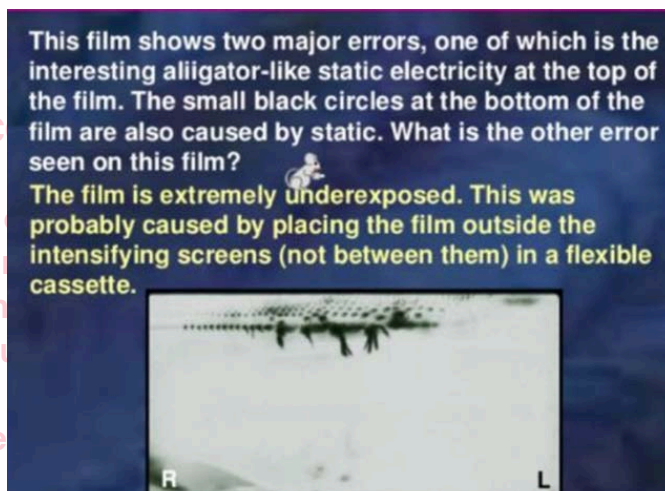
- Static electricity appears as black lines or dots on the film, often having a tree branch appearance.
- It is caused by removing the film from the box or cassette too quickly, which creates a static discharge.

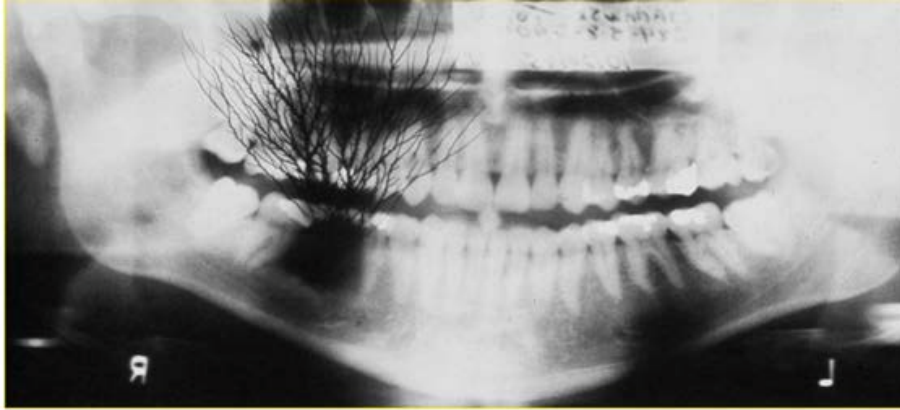

Image: Static electricity caused by friction when removing film from box or cassette too rapidly.

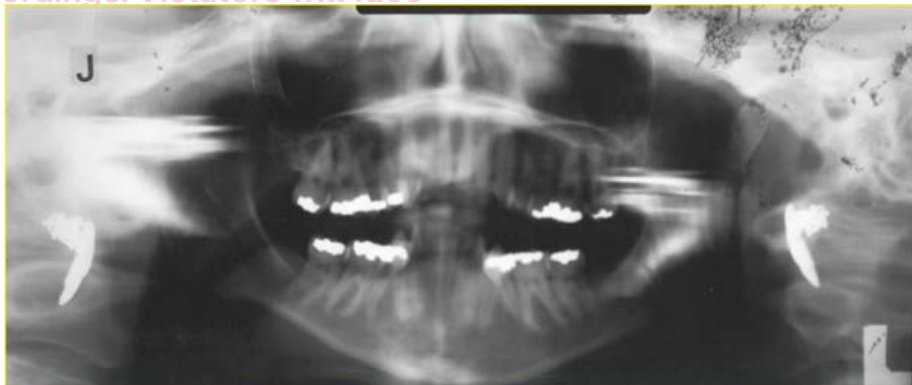

Image: Static electricity caused by friction when removing film from box or cassette too rapidly



DISCLAIMER

THIS IS COPYRIGHTED CONTENT. Unauthorized use, including screenshots, copying, misuse, reuse, or resale of any content from this app, is strictly prohibited. Our app monitors and records all screenshots and recordings. Violators will face strict legal action.

THIS IS COPYRIGHTED CONTENT. Unauthorized use, including screenshots, copying, misuse, reuse, or resale of any content from this app, is strictly prohibited. Our app monitors and records all screenshots and recordings. Violators will face strict legal action.

DISCLAIMER  
THIS IS COPYRIGHTED CONTENT. Unauthorized use, including screenshots, copying, misuse, reuse, or resale of any content from this app, is strictly prohibited. Our app monitors and records all screenshots and recordings. Violators will face strict legal action.

DISCLAIMER

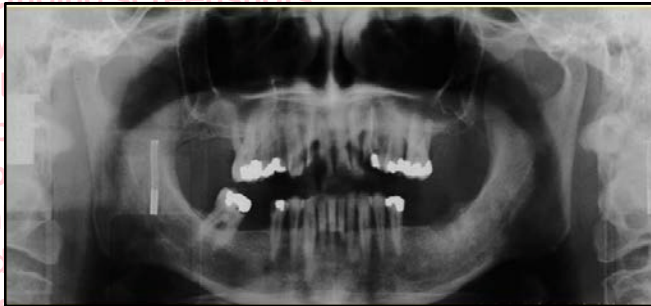THIS IS COPYRIGHTED CONTENT. Unauthorized use, including screenshots, copying, misuse, reuse, or resale of any content from this app, is strictly prohibited. Our app monitors and records all screenshots and recordings. Violators will face strict legal action.

# OPG ERRORS

## Panoramic Technique errors in OPG:

### 5) Reversed cassette:

- If the cassette is reversed, the film will be exposed to the wrong side of the screen, leading to a poor image.
- A reversed cassette can cause a variety of image issues, including:
  - **Blurry or incomplete images:** The image may be distorted or have a partial or incomplete representation of the teeth.
  - **Lack of contrast:** The image may appear washed out or have a lack of distinct lines.
  - **Light leaks:** If the cassette has a light leak, it can cause the film to fog, resulting in a gray or dark image



### 6) Incorrect exposure settings:

- If incorrect exposure factors are selected for a patient (kVp, mA), a film that is too light (underexposed) or too dark (overexposed) can be produced.

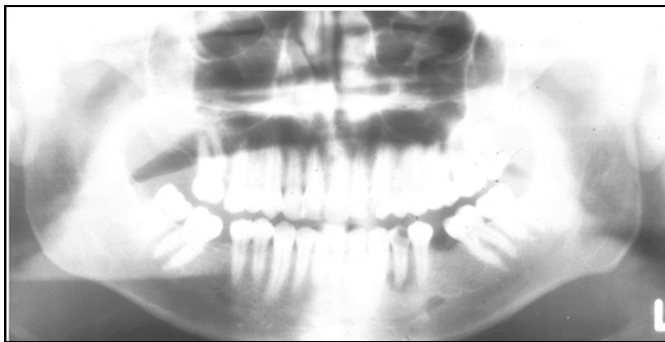


Fig: Light image (under exposure)

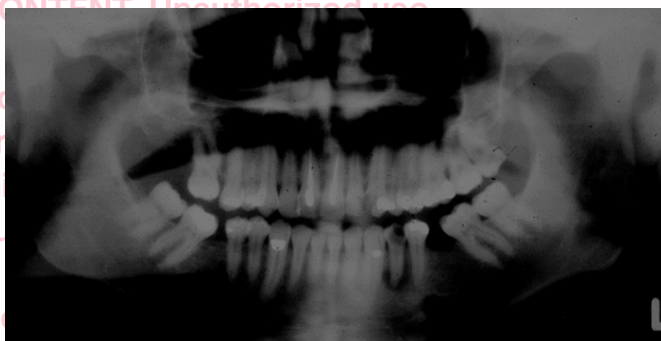

Fig: Dark image (Over exposure)

#### DISCLAIMER

THIS IS COPYRIGHTED CONTENT. Unauthorized use, including screenshots, copying, misuse, reuse, or resale of any content from this app, is strictly prohibited. Our app monitors and records all screenshots and recordings. Violators will face strict legal action.

#### DISCLAIMER

THIS IS COPYRIGHTED CONTENT. Unauthorized use, including screenshots, copying, misuse, reuse, or resale of any content from this app, is strictly prohibited. Our app monitors and records all screenshots and recordings. Violators will face strict legal action.

THIS IS COPYRIGHTED CONTENT. Unauthorized use, including screenshots, copying, misuse, reuse, or resale of any content from this app, is strictly prohibited. Our app monitors and records all screenshots and recordings. Violators will face strict legal action.

#### DISCLAIMER

# OPG ERRORS

## Panoramic Technique errors in OPG:

### 7) Double Exposure:

- The films should be processed immediately after exposure.
- If the cassettes are laid aside for later processing, the operator may pick up a cassette that has already been exposed and use it again.

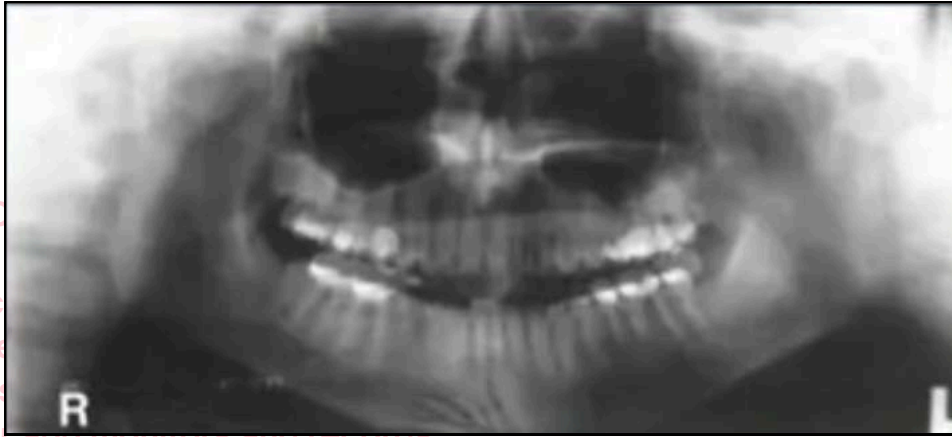


Fig: Double exposure image, also note static electricity error at the bottom of the film.

## A summary of positioning errors:

Positioning error	Manifestation on panoramic radiographs
Chin tipped high	Maxillary incisors blurry, hard palate superimposed on roots, flat occlusal plane, mandible is broad and flat, condyles at edge of film
Chin tipped low	Roots of lower incisors blurry, mandible shaped like a "V", too much smile line, condyles at top of film, spine forms arch
Slumped position	White tapered opacity in middle of image
Patient positioned forward	Anterior teeth blurry, too small and narrow, spine visible on sides of film
Patient positioned backward	Anterior teeth blurry and wide, ghosting of mandible and spine, condyles close to edge of film
Failure to position the tongue against the palate	Large, dark shadow over maxillary teeth between palate and dorsum of tongue
Patient movement during exposure	Portions of radiograph are blurred; large step defects in inferior border of mandible
Head is tilted to the side	Condyles are not equal in height, nasal structures distorted
Head is turned to one side	Teeth are wide on one side, narrow on other side of midline; ramus is wider on one side than the other; uneven pattern of blurring throughout arch; nasal structures not clear

Image: Source: Positioning errors and quality assessment in panoramic radiography (Link: <https://pmc.ncbi.nlm.nih.gov/articles/PMC3534173/>)

### DISCLAIMER

THIS IS COPYRIGHTED CONTENT. Unauthorized use, including screenshots, copying, misuse, reuse, or resale of any content from this app, is strictly prohibited. Our app monitors and records all screenshots and recordings. Violators will face strict legal action.

DISCLAIMER  
THIS IS COPYRIGHTED CONTENT. Unauthorized use, including screenshots, copying, misuse, reuse, or resale of any content from this app, is strictly prohibited. Our app monitors and records all screenshots and recordings. Violators will face strict legal action.

CC BY-NC-SA  
This content is not to be used for commercial purposes. Our app monitors and records all screenshots and recordings. Violators will face strict legal action.

DISCLAIMER

THIS IS COPYRIGHTED CONTENT. Unauthorized use, including screenshots, copying, misuse, reuse, or resale of any content from this app, is strictly prohibited. Our app monitors and records all screenshots and recordings. Violators will face strict legal action.



# IOPA AND BITEWING ERRORS

(Sources: Article on Intraoral Imaging: Basic Principles, Techniques and Error Correction CPD by dental care.com, Radiographic errors and Artifacts by Professor Abbas Ay Thaeer)

- Intraoral radiographic images can be acquired with digital receptors or radiographic film.
- Digital image receptors include
  - a) rigid sensors and
  - b) phosphor plate receptors.



- Intraoral digital receptors are available in sizes comparable to traditional dental film. Rigid digital receptors are typically available in sizes 0, 1, and 2 while the plate receptors are available in sizes 0, 1, 2, 3, and 4.
- Digital receptors cannot be sterilized. Therefore, it is important to utilize proper infection control techniques to prepare and cover digital receptors for placement inside the mouth and effective barrier removal following completion of the survey.

## Intraoral Radiographic Techniques

- The two techniques most commonly used are
  - a) Bisecting angle technique
  - b) Paralleling technique
- Although the bisecting angle technique is still utilized and may be necessary in certain circumstances, the paralleling technique is the method of choice for intraoral radiography.
- Before radiographs are taken, the patient must be informed about the procedure and consent obtained.

## Different types of Errors:

- The majority of the errors produced can be categorized into three groups:
  - A) Technique & Projection errors
  - B) Exposure errors
  - C) Processing errors

## DISCLAIMER

THIS IS COPYRIGHTED CONTENT. Unauthorized use, including screenshots, copying, misuse, reuse, or resale of any content from this app, is strictly prohibited. Our app monitors and records all screenshots and recordings. Violators will face strict legal action.

DISCLAIMER  
THIS IS COPYRIGHTED CONTENT. Unauthorized use, including screenshots, copying, misuse, reuse, or resale of any content from this app, is strictly prohibited. Our app monitors and records all screenshots and recordings. Violators will face strict legal action.

THIS IS COPYRIGHTED CONTENT. Unauthorized use, including screenshots, copying, misuse, reuse, or resale of any content from this app, is strictly prohibited. Our app monitors and records all screenshots and recordings. Violators will face strict legal action.

DISCLAIMER



# IOPA AND BITEWING ERRORS

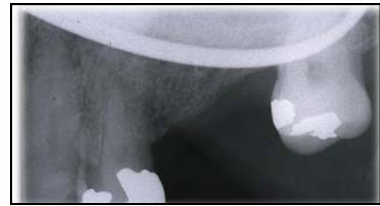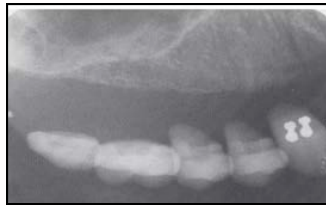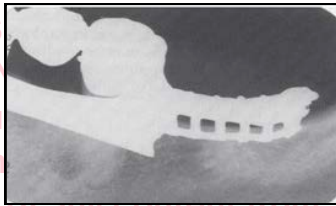
## A) Technique & Projection errors:

- It includes:

### 1) Patient Preparation errors:

#### a) Radiopaque artifact


- Appearance:** as radiopaque artifact superimposed over the dental image.
- Cause:** Dental appliances left in the mouth during exposure, jewelry & eye glasses.
- Correction:** all these items should be removed before placing of the film



Images: A) metal partial denture B) Denture left in mouth C) Eye glasses

#### b) Blurred image

- Cause:** Movement of the film, patient or X-ray tube head during exposure will result in a blurred image.
- Correction:** the operator should explain to the patient & remind him/her to remain motionless during radiological exposure.



- The most common error in this category is **movement which leads to blurred image**. Factors causing a patient to move include:
  - Discomfort:** Discomfort can be addressed by gentle, proper receptor placement, instructing the patient to close slowly, and the use of cushioned edges which can be attached to the receptor. Bending, folding, or creasing film or a digital phosphor plate receptor will produce artifacts that compromise the diagnostic quality of the radiographic image.
  - Unsupported head position**

#### DISCLAIMER

THIS IS COPYRIGHTED CONTENT. Unauthorized use, including screenshots, copying, misuse, reuse, or resale of any content from this app, is strictly prohibited. Our app monitors and records all screenshots and recordings. Violators will face strict legal action.

DISCLAIMER  
THIS IS COPYRIGHTED CONTENT. Unauthorized use, including screenshots, copying, misuse, reuse, or resale of any content from this app, is strictly prohibited. Our app monitors and records all screenshots and recordings. Violators will face strict legal action.

THIS IS COPYRIGHTED CONTENT. Unauthorized use, including screenshots, copying, misuse, reuse, or resale of any content from this app, is strictly prohibited. Our app monitors and records all screenshots and recordings. Violators will face strict legal action.

DISCLAIMER

# IOPA AND BITEWING ERRORS

## A) Projection errors:

- It includes:

### 1) Preparation errors:

#### b) Blurred image

#### iii. Gagging and/or swallowing:

- All patients have gag reflexes, some more sensitive than others. The gag reflex can be stimulated when the receptor contacts the soft palate, base of the tongue, or the posterior wall of the pharynx.
- When exposing a full mouth survey of radiographic images, it is recommended to begin in the anterior region of the mouth. An anterior placement is less likely to stimulate the gag reflex and will also help the patient become more accustomed and comfortable with the procedure
- It may help to encourage the patient to swallow once before the placement of the receptor.

Other recommended procedures to control gagging include deep breathing through the nose or mouth, anesthetizing the mouth with lozenges, mouthwash, topical anesthetic agents, or refocusing the patient's attention.<sup>15</sup> The use of a sprinkle of salt on the tongue; patient self-application of pressure on a point in the palm of the hand, the inner forearm, on the chin, or by tapping the temporal bone near the ear can help reduce the gag reflex.<sup>15-17</sup> Distraction techniques such as instructing the patient to raise one leg, bend the toes toward the body, humming, etc. will focus attention on the task rather than on gagging. When a patient begins to gag, remove the receptor, be confident and reassuring, and try again. A panoramic radiographic image may be a useful adjunct to intraoral radiographic images when the molar projections are extremely difficult for the patient to tolerate or for the clinician to obtain.

#### iv. Patient disability:

- Some patients may need assistance during the radiographic procedure due to physical or cognitive disability, injury, or medical condition.
- In such circumstances, it may be necessary to ask a family member or guardian to assist in holding the patient in position.

## DISCLAIMER

THIS IS COPYRIGHTED CONTENT. Unauthorized use, including screenshots, copying, misuse, reuse, or resale of any content from this app, is strictly prohibited. Our app monitors and records all screenshots and recordings. Violators will face strict legal action.

DISCLAIMER  
THIS IS COPYRIGHTED CONTENT. Unauthorized use, including screenshots, copying, misuse, reuse, or resale of any content from this app, is strictly prohibited. Our app monitors and records all screenshots and recordings. Violators will face strict legal action.

THIS IS COPYRIGHTED CONTENT. Unauthorized use, including screenshots, copying, misuse, reuse, or resale of any content from this app, is strictly prohibited. Our app monitors and records all screenshots and recordings. Violators will face strict legal action.

DISCLAIMER

# IOPA AND BITEWING ERRORS

## A) Projection errors:

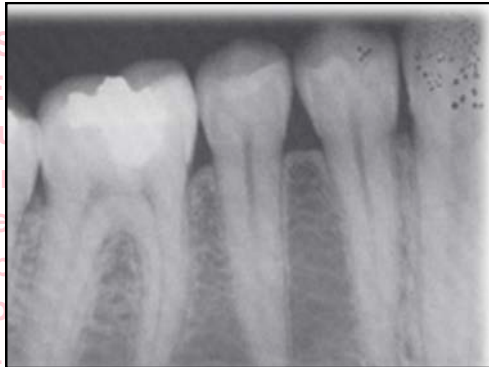- It includes:

### 1) Preparation errors:

#### c) Pressure mark:

- Pressure from the incisal edge & cusps of the teeth (mostly in the pediatric occlusal radiograph).
- May appear black or white.

**Correction:** ask the patient to bite gently.

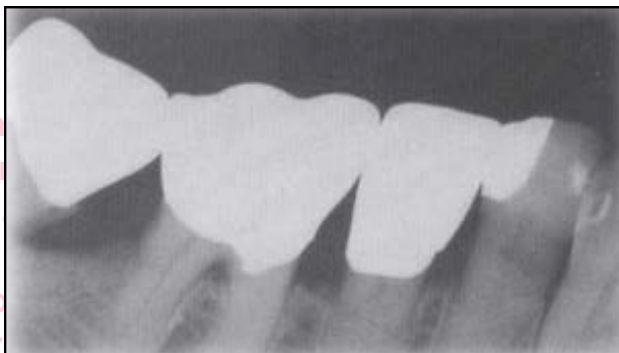


### 2) Film placement errors:

- It includes:
  - Dot artifact,
  - Crown not shown,
  - Area of interest not shown
  - Distortion,
  - Apices cut off,
  - Dropped film corner,
  - Black line

#### a) Apices Cut-off

- Appearance: Absence of apical structures & no apices appear on the film.



THIS IS COPYRIGHTED CONTENT. Unauthorized use, including screenshots, copying, misuse, reuse, or resale of any content from this app, is strictly prohibited. Our app monitors and records all screenshots and recordings. Violators will face strict legal action.

THIS IS COPYRIGHTED CONTENT. Unauthorized use, including screenshots, copying, misuse, reuse, or resale of any content from this app, is strictly prohibited. Our app monitors and records all screenshots and recordings. Violators will face strict legal action.

THIS IS COPYRIGHTED CONTENT. Unauthorized use, including screenshots, copying, misuse, reuse, or resale of any content from this app, is strictly prohibited. Our app monitors and records all screenshots and recordings. Violators will face strict legal action.

#### DISCLAIMER

THIS IS COPYRIGHTED CONTENT. Unauthorized use, including screenshots, copying, misuse, reuse, or resale of any content from this app, is strictly prohibited. Our app monitors and records all screenshots and recordings. Violators will face strict legal action.

DISCLAIMER  
THIS IS COPYRIGHTED CONTENT. Unauthorized use, including screenshots, copying, misuse, reuse, or resale of any content from this app, is strictly prohibited. Our app monitors and records all screenshots and recordings. Violators will face strict legal action.

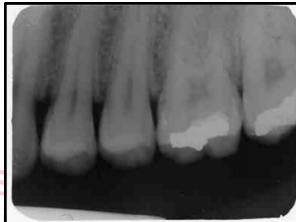# IOPA AND BITEWING ERRORS

## A) Projection errors:

- It includes:

### 2) Film placement errors:

#### a) Apices Cut-off



The root apices of the premolars and molars are "cut off" because the film was placed too close to the teeth in the maxillary arch when using the paralleling technique

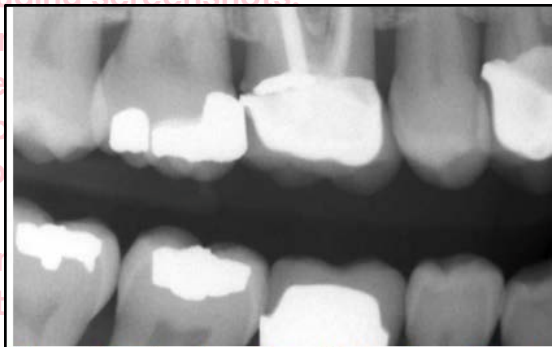


Figure 12: Bitewing – Mandibular Bone Margin Cut Off

**Cause:** Insufficient vertical angulation. The film is not positioned in the patients mouth to cover the apical regions of the teeth.

**Correction:** make sure that no more than 1:8 inch of the film edge extend beyond the incisal -occlusal surfaces of the teeth such film placement ensure adequate coverage of the tooth apices.

#### b) The crowns of teeth not shown:

- There is not enough film extending occlusally



THIS IS COPYRIGHTED CONTENT. Unauthorized use, including screenshots, copying, misuse, reuse, or resale of any content from this app, is strictly prohibited. Our app monitors and records all screenshots and recordings. Violators will face strict legal action.

DISCLAIMER  
THIS IS COPYRIGHTED CONTENT. Unauthorized use, including screenshots, copying, misuse, reuse, or resale of any content from this app, is strictly prohibited. Our app monitors and records all screenshots and recordings. Violators will face strict legal action.

DISCLAIMER

THIS IS COPYRIGHTED CONTENT. Unauthorized use, including screenshots, copying, misuse, reuse, or resale of any content from this app, is strictly prohibited. Our app monitors and records all screenshots and recordings. Violators will face strict legal action.

THIS IS COPYRIGHTED CONTENT. Unauthorized use, including screenshots, copying, misuse, reuse, or resale of any content from this app, is strictly prohibited. Our app monitors and records all screenshots and recordings. Violators will face strict legal action.

DISCLAIMER



# IOPA AND BITEWING ERRORS

## A) Projection errors:

- It includes:

### 2) Film placement errors:

#### c) Tilted Occlusal Plane

- When the receptor is not placed perpendicular to the occlusal plane, the occlusal plane will appear slanted or diagonal on the recorded image.

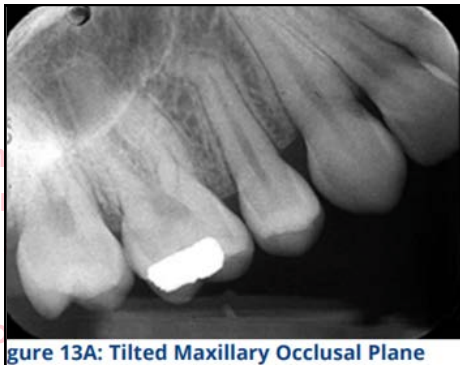

Figure 13A: Tilted Maxillary Occlusal Plane

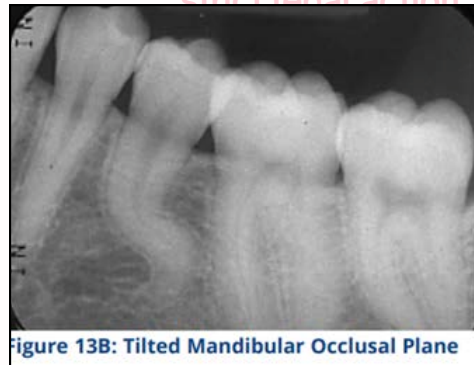

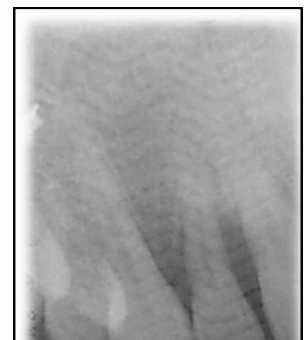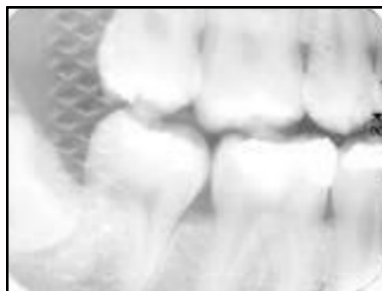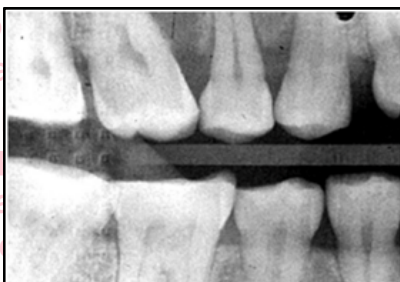Figure 13B: Tilted Mandibular Occlusal Plane

#### d) Reversed film

- Reversed film refers to a film exposed from opposite side.
- This results in light images with herringbone or Tyre track or car – Tyre appearance in the radiograph.
- This pattern is due to the embossed pattern in lead foil at which the x-ray beam is exposed.
- The exposure side of any receptor must be directed toward the x-ray source to produce an acceptable image. Backwards placement is unlikely with **rigid digital receptors** because of the wire attachment on the non-exposure side of the sensor

**Cause:** If the Film is placed in the mouth reversed and then exposed, the x-ray beam gets attenuated by the lead foil backing in the film pack. This causes the embossed pattern on the foil, a herringbone or diamond effect, to appear on the processed film

**Correction:** always place the white side of the film adjacent to the teeth.



DISCLAIMER

THIS IS COPYRIGHTED CONTENT. Unauthorized use, including screenshots, copying, misuse, reuse, or resale of any content from this app, is strictly prohibited. Our app monitors and records all screenshots and recordings. Violators will face strict legal action.

DISCLAIMER  
THIS IS COPYRIGHTED CONTENT. Unauthorized use, including screenshots, copying, misuse, reuse, or resale of any content from this app, is strictly prohibited. Our app monitors and records all screenshots and recordings. Violators will face strict legal action.

THIS IS COPYRIGHTED CONTENT. Unauthorized use, including screenshots, copying, misuse, reuse, or resale of any content from this app, is strictly prohibited. Our app monitors and records all screenshots and recordings. Violators will face strict legal action.

DISCLAIMER

# IOPA AND BITEWING ERRORS

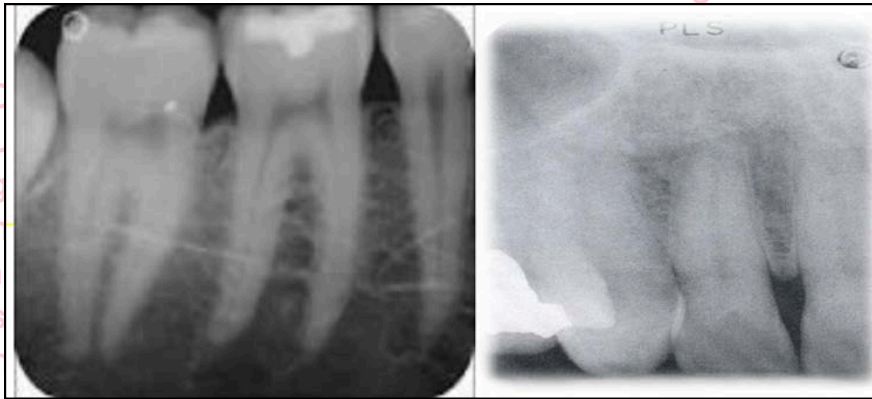
## A) Projection errors:

- It includes:

### 2) Film placement errors:

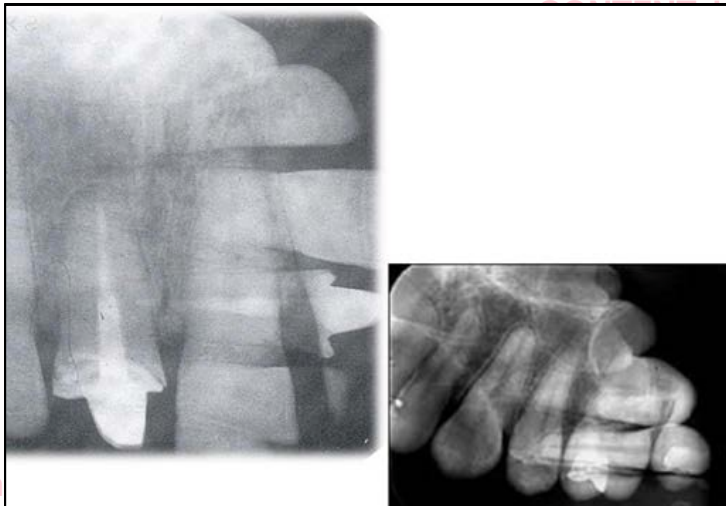
#### e) Dot Artifact

- Dot produces a circular radiolucent artifact on the final radiograph.
- It should be placed towards the occlusal portion of teeth.



#### f) Double Image Appearance

- A double image appear on the film.
- Cause: the film is exposed twice.
- Correction: separate exposed and unexposed films.



THIS IS COPYRIGHTED CONTENT. Unauthorized use, including screenshots, copying, misuse, reuse, or resale of any content from this app, is strictly prohibited.

Our app monitors and records all screenshots and recordings. Violators will face strict legal action.

**DISCLAIMER**  
THIS IS COPYRIGHTED CONTENT. Unauthorized use, including screenshots, copying, misuse, reuse, or resale of any content from this app, is strictly prohibited. Our app monitors and records all screenshots and recordings. Violators will face strict legal action.

THIS IS COPYRIGHTED CONTENT. Unauthorized use, including screenshots, copying, misuse, reuse, or resale of any content from this app, is strictly prohibited. Our app monitors and records all screenshots and recordings. Violators will face strict legal action.

THIS IS COPYRIGHTED CONTENT. Unauthorized use, including screenshots, copying, misuse, reuse, or resale of any content from this app, is strictly prohibited. Our app monitors and records all screenshots and recordings. Violators will face strict legal action.

**DISCLAIMER**

THIS IS COPYRIGHTED CONTENT. Unauthorized use, including screenshots, copying, misuse, reuse, or resale of any content from this app, is strictly prohibited. Our app monitors and records all screenshots and recordings. Violators will face strict legal action.

**DISCLAIMER**

THIS IS COPYRIGHTED CONTENT. Unauthorized use, including screenshots, copying, misuse, reuse, or resale of any content from this app, is strictly prohibited. Our app monitors and records all screenshots and recordings. Violators will face strict legal action.

# IOPA AND BITEWING ERRORS

## A) Projection errors:

- It includes:

### 2) Film placement errors:

#### g) Dropped film corner

- The film edge is not placed parallel to the occlusal surface of the teeth.

#### h) Bending Plate or film bending

- It may occur due to contact with the curvature of the palate or lingual arch and/or mishandling of the receptor.
- These receptors can be flexed but should never be bent. If the receptor is too large for the area.
- Crimping, creasing, or folding a plate or film receptor damages the emulsion and compromises the quality of the image.

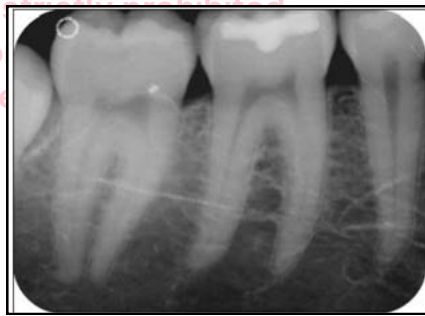

Image: Film receptor scratches

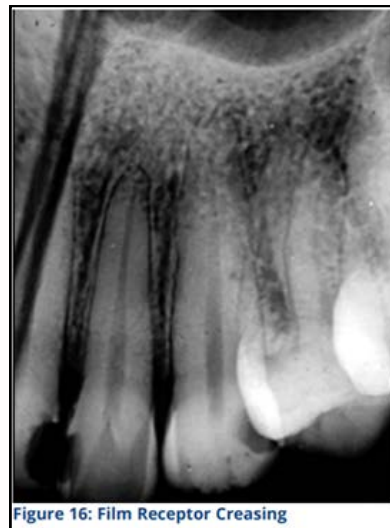

Figure 16: Film Receptor Creasing

THIS IS COPYRIGHTED CONTENT. Unauthorized use, including screenshots, copying, misuse, reuse, or resale of any content from this app, is strictly prohibited. Our app monitors and records all screenshots and recordings. Violators will face strict legal action.

### DISCLAIMER

THIS IS COPYRIGHTED CONTENT. Unauthorized use, including screenshots, copying, misuse, reuse, or resale of any content from this app, is strictly prohibited. Our app monitors and records all screenshots and recordings. Violators will face strict legal action.

DISCLAIMER  
THIS IS COPYRIGHTED CONTENT. Unauthorized use, including screenshots, copying, misuse, reuse, or resale of any content from this app, is strictly prohibited. Our app monitors and records all screenshots and recordings. Violators will face strict legal action.

DISCLAIMER  
THIS IS COPYRIGHTED CONTENT. Unauthorized use, including screenshots, copying, misuse, reuse, or resale of any content from this app, is strictly prohibited. Our app monitors and records all screenshots and recordings. Violators will face strict legal action.

# IOPA AND BITEWING ERRORS

## A) Projection errors:

- It includes:

### 2) Film placement errors:

#### i) Vertical Alignment Errors

- Vertical angulation controls the length of the recorded image.
- When using the paralleling technique and receptor holders, the vertical angulation is dictated by the holding device to direct the x-ray beam perpendicular to both the teeth and receptor.
- Vertical alignment errors often occur with the bisecting angle technique and can result in:

#### i. Elongation:

- Elongation or lengthening of the recorded teeth and surrounding structures results from **under angulation of the x-ray beam (not enough vertical angle)**

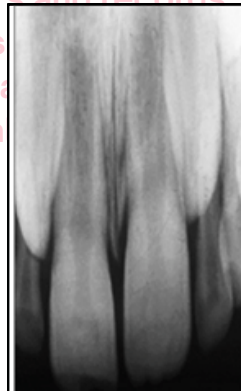


Image: Elongated image

- When elongation occurs using the paralleling technique, the angulation of the x-ray beam is less than the long axis plane of the teeth.

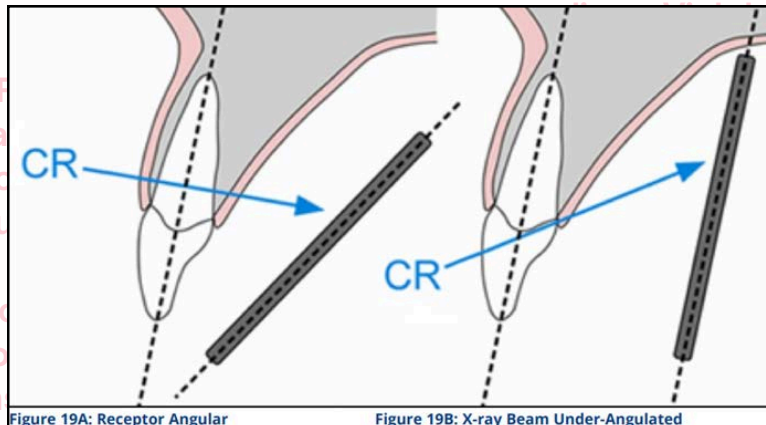


Figure 19A: Receptor Angular

Figure 19B: X-ray Beam Under-Angulated

## DISCLAIMER

THIS IS COPYRIGHTED CONTENT. Unauthorized use, including screenshots, copying, misuse, reuse, or resale of any content from this app, is strictly prohibited. Our app monitors and records all screenshots and recordings. Violators will face strict legal action.

DISCLAIMER  
THIS IS COPYRIGHTED CONTENT. Unauthorized use, including screenshots, copying, misuse, reuse, or resale of any content from this app, is strictly prohibited. Our app monitors and records all screenshots and recordings. Violators will face strict legal action.

THIS IS COPYRIGHTED CONTENT. Unauthorized use, including screenshots, copying, misuse, reuse, or resale of any content from this app, is strictly prohibited. Our app monitors and records all screenshots and recordings. Violators will face strict legal action.

DISCLAIMER



# IOPA AND BITEWING ERRORS

## A) Projection errors:

- It includes:

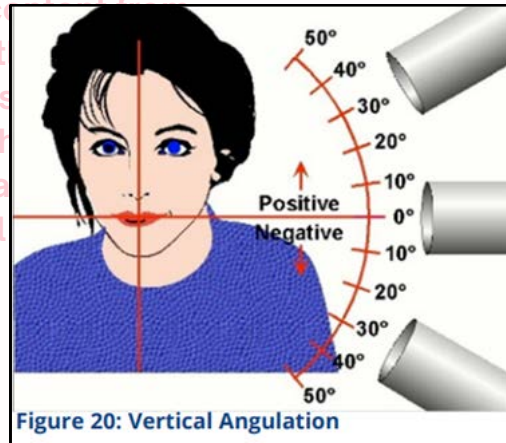
### 2) Film placement errors:

#### i) Vertical Alignment Errors

##### i. Elongation:

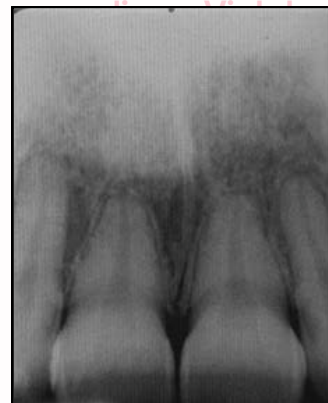
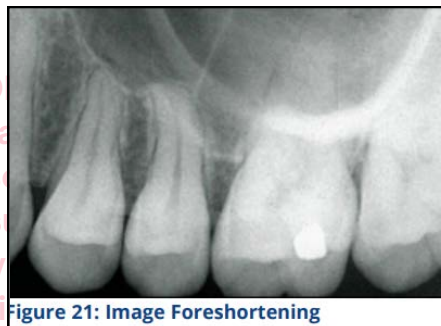Correction:

- To correct this error the clinician must increase the vertical angulation.
- In other words, for the maxillary arch, the positive vertical angulation must be increased (PID pointing down); for the mandibular arch, the negative vertical angulation must be increased (PID pointing up)



##### ii. Foreshortening of the teeth

- Foreshortening or shortening of the recorded teeth and the surrounding structures can also result from improper vertical angulation.



## DISCLAIMER

THIS IS COPYRIGHTED CONTENT. Unauthorized use, including screenshots, copying, misuse, reuse, or resale of any content from this app, is strictly prohibited. Our app monitors and records all screenshots and recordings. Violators will face strict legal action.

DISCLAIMER  
THIS IS COPYRIGHTED CONTENT. Unauthorized use, including screenshots, copying, misuse, reuse, or resale of any content from this app, is strictly prohibited. Our app monitors and records all screenshots and recordings. Violators will face strict legal action.

THIS IS COPYRIGHTED CONTENT. Unauthorized use, including screenshots, copying, misuse, reuse, or resale of any content from this app, is strictly prohibited. Our app monitors and records all screenshots and recordings. Violators will face strict legal action.

DISCLAIMER

# IOPA AND BITEWING ERRORS

## A) Projection errors:

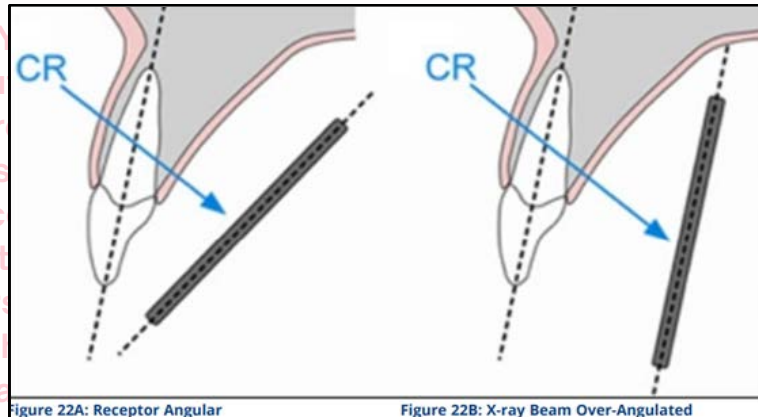
- It includes:

### 2) Film placement errors:

#### i) Vertical Alignment Errors

#### ii. Foreshortening of the teeth

- Foreshortening is the result of over-angulation of the x-ray beam (too much vertical angle).



#### Correction:

- To correct foreshortening when using the paralleling technique, the operator should decrease the positive vertical angulation for maxillary projections and, decrease the negative vertical for mandibular projections.
- This error can also occur if the receptor is not placed parallel to the long axis of the teeth.

THIS IS COPYRIGHTED CONTENT. Unauthorized use, including screenshots, copying, misuse, reuse, or resale of any content from this app, is strictly prohibited. Our app monitors and records all screenshots and recordings. Violators will face strict legal action.

#### DISCLAIMER

THIS IS COPYRIGHTED CONTENT. Unauthorized use, including screenshots, copying, misuse, reuse, or resale of any content from this app, is strictly prohibited. Our app monitors and records all screenshots and recordings. Violators will face strict legal action.

THIS IS COPYRIGHTED CONTENT. Unauthorized use, including screenshots, copying, misuse, reuse, or resale of any content from this app, is strictly prohibited. Our app monitors and records all screenshots and recordings. Violators will face strict legal action.

DISCLAIMER  
THIS IS COPYRIGHTED CONTENT. Unauthorized use, including screenshots, copying, misuse, reuse, or resale of any content from this app, is strictly prohibited. Our app monitors and records all screenshots and recordings. Violators will face strict legal action.

# IOPA AND BITEWING ERRORS

## A) Projection errors:

- It includes:

### 2) Film placement errors:

#### j) Horizontal Alignment Errors

- Proper horizontal alignment of the x-ray beam **will open interproximal contacts** and facilitate a thorough radiographic caries evaluation and assessment of alveolar bone levels, both important components of a thorough clinical and radiographic examination.
- The x-ray beam should be aimed directly between the contact points of the targeted teeth in order to open the interproximal surfaces.

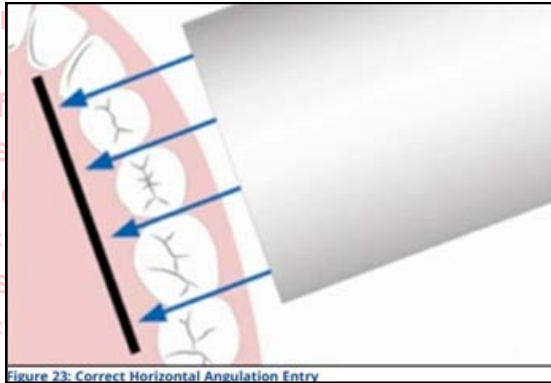


Figure 23: Correct Horizontal Angulation Entry

- Horizontal alignment errors cause the image to shift anteriorly or posteriorly, resulting in the overlapping of the proximal contacts.

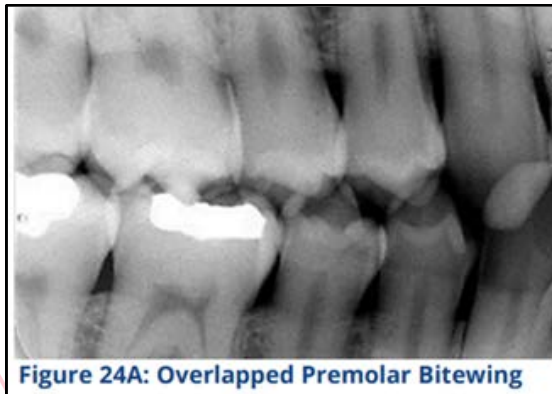

Figure 24A: Overlapped Premolar Bitewing

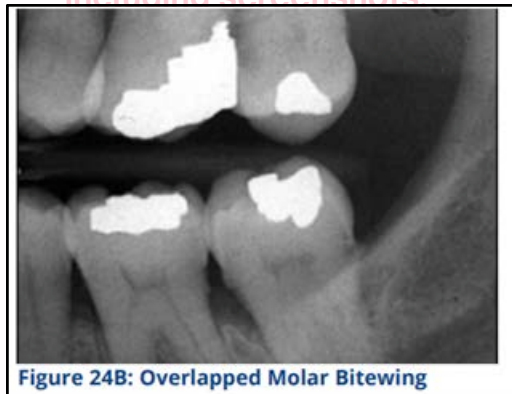

Figure 24B: Overlapped Molar Bitewing

## DISCLAIMER

THIS IS COPYRIGHTED CONTENT. Unauthorized use, including screenshots, copying, misuse, reuse, or resale of any content from this app, is strictly prohibited. Our app monitors and records all screenshots and recordings. Violators will face strict legal action.

DISCLAIMER  
THIS IS COPYRIGHTED CONTENT. Unauthorized use, including screenshots, copying, misuse, reuse, or resale of any content from this app, is strictly prohibited. Our app monitors and records all screenshots and recordings. Violators will face strict legal action.

THIS IS COPYRIGHTED CONTENT. Unauthorized use, including screenshots, copying, misuse, reuse, or resale of any content from this app, is strictly prohibited. Our app monitors and records all screenshots and recordings. Violators will face strict legal action.

# IOPA AND BITEWING ERRORS

## A) Projection errors:

- It includes:

### 2) Film placement errors:

#### k) Beam Centering Errors

- The central ray should be aligned over the center of the receptor with the x-ray beam directed perpendicular to the receptor.
- When this alignment is not observed, a **cone-cut** occurs. **Cone-cuts appear as a clear zone on traditional radiographs** after processing, due to the lack of x-ray exposure of the emulsion.
- **When using digital imaging**, the cone-cut appears as an **opaque or white zone**. The shape of the cone-cut depends on the type of collimator used when exposing the receptor.
- For example, if a round collimator is used, a curved cone-cut will appear.

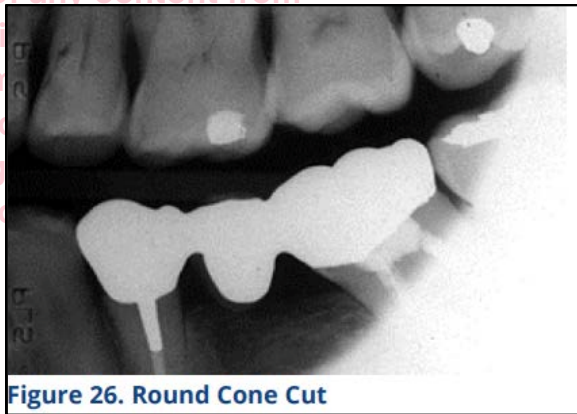

Figure 26. Round Cone Cut

Image: Digital radiograph with cone

- **Squarish or rectangular cone-cuts occur when using a rectangular collimator.**

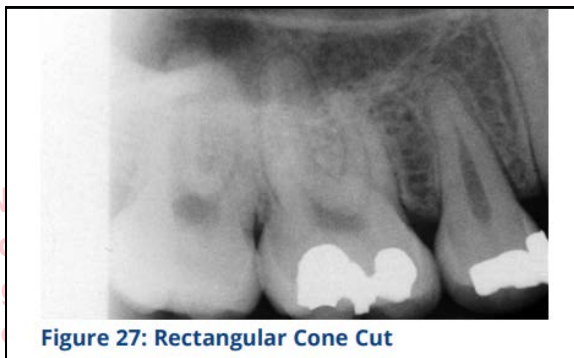

Figure 27: Rectangular Cone Cut

- To correct a cone-cut error, the beam should be re-centered toward the area of non-exposure. Improper assembly of receptor holding devices can also cause cone-cuts.

## DISCLAIMER

THIS IS COPYRIGHTED CONTENT. Unauthorized use, including screenshots, copying, misuse, reuse, or resale of any content from this app, is strictly prohibited. Our app monitors and records all screenshots and recordings. Violators will face strict legal action.

DISCLAIMER  
THIS IS COPYRIGHTED CONTENT. Unauthorized use, including screenshots, copying, misuse, reuse, or resale of any content from this app, is strictly prohibited. Our app monitors and records all screenshots and recordings. Violators will face strict legal action.

THIS IS COPYRIGHTED CONTENT. Unauthorized use, including screenshots, copying, misuse, reuse, or resale of any content from this app, is strictly prohibited. Our app monitors and records all screenshots and recordings. Violators will face strict legal action.

DISCLAIMER



# IOPA AND BITEWING ERRORS

## Summary of technical errors:

Error	Description	Correction
1. Receptor Placement	Inadequate coverage of the Structures radiographed or backwards receptor placement.	Follow established placement criteria for each periapical and bitewing. Expose correct receptor surface.
2. Receptor Handling	Phosphor plate or film with bends, creases, folds that produce artifacts or distort the captured image.	Handle receptors with care and refrain from bending, creasing or marring the emulsion. Use correct receptor size and receptor cushions to improve comfort.
3. Vertical Angulation	Shape distortion in the form of image foreshortening or image elongation.	Decrease the vertical angle to correct foreshortening. Increase the vertical to correct elongation. Ensure proper vertical placement of the receptor in relation to the teeth.
4. Horizontal Angulation	Overlapped or superimposed proximal contacts with image widening.	Direct the x-ray beam through the contact points of the teeth such that the open end of the PID is horizontally parallel to the labial or buccal surfaces of the teeth.
5. Cone cuts	Curved or squarish blank areas where the x-ray beam was not centered over the receptor.	Direct the x-ray beam to the center of the receptor. Ensure proper assembly of receptor-holder.

Table 2. Technical Error Summary.

THIS IS COPYRIGHTED CONTENT. Unauthorized use, including screenshots,

**DISCLAIMER**  
THIS IS COPYRIGHTED CONTENT. Unauthorized use, including screenshots, copying, misuse, reuse, or resale of any content from this app, is strictly prohibited. Our app monitors and records all screenshots and recordings. Violators will face strict legal action.

THIS IS COPYRIGHTED CONTENT. Unauthorized use, including screenshots, copying, misuse, reuse, or resale of any content from this app, is strictly prohibited. Our app monitors and records all screenshots and recordings. Violators will face strict legal action.

THIS IS COPYRIGHTED CONTENT. Unauthorized use, including screenshots, copying, misuse, reuse, or resale of any content from this app, is strictly prohibited. Our app monitors and records all screenshots and recordings. Violators will face strict legal action.

### DISCLAIMER

THIS IS COPYRIGHTED CONTENT. Unauthorized use, including screenshots, copying, misuse, reuse, or resale of any content from this app, is strictly prohibited. Our app monitors and records all screenshots and recordings. Violators will face strict legal action.

# IOPA AND BITEWING ERRORS


## B) Exposure Artifacts

- It includes:

### 1. Film placement errors:

#### a) Blank Image:

- A film that has receive no radiation will have no image & will appear clear film, due to:
  - The x-ray machine is not turned on.
  - The operator had completely failed to align the x-ray PID with the film.
  - The operator may not press the timer button properly to activate the exposure.
  - The film not exposed at all, while another is used twice & produce double image.



#### b) Film Exposed to Light

- Appearance:** the film appears black.
- Cause:** the film accidentally exposed to white light.
- Correction:**
  - Do not unwrap the film in a room with white light.
  - Check the dark room for possible light leaks.
  - Use safe light only during processing.



### DISCLAIMER

THIS IS COPYRIGHTED CONTENT. Unauthorized use, including screenshots, copying, misuse, reuse, or resale of any content from this app, is strictly prohibited. Our app monitors and records all screenshots and recordings. Violators will face strict legal action.

DISCLAIMER  
THIS IS COPYRIGHTED CONTENT. Unauthorized use, including screenshots, copying, misuse, reuse, or resale of any content from this app, is strictly prohibited. Our app monitors and records all screenshots and recordings. Violators will face strict legal action.

DISCLAIMER  
THIS IS COPYRIGHTED CONTENT. Unauthorized use, including screenshots, copying, misuse, reuse, or resale of any content from this app, is strictly prohibited. Our app monitors and records all screenshots and recordings. Violators will face strict legal action.

# IOPA AND BITEWING ERRORS

## B) Exposure Artifacts

- It includes:

### 1. Film placement errors:

#### c) Under/Over Exposure

- Underexposed receptors result in images that are too light or low in density.
- Light images can also be caused by an increase in the source-object distance, or not placing the tube head close enough to the patient's face during exposure.
- Exposure times are based on the assumption that the tube head is no more than 2 centimeters away from the face of the patient.
- Receptors can be underexposed if the exposure switch is not activated for the indicated or correct length of time.
- In other words, the clinician let go of the exposure button too soon.

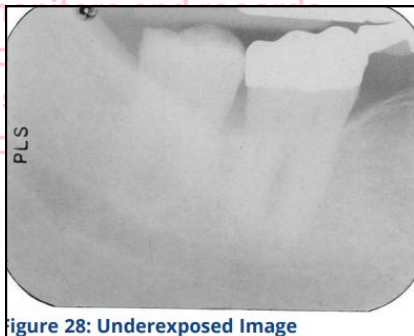

Figure 28: Underexposed Image

- The film appears light also when there is inadequate exposure time, Kvp, mA, or a combination of these factors.
- Correction includes checking the exposure time, Kvp, mA, settings on the x-ray machine before exposing the film.

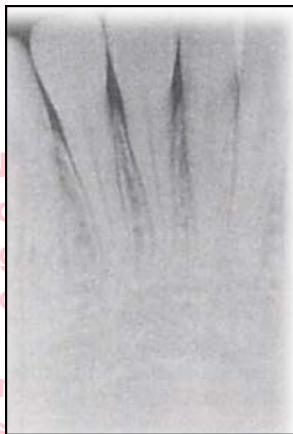

Image: Underexposed film

## DISCLAIMER

THIS IS COPYRIGHTED CONTENT. Unauthorized use, including screenshots, copying, misuse, reuse, or resale of any content from this app, is strictly prohibited. Our app monitors and records all screenshots and recordings. Violators will face strict legal action.

DISCLAIMER  
THIS IS COPYRIGHTED CONTENT. Unauthorized use, including screenshots, copying, misuse, reuse, or resale of any content from this app, is strictly prohibited. Our app monitors and records all screenshots and recordings. Violators will face strict legal action.

DISCLAIMER  
THIS IS COPYRIGHTED CONTENT. Unauthorized use, including screenshots, copying, misuse, reuse, or resale of any content from this app, is strictly prohibited. Our app monitors and records all screenshots and recordings. Violators will face strict legal action.

# IOPA AND BITEWING ERRORS

## B) Exposure Artifacts

- It includes:

### 1. Film placement errors:

#### c) Under/Over Exposure

- Overexposure results in a high density or dark image.
- The causes include improper exposure factor settings or improper assessment of patient size and stature.

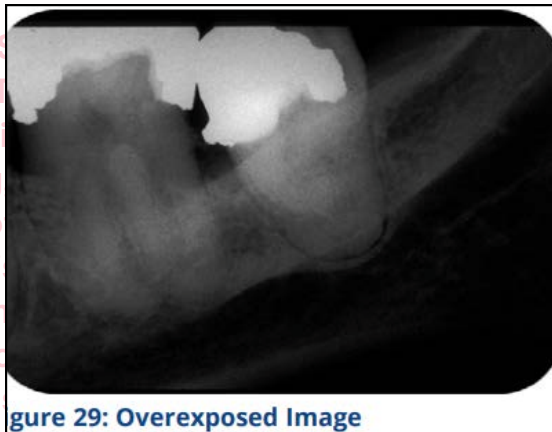
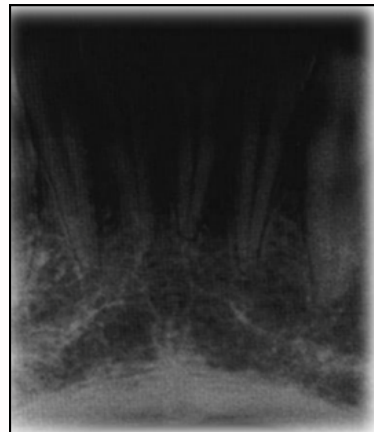
Figure 29: Overexposed Image



- Over exposed film appears dark and can be caused by excessive exposure time, KvP, mA, or a combination of these factors.
- Correction includes check the exposure time, KvP, mA, settings on the x-ray machine before exposing the film.
- Digital images that are dark or high in density can usually be salvaged by software adjustments in density unless the image appears totally black.
- This adjustment in density should be accomplished prior to printing or archiving the image.

THIS IS COPYRIGHTED CONTENT. Unauthorized use, including screenshots, copying, misuse, reuse, or resale of any content from this app, is strictly prohibited. Our app monitors and records all screenshots and recordings. Violators will face strict legal action.

#### DISCLAIMER

THIS IS COPYRIGHTED CONTENT. Unauthorized use, including screenshots, copying, misuse, reuse, or resale of any content from this app, is strictly prohibited. Our app monitors and records all screenshots and recordings. Violators will face strict legal action.

DISCLAIMER  
THIS IS COPYRIGHTED CONTENT. Unauthorized use, including screenshots, copying, misuse, reuse, or resale of any content from this app, is strictly prohibited. Our app monitors and records all screenshots and recordings. Violators will face strict legal action.

DISCLAIMER

THIS IS COPYRIGHTED CONTENT. Unauthorized use, including screenshots, copying, misuse, reuse, or resale of any content from this app, is strictly prohibited. Our app monitors and records all screenshots and recordings. Violators will face strict legal action.

THIS IS COPYRIGHTED CONTENT. Unauthorized use, including screenshots, copying, misuse, reuse, or resale of any content from this app, is strictly prohibited. Our app monitors and records all screenshots and recordings. Violators will face strict legal action.

THIS IS COPYRIGHTED CONTENT. Unauthorized use, including screenshots, copying, misuse, reuse, or resale of any content from this app, is strictly prohibited. Our app monitors and records all screenshots and recordings. Violators will face strict legal action.



# IOPA AND BITEWING ERRORS

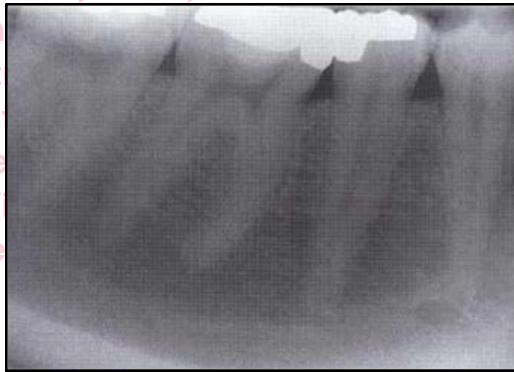## C) Processing Artifacts (for traditional films)

- It includes:

### 1) Time and temperature errors.

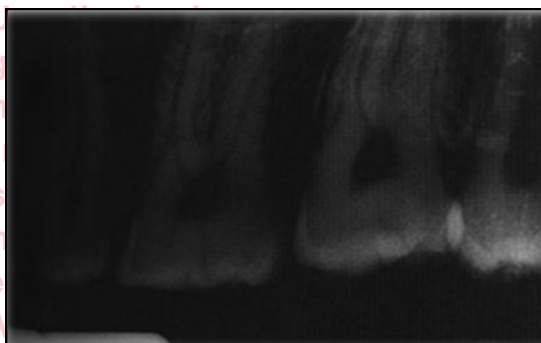
#### a) Under developed film

- Appearance:** The film appears light (faint).
- Cause:**
  - Inadequate developing time.
  - Inaccurate timer.
  - Low developer temperature.
  - Inaccurate thermometer.
  - Depleted or contaminated developer solution



#### b) Over developed film

- Appearance:** The film appears dark.
- Cause:**
  - Excess developing time.
  - Inaccurate timer.
  - High developer temperature.
  - Inaccurate thermometer.
  - Concentrated developer solution



THIS IS COPYRIGHTED CONTENT. Unauthorized use, including screenshots, copying, misuse, reuse, or resale of any content from this app, is strictly prohibited. Our app monitors and records all screenshots and recordings. Violators will face strict legal action.

THIS IS COPYRIGHTED CONTENT. Unauthorized use, including screenshots, copying, misuse, reuse, or resale of any content from this app, is strictly prohibited. Our app monitors and records all screenshots and recordings. Violators will face strict legal action.

#### DISCLAIMER

THIS IS COPYRIGHTED CONTENT. Unauthorized use, including screenshots, copying, misuse, reuse, or resale of any content from this app, is strictly prohibited. Our app monitors and records all screenshots and recordings. Violators will face strict legal action.

DISCLAIMER  
THIS IS COPYRIGHTED CONTENT. Unauthorized use, including screenshots, copying, misuse, reuse, or resale of any content from this app, is strictly prohibited. Our app monitors and records all screenshots and recordings. Violators will face strict legal action.

DISCLAIMER

THIS IS COPYRIGHTED CONTENT. Unauthorized use, including screenshots, copying, misuse, reuse, or resale of any content from this app, is strictly prohibited. Our app monitors and records all screenshots and recordings. Violators will face strict legal action.

# IOPA AND BITEWING ERRORS

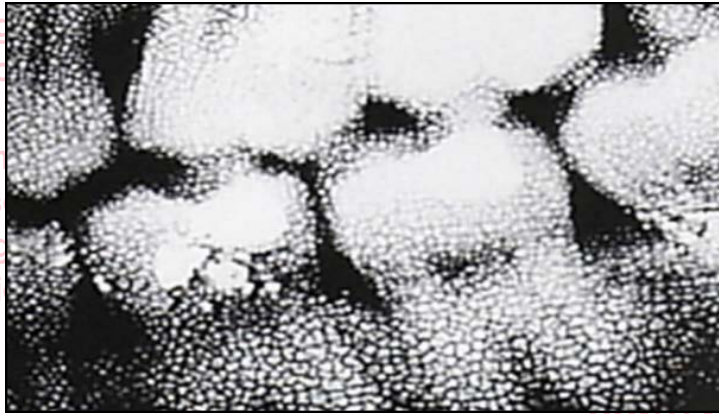
## C) Processing Artifacts (for traditional films)

- It includes:

### 1) Time and temperature errors.

#### c) Reticulation of emulsion

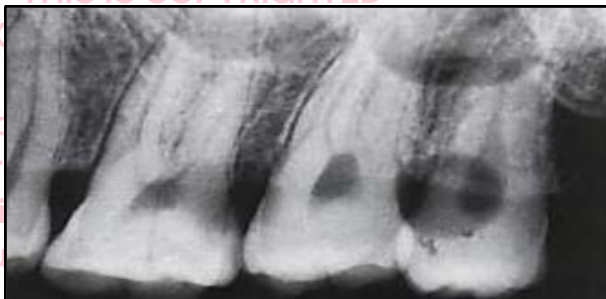- Appearance:** The film appears cracked.
- Cause:** the film is subjected to a sudden temperature change between the developer and water bath.
- Correction:** check the temperature of the processing solutions and water bath.  
Avoid drastic temperature differences between the developer and water bath.



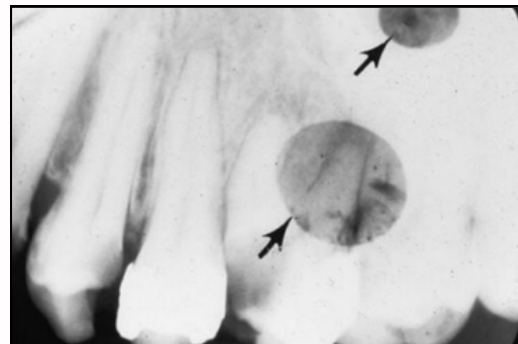### 2) Chemical contamination errors

#### a) Developer spots

- Appearance:** dark spots appear on the film.
- Cause:** developer solution comes in contact with the film before processing.
- Correction:** use clean work area in the dark room. To ensure clean working surface, place a paper towel on the work area before unwrapping films.



Images: Developer spots



#### DISCLAIMER

THIS IS COPYRIGHTED CONTENT. Unauthorized use, including screenshots, copying, misuse, reuse, or resale of any content from this app, is strictly prohibited. Our app monitors and records all screenshots and recordings. Violators will face strict legal action.

DISCLAIMER  
THIS IS COPYRIGHTED CONTENT. Unauthorized use, including screenshots, copying, misuse, reuse, or resale of any content from this app, is strictly prohibited. Our app monitors and records all screenshots and recordings. Violators will face strict legal action.

THIS IS COPYRIGHTED CONTENT. Unauthorized use, including screenshots, copying, misuse, reuse, or resale of any content from this app, is strictly prohibited. Our app monitors and records all screenshots and recordings. Violators will face strict legal action.

DISCLAIMER

# IOPA AND BITEWING ERRORS

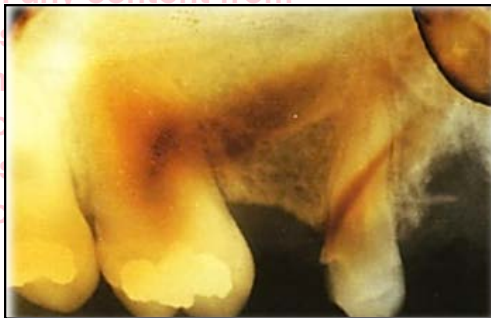## C) Processing Artifacts (for traditional films)

- It includes:

### 2) Chemical contamination errors

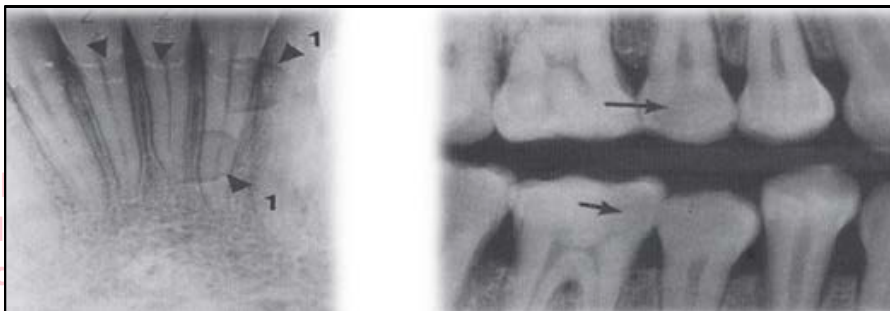
#### b) Yellow-brown stains

- Appearance:** the film appear yellowish-brown.
- Cause:**
  - exhausted developer or fixer.
  - Insufficient fixation time.
  - Insufficient rinsing.
- Correction:** replace depleted developer and fixer solutions with fresh one. Make sure that the film has adequate fixation and rinsing time. Rinse processed film in circulating cold water.



#### c) Deposits on the film:

- Chemical precipitants that adhere to the film due to contamination, improperly prepared, or exhausted solutions, unclean film hanger clips.



THIS IS COPYRIGHTED CONTENT. Unauthorized use, including screenshots, copying, misuse, reuse, or resale of any content from this app, is strictly prohibited. Our app monitors and records all screenshots and recordings. Violators will face strict legal action.

DISCLAIMER  
THIS IS COPYRIGHTED CONTENT. Unauthorized use, including screenshots, copying, misuse, reuse, or resale of any content from this app, is strictly prohibited. Our app monitors and records all screenshots and recordings. Violators will face strict legal action.

DISCLAIMER

THIS IS COPYRIGHTED CONTENT. Unauthorized use, including screenshots, copying, misuse, reuse, or resale of any content from this app, is strictly prohibited. Our app monitors and records all screenshots and recordings. Violators will face strict legal action.

DISCLAIMER

THIS IS COPYRIGHTED CONTENT. Unauthorized use, including screenshots, copying, misuse, reuse, or resale of any content from this app, is strictly prohibited. Our app monitors and records all screenshots and recordings. Violators will face strict legal action.



# IOPA AND BITEWING ERRORS

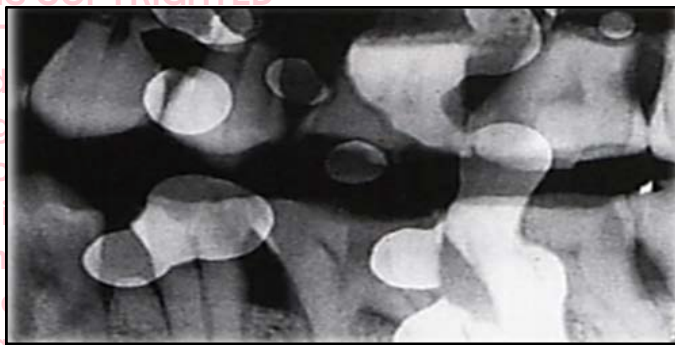
## C) Processing Artifacts (for traditional films)

- It includes:

### 2) Chemical contamination errors

#### d) Fixer Spots

- Appearance:** white spots appear on the film.
- Cause:** fixer solution come in contact with the film before processing.
- Correction:** use clean work area in the dark room. Place a paper towel on the work area before unwrapping films.

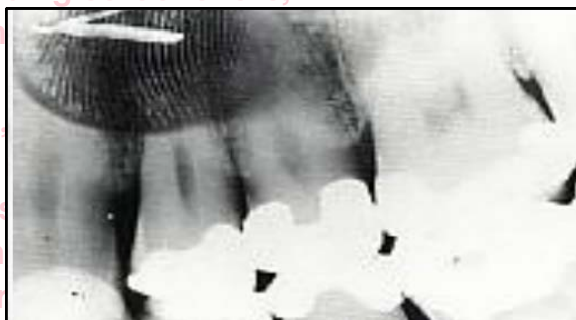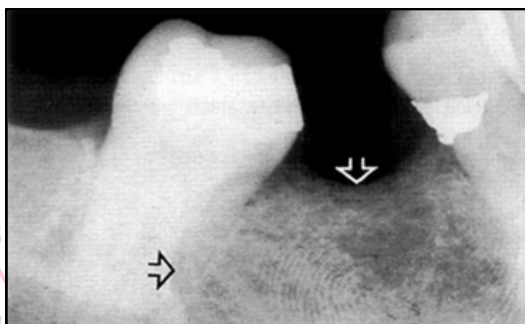


Images: Fixer spots

### 3) Film handling errors

#### a) Fingerprint artifact

- Appearance:** black fingerprint appears on the film.
- Cause:** the film is touched by fingers contaminated with developer.
- Correction:** wash and dry hands before processing films. Work in a clean area. Handle the film by the edges only.



DISCLAIMER

THIS IS COPYRIGHTED CONTENT. Unauthorized use, including screenshots, copying, misuse, reuse, or resale of any content from this app, is strictly prohibited. Our app monitors and records all screenshots and recordings. Violators will face strict legal action.

DISCLAIMER  
THIS IS COPYRIGHTED CONTENT. Unauthorized use, including screenshots, copying, misuse, reuse, or resale of any content from this app, is strictly prohibited. Our app monitors and records all screenshots and recordings. Violators will face strict legal action.

DISCLAIMER  
THIS IS COPYRIGHTED CONTENT. Unauthorized use, including screenshots, copying, misuse, reuse, or resale of any content from this app, is strictly prohibited. Our app monitors and records all screenshots and recordings. Violators will face strict legal action.



# IOPA AND BITEWING ERRORS

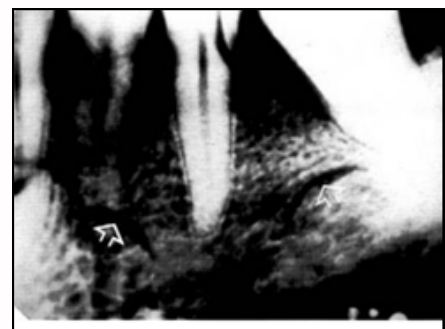

## C) Processing Artifacts (for traditional films)

- It includes:

### 3) Film handling errors

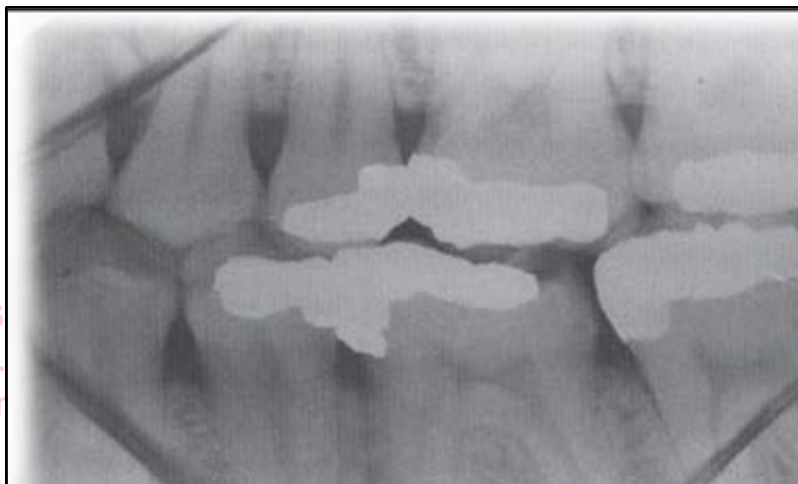
#### b) Finger nail marks

- Appearance:** black crescent-shaped marks appear on the film.
- Cause:** the film emulsion is damaged by the operator's finger nail during rough handling of the film.
- Correction:** gently handle the film by the edges only.



#### c) Bend Marks (black line marks)

- Appearance:** a thin radiolucent line appears on the film.
- Cause:** the film is creased and the film emulsion cracked
- Correction:** do not bend or crease the film excessively instead gently soften the corners of the film before placing in the patient's mouth.



THIS IS COPYRIGHTED CONTENT. Unauthorized use, including screenshots, copying, misuse, reuse, or resale of any content from this app, is strictly prohibited. Our app monitors and records all screenshots and recordings. Violators will face strict legal action.

DISCLAIMER  
THIS IS COPYRIGHTED CONTENT. Unauthorized use, including screenshots, copying, misuse, reuse, or resale of any content from this app, is strictly prohibited. Our app monitors and records all screenshots and recordings. Violators will face strict legal action.

#### DISCLAIMER

THIS IS COPYRIGHTED CONTENT. Unauthorized use, including screenshots, copying, misuse, reuse, or resale of any content from this app, is strictly prohibited. Our app monitors and records all screenshots and recordings. Violators will face strict legal action.

# IOPA AND BITEWING ERRORS

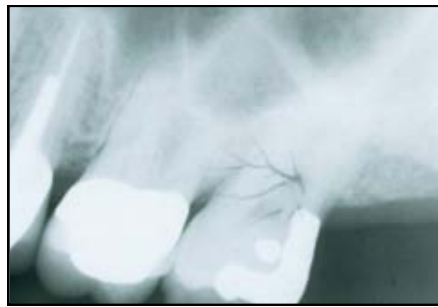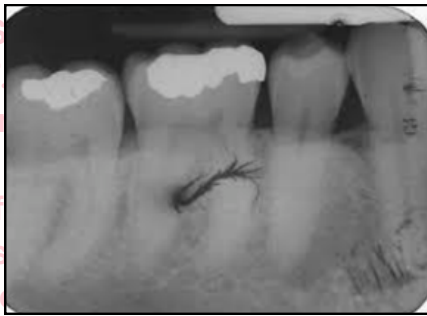## C) Processing Artifacts (for traditional films)

- It includes:

### 3) Film handling errors

#### d) Static electricity

- Appearance:** thin, black branching lines appear on the film.
- Cause:** opening a film packet quickly. Opening a film packet before touching another object such as the film processor.
- Correction:** open film packets slowly. Touch a conductive object before unwrapping films.

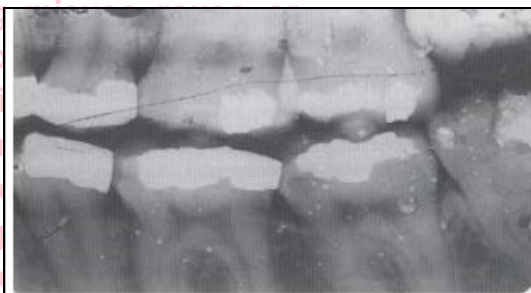


#### e) Film Fog

- Appears as a dull-gray low contrast image due to:
  - Use of out-dated film
  - Improper film storage.
  - Radiation before & after exposure.
  - Improper safelight condition.
  - Higher developing solution temperature.
  - White light leaks in the dark room
- Correction:** check the filter and bulb wattage of the safe light.

#### f) Air bubbles

- Appearance:** white spots appear on the film
- Cause:** air is trapped on the film surface after the film is placed in the processing solution. Air bubbles prevent the chemicals from affecting the emulsion in the area.
- Correction:** gently agitate and stir film racks after placing them in the processing solution.



DISCLAIMER

THIS IS COPYRIGHTED CONTENT. Unauthorized use, including screenshots, copying, misuse, reuse, or resale of any content from this app, is strictly prohibited. Our app monitors and records all screenshots and recordings. Violators will face strict legal action.

DISCLAIMER

THIS IS COPYRIGHTED CONTENT. Unauthorized use, including screenshots, copying, misuse, reuse, or resale of any content from this app, is strictly prohibited. Our app monitors and records all screenshots and recordings. Violators will face strict legal action.

THIS IS COPYRIGHTED CONTENT. Unauthorized use, including screenshots, copying, misuse, reuse, or resale of any content from this app, is strictly prohibited. Our app monitors and records all screenshots and recordings. Violators will face strict legal action.

DISCLAIMER

# IOPA AND BITEWING ERRORS

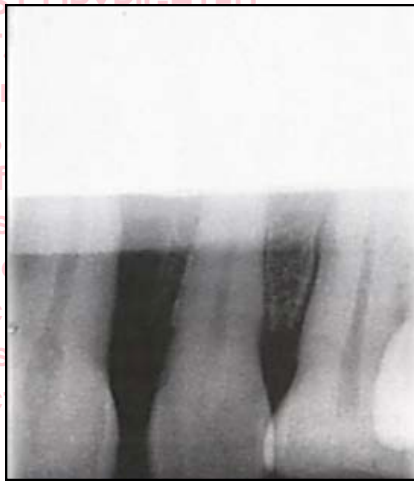## C) Processing Artifacts (for traditional films)

- It includes:

### 3) Film handling errors

#### g) Developer cut off:

- **Appearance:** a straight white border appears on the film
- **Cause:** low level of developer solution that represents an under developed portion of the film.
- **Correction:** check the developer level before processing films. Make sure that all the film parts are completely immersed in the developer solution.



#### h) Fixer cut off

- **Appearance:** a straight black border appears on the film.
- **Cause:** low level of fixer solution that represents an unfixed portion of the film.
- **Correction:** check the fixer level before processing films. Make sure that all the film parts are completely immersed in the fixer solution.

THIS IS COPYRIGHTED CONTENT. Unauthorized use, including screenshots, copying, misuse, reuse, or resale of any content from this app, is strictly prohibited. Our app monitors and records all screenshots and recordings. Violators will face strict legal action.

DISCLAIMER

THIS IS COPYRIGHTED CONTENT. Unauthorized use, including screenshots, copying, misuse, reuse, or resale of any content from this app, is strictly prohibited. Our app monitors and records all screenshots and recordings. Violators will face strict legal action.

DISCLAIMER

THIS IS COPYRIGHTED CONTENT. Unauthorized use, including screenshots, copying, misuse, reuse, or resale of any content from this app, is strictly prohibited. Our app monitors and records all screenshots and recordings. Violators will face strict legal action.

THIS IS COPYRIGHTED CONTENT. Unauthorized use, including screenshots, copying, misuse, reuse, or resale of any content from this app, is strictly prohibited. Our app monitors and records all screenshots and recordings. Violators will face strict legal action.

THIS IS COPYRIGHTED CONTENT. Unauthorized use, including screenshots, copying, misuse, reuse, or resale of any content from this app, is strictly prohibited. Our app monitors and records all screenshots and recordings. Violators will face strict legal action.

DISCLAIMER

# IOPA AND BITEWING ERRORS

## Summary:

- Film too dark

### Possible causes:

- Over exposure owing to:
  - a. Faulty X-ray equipment, e.g., timer
  - b. Incorrect exposure time setting by the operator
- Overdevelopment owing to:
  - a. Excessive time in the developer solution
  - b. Developer solution too hot
  - c. Developer solution too concentrated
- Fogging owing to:
  - a. Poor storage conditions: \* Allowing exposure to stray radiation
  - b. Too warm — Old film stock i.e. films used after expiry date
  - c. Faulty cassettes allowing ingress of stray light
  - d. Faulty darkroom processing unit: Allowing leakage of stray light.
  - e. Faulty safe-light OR Thin patient tissues.

- Film too pale

### Possible causes:

- Underexposure owing to:
  - a. Faulty X-ray equipment, e.g. timer
  - b. Incorrect exposure time setting by the operator
  - c. Failure to keep timer switch depressed throughout the exposure

THIS IS COPYRIGHTED CONTENT. Unauthorized use, including screenshots, copying, misuse, reuse, or resale of any content from this app, is strictly prohibited. Our app monitors and records all screenshots and recordings. Violators will face strict legal action.

## DISCLAIMER

THIS IS COPYRIGHTED CONTENT. Unauthorized use, including screenshots, copying, misuse, reuse, or resale of any content from this app, is strictly prohibited. Our app monitors and records all screenshots and recordings. Violators will face strict legal action.

DISCLAIMER  
THIS IS COPYRIGHTED CONTENT. Unauthorized use, including screenshots, copying, misuse, reuse, or resale of any content from this app, is strictly prohibited. Our app monitors and records all screenshots and recordings. Violators will face strict legal action.

DISCLAIMER

THIS IS COPYRIGHTED CONTENT. Unauthorized use, including screenshots, copying, misuse, reuse, or resale of any content from this app, is strictly prohibited. Our app monitors and records all screenshots and recordings. Violators will face strict legal action.



# DENTAL CARIES RADIOLOGY

(Source- Oral Radiology PRINCIPLES and INTERPRETATION Sixth Edition by STUART C. WHITE and MICHAEL J. PHAROAH)

- Dental caries is a multifactorial disease with interaction between three factors, the tooth, the microflora, and the diet.
- Radiography is a valuable supplement to a thorough clinical examination of the teeth for detecting caries.
- However, when the surface is clinically intact (i.e., no breakdown leading to cavitation has occurred), even the most meticulous examination may fail to reveal demineralizations beneath the surface, including occlusal surfaces.
- Clinical access to proximal tooth surfaces in contact is limited clinical studies have shown that a radiologic examination can reveal carious lesions that would otherwise remain undetected both in occlusal and proximal surface.
- The **bitewing projection** is the most useful radiologic examination for detecting caries.
- **Periapical radiographs** are useful primarily for detecting changes in the **periapical bone**. Use of a paralleling technique for obtaining periapical radiographs increases the value of this projection in detecting caries of both anterior and posterior teeth, especially with heavily restored teeth.

## Radiographic Detection of Lesions

### 1) PROXIMAL SURFACES

- Lesions involving proximal surfaces **most commonly** are found in the area between the **contact point** and the **free gingival margin**.

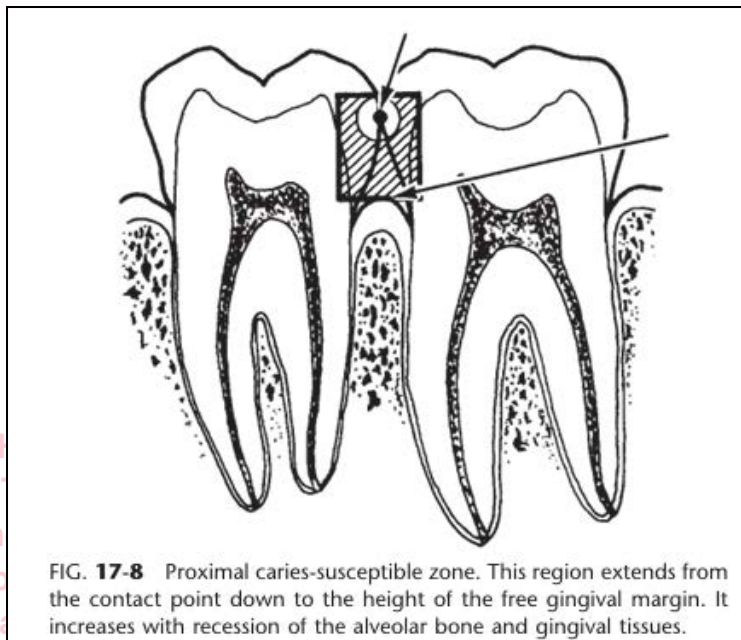


FIG. 17-8 Proximal caries-susceptible zone. This region extends from the contact point down to the height of the free gingival margin. It increases with recession of the alveolar bone and gingival tissues.

#### DISCLAIMER

THIS IS COPYRIGHTED CONTENT. Unauthorized use, including screenshots, copying, misuse, reuse, or resale of any content from this app, is strictly prohibited. Our app monitors and records all screenshots and recordings. Violators will face strict legal action.

#### DISCLAIMER

THIS IS COPYRIGHTED CONTENT. Unauthorized use, including screenshots, copying, misuse, reuse, or resale of any content from this app, is strictly prohibited. Our app monitors and records all screenshots and recordings. Violators will face strict legal action.

THIS IS COPYRIGHTED CONTENT. Unauthorized use, including screenshots, copying, misuse, reuse, or resale of any content from this app, is strictly prohibited. Our app monitors and records all screenshots and recordings. Violators will face strict legal action.

# DENTAL CARIES RADIOLOGY

(Source- Oral Radiology PRINCIPLES and INTERPRETATION Sixth Edition by STUART C. WHITE and MICHAEL J. PHAROAH)

## Radiographic Detection of Lesions

### 1) PROXIMAL SURFACES

- The shape of the early radiolucent lesion in the enamel is **classically a triangle with its broad base at the tooth surface** spreading along the enamel rods, but other appearances are also common, such as a notch, a dot, a band, or a thin line.

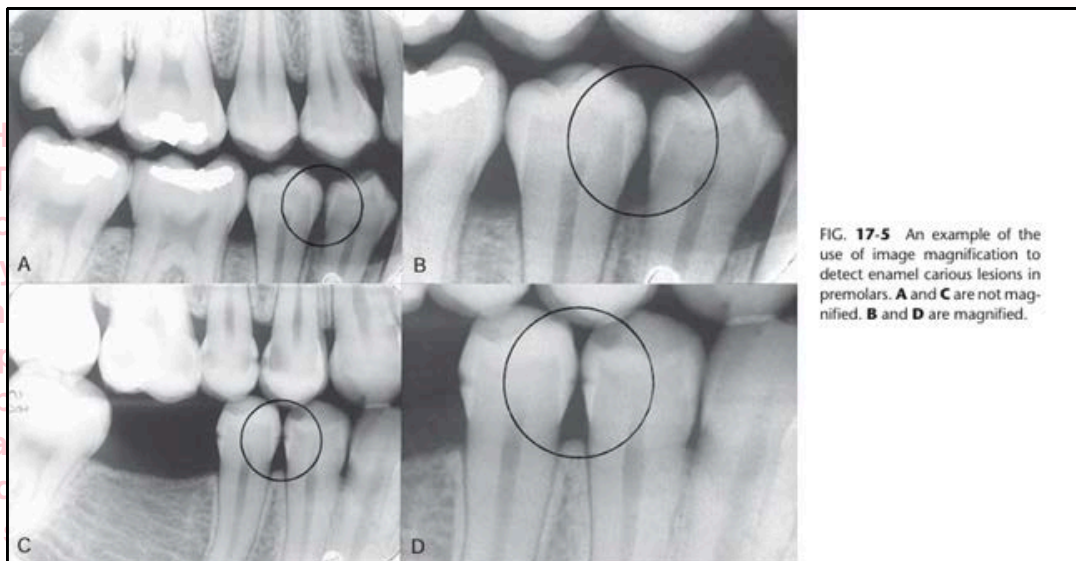


Image: Enamel Carious lesion

- When the demineralizing front reaches the dentino-enamel junction (DEJ), it spreads along the junction, frequently forming the base of a second triangle with apex directed toward the pulp. This triangle typically has a wider base than in the enamel and progresses toward the pulp along the direction of the dentinal tubules.

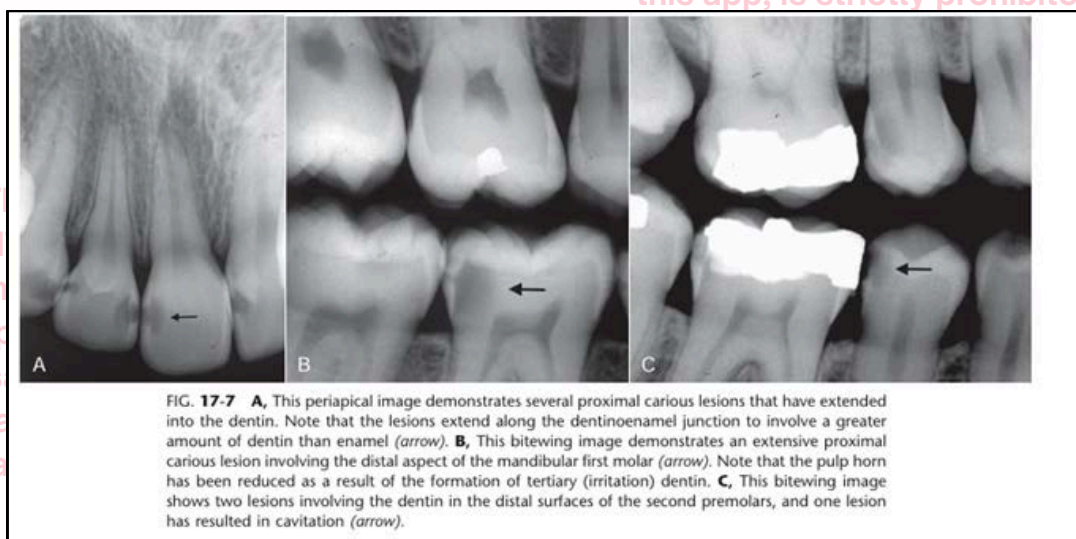


Image: Carious lesion extending to dentin.

#### DISCLAIMER

THIS IS COPYRIGHTED CONTENT. Unauthorized use, including screenshots, copying, misuse, reuse, or resale of any content from this app, is strictly prohibited. Our app monitors and records all screenshots and recordings. Violators will face strict legal action.

DISCLAIMER

THIS IS COPYRIGHTED CONTENT. Unauthorized use, including screenshots, copying, misuse, reuse, or resale of any content from this app, is strictly prohibited. Our app monitors and records all screenshots and recordings. Violators will face strict legal action.

THIS IS COPYRIGHTED CONTENT. Unauthorized use, including screenshots, copying, misuse, reuse, or resale of any content from this app, is strictly prohibited. Our app monitors and records all screenshots and recordings. Violators will face strict legal action.

DISCLAIMER

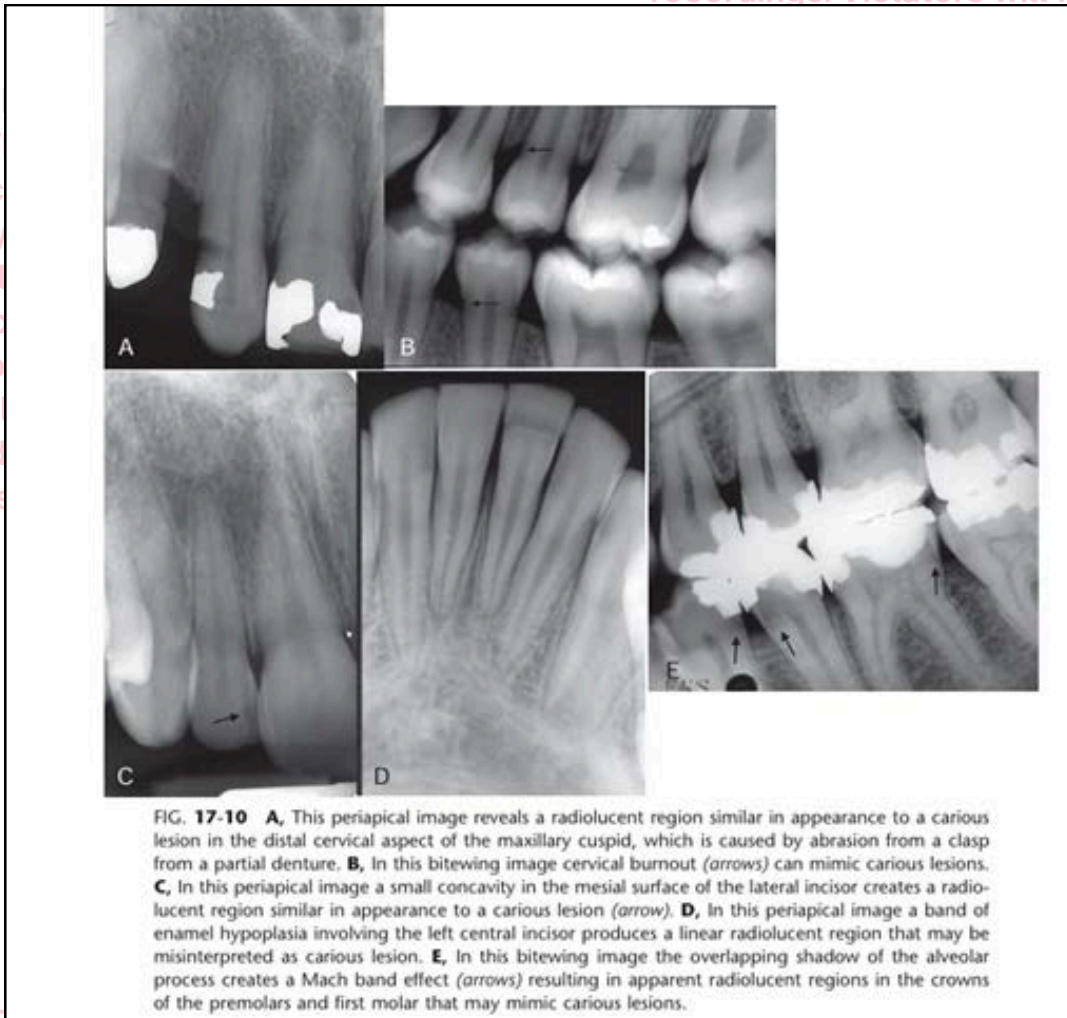
# DENTAL CARIES RADIOLOGY

(Source- Oral Radiology PRINCIPLES and INTERPRETATION Sixth Edition by STUART C. WHITE and MICHAEL J. PHAROAH)

## Radiographic Detection of Lesions

### 1) PROXIMAL SURFACES

- Various morphologic phenomena, such as pits and fissures, cervical burnout, and Mach band effect, and dental anomalies, such as hypoplastic pits and concavities produced by wear, can mimic the appearance of a carious lesion so correlation with history and thorough clinical examination is of utmost importance.



THIS IS COPYRIGHTED CONTENT. Unauthorized use, including screenshots, copying, misuse, reuse, or resale of any content from this app, is strictly prohibited. Our app monitors and records all screenshots and recordings. Violators will face strict legal action.

#### DISCLAIMER

THIS IS COPYRIGHTED CONTENT. Unauthorized use, including screenshots, copying, misuse, reuse, or resale of any content from this app, is strictly prohibited. Our app monitors and records all screenshots and recordings. Violators will face strict legal action.

#### DISCLAIMER

THIS IS COPYRIGHTED CONTENT. Unauthorized use, including screenshots, copying, misuse, reuse, or resale of any content from this app, is strictly prohibited. Our app monitors and records all screenshots and recordings. Violators will face strict legal action.

THIS IS COPYRIGHTED CONTENT. Unauthorized use, including screenshots, copying, misuse, reuse, or resale of any content from this app, is strictly prohibited. Our app monitors and records all screenshots and recordings. Violators will face strict legal action.

#### DISCLAIMER



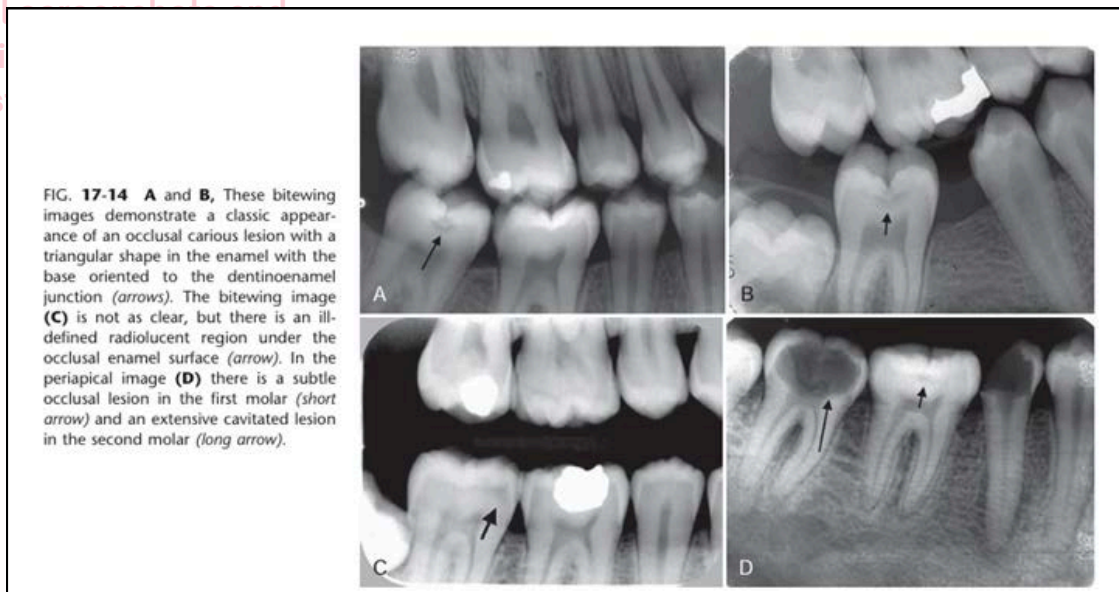
# DENTAL CARIES RADIOLOGY

(Source- Oral Radiology PRINCIPLES and INTERPRETATION Sixth Edition by STUART C. WHITE and MICHAEL J. PHAROAH)

## Radiographic Detection of Lesions

### 2) OCCLUSAL SURFACES

- Carious lesions in children and adolescents most often occur on occlusal surfaces of posterior teeth.
- The demineralization process originates in enamel pits and fissures where bacterial plaque can gather.
- The lesion spreads along the enamel rods and, if undisturbed, penetrates to the DEJ, where it may be seen as a thin radiolucent line between enamel and dentin
- Occlusal lesions **commonly start** in the sides of a **fissure wall** rather than at the base and then tend to penetrate nearly perpendicularly toward the DEJ.
- Early lesions appear clinically as chalky white, yellow, brown, or black discolorations of the occlusal fissures.
- The classic radiographic appearance of lesions extending into the dentin is a broad-based, radiolucent zone, often beneath a fissure, with little or no apparent changes in the enamel.
- The deeper the occlusal lesion, the easier it is to detect on the radiograph.



- As an occlusal lesion spreads through the dentin, it undermines the enamel, and eventually masticatory forces cause cavitation.

#### DISCLAIMER

THIS IS COPYRIGHTED CONTENT. Unauthorized use, including screenshots, copying, misuse, reuse, or resale of any content from this app, is strictly prohibited. Our app monitors and records all screenshots and recordings. Violators will face strict legal action.

#### DISCLAIMER

THIS IS COPYRIGHTED CONTENT. Unauthorized use, including screenshots, copying, misuse, reuse, or resale of any content from this app, is strictly prohibited. Our app monitors and records all screenshots and recordings. Violators will face strict legal action.

THIS IS COPYRIGHTED CONTENT. Unauthorized use, including screenshots, copying, misuse, reuse, or resale of any content from this app, is strictly prohibited. Our app monitors and records all screenshots and recordings. Violators will face strict legal action.

#### DISCLAIMER



# DENTAL CARIES RADIOLOGY

(Source- Oral Radiology PRINCIPLES and INTERPRETATION Sixth Edition by STUART C. WHITE and MICHAEL J. PHAROAH)

## Radiographic Detection of Lesions

### 3) BUCCAL AND LINGUAL SURFACES

- Buccal and lingual carious lesions often occur in **enamel pits and fissures of teeth**.
- When small, these lesions are usually round and as they enlarge, they become elliptic or semilunar.
- They demonstrate sharp, well-defined borders.
- It may be difficult to differentiate between buccal and lingual carious lesions on a radiograph.
- When viewing buccal or lingual lesions, the clinician should look for a uniform non-carious region of enamel surrounding the apparent radiolucency.
- This well-defined circular area represents parallel non-carious enamel rods surrounding the buccal or palatal lesion.

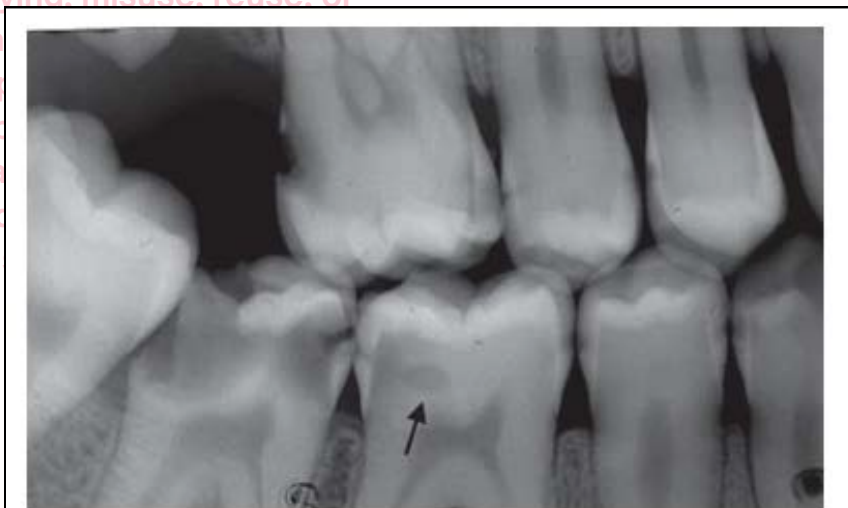

FIG. 17-15 This bitewing image reveals the presence of a small buccal lesion (arrow) involving the mandibular first molar. Note the presence of 12 proximal carious lesions. Also, the abnormal position of the mandibular third molar created an enhanced site for plaque accumulation resulting in an extensive carious lesion involving the second molar.

- Clinical evaluation with visual and tactile methods is usually the definitive method of detecting buccal or lingual lesions.

#### DISCLAIMER

THIS IS COPYRIGHTED CONTENT. Unauthorized use, including screenshots, copying, misuse, reuse, or resale of any content from this app, is strictly prohibited. Our app monitors and records all screenshots and recordings. Violators will face strict legal action.

#### DISCLAIMER

THIS IS COPYRIGHTED CONTENT. Unauthorized use, including screenshots, copying, misuse, reuse, or resale of any content from this app, is strictly prohibited. Our app monitors and records all screenshots and recordings. Violators will face strict legal action.

THIS IS COPYRIGHTED CONTENT. Unauthorized use, including screenshots, copying, misuse, reuse, or resale of any content from this app, is strictly prohibited. Our app monitors and records all screenshots and recordings. Violators will face strict legal action.

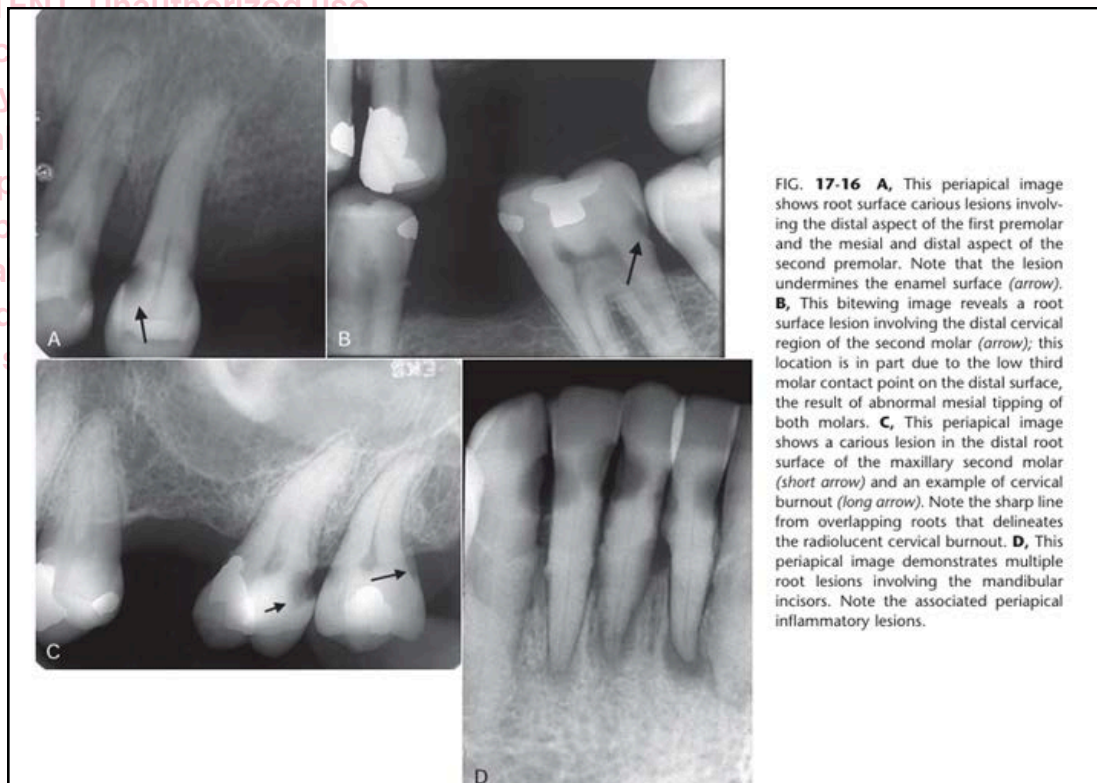
# DENTAL CARIES RADIOLOGY

(Source- Oral Radiology PRINCIPLES and INTERPRETATION Sixth Edition by STUART C. WHITE and MICHAEL J. PHAROAH)

## Radiographic Detection of Lesions

### 4) ROOT SURFACES

- Root surface lesions involve both cementum and dentin and are associated with gingival recession.
- The exposed cementum is relatively soft, near the cementsoenamel junction, and it rapidly degrades by attrition, abrasion, and erosion.
- Root surface caries should be detected clinically, and most often radiographs are not needed for diagnosis.
- In proximal root surfaces radiologic examination may reveal lesions that have gone undetected.



THIS IS COPYRIGHTED CONTENT. Unauthorized use, including screenshots, copying, misuse, reuse, or resale of any content from this app, is strictly prohibited. Our app monitors and records all screenshots and recordings. Violators will face strict legal action.

#### DISCLAIMER

THIS IS COPYRIGHTED CONTENT. Unauthorized use, including screenshots, copying, misuse, reuse, or resale of any content from this app, is strictly prohibited. Our app monitors and records all screenshots and recordings. Violators will face strict legal action.

DISCLAIMER  
THIS IS COPYRIGHTED CONTENT. Unauthorized use, including screenshots, copying, misuse, reuse, or resale of any content from this app, is strictly prohibited. Our app monitors and records all screenshots and recordings. Violators will face strict legal action.

THIS IS COPYRIGHTED CONTENT. Unauthorized use, including screenshots, copying, misuse, reuse, or resale of any content from this app, is strictly prohibited. Our app monitors and records all screenshots and recordings. Violators will face strict legal action.

DISCLAIMER

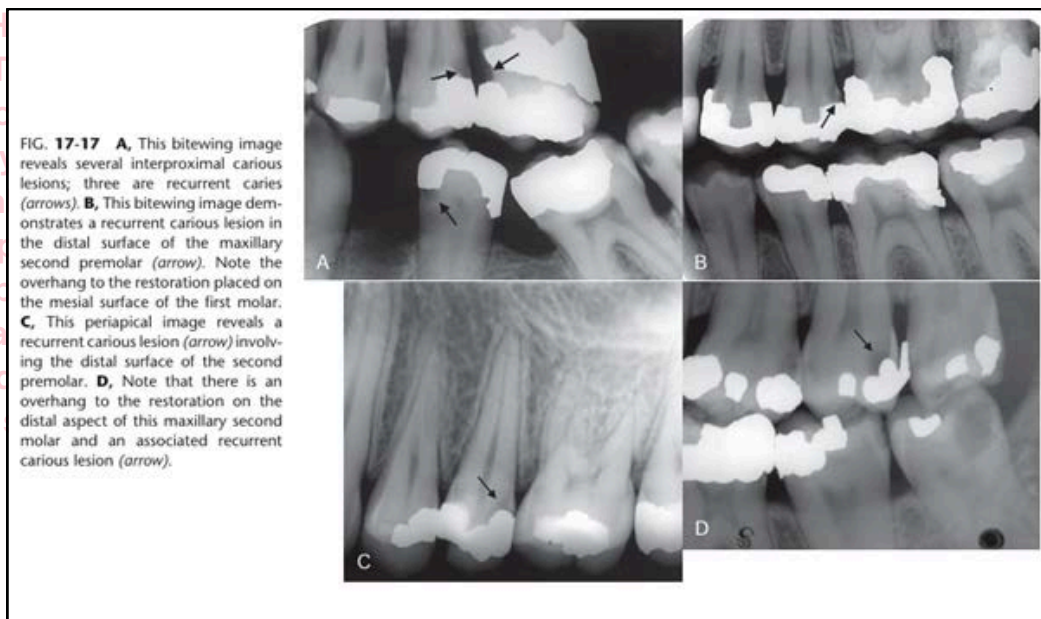
# DENTAL CARIES RADIOLOGY

(Source- Oral Radiology PRINCIPLES and INTERPRETATION Sixth Edition by STUART C. WHITE and MICHAEL J. PHAROAH)

## Radiographic Detection of Lesions

### 5) ASSOCIATED WITH DENTAL RESTORATIONS

- A carious lesion developing at the margin of an existing restoration may be termed secondary or recurrent caries.
- A lesion developing in a restored surface is most frequently a new primary demineralization, either because of faulty shaping or inadequate extension of the restoration leading to plaque accumulation.
- These lesions (secondary caries) should be treated as any new carious lesion.



- A lesion next to a restoration may be obscured by the radiopaque image of the restoration.
- Thus, two radiographic views made at different horizontal or vertical angulations of the central ray can be an aid where there are multiple radiopaque restorations.
- Also, the detection of secondary carious lesions depends on a careful clinical examination.
- **Recurrent lesions at the mesio-gingival and disto-gingival margins are most frequently detected radiographically.**
- Restorative materials vary in their radiographic appearance, some materials can be confused with caries.
- Composite, plastic, or silicate restorations also may simulate lesions. It is often possible, however, to identify and differentiate these radiolucent materials from caries by their well-defined and smooth outline reflecting the preparation or from their radiopaque liners.

#### DISCLAIMER

THIS IS COPYRIGHTED CONTENT. Unauthorized use, including screenshots, copying, misuse, reuse, or resale of any content from this app, is strictly prohibited. Our app monitors and records all screenshots and recordings. Violators will face strict legal action.

#### DISCLAIMER

THIS IS COPYRIGHTED CONTENT. Unauthorized use, including screenshots, copying, misuse, reuse, or resale of any content from this app, is strictly prohibited. Our app monitors and records all screenshots and recordings. Violators will face strict legal action.

THIS IS COPYRIGHTED CONTENT. Unauthorized use, including screenshots, copying, misuse, reuse, or resale of any content from this app, is strictly prohibited. Our app monitors and records all screenshots and recordings. Violators will face strict legal action.

#### DISCLAIMER

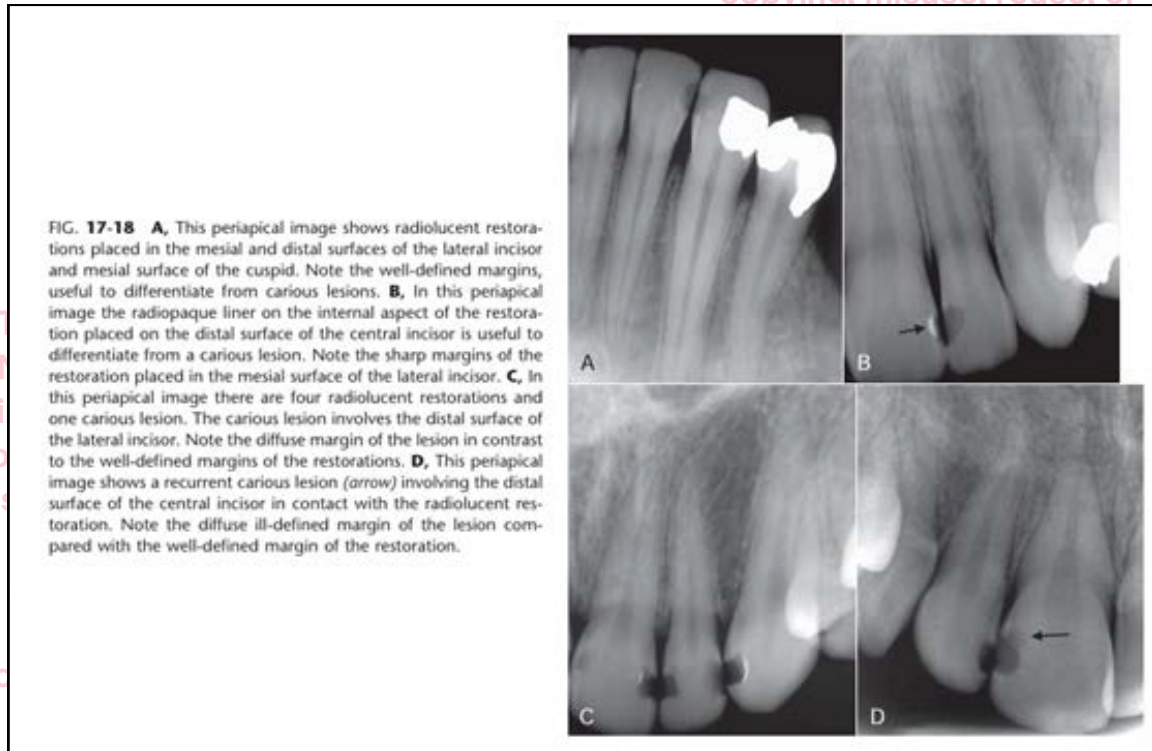


# DENTAL CARIES RADIOLOGY

(Source- Oral Radiology PRINCIPLES and INTERPRETATION Sixth Edition by STUART C. WHITE and MICHAEL J. PHAROAH)

## Radiographic Detection of Lesions

### 5) ASSOCIATED WITH DENTAL RESTORATIONS



THIS IS COPYRIGHTED CONTENT. Unauthorized use, including screenshots, copying, misuse, reuse, or resale of any content from this app, is strictly prohibited. Our app monitors and records all screenshots and recordings. Violators will face strict legal action.

#### DISCLAIMER

THIS IS COPYRIGHTED CONTENT. Unauthorized use, including screenshots, copying, misuse, reuse, or resale of any content from this app, is strictly prohibited. Our app monitors and records all screenshots and recordings. Violators will face strict legal action.

THIS IS COPYRIGHTED CONTENT. Unauthorized use, including screenshots, copying, misuse, reuse, or resale of any content from this app, is strictly prohibited. Our app monitors and records all screenshots and recordings. Violators will face strict legal action.

**DISCLAIMER**  
THIS IS COPYRIGHTED CONTENT. Unauthorized use, including screenshots, copying, misuse, reuse, or resale of any content from this app, is strictly prohibited. Our app monitors and records all screenshots and recordings. Violators will face strict legal action.

DISCLAIMER

THIS IS COPYRIGHTED CONTENT. Unauthorized use, including screenshots, copying, misuse, reuse, or resale of any content from this app, is strictly prohibited. Our app monitors and records all screenshots and recordings. Violators will face strict legal action.



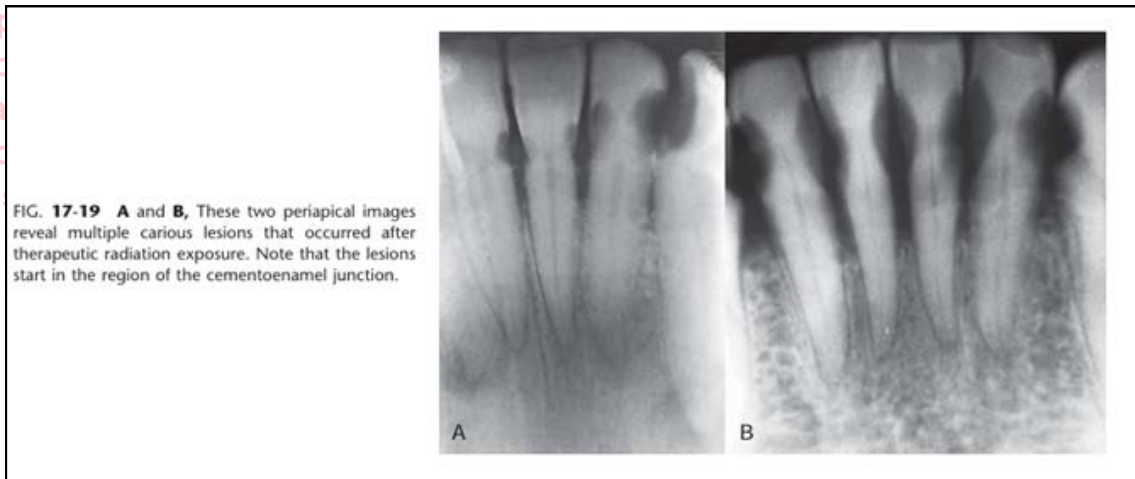
# DENTAL CARIES RADIOLOGY

(Source- Oral Radiology PRINCIPLES and INTERPRETATION Sixth Edition by STUART C. WHITE and MICHAEL J. PHAROAH)

## Radiographic Detection of Lesions

### 6) RADIATION CARIES

- Patients who have received therapeutic radiation to the head and neck may have a loss of salivary gland function, leading to xerostomia (dry mouth) and a change in the bacterial flora and possibly intrinsic change to the tooth structure.
- When untreated, this induces rampant destruction of the teeth, termed **radiation caries**.
- Typically, the destruction begins at the cervical region and may aggressively encircle the tooth, causing the entire crown to be lost, with only root fragments remaining in the jaws.
- **The radiographic appearance of radiation caries is characteristic: radiolucent shadows appearing at the necks of teeth, most obvious on the mesial and distal aspects.**



THIS IS COPYRIGHTED CONTENT. Unauthorized use, including screenshots, copying, misuse, reuse, or resale of any content from this app, is strictly prohibited. Our app monitors and records all screenshots and recordings. Violators will face strict legal action.

#### DISCLAIMER

THIS IS COPYRIGHTED CONTENT. Unauthorized use, including screenshots, copying, misuse, reuse, or resale of any content from this app, is strictly prohibited. Our app monitors and records all screenshots and recordings. Violators will face strict legal action.

DISCLAIMER  
THIS IS COPYRIGHTED CONTENT. Unauthorized use, including screenshots, copying, misuse, reuse, or resale of any content from this app, is strictly prohibited. Our app monitors and records all screenshots and recordings. Violators will face strict legal action.

DISCLAIMER

THIS IS COPYRIGHTED CONTENT. Unauthorized use, including screenshots, copying, misuse, reuse, or resale of any content from this app, is strictly prohibited. Our app monitors and records all screenshots and recordings. Violators will face strict legal action.

this app, is strictly prohibited. Our app monitors and records all screenshots and recordings. Violators will face strict legal action.

# DENTAL CARIES RADIOLOGY


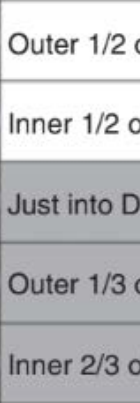



## Radiographic criteria in caries assessment

(Source- Evans Article and Oral Radiology PRINCIPLES and INTERPRETATION Sixth Edition by STUART C. WHITE and MICHAEL J. PHAROAH)

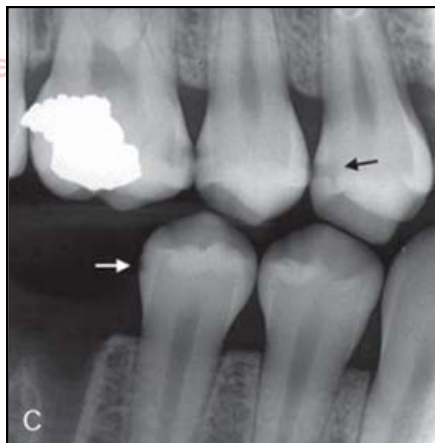
- Radiolucencies are categorized according to five category system proposed by Mejare)

**Table 3. Criteria for scoring bitewing radiolucencies on occlusal and approximal surfaces (after Mejare, 1999)**

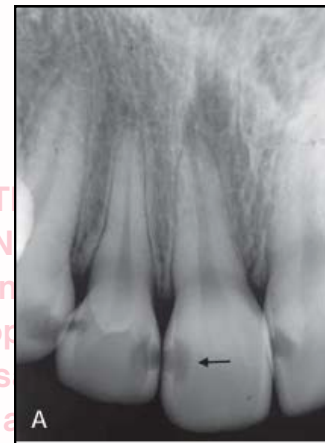Criteria for Bitewing Radiolucency Scores	
C0	No radiolucency evident (not recorded)
C1	Radiolucency is evident within the <i>outer half</i> of enamel
C2	Radiolucency extends to the <i>inner half</i> of enamel and may reach the DEJ
C3	Radiolucency extends <i>just beyond</i> the DEJ
C4	Radiolucency is evident within the <i>outer third</i> of dentine
C5	Radiolucency extends to the <i>inner two thirds</i> of dentine and may reach the pulp

	Outer 1/2 of Enamel	1
	Inner 1/2 of Enamel	2
	Just into Dentine	3
	Outer 1/3 of Dentine	4
	Inner 2/3 of Dentine	5

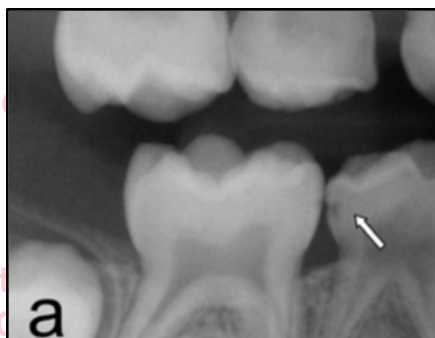### Some Examples:



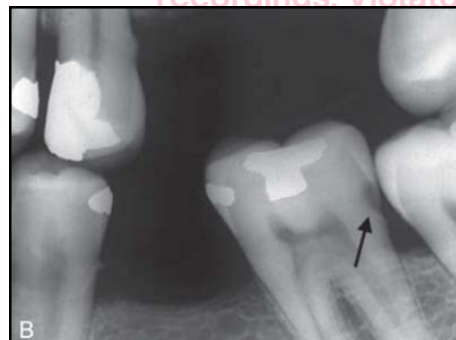- Image: Lower second premolar showing C1 lesion (white arrow),
- Upper first premolar showing C4 lesion (Black arrow)
- Upper second premolar (distal surface) showing C2 lesion.



- Image: Central incisor showing C5 lesion (Black arrow)



- Image: (White arrow) showing C3 lesion



- Image: Root caries (Black Arrow)

### DISCLAIMER

THIS IS COPYRIGHTED CONTENT. Unauthorized use, including screenshots, copying, misuse, reuse, or resale of any content from this app, is strictly prohibited. Our app monitors and records all screenshots and recordings. Violators will face strict legal action.

### DISCLAIMER

THIS IS COPYRIGHTED CONTENT. Unauthorized use, including screenshots, copying, misuse, reuse, or resale of any content from this app, is strictly prohibited. Our app monitors and records all screenshots and recordings. Violators will face strict legal action.

THIS IS COPYRIGHTED CONTENT. Unauthorized use, including screenshots, copying, misuse, reuse, or resale of any content from this app, is strictly prohibited. Our app monitors and records all screenshots and recordings. Violators will face strict legal action.

### DISCLAIMER

# PERIODONTAL RADIOLOGY

(Source: Oral Radiology PRINCIPLES and INTERPRETATION Sixth Edition, Article on Disease Staging Index for Aggressive Periodontitis by Srinivas Sulugodu Ramachandraa / José Dopicob / Nikos Donosc / Luigi Nibolid)

- Periodontal diseases are a set of conditions characterized by an inflammatory host response in the periodontal tissues that may lead to localized or generalized alterations in the soft tissues around the teeth, loss of supporting bone, and ultimately, loss of the teeth.
- Periodontal diseases are broadly classified as gingival diseases and periodontitis.
- Gingivitis presents as inflammation of the soft tissue surrounding the teeth with gingival swelling, edema, and erythema. Gingival diseases may be
  - a) dental plaque-induced or
  - b) non – plaque-induced
- Bacterial plaque-associated gingivitis is much more common than non – plaque-induced inflammatory diseases affecting the gingiva such as viral or fungal infections, mucocutaneous and allergic conditions, and traumatic injuries.
- Periodontitis is distinguished from gingivitis by the clinically detectable destruction of host tissues seen as the loss of soft tissue attachment and supporting bone of the involved teeth.
- Although periodontitis is always preceded by gingivitis, gingivitis does not always progress to periodontitis.
- Radiographs play an integral role in the assessment of periodontal disease. They provide unique information about the status of the periodontium and a permanent record of the condition of the bone throughout the course of the disease.
- Radiographs aid the clinician in identifying
  - a) the extent of destruction of alveolar bone,
  - b) local contributing factors, and
  - c) features of the periodontium that influence the prognosis.

## BOX 18-1

### Radiographic Assessment of Periodontal Conditions

Radiographs are especially helpful in the evaluation of the following features:

- Amount of bone present
- Condition of the alveolar crests
- Bone loss in the furcation areas
- Width of the periodontal ligament space
- Local irritating factors that increase the risk of periodontal disease
  - Calculus
  - Poorly contoured or overextended restorations
- Root length and morphology and the crown-to-root ratio
- Open interproximal contacts, which may be sites for food impaction
- Anatomic considerations
  - Position of the maxillary sinus in relation to a periodontal deformity
  - Missing, supernumerary, impacted, and tipped teeth
- Pathologic considerations
  - Caries
  - Periapical lesions
  - Root resorption

Image: Important features identified in radiograph

- It is important to emphasize that the clinical and radiographic examinations are complementary.

## DISCLAIMER

THIS IS COPYRIGHTED CONTENT. Unauthorized use, including screenshots, copying, misuse, reuse, or resale of any content from this app, is strictly prohibited. Our app monitors and records all screenshots and recordings. Violators will face strict legal action.

## DISCLAIMER

THIS IS COPYRIGHTED CONTENT. Unauthorized use, including screenshots, copying, misuse, reuse, or resale of any content from this app, is strictly prohibited. Our app monitors and records all screenshots and recordings. Violators will face strict legal action.

THIS IS COPYRIGHTED CONTENT. Unauthorized use, including screenshots, copying, misuse, reuse, or resale of any content from this app, is strictly prohibited. Our app monitors and records all screenshots and recordings. Violators will face strict legal action.

DISCLAIMER



# PERIODONTAL RADIOLOGY

## 1) Features of normal alveolar bone and normal periodontal tissues in radiograph

- The normal alveolar bone that supports the dentition has a characteristic radiographic appearance.
- A thin layer of opaque cortical bone often covers the alveolar crest.

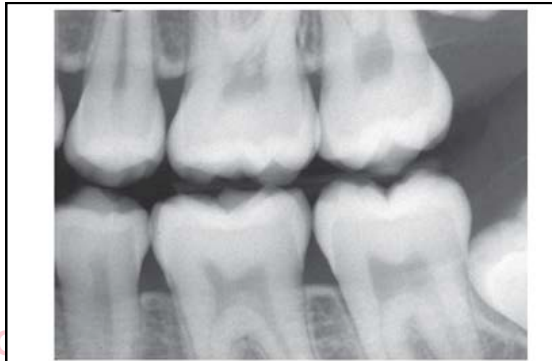

FIG. 18-1 The normal alveolar crest lies 0.5 to 2.0mm below the adjacent cementoenamel junctions and forms a sharp angle with the lamina dura of the adjacent tooth. Note that the crests may not always appear with a well-defined outer cortex.



FIG. 18-2 Between the anterior teeth, the normal alveolar crest is pointed and well corticated, coming to within 0.5 to 2.0mm of the adjacent cementoenamel junctions.

- A well-mineralized cortical outline of the alveolar crest indicates the absence of periodontitis activity. However, lack of a well mineralized alveolar crest may be found in patients with or without periodontitis.
- The alveolar crest is continuous with the lamina dura of adjacent teeth.
- In the absence of disease, this bony junction between the alveolar crest and lamina dura of posterior teeth forms a sharp angle next to the tooth root.

## 2) General radiographic features of periodontal disease:

- The following patterns of bone loss may be seen radiographically in the assessment of periodontitis.

### a) Early Bone Changes

- The early lesions of chronic periodontitis appear as areas of localized erosion of the interproximal alveolar bone crest.

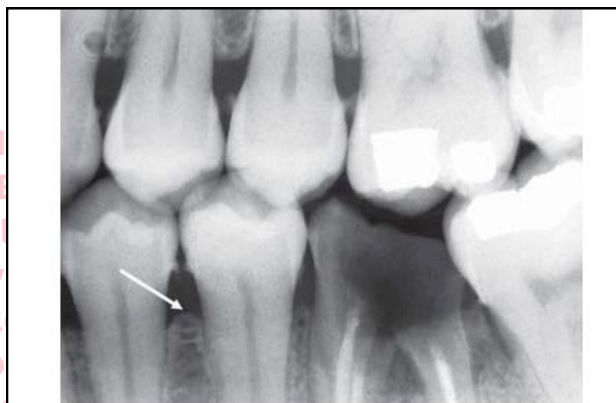

FIG. 18-3 Initial periodontal disease is seen as a loss of cortical density and a rounding of the junction between the alveolar crest and the lamina dura (arrow). Note also the more pronounced bone loss around the mandibular first molar and the generalized interproximal calculus.

### DISCLAIMER

THIS IS COPYRIGHTED CONTENT. Unauthorized use, including screenshots, copying, misuse, reuse, or resale of any content from this app, is strictly prohibited. Our app monitors and records all screenshots and recordings. Violators will face strict legal action.

### DISCLAIMER

THIS IS COPYRIGHTED CONTENT. Unauthorized use, including screenshots, copying, misuse, reuse, or resale of any content from this app, is strictly prohibited. Our app monitors and records all screenshots and recordings. Violators will face strict legal action.

THIS IS COPYRIGHTED CONTENT. Unauthorized use, including screenshots, copying, misuse, reuse, or resale of any content from this app, is strictly prohibited. Our app monitors and records all screenshots and recordings. Violators will face strict legal action.

### DISCLAIMER



# PERIODONTAL RADIOLOGY

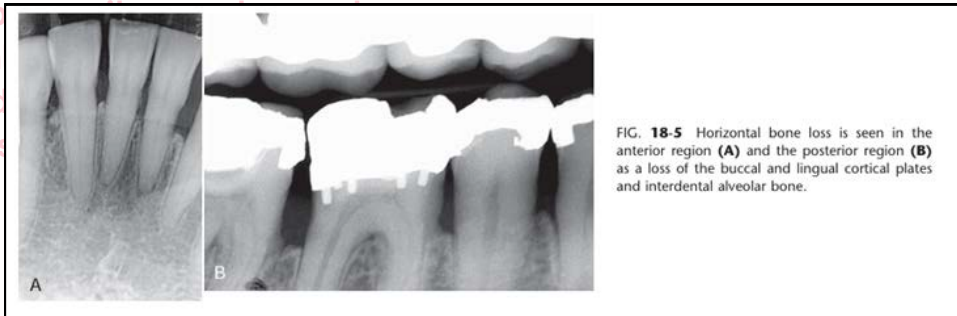
## 2) General radiographic features of periodontal disease:

### a) Early Bone Changes

- If the periodontitis progresses, the destruction of alveolar bone extends beyond early changes in the alveolar crest and may induce a variety of defects in the morphology of the alveolar crest.
- These patterns of bone loss have been divided into
  - i. horizontal bone loss,
  - ii. vertical (angular) defects,
  - iii. interdental craters,
  - iv. buccal or lingual cortical plate loss, and
  - v. furcation involvement of multirooted teeth.

### i. Horizontal bone loss:

- Horizontal bone loss is a term used to describe the radiographic appearance of loss in height of the alveolar bone where the crest is still horizontal (i.e., parallel to an imagined line joining the CEJs of adjacent teeth) but is positioned apically more than a couple of millimeters from the CEJs.



### ii. Vertical Bone Defects

- The term vertical (or angular) osseous defect describes a bony lesion that is localized to a single tooth, although an individual may have multiple vertical osseous defects.
- The radiographic presentation is a vertical deformity within the alveolus that extends apically along the root of the affected tooth from the alveolar crest.
- The vertical defect is described as
  - a. **three walled** (surrounded by three bony walls) when both buccal and lingual cortical plates remain.
  - b. **two walled** when one of these plates has been resorbed and
  - c. **one walled** when both plates have been lost
- The distinctions among these groups are important in designing the treatment plan.

#### DISCLAIMER

THIS IS COPYRIGHTED CONTENT. Unauthorized use, including screenshots, copying, misuse, reuse, or resale of any content from this app, is strictly prohibited. Our app monitors and records all screenshots and recordings. Violators will face strict legal action.

#### DISCLAIMER

THIS IS COPYRIGHTED CONTENT. Unauthorized use, including screenshots, copying, misuse, reuse, or resale of any content from this app, is strictly prohibited. Our app monitors and records all screenshots and recordings. Violators will face strict legal action.

THIS IS COPYRIGHTED CONTENT. Unauthorized use, including screenshots, copying, misuse, reuse, or resale of any content from this app, is strictly prohibited. Our app monitors and records all screenshots and recordings. Violators will face strict legal action.

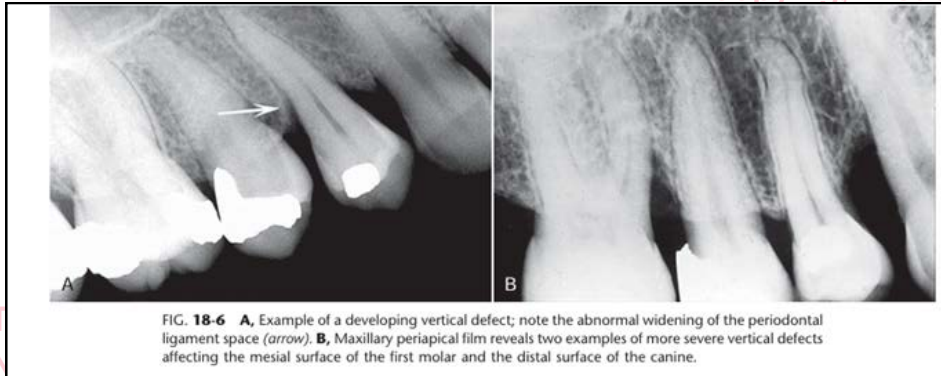
#### DISCLAIMER

# PERIODONTAL RADIOLOGY

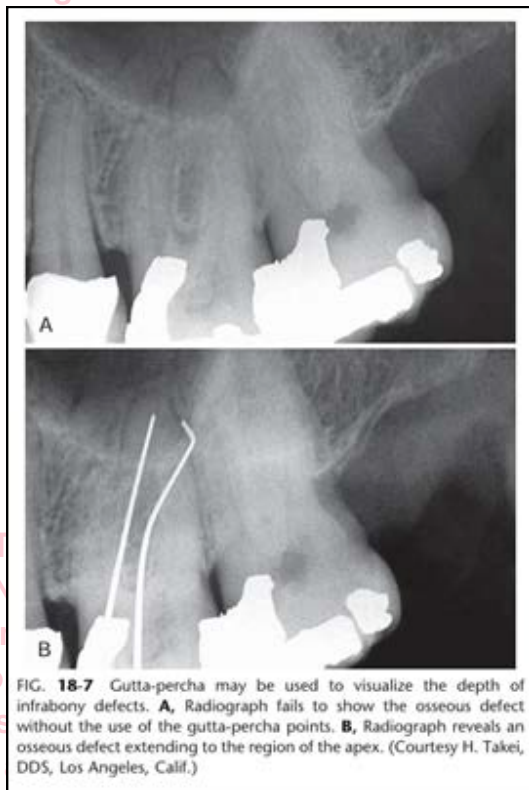
## 2) General radiographic features of periodontal disease:

### a) Early Bone Changes

#### ii. Vertical Bone Defects



- Clinical and surgical inspections are the best means of determining the number of remaining bony walls.
- Visualization of the depth of pockets may be aided by inserting a gutta-percha point.
- The point follows the defect and appears on the radiograph because gutta-percha is relatively inflexible and radiopaque.



THIS IS COPYRIGHTED CONTENT. Unauthorized use, including screenshots, copying, misuse, reuse, or resale of any content from this app, is strictly prohibited. Our app monitors and records all screenshots and recordings. Violators will face strict legal action.

#### DISCLAIMER

THIS IS COPYRIGHTED CONTENT. Unauthorized use, including screenshots, copying, misuse, reuse, or resale of any content from this app, is strictly prohibited. Our app monitors and records all screenshots and recordings. Violators will face strict legal action.

#### DISCLAIMER

THIS IS COPYRIGHTED CONTENT. Unauthorized use, including screenshots, copying, misuse, reuse, or resale of any content from this app, is strictly prohibited. Our app monitors and records all screenshots and recordings. Violators will face strict legal action.

THIS IS COPYRIGHTED CONTENT. Unauthorized use, including screenshots, copying, misuse, reuse, or resale of any content from this app, is strictly prohibited. Our app monitors and records all screenshots and recordings. Violators will face strict legal action.

DISCLAIMER

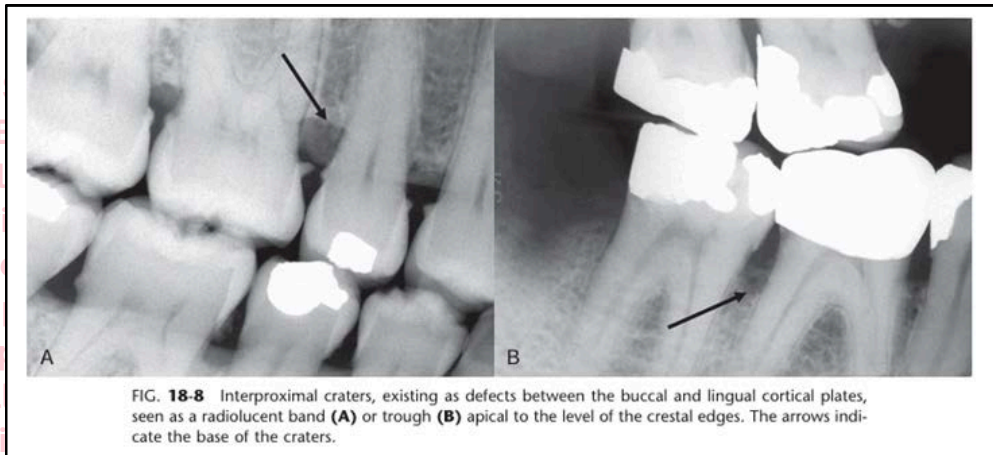
# PERIODONTAL RADIOLOGY

## 2) General radiographic features of periodontal disease:

### a) Early Bone Changes

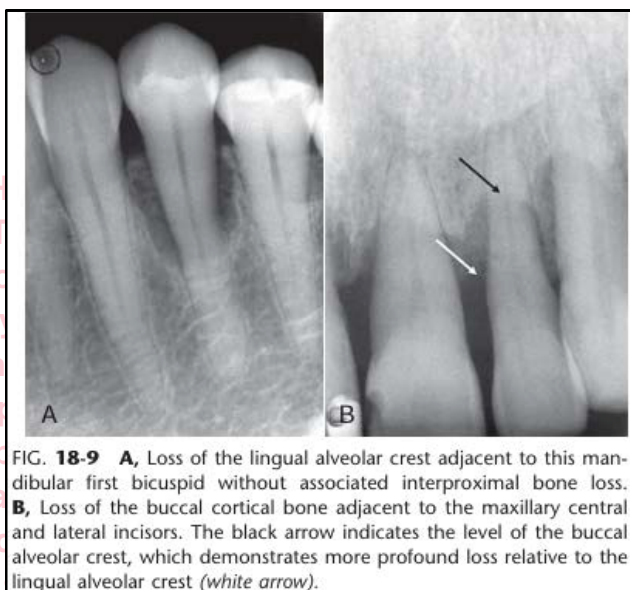
#### iii. Interdental Craters

- The interproximal crater is a two-walled, troughlike depression that forms in the crest of the interdental bone between adjacent teeth.
- Radiographically this presents as a bandlike or irregular region of bone with less density at the crest, immediately adjacent to the denser normal bone apical to the base of the crater.



#### iv. Buccal or Lingual Cortical Plate Loss

- Loss of a cortical plate may occur alone or with another type of bone loss such as horizontal bone loss.
- This type of loss is indicated by an increase in the radiolucency of the root of the tooth near the alveolar crest.
- The shape seen usually is a semicircular shadow with the apex of the radiolucency directed apically in relation to the tooth.



#### DISCLAIMER

THIS IS COPYRIGHTED CONTENT. Unauthorized use, including screenshots, copying, misuse, reuse, or resale of any content from this app, is strictly prohibited. Our app monitors and records all screenshots and recordings. Violators will face strict legal action.

#### DISCLAIMER

THIS IS COPYRIGHTED CONTENT. Unauthorized use, including screenshots, copying, misuse, reuse, or resale of any content from this app, is strictly prohibited. Our app monitors and records all screenshots and recordings. Violators will face strict legal action.

THIS IS COPYRIGHTED CONTENT. Unauthorized use, including screenshots, copying, misuse, reuse, or resale of any content from this app, is strictly prohibited. Our app monitors and records all screenshots and recordings. Violators will face strict legal action.

DISCLAIMER



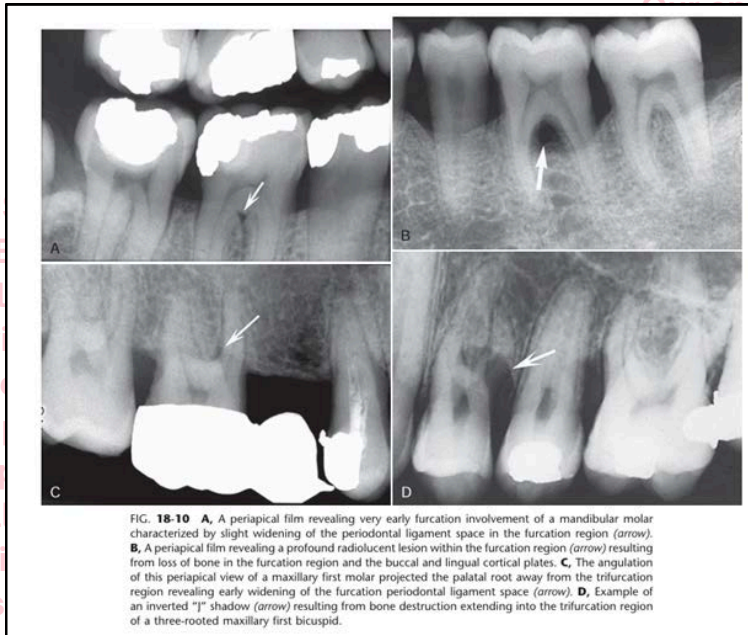
# PERIODONTAL RADIOLOGY

## 2) General radiographic features of periodontal disease:

### a) Early Bone Changes

#### v. Osseous Deformities in the Furcations of Multirooted Teeth

- Progressive periodontal disease and its associated bone loss may extend into the furcations of multirooted teeth.

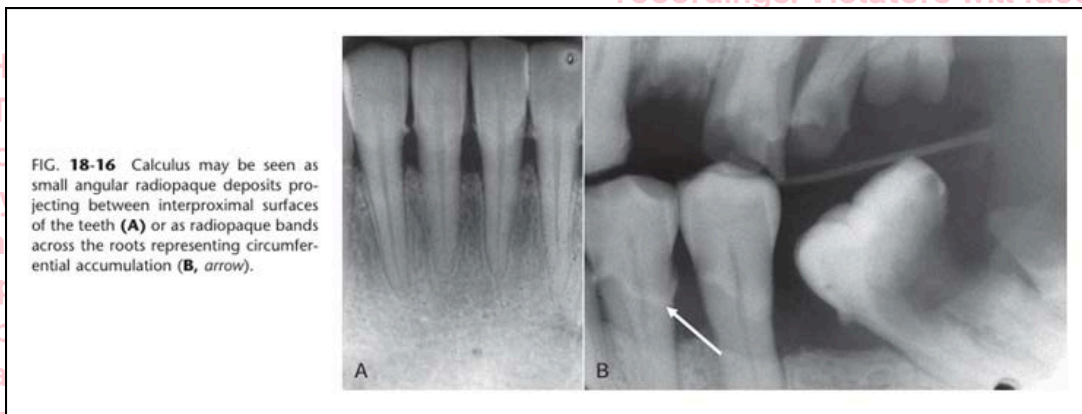


## Some Features in radiographs that is seen on periodontal disease:

### 1) Local irritating factors in periodontitis:

#### a) Calculus:

- Calculus deposits can prevent effective cleansing of a sulcus and lead to enhanced plaque formation and the progression of periodontal disease.
- Calculus is most commonly seen on the mandibular incisors but may be localized to any surface or generalized throughout the dentition.



#### DISCLAIMER

THIS IS COPYRIGHTED CONTENT. Unauthorized use, including screenshots, copying, misuse, reuse, or resale of any content from this app, is strictly prohibited. Our app monitors and records all screenshots and recordings. Violators will face strict legal action.

#### DISCLAIMER

THIS IS COPYRIGHTED CONTENT. Unauthorized use, including screenshots, copying, misuse, reuse, or resale of any content from this app, is strictly prohibited. Our app monitors and records all screenshots and recordings. Violators will face strict legal action.

THIS IS COPYRIGHTED CONTENT. Unauthorized use, including screenshots, copying, misuse, reuse, or resale of any content from this app, is strictly prohibited. Our app monitors and records all screenshots and recordings. Violators will face strict legal action.

# PERIODONTAL RADIOLOGY

Some Features in radiographs that is seen on periodontal disease:

## 1) Local irritating factors in periodontitis:

### b) Defective restorations with overhangs

- Defective restorations with overhanging or poorly contoured margins can also lead to the accumulation of plaque, thus providing an environment where periodontal disease may develop.

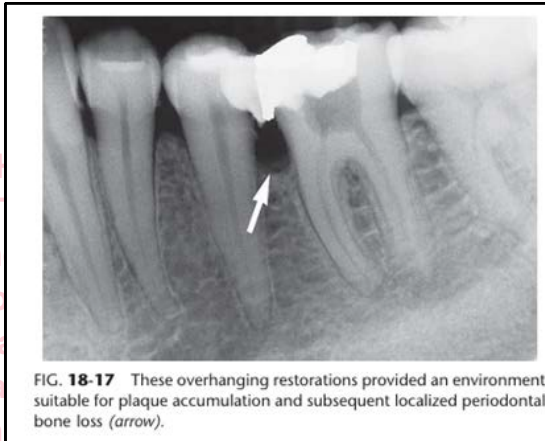


FIG. 18-17 These overhanging restorations provided an environment suitable for plaque accumulation and subsequent localized periodontal bone loss (arrow).

## 2) Misalignment of teeth leading to periodontitis:

- When the mesial and distal surfaces of adjacent teeth do not touch, the patient has an open contact.
- This condition may be dangerous to the periodontium because of the potential for food debris to become trapped in the region.
- Trapped food particles may damage the soft tissue and induce an inflammatory response and contribute to the development of localized periodontal disease.
- Open contacts are associated with periodontal disease more than closed contacts are.
- Abnormal tooth alignment does not cause periodontal disease but provides an environment where the disease may develop as a result of difficulty in maintaining adequate oral hygiene

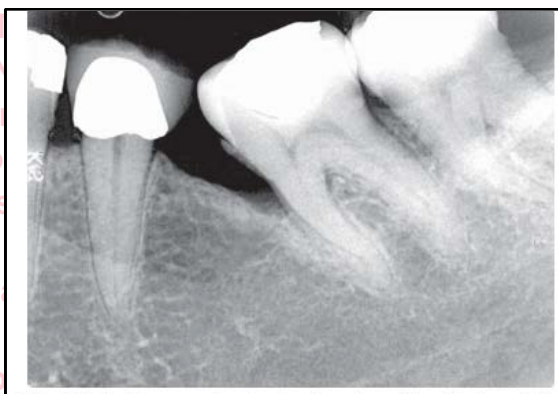


FIG. 18-15 The second molar has tipped mesially after loss of the first molar, creating an abnormal tooth alignment that was difficult for the patient to maintain and leading to localized periodontal disease. Note the calculus on the mesial surface of the second molar. The crown on the second premolar was constructed with an enlarged distal contour to stop further tipping of the molar.

DISCLAIMER

THIS IS COPYRIGHTED CONTENT. Unauthorized use, including screenshots, copying, misuse, reuse, or resale of any content from this app, is strictly prohibited. Our app monitors and records all screenshots and recordings. Violators will face strict legal action.

DISCLAIMER

THIS IS COPYRIGHTED CONTENT. Unauthorized use, including screenshots, copying, misuse, reuse, or resale of any content from this app, is strictly prohibited. Our app monitors and records all screenshots and recordings. Violators will face strict legal action.

THIS IS COPYRIGHTED CONTENT. Unauthorized use, including screenshots, copying, misuse, reuse, or resale of any content from this app, is strictly prohibited. Our app monitors and records all screenshots and recordings. Violators will face strict legal action.

DISCLAIMER

# PERIODONTAL RADIOLOGY

## Staging and grading of periodontitis

THIS IS COPYRIGHTED

### PERIODONTITIS: STAGING

Staging intends to classify the severity and extent of a patient's disease based on the measurable amount of destroyed and/or damaged tissue as a result of periodontitis and to assess the specific factors that may attribute to the complexity of long-term case management.

Initial stage should be determined using clinical attachment loss (CAL). If CAL is not available, radiographic bone loss (RBL) should be used. Tooth loss due to periodontitis may modify stage definition. One or more complexity factors may shift the stage to a higher level. See [perio.org/2017wwdc](http://perio.org/2017wwdc) for additional information.

	Periodontitis	Stage I	Stage II	Stage III	Stage IV
Severity	Interdental CAL (at site of greatest loss)	1 – 2 mm	3 – 4 mm	≥5 mm	≥5 mm
	RBL	Coronal third (<15%)	Coronal third (15% - 33%)	Extending to middle third of root and beyond	Extending to middle third of root and beyond
	Tooth loss (due to periodontitis)	No tooth loss		≤4 teeth	≥5 teeth
Complexity	Local	<ul style="list-style-type: none"> <li>Max. probing depth ≤4 mm</li> <li>Mostly horizontal bone loss</li> </ul>	<ul style="list-style-type: none"> <li>Max. probing depth ≤5 mm</li> <li>Mostly horizontal bone loss</li> </ul>	In addition to Stage II complexity: <ul style="list-style-type: none"> <li>Probing depths ≥6 mm</li> <li>Vertical bone loss ≥3 mm</li> <li>Furcation involvement Class II or III</li> <li>Moderate ridge defects</li> </ul>	In addition to Stage III complexity: <ul style="list-style-type: none"> <li>Need for complex rehabilitation due to:               <ul style="list-style-type: none"> <li>Masticatory dysfunction</li> <li>Secondary occlusal trauma (tooth mobility degree ≥2)</li> <li>Severe ridge defects</li> <li>Bite collapse, drifting, flaring</li> <li>&lt;20 remaining teeth (10 opposing pairs)</li> </ul> </li> </ul>
Extent and distribution	Add to stage as descriptor	For each stage, describe extent as: <ul style="list-style-type: none"> <li>Localized (&lt;30% of teeth involved);</li> <li>Generalized; or</li> <li>Molar/incisor pattern</li> </ul>			

all screenshots and

### PERIODONTITIS: GRADING

Grading aims to indicate the rate of periodontitis progression, responsiveness to standard therapy, and potential impact on systemic health.

Clinicians should initially assume grade B disease and seek specific evidence to shift to grade A or C.

See [perio.org/2017wwdc](http://perio.org/2017wwdc) for additional information.

	Progression		Grade A: Slow rate	Grade B: Moderate rate	Grade C: Rapid rate
Primary criteria  <i>Whenever available, direct evidence should be used.</i>	Direct evidence of progression	Radiographic bone loss or CAL	No loss over 5 years	<2 mm over 5 years	≥2 mm over 5 years
	Indirect evidence of progression	% bone loss / age	<0.25	0.25 to 1.0	>1.0
		Case phenotype	Heavy biofilm deposits with low levels of destruction	Destruction commensurate with biofilm deposits	Destruction exceeds expectations given biofilm deposits; specific clinical patterns suggestive of periods of rapid progression and/or early onset disease
Grade modifiers	Risk factors	Smoking	Non-smoker	<10 cigarettes/day	≥10 cigarettes/day
		Diabetes	Normoglycemic/no diagnosis of diabetes	HbA1c <7.0% in patients with diabetes	HbA1c ≥7.0% in patients with diabetes

THIS IS COPYRIGHTED CONTENT. Unauthorized use, including screenshots, copying, misuse, reuse, or resale of any content from this app, is strictly prohibited. Our app monitors and records all screenshots and recordings. Violators will face strict legal action.

#### DISCLAIMER

THIS IS COPYRIGHTED CONTENT. Unauthorized use, including screenshots, copying, misuse, reuse, or resale of any content from this app, is strictly prohibited. Our app monitors and records all screenshots and recordings. Violators will face strict legal action.

DISCLAIMER

THIS IS COPYRIGHTED CONTENT. Unauthorized use, including screenshots, copying, misuse, reuse, or resale of any content from this app, is strictly prohibited. Our app monitors and records all screenshots and recordings. Violators will face strict legal action.

THIS IS COPYRIGHTED CONTENT. Unauthorized use, including screenshots, copying, misuse, reuse, or resale of any content from this app, is strictly prohibited. Our app monitors and records all screenshots and recordings. Violators will face strict legal action.

DISCLAIMER



# PERIODONTAL RADIOLOGY

Some examples:

## 1) An illustration of stage 3:

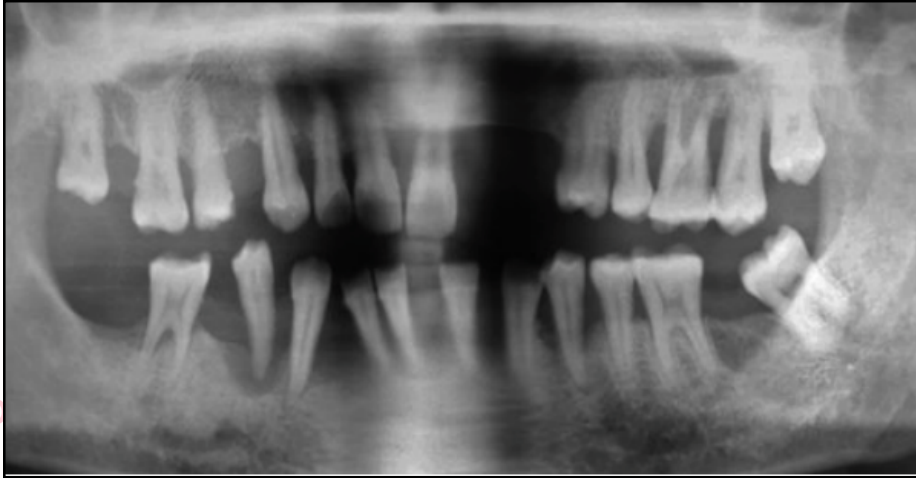

Image: OPG showing extensive bone loss up to the apical third (> 70%).

- Many teeth have widened periodontal ligament space with loss of lamina dura (periapical changes) suggesting non-vitality due to periodontal reasons.
- More than three teeth have already been lost due to periodontal reasons and many have hopeless prognosis.
- Pattern of bone destruction is prevalently horizontal in nature.

## 1) An illustration of stage 1:

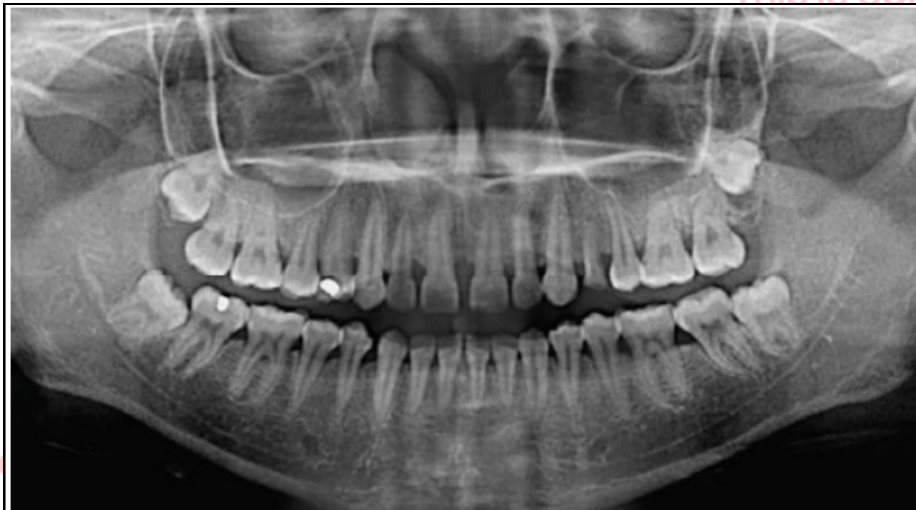

Image: OPG of a 20-year-old female patient

- It shows bone loss in the coronal third (< 50%) around first molars and incisors.
- The pattern of bone destruction is prevalently angular or vertical.
- There is no disto-labial migration, instead it is spacing due to arch length-tooth size discrepancy

### DISCLAIMER

THIS IS COPYRIGHTED CONTENT. Unauthorized use, including screenshots, copying, misuse, reuse, or resale of any content from this app, is strictly prohibited. Our app monitors and records all screenshots and recordings. Violators will face strict legal action.

### DISCLAIMER

THIS IS COPYRIGHTED CONTENT. Unauthorized use, including screenshots, copying, misuse, reuse, or resale of any content from this app, is strictly prohibited. Our app monitors and records all screenshots and recordings. Violators will face strict legal action.

THIS IS COPYRIGHTED CONTENT. Unauthorized use, including screenshots, copying, misuse, reuse, or resale of any content from this app, is strictly prohibited. Our app monitors and records all screenshots and recordings. Violators will face strict legal action.

THIS IS COPYRIGHTED CONTENT. Unauthorized use, including screenshots, copying, misuse, reuse, or resale of any content from this app, is strictly prohibited. Our app monitors and records all screenshots and recordings. Violators will face strict legal action.

THIS IS COPYRIGHTED CONTENT. Unauthorized use, including screenshots, copying, misuse, reuse, or resale of any content from this app, is strictly prohibited. Our app monitors and records all screenshots and recordings. Violators will face strict legal action.

THIS IS COPYRIGHTED CONTENT. Unauthorized use, including screenshots, copying, misuse, reuse, or resale of any content from this app, is strictly prohibited. Our app monitors and records all screenshots and recordings. Violators will face strict legal action.

THIS IS COPYRIGHTED CONTENT. Unauthorized use, including screenshots, copying, misuse, reuse, or resale of any content from this app, is strictly prohibited. Our app monitors and records all screenshots and recordings. Violators will face strict legal action.

DISCLAIMER

# PERIODONTAL RADIOLOGY

Some examples:

## 3) An illustration for stage II:

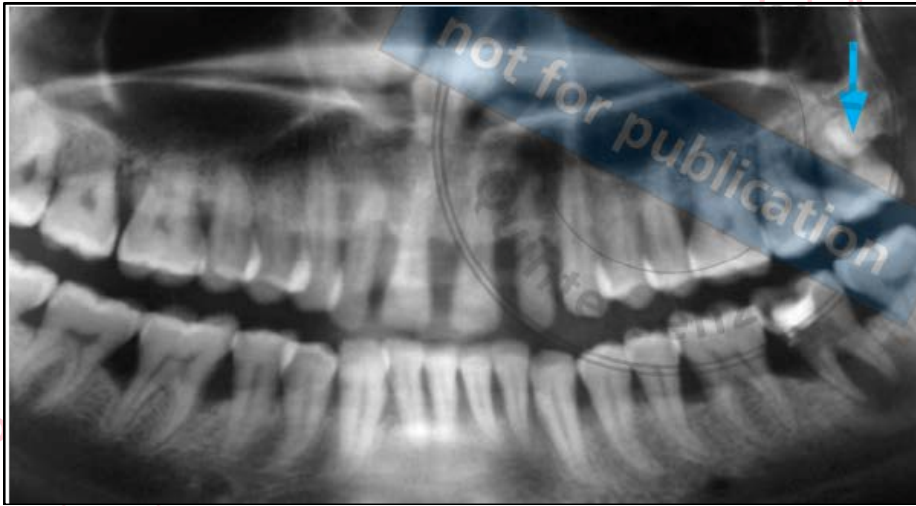


Image: OPG

- Bone loss up to the mid third of the roots can be appreciated (maximum bone loss between 50% and 70%)
- The pattern of bone destruction is a combination of horizontal and vertical bone loss.
- The left mandibular molar needs endodontic therapy due to caries reasons

THIS IS COPYRIGHTED CONTENT. Unauthorized use, including screenshots, copying, misuse, reuse, or resale of any content from this app, is strictly prohibited. Our app monitors and records all screenshots and recordings. Violators will face strict legal action.

DISCLAIMER

THIS IS COPYRIGHTED CONTENT. Unauthorized use, including screenshots, copying, misuse, reuse, or resale of any content from this app, is strictly prohibited. Our app monitors and records all screenshots and recordings. Violators will face strict legal action.

THIS IS COPYRIGHTED CONTENT. Unauthorized use, including screenshots, copying, misuse, reuse, or resale of any content from this app, is strictly prohibited. Our app monitors and records all screenshots and recordings. Violators will face strict legal action.

DISCLAIMER  
THIS IS COPYRIGHTED CONTENT. Unauthorized use, including screenshots, copying, misuse, reuse, or resale of any content from this app, is strictly prohibited. Our app monitors and records all screenshots and recordings. Violators will face strict legal action.

DISCLAIMER

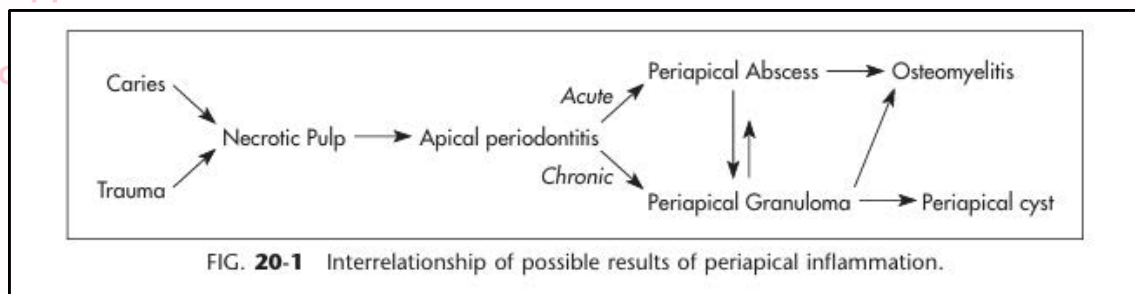
THIS IS COPYRIGHTED CONTENT. Unauthorized use, including screenshots, copying, misuse, reuse, or resale of any content from this app, is strictly prohibited. Our app monitors and records all screenshots and recordings. Violators will face strict legal action.

# PERIAPICAL LESIONS

(Source- Oral Radiology PRINCIPLES and INTERPRETATION Sixth Edition)

## Periapical inflammatory lesions:

- When the initial source of inflammation is a necrotic pulp and the bony lesion is restricted to the region of the tooth, the condition is called a periapical inflammatory lesion.
- When the infection spreads in the bone marrow and is no longer contained to the vicinity of the tooth root apex, it is called osteomyelitis.
- Periapical inflammatory lesions have been called
  - acute apical periodontitis,
  - chronic apical periodontitis,
  - periapical abscess, and
  - periapical granuloma
- Radiographically, Radiolucent presentations have been called rarefying osteitis, whereas radiopaque presentations have been called sclerosing osteitis, condensing osteitis, and focal sclerosing osteitis.
- A periapical inflammatory lesion is defined as a local response of the bone around the apex of a tooth that occurs as a result of necrosis of the pulp or through destruction of the periapical tissues by extensive periodontal disease.



- The pulpal necrosis may occur as a result of pulpal invasion of bacteria through caries or trauma.
- The periapical inflammatory lesion is characterized by apical periodontitis, an inflammatory process that may histologically represent either a periapical abscess or a periapical granuloma.
- If the periapical lesion extends farther, so that the lesion no longer is centered on the tooth apex, osteomyelitis may be considered as a possible diagnosis.
- The distinction between periapical inflammation and osteomyelitis can be made if sequestra are detected radiographically.
- Progression from periapical inflammation to osteomyelitis is relatively rare.
- The symptoms of periapical inflammatory lesions can range across a broad spectrum, from being asymptomatic to an occasional toothache to severe pain with or without facial swelling, fever, and lymphadenopathy.
- The radiographic features of periapical inflammatory lesions vary depending on the time course of the lesion. Because very early lesions may not show any radiographic changes, diagnosis of these lesions relies solely on the clinical symptoms.

## DISCLAIMER

THIS IS COPYRIGHTED CONTENT. Unauthorized use, including screenshots, copying, misuse, reuse, or resale of any content from this app, is strictly prohibited. Our app monitors and records all screenshots and recordings. Violators will face strict legal action.

## DISCLAIMER

THIS IS COPYRIGHTED CONTENT. Unauthorized use, including screenshots, copying, misuse, reuse, or resale of any content from this app, is strictly prohibited. Our app monitors and records all screenshots and recordings. Violators will face strict legal action.

THIS IS COPYRIGHTED CONTENT. Unauthorized use, including screenshots, copying, misuse, reuse, or resale of any content from this app, is strictly prohibited. Our app monitors and records all screenshots and recordings. Violators will face strict legal action.

## DISCLAIMER



# PERIAPICAL LESIONS

## Periapical inflammatory lesions:

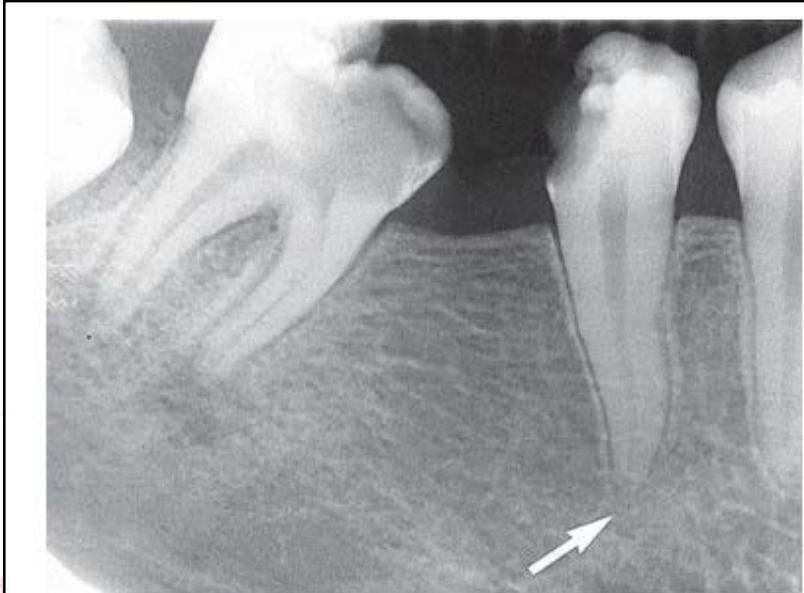

FIG. 20-2 A very early lesion involving the pulp of the second bicuspid without significant change in the periapical bone (*arrow*). In contrast, note the loss of the lamina dura and periapical bone at the apex of the mesial root of the second molar. Also note the subtle halo of sclerotic bone reaction around this apical radiolucency.

- More chronic lesions may show lytic (radiolucent) or sclerotic (radiopaque) changes, or both.
- In most cases the epicenter of periapical inflammatory lesions is found at the apex of the involved tooth.

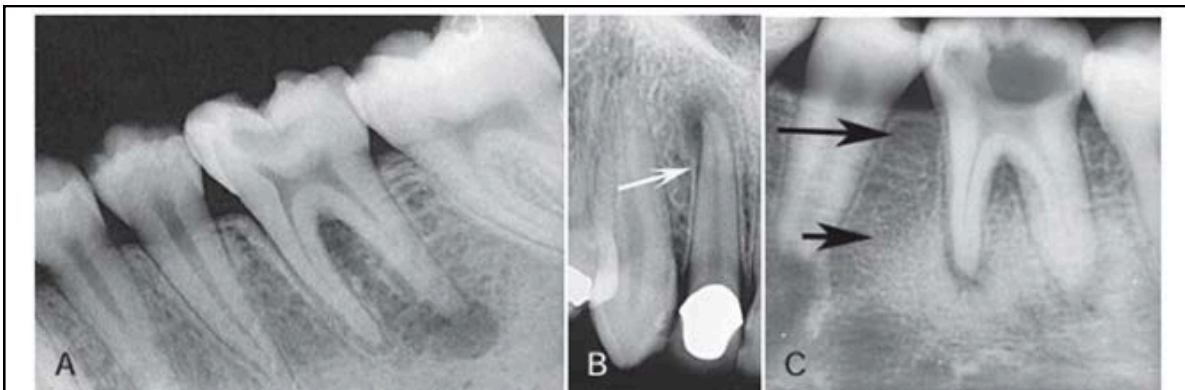


FIG. 20-3 Periapical inflammatory lesions associated with a mandibular first molar (**A**) and a maxillary lateral incisor (**B**). Note that in both cases the epicenter of bone destruction is located at the apex of the root. Also, note gradual widening of the periodontal membrane space (*arrow*) characteristic of an inflammatory lesion. **C**, This periapical image of sclerosing osteitis related to the first molar shows a gradual transition from thick and numerous trabeculae (*short arrow*) to a normal trabecular pattern (*long arrow*).

recordings. Violators will face strict legal action.

### DISCLAIMER

THIS IS COPYRIGHTED CONTENT. Unauthorized use, including screenshots, copying, misuse, reuse, or resale of any content from this app, is strictly prohibited. Our app monitors and records all screenshots and recordings. Violators will face strict legal action.

### DISCLAIMER

THIS IS COPYRIGHTED CONTENT. Unauthorized use, including screenshots, copying, misuse, reuse, or resale of any content from this app, is strictly prohibited. Our app monitors and records all screenshots and recordings. Violators will face strict legal action.

THIS IS COPYRIGHTED CONTENT. Unauthorized use, including screenshots, copying, misuse, reuse, or resale of any content from this app, is strictly prohibited. Our app monitors and records all screenshots and recordings. Violators will face strict legal action.

THIS IS COPYRIGHTED CONTENT. Unauthorized use, including screenshots, copying, misuse, reuse, or resale of any content from this app, is strictly prohibited. Our app monitors and records all screenshots and recordings. Violators will face strict legal action.

THIS IS COPYRIGHTED CONTENT. Unauthorized use, including screenshots, copying, misuse, reuse, or resale of any content from this app, is strictly prohibited. Our app monitors and records all screenshots and recordings. Violators will face strict legal action.

DISCLAIMER

# PERIAPICAL LESIONS

## Radiographic internal structure:

- **Early periapical inflammatory lesions** may show **no radiographic change** in the normal bone pattern.
- **The earliest detectable change is loss of bone density**, which usually results in **widening of the periodontal ligament space** at the apex of the tooth and later involves a larger diameter of surrounding bone.
- At this early stage no evidence may be seen of a sclerotic bone reaction

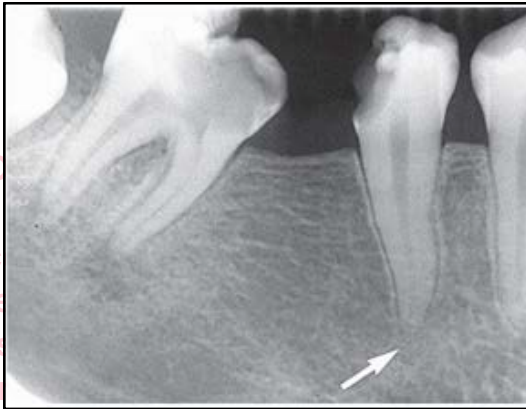
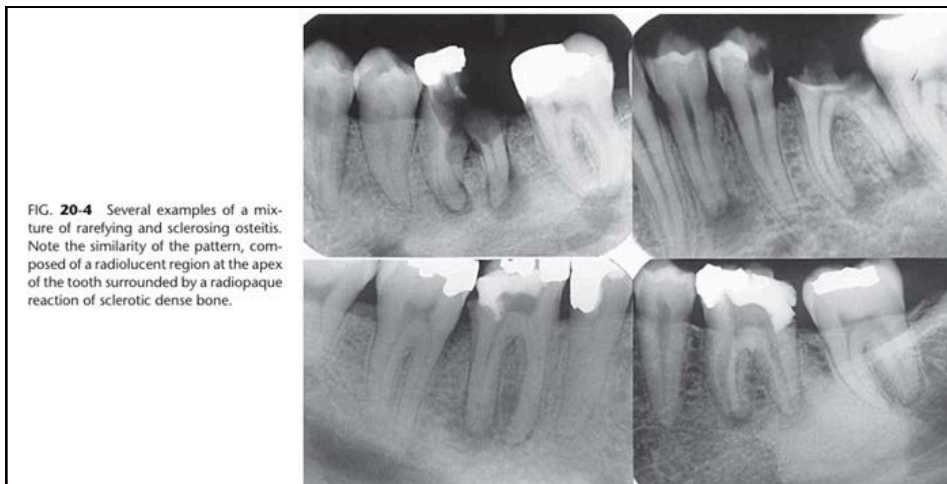


Fig: Early periapical inflammatory lesion showing only widening of PDL.

- **Later, as the disease progresses, a mixture of sclerosis and rarefaction (loss of bone giving a radiolucent appearance) of normal bone occurs.**



- The percentage of these two bone reactions varies, when most of the lesion consists of increased bone formation, the term **periapical sclerosing osteitis** is used and when most of the lesion is undergoing bone resorption, the term **periapical rarefying osteitis** is used.

## DISCLAIMER

THIS IS COPYRIGHTED CONTENT. Unauthorized use, including screenshots, copying, misuse, reuse, or resale of any content from this app, is strictly prohibited. Our app monitors and records all screenshots and recordings. Violators will face strict legal action.

## DISCLAIMER

THIS IS COPYRIGHTED CONTENT. Unauthorized use, including screenshots, copying, misuse, reuse, or resale of any content from this app, is strictly prohibited. Our app monitors and records all screenshots and recordings. Violators will face strict legal action.

THIS IS COPYRIGHTED CONTENT. Unauthorized use, including screenshots, copying, misuse, reuse, or resale of any content from this app, is strictly prohibited. Our app monitors and records all screenshots and recordings. Violators will face strict legal action.

DISCLAIMER



# PERIAPICAL LESIONS

## Radiographic internal structure:

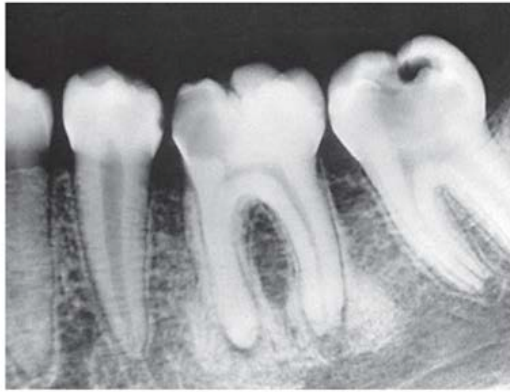


FIG. 20-5 Periapical sclerosing osteitis associated with the first molar. This is called a sclerosing lesion because most of the lesion is bone formation, resulting in a very radiopaque density. Note, however, the small region of bone loss next to the root apex and the widening of the periodontal membrane space.

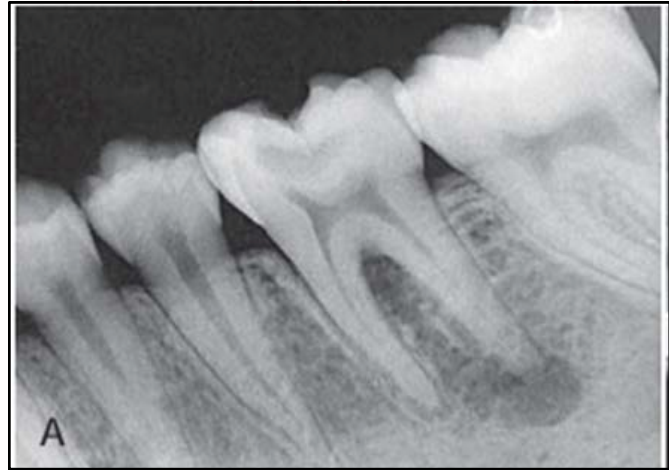

Image: Periapical rarefying osteitis.

Image: Periapical sclerosing osteitis.

- Periapical inflammatory lesions may stimulate either the resorption of bone or the manufacture of new bone.
- The lamina dura around the apex of the tooth usually is lost. The sclerotic reaction of the cancellous bone may be limited to a small region around the tooth apex or in some cases may be extensive.
- Nearby cortical boundaries may be destroyed, such as a segment of the floor of the maxillary antrum, the floor of the nasal fossa, or the buccal or lingual plates of the alveolar process immediately adjacent to the root apex.
- These lesions are capable of producing an **inflammatory periosteal reaction** (periostitis), most notably in the adjacent floor of the maxillary antrum.
- This usually results in a thin layer of new bone produced by the **inflamed periosteum within the maxillary antrum**, sometimes referred to as a “halo shadow”

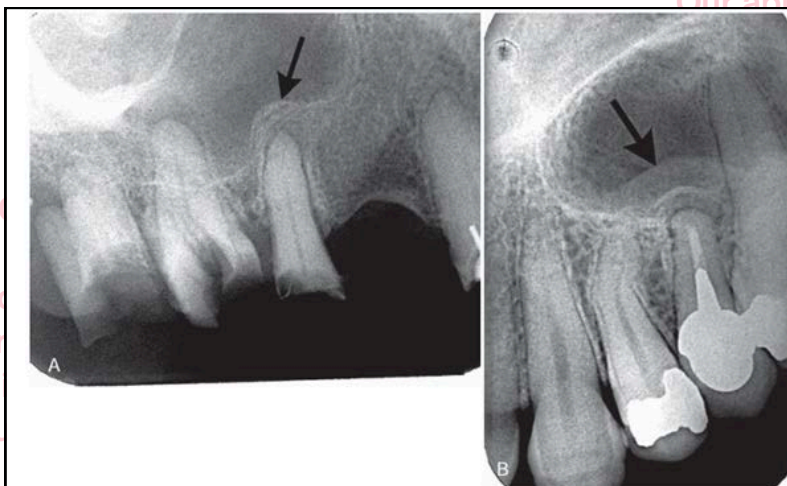


FIG. 20-6 Periostitis resulting in bone formation emanating from the floor of the maxillary antrum that arises from apical inflammatory lesions. A, Laminated type of periosteal bone formation (arrow). B, Periostitis and mucositis. The mucositis is characterized by a slight radiopaque band (arrow) next to the periosteal bone formation.

DISCLAIMER

THIS IS COPYRIGHTED CONTENT. Unauthorized use, including screenshots, copying, misuse, reuse, or resale of any content from this app, is strictly prohibited. Our app monitors and records all screenshots and recordings. Violators will face strict legal action.

DISCLAIMER

THIS IS COPYRIGHTED CONTENT. Unauthorized use, including screenshots, copying, misuse, reuse, or resale of any content from this app, is strictly prohibited. Our app monitors and records all screenshots and recordings. Violators will face strict legal action.

THIS IS COPYRIGHTED CONTENT. Unauthorized use, including screenshots, copying, misuse, reuse, or resale of any content from this app, is strictly prohibited. Our app monitors and records all screenshots and recordings. Violators will face strict legal action.

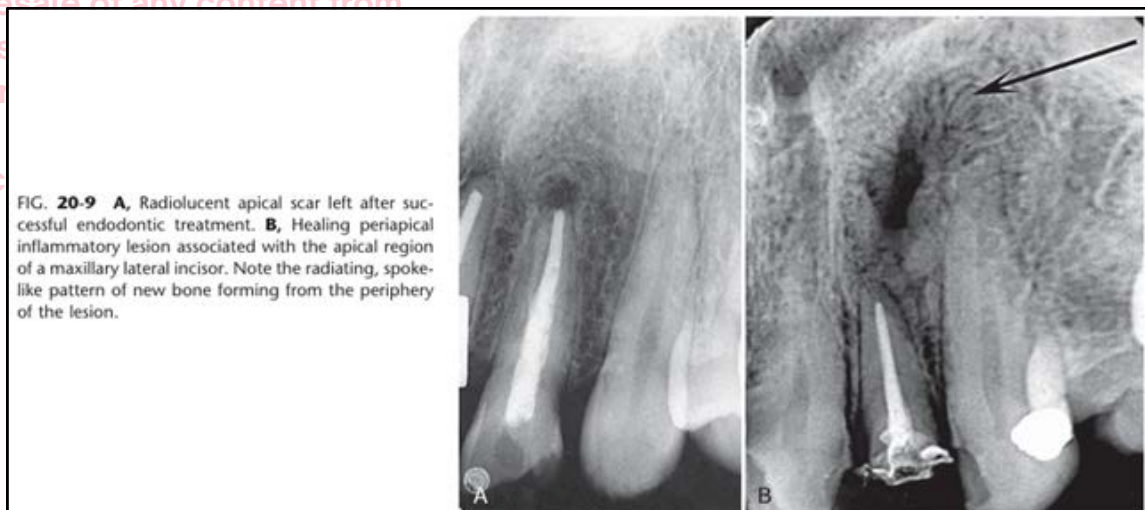
DISCLAIMER



# PERIAPICAL LESIONS

## Differential diagnosis of periapical lesions

- The periapical inflammatory lesions must be most often distinguished from periapical cemental dysplasia (PCD) and an enostosis (dense bone island, osteosclerosis) at the apex of a tooth.
- Small, radiolucent periapical lesions with a well-defined periphery simulating a cortex may be either periapical granulomas or cysts (radicular cysts).
- Differentiation between these may not be possible radiographically, unless other characteristics of a cyst, such as displacement of adjacent structures and expansion of the outer cortical boundaries of the jaw, are present. Lesions larger than 1 cm in diameter usually are radicular cysts.
- If the patient has had endodontic treatment or apical surgery, a periapical radiolucency may remain that may look like periapical rarefying osteitis.
- In either case the destroyed bone may not be replaced with normal-appearing bone but with dense fibrous scar tissue.



THIS IS COPYRIGHTED CONTENT. Unauthorized use, including screenshots, copying, misuse, reuse, or resale of any content from this app, is strictly prohibited. Our app monitors and records all screenshots and recordings. Violators will face strict legal action.

### DISCLAIMER

THIS IS COPYRIGHTED CONTENT. Unauthorized use, including screenshots, copying, misuse, reuse, or resale of any content from this app, is strictly prohibited. Our app monitors and records all screenshots and recordings. Violators will face strict legal action.

DISCLAIMER  
THIS IS COPYRIGHTED CONTENT. Unauthorized use, including screenshots, copying, misuse, reuse, or resale of any content from this app, is strictly prohibited. Our app monitors and records all screenshots and recordings. Violators will face strict legal action.

this app, is strictly prohibited. Our app monitors and records all screenshots and recordings. Violators will face strict legal action.

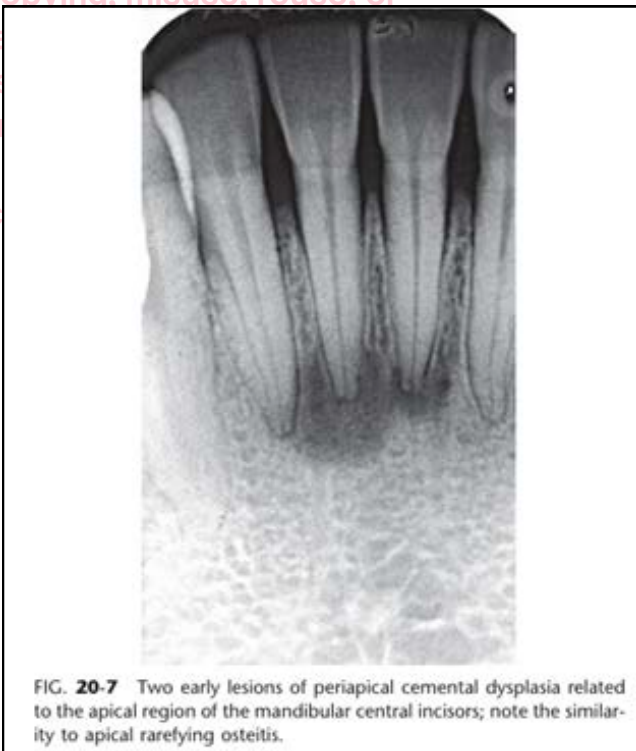
THIS IS COPYRIGHTED CONTENT. Unauthorized use, including screenshots, copying, misuse, reuse, or resale of any content from this app, is strictly prohibited. Our app monitors and records all screenshots and recordings. Violators will face strict legal action.

DISCLAIMER

# PERIAPICAL LESIONS

## Distinguishing features between PCD and periapical inflammatory lesion:

- In the early radiolucent phase of PCD, the radiographic characteristics may not reliably differentiate PCD from a periapical inflammatory lesion and the diagnosis rely solely on the clinical examination, including a **test of tooth vitality**.
- With long standing periapical inflammatory lesions, the pulp chamber of the involved tooth may be wider than the adjacent teeth.
- More mature PCD lesions shows evidence of a dense, radiopaque structure within the radiolucency, which helps in the differential diagnosis.
- Also, a common site for PCD is associated with the apical region of the mandibular anterior teeth. (Periapical inflammatory can be associated with any teeth)
- External root resorption is more common with inflammatory lesions than with PCD.



THIS IS COPYRIGHTED  
CONTENT. Unauthorized use,  
including screenshots,  
copying, misuse, reuse, or  
resale of any content from  
this app, is strictly prohibited.  
Our app monitors and records  
all screenshots and  
recordings. Violators will face  
strict legal action.

### DISCLAIMER

THIS IS COPYRIGHTED CONTENT. Unauthorized use, including screenshots, copying, misuse, reuse, or resale of any content from this app, is strictly prohibited. Our app monitors and records all screenshots and recordings. Violators will face strict legal action.

### DISCLAIMER

THIS IS COPYRIGHTED CONTENT. Unauthorized use, including screenshots, copying, misuse, reuse, or resale of any content from this app, is strictly prohibited. Our app monitors and records all screenshots and recordings. Violators will face strict legal action.

THIS IS COPYRIGHTED  
CONTENT. Unauthorized use,  
including screenshots,  
copying, misuse, reuse, or  
resale of any content from  
this app, is strictly prohibited.  
Our app monitors and records  
all screenshots and  
recordings. Violators will face  
strict legal action.

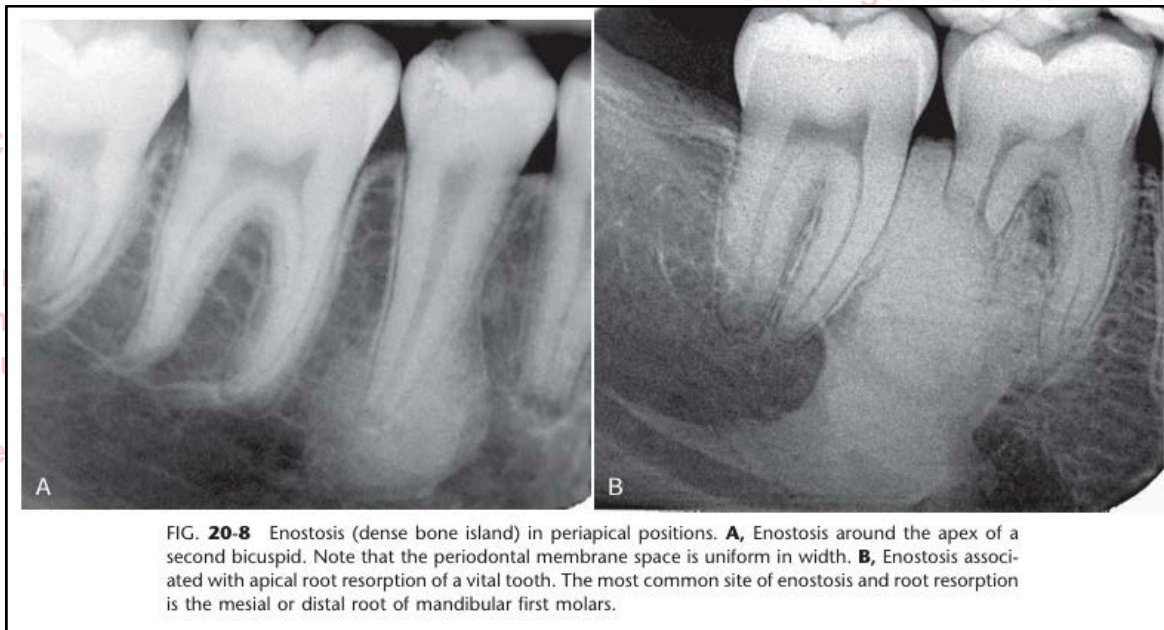
THIS IS COPYRIGHTED CONTENT. Unauthorized use, including screenshots, copying, misuse, reuse, or resale of any content from this app, is strictly prohibited. Our app monitors and records all screenshots and recordings. Violators will face strict legal action.

### DISCLAIMER

# PERIAPICAL LESIONS

## Distinguishing features between Enostosis and periapical inflammatory lesion:

- When enostosis is centered on the root apex, it may mimic an inflammatory lesion. However, the periodontal ligament space around the apex of the tooth has a normal uniform width.
- Also, the periphery of an enostosis usually is well defined and does not blend gradually with surrounding trabeculae.



THIS IS COPYRIGHTED  
CONTENT. Unauthorized use,  
including screenshots,  
copying, misuse, reuse, or  
resale of any content from  
this app, is strictly prohibited.  
Our app monitors and records  
all screenshots and  
recordings. Violators will face  
strict legal action.

### DISCLAIMER

THIS IS COPYRIGHTED CONTENT. Unauthorized use, including screenshots, copying, misuse, reuse, or resale of any content from this app, is strictly prohibited. Our app monitors and records all screenshots and recordings. Violators will face strict legal action.

### DISCLAIMER

THIS IS COPYRIGHTED CONTENT. Unauthorized use, including screenshots, copying, misuse, reuse, or resale of any content from this app, is strictly prohibited. Our app monitors and records all screenshots and recordings. Violators will face strict legal action.

THIS IS COPYRIGHTED  
CONTENT. Unauthorized use,  
including screenshots,  
copying, misuse, reuse, or  
resale of any content from  
this app, is strictly prohibited.  
Our app monitors and records  
all screenshots and  
recordings. Violators will face  
strict legal action.

including screenshots,  
copying, misuse, reuse, or  
resale of any content from  
this app, is strictly prohibited.  
Our app monitors and records  
all screenshots and  
recordings. Violators will face  
strict legal action.

THIS IS COPYRIGHTED CONTENT. Unauthorized use, including screenshots, copying, misuse, reuse, or resale of any content from this app, is strictly prohibited. Our app monitors and records all screenshots and recordings. Violators will face strict legal action.

DISCLAIMER



# JAW CYSTS, TUMORS, RADIOLUCENT LESIONS

(Source- Oral Radiology PRINCIPLES and INTERPRETATION Sixth Edition STUART C. WHITE, MICHAEL J. PHAROAH)

## 1) Inflammatory lesions of Jaw

- Inflammatory lesions are by far the most common pathologic condition of the jaws.

### a) PERICORONITIS (Operculitis)

- The term pericoronitis refers to inflammation of the tissues surrounding the crown of a partially erupted tooth.
- It is most often seen in association with the mandibular third molars in young adults.
- The gingiva surrounding the erupted portion of the crown becomes inflamed when food or microbial debris becomes trapped under the soft tissue.

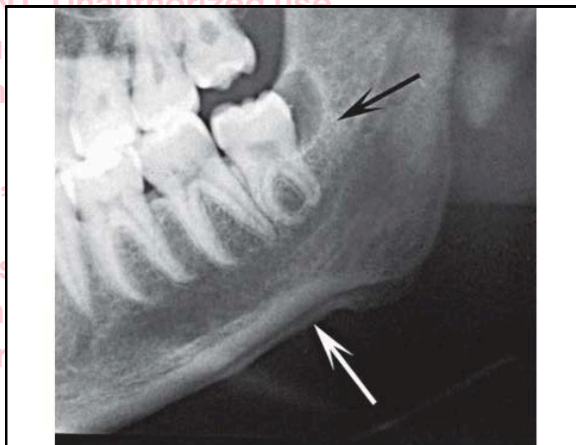


FIG. 20-10 Cropped panoramic view of a case of pericoronitis related to a partially erupted third molar. Note the sclerotic bone reaction adjacent to the follicular cortex (black arrow) and the periosteal reaction (white arrow).

- The radiologic signs of pericoronitis can range from no changes when the inflammatory lesion is confined to the soft tissues to localized rarefaction and sclerosis to osteomyelitis in the most severe cases.
- When bone changes are associated with pericoronitis, they are centered on the follicular space or the portion of the crown still embedded in bone or in close proximity to bone. The mandibular third molar region is the most common location
- The periphery of pericoronitis is ill defined, with a gradual transition of the normal trabecular pattern into a sclerotic region.
- The internal structure of bone adjacent to the pericoronitis most often is sclerotic with thick trabeculae.
- An area of bone loss or radiolucency immediately adjacent to the crown that enlarges the follicular space may be seen.
- As with the periapical inflammatory lesions, pericoronitis may cause the typical changes of sclerosis and rarefaction of surrounding bone.
- In extensive cases, evidence of periosteal new bone formation may be seen at the inferior cortex, the posterior border of the ramus, and along the coronoid notch of the mandible.

#### DISCLAIMER

THIS IS COPYRIGHTED CONTENT. Unauthorized use, including screenshots, copying, misuse, reuse, or resale of any content from this app, is strictly prohibited. Our app monitors and records all screenshots and recordings. Violators will face strict legal action.

#### DISCLAIMER

THIS IS COPYRIGHTED CONTENT. Unauthorized use, including screenshots, copying, misuse, reuse, or resale of any content from this app, is strictly prohibited. Our app monitors and records all screenshots and recordings. Violators will face strict legal action.

THIS IS COPYRIGHTED CONTENT. Unauthorized use, including screenshots, copying, misuse, reuse, or resale of any content from this app, is strictly prohibited. Our app monitors and records all screenshots and recordings. Violators will face strict legal action.

#### DISCLAIMER

# JAW CYSTS, TUMORS, RADIOLUCENT LESIONS

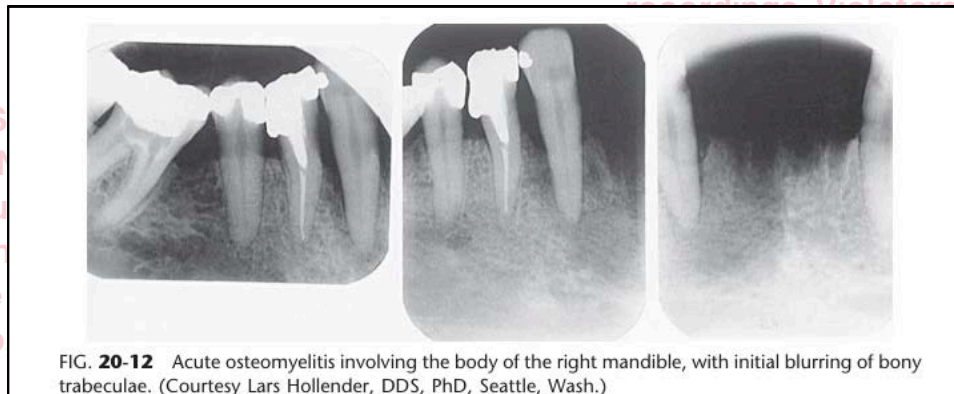
(Source- Oral Radiology PRINCIPLES and INTERPRETATION Sixth Edition STUART C. WHITE, MICHAEL J. PHAROAH)

## 1) Inflammatory lesions of Jaw

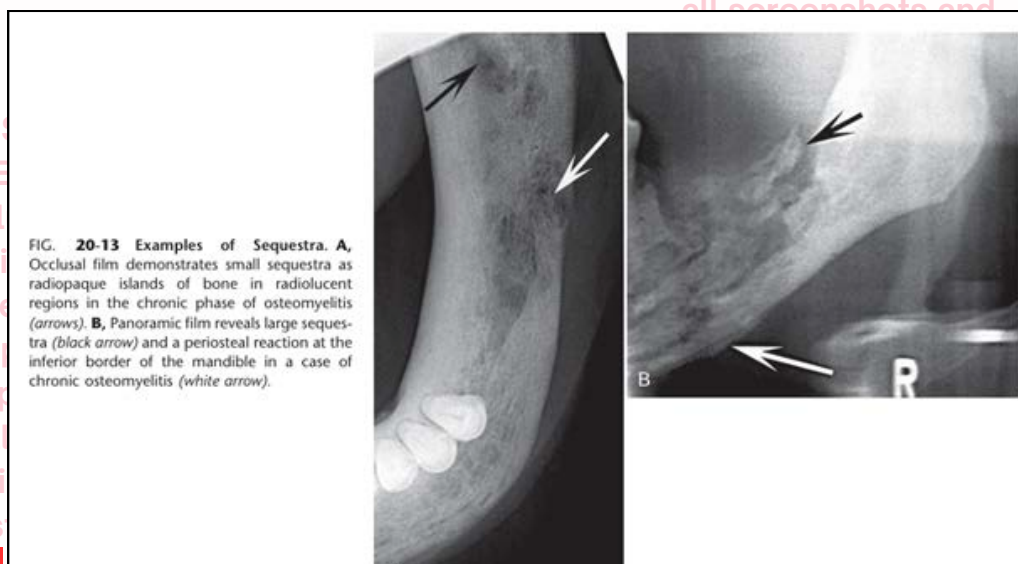
- Inflammatory lesions are by far the most common pathologic condition of the jaws.

### b) OSTEOMYELITIS

- Osteomyelitis is an inflammation of bone.
- The inflammatory process may spread through the bone to involve the marrow, cortex, cancellous portion, and periosteum.



- The first radiographic evidence of the acute form of osteomyelitis is a slight decrease in the density of the involved bone, with a loss of sharpness of the existing trabeculae.
- In time the bone destruction becomes more profound, resulting in an area of radiolucency in one focal area or in scattered regions throughout the involved bone.
- Later, the appearance of sclerotic regions becomes apparent.
- Sequestra may be present but usually are more apparent and numerous in chronic forms. It can be identified by closely inspecting a region of bone destruction (radiolucency) for an island of bone. This island of nonvital bone may vary in size from a small dot (smaller sequestra usually are seen in young patients) to larger segments of radiopaque bone.



DISCLAIMER

THIS IS COPYRIGHTED CONTENT. Unauthorized use, including screenshots, copying, misuse, reuse, or resale of any content from this app, is strictly prohibited. Our app monitors and records all screenshots and recordings. Violators will face strict legal action.

DISCLAIMER

THIS IS COPYRIGHTED CONTENT. Unauthorized use, including screenshots, copying, misuse, reuse, or resale of any content from this app, is strictly prohibited. Our app monitors and records all screenshots and recordings. Violators will face strict legal action.

THIS IS COPYRIGHTED CONTENT. Unauthorized use, including screenshots, copying, misuse, reuse, or resale of any content from this app, is strictly prohibited. Our app monitors and records all screenshots and recordings. Violators will face strict legal action.

DISCLAIMER

# JAW CYSTS, TUMORS, RADIOLOUCENT LESIONS

(Source- Oral Radiology PRINCIPLES and INTERPRETATION Sixth Edition STUART C. WHITE, MICHAEL J. PHAROAH)

## 1) Inflammatory lesions of Jaw

- Inflammatory lesions are by far the most common pathologic condition of the jaws.

### b) OSTEOMYELITIS

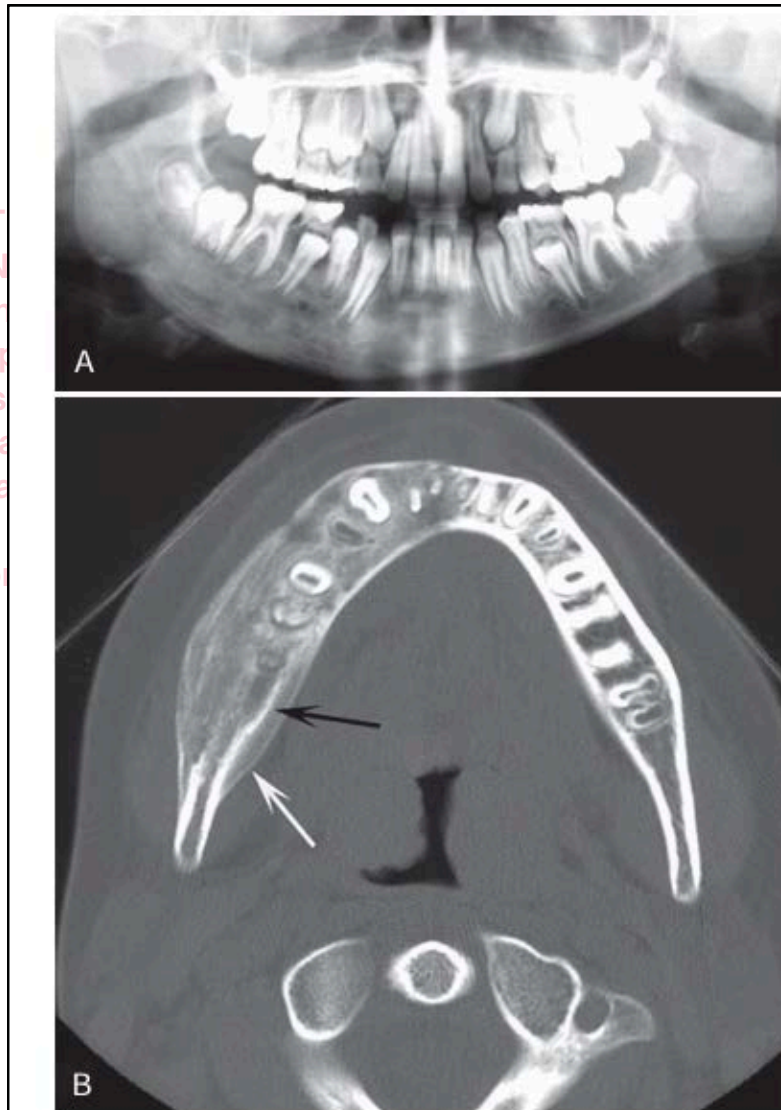


FIG. 20-16 Chronic osteomyelitis. **A**, This panoramic film demonstrates chronic osteomyelitis of the patient's right mandible; note the increase in density and size of the right mandible compared with the left side. **B**, An axial CT image using bone window of the mandible of the same case. Note the increase in bone density, width of the mandible, and the new periosteal bone formation (white arrow) and evidence of the original cortex (black arrow).

THIS IS COPYRIGHTED CONTENT. Unauthorized use, copying, misuse, reuse, or resale of any content from this app, is strictly prohibited.

Violators and records screenshots and recordings. Violators will face legal action.

**DISCLAIMER**  
THIS IS COPYRIGHTED CONTENT. Unauthorized use, including screenshots, copying, misuse, reuse, or resale of any content from this app, is strictly prohibited. Our app monitors and records all screenshots and recordings. Violators will face strict legal action.

COPYRIGHTED  
Unauthorized use, screenshots, misuse, reuse, or any content from this app, is strictly prohibited. Violators and records screenshots and recordings. Violators will face legal action.

#### DISCLAIMER

THIS IS COPYRIGHTED CONTENT. Unauthorized use, including screenshots, copying, misuse, reuse, or resale of any content from this app, is strictly prohibited. Our app monitors and records all screenshots and recordings. Violators will face strict legal action.



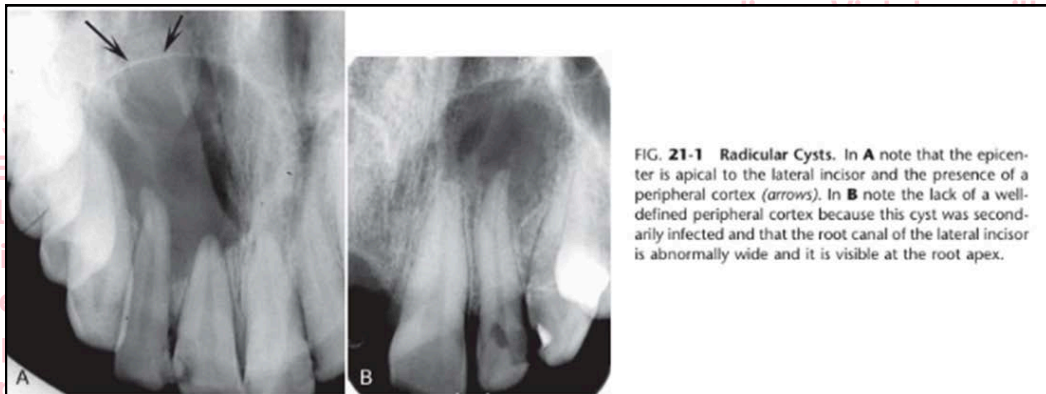
# JAW CYSTS, TUMORS, RADIOLUCENT LESIONS

(Source- Oral Radiology PRINCIPLES and INTERPRETATION Sixth Edition STUART C. WHITE, MICHAEL J. PHAROAH)

## 2) Cysts of jaw

### a) Radicular Cysts:

- In most cases the epicenter of a radicular cyst is located approximately at the apex of a nonvital tooth.
- Occasionally it appears on the mesial or distal surface of a tooth root, at the opening of an accessory canal, or infrequently in a deep periodontal pocket.



- The periphery usually has a well-defined cortical border. If the cyst becomes secondarily infected, the inflammatory reaction of the surrounding bone may result in loss of this cortex or alteration of the cortex into a more sclerotic border.
- In most cases the internal structure of radicular cysts is radiolucent.
- Occasionally, dystrophic calcification may develop in long-standing cysts, appearing as sparsely distributed, small particulate radiopacities.
- If a radicular cyst is large, displacement and resorption of the roots of adjacent teeth may occur.
- The resorption pattern may have a curved outline. In rare cases the cyst may resorb the roots of the related nonvital tooth.
- The cyst may invaginate the antrum, but there should be evidence of a cortical boundary between the contents of the cyst and the internal structure of the antrum.

THIS IS COPYRIGHTED  
CONTENT. Unauthorized use,  
including screenshots,  
copying, misuse, reuse, or  
resale of any content from  
this app, is strictly prohibited.  
Our app monitors and records  
all screenshots and  
recordings. Violators will face  
strict legal action.

#### DISCLAIMER

THIS IS COPYRIGHTED CONTENT. Unauthorized use, including screenshots, copying, misuse, reuse, or resale of any content from this app, is strictly prohibited. Our app monitors and records all screenshots and recordings. Violators will face strict legal action.

#### DISCLAIMER

THIS IS COPYRIGHTED CONTENT. Unauthorized use, including screenshots, copying, misuse, reuse, or resale of any content from this app, is strictly prohibited. Our app monitors and records all screenshots and recordings. Violators will face strict legal action.

THIS IS COPYRIGHTED CONTENT. Unauthorized use, including screenshots, copying, misuse, reuse, or resale of any content from this app, is strictly prohibited. Our app monitors and records all screenshots and recordings. Violators will face strict legal action.

#### DISCLAIMER

# JAW CYSTS, TUMORS, RADIOLUCENT LESIONS

(Source- Oral Radiology PRINCIPLES and INTERPRETATION Sixth Edition STUART C. WHITE, MICHAEL J. PHAROAH)

## 2) Cysts of jaw

### a) Radicular Cysts:

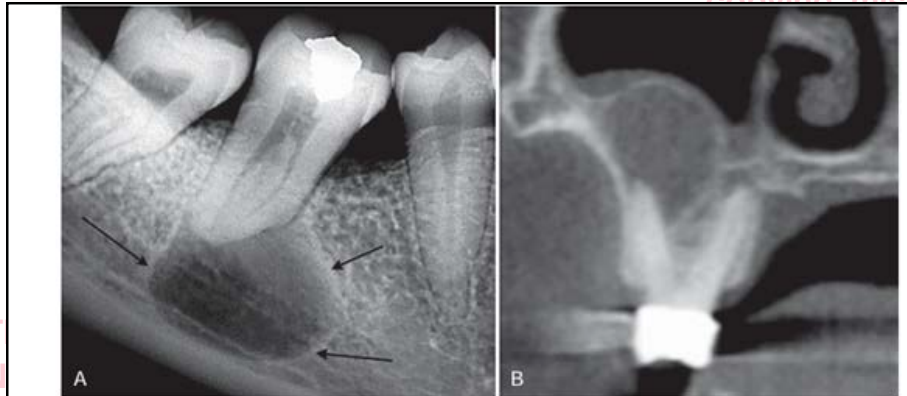


FIG. 21-2 **A**, A periapical film of a radicular cyst reveals a lesion with a well-defined cortical boundary (arrows). Note that the presence of the inferior cortex of the mandible has influenced the circular shape of the cyst. **B**, A coronal cone beam CT image of a radicular cyst related to the buccal root of a maxillary molar. Note the circular shape of the cyst as it invaginates the maxillary sinus. (Courtesy

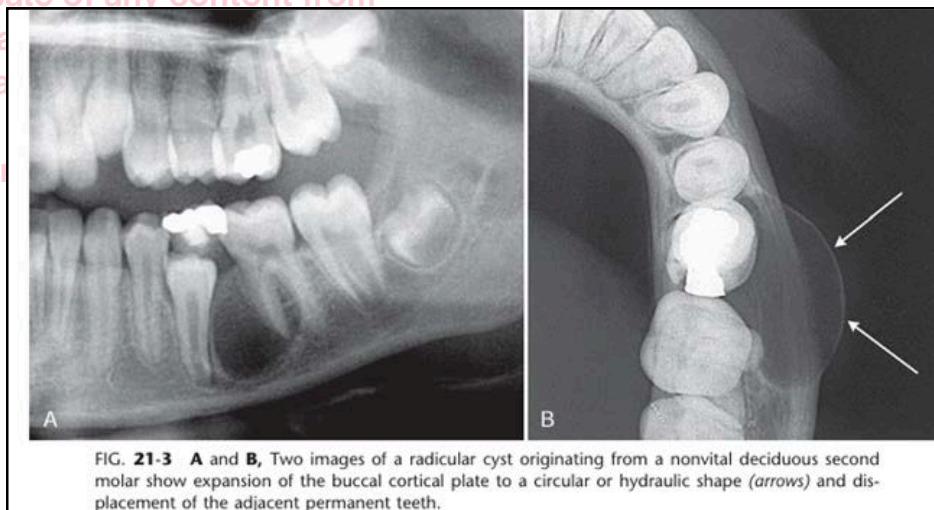


FIG. 21-3 **A** and **B**, Two images of a radicular cyst originating from a nonvital deciduous second molar show expansion of the buccal cortical plate to a circular or hydraulic shape (arrows) and displacement of the adjacent permanent teeth.

THIS IS COPYRIGHTED  
CONTENT. Unauthorized use,  
including screenshots,  
copying, misuse, reuse, or  
resale of any content from  
this app, is strictly prohibited.  
Our app monitors and records  
all screenshots and  
recordings. Violators will face  
strict legal action.

#### DISCLAIMER

THIS IS COPYRIGHTED CONTENT. Unauthorized use, including screenshots, copying, misuse, reuse, or resale of any content from this app, is strictly prohibited. Our app monitors and records all screenshots and recordings. Violators will face strict legal action.

#### DISCLAIMER

THIS IS COPYRIGHTED CONTENT. Unauthorized use, including screenshots, copying, misuse, reuse, or resale of any content from this app, is strictly prohibited. Our app monitors and records all screenshots and recordings. Violators will face strict legal action.

THIS IS COPYRIGHTED  
CONTENT. Unauthorized use,  
including screenshots,  
copying, misuse, reuse, or  
resale of any content from  
this app, is strictly prohibited.  
Our app monitors and records  
all screenshots and  
recordings. Violators will face  
strict legal action.

THIS IS COPYRIGHTED CONTENT. Unauthorized use, including screenshots, copying, misuse, reuse, or resale of any content from this app, is strictly prohibited. Our app monitors and records all screenshots and recordings. Violators will face strict legal action.

#### DISCLAIMER

# JAW CYSTS, TUMORS, RADIOLUCENT LESIONS

(Source- Oral Radiology PRINCIPLES and INTERPRETATION Sixth Edition STUART C. WHITE, MICHAEL J. PHAROAH)

## 2) Cysts of jaw

### b) Dentigerous Cyst

- The epicenter of a dentigerous cyst is found just above the crown of the involved tooth, most commonly the mandibular or maxillary third molar or the maxillary canine.
- This cyst attaches at the cementoenamel junction.
- Some dentigerous cysts are eccentric, developing from the lateral aspect of the follicle so that they occupy an area beside the crown instead of above the crown.
- Dentigerous cysts typically have a well-defined cortex with a curved or circular outline. If infection is present, the cortex may be missing. The internal aspect is completely radiolucent except for the crown of the involved tooth.

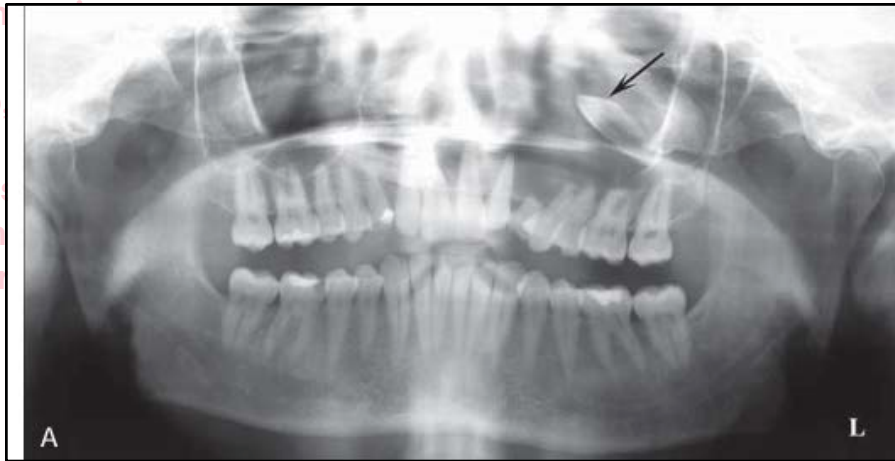


Image: Large dentigerous cyst associated with maxillary left canine which has been displaced.

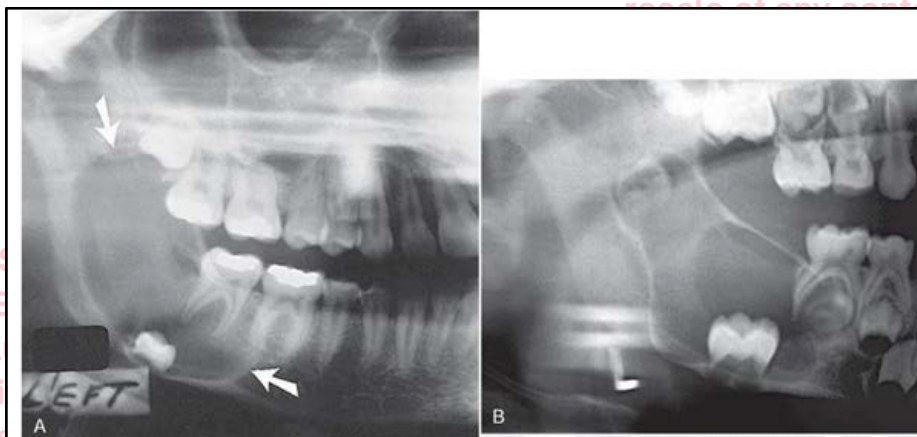


Image: Dentigerous teeth displacing the teeth.

#### DISCLAIMER

THIS IS COPYRIGHTED CONTENT. Unauthorized use, including screenshots, copying, misuse, reuse, or resale of any content from this app, is strictly prohibited. Our app monitors and records all screenshots and recordings. Violators will face strict legal action.

#### DISCLAIMER

THIS IS COPYRIGHTED CONTENT. Unauthorized use, including screenshots, copying, misuse, reuse, or resale of any content from this app, is strictly prohibited. Our app monitors and records all screenshots and recordings. Violators will face strict legal action.

THIS IS COPYRIGHTED CONTENT. Unauthorized use, including screenshots, copying, misuse, reuse, or resale of any content from this app, is strictly prohibited. Our app monitors and records all screenshots and recordings. Violators will face strict legal action.



# JAW CYSTS, TUMORS, RADIOLUCENT LESIONS

(Source- Oral Radiology PRINCIPLES and INTERPRETATION Sixth Edition STUART C. WHITE, MICHAEL J. PHAROAH)

## 2) Cysts of jaw

### c) Odontogenic kerato-cyst: (KOT)

- The most common location of KOT (kerato-cystic odontogenic tumor) is the posterior body of the mandible (90% occur posterior to the canines) and ramus (more than 50%)
- The epicenter is located superior to the inferior alveolar nerve canal.
- This type of cyst occasionally has the same pericoronal position as, and is indistinguishable from, a dentigerous cyst.
- KOTs usually show evidence of a cortical border unless they have become secondarily infected.
- The internal structure is most commonly radiolucent. The presence of internal keratin does not increase the radiopacity.
- In some cases, curved internal septa may be present, giving the lesion a multilocular appearance.
- An important characteristic of the KOT is its propensity to grow along the internal aspect of the jaws, causing minimal expansion.
- This occurs throughout the mandible except for the upper ramus and coronoid process, where considerable expansion may occur.

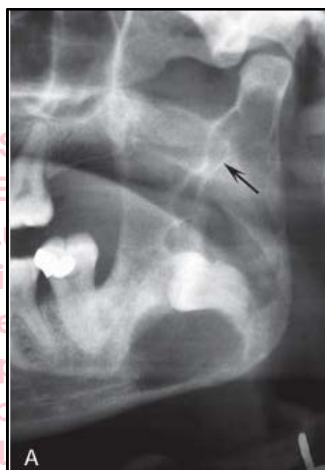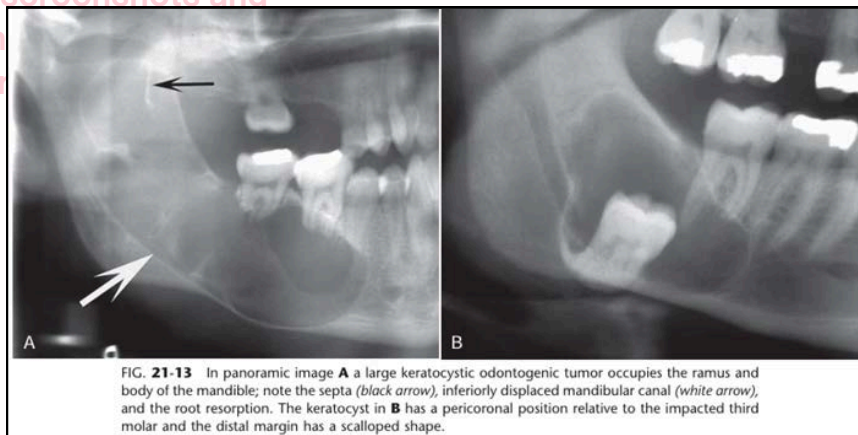


Image: keratocystic odontogenic tumor occupying the mandibular ramus; note the septa (arrow)

DISCLAIMER

THIS IS COPYRIGHTED CONTENT. Unauthorized use, including screenshots, copying, misuse, reuse, or resale of any content from this app, is strictly prohibited. Our app monitors and records all screenshots and recordings. Violators will face strict legal action.

DISCLAIMER

THIS IS COPYRIGHTED CONTENT. Unauthorized use, including screenshots, copying, misuse, reuse, or resale of any content from this app, is strictly prohibited. Our app monitors and records all screenshots and recordings. Violators will face strict legal action.

THIS IS COPYRIGHTED CONTENT. Unauthorized use, including screenshots, copying, misuse, reuse, or resale of any content from this app, is strictly prohibited. Our app monitors and records all screenshots and recordings. Violators will face strict legal action.

DISCLAIMER

# JAW CYSTS, TUMORS, RADIOLUCENT LESIONS

(Source- Oral Radiology PRINCIPLES and INTERPRETATION Sixth Edition STUART C. WHITE, MICHAEL J. PHAROAH)

## 2) Cysts of jaw

### c) Odontogenic kerato-cyst: (KOT)

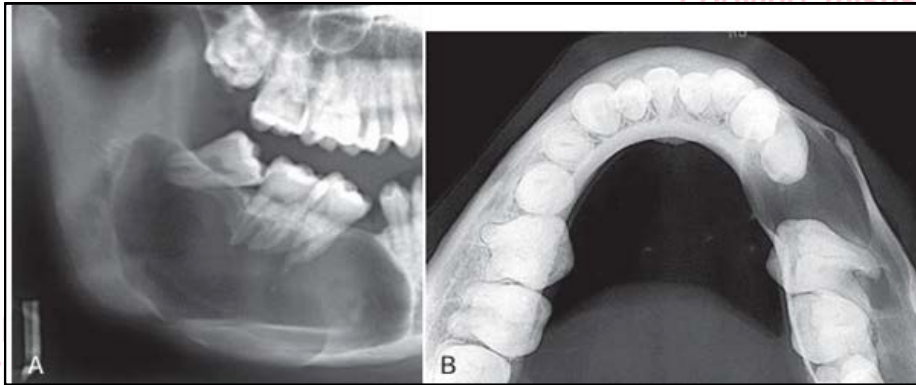


Image: (A) A large (KOT) occupying most of the right body and ramus of the mandible. (B) Despite the large size, the buccal and lingual cortical plates of the mandible have been expanded only slightly, as seen in the occlusal film.

### d) Lateral Periodontal Cyst

- A total of 50% to 75% of lateral periodontal cysts develop in the mandible, mostly in a region extending from the lateral incisor to the second premolar.
- A lateral periodontal cyst appears as a well-defined radiolucency with a prominent cortical boundary and a round or oval shape.
- The internal aspect usually is radiolucent.
- The botryoid variety may have a multilocular appearance, although this aspect is related more to the histologic appearance.

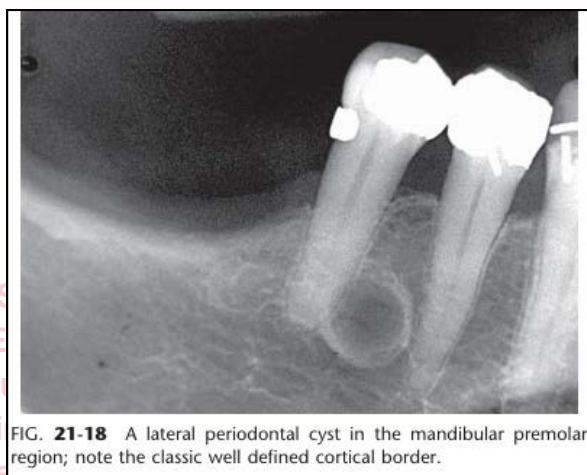


FIG. 21-18 A lateral periodontal cyst in the mandibular premolar region; note the classic well defined cortical border.

DISCLAIMER

THIS IS COPYRIGHTED CONTENT. Unauthorized use, including screenshots, copying, misuse, reuse, or resale of any content from this app, is strictly prohibited. Our app monitors and records all screenshots and recordings. Violators will face strict legal action.

DISCLAIMER

THIS IS COPYRIGHTED CONTENT. Unauthorized use, including screenshots, copying, misuse, reuse, or resale of any content from this app, is strictly prohibited. Our app monitors and records all screenshots and recordings. Violators will face strict legal action.

THIS IS COPYRIGHTED CONTENT. Unauthorized use, including screenshots, copying, misuse, reuse, or resale of any content from this app, is strictly prohibited. Our app monitors and records all screenshots and recordings. Violators will face strict legal action.

DISCLAIMER

# JAW CYSTS, TUMORS, RADIOLUCENT LESIONS

(Source- Oral Radiology PRINCIPLES and INTERPRETATION Sixth Edition STUART C. WHITE, MICHAEL J. PHAROAH)

## 2) Cysts of jaw

### e) Calcifying Cystic Odontogenic Tumor

- At least 75% of CCOTs occur in bone, with a nearly equal distribution between the jaws.
- Most (75%) occur anterior to the first molar, especially associated with cuspids and incisors, where the cyst sometimes manifests as a peri-coronal radiolucency.
- The periphery can vary from well- defined and corticated with a curved, cyst like shape to ill-defined and irregular.
- The internal aspect can vary in appearance. It may be completely radiolucent, it may show evidence of small foci of calcified material that appear as white flecks or small smooth pebbles or it may show even larger, solid, amorphous masses.
- In rare cases the lesion may appear multilocular.
- Occasionally (20% to 50% of cases) this tumor is associated with a tooth (most commonly a cuspid) and impedes its eruption.
- Displacement of teeth and resorption of roots may occur. Perforation of the cortical plate may be seen radiographically with enlarging lesions.

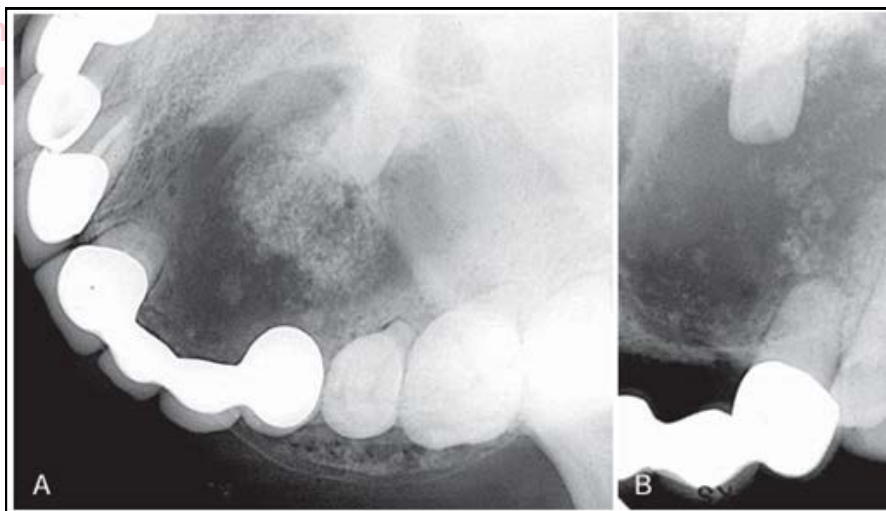


Image: A and B, Calcifying cystic odontogenic tumor (CCOT) related to the lateral incisor with well-defined corticated border, internal calcifications, and resorption of part of the root of the central incisor.

**DISCLAIMER**

THIS IS COPYRIGHTED CONTENT. Unauthorized use, including screenshots, copying, misuse, reuse, or resale of any content from this app, is strictly prohibited. Our app monitors and records all screenshots and recordings. Violators will face strict legal action.

**DISCLAIMER**

THIS IS COPYRIGHTED CONTENT. Unauthorized use, including screenshots, copying, misuse, reuse, or resale of any content from this app, is strictly prohibited. Our app monitors and records all screenshots and recordings. Violators will face strict legal action.

THIS IS COPYRIGHTED CONTENT. Unauthorized use, including screenshots, copying, misuse, reuse, or resale of any content from this app, is strictly prohibited. Our app monitors and records all screenshots and recordings. Violators will face strict legal action.

**DISCLAIMER**



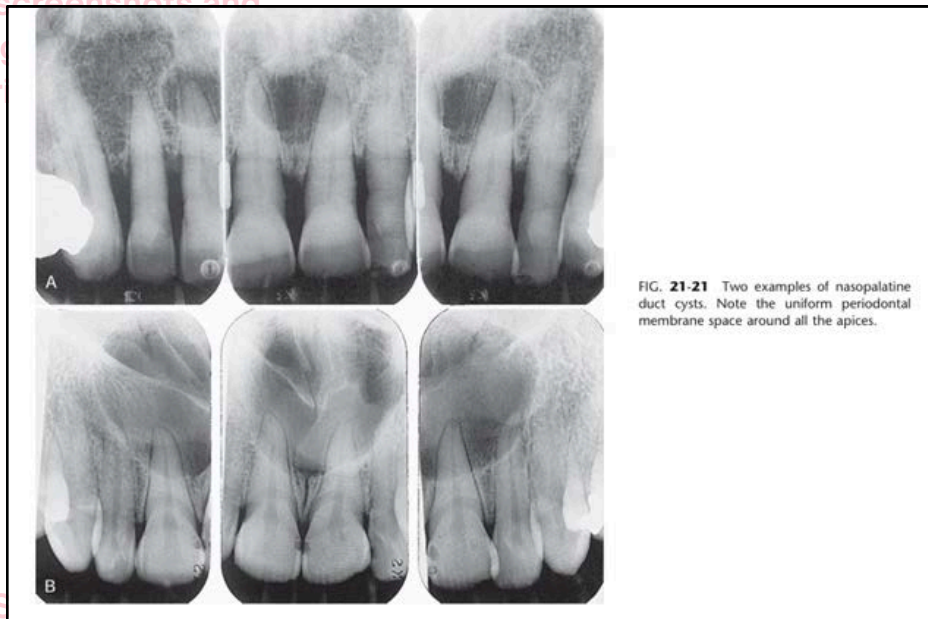# JAW CYSTS, TUMORS, RADIOLUCENT LESIONS

(Source- Oral Radiology PRINCIPLES and INTERPRETATION Sixth Edition STUART C. WHITE, MICHAEL J. PHAROAH)

## 2) Cysts of jaw

### f) Nasopalatine Duct Cyst

- AKA incisive canal cyst, nasopalatine cyst, median palatine cyst, and median anterior maxillary cyst.
- Most nasopalatine duct cysts are found in the nasopalatine foramen or canal.
- However, if this cyst extends posteriorly to involve the hard palate, it often is referred to as a median palatal cyst.
- If it expands anteriorly between the central incisors, destroying or expanding the labial plate of bone and causing the teeth to diverge, it sometimes is referred to as a median anterior maxillary cyst.
- The periphery usually is well defined and corticated and is circular or oval in shape. The shadow of the nasal spine sometimes is superimposed on the cyst, giving it a **heart shape**.
- Most nasopalatine duct cysts are totally radiolucent.
- Some rare cysts may have internal dystrophic calcifications, which may appear as ill-defined, amorphous, scattered radiopacities.



#### DISCLAIMER

THIS IS COPYRIGHTED CONTENT. Unauthorized use, including screenshots, copying, misuse, reuse, or resale of any content from this app, is strictly prohibited. Our app monitors and records all screenshots and recordings. Violators will face strict legal action.

#### DISCLAIMER

THIS IS COPYRIGHTED CONTENT. Unauthorized use, including screenshots, copying, misuse, reuse, or resale of any content from this app, is strictly prohibited. Our app monitors and records all screenshots and recordings. Violators will face strict legal action.

THIS IS COPYRIGHTED CONTENT. Unauthorized use, including screenshots, copying, misuse, reuse, or resale of any content from this app, is strictly prohibited. Our app monitors and records all screenshots and recordings. Violators will face strict legal action.

#### DISCLAIMER

# JAW CYSTS, TUMORS, RADIOLUCENT LESIONS

(Source- Oral Radiology PRINCIPLES and INTERPRETATION Sixth Edition STUART C. WHITE, MICHAEL J. PHAROAH)

## 2) Cysts of jaw

### g) Simple Bone Cyst:

- AKA Traumatic bone cyst, hemorrhagic bone cyst, extravasation cyst, progressive bone cavity, solitary bone cyst.
- Almost all SBCs are found in the mandible in rare cases they develop in the maxilla.
- The lesion can occur anywhere in the mandible but is seen most often in the ramus and posterior mandible in older patients.
- SBCs also frequently occur with cemento-osseous and fibrous dysplasia.
- The margin may vary from a well-defined, delicate cortex to an ill-defined border that blends into the surrounding bone.
- The boundary usually is better defined in the alveolar process around the teeth than in the inferior aspect of the body of the mandible.
- The shape most often is smooth and curved, like a cyst, with an oval or **scalloped border**. The lesion **often scallops** between the roots of the teeth.
- The internal structure is totally radiolucent, but occasionally it may appear multilocular, although the lesion does not contain true septa.
- This appearance is the result of pronounced scalloping of the endosteal surface of either the buccal or lingual plate.

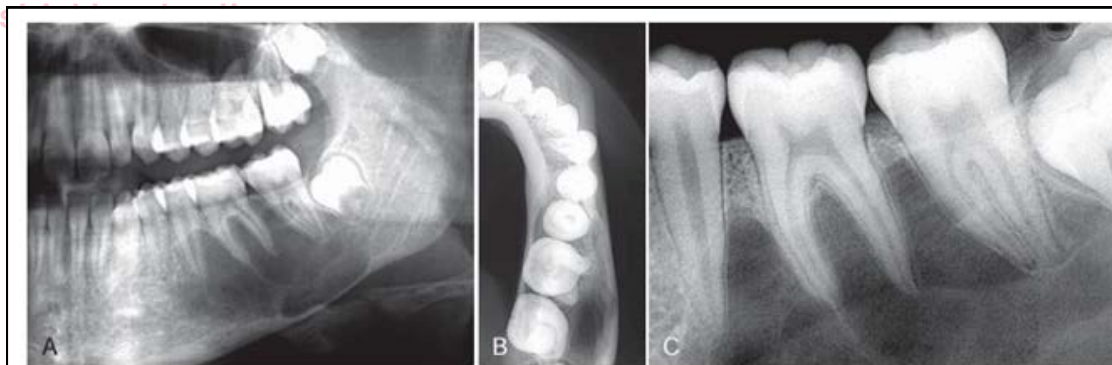


FIG. 21-27 A panoramic film demonstrating an SBC (A), an occlusal film (B), and a periapical film (C). The occlusal film shows that no expansion has occurred in the buccal or lingual cortical plates. Except for the superior border, the borders are ill defined and the lesion has scalloped around the teeth and thinned the inferior border of the mandible, but the lamina dura is still present.

THIS IS COPYRIGHTED CONTENT. Unauthorized use, including screenshots, copying, misuse, reuse, or resale of any content from this app, is strictly prohibited. Our app monitors and records all screenshots and recordings. Violators will face strict legal action.

#### DISCLAIMER

THIS IS COPYRIGHTED CONTENT. Unauthorized use, including screenshots, copying, misuse, reuse, or resale of any content from this app, is strictly prohibited. Our app monitors and records all screenshots and recordings. Violators will face strict legal action.

DISCLAIMER  
THIS IS COPYRIGHTED CONTENT. Unauthorized use, including screenshots, copying, misuse, reuse, or resale of any content from this app, is strictly prohibited. Our app monitors and records all screenshots and recordings. Violators will face strict legal action.

THIS IS COPYRIGHTED CONTENT. Unauthorized use, including screenshots, copying, misuse, reuse, or resale of any content from this app, is strictly prohibited. Our app monitors and records all screenshots and recordings. Violators will face strict legal action.

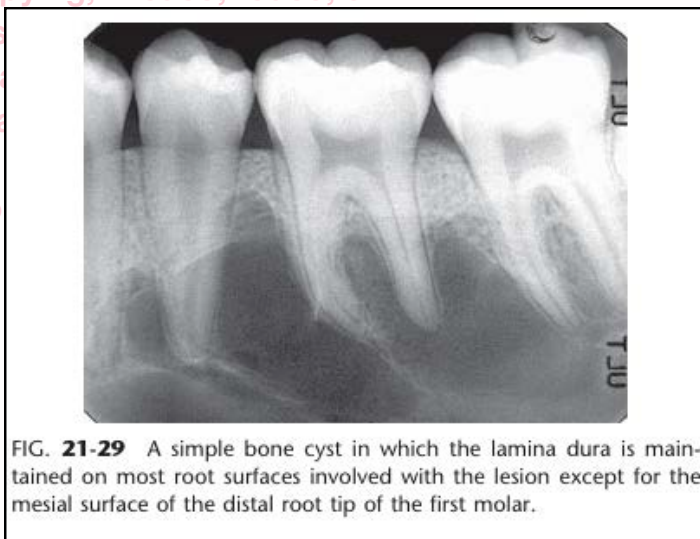
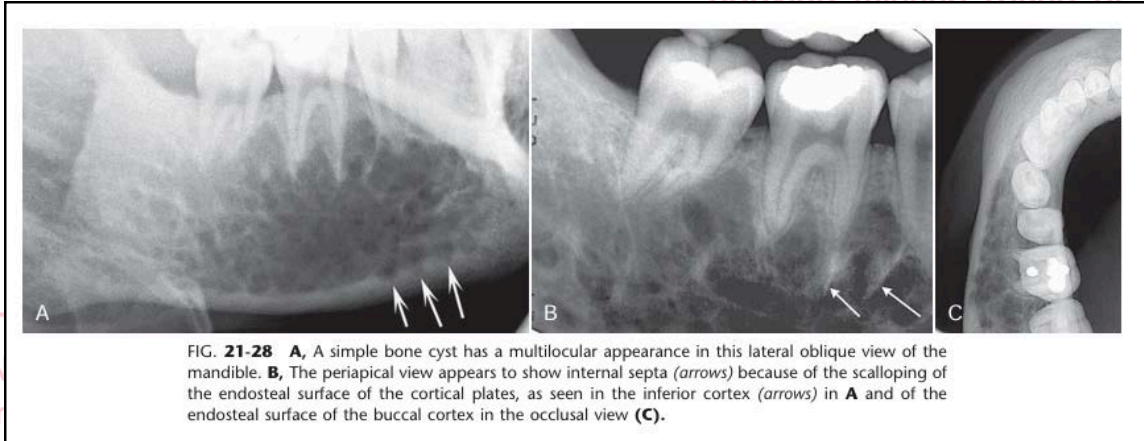
DISCLAIMER

# JAW CYSTS, TUMORS, RADIOLOUCENT LESIONS

(Source- Oral Radiology PRINCIPLES and INTERPRETATION Sixth Edition STUART C. WHITE, MICHAEL J. PHAROAH)

## 2) Cysts of jaw

### g) Simple Bone Cyst:



THIS IS COPYRIGHTED  
CONTENT. Unauthorized use,  
including screenshots,  
copying, misuse, reuse, or  
resale of any content from  
this app, is strictly prohibited.  
Our app monitors and records  
all screenshots and  
recordings. Violators will face  
strict legal action.

#### DISCLAIMER

THIS IS COPYRIGHTED CONTENT. Unauthorized use, including screenshots, copying, misuse, reuse, or resale of any content from this app, is strictly prohibited. Our app monitors and records all screenshots and recordings. Violators will face strict legal action.

#### DISCLAIMER

THIS IS COPYRIGHTED CONTENT. Unauthorized use, including screenshots, copying, misuse, reuse, or resale of any content from this app, is strictly prohibited. Our app monitors and records all screenshots and recordings. Violators will face strict legal action.

THIS IS COPYRIGHTED  
CONTENT. Unauthorized use,  
including screenshots,  
copying, misuse, reuse, or  
resale of any content from  
this app, is strictly prohibited.  
Our app monitors and records  
all screenshots and  
recordings. Violators will face  
strict legal action.



# JAW CYSTS, TUMORS, RADIOLUCENT LESIONS

(Source- Oral Radiology PRINCIPLES and INTERPRETATION Sixth Edition STUART C. WHITE, MICHAEL J. PHAROAH)

## 3) Tumors of Jaw

### a) Ameloblastoma

- Most ameloblastomas (80%) develop in the molar ramus region of the mandible, but they may extend to the symphyseal area.
- Most lesions that occur in the maxilla are in the third molar area and extend into the maxillary sinus and nasal floor.
- In either jaw this tumor can originate in an occlusal position to a developing tooth.
- The ameloblastoma is usually well defined and frequently delineated by a cortical border.
- The border is often curved, and in small lesions the border and shape may be indistinguishable from a cyst.
- The periphery of lesions in the maxilla is usually more ill-defined.
- The internal structure varies from totally radiolucent to mixed with the presence of bony septa creating internal compartments.
- These septa can be straight but are more commonly coarse and curved.
- These septa are often remodeled into curved shapes providing a **honeycomb** (numerous small compartments or loculations) or **soap bubble** (larger compartments of variable size) patterns.
- Generally, the loculations are larger in the posterior mandible and smaller in the anterior mandible.
- In the desmoplastic variety the internal structure can be composed of very irregular sclerotic bone resembling a bone dysplasia or bone-forming tumor.
- There is a pronounced tendency for ameloblastomas to cause **extensive root resorption. Tooth displacement is common.**

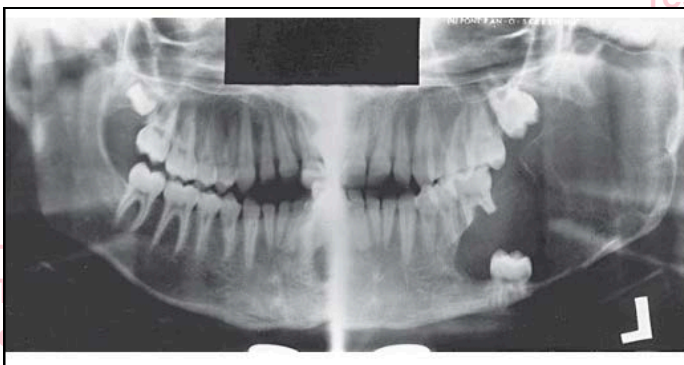


FIG. 22-11 A unicystic ameloblastoma developing occlusal to the left second mandibular molar causing expansion of the mandibular body and ramus to the sigmoid notch and condylar neck and inferior displacement of the mandibular second molar and root resorption of the alveolar left first molar. (Courtesy E. J. Burkes, DDS, Chapel Hill, N.C.)

#### DISCLAIMER

THIS IS COPYRIGHTED CONTENT. Unauthorized use, including screenshots, copying, misuse, reuse, or resale of any content from this app, is strictly prohibited. Our app monitors and records all screenshots and recordings. Violators will face strict legal action.

#### DISCLAIMER

THIS IS COPYRIGHTED CONTENT. Unauthorized use, including screenshots, copying, misuse, reuse, or resale of any content from this app, is strictly prohibited. Our app monitors and records all screenshots and recordings. Violators will face strict legal action.

THIS IS COPYRIGHTED CONTENT. Unauthorized use, including screenshots, copying, misuse, reuse, or resale of any content from this app, is strictly prohibited. Our app monitors and records all screenshots and recordings. Violators will face strict legal action.

#### DISCLAIMER

# JAW CYSTS, TUMORS, RADIOLUCENT LESIONS

(Source- Oral Radiology PRINCIPLES and INTERPRETATION Sixth Edition STUART C. WHITE, MICHAEL J. PHAROAH)

## 3) Tumors of Jaw

### a) Ameloblastoma

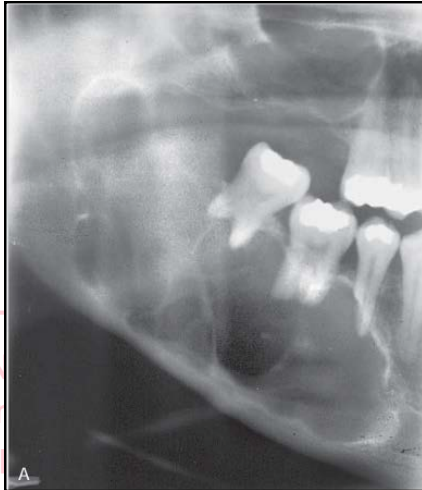

Image: Multilocular Ameloblastoma showing A large lesion in the mandibular body and ramus with a few straight septa.

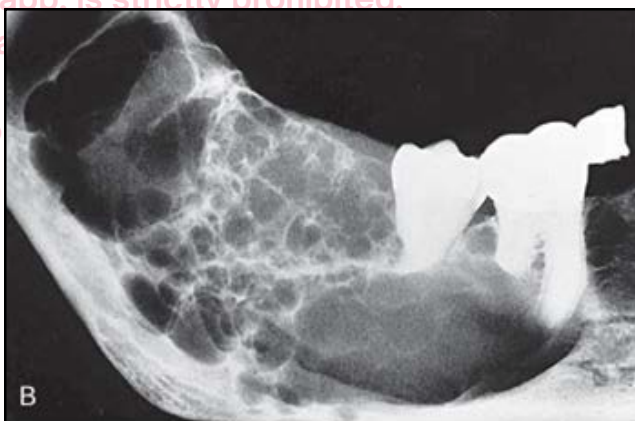

Image: Lateral radiograph of a resected mandibular specimen containing a multilocular ameloblastoma with coarse curved septa.

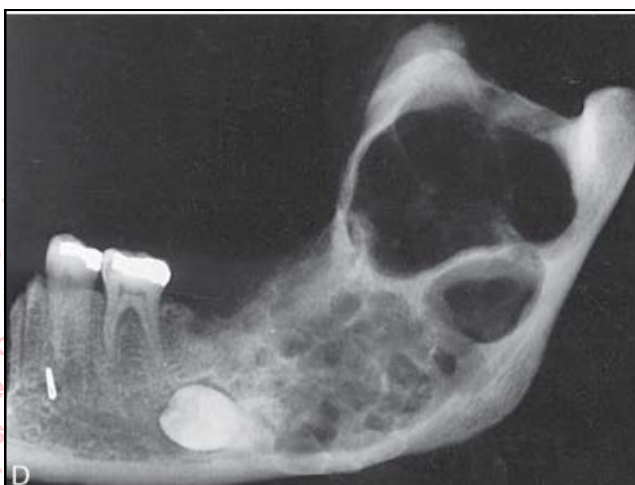


Image: A large multilocular lesion in the right mandibular ramus

THIS IS COPYRIGHTED CONTENT. Unauthorized use, including screenshots, copying, misuse, reuse, or resale of any content from this app, is strictly prohibited. Our app monitors and records all screenshots and recordings. Violators will face strict legal action.

**DISCLAIMER**  
THIS IS COPYRIGHTED CONTENT. Unauthorized use, including screenshots, copying, misuse, reuse, or resale of any content from this app, is strictly prohibited. Our app monitors and records all screenshots and recordings. Violators will face strict legal action.

all screenshots and recordings. Violators will face strict legal action.

#### DISCLAIMER

THIS IS COPYRIGHTED CONTENT. Unauthorized use, including screenshots, copying, misuse, reuse, or resale of any content from this app, is strictly prohibited. Our app monitors and records all screenshots and recordings. Violators will face strict legal action.

**DISCLAIMER**

THIS IS COPYRIGHTED CONTENT. Unauthorized use, including screenshots, copying, misuse, reuse, or resale of any content from this app, is strictly prohibited. Our app monitors and records all screenshots and recordings. Violators will face strict legal action.

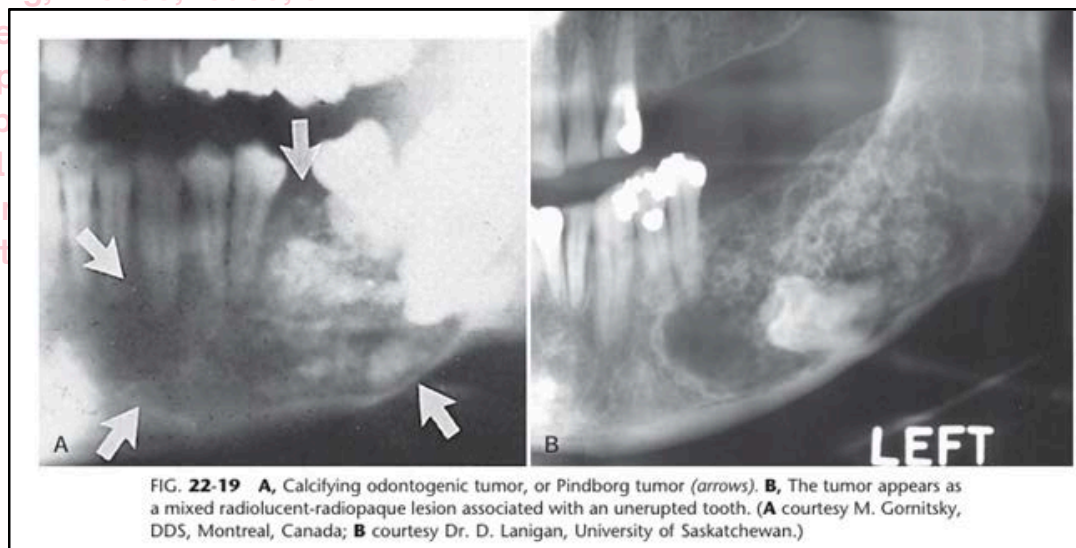
# JAW CYSTS, TUMORS, RADIOLUCENT LESIONS

(Source- Oral Radiology PRINCIPLES and INTERPRETATION Sixth Edition STUART C. WHITE, MICHAEL J. PHAROAH)

## 3) Tumors of Jaw

### b) Calcifying Epithelial Odontogenic Tumor

- AKA Pindborg tumor and ameloblastoma of unusual type with calcification.
- As with ameloblastomas, CEOTs have a definite predilection for the mandible, and most develop in the premolar-molar area, with common association with an unerupted or impacted tooth.
- The border may have a well-defined cyst like cortex.
- In some tumors the boundary may be irregular and ill defined.
- The internal aspect may appear unilocular or multilocular with numerous scattered, radiopaque foci of varying size and density.
- The most characteristic and diagnostic finding is the appearance of radiopacities close to the crown of the embedded tooth.
- CEOTs may displace a developing tooth or prevent its eruption.



THIS IS COPYRIGHTED  
CONTENT. Unauthorized use,  
including screenshots,  
copying, misuse, reuse, or  
resale of any content from  
this app, is strictly prohibited.  
Our app monitors and records  
all screenshots and  
recordings. Violators will face  
strict legal action.

#### DISCLAIMER

THIS IS COPYRIGHTED CONTENT. Unauthorized use, including screenshots, copying, misuse, reuse, or resale of any content from this app, is strictly prohibited. Our app monitors and records all screenshots and recordings. Violators will face strict legal action.

DISCLAIMER  
THIS IS COPYRIGHTED CONTENT. Unauthorized use, including screenshots, copying, misuse, reuse, or resale of any content from this app, is strictly prohibited. Our app monitors and records all screenshots and recordings. Violators will face strict legal action.

DISCLAIMER

THIS IS COPYRIGHTED CONTENT. Unauthorized use, including screenshots, copying, misuse, reuse, or resale of any content from this app, is strictly prohibited. Our app monitors and records all screenshots and recordings. Violators will face strict legal action.



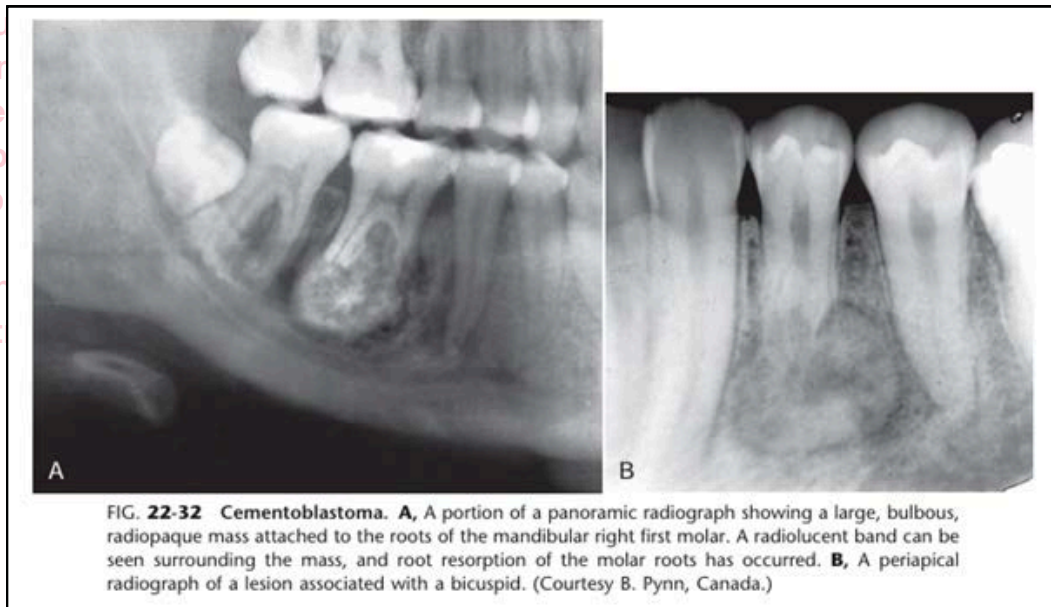
# JAW CYSTS, TUMORS, RADIOLUCENT LESIONS

(Source- Oral Radiology PRINCIPLES and INTERPRETATION Sixth Edition STUART C. WHITE, MICHAEL J. PHAROAH)

## 3) Tumors of Jaw

### c) Benign Cementoblastoma

- Synonyms include Cementoblastoma and true cementoma.
- Benign cementoblastomas occur more often in the mandible (78%) and form most commonly on a premolar or first molar (90%).
- The lesion is a well-defined radiopacity with a cortical border and then a well-defined radiolucent band just inside the cortical border.
- Benign cementoblastomas are mixed radiolucent-radiopaque lesions where the majority of the internal structure is radiopaque.
- The resulting pattern may be amorphous or may have a wheel spoke pattern.



THIS IS COPYRIGHTED  
CONTENT. Unauthorized use,  
including screenshots,  
copying, misuse, reuse, or  
resale of any content from  
this app, is strictly prohibited.  
Our app monitors and records  
all screenshots and  
recordings. Violators will face  
strict legal action.

#### DISCLAIMER

THIS IS COPYRIGHTED CONTENT. Unauthorized use, including screenshots, copying, misuse, reuse, or resale of any content from this app, is strictly prohibited. Our app monitors and records all screenshots and recordings. Violators will face strict legal action.

DISCLAIMER  
THIS IS COPYRIGHTED CONTENT. Unauthorized use, including screenshots, copying, misuse, reuse, or resale of any content from this app, is strictly prohibited. Our app monitors and records all screenshots and recordings. Violators will face strict legal action.

this app, is strictly prohibited.  
Our app monitors and records  
all screenshots and  
recordings. Violators will face  
strict legal action.

THIS IS COPYRIGHTED CONTENT. Unauthorized use, including screenshots, copying, misuse, reuse, or resale of any content from this app, is strictly prohibited. Our app monitors and records all screenshots and recordings. Violators will face strict legal action.

DISCLAIMER